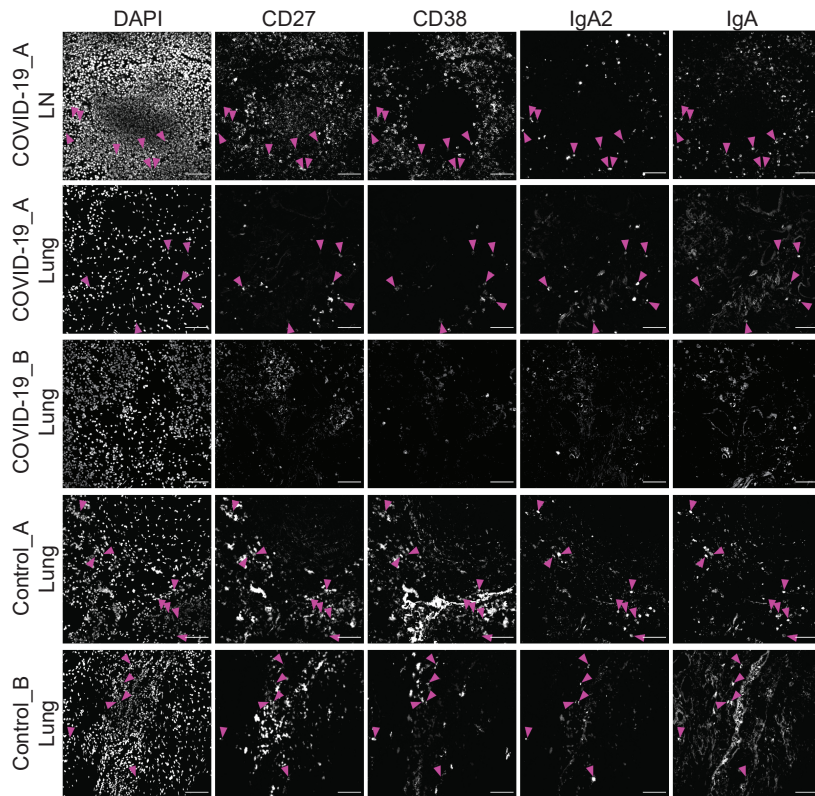


Supplementary Figure 5

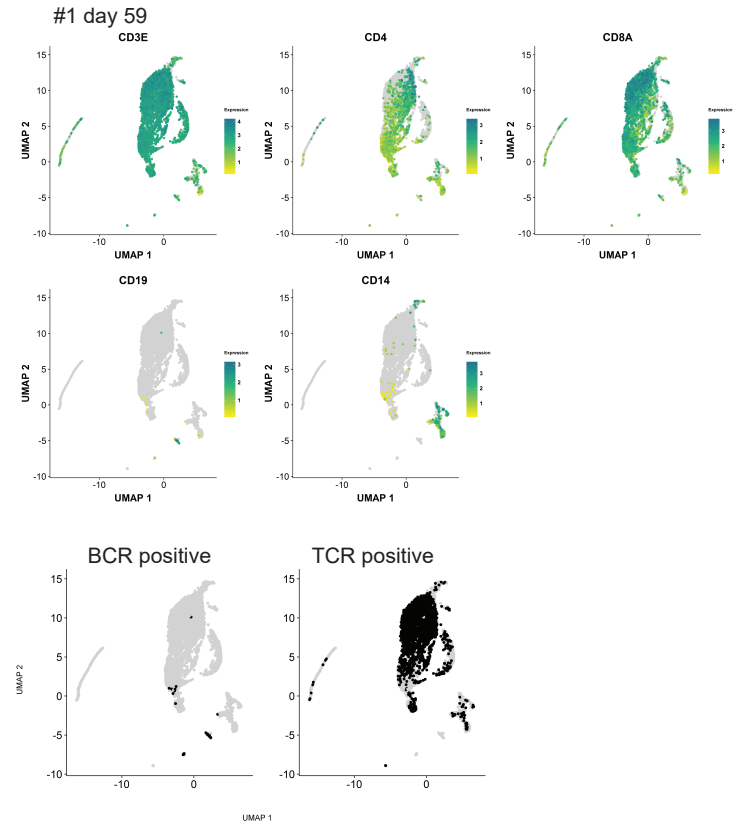
a

Patient ID	sex	age	COVID-19 duration in days	SARS-CoV-2 qPCR ante-mortem	PMI in hours	ventilation	Comorbidities						lung tissue SARS-CoV-2 RNA in log10 copies/10,000 cells
							cardiovascular	respiratory	gastrointestinal	CNS	urinary	miscellaneous	
Covid-19_A	m	76	14	positive	30	no	arterial hypertension, ischemic cardiomyopathy, myocardial infarction	heavy smoker	-	-	-	-	6,73
Covid-19_B	f	68	34	positive	16	yes	arterial hypertension, coronary heart disease	COPD, stage 2 (Gold classification)	-	-	-	class 1 obesity, hypothyroidism	1,25
Covid-19_C	f	56	27	positive	36	yes	cardiomyopathy	-	acute liver failure	delirium	acute renal failure	class 1 Obesity, type II Diabetes	2,46
Control_A	f	94	N/A	negative	60	no	coronary arteriosclerosis	bronchopneumonia due to aspiration	-	unknown neurodegenerative disease with dementia	-	-	N/A
Control_B	f	53	N/A	negative	48	no	-	bronchopneumonia due to aspiration	-	unknown neurodegenerative disease with dementia	-	cachexia	N/A
Control_C	m	59	N/A	negative	48	no	lung emboly	bronchopneumonia due to aspiration	malnutrition	meningitis, hydrocephalus	-	-	N/A

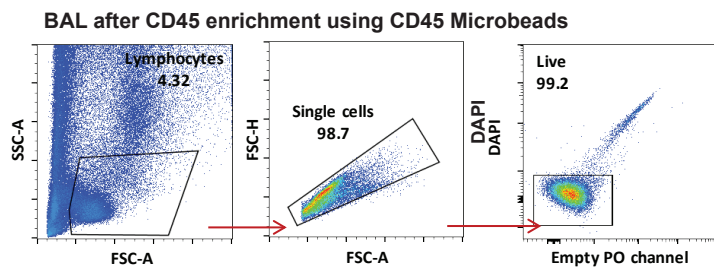
b



d



c



e

