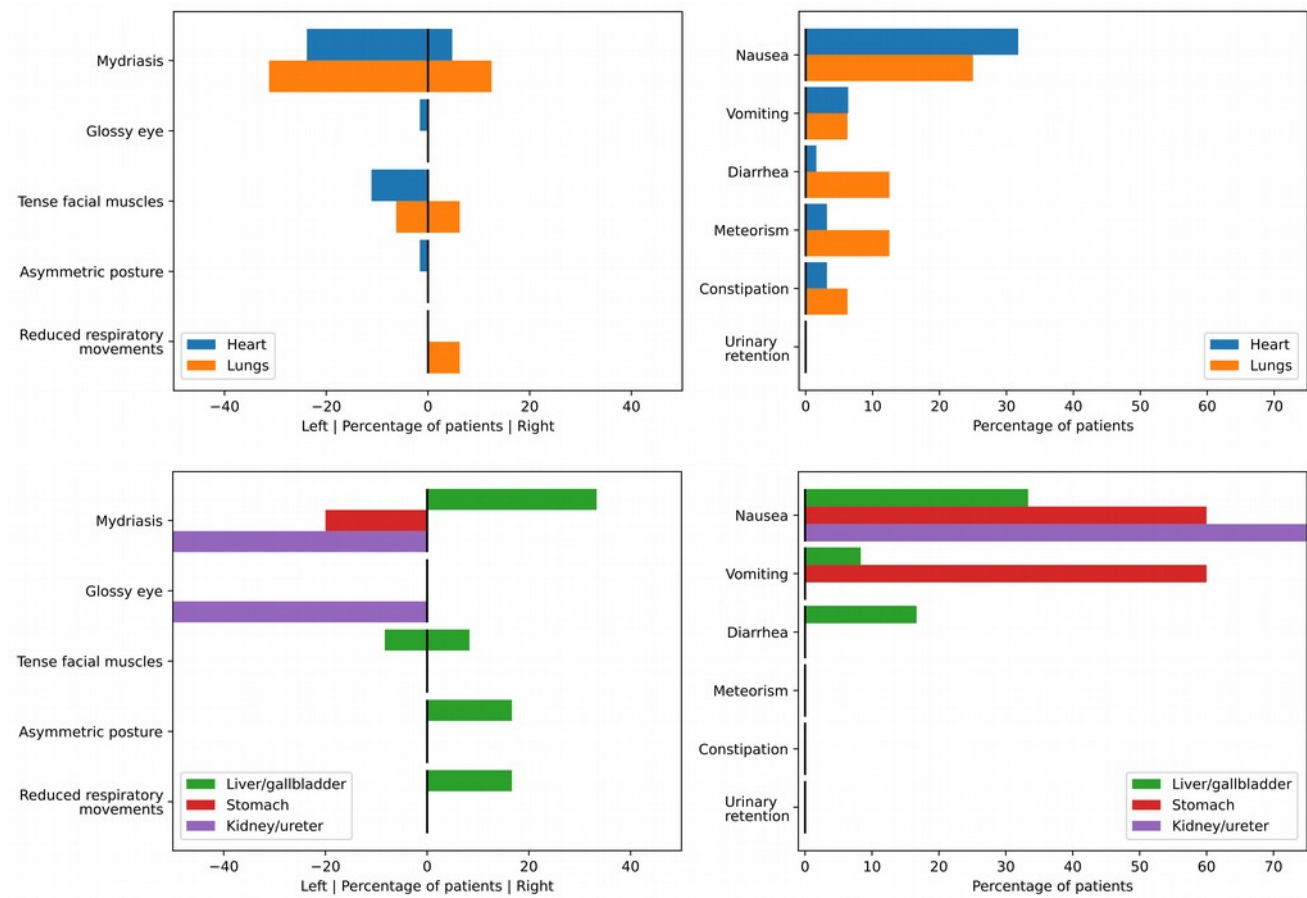


Shaballout et al. - Segmental Signs in Visceral Disease



Supplementary Figure 1. Lateralization signs (left) and segmental symptoms (right) for chest organs (top) and abdominal organs (bottom).