

1 **Title:**

2 A Method For Mimicking Tumour Tissue In Brain Ex-Vivo
3 Ultrasound For Research Application And Clinical Training

4

5 **Authors:**

6 Alistair Weld^a

7 Luke Dixon^b

8 Giulio Anichini^c

9 Giovanni Faoro^d

10 Arianna Menciassi^d

11 Sophie Camp^c

12 Stamatia Giannarou^a

13

14 **Affiliations:**

15 ^aHamlyn Centre, Imperial College London, UK

16 ^bDepartment of Imaging, Charing Cross Hospital, UK

17 ^cDepartment of Neurosurgery, Charing Cross Hospital, UK

18 ^dBioRobotics Institute, Scuola Superiore Sant'Anna, IT

19

20 **Abstract:**

21 *Background:* Intraoperative ultrasound is becoming a common tool in neurosurgery.

22 However, effective simulation methods are limited. Current, commercial, and homemade
23 phantoms lack replication of anatomical correctness and texture complexity of brain and
24 tumour tissue in ultrasound images.

25 *Methods:* We utilise ex-vivo brain tissue, as opposed to synthetic materials, to achieve
26 realistic echogenic complexity and anatomical correctness. Agar, at 10-20% concentrate, is
27 injected into brain tissue to simulate the tumour mass. A commercially available phantom
28 was purchased for benchmarking.

29 *Results:* Qualitative analysis is performed by experienced professionals, measuring the
30 impact of the addition of agar and comparing it to the commercial phantom. Overall, the use
31 of ex vivo tissue was deemed more accurate and representative, compared to the synthetic
32 materials-based phantom, as it provided good visualisation of real brain anatomy and good
33 contrast within tissue. The agar tumour correctly produced a region of higher echogenicity
34 with slight diffusion along the margin and expected interaction with the neighbouring
35 anatomy.

36 *Conclusion:* The proposed method for creating tumour-mimicking tissue in brain tissue is
37 inexpensive, accurate, and simple. Beneficial for both the trainee clinician and the researcher.
38 A total of 576 annotated images are made publicly available upon request.

39

40 **Keywords:**

41 Ultrasound, Homemade Phantom, Inexpensive, Brain Tumour

42 **Abbreviations:**

43 Intraoperative ultrasound (IOUS)

44 Ultrasound (US)

45 **Introduction:**

46

47 Intraoperative ultrasound (IOUS) is an increasingly popular tool, as it is a viable alternative
48 to more complex, time consuming and expensive solutions such as intraoperative magnetic
49 resonance imaging [1] [2] However, who performs this task is not well defined, whether it
50 should be the surgeon, radiologist, sonographer, or a combination of these professionals. The
51 background commensurate training, in turn, remains highly variable and not standardised. In
52 radiology, radiologists and sonographers undergo formal training and routinely perform
53 hundreds of supervised ultrasound (US) scans on real patients over a condensed period to
54 reach competency with accepted forms of assessment and accreditation. In contrast, in
55 surgery, US training is highly variable depending on local practice and expertise and typically
56 lacks the same structure. This is compounded by the much lower frequency of cases and
57 greater risks that are inherent to intraoperative US which greatly limits access and slows
58 experience in contrast to routine nonoperative diagnostic US which is high volume, low risk,
59 and ubiquitous across most hospitals. Considering these challenges but also the many
60 strengths of IOUS, such as real-time imaging and ease of integration into the surgical
61 workflow, methods to improve surgical training in IOUS are needed.

62

63 A particularly noteworthy application of IOUS is in oncological brain surgery, where the goal
64 is maximal safe resection (removing the most tumour while preserving function and avoiding
65 disability). This is due to the reduced reliability of preoperative imaging and challenges with
66 delineating pathological from functional tissue [3]. Precision and safety are of the utmost
67 importance, as the probe interacts with highly sensitive, fragile, and functionally crucial
68 cortical surfaces. During tumour resection, a craniotomy is performed to expose a localised
69 section of the brain surface directly above the tumour. IOUS can then be used to locate
70 pathological tissue. This cavity is typically small, with a limited field of view, and will often
71 contain blood products, gas, and other sources of artefacts that can complicate scanning [4].
72 The difficulty with gaining necessary IOUS experience is particularly daunting in
73 neurosurgery, where it is uniquely not possible to perform practice US scanning of the brain
74 on people outside of the operating theatre as a window through the skull is needed. This
75 further steepens the learning curve impacting adoption and performance.

76

77 Traditionally, medical phantoms are used to simulate anatomy and medical procedures. There
78 is limited access to purchasable educational tools and known homemade methods for creating
79 phantoms for brain IOUS. Most commercially available brain phantoms are primarily
80 designed for basic surgical training and tend to be expensive. As ultrasound is only one facet
81 of the surgical process, the anatomical correctness of the tissue is usually simplistic, lacking
82 real structural and textural details. This, in the case of the brain, is a significant issue due to
83 the inherent complexity of the anatomy.

84

85 Homemade phantoms can be a more affordable and customisable solution. These phantoms
86 can be made using food products [5] such as spam [6] or solutions such as ballistic gelatin [7]
87 [8], bovine gelatin [9], sodium alginate [10], polyvinyl alcohol (PVA) [11] or agar [12] [13].
88 In particular, agar has been shown to successfully replicate the mechanical properties of
89 human tumour tissue [14]. Although these methods are inexpensive, the core structure of the
90 phantom will be simplistic and homogenous. Foreign bodies can be embedded in the medium
91 to create diversity in echogenic features [15]. However, in combination this isn't realistic.
92 Real tissue is complex, and the interpretation of the ultrasound perspective and visible
93 anatomy is one of the fundamental challenges in IOUS.

94

95 This article highlights the importance of creating anatomical accuracy in phantoms. A
96 method is proposed to create a phantom to mimic tumours in inexpensive brain ex vivo using
97 agar.

98 **Materials and Methods:**

99

100 A summary of the cost and difficulty of creating the phantom is provided in Table.1. As a
101 benchmark for commercially available phantoms, the 'Tumour box' and 5 'Glioma Cartridge'
102 from UpSurgeOn [27], were purchased at the cost of 654.92 € and 855.00 € with a shipping
103 fee of 50.00 €. This phantom is designed primarily for resection practice, with ultrasound
104 property being only a secondary feature. However, this was the reason for the preference of
105 this phantom, as with most other medical training phantoms, the phantom will be interacted
106 with in such a way that there will be destruction of the material. For example, phantoms are
107 commonly used for vascular access, epidurals, joint injections, or aspiration. Therefore,
108 having multiple cartridges is a significant benefit of this phantom, unlike alternatives such as
109 the Adult Brain phantoms by True Phantom Solutions. Although the latter may have better
110 imaging feedback, it costs more (\$1,738 Basic, \$3,090 Standard and \$4,250 Complex model),
111 it is non-replaceable and can only be used in such a way as to preserve the integrity of the
112 material. No cutting, modification, or rough handling.

113

114 Multiple ovine and bovine ex vivo samples (Figure.1) were purchased at the cost of £5 each.
115 All data were captured using an Ultrasonix Sonix CEP ultrasound system and a L14-5 linear
116 probe. This was chosen as it is a previous generation machine, therefore producing lower
117 quality images than can be expected with the modern state-of-the-art systems and mimicking
118 a real-life scenario where clinicians rarely have access to the latest technological
119 developments. Among the different materials used in the literature, to simulate brain tumours,
120 agar was chosen due to its low cost and matching mechanical properties [14]. Agar is also
121 easy to manipulate, since there is no need for freeze-thawing cycles (as needed with PVA
122 [11]), and it can be injected during its liquid stage and allowed to solidify after injection in
123 minimal time.

124

125 Tumour simulation was achieved using 2ml of 10-20% concentrate agar, heated using a
126 Fisherbrand™ Hotplate Stirrer set to 150° and 1500 rpm, injected into the depth of the
127 subcortical white matter/centrum semiovale - the agar was cooled before injection. Where
128 both these areas are approximately equivalent to the human counterpart in terms of
129 anatomical features such as texture, locations, colour, and physiological role. Depending on
130 the concentration, temperature, volume, and area injected, from our observations, the time it
131 took to harden could vary anywhere from a few minutes up to half an hour. To simulate the
132 necrotic core of a tumour, water was injected into the hardened agar. Ultrasound feedback
133 was used to guide the needle into the agar solution.

134

135 Two experienced IOUS operators individually assessed the phantoms in relation to the
136 acquired images. Evaluation categories were defined for qualitative assessment, using the
137 five-point Likert scale. Five categories were chosen, which were considered comprehensive
138 for the evaluation of medical phantoms and their similarity to real brain tissue. The categories
139 are Reusability, Echotexture, Cerebral structure, Tactile feedback, and Tumour mimic
140 semblance.

141 **Results:**

142

143 The results of the qualitative ratings are shown in Table.2. Overall, the quality of the
144 phantoms made using real brain tissue produced superior imaging, anatomical accuracy, and
145 tumour accuracy, in comparison to the phantom. However, the animal phantom was not
146 reusable and had to be disposed of on the day of use to prevent decay and necrosis.

147

148 *Phantom analysis:*

149

150 Figure.2 shows an image of the phantom captured by our device. The most prominent and
151 noticeable features are the linear, horizontal hyperechogenic lines. Although useful in
152 defining the echogenic nature of the tissue analysed, their clinical correlation is debatable.
153 The tumour itself appears as a circular hyperechoic ring with a hypoechoid core, causing
154 significant acoustic shadowing. In the clinical setting, such shadowing is generally indicative
155 of a tumour with a calcified component. In general, although there is echogenic diversity,
156 these features are incoherent and do not resemble real anatomy.

157

158 *Ex-Vivo and agar:*

159

160 The unmodified bovine brain sample is shown on the left side of Figure.3 and the ovine
161 sample in section A and B of Figure.4. The good contrast within the tissue is the first
162 noticeable property. The samples provided a good visualisation of the cortical sulci and gyri,
163 with evident arachnoidal hyperechogenicity and differentiation of grey-white matter. There
164 were no shadows, artefacts, or elements of degradation. The images obtained through these
165 specimens closely resembled a mammalian brain anatomy and therefore were considered
166 more reliable to reproduce a clinical neurosurgical scenario.

167

168 In the same figures, the same tissues are also shown, but with the addition of injected 10-20%
169 concentrate agar. In the context of the bovine brain, the addition of agar is shown in the right
170 image of Figure.3. With the ovine tissue, sections C and D in Figure.4 show the agar solution.
171 The agar solution was injected into the depth of the inferior frontal sulcus. As expected, the
172 tumour appeared embedded in the subcortical white matter creating an echogenic sphere,
173 with a narrow tract following the entry point.

174

175 Unlike phantoms, agar injection into a real brain not only showed a well-defined and clearly
176 identifiable anomaly but also provided a mass and an infiltrative effect to the surrounding
177 areas. This interaction with brain tissue appears to be more reliable and useful for educational
178 purposes and research applications.

179

180 For reference of a normal IOUS view of brain tumour tissue, Figure.5 shows images of
181 glioblastomas - highlighted with yellow dotted lines - taken intraoperatively and right before
182 resection, at Charing Cross Hospital, using a state-of-the-art system Canon i900 ultrasound
183 machine [28]. Noticeable are the layered tissue, which produces structured echogenic
184 diversity. Similar to what is seen in the ovine and bovine tissue and dissimilar to what is seen
185 in the phantom. The tumours share similar resemblance to that produced using agar, creating
186 a region of concentrated, higher echogenicity with diffusion along the margins.

187

188

189

190 A cross section of the agar in one of the ovine ex vivo samples is shown in Figure.7. The agar
191 was mixed before injection with acriflavine to dye the tissue. As shown in the figure, it is
192 possible to embed the agar solution in an area of normal tissue.

193

194 *Necrosis Simulation:*

195

196 Figure.6 shows an example of the outcome of injecting water directly into the agar solution.
197 In this example, the water successfully displaces the agar, creating a nested spherical area of
198 lower echogenicity within the higher echogenic agar solution. This can be seen as an area of
199 slightly higher echogenicity than the background levels. The figure also shows an image of a
200 human brain tumour with a necrotic core to highlight the impact on the echogenic profile.

201 **Discussion:**

202

203 The creation of resources for surgical simulation, particularly the simulation of anatomy, is
204 ever in demand and requires ongoing commitments to overcome a series of technical,
205 logistical, and regulatory challenges. Regarding the specific problems related to the
206 application of IOUS during brain tumour surgery, the current article addresses one of the
207 critical issues related to this imaging technology, the lack of simulation resources to support
208 preclinical / cadaveric training and technical innovation.

209

210 Through our experiments with agar injection into animal ex vivo brain tissue, we show that it
211 is possible to mimic tumours in inexpensive real tissue, replicating an anatomy that is as
212 similar to human as possible and providing the expected ultrasound feedback. The simulation
213 of necrosis, by injecting water into the hardened agar, created an acceptable resemblance to a
214 high-grade real-life tumour scenario. This solution removed a few of the issues related to the
215 artificial phantom, namely the lack of resemblance to the surrounding gyri and sulci, the
216 acoustic shadow underlying the tumour model (absent in most cases) and overall, the signal
217 obtained in terms of both resolution and reliability.

218

219 The creation of medical simulation resources such as this is important, as it provides a
220 method of improving practical skills and reducing the dependency on learning from
221 experience during real surgeries. Extending from this, it would also facilitate learning new
222 US-guided techniques such as US-guided core biopsies which are presently, due to lack of
223 access, under applied in neurosurgery but readily used in other medical fields. For example,
224 in this case the operators found that the task of using US to guide the agar injections was
225 qualitatively associated with an improvement in US coordination and US localisation of the
226 needle.

227

228 In addition, inexpensive, accurate simulation of brain anatomy and pathology encourages
229 technical innovation. For example, data can be collected more easily (possibly to supplement
230 the more difficult-to-acquire in vivo data), to enable deep learning training, which usually
231 requires large volumes of data to prevent overfitting. Furthermore, the inexpensiveness and
232 anatomical and textural accuracy of the phantom can provide a tool for conducting robotic
233 experiments [16]. As with most robotic applications for surgery, ultrasound guidance is still
234 in an early preclinical, experimental research-focused phase. As such, this has allowed for
235 temporary circumvention of the simulation of more challenging surgical procedures which
236 may utilise ultrasound, and the expected intricacies of the anatomical features that would be
237 present. In a large number of these robotic setups, the application is non-invasive, on-the-skin
238 procedures [17] [18], or are works that can be evaluated on simple synthetic medical
239 phantoms, to explore technical novelty in the design and control of the robotic system [19]
240 [20] [21] [22]. Nevertheless, evaluation of robotic systems on ex vivo is not uncommon. For
241 example human cadavers for spine scanning [23], porcine tissue for needle tracking [24],
242 kidney and heart for learning-from-demonstration [25]. Germane to this article, [26] uses an
243 unmodified chicken breast for the evaluation of focused US ablation. The study pertained to
244 the feasibility of real-time detection of the ablation area and, as such, the task did not require
245 the ablated tissue to be pathological. However, the clinical motivation for this research and
246 many others within the field of robotic ultrasound is therapeutic surgery. By using the method
247 proposed in this paper, or future similar methods, the tumour mimicking tissue can act as the
248 target for the robotic experiment e.g. thermal ablation.

249

250 Our solution is not without limitations. First, prion disease represents a serious biohazard and
251 needs to be addressed properly when manipulating the brains of dead animals. We have
252 circumvented this problem opting for young animal brains (veals and lambs) specifically
253 harvested for human consumption and have already gone through official clearance with the
254 relevant regulatory authorities. If an adult animal brain is preferable for whatever reason, a
255 much stricter protocol would be required. As an additional precaution measure to manage any
256 biosafety risk, all biological material has been discarded according to standard safety
257 protocols. Second challenge, working with ex vivo biological tissue should ideally be done in
258 biosafe laboratories, unlike commercial phantoms, which could be used in any setting. This
259 set-up is per se expensive and/or not always accessible for all centres. Finally, while the
260 tissue does show much closer resemblance with the in vivo images, the possibility of
261 degradation-related artefacts must be considered. For these experiments, tissue samples were
262 kept out of the refrigerator at room temperature for more than an hour, and the harvesting
263 time presumably took place 24 to 48 hours earlier. However, no significant necrosis or tissue
264 degradation was observed within this time period, both on macroscopic inspection and on
265 imaging. Some degree of manipulation-related damage was noticed especially at the level of
266 the basal structures, but this was negligible for the purpose of our acquisitions. Some of the
267 tissue that was left out was later frozen and used on another day, and it was observed that the
268 fluctuation of temperature and the freezing process minimally impacted the usability of the
269 tissue. In general, we found that this setting and time frame is acceptable, reliable, and
270 replicable.

271 **Conclusions:**

272

273 Methods for mimicking tumours within ultrasound images are valuable both for clinical
274 training and research. This is especially the case with brain tumours, which are complex,
275 highly variable, and diffuse. IOUS is a difficult tool to become proficient with, outside of real
276 surgeries. The lack of affordable and accurate commercially available phantoms creates the
277 need for home-made methods to create inexpensive homemade phantoms. Our proposed
278 method solves this by mimicking tumours within real tissue, by combining easy and cheap
279 butchers meat with agar powder. Furthermore, this will encourage technical innovation, as
280 the lack of simulation resources has been a significant bottleneck in technical innovation. A
281 data set is created and made publicly available upon request that contains bounding-box
282 annotations of multiple ex vivo ovine brains containing tumour-mimicking agar. The data set
283 contains 576 annotated images and 388 images without tumours, where the frames were
284 extracted from US videos at 1Hz. The images are stored as MAT-files with the annotations in
285 CSV files with the structure [top left corner, width, height]. Sample images from the data set
286 are shown in Figure.8.

287

288 Future work is encouraged to improve the realism of the tumour mimicry. This could include
289 testing different concentrations of agar solution, testing different locations, and using more
290 than one compound to simulate tumour characteristics, creating more complex layering and
291 diffusion effects. Further research is desirable to simulate a more infiltrative type of lesion,
292 with reduced margin sharpness.

293 **Compliance With Ethical Standards:**

294

295 *Funding*

296 This project was supported by the UK Research and Innovation (UKRI) Centre for Doctoral
297 Training in AI for Healthcare (EP/S023283/1), the Royal Society (URF\R\ 201014), the
298 NIHR Imperial Biomedical Research Centre.

299

300 *Conflict Of Interest*

301 The authors declare no conflicts of interest.

302

303 *Ethical Approval*

304 This article does not contain any studies with human participants or animals performed by
305 any of the authors.

306 Bibliography

307

- [1] C. P. B. Rajashree Uday Gandhe, "Intraoperative magnetic resonance imaging for neurosurgery – An anaesthesiologist's challenge," *Indian Journal of Anaesthesia*, pp. 411 - 417, 2018.
- [2] F. S. ., O. S. ., M. P. t. L.-P. ., O. P. T. a. A. G. H. K. ., J. J. v. O. ., D. M. ., H. v. S. Pieter Leonard Kubben, "Intraoperative magnetic resonance imaging versus standard neuronavigation for the neurosurgical treatment of glioblastoma: A randomized controlled trial," *Surgical Neurology International*, 2014.
- [3] A. L. ., M. G.-S. ., D. N. ., S. J. C. Luke Dixon, "Intraoperative ultrasound in brain tumor surgery: A review and implementation guide," *Neurosurgical Review*, pp. 2503 - 2515, 2022.
- [4] J. B. ., V. P. B. ., A. K. ., D. T. ., A. L. Andrej Steno, "Current Limitations of Intraoperative Ultrasound in Brain Tumor Surgery," *Frontiers in Oncology*, 2021.
- [5] L. N. ., V. A. B. ., R. E. L. Juliana Wilson, "An Easy-to-Make, Low-Cost Ultrasound Phantom for Simulation Training in Abscess Identification and Aspiration," *Journal of Ultrasound in Medicine*, 2017.
- [6] P. S. H. ., T. C. ., B. D. Laura Nolting, "An Inexpensive and Easy Ultrasound Phantom," *Journal of Ultrasound in Medicine*, 2016.
- [7] J. Z. K. ., L. A. S. ., D. E. B. ., A. J. H. ., S. A. Richard Amini, "A novel and inexpensive ballistic gel phantom for ultrasound training," *World journal of emergency medicine*, pp. 225-228, 2015.
- [8] J. C. ., J. S. B. Dustin Morrow, "Versatile, Reusable, and Inexpensive Ultrasound Phantom Procedural Trainers," *Journal of Ultrasound in Medicine*, 2016.
- [9] B. J. J. Jose Mario Martinez, "3D perfused brain phantom for interstitial ultrasound thermal therapy and imaging: design, construction and characterization," *Physics in Medicine & Biology*, pp. 1879 - 1900, 2015.
- [10] M. Aoyagi, "Sodium Alginate Ultrasound Phantom for Medical Education," *Ultrasonic Imaging*, pp. 253 - 261, 2021.
- [11] J. S. ., E. M. ., S. R. S. ., R. B. ., S. O. ., T. K. M. V. ., A. E. D. Eleanor C. Mackle, "Patient-Specific Polyvinyl Alcohol Phantom Fabrication with Ultrasound and X-Ray Contrast for Brain Tumor Surgery Planning," *Journal of visualized experiments*, 2020.
- [12] N. E. ., L. G. ., A. C. ., C. I. ., C. D. Anastasia Antoniou, "Tumor phantom model for MRI-guided focused ultrasound ablation studies," *Medical physics*, 2023.
- [13] T. D. ., M. P. ., M. B. ., C. D. Georgios Menikou, "MRI compatible head phantom for ultrasound surgery," *Ultrasonics*, pp. 144-152, 2015.
- [14] A. R. ., K. A. D. ., C. S. S. Daniel C. Stewart, "Mechanical characterization of human brain tumors from patients and comparison to potential surgical phantoms," *PLoS ONE*, 2017.
- [15] S. A. S. ., P. S. ., A. V. M. Vikas Kumar Singh, "Customized Low Cost Model for Hands-on Training in Intraoperative Ultrasound for Neurosurgeons: Our Experience and Review of Literature," *World neurosurgery*, 2020.
- [16] S. E. S. ., N. N. Zhongliang Jiang, "Robotic Ultrasound Imaging: State-of-the-Art and Future Perspectives," *Medical image analysis*, 2023.

- [17] M. K.-S. L. ,. D. N.-A. ,. Y. P. Z. Maria Victorova, "Follow the Curve: Robotic Ultrasound Navigation with Learning Based Localization of Spinous Processes for Scoliosis Assessment," *IEEE Access*, 2021.
- [18] Y. Z. ,. Y. B. ,. M. Z. ,. T. W. ,. N. N. Zhongliang Jiang, "Deformation-Aware Robotic 3D Ultrasound," *IEEE Robotics and Automation Letters*, pp. 7675-7682, 2021.
- [19] A. W. ,. J. K. ,. A. K. ,. L. D. ,. G. A. ,. S. C. ,. A. A.-S. ,. S. G. Michael Dyck, "Toward Safe and Collaborative Robotic Ultrasound Tissue Scanning in Neurosurgery," *IEEE Transactions on Medical Robotics and Bionics*, pp. 64-67, 2023.
- [20] J. C. ,. R. S. S. ,. T. M. ,. N. U. ,. S. H. ,. M. T. Mojtaba Akbari, "Robot-assisted Breast Ultrasound Scanning Using Geometrical Analysis of the Seroma and Image Segmentation," *IEEE/RSJ International Conference on Intelligent Robots and Systems (IROS)*, pp. 3784-3791, 2021.
- [21] C. M. H. ,. J. S. ,. S. M. Filip Suligoj, "RobUST—An Autonomous Robotic Ultrasound System for Medical Imaging," *IEEE Access*, pp. 67456-67465, 2021.
- [22] S. M. ,. S. P. ,. V. I. ,. A. M. Giovanni Faoro, "An Artificial Intelligence-Aided Robotic Platform for Ultrasound-Guided Transcarotid Revascularization," *IEEE Robotics and Automation Letters*, pp. 2349-2356, 2023.
- [23] A. D. ,. Y. C. ,. K. N. ,. G. B. ,. N. A. C. ,. A. M. ,. F. C. ,. C. J. L. ,. M. F. ,. P. F. ,. E. B. V. P. Ruixuan Li, "Robot-assisted ultrasound reconstruction for spine surgery: from bench-top to pre-clinical study," *International Journal of Computer Assisted Radiology and Surgery*, pp. 1613-1623, 2023.
- [24] X. L. ,. X. C. ,. A. K. ,. Y. B. ,. Y. C. ,. K. W. S. A. ,. N. N. Zhongliang Jiang, "Needle Segmentation Using GAN: Restoring Thin Instrument Visibility in Robotic Ultrasound," *ArXiv*, 2024.
- [25] Y. B. ,. M. Z. ,. Y. H. ,. M. B. ,. N. N. Zhongliang Jiang, "Intelligent robotic sonographer: Mutual information-based disentangled reward learning from few demonstrations," *The International Journal of Robotics Research*, pp. 981 - 1002, 2023.
- [26] H. R. ,. J.-w. H. ,. H.-J. K. Moslem Sadeghi-Goughari, "Artificial intelligence-assisted ultrasound-guided focused ultrasound therapy: a feasibility study," *International Journal of Hyperthermia*, 2023.
- [27] UpSurgeOn, "BrainTumorBox," 2024. [Online]. Available: <https://store.upsurgeon.com/products/braintumorbox/>.
- [28] L. D. ,. G. A. ,. N. P. ,. A. N. ,. M. D. ,. K. O. ,. A. L. ,. S. G. ,. S. C. Alistair Weld, "Challenges with segmenting intraoperative ultrasound for brain tumours," *Acta Neurochirurgica*, 2024.

308
309
310

311 **Tables:**

312

313

314

Table 1 - Cost, acquisition and setup

	UpSurgeon	Animal Brain
Cost	High	Low
Availability	Moderate	Easy
Time to construct	5 min	10 min
Special storage	No	Yes
Special handling	No	Yes
Complexity of set up	Simple	Intermediate

315

316

317

318

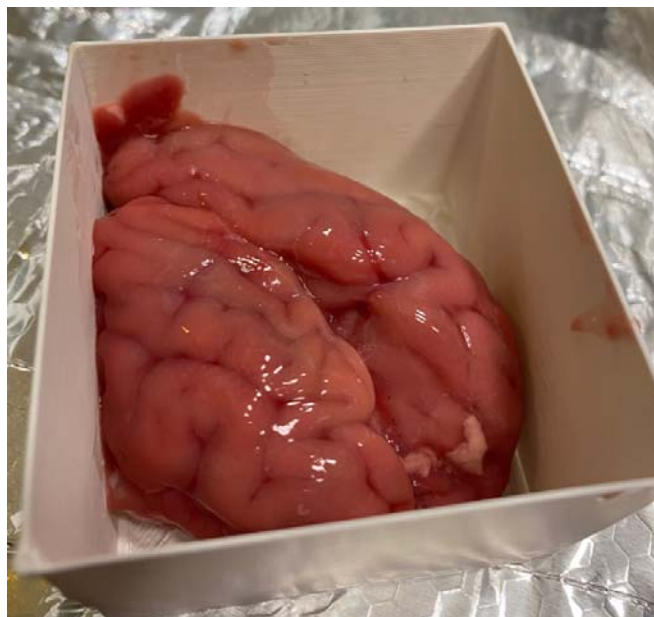
Table 2 - Qualitative assessment using a five-point Likert scale (1 = poor to 5 = excellent)

	UpSurgeon	Animal Brain
Reusability	4	2
Echotexture	3	5
Cerebral structure	1	5
Tactile feedback	2	5
Tumour mimic semblance	2	4

319

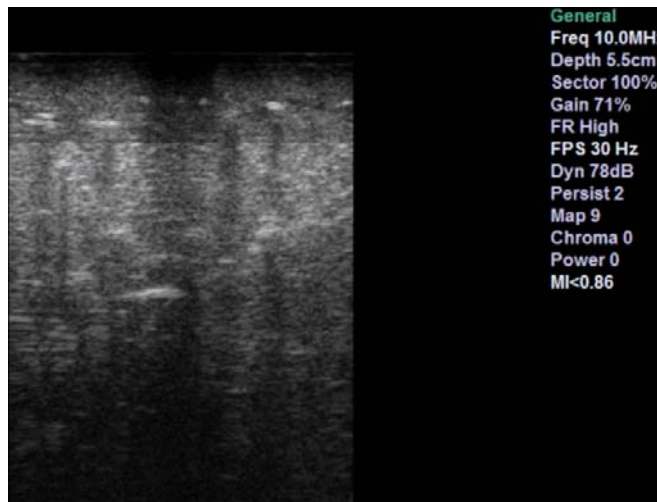
320

321 **Figures:**
322



323
324 Figure 1 - An ovine sample used to collect the data, before the agar solution was injected.
325 The container has the dimensions 6.5cm x 7.0cm.

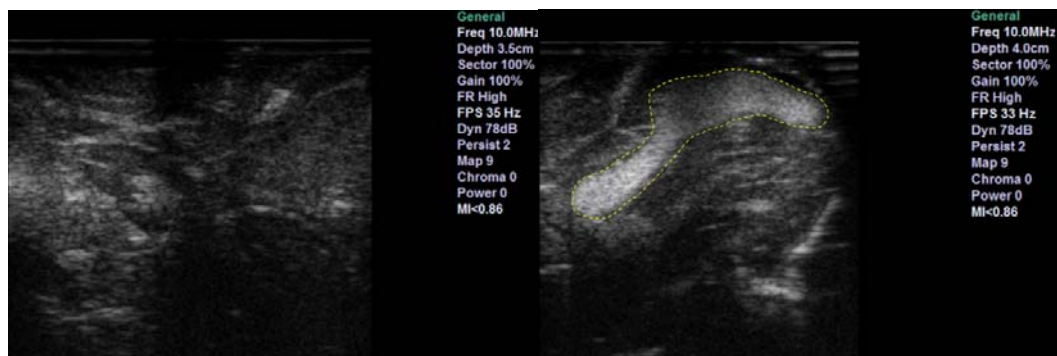326
327
328



329
330 Figure 2 - UpSurgeOn brain box phantom image from our machine.

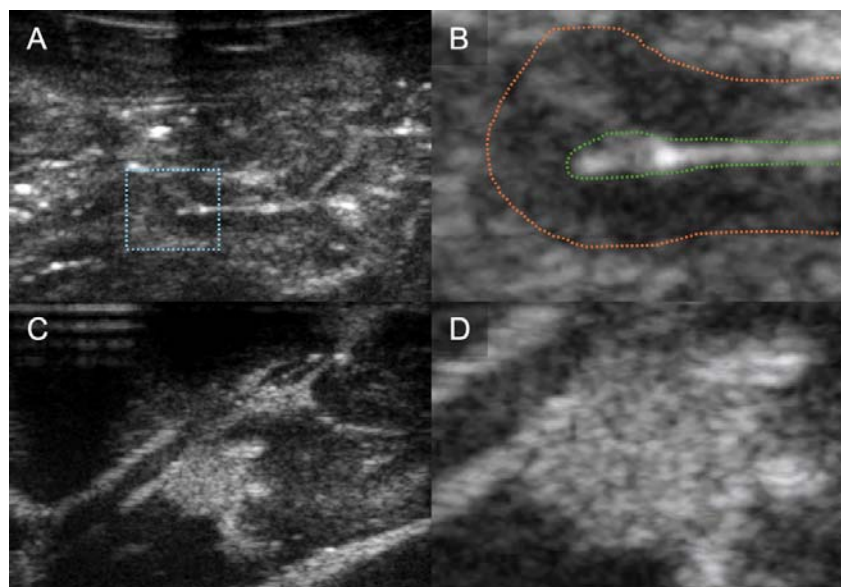
331
332
333
334
335
336
337
338

339
340
341
342



343
344 Figure 3 - Bovine sample. Left shows ultrasound feedback of phantom without tumour
345 addition. Right shows ultrasound feedback with agar injected

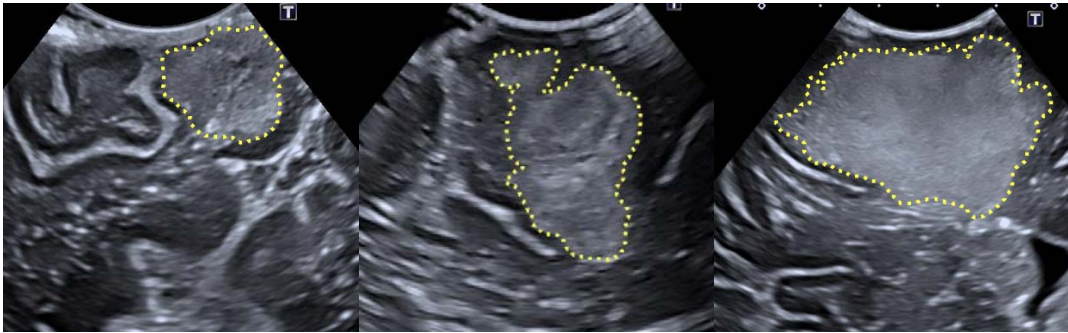346
347
348



349
350 Figure 4 - Ovine sample. B-mode image of sheep brain (A) with magnified image of gyrus
351 (B) demonstrating discernible normal cerebral architecture with sulci and pia (outlined by
352 green dotted line), cortex (outlined by orange dotted line) and surrounding white matter. B-
353 mode image of the same sheep brain after localised infiltration of agar to mimic a
354 hypercellular, echogenic tumour (C) with magnified image of tumour mimic demonstrating
355 clear margins (D).

356
357
358
359
360
361
362

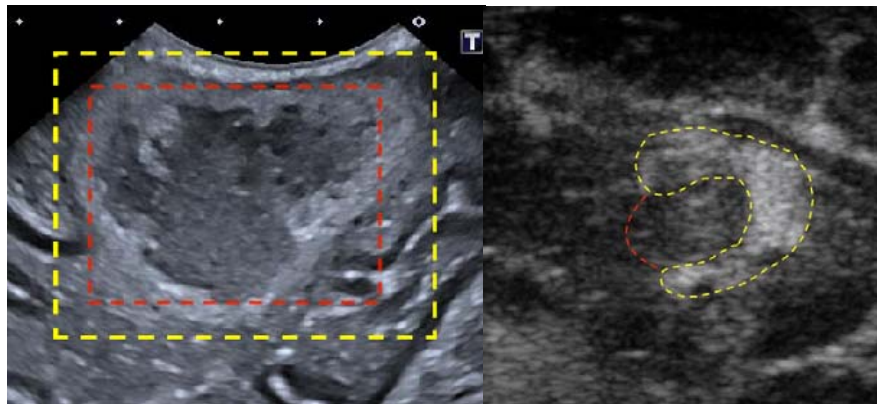
363
364



365
366
367
368

Figure 5 - Human intraoperative ultrasound images of Glioblastoma. The tumours are highlighted using the yellow dotted lines. The left and right figures show a maximum depth of 5cm, while the middle figure shows a maximum depth of 4.5cm.

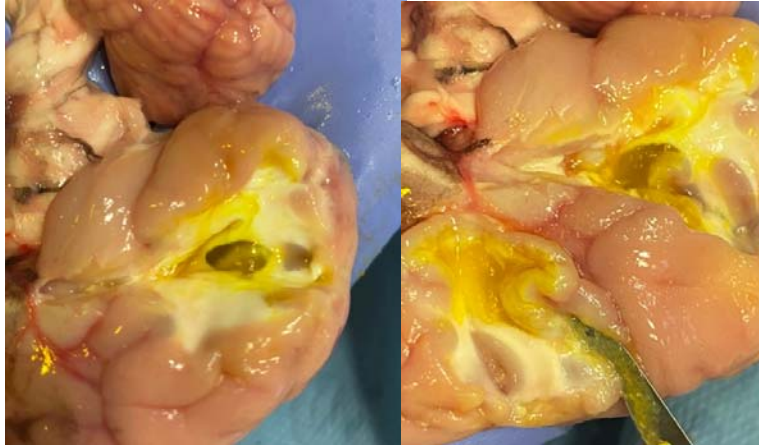369
370
371



372
373
374
375

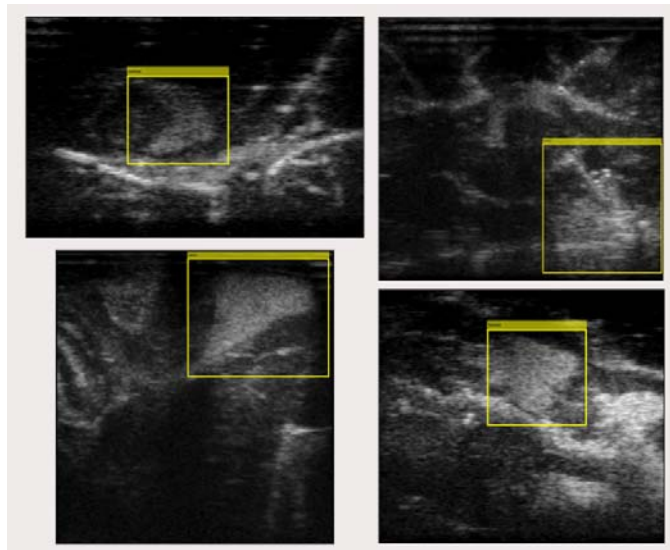
Figure 6 - The right example shows a real case of a brain tumour, highlighted in yellow, with a necrotic core, highlighted in red. On the left is water added to the agar to simulate a necrotic core. Yellow line outlines the agar, red line outlines the water.

376
377
378



379
380
381
382

Figure 7 - Cross section of one of the ovine brains. In this sample, two sites were injected with agar (dyed yellow)



383
384

Figure 8 - Samples from the data set with super imposed bounding box annotation.