

1 **Title:** Photoreceptor outer segment reflectivity with ultrahigh resolution visible light  
2 optical coherence tomography in systemic hydroxychloroquine use

3  
4 **Authors:** Anupam K. Garg, M.D., Ph.D.<sup>1,\*</sup>; Jingyu Wang, Ph.D.<sup>1,2,\*</sup>, Bailee Alonzo,  
5 B.S.<sup>1</sup>, Ji Yi, Ph.D.<sup>1,2</sup>, Amir H. Kashani, M.D., Ph.D.<sup>1,3</sup>

6  
7 **Institutions:**

8 <sup>1</sup>Wilmer Eye Institute, Johns Hopkins University, Baltimore, MD, USA

9 <sup>2</sup>Department of Biomedical Engineering, Johns Hopkins University, Baltimore, MD, USA

10 <sup>3</sup>Department of Biomedical Engineering, Johns Hopkins Hospital, Baltimore, MD, USA

11 \*These authors contributed equally.

12

13 **Corresponding Author:**

14 Amir H. Kashani, M.D., Ph.D.

15 Boone Pickens Professor of Ophthalmology and Biomedical Engineering

16 Wilmer Eye Institute

17 600 N Wolfe Street

18 [akashan1@jhmi.edu](mailto:akashan1@jhmi.edu)

19

20 Financial Support:

21 The study is supported by NIH funding R01NS108464 (JY), R01EY032163 (JY),

22 R01EY034607 (JY), and the Boone Pickens Professorship in Ophthalmology (AHK).

23

24

25 Commercial Relationships Disclosures:

26 **A.K. Garg**, None; **J. Wang**, None; **B. Alonzo**, None; **J. Yi**, None; **A.H. Kashani**, Carl

27 Zeiss Meditec (C), Aspen Biosciences (C), RegenXBio (C).

28

29 Abbreviations:

30 **OCT**, optical coherence tomography; **VIS**, visible light; **SS**, swept source; **SD**, spectral

31 domain; **HCQ**, hydroxychloroquine; **ELM**, external limiting membrane; **EZ**, ellipsoid

32 zone; **COST**, cone outer segment tips; **ROST**, rod outer segment tips; **RPE**, retinal

33 pigment epithelium; **BM**, Bruch's membrane

34

## 35 **Abstract**

36 Purpose: To evaluate outer retinal organization in normal subjects and those using  
37 hydroxychloroquine (HCQ) with ultrahigh resolution visible light optical coherence  
38 tomography (VIS-OCT).

39 Methods: Forty eyes of 22 adult subjects were recruited from a tertiary care retina  
40 practice including controls (20 eyes, 12 subjects, mean age  $40\pm 22$  yrs, mean logMAR  
41 BCVA 0.19, 90% female) and subjects with a history of HCQ use (20 eyes, 10 subjects,  
42 mean age  $62\pm 17$  yrs, mean logMAR BCVA 0.03, 67% female). Each subject was  
43 imaged using a custom-built VIS-OCT device (axial resolution  $1.3\mu\text{m}$ ) and FDA-  
44 approved OCT devices.

45 Results: Using VIS-OCT, control subjects demonstrate 5 and 6 hyperreflective bands in  
46 the foveal and parafoveal regions, respectively, between the outer nuclear layer and  
47 Bruch's membrane. These bands demonstrate intensity profiles complementary to the  
48 known histopathologic distribution of rods and cones. In comparison to controls,  
49 subjects taking HCQ demonstrate blunting of all bands, particularly bands 2-4. In all  
50 cases of suspected or known toxicity, VIS-OCT demonstrated attenuation of band 3i  
51 and in no cases was there attenuation of other bands that was more severe than band  
52 3i, suggesting that changes in the reflectivity of Band 3i may be the earliest identifiable  
53 sign of HCQ toxicity.

54 Conclusions: VIS-OCT of the outer retina demonstrates a unique outer retinal banding  
55 pattern corresponding to photoreceptor density profiles. There is a notable attenuation  
56 of the photoreceptor outer segment reflectivity profile associated with early HCQ

- 57 toxicity. This finding may be an early, and possibly reversible, sign of HCQ toxicity,
- 58 primarily impacting the cones.

## 59 Introduction

60 Hydroxychloroquine (HCQ) is a well-described anti-inflammatory and anti-malarial  
61 medication with relatively rare but devastating toxic effects on the retina<sup>1</sup>. Although a  
62 benign drug in general, the potential for this serious side-effect causes significant  
63 problems in the management of patients who are on the medication. The exact  
64 pathophysiology of the side-effect is not well understood however several lines of  
65 evidence suggest that toxicity at the level of the retinal pigment epithelium and,  
66 secondarily the photoreceptor, is likely. *In vitro* studies have demonstrated that HCQ  
67 inhibits protein synthesis<sup>2</sup> and lysosomal function<sup>3</sup> in RPE. Toxicity manifests in  
68 subjects with prolonged HCQ exposure as thinning of the outer retina and loss of the  
69 retinal pigment epithelium in a bulls-eye pattern<sup>4</sup>. However, even subjects without any  
70 clinical findings or subjective symptoms can demonstrate subclinical signs of toxicity  
71 such as modest retinal thinning on OCT and decreased signal amplitude on mfERG<sup>5,6</sup>.  
72 Careful analysis of OCT images has suggested these changes are caused by loss of  
73 the ellipsoid zone<sup>7</sup> and/or changes in the photoreceptor outer segments<sup>8</sup>. While severe  
74 changes may be seen with retinal thickness maps<sup>9</sup>, the resolution of commercially  
75 available OCT devices is not sufficient to easily and reliably assess subclinical changes  
76 in the outer segment banding patterns on single OCT volumes<sup>10</sup>. To overcome this  
77 limitation, serial OCT imaging has been used to detect very subtle paracentral thinning  
78 patterns that seem strongly correlated with toxicity<sup>6</sup>. This finding suggests that higher  
79 resolution imaging of the photoreceptor/RPE complex may reveal even earlier signs of  
80 toxicity.

81

82 While most commercial devices utilize near-IR wavelength light, ultrahigh resolution  
83 visible light OCT (VIS-OCT) utilizes shorter wavelengths of light to enable higher axial  
84 resolution (~1  $\mu\text{m}$ ) compared to conventional OCT devices<sup>11</sup>. Recent technological  
85 advances have enabled the development of VIS-OCT devices for human retinal  
86 imaging, enabling characterization of both inner and outer retinal layers in greater detail  
87 than previously possible in human subjects<sup>12–15</sup> and animal models<sup>16,17</sup>. Prior work has  
88 demonstrated that VIS-OCT reveals outer retinal banding morphology that was not  
89 readily visible with conventional devices in control subjects without a known history of  
90 retinal pathology, including Bruch's membrane and sub-bands in photoreceptor outer  
91 segments<sup>18</sup>. Similar banding morphology has also been recently demonstrated using  
92 ultrahigh resolution SD-OCT prototype devices<sup>19,20</sup>. *In vivo* characterization of these fine  
93 details and their changes in retinal disease may provide valuable insights into disease  
94 pathophysiology and management. Given that the outer retina is primarily affected in  
95 early HCQ toxicity, VIS-OCT is a promising imaging modality to enable early detection  
96 of HCQ toxicity. In this study we used a custom-built VIS-OCT device to identify subtle  
97 outer retinal changes in HCQ toxicity not visible with conventional OCT devices.

98

## 99 **Methods**

### 100 *Recruitment of Subjects*

101 Both eyes of adult subjects with a history of hydroxychloroquine use were prospectively  
102 recruited from a tertiary care retina practice for retinal imaging with a custom-built dual-  
103 channel VIS-OCT device with an axial resolution of 1.3 $\mu\text{m}$  (see Wang et al., 2022 for  
104 technical details<sup>18,21</sup>) (**Figure 1**). Each subject was also imaged using a commercial

105 swept-source OCT imaging device. The most recent hepatic and renal function testing  
106 results of each subject were also obtained. Control subjects were recruited from the  
107 retina clinics if they had no vision threatening retinal or ocular disease in at least one  
108 eye. Information regarding subjects is summarized in **Table 1**. All subjects provided  
109 informed consent according to a human subject protocol approved by the Johns  
110 Hopkins Medicine Institutional Review Boards (IRB) and in accordance with the  
111 principles of the Declaration of Helsinki. Subjects with significant media opacity, poor  
112 signal quality, or inability to fixate sufficiently to obtain at least one high quality foveal  
113 line scan were excluded.

114

#### 115 *Imaging Device*

116 The dual-channel VIS-OCT features a visible-light bandwidth ranging from 500 to 650  
117 nm and a near-infrared light bandwidth spanning from 750 nm to 900 nm, with power  
118 levels of 0.25 mW and 0.8 mW on the cornea, respectively. Subjects were instructed to  
119 fixate using one of two LED displays that served as an external fixation target. A tunable  
120 lens was utilized to correct spherical errors. For each eye, the image was initially  
121 aligned and optimized under the NIR channel and then promptly imaged with the visible  
122 light channel.

123

#### 124 *Imaging Protocol*

125 All subjects had standard SD-OCT imaging performed as part of their standard of care  
126 assessment. In addition, subjects were scanned using two research OCT devices  
127 including a custom-built ultrahigh resolution visible light OCT (VIS-OCT) system and a

128 commercially available SS-OCT system (PlexElite, Carl Zeiss Meditec, Dublin, CA.  
129 Imaging on the SS-OCT was performed using a standard 6mm x 6mm raster scan  
130 pattern centered on the fovea. The VIS-OCT imaging was performed using a high-  
131 definition 4-line radial scanning pattern (32x2048 A-lines x 4 B-scans) as well as  
132 multiple high-definition single line scans (64x1024 A-lines x 1 B-scan) in the region of  
133 the raster scan pattern from the SS- and SD-OCT devices. For all VIS-OCT scans, 32  
134 or 64 modulated A-lines over ~0.1 mm orthogonal to the B-scan direction were  
135 averaged to produce high-quality images with reduced speckle noise<sup>21,22</sup>. The line rate  
136 was 100kHz with a total acquisition time of 2.62 seconds per scan pattern. Images  
137 were flattened using a custom algorithm. VIS-OCT and SS-OCT foveal scans were  
138 manually registered by using the depth of the foveal center.

139

#### 140 *Image Processing for VIS-OCT*

141 We employed a per-A-line noise cancellation algorithm to eliminate baseline light source  
142 spectrum, reduce noise, and enhance the signal-to-noise ratio. Dispersion  
143 compensation and fast Fourier transform (FFT) were then applied to generate B-scans.  
144 To establish the display range, we defined the intensity of background after FFT as the  
145 lower boundary and selected the intensity value at 0.05% from the sorted values (from  
146 high to low) as the upper boundary. Utilizing these upper and lower boundaries, we  
147 applied a logarithmic scale and normalization for image display. Given the substantial  
148 dynamic range (exceeding 60 dB for control subjects) between the inner and outer  
149 retina, achieving a balanced visual effect proved challenging. Therefore, we increased  
150 the image brightness by 40% to enhance the visibility of the inner retina, although this

151 resulted in saturation of the outer retina. Additionally, we manually flattened the B-scans  
152 based on band 5 (Bruch's membrane) (**Supplemental Figure 1**). The intensity of each  
153 outer retinal layer was quantified by manually segmenting the boundaries of each layer  
154 and calculating the cumulative intensity between the boundaries. Manual segmentation  
155 was performed independently by two separate graders and differences were  
156 adjudicated by a third grader.

157

## 158 **Results**

159 As described in Table 1, a total of 20 eyes from 12 control subjects (without known  
160 retinal pathology) were recruited into this study. VIS-OCT imaging of these subjects  
161 demonstrates outer retinal anatomy in finer detail than previously possible with  
162 conventional OCT technology. **Figure 1 and Supplemental Figure 2** demonstrate  
163 representative VIS-OCT images from control subjects. Within the foveola, five hyper-  
164 reflective outer retinal bands are visualized, labeled as bands 1-5 (**Figure 1C**). These  
165 bands are putatively identified as the external limiting membrane (ELM, band 1),  
166 ellipsoid zone (EZ, band 2), cone photoreceptor outer segment tips (COST, band 3),  
167 retinal pigment epithelium (RPE, band 4) and Bruch's Membrane (BM, band 5). This  
168 banding pattern was observed in all control subjects irrespective of patient age. Henle's  
169 fiber layer was visible as a slightly darker region above the outer nuclear layer (**Figure**  
170 **1B, 1E**). Magnified views of the inner plexiform layer demonstrate sublayers in the  
171 perifoveal region (**Figure 1B and 1F**), consistent with previous findings<sup>23</sup>.

172



173 In the parafoveal region, outer retinal band 3 consistently divides into two distinct  
174 hyperreflective bands (labelled bands 3 inner (3i) and 3 outer (3o)) for a total of six  
175 hyperreflective bands (**Figure 1A and 1D**). In accordance with prior anatomical studies  
176 and previously published VIS-OCT imaging data<sup>13,21</sup>, these bands are putatively  
177 identified as the cone and rod photoreceptor outer segment tips (COST/ROST),  
178 respectively. To better characterize these bands, each one was manually segmented,  
179 and the mean intensity of each band averaged across three control subjects was plotted  
180 as a function of the distance from the fovea (**Figure 2**). Notably, the intensity of band 3i  
181 peaks in the foveal region and sharply declines with increasing retinal eccentricity. On  
182 the other hand, band 3o is not visible in the foveal region and gradually appears with  
183 increasing retinal eccentricity. This pattern mirrors previously published histological  
184 studies of cone and rod density<sup>24,25</sup>, supporting the hypothesis that bands 3i and 3o  
185 represent cone and rod photoreceptor outer segments tips, respectively. This inverse  
186 relationship between bands 3i and 3o was consistent between two graders who  
187 independently segmented the layers (**Supplemental Figure 3**).

188

189 A total of 20 eyes from 10 subjects with a history of hydroxychloroquine use were  
190 recruited (**Table 1**). These subjects demonstrated a range in severity of  
191 hydroxychloroquine toxicity findings (including subjects with suspected toxicity or no  
192 evidence of toxicity on prior testing) and were imaged using VIS-OCT. These subjects  
193 range in age (33 to 84 years) and length of hydroxychloroquine use (1 to 35 years). The  
194 approximate cumulative lifetime hydroxychloroquine dose was calculated, and each

195 patient's most recent renal and hepatic function testing was recorded if available from  
196 their medical records.

197

198 **Figure 3** illustrates data from a 61-65 age range female subject with an 11-year history  
199 of hydroxychloroquine use and qualitatively unremarkable SD-OCT and SS-OCT scans  
200 (Figure 3B). The patient had excellent visual acuity (20/20 in both eyes) and denied any  
201 subjective vision changes at the time of examination. Hydroxychloroquine toxicity was  
202 suspected based on serial SD-OCT mean central subfield thickness measurements  
203 showing decreasing thickness in the nasal and temporal ETDRS subfield sectors as  
204 described in Melles et al., 2022 (**Figure 3B, 3F**). VIS-OCT images (**Figure 3A, 3C-D**)  
205 were compared to a control subject (**Figure 3E**) and demonstrated blunting of most  
206 band boundaries as well as essentially complete loss of Band 3i in the parafoveal  
207 region. **Figure 3G** illustrates the average intensity profile of the outer retina in the nasal  
208 parafovea from 3mm to 6mm eccentricity, corresponding to the outer parafoveal ETDRS  
209 subfield (indicated with vertical white dashed lines in **Figure 3A**). There is a marked  
210 decrease in the pixel intensity of regions corresponding to band 3i and 3o (red line)  
211 relative to the average of three control subjects (black line) as well as in comparison to  
212 the intensity of bands 4 and 5, suggestive of damage to the photoreceptor bands. This  
213 decrease in band reflectivity (~5x decrease) is much larger proportionately than the  
214 qualitative decrease in the thickness from ELM to Bruch's membrane illustrated in  
215 **Figure 3G**. Also, the mean retinal thickness from the same 3mm to 6mm nasal  
216 parafoveal ETDRS subfield is within the normal range relative to a normative database  
217 (279  $\mu\text{m}$  in **Figure 3F**).

218

219 **Figure 4** illustrates data from a 71-75 age range female subject with a 5-year history of  
220 hydroxychloroquine use and excellent best corrected visual acuity of 20/25 in the right  
221 eye and 20/20 in the left eye. She denied any subjective vision changes at the time of  
222 the examination. SD and SS-OCT images suggested a very mild parafoveal attenuation  
223 of the external limiting membrane and/or ellipsoid zone. Serial SD-OCT central subfield  
224 thickness assessments suggested thinning in the nasal and temporal parafoveal  
225 ETDRS subfields as described in Melles et al., 2022 (**Figure 4F**). These findings were  
226 concerning for early hydroxychloroquine toxicity and the patient was closely monitored  
227 while encouraging minimizing the dose of hydroxychloroquine. VIS-OCT imaging  
228 demonstrates diffuse attenuation of band 3i and patchy parafoveal attenuation of band  
229 3o, which were not clearly apparent on individual b-scans scans in commercially  
230 available devices (**Figure 4A versus 4B**) nor in control subjects (**Figure 4C,D**  
231 compared to Figure 4E). Similar to the subject demonstrated in **Figure 3**, there was a  
232 marked decrease in the intensity of the photoreceptor bands (particularly bands 3i and  
233 3o) relative to the intensity of bands 4 and 5 (**Figure 4G**). This decrease in band  
234 reflectivity was present despite of any qualitative decrease in the thickness from ELM to  
235 Bruch's membrane, as illustrated in Figure 4G. The subject ultimately stopped HCQ due  
236 to the significant concern for early toxicity.

237

238 VIS-OCT imaging of subjects with symptomatic and severe HCQ retinal toxicity  
239 demonstrated marked parafoveal attenuation of bands 2, 3i, 3o, and 4 (**Figure 5A**).  
240 Given the severity of damage, this attenuation was also evident with SS-OCT (**Figure**

241 **5B)** and with a marked decrease in SD-OCT central subfield retinal thickness as well  
242 **(Figure 5F)**. At the time of imaging, the patient's best-corrected visual acuity was 20/63  
243 in the right eye and 20/80 in the left eye and the patient had been previously diagnosed  
244 with severe HCQ toxicity. The medication had been discontinued prior to our  
245 examination. Notably, even in this subject, there was more severe attenuation of band  
246 3i compared to any other band with increasing eccentricity beyond the parafovea where  
247 clear atrophy was not evident. While all bands were less distinct than normal, bands 1,  
248 2 and 3o were particularly diffuse when compared with a control subject **(Figure 5C, D**  
249 **compared for E)**. In no case was the attenuation of any band more severe than the  
250 attenuation of Band 3i **(Figure 5G)**. As in the previous case, this decrease in band  
251 reflectivity was present despite of any qualitative decrease in the thickness from ELM to  
252 Bruch's membrane, as illustrated in **Figure 5G**.

253

## 254 **Discussion**

255 Using ultrahigh resolution visible light OCT, we demonstrate outer retinal banding  
256 patterns that are not clearly or reliably visible with commercially available SD or SS-  
257 OCT. Most importantly, these changes in banding pattern reflectivity are much larger in  
258 magnitude than changes in retinal thickness measured qualitatively or quantitatively on  
259 SD-OCT or SS-OCT. We also demonstrate that the outer retinal band intensity profiles  
260 on VIS-OCT in healthy controls are similar to the known density profiles of rods and  
261 cones from histologic studies. In control subjects, we consistently identify five outer  
262 retinal bands in the foveola (Bands 1, 2, 3, 4, and 5) and six bands in the parafovea  
263 (Bands 1, 2, 3i, 3o, 4, and 5). These bands putatively represent (1) the external limiting

264 membrane, (2) the ellipsoid zone, (3i) the cone outer segment tips, (3o) the rod outer  
265 segment tips, (4) the retinal pigment epithelium and (5) Bruch's membrane. These data  
266 strongly suggest that VIS-OCT imaging can distinguish rod- and cone-specific retinal  
267 anatomy non-invasively.

268

269 We demonstrate the utility of ultrahigh resolution VIS-OCT to detect sub-clinical  
270 changes in the outer retinal band reflectivity corresponding to photoreceptor outer  
271 segments in asymptomatic subjects at high risk of hydroxychloroquine toxicity.  
272 Specifically, we observe that Band 3i (corresponding to the putative cone outer segment  
273 tips) is consistently and most severely attenuated in subjects at high risk of toxicity and  
274 in whom serial SD-OCT measurements from commercial devices demonstrate retinal  
275 thinning. Notably, this latter finding of serial thinning has been implicated in HCQ  
276 toxicity<sup>6</sup>. We hypothesize that attenuation of Band 3i is the earliest sign of HCQ toxicity  
277 and may be readily detectable on a single visit VIS-OCT while serial SD-OCT  
278 measurements over months or years are needed to detect decreasing thickness trends.  
279 In our individual VIS-OCT scans, the attenuation of VIS-OCT banding reflectivity is  
280 present despite normal retinal thickness as measured with central subfield thickness  
281 using SD-OCT when compared with age-matched control subjects. We hypothesize that  
282 this outer retinal attenuation of band 3i is the earliest known marker of  
283 hydroxychloroquine toxicity. Our analyses assessing the cumulative intensity of bands  
284 3i and 3o at increasing retinal eccentricities in **Figure 2** closely align with previously  
285 published anatomical studies quantifying cone and rod densities<sup>24</sup>, supporting the

286 hypothesis that these bands represent the cone and rod photoreceptor outer segments,  
287 respectively.

288

289 The mechanism of hydroxychloroquine retinopathy is not clearly understood, though  
290 prior studies have suggested multiple potential mechanisms<sup>26</sup>. A study by Xu et al.  
291 demonstrates that both chloroquine and hydroxychloroquine inhibit organic anion  
292 transporting peptide 1A2 (OATP1A2), which mediates uptake of all-*trans*-retinoic acid in  
293 the retinal pigment epithelium in the visual cycle.<sup>27</sup> This may lead to toxicity of both  
294 photoreceptors as well as the retinal pigment epithelium. Animal studies have revealed  
295 the binding of chloroquine to pigmented retinal structures, including the retinal pigment  
296 epithelium<sup>28</sup>. It is unclear why band 3i appears to be attenuated first in subjects on HCQ  
297 followed by band 3o, though this finding suggests a tendency for cone photoreceptors to  
298 be preferentially over rods. In more severe stages, as shown in **Figure 5**, there appears  
299 to be attenuation of the remaining outer retinal bands including the retinal pigment  
300 epithelium, favoring a mechanism of toxicity affecting both the RPE as well as the  
301 photoreceptors.

302

303 Recent work has measured ellipsoid zone attenuation with SD-OCT to detect and  
304 quantify HCQ toxicity<sup>29,30</sup>. Our results demonstrate the ability of VIS-OCT imaging to  
305 detect early HCQ toxicity with attenuation of the photoreceptor bands, which are not  
306 easily visible with SD-OCT or SS-OCT, prior to EZ attenuation. We demonstrate that  
307 early HCQ toxicity is characterized mainly by attenuation of bands 3i and 3o, with more  
308 severe toxicity affecting the EZ and the retinal pigment epithelium. This corroborates

309 earlier studies that suggest damage occurs to the photoreceptors<sup>4,28</sup>. As demonstrated  
310 in Figures 3 and 4, early toxicity is often not apparent on individual line scans with SS-  
311 OCT (or SD-OCT), requiring averaging of retinal thickness across a large region to  
312 observe retinal thinning on serial thickness maps. Using VIS-OCT, these changes are  
313 apparent on foveal line scans, and may assist with earlier diagnosis of HCQ toxicity.

314

315 It is important to note that there are limitations to VIS-OCT imaging compared to SS-  
316 OCT and conventional FDA approved devices. First, the brightness of the visible light  
317 used to acquire VIS-OCT images can be distracting to patients, particularly when  
318 utilizing lengthy imaging protocols or in patients who are light sensitive. Additionally,  
319 while its increased resolution allows for visualization of Bruch's membrane, visible light  
320 is limited in its ability to penetrate beyond Bruch's membrane and visualize structures  
321 within the choroid, which may limit its utility in the diagnosis of choroidal pathologies.

322

323 Due to our small sample size and our study being limited to subjects with HCQ use and  
324 toxicity, it remains unclear whether the pattern of changes described can also be seen  
325 in other retinal diseases or whether they are specific to HCQ toxicity. Our findings  
326 support previous work suggesting that anatomically detectable damage to  
327 photoreceptors precedes similar damage to the RPE<sup>1,4</sup>. Prospective studies and  
328 analyses with larger sample sizes will be necessary to further characterize these  
329 changes. Additionally, as previously described, the pattern of retinal toxicity and vision  
330 loss associated with HCQ use varies in patients of Asian descent, and additional work is  
331 necessary to determine whether VIS-OCT can demonstrate this difference or provide

332 further insight into its pathogenesis. Prior work has also demonstrated that in a minority  
333 of patients, early HCQ toxicity is detected on visual field testing prior to clear SD-OCT  
334 changes although this is likely due to the limited resolution of single SD-OCT scans to  
335 reliably demonstrate changes in the outer retinal layers as we have shown above.<sup>31</sup>  
336 Further work with a larger sample size is necessary to determine whether changes on  
337 VIS-OCT can reliably be detected prior to visual field changes.



## 338 References

- 339 1. Marmor MF, Kellner U, Lai TYY, Melles RB, Mieler WF. Recommendations on  
340 Screening for Chloroquine and Hydroxychloroquine Retinopathy (2016 Revision).  
341 *Ophthalmology*. 2016;123(6):1386-1394. doi:10.1016/j.ophtha.2016.01.058
- 342 2. Gonasun LM, Potts AM. In vitro inhibition of protein synthesis in the retinal pigment  
343 epithelium by chloroquine. *Investigative Ophthalmology*. 1974;13(2).
- 344 3. Sundelin SP, Terman A. Different effects of chloroquine and hydroxychloroquine on  
345 lysosomal function in cultured retinal pigment epithelial cells. *APMIS*.  
346 2002;110(6):481-489. doi:10.1034/j.1600-0463.2002.100606.x
- 347 4. Marmor MF. Comparison of Screening Procedures in Hydroxychloroquine Toxicity.  
348 *Arch Ophthalmol*. 2012;130(4):461. doi:10.1001/archophthalmol.2011.371
- 349 5. Ruberto G, Bruttini C, Tinelli C, Cavagna L, Bianchi A, Milano G. Early morpho-  
350 functional changes in patients treated with hydroxychloroquine: a prospective cohort  
351 study. *Graefes Arch Clin Exp Ophthalmol*. 2018;256(11):2201-2210.  
352 doi:10.1007/s00417-018-4103-9
- 353 6. Melles RB, Marmor MF. Rapid Macular Thinning Is an Early Indicator of  
354 Hydroxychloroquine Retinal Toxicity. *Ophthalmology*. 2022;129(9):1004-1013.  
355 doi:10.1016/j.ophtha.2022.05.002
- 356 7. Ugwuegbu O, Uchida A, Singh RP, et al. Quantitative assessment of outer retinal  
357 layers and ellipsoid zone mapping in hydroxychloroquine retinopathy. *Br J*  
358 *Ophthalmol*. 2019;103(1):3-7. doi:10.1136/bjophthalmol-2018-312363
- 359 8. Barnes AC, Bhavsar KV, Weber ML, Witkin AJ. A subtle case of hydroxychloroquine  
360 retinopathy: spectral domain optical coherence tomography findings. *Eye*.  
361 2014;28(12):1521-1522. doi:10.1038/eye.2014.212
- 362 9. Kim KE, Ahn SJ, Woo SJ, et al. Use of OCT Retinal Thickness Deviation Map for  
363 Hydroxychloroquine Retinopathy Screening. *Ophthalmology*. 2021;128(1):110-119.  
364 doi:10.1016/j.ophtha.2020.06.021
- 365 10. De Sisternes L, Hu J, Rubin DL, Marmor MF. Analysis of Inner and Outer Retinal  
366 Thickness in Patients Using Hydroxychloroquine Prior to Development of  
367 Retinopathy. *JAMA Ophthalmol*. 2016;134(5):511.  
368 doi:10.1001/jamaophthalmol.2016.0155
- 369 11. Yi J, Wei Q, Liu W, Backman V, Zhang HF. Visible-light optical coherence  
370 tomography for retinal oximetry. Published online 2014.

- 371 12. Zhang T, Kho AM, Yiu G, Srinivasan VJ. Visible Light Optical Coherence  
372 Tomography (OCT) Quantifies Subcellular Contributions to Outer Retinal Band 4.  
373 *Trans Vis Sci Tech*. 2021;10(3):30. doi:10.1167/tvst.10.3.30
- 374 13. Srinivasan VJ, Kho AM, Chauhan P. Visible Light Optical Coherence Tomography  
375 Reveals the Relationship of the Myoid and Ellipsoid to Band 2 in Humans. *Trans Vis*  
376 *Sci Tech*. 2022;11(9):3. doi:10.1167/tvst.11.9.3
- 377 14. Shu X, Beckmann L, Wang Y, et al. Designing visible-light optical coherence  
378 tomography towards clinics. *Quant Imaging Med Surg*. 2019;9(5):769-781.  
379 doi:10.21037/qims.2019.05.01
- 380 15. Yi J, Chen S, Shu X, Fawzi AA, Zhang HF. Human retinal imaging using visible-light  
381 optical coherence tomography guided by scanning laser ophthalmoscopy. *Biomed*  
382 *Opt Express*. 2015;6(10):3701. doi:10.1364/BOE.6.003701
- 383 16. Chauhan P, Kho AM, FitzGerald P, Shibata B, Srinivasan VJ. Subcellular  
384 Comparison of Visible-Light Optical Coherence Tomography and Electron  
385 Microscopy in the Mouse Outer Retina. *Invest Ophthalmol Vis Sci*. 2022;63(9):10.  
386 doi:10.1167/iovs.63.9.10
- 387 17. Chauhan P, Kho AM, Srinivasan VJ. From Soma to Synapse: Imaging Age-Related  
388 Rod Photoreceptor Changes in the Mouse with Visible Light OCT. *Ophthalmology*  
389 *Science*. 2023;3(4):100321. doi:10.1016/j.xops.2023.100321
- 390 18. Wang J, Nolen S, Song W, Shao W, Yi W, Yi J. *Second-Generation Dual-Channel*  
391 *Visible Light Optical Coherence Tomography Enables Wide-Field, Full-Range, and*  
392 *Shot-Noise Limited Retinal Imaging*. *Biophysics*; 2022.  
393 doi:10.1101/2022.10.05.511048
- 394 19. Won J, Takahashi H, Ploner SB, et al. Topographic Measurement of the Subretinal  
395 Pigment Epithelium Space in Normal Aging and Age-Related Macular Degeneration  
396 Using High-Resolution OCT. *Invest Ophthalmol Vis Sci*. 2024;65(10):18.  
397 doi:10.1167/iovs.65.10.18
- 398 20. Reche J, Stocker AB, Henchoz V, et al. High-Resolution Optical Coherence  
399 Tomography in Healthy Individuals Provides Resolution at the Cellular and  
400 Subcellular Levels. *Trans Vis Sci Tech*. 2023;12(7):12. doi:10.1167/tvst.12.7.12
- 401 21. Wang J, Nolen S, Song W, et al. A dual-channel visible light optical coherence  
402 tomography system enables wide-field, full-range, and shot-noise limited human  
403 retinal imaging. *Commun Eng*. 2024;3(1):21. doi:10.1038/s44172-024-00167-7
- 404 22. Rubinoff I, Beckmann L, Wang Y, et al. Speckle reduction in visible-light optical  
405 coherence tomography using scan modulation. *Neurophoton*. 2019;6(04):1.  
406 doi:10.1117/1.NPh.6.4.041107

- 407 23. Zhang T, Kho AM, Srinivasan VJ. In vivo Morphometry of Inner Plexiform Layer  
408 (IPL) Stratification in the Human Retina With Visible Light Optical Coherence  
409 Tomography. *Front Cell Neurosci.* 2021;15:655096. doi:10.3389/fncel.2021.655096
- 410 24. Curcio CA, Sloan KR, Kalina RE, Hendrickson AE. Human photoreceptor  
411 topography. *J Comp Neurol.* 1990;292(4):497-523. doi:10.1002/cne.902920402
- 412 25. Song H, Chui TYP, Zhong Z, Elsner AE, Burns SA. Variation of Cone Photoreceptor  
413 Packing Density with Retinal Eccentricity and Age. *Invest Ophthalmol Vis Sci.*  
414 2011;52(10):7376. doi:10.1167/iovs.11-7199
- 415 26. Yusuf IH, Sharma S, Luqmani R, Downes SM. Hydroxychloroquine retinopathy. *Eye.*  
416 2017;31(6):828-845. doi:10.1038/eye.2016.298
- 417 27. Xu C, Zhu L, Chan T, et al. Chloroquine and Hydroxychloroquine Are Novel  
418 Inhibitors of Human Organic Anion Transporting Polypeptide 1A2. *Journal of*  
419 *Pharmaceutical Sciences.* 2016;105(2):884-890. doi:10.1002/jps.24663
- 420 28. Rosenthal R, Kolb H, Bergsma D, Huxsoll D, Hopkins JL. Chloroquine retinopathy in  
421 the rhesus monkey. 1978;17(12).
- 422 29. Kalra G, Talcott KE, Kaiser S, et al. Machine Learning–Based Automated Detection  
423 of Hydroxychloroquine Toxicity and Prediction of Future Toxicity Using Higher-Order  
424 OCT Biomarkers. *Ophthalmology Retina.* 2022;6(12):1241-1252.  
425 doi:10.1016/j.oret.2022.05.031
- 426 30. De Silva T, Jayakar G, Grisso P, Hotaling N, Chew EY, Cukras CA. Deep Learning-  
427 Based Automatic Detection of Ellipsoid Zone Loss in Spectral-Domain OCT for  
428 Hydroxychloroquine Retinal Toxicity Screening. *Ophthalmology Science.*  
429 2021;1(4):100060. doi:10.1016/j.xops.2021.100060
- 430 31. Marmor MF, Melles RB. Disparity between Visual Fields and Optical Coherence  
431 Tomography in Hydroxychloroquine Retinopathy. *Ophthalmology.*  
432 2014;121(6):1257-1262. doi:10.1016/j.ophtha.2013.12.002

433

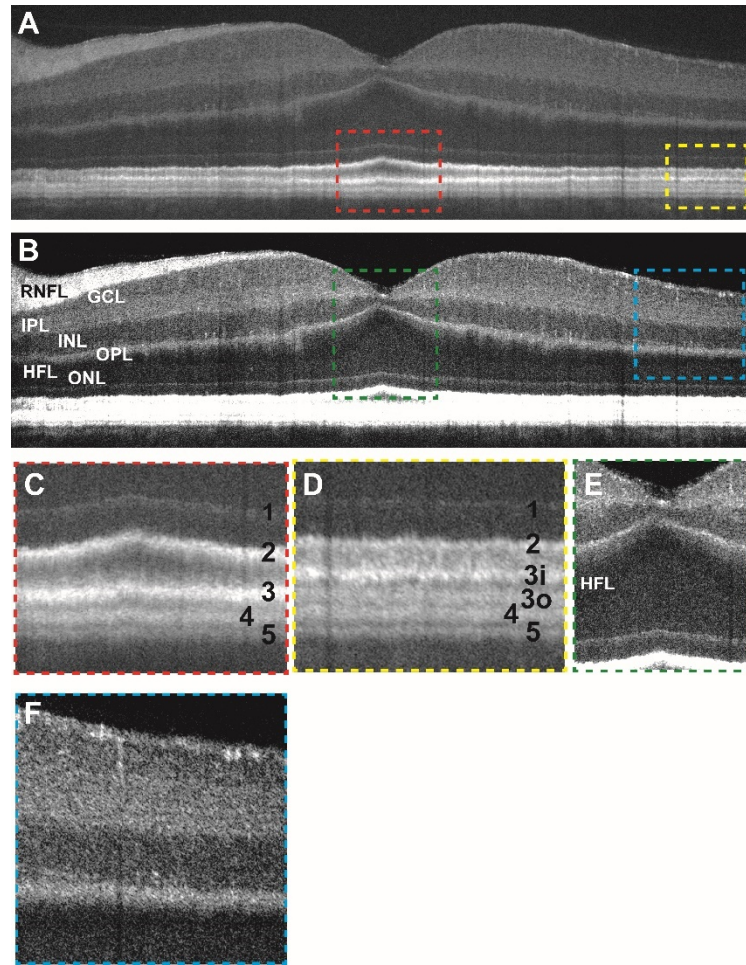
434 **Tables**

435 **Table 1:** Demographic information of study subjects

Subject	Diagnosis	Age range	Race	Sex	Years HCQ Use	Known Toxicity?	Cumulative HCQ Dose, Renal/Hepatic Function	Visual Acuity
271	SLE	66-70	WNH	F	22	suspected	3212 gm Creatine: 0.9 mg/dl AST/ALT: 25/19 U/L	20/20 OU
308	SLE	66-70	BNH	F	27	no	4088 gm Creatine: 0.89 mg/dl AST/ALT: 25/17 U/L	20/20 OU
178	Sjogren's Syndrome and SLE	51-55	WNH	F	4	yes	584 gm Creatine: 0.56 mg/dl AST/ALT: 29/26 u/L	20/50 OD 20/80 OS
347	RA	76-80	WNH	F	31	suspected	4526 gm Creatine: 1.5 mg/dL AST/ALT: 26/19 U/L	20/50 OD 20/40 OS
370	Undifferentiated connective tissue disease	31-35	WNH	F	1	no	146 gm Creatine: 0.7 mg/dL AST/ALT: 17/26 U/L	20/20 OU
374	SLE	31-35	BNH	F	2	no	292 gm Creatine: 0.7 mg/dL AST/ALT: 22/20 U/L	20/20 OU
417	RA	76-80	WNH	F	35	yes	unknown cumulative dose Creatine: 0.9 mg/dL AST/ALT: 40/25 U/L	20/50 OD 20/250 OS
439	SLE	61-65	WNH	F	11	no	1204.5 gm Creatine: 1.5 mg/dL	20/20 OU

							AST/ALT: 21/10 U/L	
445	RA and Sarcoidosis	81-85	WNH	M	5	no	730 gm Creatine: 0.99 AST/ALT: 18/7 U/L	20/40 OD 20/25 OS
378	SLE	71-75	BNH	F	5	suspected	730 gm Creatine: 0.9 mg/dL AST/ALT: 19/15 U/L	20/25 OU
<b>Subject</b>	<b>Diagnosis</b>	<b>Age</b>	<b>Race</b>	<b>Sex</b>	<b>Eye(s) Imaged</b>		<b>Diagnosis</b>	
451	Control	26-30	BNH	M	OU		N/A	-
456	Control	21-25	WNH	F	OU		N/A	20/20 OU
446	Control	21-25	WNH	F	OU		N/A	20/20 OU
464	Control	21-25	WNH	F	OU		N/A	-
465	Control	21-25	BNH	F	OU		N/A	20/20 OU
402	Control	66-70	WNH	M	OU		N/A	20/20 OU
399	Control	26-30	ANH	F	OD		Optic disc pit OS	20/20 OD
395	Control	76-80	WNH	F	OU		PVD OU	20/32 OD 20/25 OS
385	Control	26-30	WH	M	OU		N/A	-
303	Control	61-65	WNH	F	OD		Choroidal nevus OS	20/32 OD
409	Control	31-35	WNH	F	OU		CRVO OS	20/32 OD 20/12.5 OS
333	Control	56-60	BNH	M	OU		PVD OD	20/20 OU
<p>The final column ("Notes") includes the cumulative HCQ dose and renal/hepatic function testing results for subjects with a history of hydroxychloroquine use. For control subjects, the primary diagnosis resulting in examination in the retina clinic is listed ("N/A" indicates subjects who were recruited as a control subject without any ocular complaint). AST: aspartate transaminase; ALT: alanine transaminase; BNH: black/non-Hispanic; CRVO: central retinal vein occlusion; HCQ: hydroxychloroquine; OD: right eye; OS: left eye; OU: both eyes; PVD: posterior vitreous detachment; RA: rheumatoid arthritis; SLE: systemic lupus erythematosus; WNH: white/non-Hispanic</p>								

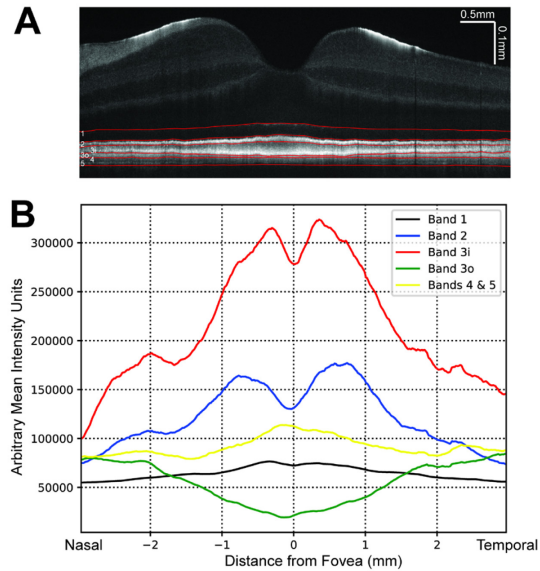
437 **Figures**



438

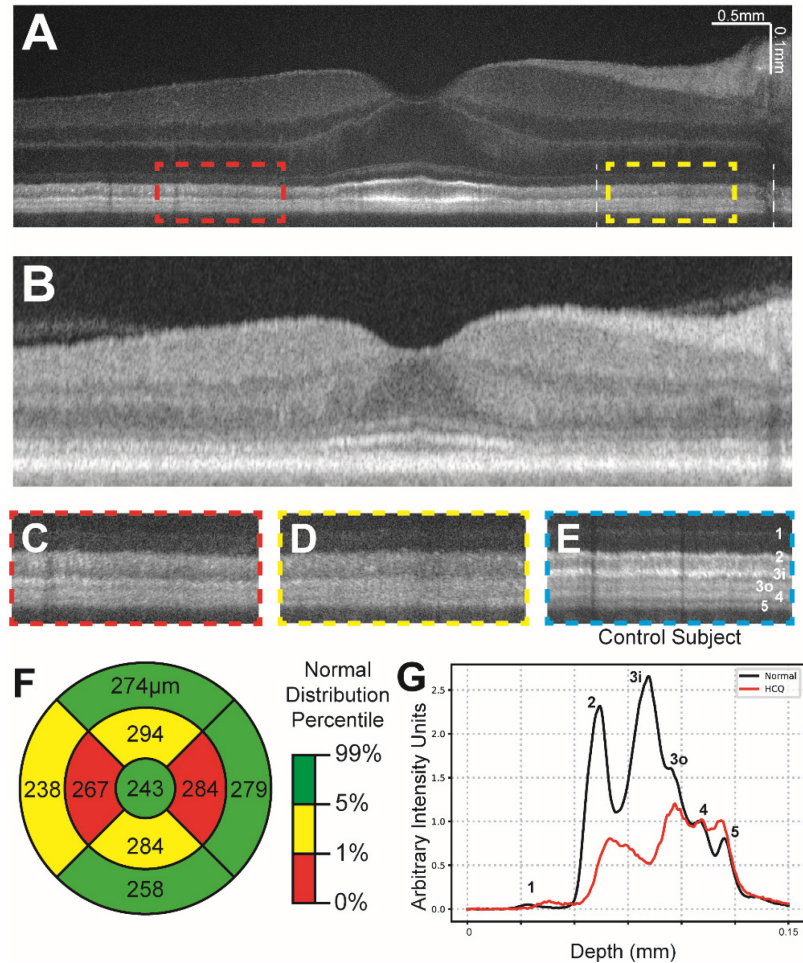
439 **Figure 1:** (a) Contrast-adjusted VIS-OCT image of a 36-40 age range Caucasian male  
440 subject with no known ocular history or retinal pathology highlighting outer retinal  
441 features. (b) Contrast-adjusted image highlighting inner retinal features. (c) Magnified  
442 view of foveal outer retinal features seen in panel (a) demonstrating outer retinal  
443 banding pattern with outer retinal bands labeled. (d) Magnified view of parafoveal outer  
444 retina. (e) Magnified view of foveal inner retinal features seen in panel (c) (see  
445 abbreviations below). (f) Magnified view of parafoveal inner retinal features.

446 RNFL: retinal nerve fiber layer, GCL: ganglion cell layer, IPL: inner plexiform layer, INL:  
447 inner nuclear layer, OPL: outer plexiform layer, ONL: outer nuclear layer, HFL: Henle's  
448 fiber layer



449

450 Figure 2: (a) VIS-OCT image of control subject demonstrating manual segmentation of  
451 outer retinal layers (red). (b) Mean intensity of each outer retinal band (summation of  
452 intensity between manually segmented outer retinal bands) averaged across three  
453 control subjects shown relative to distance from the foveal pit.

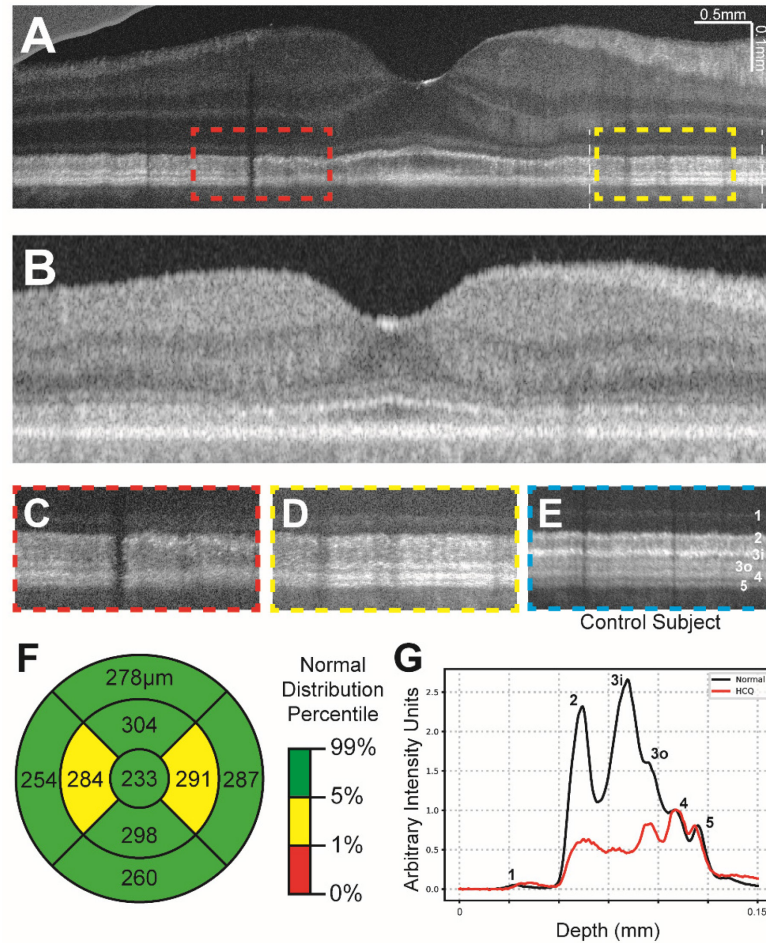


454

455 **Figure 3:** (a) Contrast-adjusted VIS-OCT image of a 61-65 age range subject with a  
456 history of systemic lupus erythematosus and 11 years of hydroxychloroquine use. (b)  
457 Swept-source OCT image of same subject in (a). (c-d) Magnified view of parafoveal  
458 outer retinal features (dashed lines in (a)) demonstrating broadening of band 2 and loss  
459 of layer 3i. (e) Magnified view of outer retinal features from control subject at similar  
460 distance to fovea as c-d, scaled to align with panels c-d. (f) Central subfield thickness  
461 map of total retinal thickness obtained from swept-source OCT, measurements listed in  
462 micrometers. Coloring indicates normal distribution percentile per device manufacturer.  
463 (g) Averaged A-line signal over nasal 3mm-6mm eccentricity from Panel A between two



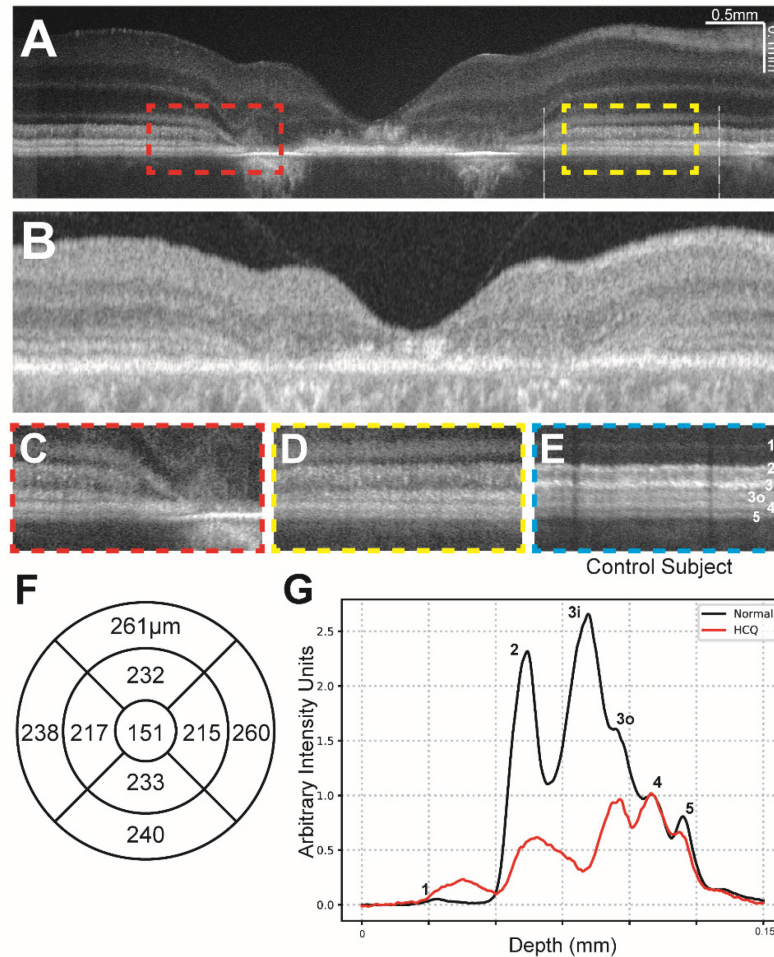
464 white lines. The A-line trace signal is extracted from the same region in normal eyes in  
465 Figure 1. Both A-lines have zero means and were normalized to RPE band.



466

467 **Figure 4:** (a) Contrast-adjusted VIS-OCT image of 71-75 age range patient with a 5-year  
468 history of HCQ use and suspected HCQ retinal toxicity. (c-d) Magnified view of  
469 parafoveal outer retinal features (dashed lines in (a)) demonstrating broadening of band  
470 2 and loss of band 3i and patchy attenuation of band 3o. (e) Magnified view of outer  
471 retinal features from control subject at similar distance to fovea as c-d, scaled to align  
472 with panels c-d. (f) Central subfield thickness map of total retinal thickness obtained  
473 from swept-source OCT, measurements listed in micrometers. (g) Averaged A-line

474 signal over nasal 3mm-6mm eccentricity from Panel A between two white lines. The A-  
475 line trace signal is extracted from the same region in normal eyes in Figure 1. Both A-  
476 lines have zero means and were normalized to RPE band.



477

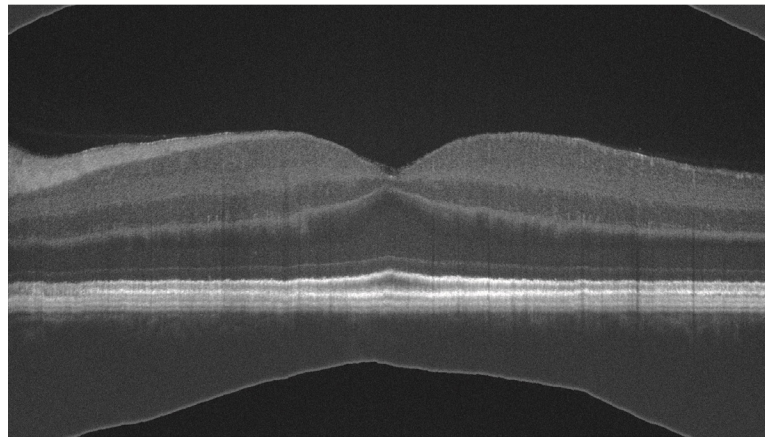
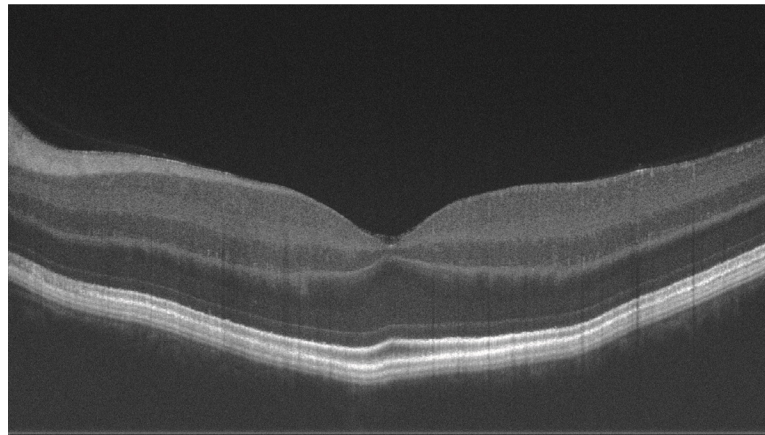
478 **Figure 5:** (a) Contrast-adjusted VIS-OCT image of 51-55 age range patient with a 4-year  
479 history of HCQ use with severe HCQ retinal toxicity and no other known retinal  
480 pathology. (c-d) Magnified view of parafoveal outer retinal features (dashed lines in (a))  
481 demonstrating diffuse loss of bands 2, 3i, 3o, and 4. (e) Magnified view of outer retinal  
482 features from control subject at similar distance to fovea as c-d, scaled to align with  
483 panels c-d. (f) Central subfield thickness map of total retinal thickness obtained from

484 swept-source OCT, measurements listed in micrometers. Normative data not available.

485 **(g)** Averaged A-line signal over nasal 3mm-6mm eccentricity from Panel A between two

486 white lines. The A-line trace signal is extracted from the same region in normal eyes in

487 Figure 1. Both A-lines have zero means and were normalized to RPE band.

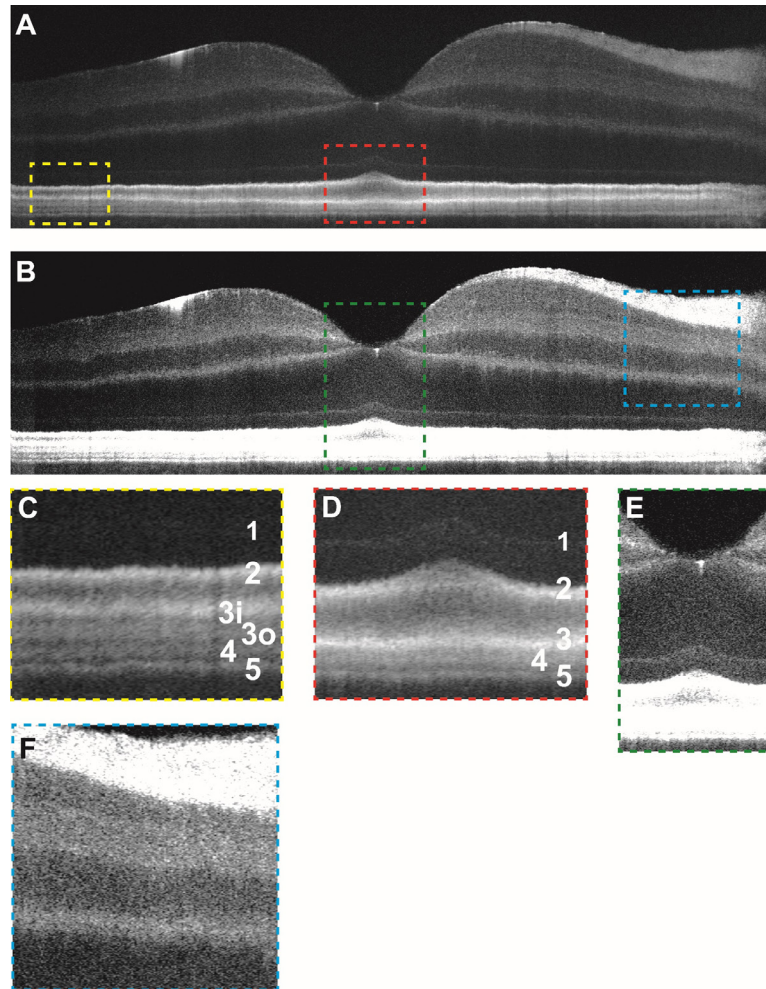


488

489 Supplemental Figure 1: **(a)** Sample raw output of foveal line scan from VIS-OCT device

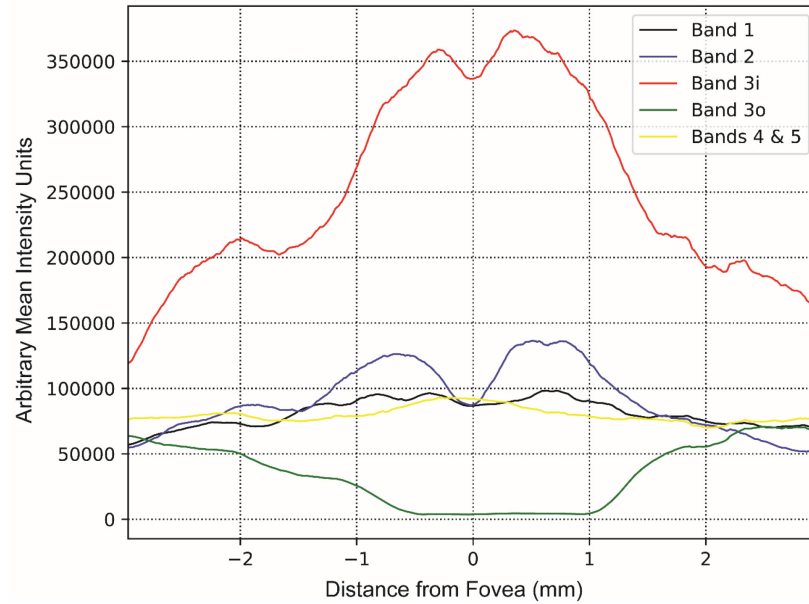
490 prior to image processing. **(b)** Foveal line scan following image flattening and contrast

491 adjustment as described in Methods.



492

493 Supplemental Figure 2: (a) Contrast-adjusted VIS-OCT image of a 26-30 age range  
494 Caucasian male subject with no known ocular history or retinal pathology highlighting  
495 outer retinal features. (b) Contrast-adjusted image highlighting inner retinal features. (c)  
496 Magnified view of foveal outer retinal features seen in panel (a) demonstrating outer  
497 retinal banding pattern with outer retinal bands labeled. (d) Magnified view of parafoveal  
498 outer retina. (e) Magnified view of foveal inner retinal features seen in panel (c) (see  
499 abbreviations below). (f) Magnified view of parafoveal inner retinal features.



500

501 Supplemental Figure 3: Mean intensity of each outer retinal band (summation of  
502 intensity between manually segmented outer retinal bands) averaged across three  
503 control subjects shown relative to distance from the foveal pit for VIS-OCT scan  
504 displayed in Figure 2A. Manual segmentation of outer retinal bands performed  
505 independently by second grader.