

1 Original Article

## 2 **Development and Validation of Collaborative Robot-assisted** 3 **Cutting Method for Iliac Crest Flap Raising: Randomized** 4 **Crossover Trial**

5 **Paulina Becker<sup>1,2</sup>, Yao Li<sup>1,2</sup>, Sergey Drobinsky<sup>3</sup>, Jan Egger<sup>4</sup>, Kunpeng Xie<sup>1,2</sup>, Ashkan Rashad<sup>1</sup>, Klaus Radermacher<sup>3</sup>,**  
6 **Rainer Röhrig<sup>2</sup>, Matías de la Fuente<sup>3</sup>, Frank Hölzle<sup>1</sup>, Behrus Puladi<sup>1,2,\*</sup>**

7  
8 1 Department of Oral and Maxillofacial Surgery, University Hospital RWTH Aachen, Aachen, Germany

9 2 Institute of Medical Informatics, University Hospital RWTH Aachen, Aachen, Germany

10 3 Chair of Medical Engineering, RWTH Aachen University, 52074 Aachen, Germany

11 4 Institute for Artificial Intelligence in Medicine, University of Duisburg-Essen, 45131 Essen, Germany

12

### 13 **\*Corresponding author:**

14 Dr. med. Dr. med. dent. Behrus Puladi

15 E-mail: [bpuladi@ukaachen.de](mailto:bpuladi@ukaachen.de)

16 Tel.: +49-241-80-38389

17 Fax: +49-241-80-82430

18 Department of Oral and Maxillofacial Surgery & Institute of Medical Informatics

19 University Hospital RWTH Aachen,

20 Pauwelsstraße 30, 52074 Aachen, Germany

21

22

### 23 **Abstract:**

24 The current gold standard of computer-assisted jaw reconstruction includes raising microvascular bone flaps with  
25 patient-specific 3D-printed cutting guides. The downsides of cutting guides are invasive fixation, periosteal  
26 denudation, preoperative lead time and missing intraoperative flexibility. This study aimed to investigate the  
27 feasibility and accuracy of a robot-assisted cutting method for raising iliac crest flaps compared to a conventional  
28 3D-printed cutting guide.

29 In a randomized crossover design, 40 participants raised flaps on pelvic models using conventional cutting guides  
30 and a robot-assisted cutting method. The accuracy was measured and compared regarding osteotomy angle  
31 deviation, Hausdorff Distance (HD) and Average Hausdorff Distance (AVD). Duration, workload and usability  
32 were further evaluated.

33 The mean angular deviation for the robot-assisted cutting method was  $1.9 \pm 1.1^\circ$  (mean $\pm$ sd) and for the 3D-printed  
34 cutting guide it was  $4.7 \pm 2.9^\circ$  ( $p < 0.001$ ). The HD resulted in a mean value of  $1.5 \pm 0.6$ mm (robot) and  $2.0 \pm 0.9$ mm  
35 (conventional) ( $p < 0.001$ ). For the AVD, this was  $0.8 \pm 0.5$ mm (robot) and  $0.8 \pm 0.4$ mm (conventional) ( $p = 0.320$ ).

36 Collaborative robot-assisted cutting is an alternative to 3D-printed cutting guides in experimental static settings,  
37 achieving slot design benefits with less invasiveness and higher intraoperative flexibility. In the next step, the  
38 results should be tested in a dynamic environment with a moving phantom and on the cadaver.

39 **NOTE: This preprint reports new research that has not been certified by peer review and should not be used to guide clinical practice.**

40 **Keywords:** Surgical robotics; Computer-assisted surgery; Iliac crest flap; DCIA flap; Cutting guide; Augmented  
41 Reality

## 42 **Introduction**

43 Surgical reconstruction of the lower jaw (mandible) and upper jaw (maxilla) is a complex procedure in oral  
44 and maxillofacial surgery (OMFS), that is performed to restore bone continuity and its physiological functions,  
45 such as mastication, swallowing or speech [1]. In addition to functionality, the surgery must meet aesthetic  
46 requirements as well [2]. Common reasons for jaw discontinuity are tumors, congenital malformations, severe  
47 osteomyelitis/osteonecrosis or severe trauma [3]. The reconstruction of the jaw can be performed using different  
48 donor sites. Typically, vascularized flaps are raised from the fibula, iliac crest, or scapula, each having its strengths  
49 and limitations [4].

50 In recent years, computer-assisted surgery (CAS) has become the gold standard for maxillofacial reconstruction  
51 compared to freehand reconstruction. Based on surface models from preoperative computed tomography (CT) or  
52 cone beam computed tomography (CBCT) scans, CAS involves virtual surgical planning (VSP) of the lower or  
53 upper jaw resection and corresponding bone reconstruction with an osseous flap. The preoperative plan is then  
54 translated to the operating room using 3D-printed cutting guides for both jaw resection and flap raising [5]. This  
55 increases the accuracy and safety of bone resection, including flap raising, while decreasing surgical time and  
56 duration of ischemia [6].

57 However, 3D-printed guides have several downsides: A lack of intraoperative flexibility due to the need of  
58 preoperative design, fabrication, and sterilization [7]; the manufacturing process itself is time-consuming and  
59 costly [6]; the need of operative invasive fixation of the guide, including some periosteal denudation to ensure  
60 proper placement of the guide, which can potentially compromise bone perfusion and could cause osteonecrosis  
61 [8–10];

62 For this reason, an attempt was already made in 2011 to use classic navigation instead of 3D-printed cutting  
63 guides [11,12] . However, surgical navigation has the disadvantage that the spatial separation between the surgical  
64 field and the surgical navigation has a negative impact on hand-eye coordination and depth perception [12,13],  
65 which worsens with increasing complexity of the surgical task. Therefore, several studies have attempted to  
66 develop alternative flap raising systems with robotic approaches [7,14–18] as well as augmented reality (AR) [19–  
67 23] (Table 1). Both methods have different advantages and disadvantages. So far, robotic approaches have only  
68 been investigated for free fibula flaps (FFF) and on the mandibula [24], but no studies investigated haptic robot-  
69 assisted methods for deep circumflex iliac artery (DCIA) flap harvesting. However, the results about FFF  
70 harvesting are not directly transferable to DCIA raising because unlike FFF, where only isolated vertical

71 osteotomies are required due to the anatomy of the fibula, the anatomy of the iliac crest requires at least one  
72 horizontal osteotomy to connect the osteotomy planes.

### 73 *State of the Art*

74 Hu et al. presented a haptic-guided robotic approach for raising FFFs by sensor-aware hybrid force-motion  
75 control [7]. The sensor increased or decreased the motion or stopped the osteotomy when a change in force  
76 occurred. Based on the VSP the robotic arm moves to the preplanned trajectory, while the saw can still be  
77 controlled by the surgeon. An optical tracker was used to register the position of the fibula and to navigate  
78 according to the VSP. In a preclinical study, de Boutray et al. developed a robotic system for FFF raising, where  
79 a robotic arm placed a surgical guide with optical tracking markers on the bone which allowed the participants to  
80 perform the osteotomies [15]. The collaborative approaches showed angular accuracies of  $1.3\pm 0.7^\circ$  [7] and  
81  $1.9\pm 1.2^\circ$  [15].

82 In addition to the use of robots with haptic augmentation, systems with visual augmentation have been  
83 developed. Pietruski et al. demonstrated an application with AR with head-mounted displays (HMDs) in 2020,  
84 comparing a single AR approach to a combined approach with Navigation and AR. 3D-printed cutting guides were  
85 used as the control group [19].

86 In 2021, Meng et al. showed an approach with Mixed Reality using HMDs, guided by voice and gestures [20].  
87 Two other studies used a light projection with a robotic arm of the flap design on the iliac crest instead of a robotic  
88 approach in 2022. However, these approaches have shown inaccuracies in visualizing two-dimensional images on  
89 a three-dimensional object [21,22].

90 In 2023, Liu et al. compared AR with HMDs to 3D-printed cutting guides on phantom models of the fibula and  
91 on rabbits [23]. Shao et al. investigated a combined approach with AR and robot-assisted navigation [16]. Battaglia  
92 et al. presented a workflow for a marker less AR approach with a mobile app that displayed a surgical plan of  
93 reconstruction and compared it intraoperatively with the actual anatomy [25].

94 Besides robot-assisted and AR approaches, Chao et al. investigated the feasibility and accuracy of pre-planned  
95 autonomous robotic osteotomies for FFF harvesting. Using VSP, osteotomy planes were generated for three 3D-  
96 printed fibula models and programmed into an autonomous robot with a mounted saw [14]. Zhu et al. compared  
97 three different methods of FFF harvesting. The first method was an autonomous robotic system with optical  
98 tracking, the second was computer-assisted navigation and the third was the freehand technique [26]. Guo et al.  
99 conducted a further study about an autonomous robotic system for FFF harvesting, where an algorithm converted  
100 the preoperative VSP into motion paths [18]. Accuracies for angular deviations for flap raising with autonomous

101 systems range from  $1.6 \pm 1.1^\circ$  to  $4.2 \pm 1.7^\circ$ . To the best of our knowledge, autonomous robotic systems have not  
102 been tested for DCIA raising [14,26]. Overall, the majority of the studies focused on FFF raising.

103 Unlike collaborative robots, autonomous systems have higher regulatory requirements of the FDA or MDR  
104 [27]. Legal requirements are further increased by the risk of injuring important abdominal structures [28,29] and  
105 require patient and surgeon acceptance prior to clinical implementation [30]. While osteotomy angles are not more  
106 accurate than those of collaborative approaches, the overall benefit seems to be small [26].

107 The advantages of collaborative robotic surgery over autonomous systems are consistent with their already  
108 established usage in orthopedic surgery [31,32]. Several systems, such as the MAKO or ROSA Knee System, are  
109 used for hip and knee replacement, reducing the surgeon's physical workload while improving the quality, safety  
110 and efficiency of osteotomies [33]. While the MAKO system consists of a saw, that is mounted to the robot directly  
111 as an end-effector and sets physical limits to protect the cruciate ligaments, the ROSA Knee System places a  
112 cutting guide on the surface of the bone, so that the surgeon cuts along the template manually [32,34]. However,  
113 flap raising like FFF, DCIA flap or scapula flap are different surgical procedures because not only planes, but a  
114 full transplant with soft tissue and most importantly the vascular pedicle is raised. The pedicle is very vulnerable  
115 and must be protected during the surgery to prevent flap loss.

116 Furthermore, the anatomy and especially the vascular supply differs as well. The risk of major bleeding in the  
117 knee is significantly lower than the risk of pelvic bleeding from the iliac vessels or abdominal bleeding or infection,  
118 which can lead to death [35,36]. As these systems do not have approval for procedures like flap raising or jaw  
119 reconstruction, systems like MAKO or ROSA cannot be used one-to-one in OMFS [37].

## 120 *Objectives*

121 For these reasons, this study aimed to present a new approach inspired by systems already used in orthopedic  
122 surgery [31,32] and preclinical collaborative robot-assisted FFF raising [15]. However, all studies about robot-  
123 assisted flap raising in OMFS to date have been exploratory, often lacking gold standard comparisons, while the  
124 small number of participants/osteotomies do not adequately account for possible intra- and interrater variability  
125 (Table 1).

126 To address these limitations, we conducted to our knowledge the first prospective, randomized, crossover study  
127 to evaluate the feasibility and accuracy of a haptic robot-assisted cutting method compared to conventional 3D-  
128 printed cutting guides in DCIA flaps. For this purpose, a static setting with phantom models of the iliac crest was  
129 used and DCIA flaps were raised by participants using both methods.

## 130 **Methods**

### 131 *Study design*

132 40 participants with no prior experience in flap raising with 3D-printed cutting guides (medical and dental  
133 students, residents or specialists in oral surgery or oral and maxillofacial surgery) were included and performed  
134 both methods in a randomized cross-over order (Figure 1). The primary endpoint was the angular deviation of the  
135 osteotomy planes between the planned and raised flaps using the robot-assisted method (intervention) and the 3D-  
136 printed cutting guide (control). Secondary endpoints were the Hausdorff distance (HD) and average Hausdorff  
137 distance (AVD) of the osteotomy planes, the flap raising duration, the perceived workload with NASA-TLX [38]  
138 (German version) [39] and the user satisfaction (Figure 2). The carry-over effect as a training effect was considered  
139 low since the settings of the two methods were not identical and all participants were novices in iliac crest flap  
140 raising.

141 The study was approved by the Ethics Committee of RWTH Aachen University (approval number EK 23-149,  
142 date of approval 20.07.2023) and the study protocol was prospectively registered in the German Clinical Trials  
143 Register (DRKS00031358). The study was successfully conducted at the Chair of Medical Engineering of RWTH  
144 Aachen University, Germany, from July 31, 2023 to September 21, 2023 and followed the CONSORT 2010  
145 guidelines and its extension for crossover studies [40,41].

### 146 *Preparation*

147 For this study, a CT scan was randomly selected from a previous study [42]. After segmentation, the hip model  
148 was reduced to the region of the iliac crest and 3D-printed using a Prusa i3 MKS+ (Prusa Research a.s., Prague,  
149 Czech Republic) and PLA filament (Beige PLA Filament, made for Prusa, Prusa, Czech Republic) with 0.15 mm  
150 layer height and 10% infill.

151 The software Blender (3.6 LTS, [www.blender.org](http://www.blender.org)) was used to plan osteotomies by VSP (Figure 3A). Based  
152 on the osteotomy planes, the conventional cutting guide for the control group was designed using the displace,  
153 solidify and boolean modifiers in Blender. Afterwards, the designed cutting guide was 3D-printed with the same  
154 printer model using PETG filament (Prusament, Prusa Research a.s., Prague, Czech Republic) (Figure 4D).

155 The intervention arm consisted of the robot-assisted cutting method (Figure 4A, C). For this method, a saw  
156 guide was first designed in Blender and then fabricated out of Aluminum 7075. The height of the slot was 0.8mm  
157 and the depth of the guide was 2cm. The saw guide was mounted on a robotic arm, a Franka Emika Panda (Franka,  
158 Munich, Germany).

159 The Franka Emika Panda was selected due to its seven degrees of freedom, which facilitate a high degree of  
160 arm agility. Moreover, the robot exhibits high accuracy, with a position repeatability of  $\pm 0.1$  mm. Furthermore,

161 the robot is programmable via a multitude of interfaces, including three Franka interfaces, in addition to C++,  
162 ROS, ROS2, MATLAB, and Simulink. This makes the robot highly versatile, enabling its application in other  
163 specialties. One of the most decisive factors, however, was the robot's compactness and the internal collision  
164 detection mechanism, with a collision detection time of <2ms, which increases patient and user safety [43].

165 The robot was programmed to place the guide on the surface of the hip model and allowed the participant to  
166 perform the osteotomy restricted by the saw guide. The phantom models were mounted on an aluminum frame,  
167 which was maintained in a fixed position throughout the duration of the study. To program the right cutting  
168 positions, we previously 3D-printed a positioning reference based on the planned CAD/CAM prototype. An  
169 additional intermediate position was programmed from which the robot moved to the next osteotomy position.  
170 Thereby, the participants still perform the osteotomy themselves and maintain control of the procedure, while the  
171 robot positions a saw guide and provides haptic assistance of the osteotomies according to the preprogrammed  
172 plan. The specific osteotomy positions for the robotic arm were programmed with ROS (ROS Noetic, Open Source  
173 Robotics Foundation) and C++.

174 Unlike the 3D-printed cutting guide, the shape of the saw guide placed by the robot did not visualize the shape  
175 of the flap. Therefore, we implemented a static holographic visualization of the robot-assisted cutting method, to  
176 illustrate the dimensions of the flap and the sequence of osteotomies. The iliac crest, osteotomy sequence and saw  
177 guide were displayed in the Looking Glass 7.9" (Looking Glass Factory Inc., New York, USA) using the Blender  
178 add-on for Looking Glass (Alice/LG, version 2.2).

### 179 *Trial*

180 To avoid bias due to a learning effect from previous osseous flap raising with 3D-printed cutting guides,  
181 participants with self-performed raising of bone flaps with 3D-printed cutting guides in the past were excluded.  
182 Furthermore, left-handed participants were excluded because an adaptive positioning of the robot on the right side  
183 was not possible for this study.

184 Each participant had to fill out written informed consent and an entrance questionnaire before starting the trial.  
185 According to a random allocation rule (planned and performed by B.P.) with a balanced block size of 20 for each  
186 method, they started either with the 3D-printed cutting guide or robot-assisted cutting method. Before starting the  
187 first method, two test planes were sawed on a test block by each participant to get used to the saw (C2 shaver  
188 system, Eberle GmbH, Wurmberg, Germany) and the material of the phantom models. After each method, the  
189 participants filled out the NASA-TLX score [39]. The duration was measured from the first osteotomy plane to  
190 the completion of the last plane. Finally, a closing questionnaire with Likert and open-ended questions was filled  
191 out.

## 192 *Evaluation*

193 Due to the variability of the raised flaps, scanning in a reproducible manner would be difficult. Instead, we  
194 scanned the os ilium models in a standardized manner on a 3D-printed specific mount using a 3D scanner T710  
195 (Medit, Seoul, South Korea) at a resolution of 4  $\mu\text{m}$  (Figure 3B).

196 The evaluation was performed in a blinded manner by two independent investigators (P.B. and Y.L.). Blinding  
197 was performed by an independent person (B.P.). The file names were given random alphanumeric names and all  
198 metadata (date of creation, etc.) of the file was removed, as well as any possible identifying content (e.g., labels  
199 on the files). Both investigators used Blender to generate planes based on four points, consisting of two triangles  
200 for every osteotomy plane (Figure 3C). Each plane was then exported separately as an STL-file. Outliers (planes  
201 with a difference of  $0.5^\circ$  or more between the two investigators) were reviewed (B.P.) and were corrected if there  
202 were any obvious irregularities (P.B. or Y.L.).

203 Despite the scanning mount for reproducible scans, during the evaluation of all scanned 80 models, we noted  
204 that not all models were perfectly aligned with each other. Therefore, the scans were additionally registered using  
205 iterative closest point (ICP) point-to-plane point clouds with the Open3D Python library. Both the originally  
206 planned model and the scanned model were registered based on 50,000 points. The registration was run with the  
207 following termination parameters: `relative_fitness`,  $1.0 \times 10^{-6}$ ; `relative_rmse`,  $1.0 \times 10^{-6}$ ; the maximum number of  
208 iterations, 100,000. The corresponding transformation matrices (4x4 matrix) were then used to align the created  
209 evaluated cutting planes and scanned models to the planned cutting planes.

210 To evaluate the angular osteotomy plane deviation, the normal vector of the plane was used. Because four  
211 points do not necessarily lead to an even plane, the average normal vector of the two triangles of the plane was  
212 calculated. Based on the average normal vector and after applying the registration transformation, the angle  
213 difference between planned and executed osteotomy planes was measured in degrees. The preoperatively planned  
214 angles were set as a reference to  $0^\circ$ . All planes were then automatically calculated using the Trimesh library in  
215 Python.

216 To extract the raised flap, we used the boolean operator with a Python script in Blender according to the reverse  
217 engineering principle. Based on the average normal vector, planes were calculated at the same position as the  
218 registered osteotomy planes. The exact flap was generated from these planar planes by applying a boolean operator  
219 on the complete os ilium model, considering the cutting width of 0.7mm (according to the manufacturer). The  
220 volumes of the flaps were calculated in ml. For HD and AVD, the corresponding osteotomy planes from the  
221 generated models were used.

222 All calculations were made using the with the Open3D and Trimesh library in Python.

## 223 *Sample Size Calculation and Statistical Analysis*

224 The sample size calculation and statistical analysis were performed in R (version 4.3.0, [www.r-project.org](http://www.r-project.org)).  
225 For this purpose, a pretrial was conducted with two medical students and two surgeons, who were randomly  
226 assigned to raise DCIA flaps with both methods. Based on the eight harvested flaps, 24 planes were evaluated and  
227 used for a simulation-based power analysis for a linear mixed-effects model (LMM) with lmerTest Package [44].  
228 The conventional method had an angular deviation of  $4.1 \pm 2.1^\circ$  (mean $\pm$ sd) and the robot-assisted method  $2.1 \pm 0.6^\circ$ .  
229 The significance level was set at  $\alpha=0.05$  and the power at 95% resulting in a sample size of 34 subjects. Four more  
230 subjects were added to the study to account for dropouts and non-usable data, giving a total of 38 subjects.

231 The osteotomy angle deviations, the HD and the AVD were also analyzed by LMMs. The dependent variable  
232 was the osteotomy angle, while the method (robot-assisted vs 3D-printed) and the orientation of the osteotomy  
233 (horizontal vs vertical) were considered independent variables and fixed effects. Mixed effects were the subjects  
234 themselves and the osteotomy plane (1-4). The NASA-TLX score was analyzed using a *t*-test, while the duration  
235 was analyzed with a Wilcoxon test due to non-normally distributed values. Normal distribution was previously  
236 tested using the Shapiro-Wilk test. A p-value  $<0.05$  was considered statistically significant.

## 237 **Results**

238 Overall, 40 participants took part in our study. 16 (40.0%) were female and 24 (60.0%) were male. The mean  
239 age was 27.1 years (sd 5.3). 17 (42.5%) surgeons and 23 (57.5%) students were included. 16 (40.0%) of the  
240 participants were medical students, 7 (17.5%) dental students, 13 residents (32.5%), and 4 specialists (10.0%). The  
241 mean study progress was  $4.3 \pm 0.8$  years, while the average years practiced were  $5.8 \pm 4.5$ . 38 participants had no  
242 previous experience with 3D-printed cutting guides. Two participants were recognized after participation as having  
243 some experience with 3D-printed cutting guides. To rule out any possible influence, the analyses were also carried  
244 out without them and did not lead to any change in the results of the p-values (Table 2).

245 All in all, 80 models with four osteotomy planes each were evaluated, giving a total of 320 planes. The resulting  
246 root mean square error (RMSE) for ICP registration was  $0.28 \pm 0.05$  mm. For the primary endpoint, the robotic-  
247 assisted method was with an angular deviation of  $1.9 \pm 1.1^\circ$  significantly more accurate, than the 3D-printed cutting  
248 guide with an angular deviation of  $4.7 \pm 2.9^\circ$  (LMM,  $p < 0.001$ ). Overall, the angular deviation for the robot-assisted  
249 cutting method was  $2.8^\circ$  more accurate (Figure 5C). Regardless of the method, the vertical osteotomies showed a  
250 lower accuracy of  $0.6^\circ$  (LMM,  $p=0.008$ ). A visualization of the osteotomy planes for both methods is shown in  
251 Figure 5A, B.



252 The HD was  $1.5\pm 0.6$  mm for the robot-assisted cutting method and  $2.0\pm 0.9$  mm for the 3D-printed cutting  
253 guide (LMM,  $p<0.001$ ) (Figure 5D). The AVD was  $0.8\pm 0.5$  mm for the robot-assisted cutting method and  $0.8\pm 0.4$   
254 mm for the 3D-printed cutting guide (LMM,  $p=0.320$ ) (Figure 5E). The average volume was 17.32 ml for all raised  
255 DCIA flaps and 17.41 ml for the planned DCIA flap.

256 Subjective workloads were rated significantly lower for the robot-assisted cutting method with an overall score  
257 of  $38.3\pm 16.5$  compared to the conventional method with a total result of  $47.7\pm 17.5$  ( $t$ -test,  $p=0.015$ ) (Figure 6A).  
258 The duration was shorter with the 3D-printed cutting guide with  $02:07\pm 00:49$  min:s compared to  $03:14\pm 00:04$   
259 min:s for the robot-assisted cutting method (Wilcoxon signed-rank test,  $p<0.001$ ) (Figure 6B).

260 According to the Likert questions (Table 3), the 3D-printed cutting guide was rated to be more intuitive  
261 (conventional: 3.4, robot-assisted 3.3,  $p=0.687$ ) and practical (conventional: 3.4, robot-assisted: 2.8,  $p=0.008$ )  
262 compared to the robot-assisted method. Both methods were rated equally to be recommended (3.2 for both  
263 methods,  $p=0.975$ ). For the remaining Likert questions, the robot-assisted cutting method was rated superior,  
264 especially ratings regarding the accuracy (conventional = 3.1, robot-assisted = 3.5,  $p=0.033$ ), safety (conventional  
265 = 2.7, robot-assisted = 3.4,  $p=0.001$ ) and haptic support (conventional = 2.8, robot-assisted = 3.6,  $p<0.001$ ) were  
266 significantly better (Figure 6C, D).

267 The open questions revealed the following: Many participants mentioned the good haptic guidance and  
268 accuracy of the robot-assisted cutting method, especially for beginners. However, some participants also  
269 mentioned a limited view of the bone due to the mounted saw guide as a negative aspect. Regarding the 3D-printed  
270 cutting guide, lower haptic guidance and the time-consuming fixation with screws were criticized. Positive aspects  
271 were easy handling and the visualization of the transplant by the shape of the cutting guide (Table 4).

272 In total, 21 participants preferred the robot-assisted cutting method, and 19 participants preferred the 3D-  
273 printed cutting guides.

## 274 Discussion

275 To our knowledge, this is the first RCT to compare a collaborative robot-assisted cutting method with 3D-  
276 printed cutting guides and to demonstrate its feasibility for raising DCIA flaps. The main findings were a higher  
277 angular accuracy and a reduction of the subjective workload of the robot-assisted cutting method compared to 3D-  
278 printed cutting guides. With less than four minutes, both methods were sufficiently fast. The HD was also lower  
279 for the robot-assisted method, while the AVD showed no significant difference.

280 On average, the robot-assisted cutting method ( $1.9\pm 1.1^\circ$ ) was  $2.8^\circ$  more accurate than the conventional 3D-  
281 printed cutting guides ( $4.7\pm 2.9^\circ$ ). These findings are comparable to the results from the studies conducted by Hu

282 et al. [7] and de Boutray et al. [15] with angular deviations of  $1.3\pm 0.7^\circ$  respectively  $1.9\pm 1.2^\circ$ . Common numbers  
283 for angular deviations for 3D-printed cutting guides are  $4.1\pm 2.3^\circ$ ,  $7.0\pm 4.7^\circ$ ,  $8.5\pm 5.4^\circ$  and  $6.9\pm 4.0^\circ$  (Table 1). The  
284 results show that the preoperative plan (CAD/CAM) is accurately transferred to the surgical site by the robot-  
285 assisted cutting method.

286 Nevertheless, the previously described robot-assisted methods for FFF raising had a purely exploratory design  
287 and only a few participants were included [7,15]. Consequently, the inter-rater variance was not considered and  
288 not all, but many other studies had no control group [7,14–16,20]. In contrast [18], our study is a confirmatory  
289 study, including study registration with sample size calculation including a large number of participants and  
290 comparison to the gold standard (3D-printed cutting guides) as a control. This is however necessary to evaluate  
291 the effectiveness of the method and to attribute causality [45].

292 Interestingly, there was no difference in translational error (for AVD) between the two methods. This suggests  
293 that there was mainly a rotational error of the osteotomy depending on the method (Figure 5F). The AVD results  
294 in many very low values (Figure 5G) due to the crossing of the performed osteotomy with the planned osteotomy.  
295 A parallel translation would have resulted in significantly higher AVD values. The AVD values of this study are  
296 comparable to the translational error of 1.2 mm found in the study conducted by Zhu et al [26].

297 The angular deviation should be considered in the context of the lack of a standardized design for 3D-printed  
298 cutting guides. In this regard, slot and flange designs are the common ways to guide the surgeon during osteotomy  
299 [46,47]. Slotted guides have a smaller range of motion (depending on their design) because they constrain the saw  
300 to more dimensions, which may explain the observed differences between the robot-assisted and 3D-printed guide  
301 methods. However, in the study by Pietruski et al, the 3D-printed cutting guide with a slot design for FFF raising  
302 showed an angular deviation of  $4.1\pm 2.3^\circ$  [19], which is comparable to our flange-designed 3D-printed cutting  
303 guides. In addition to the choice of slots or flanges, the length of blade guidance is also critical. Usually, an  
304 increased depth of the guide leads to higher guidance. While the guide for the robot-assisted cutting method had a  
305 depth of 2 cm, the depth of the flange of the 3D-printed cutting guide was only 5mm.

306 It is important to note that as DCIA flaps require connected osteotomies to raise the flap, a total slot design for  
307 all osteotomies is not an option, while the slots themselves already lead to a larger, more invasive cutting guide.  
308 Therefore, many studies used a flange design for 3D-printed cutting guides to raise DCIA flaps in real clinical  
309 cases [48–51]. Some studies partially designed a guide with slots, however only the vertical osteotomies were  
310 performed through the slots [47,52] (Table 1). The accuracy of cutting guides is further affected by the position of  
311 the guide on the bone and by the fixation with screws which could explain the lower accuracy of cutting guides  
312 compared to the robot-assisted method.

313 When evaluating the clinical relevance of the accuracies of osteotomies and surgical cutting guides in our study  
314 and the literature, the reproducibility and comparability of those are limited. Besides different cutting guide  
315 designs, there are also different methods to evaluate the accuracy of CAS. Landmarks, superimposition and  
316 resection planes are possible ways for evaluation [53], while the image quality and the segmentation itself also  
317 influence the subsequent steps of the CAS [54].

318 Besides these technical considerations, the primary goal of maxillofacial reconstruction is aesthetic and  
319 functional restoration of the jaw. One of the most important functional outcomes is the dental occlusion, as patients  
320 are sensitive to even the smallest changes [55]. In addition to changes in dental occlusion, mandibular deviation  
321 can be caused by changes in the position of the condyles [56]. Unlike the upper jaw, the mandible has many  
322 muscles attached to it, which further affect the position of the jaw through muscle tone [57]. Furthermore, dental  
323 rehabilitation is highly dependent on an accurate reconstruction of the jaw [58]. However, no numbers are available  
324 to quantify a desired outcome in terms of angular or linear deviation of the reconstructed jaw [59].

325 The outcome of the reconstruction depends on several factors, including the translational and rotational errors  
326 of the osteotomies of both the jaw resection, and the raised bone flap. Both angles accumulate to the overall margin  
327 of error, not only in translation but also in rotation of the mandible [60], which will cause corresponding  
328 inaccuracies in the position of the condyles in the temporomandibular joint, the contour of the jaw, or the dental  
329 occlusions (Figure 7 A, B). Figures 7C and D illustrate the potential error caused by osteotomy angle deviations  
330 of 2° and 5° of a raised flap, showing an increased distance between the two condyles and therefore a change in  
331 condyle position in the articular fossa. This suggests that a 2.8° angular deviation of the osteotomy (planned vs.  
332 performed) may have a major impact, with accurate reconstruction being critical to multiple rehabilitation factors  
333 of the patient, whereas translation errors of approximately 1 mm reported by others and by us seem to contribute  
334 less. Current angular accuracies of mandibular reconstruction with classical CAS range from 0.9°-17.5° and linear  
335 deviations range from 0-12.5mm using condylar measurements, indicating that there is still an issue here [53].

336 Nevertheless, participants reported that the 3D-printed cutting guide was more practical and intuitive. 3D-  
337 printed cutting guides have been used for decades now and were tested in multiple scenarios [61]. They were  
338 originally introduced by Radermacher et al. at the Helmholtz Institute for Biomedical Engineering at RWTH  
339 Aachen University in the early 1990s [62,63]. Their design is easy to understand, as it shows the shape of the flap  
340 to be harvested.

341 The limited view of the osteotomy caused by the guide mounted onto the robotic arm could easily be improved  
342 by increasing the distance between the bone and the cutting guide. Attaching the saw directly to the robotic arm  
343 like the MAKO robot [32] might further improve depth control and protect the abdomen. With trials in a more

344 clinical environment, the usability of the robot-assisted cutting guides could be improved further regarding the  
345 handling and placement in the operating room.

346 However, surgeons are already relieved from physically exhausting tasks and can focus on the precise  
347 execution of flap harvesting [64], which is also consistent with the reported subjective workload values in our  
348 study. Combined with optical tracking, the robot-assisted cutting method would not require patient specific  
349 manufacturing and could be adapted during surgery. This would increase the intraoperative flexibility and  
350 overcome the disadvantages of conventional cutting guides, such as high production costs and longer preoperative  
351 lead times [15]. Furthermore, invasive fixation of the guide with screws would no longer be necessary.

352 Collaborative robotic systems either place a physical guide and/or use VSP to transfer the osteotomy planes to  
353 the robot. Thereby the osteotomy angle is pre-set by the robotic arm [15]. More inexperienced surgeons could  
354 profit from the limited degree of freedom for the sawing blade provided by the saw guide, as there is a lower risk  
355 of accidentally slipping away with the saw.

356 In addition to that, the robot-assisted method also provides a physical end stop, that can protect the pedicle and  
357 other abdominal soft tissue behind the iliac crest from being harmed. This is particularly important for raising  
358 DCIA flaps, as injuries of the abdominal cavity can lead to potentially lethal consequences [35].

359 Compared to an autonomous system performing the osteotomy, a collaborative approach has the advantage  
360 that the surgeon is always in control, which could lead to better acceptance by both patients and surgeons and  
361 facilitate translation from a regulatory perspective. DCIA flap raising is much more complex than FFF raising  
362 because it requires the osteotomy of a combination of linked planes. This implies that the individual osteotomies  
363 need to be coordinated not only in terms of angular deviation but also regarding length and distance.

364 Robot-assisted flap raising in OMFS still requires further investigation and interdisciplinary research including  
365 surgeons, technicians, and industry, to improve the application of robot-assisted cutting methods during a realistic  
366 procedure. Cadaver studies, haptic guidance and real-time navigation could create new findings for reconstructive  
367 surgeries. In complex situations, osteotomies may be performed using robot-assisted Er:YAG laser [65]. In  
368 combination with planning algorithms or Artificial Intelligence, the transplant could be planned and programmed  
369 into the robot [18].

370 Nevertheless, there are some limitations of our study. First, we only assessed both methods in a static setting.  
371 During a real surgical procedure, optical tracking combined would be necessary [15]. Dynamic motion control  
372 could increase the stiffness of the robotic arm and thereby reduce errors caused by the movement of the robot.

373 Furthermore, the lack of clinical results was also caused by using phantom models in an artificial setting,  
374 without surrounding structures such as soft tissue and without having to consider the limited space in the surgical

375 field. However, the use of the same phantom model, with the same transplant planning in an identical setting  
376 allowed a standardized study for reliable results regarding inference statistics.

377 Since the study aimed to assess the general feasibility of the system for raising DCIA flaps, a next step to  
378 advance clinical translation should be to investigate the system in a dynamic setting such as cadavers. As in the  
379 operating room, the entire body will be present, and optical tracking with navigation systems will be performed.  
380 This would be a more realistic scenario, which first simulates how the robotic arm acts in the surgical situs and  
381 second investigates the feasibility of the system regarding limited space in the operating room.

382 In experimental and static settings, the haptic robot-assisted method is a good alternative to 3D-printed cutting  
383 guides for raising DCIA flaps. The increased angular accuracy obtained with the robot-assisted method for DCIA  
384 harvesting is comparable to the current outcomes of preclinical studies on robotic methods used for FFF harvesting.  
385 Furthermore, robotic approaches can prevent the need for invasive fixation of a 3D-printed cutting guide and allow  
386 for intraoperative planning and flexible planning adaptation. The flange design of the 3D-printed gutting guide  
387 resulted in a higher rotational error, but only in a small translational error, which was comparable for both methods.  
388 To verify these outcomes, the next step will be to test the results in a dynamic environment with a moving phantom  
389 or a cadaver.

## 390 References

- 391 1. Truscott, A., Zamani, R. & Akrami, M. Comparing the use of conventional and three-dimensional printing  
392 (3DP) in mandibular reconstruction. *Biomedical engineering online* **21**, 18 (2022).
- 393 2. Okoturo, E. Non-vascularised iliac crest bone graft for immediate reconstruction of lateral mandibular  
394 defect. *Oral and maxillofacial surgery* **20**, 425–429 (2016).
- 395 3. Batstone, M. D. Reconstruction of major defects of the jaws. *Australian dental journal* **63 Suppl 1**, S108-  
396 S113 (2018).
- 397 4. Kademani, D. & Keller, E. Iliac crest grafting for mandibular reconstruction. *Atlas of the oral and*  
398 *maxillofacial surgery clinics of North America* **14**, 161–170 (2006).
- 399 5. Braak, T. P. ter *et al.* A surgical navigated cutting guide for mandibular osteotomies: accuracy and  
400 reproducibility of an image-guided mandibular osteotomy. *International journal of computer assisted*  
401 *radiology and surgery* **15**, 1719–1725 (2020).
- 402 6. Chen, X. *et al.* Computer-aided design and manufacturing of surgical templates and their clinical  
403 applications: a review. *Expert review of medical devices* **13**, 853–864 (2016).
- 404 7. Hu, J. *et al.* A collaborative robotic platform for sensor-aware fibula osteotomies in mandibular  
405 reconstruction surgery. *Computers in biology and medicine* **162**, 107040 (2023).
- 406 8. Peel, S., Bhatia, S., Eggbeer, D., Morris, D. S. & Hayhurst, C. Evolution of design considerations in  
407 complex craniofacial reconstruction using patient-specific implants. *Proceedings of the Institution of*  
408 *Mechanical Engineers. Part H, Journal of engineering in medicine* **231**, 509–524 (2017).
- 409 9. Ramírez, E. A. *et al.* Positioning assessment of surgical cutting guides for osteosarcoma resection utilizing  
410 3D scanning technology. *Procedia CIRP* **89**, 176–181 (2020).
- 411 10. Schmidtmann, U. Ergebnisse der elastischen Plattenosteosynthese (1997).
- 412 11. Juergens, P. *et al.* Navigation-guided harvesting of autologous iliac crest graft for mandibular  
413 reconstruction. *Journal of oral and maxillofacial surgery : official journal of the American Association of*  
414 *Oral and Maxillofacial Surgeons* **69**, 2915–2923 (2011).
- 415 12. Pietruski, P. *et al.* Navigation-guided fibula free flap for mandibular reconstruction: A proof of concept  
416 study. *Journal of plastic, reconstructive & aesthetic surgery : JPRAS* **72**, 572–580 (2019).
- 417 13. Benmahdjoub, M., van Walsum, T., van Twisk, P. & Wolvius, E. B. Augmented reality in  
418 craniomaxillofacial surgery: added value and proposed recommendations through a systematic review of the  
419 literature. *International journal of oral and maxillofacial surgery* **50**, 969–978 (2021).
- 420 14. Chao, A. H. *et al.* Pre-programmed robotic osteotomies for fibula free flap mandible reconstruction: A  
421 preclinical investigation. *Microsurgery* **36**, 246–249 (2016).
- 422 15. Boutray, M. de *et al.* Robot-guided osteotomy in fibula free flap mandibular reconstruction: a preclinical  
423 study. *International journal of oral and maxillofacial surgery*; 10.1016/j.ijom.2023.07.010 (2023).
- 424 16. Shao, L. *et al.* Robot-assisted augmented reality surgical navigation based on optical tracking for  
425 mandibular reconstruction surgery. *Medical physics*; 10.1002/mp.16598 (2023).
- 426 17. Zhao, R. *et al.* Augmented reality guided in reconstruction of mandibular defect with fibular flap: A cadaver  
427 study. *Journal of stomatology, oral and maxillofacial surgery* **124**, 101318 (2023).
- 428 18. Guo, Y. *et al.* Design and implementation of a surgical planning system for robotic assisted mandible  
429 reconstruction with fibula free flap. *International journal of computer assisted radiology and surgery* **17**,  
430 2291–2303 (2022).
- 431 19. Pietruski, P. *et al.* Supporting fibula free flap harvest with augmented reality: A proof-of-concept study. *The*  
432 *Laryngoscope* **130**, 1173–1179 (2020).
- 433 20. Meng, F. H. *et al.* Feasibility of the application of mixed reality in mandible reconstruction with fibula flap:  
434 A cadaveric specimen study. *Journal of stomatology, oral and maxillofacial surgery* **122**, e45-e49 (2021).
- 435 21. Winnand, P. *et al.* Navigation of iliac crest graft harvest using markerless augmented reality and cutting  
436 guide technology: A pilot study. *The international journal of medical robotics + computer assisted surgery*  
437 *: MRCAS* **18**, e2318 (2022).
- 438 22. Modabber, A. *et al.* Comparison of augmented reality and cutting guide technology in assisted harvesting of  
439 iliac crest grafts - A cadaver study. *Annals of anatomy = Anatomischer Anzeiger : official organ of the*  
440 *Anatomische Gesellschaft* **239**, 151834 (2022).
- 441 23. Liu, S. *et al.* Mandibular resection and defect reconstruction guided by a contour registration-based  
442 augmented reality system: A preclinical trial. *Journal of cranio-maxillo-facial surgery : official publication*  
443 *of the European Association for Cranio-Maxillo-Facial Surgery* **51**, 360–368 (2023).
- 444 24. Kong, X., Duan, X. & Wang, Y. An integrated system for planning, navigation and robotic assistance for  
445 mandible reconstruction surgery. *Intel Serv Robotics* **9**, 113–121 (2016).

- 446 25. Battaglia, S. *et al.* Combination of CAD/CAM and Augmented Reality in Free Fibula Bone Harvest. *Plastic*  
447 *and reconstructive surgery. Global open* **7**, e2510 (2019).
- 448 26. Zhu, J.-H. *et al.* Prospects of Robot-Assisted Mandibular Reconstruction with Fibula Flap: Comparison  
449 with a Computer-Assisted Navigation System and Freehand Technique. *Journal of reconstructive*  
450 *microsurgery* **32**, 661–669 (2016).
- 451 27. O’Sullivan, S. *et al.* Legal, regulatory, and ethical frameworks for development of standards in artificial  
452 intelligence (AI) and autonomous robotic surgery. *The international journal of medical robotics +*  
453 *computer assisted surgery : MRCAS* **15**, e1968 (2019).
- 454 28. Yang, G.-Z. *et al.* Medical robotics-Regulatory, ethical, and legal considerations for increasing levels of  
455 autonomy. *Science robotics* **2** (2017).
- 456 29. Freudlsperger, C. *et al.* Knöcherne Rekonstruktionen des Ober- und Unterkiefers – Grundprinzipien,  
457 virtuelle Planung und intraoperative Umsetzung. *MKG-Chirurg* **14**, 199–211 (2021).
- 458 30. Moustris, G. P., Hiridis, S. C., Deliparaschos, K. M. & Konstantinidis, K. M. Evolution of autonomous and  
459 semi-autonomous robotic surgical systems: a review of the literature. *The international journal of medical*  
460 *robotics + computer assisted surgery : MRCAS* **7**, 375–392 (2011).
- 461 31. Batailler, C., Hannouche, D., Benazzo, F. & Parratte, S. Concepts and techniques of a new robotically  
462 assisted technique for total knee arthroplasty: the ROSA knee system. *Archives of orthopaedic and trauma*  
463 *surgery* **141**, 2049–2058 (2021).
- 464 32. Roche, M. The MAKO robotic-arm knee arthroplasty system. *Archives of orthopaedic and trauma surgery*  
465 **141**, 2043–2047 (2021).
- 466 33. Li, T., Badre, A., Alambeigi, F. & Tavakoli, M. Robotic Systems and Navigation Techniques in  
467 Orthopedics: A Historical Review. *Applied Sciences* **13**, 9768 (2023).
- 468 34. Klodmann, J. *et al.* Robotische Assistenzsysteme für die Chirurgie : Aktuelle Entwicklungen und  
469 Schwerpunkte der Forschung. *Der Chirurg; Zeitschrift für alle Gebiete der operativen Medizin* **91**, 533–  
470 543 (2020).
- 471 35. Douma, M. & Brindley, P. G. Abdominal aortic and iliac artery compression following penetrating trauma:  
472 a study of feasibility. *Prehospital and disaster medicine* **29**, 299–302 (2014).
- 473 36. Hu, Y. *et al.* Blood loss of total knee arthroplasty in osteoarthritis: an analysis of influential factors. *Journal*  
474 *of orthopaedic surgery and research* **13**, 325 (2018).
- 475 37. Wilkman, T., Husso, A. & Lassus, P. Clinical Comparison of Scapular, Fibular, and Iliac Crest Osseal Free  
476 Flaps in Maxillofacial Reconstructions. *Scandinavian journal of surgery : SJS : official organ for the*  
477 *Finnish Surgical Society and the Scandinavian Surgical Society* **108**, 76–82 (2019).
- 478 38. Hart, S. G. & Staveland, L. E. Development of NASA-TLX (Task Load Index): Results of Empirical and  
479 Theoretical Research **52**, 139–183 (1988).
- 480 39. Flägel, K., Galler, B., Steinhäuser, J. & Götz, K. Der „National Aeronautics and Space Administration-Task  
481 Load Index“ (NASA-TLX) – ein Instrument zur Erfassung der Arbeitsbelastung in der hausärztlichen  
482 Sprechstunde: Bestimmung der psychometrischen Eigenschaften. *Zeitschrift für Evidenz, Fortbildung und*  
483 *Qualität im Gesundheitswesen* **147-148**, 90–96 (2019).
- 484 40. Schulz, K. F., Altman, D. G. & Moher, D. CONSORT 2010 statement: updated guidelines for reporting  
485 parallel group randomised trials. *BMJ (Clinical research ed.)* **340**, e332 (2010).
- 486 41. Dwan, K., Li, T., Altman, D. G. & Elbourne, D. CONSORT 2010 statement: extension to randomised  
487 crossover trials. *BMJ (Clinical research ed.)* **366**, l4378 (2019).
- 488 42. Ulbrich, M. *et al.* Advantages of a Training Course for Surgical Planning in Virtual Reality for Oral and  
489 Maxillofacial Surgery: Crossover Study. *JMIR serious games* **11**, e40541 (2023).
- 490 43. Petrea, R. A. B., Bertoni, M. & Oboe, R. (eds.). *On the Interaction Force Sensing Accuracy Of Franka*  
491 *Emika Panda Robot* (IEEE, 2021).
- 492 44. Kuznetsova, A., Brockhoff, P. B. & Christensen, R. H. B. lmerTest Package: Tests in Linear Mixed Effects  
493 Models. *J. Stat. Soft.* **82** (2017).
- 494 45. D’Agostino, R. B. & Kwan, H. Measuring effectiveness. What to expect without a randomized control  
495 group. *Medical care* **33**, AS95-105 (1995).
- 496 46. Brouwer de Koning, S. G. *et al.* Evaluating the accuracy of resection planes in mandibular surgery using a  
497 preoperative, intraoperative, and postoperative approach. *International journal of oral and maxillofacial*  
498 *surgery* **50**, 287–293 (2021).
- 499 47. Busch, A. & Rustemeyer, J. Virtual Planning and Application of Computer-aided Designed/ Computer-  
500 aided Manufactured Technique for Reconstruction of Mandible Defects with Iliac Crest Flaps. *J Otol*  
501 *Rhinol* **04** (2015).

- 502 48. Zhu, W.-Y., Choi, W. S. & Su, Y.-X. Three-dimensional Printing Technology for Deep Circumflex Iliac  
503 Artery Flap: From Recipient to Donor Sites. *Plastic and reconstructive surgery. Global open* **9**, e3618  
504 (2021).
- 505 49. Brandenburg, L. S. *et al.* Donor site morbidity after computer assisted surgical reconstruction of the  
506 mandible using deep circumflex iliac artery grafts: a cross sectional study. *BMC surgery* **23**, 4 (2023).
- 507 50. Sasaki, R. & Rasse, M. Mandibular Reconstruction Using ProPlan CMF: A Review. *Craniomaxillofacial*  
508 *Trauma & Reconstruction Open* **1**, s-0037-1606835 (2017).
- 509 51. Xu, G. *et al.* Mandibular Reconstruction With the Contralateral Vascularized Iliac Flap Using Individual  
510 Design: Iliac Crest Used to Reconstruct the Ramus and the Anterior Border of the Iliac Wing Used to  
511 Reconstruct the Inferior Border: A Case Report. *Frontiers in surgery* **9**, 924241 (2022).
- 512 52. Chandra, S. R. & Pillai, V. in *Oral and Maxillofacial Surgery for the Clinician*, edited by K. Bonanthona, E.  
513 Panneerselvam, S. Manuel, V. V. Kumar & A. Rai (Springer Nature Singapore, 2021), Vol. 1, pp. 1997–  
514 2008.
- 515 53. van Baar, G. J. C., Forouzanfar, T., Liberton, N. P. T. J., Winters, H. A. H. & Leusink, F. K. J. Accuracy of  
516 computer-assisted surgery in mandibular reconstruction: A systematic review. *Oral oncology* **84**, 52–60  
517 (2018).
- 518 54. Gruber, L. J. *et al.* Accuracy and Precision of Mandible Segmentation and Its Clinical Implications: Virtual  
519 Reality, Desktop Screen and Artificial Intelligence. *Expert Systems with Applications* **239**, 122275 (2024).
- 520 55. Seikaly, H. *et al.* The Alberta Reconstructive Technique: An Occlusion-Driven and Digitally Based Jaw  
521 Reconstruction. *The Laryngoscope* **129 Suppl 4**, S1-S14 (2019).
- 522 56. Onodera, K. *et al.* Towards Optimum Mandibular Reconstruction for Dental Occlusal Rehabilitation: From  
523 Preoperative Virtual Surgery to Autogenous Particulate Cancellous Bone and Marrow Graft with Custom-  
524 Made Titanium Mesh-A Retrospective Study. *Journal of clinical medicine* **12** (2023).
- 525 57. Chen, H. *et al.* Changes in condylar position and morphology after mandibular reconstruction by  
526 vascularized fibular free flap with condyle preservation. *Clinical oral investigations* **27**, 6097–6109 (2023).
- 527 58. Jacobsen, H.-C., Wahnschaff, F., Trenkle, T., Sieg, P. & Hakim, S. G. Oral rehabilitation with dental  
528 implants and quality of life following mandibular reconstruction with free fibular flap. *Clinical oral*  
529 *investigations* **20**, 187–192 (2016).
- 530 59. Wijbenga, J. G., Schepers, R. H., Werker, P. M. N., Witjes, M. J. H. & Dijkstra, P. U. A systematic review  
531 of functional outcome and quality of life following reconstruction of maxillofacial defects using  
532 vascularized free fibula flaps and dental rehabilitation reveals poor data quality. *Journal of plastic,*  
533 *reconstructive & aesthetic surgery : JPRAS* **69**, 1024–1036 (2016).
- 534 60. Steybe, D. *et al.* Analysis of the accuracy of computer-assisted DCIA flap mandibular reconstruction  
535 applying a novel approach based on geometric morphometrics. *Head & neck* **44**, 2810–2819 (2022).
- 536 61. Khorsandi, D. *et al.* 3D and 4D printing in dentistry and maxillofacial surgery: Printing techniques,  
537 materials, and applications. *Acta biomaterialia* **122**, 26–49 (2021).
- 538 62. Staudte, H.-W., Rau, G. & Radermacher, K. in *Proceedings of the 15<sup>th</sup> International Conference on IEEE*  
539 *Engineering in Medicine and Biology Society [front matter]* (IEEE, 1993), pp. 946–947.
- 540 63. Radermacher, K. *et al.* Computer assisted orthopaedic surgery with image based individual templates.  
541 *Clinical orthopaedics and related research*, 28–38 (1998).
- 542 64. Liu, H.-H., Li, L.-J., Shi, B., Xu, C.-W. & Luo, E. Robotic surgical systems in maxillofacial surgery: a  
543 review. *International journal of oral science* **9**, 63–73 (2017).
- 544 65. Augello, M. *et al.* Performing partial mandibular resection, fibula free flap reconstruction and midfacial  
545 osteotomies with a cold ablation and robot-guided Er:YAG laser osteotome (CARLO®) - A study on  
546 applicability and effectiveness in human cadavers. *Journal of cranio-maxillo-facial surgery : official*  
547 *publication of the European Association for Cranio-Maxillo-Facial Surgery* **46**, 1850–1855 (2018).

549



550 **Declaration**

551 **Acknowledgments:** We would like to thank the Institute of Anatomy of the RWTH Aachen University and Mr.  
552 Heiko Löffler from the Eberle company for providing us the oscillating saws and for the technical support during  
553 the study. We would like to thank Mr. Adalbert Mazur from the Scientific Workshop of the Medical Faculty of  
554 RWTH Aachen University for producing the sawing guide.

555  
556 **Author Contributions:** Conceptualization, B.P., P.B., R.R. and F.H.; methodology, P.B., B.P., S.D., M.F. and  
557 J.E.; software, P.B., B.P. and R.R.; validation, P.B., Y.L., B.P., M.F. and K.X.; formal analysis, P.B., B.P., K.R.  
558 and A.R.; investigation, P.B. and B.P.; resources, K.R., F.H., R.R. and B.P.; data curation, P.B. and Y.L.; writing—  
559 original draft preparation, P.B.; writing—review and editing, B.P., P.B., Y.L., S.D., J.E., K.X., A.R., K.R., R.R.,  
560 M.F. and F.H.; visualization, P.B. and B.P.; supervision, B.P.; project administration, B.P.; funding acquisition,  
561 B.P.; All authors have read and agreed to the published version of the manuscript.

562  
563 **Data Availability Statement:** The data presented in this study are available on request from the corresponding  
564 author.

565  
566 **Funding:** Behrus Puladi was funded by the Medical Faculty of RWTH Aachen University as part of the Clinician  
567 Scientist Program. We acknowledge FWF enFaced 2.0 [KLI 1044, <https://enfaced2.ikim.nrw/>] and KITE  
568 (Plattform für KI-Translation Essen) from the REACT-EU initiative [<https://kite.ikim.nrw/>, EFRE-0801977].

569  
570 **Institutional Review Board Statement:** The study has been approved by the Institutional Review Board (or  
571 Ethics Committee) of University Hospital RWTH Aachen (protocol code EK 23-149 and date of approval:  
572 20.07.2023).

573  
574 **Informed Consent Statement:** Informed consent was obtained from all subjects involved in the study. Figure 3A  
575 shows the first author, who consented to have her photograph included in Figure 3.

576  
577 **Competing Interests:** The authors declare no competing interests.  
578

579 **Tables**

580 *Table 1*

Study#	Year	Design	Intervention	Control	Flap	Model	Participants	Amount of models / osteotomies	Angular Deviation [Intervention / Control]	Distance [Intervention / Control]
Chao et al. [14]	2016	Explorative study	Autonomous robotic system	-	Fibula	Phantom	Robot (KUKA lightweight robot)	3 / 18	4.2±1.7° / -	1.3±0.4 mm <sup>a</sup> / -
Zhu et al. [26]	2016	Explorative study	Autonomous and manual robotic system	Computer-assisted navigation & Freehand Technique	Fibula	Phantom & Sheep	Robot (Custom/ Omega 6)	Phantom: 15 Animal: 6	-	Phantom: 1.2, 1.6, 2.3 mm <sup>b</sup>  Animal: 1.8, 1.8, 2.1 mm <sup>b</sup> 3.0±1.1 mm <sup>c</sup>
Pietruski et al. [19]	2020	Explorative study	Navigation and AR (nAR: HMDs with marker spheres)	Simple AR (sAR: HMDs) Cutting Guide (Slot Design)	Fibula	Phantom	3 Surgeons	18 / 126	5.0±2.9° (nAR)/ 5.1±3.6° (sAR)/ 4.1±2.3°	2.7±1.1 mm <sup>c</sup> 2.8±1.1 mm <sup>c</sup>
Meng et al. [20]	2021	Explorative study	AR (HMDs)	-	Fibula	Phantom	Number of participants unclear	10 / 40	2.9±2.0° / -	2.1±1.3 mm <sup>d</sup> / -
Guo et al. [18]	2022	Explorative study	Autonomous robotic system	-	Fibula	Phantom	Robot (UR5)	10 Phantom models	1.6±1.1°	1.0±0.7 mm <sup>e</sup>
Winnand et al. [21]; Modabber et al. [22]	2022	Explorative study	AR (Light projection with a robotic arm)	3D-printed Cutting Guide (Flange Design)	Iliac Crest	Phantom / Cadaver	2 (1x Resident, 1x Specialist)	Phantom: 40 Cadaver: 10 (20)*	Phantom: 10.2±7.2° / 7.0±4.7° Cadaver: 15.0±11.7° / 8.5±5.4°	Phantom: 2.3±2.0 mm/ 1.3±1.0 mm <sup>f</sup> Phantom: 2.7±3.3 mm/ 1.5±1.4 mm <sup>g</sup>
De Boutray et al. [15]	2023	Explorative Study	Robot-assisted (Franka Emika Panda)	-	Fibula	Phantom	1 surgeon	6 / 26	Phantom: 1.9±1.2° / -	Phantom: 0.4±0.3 mm <sup>h</sup> / -
Hu et al. [7]	2023	Explorative Study	Robot-assisted (UR5)	-	Fibula	Phantom	3 (One expert operator and two intermediate level operators)	3 / 24	1.3±0.7° / -	1.1±0.4 mm <sup>e</sup> / -
Liu et al. [23]	2023	Explorative study	Phantom: AR (HMD)  Rabbit: AR (HMD)	Phantom: -  Rabbit: 3D-printed Cutting Guide (Flange design)	Fibula	Phantom & Rabbit	1 (maxillofacial surgeon)	9 Fibulae (Phantom) 12 rabbits	Phantom: 5.5±2.1° / -  Rabbit: 6.5±3.0°/ 6.9±4.0°	Phantom: 1.9±0.4 mm / <sup>j</sup> Rabbit: 0.9±0.2 mm / 0.8±0.2 mm <sup>i</sup>
Shao et al. [16]	2023	Explorative Study	Robot-assisted (UR5) and AR (HMD)	-	Fibula	Cadaver	5 (3 surgeons, 2 engineers)	12	-	Dlong: 0.6±0.4 mm, Dshort: 0.7±0.6 mm, Dline: 0.7±0.6 mm, DFpoints: 1.1±0.3 mm <sup>j</sup>
This study	2023	Cross-over RCT	Robot with sawing guide (Franka Emika Panda)	3D-printed Cutting Guide (Flange Design)	Iliac Crest	Phantom	40 (23 Students + 17 Surgeons)	80 / 320	1.9±1.1°/ 4.7±2.9°	1.5±0.6 mm/ 2.0±0.9 mm

581 # Literature searches for English language papers were conducted by two investigators (P.B. and B.P.)  
 582 independently on PubMed (n=233) and Scopus (n=325) using the following search term last on December 13,  
 583 2023: ("navigation"[Title/Abstract] OR "augmented reality"[Title/Abstract] OR "robot\*" [Title/Abstract]) AND  
 584 ("jaw"[Title/Abstract] OR "mandib\*" [Title/Abstract] OR "maxill\*" [Title/Abstract]) AND  
 585 ("reconstruction"[Title/Abstract] OR "FFF"[Title/Abstract] OR "fibula"[Title/Abstract] OR  
 586 "scapula"[Title/abstract] OR "DCIA"[Title/Abstract] OR "iliac crest"[Title/Abstract] OR "flap"[Title/Abstract])

587 \* two transplants were harvested on each model

588 <sup>a</sup> the average linear variation of the osteotomized segments compared to the preoperative plan

589 <sup>b</sup> mean deviation of the fibula implant after superimposition

590 <sup>c</sup> deviation of two control points

591 <sup>d</sup> distance between actual and virtual fibular osteotomy

592 <sup>e</sup> fibula segment length variation

593 <sup>f</sup> mean distances of the osteotomy planes from the planned trajectories

594 <sup>g</sup> deviation between planes and planned osteotomy surface

595 <sup>h</sup> deviations between the lengths of the obtained and virtual fragments

596 <sup>i</sup> distance deviations for the reconstructed tibiofibular osteotomy surfaces

597 <sup>j</sup> D<sub>long</sub>: long side length deviation, D<sub>short</sub>: short side length deviation, D<sub>line</sub>: center line segment length deviation,

598 DF<sub>points</sub> average distance error of the control points

599

600

601 *Table 2*

602 **Table 2.** Characteristics of the cohort

Parameter		Started with Cutting Guide (n=20)	Started with robot-assisted method (n=20)	Total (n=40)
Sex	Female	7 (35.0%)	9 (45.0%)	16 (40.0%)
	Male	13 (65.0%)	11 (55.0%)	24 (60.0%)
Age	Mean (SD)	25.9 (4.3)	28.2 (6.1)	27.1 (5.3)
Profession	Student	13 (65.0%)	10 (50.0%)	23 (57.5%)
	Doctor	7 (35.0%)	10 (50.0%)	17 (42.5%)
Group	Dental Student	6 (30.0%)	1 (5.0%)	7 (17.5%)
	Medical Student	7 (35.0%)	9 (45.0%)	16 (40.0%)
	Resident	6 (30.0%)	7 (35.0%)	13 (32.5%)
	Specialist	1 (5.0%)	3 (15.0%)	4 (10.0%)
Stud Progress (Years)	Mean (SD)	4.3 (0.9)	4.4 (0.8)	4.3 (0.8)
Years Practiced	Mean (SD)	4.9 (2.7)	6.4 (5.4)	5.8 (4.5)
Previous experience with 3D-printed cutting guides		2	0	2 (5.0%)

603

604 *Table 3*

605 **Table 3.** Likert questionnaires

Questions	3D-printed (n=40)	Robot-assisted (n=40)	Total (n=80)	p value
The method helps to precisely implement the planned osteotomy.	3.1 (0.8)	3.5 (0.6)	3.3 (0.7)	0.033
I felt safer when sawing with the method.	2.7 (1.1)	3.4 (0.7)	3.1 (1.0)	0.001
The method provided good haptic support.	2.8 (0.9)	3.6 (0.7)	3.2 (0.9)	< 0.001
The method is intuitive.	3.4 (0.7)	3.3 (0.7)	3.4 (0.7)	0.687
The method is easy to use.	3.3 (0.9)	3.5 (0.6)	3.4 (0.8)	0.617
The method helps to saw effectively.	3.2 (0.9)	3.4 (0.7)	3.3 (0.8)	0.551
The use of the method increases patient safety.	3.2 (0.9)	3.4 (0.7)	3.3 (0.8)	0.511
The method improves the outcome of flap harvesting.	3.2 (0.9)	3.4 (0.8)	3.3 (0.8)	0.551
I would recommend the use of the method.	3.2 (0.8)	3.2 (0.8)	3.2 (0.8)	0.975
In my opinion, the method is practical.	3.4 (0.7)	2.8 (0.9)	3.1 (0.8)	0.008

606

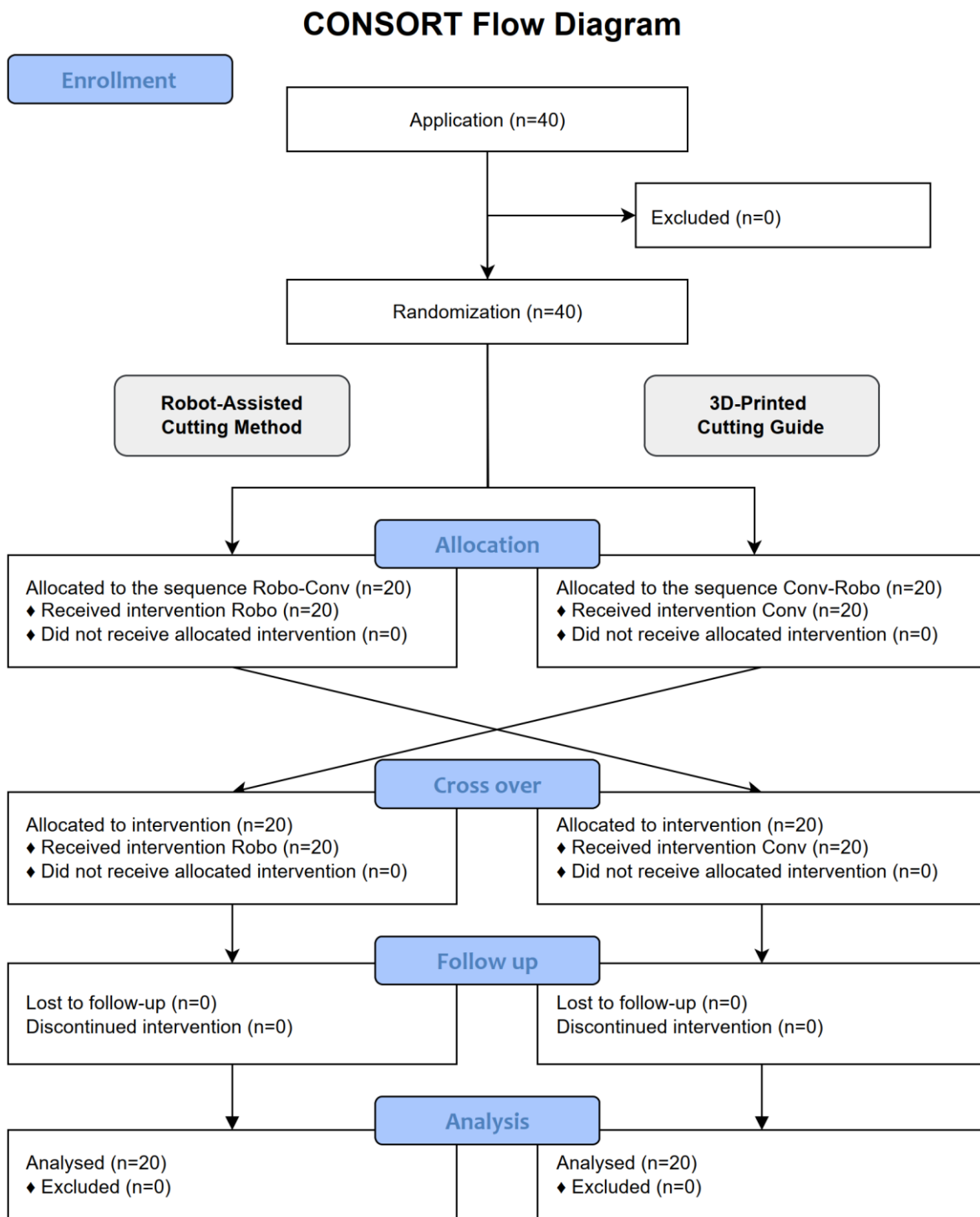
607 *Table 4*

<i>Method</i>	<b>Positive</b>	<b>Negative</b>
<i>3D-printed</i>	<ul style="list-style-type: none"> <li>• Easy to use, good visualization of the transplant.</li> <li>• Good view on the osteotomy planes during the sawing process.</li> <li>• Better prediction of the length of the osteotomy planes.</li> <li>• Stable fixation on the bone.</li> <li>• Subjective security while sawing.</li> <li>• Higher independency of the surgeon.</li> <li>• No breaks between the single planes.</li> <li>• Easy to fixate the cutting-guide.</li> <li>• Good orientation.</li> </ul>	<ul style="list-style-type: none"> <li>• Less haptic support, fixation with screws.</li> <li>• Less control about the angulations.</li> <li>• Exhausting fixation of the cutting guides with screws.</li> <li>• No physical end stop.</li> <li>• Higher risk of slipping away with the saw.</li> <li>• Worse haptic guidance.</li> <li>• Difficult to place the saw directly underneath the cutting guide.</li> <li>• High risk for mistakes.</li> <li>• Functional &amp; optical worse result.</li> </ul>
<i>Robot-assisted</i>	<ul style="list-style-type: none"> <li>• Very good haptic support, translational and angular limitation of the osteotomy planes.</li> <li>• A physical end stop and limitation in every direction.</li> <li>• No need to screw a cutting guide to the bone before sawing.</li> <li>• High subjective security.</li> <li>• Higher subjective accuracy.</li> <li>• Lower chance to slip away with the saw and to make mistakes.</li> <li>• Very intuitive.</li> <li>• Universal cutting-guide design, that does not need to be individually manufactured.</li> <li>• Even beginners are able to perform precise osteotomies.</li> <li>• Nice optical result of the transplant.</li> <li>• Gentler procedure, High-Tech!</li> </ul>	<ul style="list-style-type: none"> <li>• Limited view on the bone and on the osteotomy planes.</li> <li>• High dependency on the robot.</li> <li>• Time consuming, regarding preparations and moving times between the osteotomies.</li> <li>• Takes up space in the OR.</li> <li>• Sometimes the guidance was too precise, so that the saw had to be held very straight, otherwise it blocked because of the friction.</li> <li>• Physically exhausting because of being limited from the robot.</li> <li>• Additional technical and personnel costs.</li> <li>• Less intuitive, more difficult handling.</li> <li>• Limited stability of the robotic arm.</li> </ul>

608

609 **Figures**

610 *Figure 1*

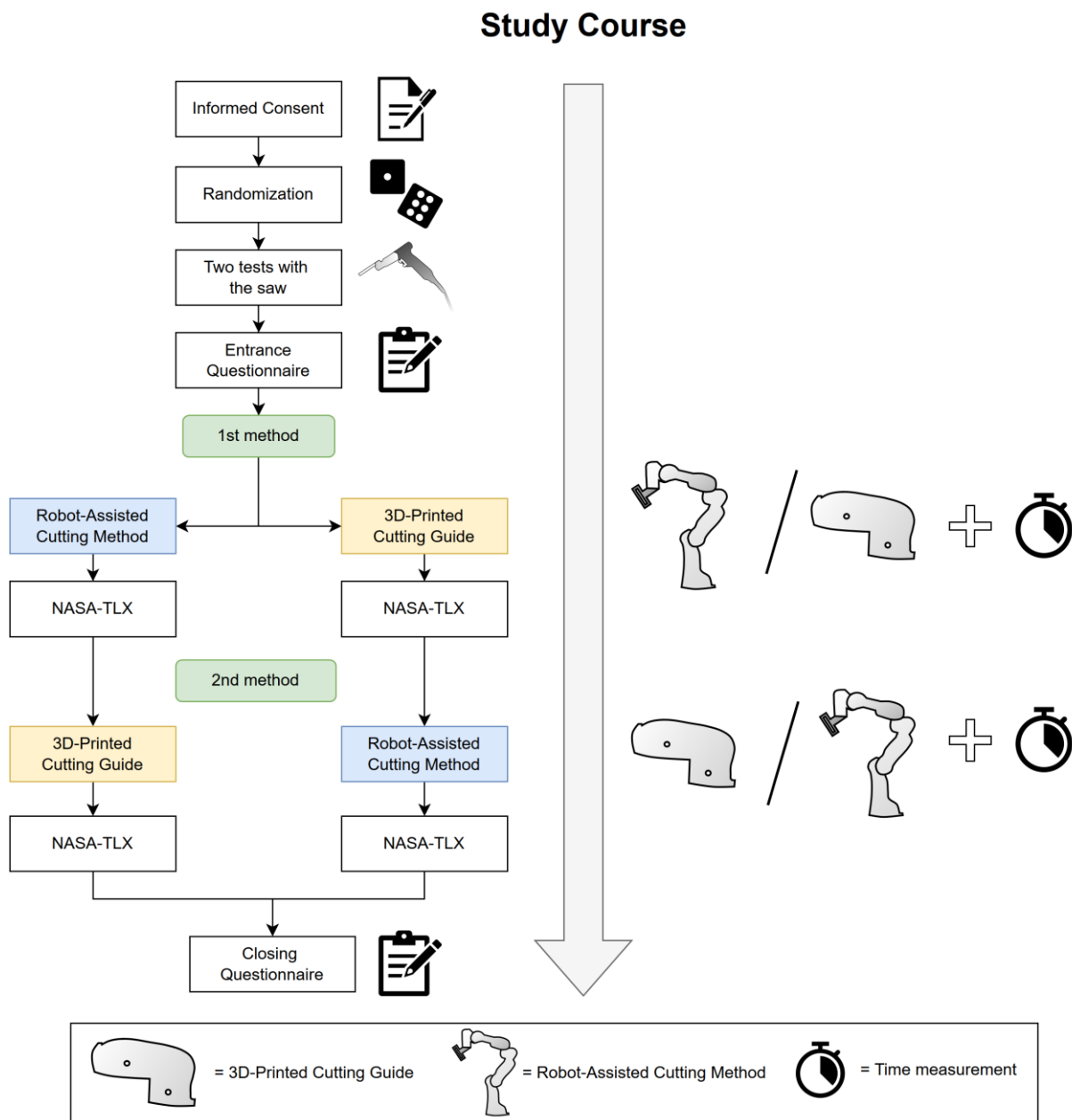


611 **Figure 1.** CONSORT flow diagram.  
612

613

614

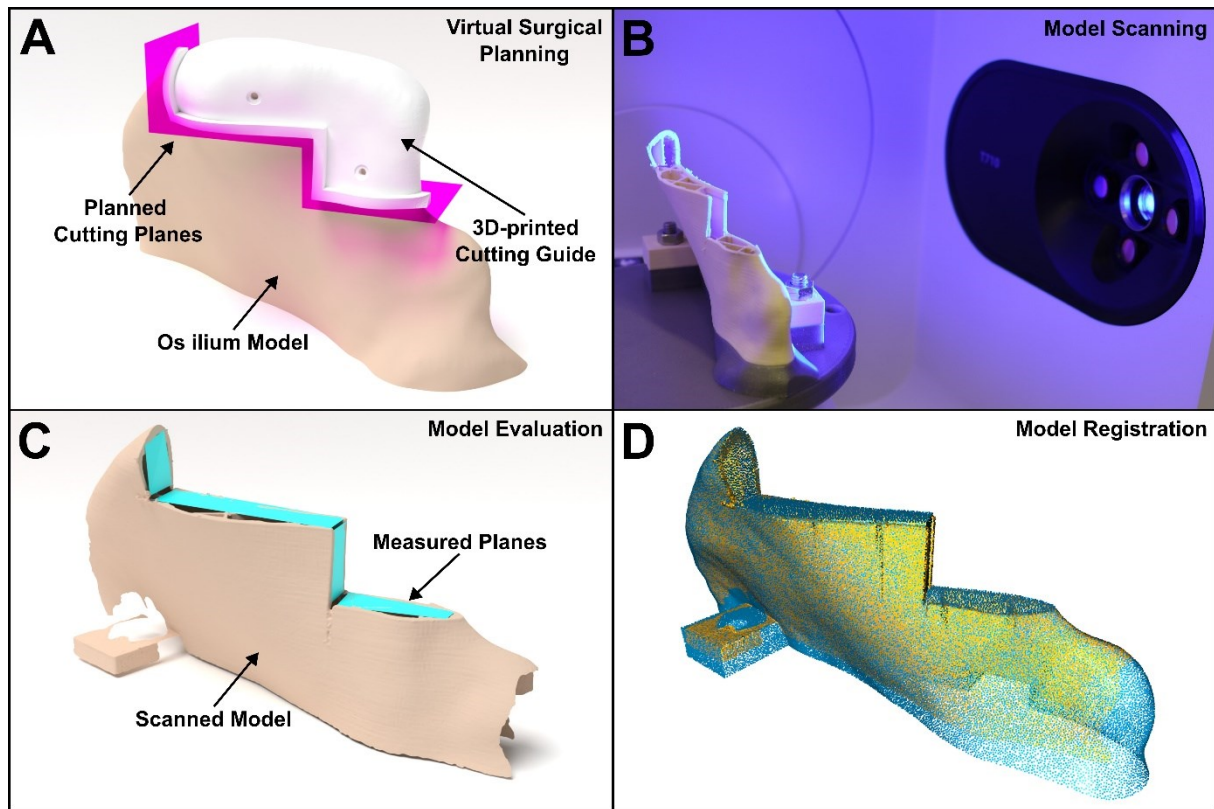
615 *Figure 2*



616

617 **Figure 2.** Description of the chronological order of the study.

618 *Figure 3*

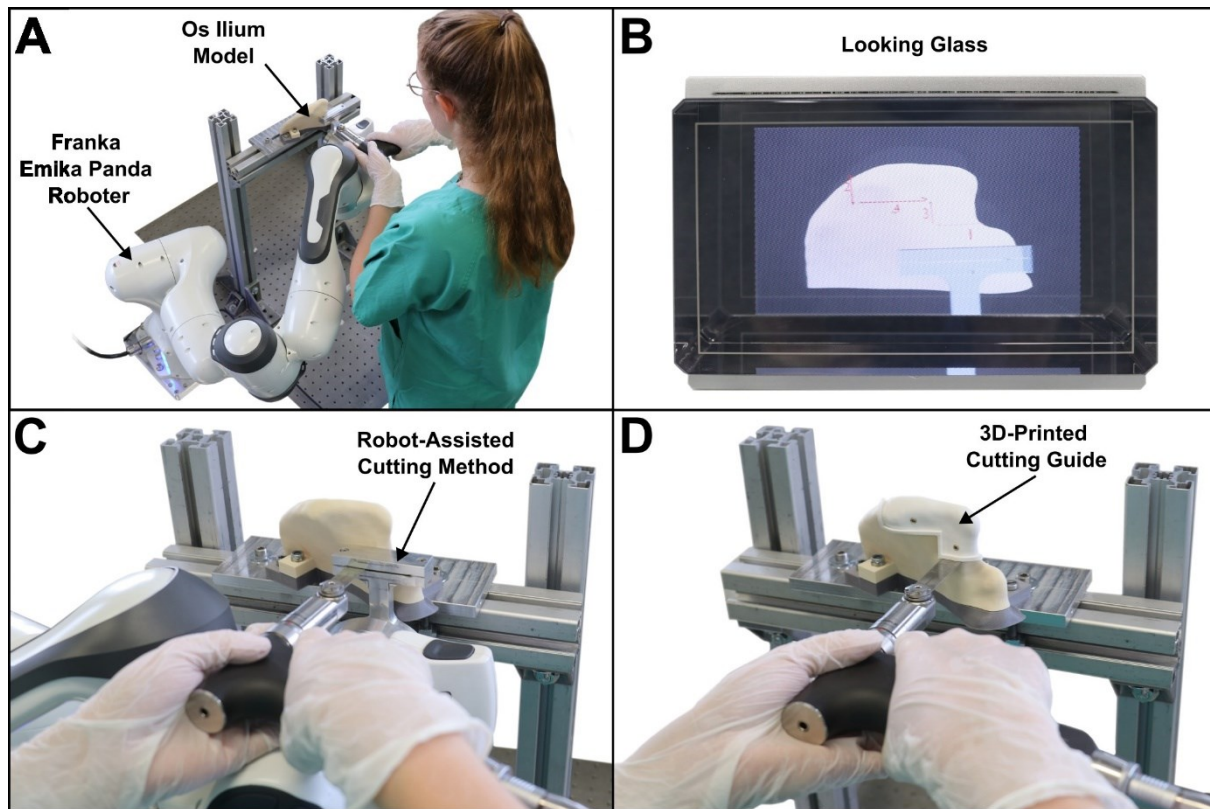


619

620 **Figure 3.** (A) Virtual Planning of the transplant and Computer assisted design of the surgical cutting guide in  
621 Blender. (B) Scanning process of the sawed iliac crest model using a 3D-Scanner (Medit T710, Medit, Seoul,  
622 South Korea). (C) 3D-Visualization of the scanned model, including planes based on four points, that were used  
623 for the evaluation and were created by two independent investigators. (D) Iterative closest point (ICP) registration  
624 of the scanned model with the planning model.

625

626 *Figure 4*



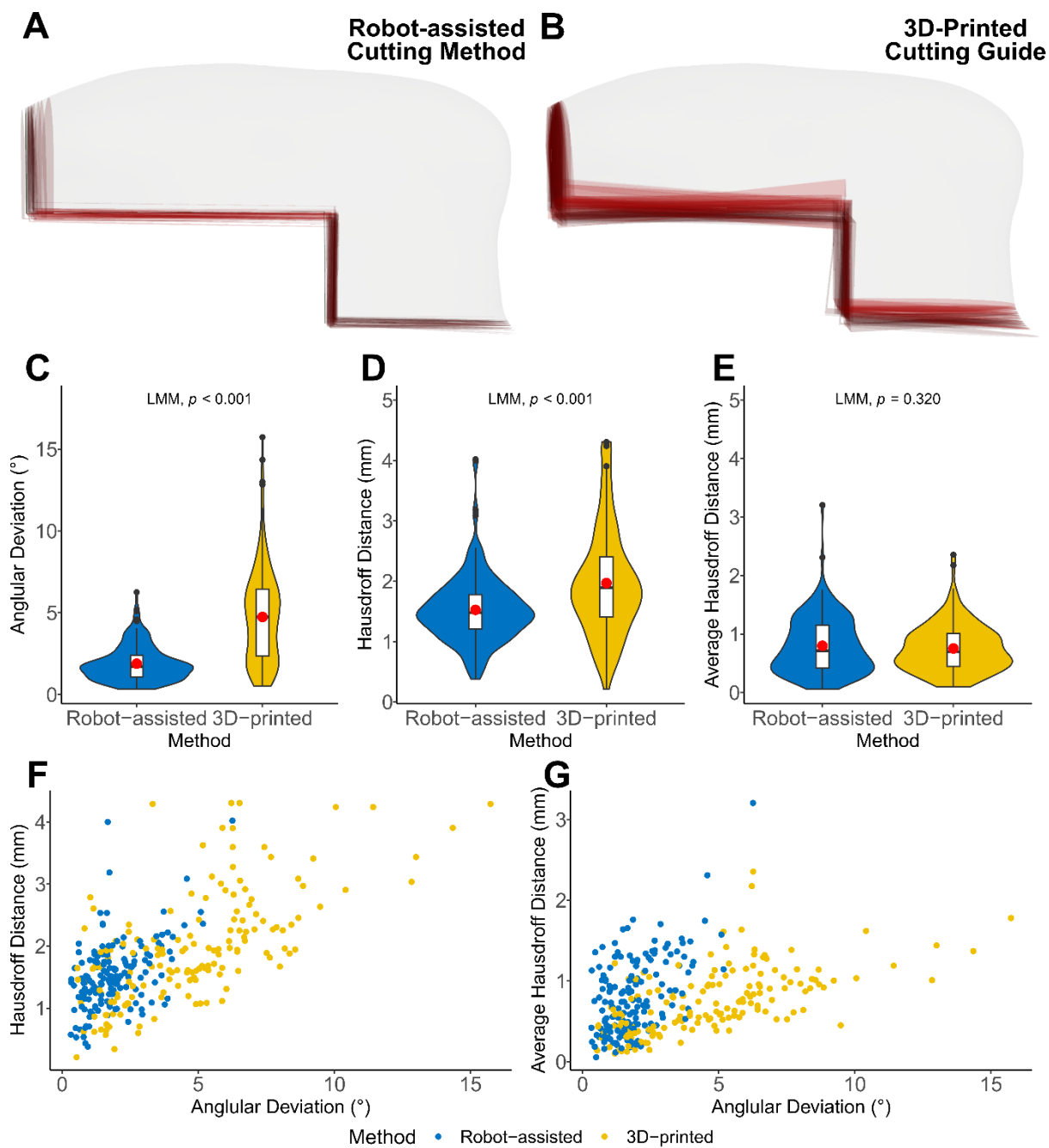
627

628 **Figure 4.** (A) A participant performing the osteotomy using the robot-assisted cutting method with the Franka  
629 Emika Panda Robot. (B) Holographic visualization of the robotic method and of the osteotomy sequence. (C)  
630 Experimental setup of the robot-assisted cutting method. (D) Experimental setup of the conventional 3D-printed  
631 cutting guide.

632



633 *Figure 5*

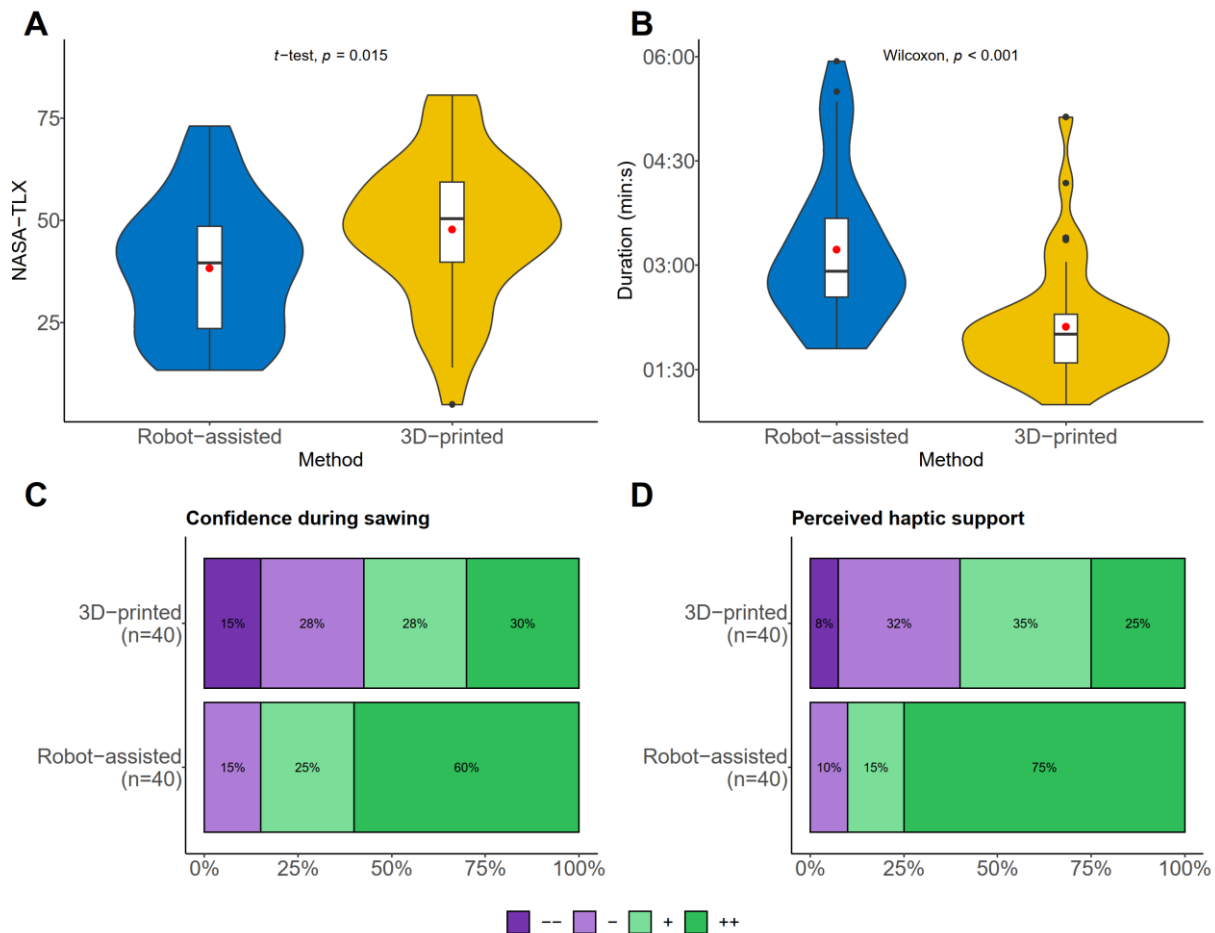


634

635 **Figure 5.** (A) Comparison of all 40 osteotomies performed with the robot-assisted cutting method (red) with the  
636 planned transplant (white). (B) Comparison of all 40 osteotomies performed with the 3D-printed cutting guides  
637 (red) with the planned transplant (white). (C) Difference of the osteotomy angles between the planned and  
638 harvested osteotomy planes for the 3D-printed cutting guide and the robot-assisted cutting method in degrees. (D)  
639 Hausdorff Distance between the planned and harvested osteotomy planes for the 3D-printed cutting guide and the  
640 robot-assisted cutting method in mm. (E) Average Hausdorff Distance between the planned and harvested  
641 osteotomy planes for the 3D-printed cutting guide and the robot-assisted cutting method in mm. (F) Visualization  
642 of angular deviation (x-axis) versus HD (y-axis) for both methods. (G) Visualization of angular deviation (x-axis)  
643 versus AVD (y-axis) for both methods. (F, G) Blue points are from the robot-assisted method and yellow points  
644 are from the 3D-printed cutting guide.

645

646 *Figure 6*

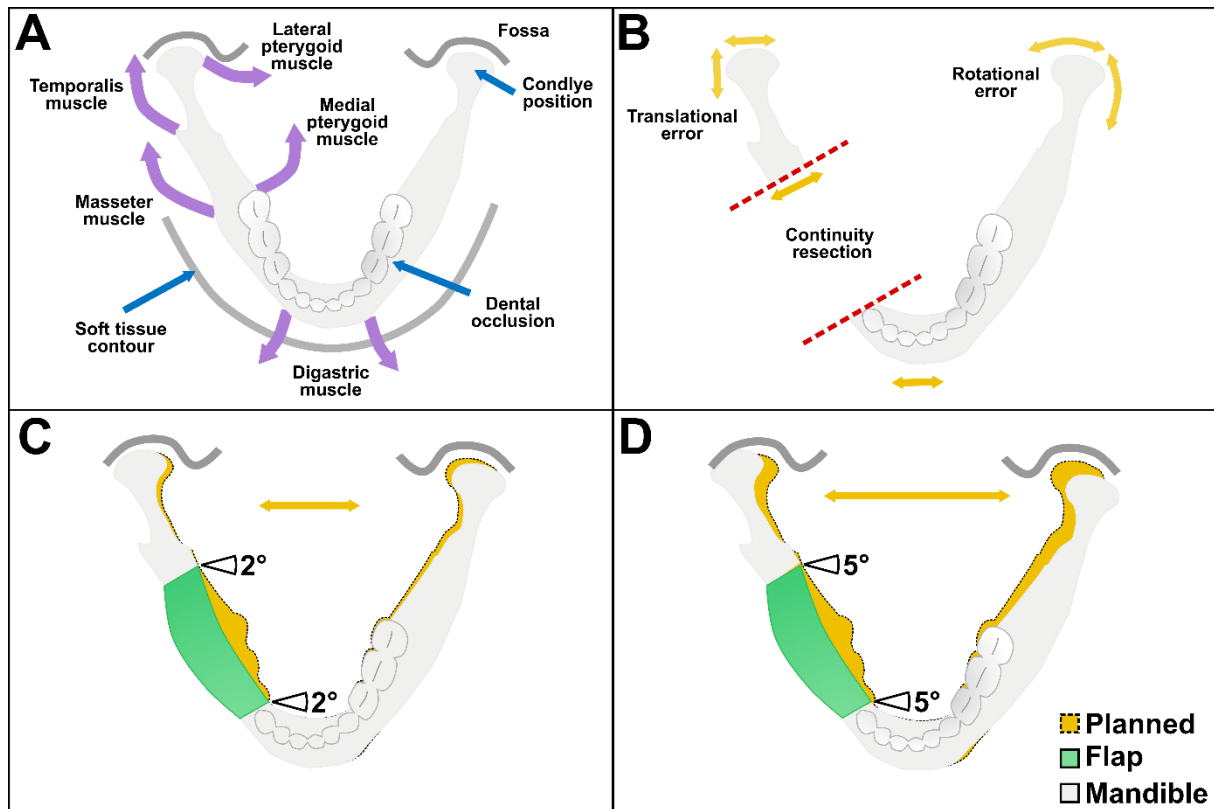


647

648 **Figure 6.** (A) Results of the subjectively experienced workload measured with NASA-TLX score using the mean  
649 and standard deviation. (B) Results of the average duration and standard deviation of the 3D-printed cutting guide  
650 and robot-assisted cutting method. (C) Results of the second Likert Question about how safe the participant felt  
651 during the sawing process, dark purple meaning very poor (1) and dark green meaning very good (4). (D) Results  
652 for the third Likert Question “The method provided good haptic support during the sawing process”, dark purple  
653 meaning very poor (1) and dark green meaning very good (4).

654

655 *Figure 7*



656

657 **Figure 7.** (A) Schematic visualization of muscles (purple arrows: digastric, masseter, temporalis, lateral and  
658 medial pterygoid muscle) affecting functional outcomes (blue arrows: condyle position in the articular fossa,  
659 dental occlusion and soft tissue contour) of the mandible. (B) Possible sources of error (yellow arrows: translation  
660 and rotation) in accuracy and functional results during mandibular reconstruction. Red dashed line the conducted  
661 discontinuity resection. (C) Simulated translational error of the condyle position with an angular deviation of the  
662 osteotomy angles of  $2^\circ$ . (D) Simulated translational error of the condyle position with an angular deviation of the  
663 osteotomy angles of  $5^\circ$ .