

Supplementary Information of

Spatiotemporal Rhythmic Seizure Sources Can be Imaged by means of Biophysically Constrained Deep Neural Networks

Rui Sun¹, Abbas Sohrabpour¹, Boney Joseph², Gregory Worrell², Bin He^{1,3,*}

1. Department of Biomedical Engineering, Carnegie Mellon University, Pittsburgh, PA
2. Department of Neurology, Mayo Clinic, Rochester, MN
3. Neuroscience Institute, Carnegie Mellon University, Pittsburgh, PA

* Correspondence:

Bin He, PhD

Carnegie Mellon University

Department of Biomedical Engineering

5000 Forbes Avenue, Pittsburgh, PA 15213, USA

Email: bhe1@andrew.cmu.edu

Table S1

Patient information						
Pt. #	Gender	Surgical Resection	Intracranial EEG	Follow-up	Outcome	Surgery age range
1	F	Right anterior temporal lobectomy and amygdalohippocampectomy	Right temporal grids and strips and depth electrodes on mesial side	1 year	ILAE-1	31-35
2	M	Right anterior temporal lobectomy and hippocampectomy	Bilateral depth electrodes into hippocampi	3 years	ILAE-1	26-30
3	F	Left anterior temporal lobectomy and amygdalohippocampectomy	Left frontal and temporal grids and strips and depth electrodes on mesial side	3 years	ILAE-1	26-30
4	F	Left anterior temporal lobectomy and amygdalohippocampectomy	Left temporal strips and mesial depth electrodes	32 months	ILAE-1	21-25
5	F	Left anterior frontal lobe excision	N.A.	30 months	ILAE-1	21-25
6	F	Right anterior temporal lobectomy and amygdalohippocampectomy	Right temporal grids and strips and depth electrodes on mesial side	1 year	ILAE-1	21-25
7	F	Left anterior temporal lobectomy and amygdalohippocampectomy	Left frontal and temporal grids and strips and mesial depth electrodes	1 year	ILAE-2	N.A.
8	F	Right temporal lobectomy and amygdalohippocampectomy	N.A.	2 years	ILAE-2	46-50
9	F	Right temporal lobectomy and amygdalohippocampectomy	Right temporal grids and strips and depth electrodes on mesial side	1 year	ILAE-1	16-20
10	F	Left temporal lobectomy and amygdalohippocampectomy	N.A.	32 months	ILAE-1	56-60
11	F	Left temporal lobectomy and amygdalohippocampectomy	Right temporal grids and strips and depth electrodes on mesial side	1 year	ILAE-1	51-55
12	F	Right temporal lobectomy and amygdalohippocampectomy	Right temporal grids and strips and depth electrodes on mesial side	1 year	ILAE-1	21-25
13	F	Extended right temporal lobectomy with amygdalohippocampectomy	Multiple right lateral temporal and sub-temporal grids and strips of electrodes	15 months	ILAE-1	36-40

14	M	Right temporal lobectomy and amygdalohippocampectomy	Right temporal grids and strips and depth electrodes on mesial side	1.5 years	ILAE-1	46-50
15	M	Right anterior temporal lobectomy and amygdalohippocampectomy	Right temporal grids and strips and depth electrodes on mesial side	1 year	ILAE-1	51-55
16	F	Left parietal focal cortical resection	Right temporal grids and strips and depth electrodes on mesial side	1 year	ILAE-1	21-25
17	M	Modified left frontal lobectomy	Left frontal strips	19 months	ILAE-1	21-25
18	M	Right temporal lesion resection	N.A.	19 months	ILAE-1	46-50
19	F	Right frontal cortical resection	Right frontal, orbital frontal, and bilateral interhemispheric grid/strips/depth electrodes	14 months	ILAE-1	11-15
20	F	Left anterior temporal lobectomy and amygdalohippocampectomy	Left parietal, left temporal mesial, and lateral neocortical region depth, subdural grid, and strip electrodes	16 months	ILAE-1	21-25
21	M	Right mesial frontal orbital lobe excision	Bilateral temporal and frontal depth electrodes	15 months	ILAE-1	21-25
22	M	Right frontotemporal lobe resection	Right temporoparietal and right parietal grid, right temporal depth electrodes	11 months	ILAE-5	21-25
23	M	Right temporal lobectomy and amygdalohippocampectomy	Bitemporal depth electrodes	8 months	ILAE-4	36-40
24	F	Right temporal lobectomy and amygdalohippocampectomy	Right temporal strips and mesial temporal depth electrodes	19 months	ILAE-3	46-50
25	M	Right anterior temporal lobectomy and amygdalohippocampectomy	Right temporal strips and mesial temporal depth electrodes	18 months	ILAE-4	26-30
26	F	Left anterior temporal lobectomy and amygdalohippocampectomy	Left temporal grid and strips on the inferior temporal side and left frontal, depth electrodes on temporal and frontal	12 months	ILAE-4	21-25
27	F	Focal temporo-occipital cortical resection	Right fronto-temporal grids and strips and depth electrodes close to amygdala and hippocampus, and later right posterotemporo-parietal grids and strips	12 months	ILAE-4	21-25

28	M	Right temporal lobectomy and amygdalohippocampectomy	Right temporal strips	13 months	ILAE-4	26-30
29	F	Left temporal lobectomy and amygdalohippocampectomy	left temporal strips and mesial depth electrodes	15 months	ILAE-4	56-60
30	F	Left anterior temporal lobectomy and amygdalohippocampectomy	Left temporal strips and electrodes	12 months	ILAE-3	N.A.
31	M	Lateral temporal extending into parietal cortex resection	Left subdural grids, strips, and depth electrodes	14 months	ILAE-5	31-35
32	M	Posterior superior margin of the sylvian fissure resection	Right subdural grids, strips, and depth electrodes	15 months	ILAE-5	36-40
33	M	Left anterior temporal lobectomy, amygdalohippocampectomy, and left posterior temporo-occipital corticectomy	Left temporal subdural grids, strip electrodes, and left depth electrodes	15 months	ILAE-3	46-50

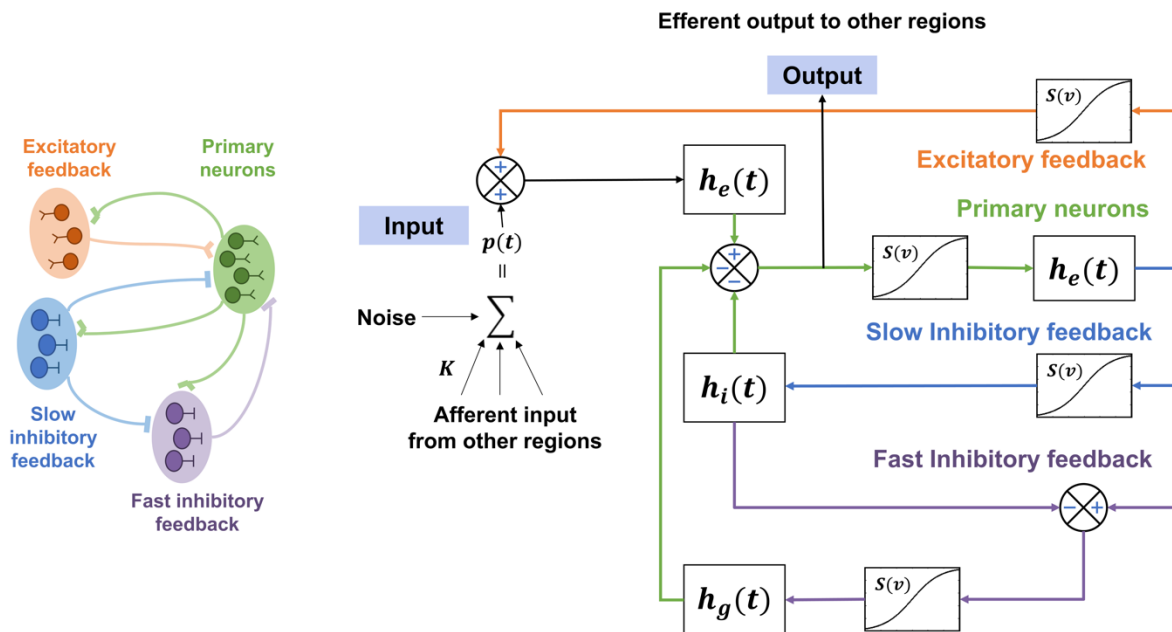


Figure S1. A single-element modified Jansen-Rit model simulates four neuronal sub-populations: the primary neurons (i.e., pyramidal cells), as well as excitatory, slow inhibitory and fast inhibitory interneurons. The influence from other neural ensembles is modeled as an excitatory input $p(t)$ that represents the average pulse density, i.e., average firing rate, of afferent action potentials. The behavior of each subpopulation is modeled using linear functions $h(t)$ that describe how presynaptic information, from excitatory and inhibitory populations, is transformed into postsynaptic information, and nonlinear function $S(v)$ that models the change from average membrane potential of the subpopulation to average pulse density.

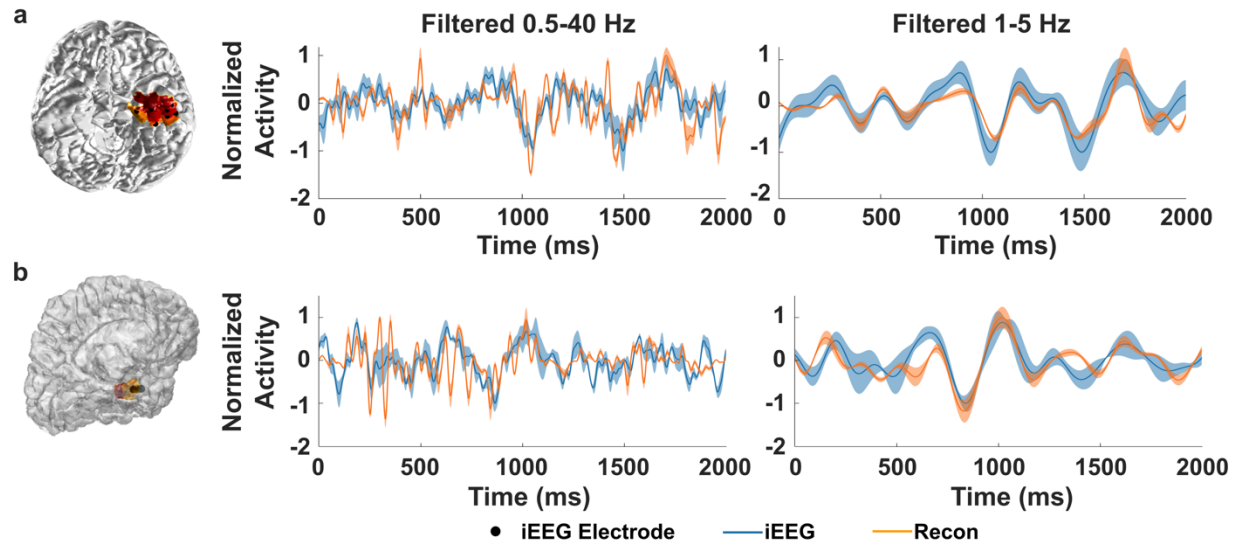


Figure S2. Comparing estimated time-courses from EEG to intracranial EEG recordings in 2 patients. The reconstructed time-courses near the SOZ electrodes from DeepSIF were averaged and compared to the averaged iEEG traces. The major ictal frequency for these patients is around 3 Hz. **a**, The linear correlation between the iEEG and reconstruction is 0.5 for wide-band signal, and 0.84 for narrow-band signal filter around the major frequency. **b**, The linear correlation between the iEEG and reconstruction is 0.4 for wide-band signal, and 0.77 for narrow-band signal filter around the major frequency.

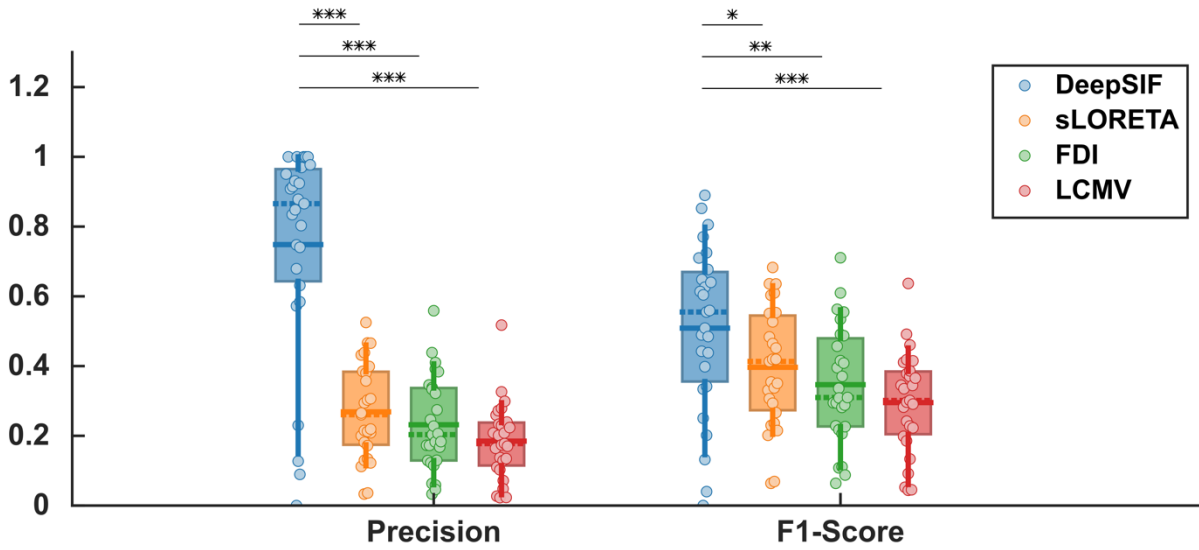


Figure S3. Precision and F1-Score for different ictal source imaging methods. Paired one-sided Wilcoxon signed rank test was used with statistical significance cutoffs of (* $P < 0.05$, ** $P < 0.01$, *** $P < 0.001$).

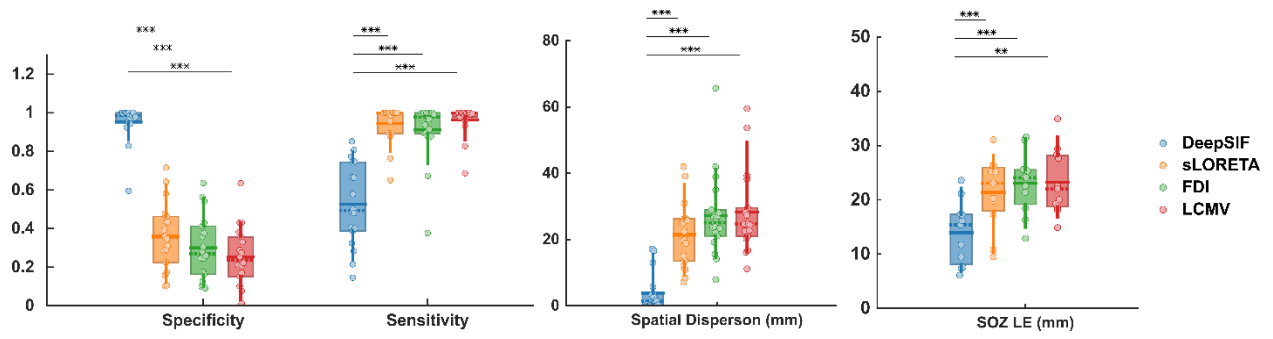


Figure S4. Ictal source imaging results for different ictal imaging methods in the seizure free group. Paired one-sided Wilcoxon signed rank test was used with statistical significance cutoffs of (* $P < 0.05$, ** $P < 0.01$, *** $P < 0.001$).