

SUPPLEMENTARY ONLINE MATERIALS

589
590

591 MDA5-autoimmunity and Interstitial Pneumonitis Contemporaneous with the COVID- 592 19 Pandemic (MIP-C)

593

594 Authors

595 Khizer Iqbal*¹, Saptarshi Sinha*², Paula David*¹, Gabriele De Marco^{3, 4, 5}, Sahar Taheri⁶, Ella
596 McLaren², Sheetal Maisuria⁴, Gururaj Arumugakani^{7, 8}, Zoe Ash⁹, Catrin Buckley¹, Lauren Coles¹,
597 Chamila Hettiarachchi³, Gayle Smithson³, Maria Slade³, Rahul Shah¹, Helena Marzo-Ortega⁴,
598 Mansoor Keen⁹, Catherine Lawson¹⁰, Joanna Mclorinan¹, Sharmin Nizam³, Hanu Reddy¹¹, Omer
599 Sharif¹², Shabina Sultan¹¹, Gui Tran¹⁰, Mark Wood¹, Samuel Wood¹, Pradipta Ghosh^{2, 13‡}, Dennis
600 McGonagle^{1,4‡}

601

602 *These authors contributed Equally as first author

603

604 Affiliations

605 ¹Leeds Teaching Hospitals NHS Trust, Rheumatology Department, Leeds, United Kingdom. ²Department of Cellular and
606 Molecular Medicine, School of Medicine, University of California San Diego, La Jolla, CA, 92093, USA. ³Mid Yorkshire
607 Teaching NHS Trust, Rheumatology, Wakefield, United Kingdom ⁴University of Leeds, Leeds Institute of Rheumatic and
608 Musculoskeletal Medicine, Leeds, United Kingdom. ⁵NIHR Leeds Biomedical Research Centre, Leeds Teaching Hospitals
609 NHS Trust, Leeds, United Kingdom. ⁶ Department of Computer Science and Engineering, Jacob's School of Engineering,
610 University of California San Diego, La Jolla, CA. 92093, USA. ⁷Leeds Teaching Hospitals NHS Trust, Pathology, Leeds, United
611 Kingdom, ⁸University of Leeds, Immunology, Leeds, United Kingdom. ⁹Bradford Teaching Hospitals NHS Foundation Trust,
612 Rheumatology, Bradford, United Kingdom. ¹⁰Harrogate and District NHS Foundation Trust, Rheumatology, Harrogate,
613 United Kingdom. ¹¹Airedale NHS Foundation Trust, Rheumatology, Steeton with Eastburn, United Kingdom. ¹²Calderdale
614 and Huddersfield NHS Foundation Trust, Rheumatology, Huddersfield and Halifax, United Kingdom. ¹³Department of
615 Medicine, School of Medicine, and Veterans Affairs Medical Center, University of University of California San Diego, La
616 Jolla, CA. 92093, USA.

617

618

619 ‡Corresponding Authors:

620 Dennis McGonagle PhD FRCPI

621 Leeds Teaching Hospitals NHS Trust, Rheumatology Department, Leeds, United Kingdom | University
622 of Leeds, Leeds Institute of Rheumatic and Musculoskeletal Medicine, Leeds, United Kingdom |

623 Email: d.g.mcgonagle@leeds.ac.uk

624

625 Pradipta Ghosh, M.D.

626 Professor, Departments of Medicine and Cellular and Molecular Medicine, University of California
627 San Diego; 9500 Gilman Drive (MC 0651), George E. Palade Bldg, Rm 232, 239; La Jolla, CA 92093,
628 USA | Phone: 858-822-7633 | Email: prghosh@ucsd.edu

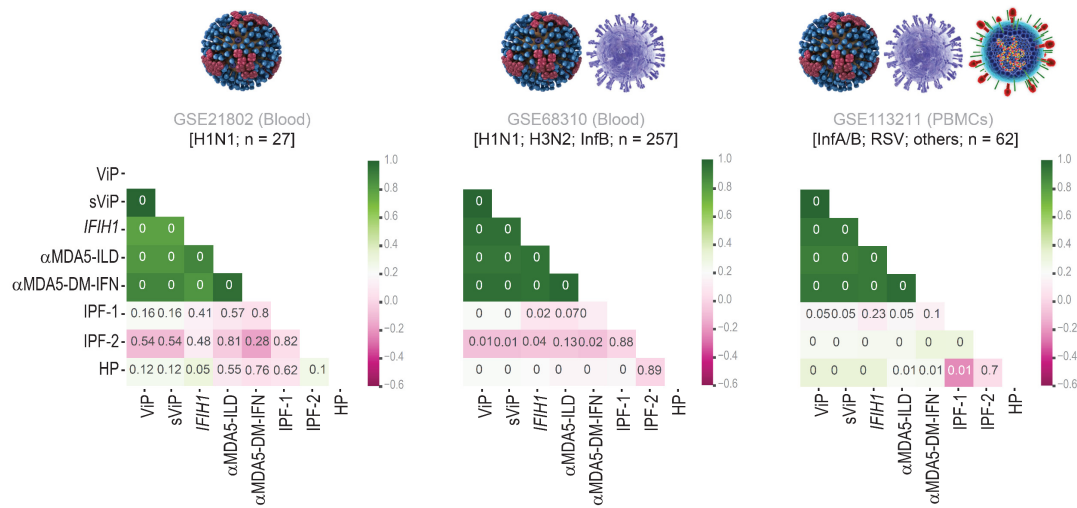
629 **INVENTORY OF SUPPLEMENTARY MATERIALS**

- 630 • Supplementary Figures (2)
- 631 • Supplemental Tables (2)
- 632 • Supplementary Information (2). These are uploaded separately as excel datasheets

633

Supplementary figures

634 Supplementary figure 1

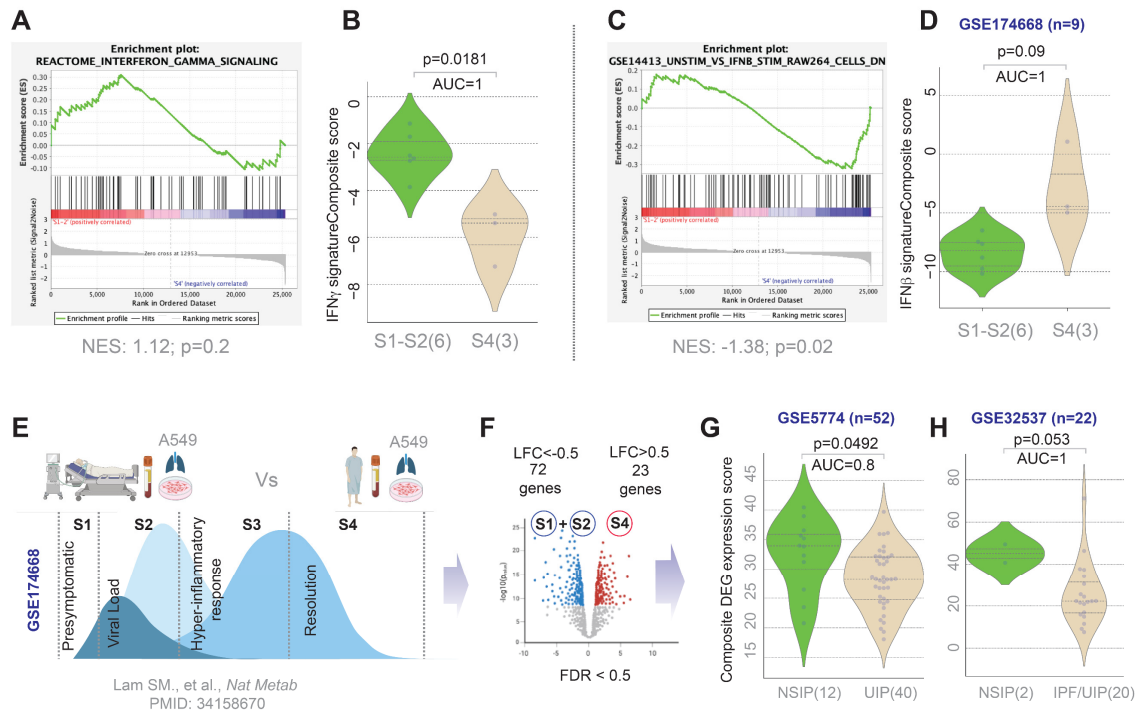


635

636

637 **Supplementary Figure 1: [Related to Figure 4]**

638 **Induction of *IFIH1* in respiratory viral pandemics correlates with the induction of Type 1-centric cytokine storm and α-**
 639 **MDA5-ILD risk signatures in whole blood and PBMCs.** Graphical representation of a correlation matrix representing the
 640 pair-wise correlation between multiple variables, i.e., composite scores of different gene signatures elaborated in **Figure**
 641 **4A.** The colour key spans from -1 (magenta) to 1 (green), indicating both strength and direction of correlation. Numbers
 642 within the heatmap indicate statistical significance (only significant *p values* are displayed).



644

645

646 **Supplementary Figure 2: [Related to Figure 6]**

647 **Serum derived exosomes from convalescent patients with CoV induce a Type 1-centric immunophenotype that is**
 648 **induced also in the lung tissues from non-specific interstitial pneumonitis (NSIP).**

649 A-D. Gene Set Enrichment Analyses (GSEA pre-ranked analysis) of Type 1 and 2 interferon response derived from MSigDB
 650 demonstrate the differential activation of these interferons in lung epithelial cells exposed to exosome vesicles from the
 651 serum of early (A-B) and late (C-D) stages of COVID-19 infection.

652 E-F. Schematic in panel E shows the workflow for the derivation of differentially expressed genes (DEGs; panel F) in lung
 653 epithelial cells exposed to exposed to exosome vesicles from the serum of early (S1-2) and late (S4) stages of COVID-19
 654 infection.

655 G. Violin plots display the composite score of the DEGs (used as a gene signature) in two independent transcriptomic
 656 datasets of lung tissues from subjects with undefined (UIP) or non-specific (NSIP) interstitial pneumonitis and non-diseased
 657 controls.

658

Supplemental Table 1- MDA5 Related ILD Patterns

Gender, age (age range)	ethnicity	past history of autoimmunity	COVID19 vaccination (first dose)	COVID19 infection status	Non-clinical ILD features	Baseline CK	ANA IIF	Other myositis Ab	Imaging	Treatment	Treatment outcome
Male, (45-49)	white-british	nil	7 months after, no flare	not known	proximal muscle weakness, inflammatory arthritis, cutaneous features (ex. Gottron's)	304	negative	anti-PL7+	Chest CT with pulmonary fibrosis and ground glass in the bases, pattern consistent with ILD	MTX (2020, for arthritis), IVIg (during septic arthritis), MMF (nonresponse), cyclophosphamide pulses, HCQ (stopped due to retinal damage)	progressive lung disease
Male, (85-89)	white-british	nil	3 months after, no flare	10 months after, no flare	none	178	negative	anti-SAE1	Chest CT with NSIP pulmonary fibrosis picture	nintenamib	progressive lung disease
Female, (50-54)	white-british	nil	2 months after, no flare	not known	heliotrop rash, shwal, gottren's, synovitis	92	positive	none	Chest CT initially normal but after a year central mid and upper zone ill defined areas of ground glass opacification, no pulmonary fibrosis	MTX, prednisolone, nifedipine	stable lung disease
Female, (65-69)	n/a	nil	4 months before	1 year and 4 months after, no flare	raynaud	149	positive	none	Chest CT with NSIP pattern pulmonary fibrosis	Rituximab, MMF, cyclophosphamide pulse then MMF again	died (ILD)
Female, (60-64)	white-british	Hypothyroidism?	2 months after, no flare	not known	none (possibly synovitis)	71	negative	anti-TIFFgamma	Chest-CT with co-existing pulmonary fibrosis and emphysema (smoker)	nintenamib	progressive lung disease
Male, (40-44)	any other Asian	nil	not vaccinated	not known	synovitis, possibly gotttron's, possibly heliotropic, slightly proximal weakness in upper limbs	47	negative	anti-Ro52	CT angiogram pulmonary - negative for PE, but bilateral ground glass changes	3x doses IV methylprednisolone and then oral prednisolone, IV cyclophosphamide, 5 days of IVIG, tacrolimus and HCL, Rituximab	died (ILD)
Male, (60-64)	white-british	nil	2 weeks before	not known	none	33	positive	anti-SAE1	Most recent chest CT with progressive interstitial lung changes with new ground glass opacification and	methylprednisolone IV	died (ILD)

									pulmonary fibrosis, new bilateral effusions		
Female, (30-34)	white-british	nil	11 months before	not known	mechanic hands	52	positive	anti-SAE1	Most recent chest CT when compared to exam performed six months before, there were new areas of ground-glass changes/consolidation (both centrally and peripherally) in the upper lobes bilaterally and middle lobe.	methylprednisolone IV, cyclophosphamide, Rituximab, MMF	died (ILD)
Female, (55-59)	"other ethnic group"	nil	3 months before	1 year and 8 months after, no flare	mechanic hands, SLE overlap	105	positive	Anti-SAE1, Anti-SRP	Chest CT with upper lobe pulmonary fibrosis and ground glass appearance compatible with ILD	long term steroids, cyclophosphamide, rituximab, azathioprine (intolerant, stopped), MMF, IVIg	stable lung disease
Female, (70-74)	white-british	nil	1 day after	not known	none	29	positive	none	Chest CT with significant amount of ground glass change with subpleural sparing, compatible with NSIP	none (waiting on tests to differentiate from hypersensitivity)	died (ILD)
Female, (60-64)	white-british	Grave's disease	5 months before	10 months before, flared	raynaud	78	negative	none	Chest CT with upper lobe fibrosis with honeycombing	none	stable lung disease
Female, (75-79)	white-british	hypothyroidism?	5 months after, flared	not known	sicca symptoms	50	negative	Anti-SAE1	Chest CT with UIP fibrosis	none	stable lung disease
Male, (35-39)	Pakistani	nil	not vaccinated	not known	cutaneous rash (gottron's papules, facial malar/abdominal rash)	299	positive	none	Chest CT with pneumopericardium and mediastinum with multifocal consolidation and ground glass changes alongside with traction bronchiectasis	methylprednisolone IV, IVIg, cyclophosphamide	died (ILD)
Female, (10-14)	Pakistani	nil	not vaccinated	1 year and 3 months before	inflammatory arthritis, sclerodermatous skin and calcinosis	105	positive	anti-Ro52	Chest CT with some pulmonary fibrosis	azathioprine, MMF, Rituximab, IVIg, sodium thiosulphate, HCO, prednisolone	stable lung disease
Female, (50-54)	n/a	nil	not vaccinated	not known	none	n/a	negative	anti-SAE1	Chest CT with round glass changes with traction of the airways	none (waiting on tests)	died (ILD)

									just patchy and geographical and worse at the bases (not NSIP pattern, could be CTD-ILD)		
Female, (50-54)	not given	nil	3 months before	2 months after, flared	periorbital rash, also in upper arm and wrists	n/a	negative	anti-PL7+, anti-Ro52, anti-PSc100	Chest CT with ground glass changes compatible with ILD	cyclophosphamide, steroids, MMF	stable lung disease
Male, (70-74)	white-british	nil	8 months before	not known	none	47	negative	anti-SAE1	Chest CT with mild fibrosis, interstitial changes and subtle sub-pleural abnormalities	none	stable lung disease
Male, (80-84)	not given	nil	1 year and 5 months before	not known	none	68	positive	none	Chest CT with bilateral mainly peripheral and basal fibrosis with ground glass changes and bronchiectasis	none	stable lung disease
Male, (85-89)	white-british	nil	1 year and 8 months before	not known	none	63	negative	anti-PL2, anti-SRP, anti-Mi-2-alpha	Chest CT showing fibrosis, emphysema and true lower lobe bronchiectasis	none	stable lung disease
Male, (50-54)	Pakistani	nil	6 months before	not known	none	136	positive	none	Chest CT showing extensive patchy bilateral ground glass changes, bronchiectasis	steroids, to start nintedanib	progressive lung disease
Male, (70-74)	white-british	nil	1 year before	1 year before	none	116	positive	none	Chest CT showing pulmonary fibrosis and nodules	none	stable lung disease
Male, (55-59)	n/a	nil	1 week before	not known	hemoptysis (self-resolved)	n/a	positive	anti-Ro52	n/a	n/a	n/a
Female, (70-74)	n/a	nil	1 year and 8 months before	not known	raynaud, synovitis, rashes	n/a	positive	anti-PMScl100 and anti-PMScl70	Chest CT with usual UIP	MTX	stable lung disease
Male, (30-34)	n/a	nil	not vaccinated	5 days before	mild synovitis, stiffness and weakness with power reduced in lower limbs and some	27	positive	none	Chest CT scan 2 months prior to admission demonstrated bilateral peripheral ground glass change in both lungs. In admission progression of changes compatible	steroids, cyclophosphamide, rituximab, tofacitinib, plasma exchange	initial partial response but than progressive disease and died

					breathlessness, rash				with rapid progressive ILD.		
Male, (70-74)	n/a	nil	1 year and 10 months before	not known	none	206	positive	none	CT with non-typical ILD findings	none	stable lung disease
ILD = Interstitial Lung Disease; CK = Creatin-Kinase; ANA IIF = Anti-Nuclear Antibodies Indirect ImmunoFluorescence; N/A = Not Available; CT = Computer Tomography scan; CTD = connective tissue disease; UIP = Usual Interstitial Pneumonia IV = Intra-Venous; MMF = Mophetyl Mychophenolate; MTX = Methotrexate, HCQ = HydroxyChloroQuine; IVIg = IV Immunoglobulins; not known for COVID-19 infection status considered when not tested											

660

661

662 Supplemental Table 2: Characteristics of Non-ILD patients

Gender, age (age range)	ethnicity	past history of autoimmunity	COVID-19 vaccine status	COVID-19 infection before (how long)	Non-clinical ILD features	Baseline CK	ANA IIF	Other myositis Ab	Relevant Imaging	Treatment	Treatment outcome
Female, (35-39)	any other Asian	nil	1 month after, no flare	not known	Symmetrical proximal myositis, gottrons's papules, photosensitivity, inflammatory arthritis	123	positive	none	proximal myositis in femur MRI	prednisolone, MTX	partial response
Male, (45-49)	white-British	nil	1 year and 9 months after, cutaneous flare	11 months after, no flare	overlap connective tissue disease with dermatomyositis and systemic sclerosis (Raynaud's, synovitis, cutaneous ulcers, dermatomyositis rash and mouth ulcer)	89	negative	none, but SCL70	n/a	rituximab, HCO, MMF, PPI	improvement
Male, (50-54)	any other Asian	nil	1 year after, no flare	11 months before	right tight myositis	33	negative	AntiRO52, antiIOJ, anti-PL7, Anti-PM-Scl75, anti-KU, Anti SAE1, anti NXP2, anti-TIF1, anti MI-2 alpha	MRI and US thigh normal muscle appearance	none	total improvement
Female, (80-84)	white-British	nil	1 week after, flare? Trigger?	not known	Raynaud, non-myositis	126	positive	none	none	nifedipine	improvement
Female, (50-54)	white-Irish	nil	5 months before	not known	proximal myopathy	280	positive	none	Thigh MRI compatible with myositis	MMF, prednisolone, rituximab	improvement
Male, (45-49)	white-British	sarcoidosis?	2 months after, no flare	not known	Raynaud, periungal changes, non-myositis	481	negative	anti-SAE1	none	none	stable

Female, (55-59)	white-British	nil	3 months before	not known	Raynaud, synovitis	66	positive	anti-Ro52	none	nifedipine	progression
Female, (75-79)	white-British	nil	3 months before	2 months before	neck pain, progressive breathlessness	220	positive	anti-PMScl100	Chest CT with no ILD, no evidence of myositis in neck MRI	none	stable
Female, (25-29)	N/A	nil	6 days before	not known	Raynaud	62	positive	none	none	none	stable
Female, (40-44)	black-Caribbean	nil	not vaccinated	not known	inflammatory arthritis, Raynaud, two miscarriages (APL negatives)	63	negative	anti-Ro52, anti-PL7, anti PSc100	none	MTX, steroids, HCO, azathioprine	no response
Male, (70-74)	N/A	nil	1 year and 6 months before	not known	haemoptysis and haematuria	n/a	positive	anti-PL7, anti SAE1, anti-ku, anti NXP2, anti-Ro52	Chest CT with no ILD	none	improvement
Female, (35-39)	Pakistani	SLE	2 years and 5 months after, no flare	2 years and 10 months after, no flare	nail fold abnormalities, leukopenia, panniculitis, malar rash, heliotrope rash, digital maculopathy, myositis	33	negative	none	signs of myositis in MRI of proximal inferior limbs	prednisolone, HCO, MMF and 1 cycle rituximab	partial response
Male, (5-9)	white-British	nil	not vaccinated	not known	sore gums, mouth ulcers, gottrons's papules, polyarthritis, fever, mild weakness on legs	211	negative	anti-Ro52	MRI thighs with widespread patchy muscle oedema	IV methylprednisolone, MMF, MTX	no response
Female, (70-74)	white-British	amyopathic dermatomyositis anti-MDA5- but antiRo52 and Anti-iku +	5 days after	2 weeks before, Trigger?	calcinosis, dermatomyositis cutaneous changes (not specified)	174	positive	anti-Ro52, anti-NPX2	MRI thigh normal, pulmonary function test normal	oral steroids, MTX	stable
Female, (10-14)	black-African	Sjogren syndrome	not vaccinated	not known	synovitis, sicca syndrome, weak proximal limbs	115	positive	anti-Ro52 (was + in 2018, MDA5 was -)	MRI compatible with myositis	MTX, MMP, HCO, rituximab	partial response
Female, (10-14)	not given	nil	not vaccinated	not known	malaise, léthargie, joint pains, Raynaud	25	negative	anti-PMScl75,	none	none	improvement

Male, (85-89)	white-British	nil	8 months before	not known	dysphagia	n/a	positive	anti-Mi2-beta, anti-Mi-2-alpha	n/a	n/a	n/a
Male, (50-54)	white-British	nil	7 months before	not known	hyperkeratosis	38	negative	none	n/a	n/a	died
Female, (35-39)	white-black African	nil	4 months before	7 months before	Raynaud's phenomenon with Dermatomyositis like skin rash, mechanic hands, inflammatory joint pain, chronic fatigue	76	positive	none	none	methylphenidate	stable
Female, (35-39)	white-British	lupus	7 months before	not known	Periungal inflammation, proximal weakness	221	positive	anti-Ro52	n/a	MTX, HCQ, thalidomide, rituximab, iloprost, tacrolimus	no response
Female, (65-69)	white-British	nil	8 months before	10 months after, no flare	Inflammatory arthritis, clubbing, oesophageal dysmotility, Raynaud	29	negative	none	Chest CT with no evidence of ILD, achalasia on chest CT	Rituximab, MTX, prednisolone, HCQ	no response
Male, (65-69)	white-British	nil	3 months after, no flare	1 month after, flared	Mild proximal weakness, inflammatory arthritis, lymphopaenia	350	negative	anti-SAE1	none	MTX, prednisolone, nifedipine	improvement
Female, (40-44)	white-British	nil	4 months before	not known	Raynaud	n/a	positive	none	n/a	n/a	n/a
Male, (45-49)	white-British	nil	1 month before	not known	inflammatory arthritis and weight loss	n/a	positive	anti-SAE1	n/a	n/a	n/a
Female, (35-39)	N/A	nil	not vaccinated	not known	Raynaud	n/a	negative	none	n/a	n/a	n/a
Female, (60-64)	N/A	nil	1 year and 4 months before	not known	Raynaud	76	positive	anti-PMScl75, anti-NXP2,	none	none	stable
Female, (70-74)	any other Asian	Hypothyroidism?	1 year and 4 months before	not known	Myositis, myocardial involvement, toe	36	negative	anti-Mi2-alpha	echo EF < 30%, MRI with myositis features (thigh)	prednisolone, MMF, rituximab	stable

					ulceration and Raynaud						
Female, (60-64)	white-British	nil	1 year and 4 months before	not known	Raynaud	388	positive	antiPL7	normal EMG, normal chest CT, normal MRI thigh	none	improvement
Female, (25-29)	"other ethnic group"	crohn's disease, HS	not vaccinated	not known	Raynaud, puffy fingers, pitting scars	81	positive	anti-PMScI75	early scleroderma on capillaroscopy, normal pulmonary function	nifedipine	progression
Female, (45-49)	white-British	nil	1 year and 6 months before	not known	Raynaud	121	positive	none	US of shoulder with degenerative changes	none	stable
Female, (55-59)	white-British	nil	4 months before	not known	MCTD symptoms	n/a	positive	anti-mibeta2, anti-PMScI75	n/a	n/a	n/a
Male, (55-59)	n/a	nil	1 year and 9 months before	not known	proximal myopathy, rashes, sicca syndrome, synovitis, Raynaud.	normal	positive	anti-RS, Anti-OJ, Anti-PL7, anti-EJ, Anti-Ku, Anti-NXP2, Anti-MRIFgamma2, Anti-Ro52	n/a	none	stable
Female, (60-64)	black-Caribbean	nil	7 months before	not known	myopathy, transient raised CK	1715	positive	none	no fatty atrophy or active myositis on imaging	observation/none	improvement
Male, (60-64)	white-British	nil	1 month before	not known	myositis	11000	negative	none	myositis on MRI thighs biopsy suggestive of statin myositis HMGCoA Ab+	prednisolone and MTX	improvement
Female, (80-84)	"other ethnic group"	PMR	8 months before	not known	myositis	22000	positive	OJ Ab, EJ Ab, MPL122, PL-7, Ku,MTIFG2	CT with no ILD	none	improvement
Female, (75-79)	white-Irish	nil	10 months before	not known	myositis and synovitis	55	negative	none	CT with no ILD	prednisone	improvement
ILD = Interstitial Lung Disease; CK = Creatin-Kinase; ANA IIF = Anti-Nuclear Antibodies Indirect Immunofluorescence; N/A = Not Available; CT = Computer Tomography scan; MRI = magnetic resonance imaging; US (ultrasound); IV = Intra-Venous; MMF = Mophetyl Mychophenolate; MTX = Methotrexate, HCQ = HydroxyChloroQuine; PPI = proton pump inhibitors; not known for COVID-19 infection status considered when not tested											

663
664