

A COMPREHENSIVE STUDY OF GPT-4V'S MULTIMODAL CAPABILITIES IN MEDICAL IMAGING

Yingshu Li^{1*}, Yunyi Liu^{1*}, Zhanyu Wang^{1,4*}, Xinyu Liang⁵, Lingqiao Liu³, Lei Wang²,
Leyang Cui⁴, Zhaopeng Tu⁴, Longyue Wang^{4†}, Luping Zhou¹

¹The University of Sydney ²The University of Wollongong

³The University of Adelaide ⁴Tencent AI Lab

⁵Guangzhou University of Chinese Medicine

ABSTRACT

This paper presents a comprehensive evaluation of GPT-4V's capabilities across diverse medical imaging tasks, including Radiology Report Generation, Medical Visual Question Answering (VQA), and Visual Grounding. While prior efforts have explored GPT-4V's performance in medical imaging, to the best of our knowledge, our study represents the first quantitative evaluation on publicly available benchmarks. Our findings highlight GPT-4V's potential in generating descriptive reports for chest X-ray images, particularly when guided by well-structured prompts. However, its performance on the MIMIC-CXR dataset benchmark reveals areas for improvement in certain evaluation metrics, such as CIDEr. In the domain of Medical VQA, GPT-4V demonstrates proficiency in distinguishing between question types but falls short of prevailing benchmarks in terms of accuracy. Furthermore, our analysis finds the limitations of conventional evaluation metrics like the BLEU score, advocating for the development of more semantically robust assessment methods. In the field of Visual Grounding, GPT-4V exhibits preliminary promise in recognizing bounding boxes, but its precision is lacking, especially in identifying specific medical organs and signs. Our evaluation underscores the significant potential of GPT-4V in the medical imaging domain, while also emphasizing the need for targeted refinements to fully unlock its capabilities.

1 INTRODUCTION

Large Language Models (LLMs) have consistently demonstrated remarkable prowess across various domains and tasks (Touvron et al., 2023; OpenAI, 2023; Anil et al., 2023). The ongoing pursuit of enhancing LLMs' capacity for visual comprehension has spurred the emergence of a new research area: Large Multimodal Models (LMMs) (Ye et al., 2023; Li et al., 2023b; Awadalla et al., 2023). The basic approach has been to either fine-tune the visual encoder to align with a fixed pre-trained LLM or to use a vision-language model to convert visual input into textual descriptions that can be understood by the LLM. These applications are all based solely on the use of the LLM and do not really explore the visual capabilities of the LLM. GPT-4V, a cutting-edge Large Multimodal Model (LMM) incorporating visual understanding capabilities, is constructed as an evolution of state-of-the-art Large Language Models (LLMs). This model is trained on an extensive corpus of multimodal data. Yang et al. conducted a comprehensive case study to assess GPT-4V's performance in general-purpose scenarios, revealing its robust visual comprehension ability (Yang et al.,

*Equal Contribution

†Corresponding Author (vinnyliwang@tencent.com)

2023b). Moreover, LMMs have been widely used in the medical field (Wang et al., 2023b; Singhal et al., 2023). The introduction of visual capabilities into GPT-4V opens up opportunities for an in-depth examination of its potential in the domain of medical multimodality. So this paper will evaluate the main image, and multi-modal tasks in the medical imaging field based on GPT-4V.

The main contribution of this paper is to explore the capabilities of GPT-4V on medical image analysis. We selected the 3 main medical multimodal tasks, **Radiology Report Generation**, **Medical Visual Question Answering**, and **Medical Visual Grounding**, to assess GPT-4V’s performance in the context of medical images. Our evaluation encompassed *standard benchmarks* and comparative analysis against current state-of-the-art models. Furthermore, we conducted in-depth case studies using representative examples for each task, enhancing our comprehension of GPT-4V’s capabilities in medical image understanding.

2 RELATED WORK

2.1 RADIOLOGY REPORT GENERATION

Radiology report generation has emerged as a prominent research area within the domain of medical image analysis in recent years. While similar to image captioning (Vinyals et al., 2015; Xu et al., 2015; Pan et al., 2020), this task presents heightened complexity due to the extended length of medical reports and the increased difficulty in identifying medical anomalies within images, due to data imbalance issues. Numerous research has relied on encoder-decoder architectures to address this task. The research can be grouped into two primary research directions. The first direction concentrates on enhancing the model’s architecture to facilitate improved extraction of visual features and the generation of high-quality medical reports. For example, Li et al. used a hierarchical architecture to generate reports with normality and abnormality respectively (Li et al., 2018). Similarly, Liu et al. employed a hierarchical structure to initially generate topics and subsequently produce related sentences (Liu et al., 2019). With the prevailing of the transformer (Vaswani et al., 2017), Chen et al. introduced a transformer-based model, enhancing it with relational memory and memory-driven conditional layer normalization to enhance image feature recognition and capture crucial report patterns (Chen et al., 2020). Another research direction is to solve the data bias problem by incorporating external knowledge information. Zhang et al. constructed a predefined medical knowledge graph to augment the model’s ability to capture valuable medical information (Zhang et al., 2020). To further enrich this supplementary knowledge, Li et al. developed a dynamic approach that enables real-time updates to the knowledge graph (Li et al., 2023c).

Furthermore, in recent times, there has been a surge in radiology report generation methods leveraging Large Language Models (LLMs). These approaches leverage the capabilities of large language models to generate long-text content and utilize abundant knowledge sources to enhance the quality of radiology reports. Wang et al. employs Llama2 to elevate the quality of the generated reports. To achieve effective image-text alignment, the image embeddings are mapped to the feature space of the Llama2 (Touvron et al., 2023) via a visual mapper to ensure uniform dimensionality (Wang et al., 2023b).

2.2 VISUAL QUESTION ANSWERING

Visual Question Answering (VQA) (Jiang et al., 2020; Wu et al., 2019) has solidified its stature as a paramount domain, striving to empower machines to decipher visual content and respond to pertinent natural language inquiries. Given a pair comprising an input image and a correlated question, the VQA model is engineered to generate the corresponding answer. A plethora of previous scholarly works have delved into VQA, revealing four critical components within these models: the image encoder, the text encoder, a fusion method, and either a generator or a classifier, contingent upon the model’s architectural design. The nature of the posed questions bifurcates into two categories based on the answer type: the close-end type (Nguyen et al., 2019; Finn et al., 2017; Eslami et al., 2021) and the open-end (Ambati & Dudyala,

2018; Khare et al., 2021) type. Predominantly, models address these two categories distinctly; they typically employ a classification-based approach for close-end types, whereas for open-end types, a generation-based method is utilized. Nevertheless, a select number of studies have attempted to integrate both question types within a singular model (Ren & Zhou, 2020). A notable example is the Q2ATransformer (Liu et al., 2023), which simultaneously tackles both varieties of questions, amalgamating the strengths of classification-based and generation-based methodologies, and subsequently achieving exemplary accuracy across both question types.

With the emergence of Large Language Models (LLMs), there has been a substantial influx of research leveraging LLMs to augment the linguistic inferencing capabilities of VQA (Li et al., 2023a). Moreover, certain studies have pioneered the use of LLMs for facilitating continuous questioning in VQA. The introduction of models such as GPT-3.5 has led to the generation of more LLM-based datasets, mitigating the issue of data scarcity (Pellegrini et al., 2023). The advent of GPT-4V marks a significant milestone, as it incorporates image comprehension capabilities directly into the LLM framework. This eliminates the need for VQA systems to translate all tasks into a language understandable by traditional LLMs. With the ability to process multimodal inputs seamlessly, the evolution of LLMs has opened new horizons for research and development in VQA. This paper endeavors to elucidate the application of GPT-4V in the realm of medical image-based VQA, exploring its potential and implications in this specialized field.

2.3 VISUAL GROUNDING

Visual grounding (Kamath et al., 2021) stands as a pivotal field at the crossroads of computer vision and natural language processing. Essentially, this task requires interpreting an image while taking into account a relevant textual description of an object, which could range from a single sentence or caption to a more elaborate description. The end goal is to produce a bounding box that accurately outlines the designated object. Given its critical role in integrating visual and textual information, visual grounding has established itself as a crucial application in the realm of multimodal interactions.

With the emergence of extensive language modeling, there has been a noteworthy blend of visual grounding techniques with Large Language Models (LLMs) (Peng et al., 2023; Zhao et al., 2023). In a conventional setup, data from bounding boxes, obtained through visual grounding, is fed into the LLM as a segment of the prompt. This approach steers the LLM towards making the right assessments. However, the debut of GPT-4V marks a significant transformation in this workflow. It eliminates the requirement for crafting prompts manually, allowing users to directly input images and text, and in turn, directly obtain the related bounding box outputs. This advancement simplifies the process, removing the need for extra steps and intermediaries.

The majority of visual grounding research primarily centers on general imagery, with scant attention paid to the realm of medical images. This disparity could stem from a noticeable dearth of datasets specifically tailored for medical visual grounding. The MS-CXR dataset, a recent published visual grounding dataset, makes some improvement of medical image visual grounding application, some publications (Huang et al., 2023; Sun et al., 2023a;b) comes out base on it. Nevertheless, even as this dataset becomes more widely recognized, there remains a limited body of academic work exploring its potential and applications, highlighting a crucial area for future research and development.

In this paper, we will embark on a comprehensive review of GPT-4V's applications within the domain of medical visual grounding, exploring its capabilities, impact, and potential avenues for future research and development.

3 RADIOLOGY REPORT GENERATION

The exponential growth of radiological imaging data has imposed an escalating burden on radiologists, leading to a heightened risk of diagnostic errors with potentially severe consequences. Consequently, there is a growing demand for automated radiology report generation, which is anticipated to alleviate the workload of radiologists and mitigate diagnostic inaccuracies. The rapid advancements in artificial intelligence, particularly in the domains of computer vision and natural language processing, have made automated medical report generation a feasible reality (e.g., Chen et al., 2020; 2021; Liu et al., 2021; Wang et al., 2023a). A prominent challenge in automated medical report generation is long text generation. Presently, large language models (LLMs) (e.g., Touvron et al., 2023; Chowdhery et al., 2022) have gained widespread prominence and demonstrate a strong proficiency in generating long text. Furthermore, LLM-based large multi-modal models (LMMs) (e.g., Zhu et al., 2023; Wu et al., 2023) possess a notable capability for multi-modal content generation. While LMMs show potential in multi-modal content generation, their efficacy in specialized tasks like radiology report generation is yet to be fully explored. The accuracy and reliability of such reports are paramount, making it crucial to evaluate LMMs in this domain rigorously. In the following sections, we examined the GPT-4V’s capability for generating radiology reports using distinct prompt strategies and the dataset.

3.1 EVALUATION

This section presents an evaluation of the GPT-4V model’s capacity for medical report generation. We employ the MIMIC-CXR dataset (Johnson et al., 2019) for assessment. The model is tasked with generating diagnostic reports for given medical images. To facilitate comparison with established methodologies (e.g., Chen et al., 2020; Yang et al., 2021a; Liu et al., 2021; Wang et al., 2022b; 2023a), we employ widely recognized metrics, specifically BLEU scores (Papineni et al., 2002), ROUGE-L (Lin, 2004), METEOR (Banerjee & Lavie, 2005), and CIDEr (Vedantam et al., 2015), to gauge the quality of the generated reports.

Our evaluation focuses on the model’s performance with the MIMIC-CXR testset. Each evaluation instance comprises a single medical image coupled with a carefully crafted text prompt as the input.

3.1.1 DATASET: MIMIC-CXR

MIMIC-CXR, the largest publicly available dataset in this domain, includes both chest radiographs and unstructured textual reports. This dataset comprises a total of 377,110 chest X-ray images and 227,835 corresponding reports, obtained from 64,588 patients who underwent examinations at the Beth Israel Deaconess Medical Center between 2011 and 2016. To facilitate fair and consistent comparisons, we followed the official partitioning provided by MIMIC-CXR, resulting in a test set containing 3,858 samples.

3.1.2 PROMPT DESIGN STRATEGIES FOR EVALUATION

To better activate the capabilities of the GPT-4V, we explored different prompt design strategies, including zero-shot and few-shot approaches. In the **zero-shot** scenario, we provided examples without reference reports, while in the few-shot way, we explored three different prompt settings: (1) two normal reports (**Few-shot normal examples prompt**), (2) two abnormal reports (**Few-shot abnormal examples prompt**), and (3) one normal report paired with one abnormal report (**Few-shot mixed examples prompt**). Our extensive evaluation of these prompt strategies unveiled that the inclusion of both a normal and an abnormal example consistently led to the generation of higher-quality reports. Consequently, we employed prompts with one normal and one abnormal example (**Few-shot mixed examples prompt**) to evaluate GPT-4V on MIMIC-CXR benchmark.

3.1.3 OVERVIEW OF PROMPT METHODS

Our primary objective is to evaluate the baseline performance of GPT-4V in medical report generation. Consequently, we focused solely on the **zero-shot prompt** and the **few-shot prompt**, avoiding the use of complex techniques like chain-of-thought (Wei et al., 2022b) or ensembling strategies (Wang et al., 2022a). Illustrative examples of prompt design strategies are provided in Appendix A.1.

This section provides an introduction to the settings of the zero-shot prompt and few-shot prompt, along with a comprehensive description of our prompt definition. A detailed analysis of the GPT-4V's generated reports under various prompts will be presented in Section 3.2.

Zero-shot Prompt Scenario The zero-shot prompt is employed to assess GPT-4V's capacity to autonomously generate reports without external guidance. To facilitate a comprehensive comparison with the Ground Truth report, we tasked GPT-4V with generating both the expression and findings sections.

Few-Shot Prompts Scenario In-context few-shot learning represents a crucial methodology for enhancing the capabilities of large language models (Tsimpoukelli et al., 2021; Wei et al., 2022a; Dai et al., 2022). It enables the model to acquire the necessary output format by providing a set of examples. In contrast to fine-tuning, this method empowers the model to generate desired results without any parameter updating at inference time. We evaluated the in-context few-shot learning capability of GPT-4V using diverse prompt examples. Within the scope of our evaluation, we employ contextual learning to facilitate GPT-4V in generating responses that closely align with the form of ground truth, facilitating meaningful comparisons.

In our investigation of few-shot prompts for the GPT-4V, we conducted experiments with a range of prompt strategies designed for GPT-4V. Specifically, we explored diverse compositions:

- Exclusively using normal examples (**Few-shot normal examples prompt**);
- Exclusively using abnormal examples (**Few-shot abnormal examples prompt**);
- Combining one normal and one abnormal example (**Few-shot mixed examples prompt**);

The details of example reports in prompts are shown in Appendix A.1. Our observations highlighted the substantial impact of prompt type on the model's output. Depending on the chosen prompt, the model displayed a clear preference either for generating normal reports or abnormal reports. Details will be discussed in section 3.2.

3.1.4 COMPARISON WITH SOTA

Table 3 presents a comprehensive performance comparison between the GPT-4V model and state-of-the-art methods using the MIMIC-CXR dataset (Johnson et al., 2019). The methods encompasses standard image captioning techniques, including Show-Tell (Vinyals et al., 2015), Att2in (Xu et al., 2015), AdaAtt (Lu et al., 2017), Transformer (Vaswani et al., 2017), and M2Transformer (Cornia et al., 2020). Additionally, the evaluation methods also have medical report generation methods, specifically R2Gen (Chen et al., 2020), R2GenCMN Chen et al. (2021), MSAT (Wang et al., 2022b), and METransformer (Wang et al., 2023a). To provide fair comparisons, we employ the exact same prompting structure (**Few-shot mixed examples prompt**) to help GPT-4V generate the medical report.

From Table 3, it's clear that medical report generation models such as METransformer, MSAT, and R2Gen showcase top-tier performance. Nevertheless, GPT-4V's capability to generate medical reports is impressive, even if it's a general-purpose model. Leveraging the advantages of an extensive pre-training dataset, it excels in several metrics, including BLEU, ROUGE, and METEOR. However, when compared to models specifically trained on MIMIC-CXR, it exhibits a gap, particularly evident in the CIDEr metric. This discrepancy arises because the CIDEr metric assigns varying score weights to words based on their occurrence

Table 1: Comparison MIMIC-CXR datasets.

Dataset	Methods	BLEU-1	BLEU-2	BLEU-3	BLEU-4	ROUGE	METEOR	CIDEr
MIMIC-CXR	Show-Tell (Vinyals et al., 2015)	0.308	0.190	0.125	0.088	0.256	0.122	0.096
	Att2in (Xu et al., 2015)	0.314	0.198	0.133	0.095	0.264	0.122	0.106
	AdaAtt (Lu et al., 2017)	0.314	0.198	0.132	0.094	0.267	0.128	0.131
	Transformer (Vaswani et al., 2017)	0.316	0.199	0.140	0.092	0.267	0.129	0.134
	M2Transformer (Cornia et al., 2020)	0.332	0.210	0.142	0.101	0.264	0.134	0.142
	R2Gen (Chen et al., 2020)	0.353	0.218	0.145	0.103	0.277	0.142	-
	R2GenCMN (Chen et al., 2021)	0.353	0.218	0.148	0.106	0.278	0.142	-
	PPKED (Liu et al., 2021)	0.360	0.224	0.149	0.106	0.284	0.149	0.237
	GSK (Yang et al., 2021b)	0.363	0.228	0.156	0.115	0.284	-	0.203
	MSAT (Wang et al., 2022b)	0.373	0.235	0.162	0.120	0.282	0.143	0.299
	METransformer (Wang et al., 2023a)	0.386	0.250	0.169	0.124	0.291	0.152	0.362
GPT-4V (OpenAI, 2023)	0.338	0.190	0.109	0.061	0.240	0.125	0.033	

frequencies, potentially limiting GPT-4V’s performance in generating certain MIMIC-CXR-specific words, consequently yielding relatively lower scores.

Furthermore, our testing has revealed that GPT-4V possesses the capacity to generate information that is absent in the ground truth but is visually evident in the image. This phenomenon contributes to GPT-4V’s relatively lower performance on metrics such as BLEU, which primarily assesses word match rates. One example is shown in Figure 1.

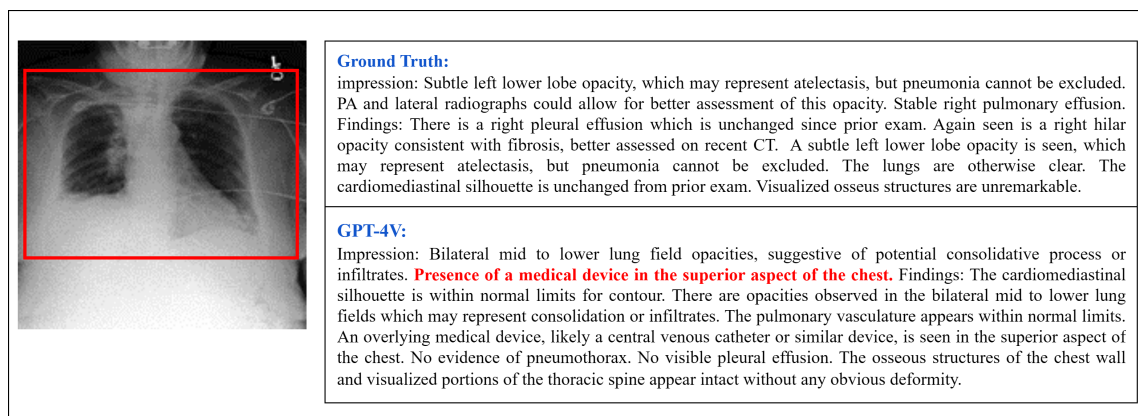


Figure 1: One case with few-shot mixed examples prompt. The ground truth does not reference a medical device; however, one is visibly present in the image and indicated by a red box. GPT-4V demonstrates the ability to recognize this medical device.

3.2 CASE STUDY

3.2.1 ZERO-SHOT BEHAVIOR

In the zero-shot scenario, through a series of tests on multiple chest X-ray images, we observed that GPT-4V consistently generates reports with a focus on various anatomical organs. This phenomenon is illustrated in Figure 11. Notably, GPT-4V tends to follow a specific order, including the information of lung, cardiomedastinal silhouette, bones, diaphragm, and soft tissues, for the majority of the generated reports.

While the format of the generated reports may vary from MIMIC-CXR, the content within these reports does convey both normal and abnormal aspects of the radiographic images. Figure 2 shows a selection of examples. The observations reveal that GPT-4V can describe the normal aspects in the images. Furthermore, as demonstrated in Example 3, GPT-4V exhibits the capacity to recognize abnormalities, '*suggestive of a possible infectious or inflammatory process*'. These instances collectively underscore that, even in the context of Zero-shot prompts, GPT-4V may not replicate the exact report format found in MIMIC-CXR, yet it demonstrates a noteworthy ability to generate relevant reports and identify anomalies.

3.2.2 FEW-SHOT BEHAVIOR

In this prompt scenario, we explored 3 kinds of prompt settings:

- **Few-shot normal examples prompt**
- **Few-shot abnormal examples prompt**
- **Few-shot mixed examples prompt**

In this section, we present a comprehensive analysis of reports generated by GPT-4V under three distinct few-shot prompts. We observe that different prompts significantly influence the generated reports. Specifically, Figure 3 illustrates the response to a normal chest X-ray image, where we employ three distinct prompt methodologies to guide GPT-4V in generating corresponding reports. Interestingly, the reports generated from the normal examples prompt and mixed examples prompt both describe the image as normal. In contrast, the report originating from the abnormal examples prompt highlights anomalies. This indicates that GPT-4V's inclination to generate normal or abnormal reports varies based on the provided example reports.

The analysis of reports generated for an abnormal chest X-ray image can be found in the appendix A.2 with a more detailed explanation. However, it's worth noting here that our subsequent tests have shown that the mixed examples prompt (illustrated in figure 3, 14) has a significant influence on GPT-4V's capacity to accurately determine the normalcy or abnormality of an image. Due to this observed consistency and reliability, we opted for the mixed examples prompt when testing the entire MIMIC-CXR test set and in the computation of related evaluation metrics.

For these examples, we can know summarize the impact of different prompts on the generated reports as follows:

Normal Examples Prompt The generated report focuses on the normal aspects of the image, seemingly overlooking or not emphasizing the abnormalities present. This could be attributed to the inherent bias introduced by the normal examples in the prompt, steering the GPT-4V's focus towards more routine or standard interpretations.

Abnormal Examples Prompt As expected, the report provides a clear and distinct description of the abnormalities evident in the X-ray. However, for normal chest X-ray radiographs, the GPT-4V may also exhibit a heightened probability of generating certain erroneous indications of abnormality.

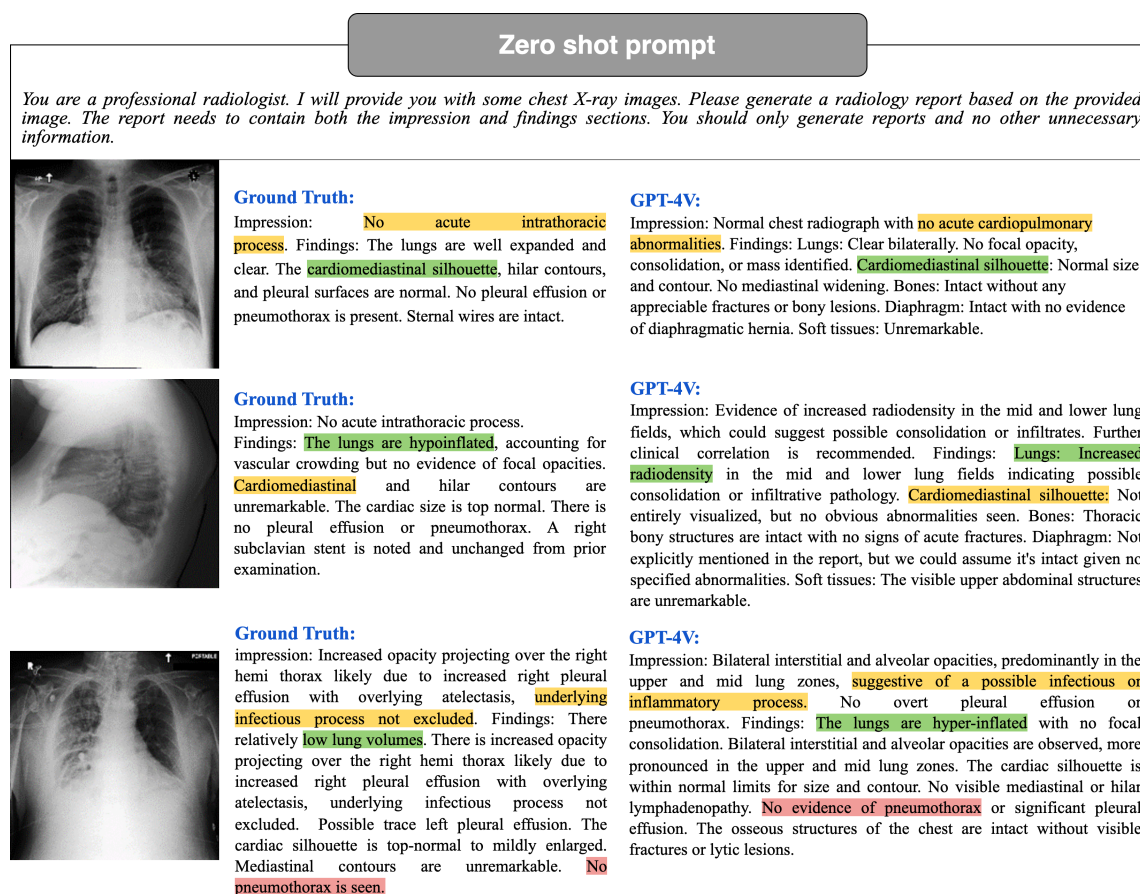


Figure 2: Zero-shot prompt example. GPT-4V can generate radiology reports without example reports and can convey both normal and abnormal aspects. For better illustration, the key medical information in the reports is highlighted using different colors.


Mixed Examples Prompt The mixed examples prompt leads the GPT-4V to accurately describe the abnormal and normal conditions of the image. This suggests a balanced effect, where the GPT-4V doesn't get overly biased by either the normal or abnormal examples but leverages both to arrive at an accurate interpretation.

From this in-depth examination, it becomes evident that the choice of prompt plays a pivotal role in guiding GPT-4V's performance, especially when anomalies are present in medical images. The mixed examples prompt, in particular, shows promise in achieving a balanced and accurate report, making it a potential choice for diverse medical scenarios.

3.2.3 PROMPT AUGMENTATION FOR OUTPUT VIEW INFORMATION

Additionally, our investigations revealed that augmenting the information content within a given prompt enables GPT-4V to produce more pertinent information in its generated reports. As an illustrative example,

Normal Case

<p>Text-Prompt:</p> <p><i>You are a professional radiologist. I will provide you with some chest X-ray images. Please generate a radiology report based on the provided image. You should only generate reports and no other unnecessary information. The format of the output report should be similar to the example:</i></p> <p><i>Examples:</i> =====</p> <p><i>Example 1</i></p> <p><i>Example 2</i></p>	<p>Image:</p> 
--	--

Ground Truth:
Impression: No acute intrathoracic process.
Findings: The lungs are well expanded and clear. **The cardiomeastinal silhouette**, hilar contours, and pleural surfaces are normal. **No pleural effusion or pneumothorax is present.** Sternal wires are intact.

Few-shot mixed examples prompt:
Impression: Normal cardiopulmonary findings with no acute abnormalities. Findings: Frontal view of the chest demonstrates clear lung fields without focal consolidations, masses, or opacities. **The cardiomeastinal silhouette** and pulmonary vasculature are within normal limits. Both hemidiaphragms are intact with no evidence of elevation. **There is no visible pneumothorax, pleural effusion, or significant lymphadenopathy.** The bony thoracic structures appear intact without any evident pathological changes.

Few-shot normal examples prompt:
Impression: No acute cardiopulmonary abnormalities noted. Findings: **The lungs are clear without any evidence of consolidation, pleural effusion, or pneumothorax.** **The cardiomeastinal silhouette is within normal limits.** There is no evidence of pulmonary nodules or masses. No significant bony abnormalities are noted in the imaged portions of the chest. The imaged upper abdomen appears unremarkable.

Few-shot abnormal examples prompt:
Impression: **Increased opacity in the left lower lung zone, consistent with consolidation or infiltrate, which may suggest pneumonia. Mediastinal and cardiac contours are within normal limits.** Findings: PA view of the chest demonstrates an increased opacity in the left lower lung zone, which may be secondary to consolidation or infiltrate. The lungs are otherwise well aerated. **No evidence of pneumothorax or pleural effusion.** The mediastinal and cardiac contours appear within normal limits. No visible pulmonary nodules or masses. No evidence of mediastinal widening or adenopathy. The bony thorax and soft tissues appear unremarkable.

Figure 3: Few-shot normal case (The key medical information in the reports is highlighted using different colors). GPT-4V is more likely to generate abnormal reports when the prompt includes two abnormal examples. The words in red correspond to descriptions of abnormal conditions.

we incorporated instances with view information for chest X-ray images within both the few-shot mixed examples prompt and the few-shot abnormal Examples prompt. Conversely, view information was omitted in the few-shot normal examples prompt. This deliberate contrast in prompt content demonstrated that prompts containing view information effectively instructed GPT-4V to incorporate considerations of image viewpoint into the report generation process.

More specifically, we supplemented the few-shot mixed examples prompt and the few-shots abnormal examples prompt with the following view information:

- Frontal and lateral views of the chest;
- PA and lateral views of the chest provided.

Preprint (work in progress)

As illustrated in Figure 4,15 the inclusion of view information prompts GPT-4V to incorporate corresponding viewpoint details into the generated report. For instance, it generates phrases like 'PA view of the chest provided' and 'Frontal view of the chest demonstrates...'. However, it is essential to acknowledge that while enhancing the prompt with view information empowers GPT-4V to produce reports enriched with these details, there are instances where GPT-4V inaccurately identifies viewpoint information. The incorrect case is shown in Appendix A.3.

Viewpoints information case 1

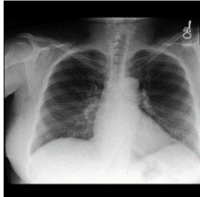
<p>Text-Prompt:</p> <div style="border: 1px solid black; padding: 5px; margin-bottom: 10px;"><p><i>You are a professional radiologist. I will provide you with some chest X-ray images. Please generate a radiology report based on the provided image. You should only generate reports and no other unnecessary information. The format of the output report should be similar to the example:</i></p><p><i>Examples:</i> =====</p><p><i>Example 1</i></p><p><i>Example 2</i></p></div> <p>Ground Truth: Impression: No acute cardiopulmonary abnormality. No acute fracture identified. If there is continued clinical concern for a rib fracture, a dedicated rib series is suggested. Findings: Heart size is normal. The mediastinal and hilar contours are normal. The pulmonary vasculature is normal. Lungs are clear. No pleural effusion or pneumothorax is seen. There are no acute osseous abnormalities.</p> <p>Few-shot mixed examples prompt: Impression: No acute pulmonary abnormality. Findings: Frontal view of the chest demonstrates clear lungs with no focal consolidation, mass, or nodular opacity. The heart size is normal, and the cardiomeastinal silhouette is unremarkable. No evidence of pneumothorax, pleural effusion, or significant mediastinal widening. The pulmonary vasculature is normal. Both hemidiaphragms and the costophrenic angles appear intact. No osseous abnormalities seen.</p> <p>Few-shot normal examples prompt: Impression: No acute cardiopulmonary abnormalities detected. Findings: The lungs are clear without focal consolidation. There is no evidence of pleural effusion or pneumothorax. The cardiomeastinal silhouette is within normal limits. No visible nodular opacities suggesting no overt masses. The imaged upper abdomen does not show any abnormalities. No evidence of rib fractures or deformities in the visible sections.</p> <p>Few-shot abnormal examples prompt: Impression: Normal cardiomeastinal silhouette. Lungs are clear. No acute osseous findings. Findings: PA view of the chest provided. The cardiomeastinal silhouette is within normal limits. The lungs are clear bilaterally with no evidence of focal consolidation, pleural effusion, or pneumothorax. There is no significant hilar adenopathy. The bony structures of the chest wall appear intact. The diaphragmatic contours are smooth and uninterrupted. No evidence of significant osseous abnormalities.</p>	<p>Image:</p> 
--	--

Figure 4: Viewpoint information Case 1 (The key medical information in the reports is highlighted using different colors). The inclusion of view information in the prompt results in a higher probability of GPT-4V generating view information, indicated in red text in the figure. Notably, GPT-4V does not generate view information when the prompt lacks such information, as seen in the normal examples prompt (in Figure 13).

This phenomenon can be attributed to two primary factors: firstly, potential constraints in GPT-4V's inherent recognition capabilities, and secondly, the potential inadequacy of prompt design in fully activating GPT-4V's ability to discern viewpoint information.

Preprint (work in progress)

It is imperative to emphasize that, even with the incorporation of view information, the core content within the generated reports exhibits a high degree of consistency (crucial medical information in the reports is distinguished using diverse colours in Figure 4). This observation leads to a significant conclusion: the inclusion of supplementary information within the prompt broadens the spectrum of content integrated into the generated report, all while preserving GPT-4V's capability to fulfill common tasks.

These examples vividly illustrate the critical role of prompt design within the domain of in-context few-shot learning. In contrast to the fine-tuning approach, few-shot learning empowers GPT-4V to gain essential knowledge from the prompt and subsequently apply this knowledge in generative tasks. Consequently, the meticulous design of a logical and effective prompt emerges as a pivotal factor when leveraging GPT-4V for medical report generation tasks. This aspect of prompt design deserves future studies.

3.3 DISCUSSION

Our extensive evaluation and case study of GPT-4V's capabilities in Radiology Report Generation reveal its potential as well as its current limitations. By employing various prompts, GPT-4V demonstrates the capacity to generate descriptive reports for chest X-ray images, covering both normal and abnormal aspects. Remarkably, the design of the prompt significantly influences GPT-4V's performance; prompts with more information lead to greater attention to the image and the generation of more detailed descriptions.

It is essential to highlight that GPT-4V was not trained specifically on MIMIC-CXR, which impacts its capacity to generate specific rare words, leading to relatively lower scores on commonly used evaluation metrics. Nevertheless, GPT-4V demonstrates the ability to generate content related to images that is not explicitly mentioned in the Ground Truth but is visually apparent. As a result, further research aimed at improving GPT-4V's report accuracy remains a valuable pursuit.

4 MEDICAL VISUAL QUESTION ANSWERING

Visual Question Answering (VQA) has become a much critical research area. The goal of VQA systems is to enable computers to understand natural language questions and provide accurate answers on images. In the following, we will explore the medical image VQA performance of GPT-4V on the VQA-RAD dataset and compare it with the current SOTA method.

4.1 EVALUATION

In order to assess GPT-4V's effectiveness on the Medical VQA dataset, we embarked on a comprehensive series of experiments. Utilizing the GPT-4V model, we applied it to generate predicted answers based on the input medical image and the question related to this image. Then, proceeded to calculate the accuracy of the results. Subsequently, we conducted a comparative analysis with the current state-of-the-art (SOTA) methods. Herein, we present our principal observations and conclusions.

4.1.1 DATASET: VQA-RAD

VQA-RAD (Lau et al., 2018) is one of the most widely utilized radiology datasets. It comprises 315 images along with 3515 question-answer pairs, ensuring that each image corresponds to at least one question-answer pair. The questions encompass 11 distinct categories, including "anomalies," "properties," "color," "number," "morphology," "organ type," "other," and "section." A noteworthy 58% of these questions are designed as closed-ended queries, while the remainder take the form of open-ended inquiries. These images predominantly feature the head, chest, and abdomen regions of the human body. It is essential to manually partition the dataset into training and test sets for accurate evaluation.

Preprint (work in progress)

4.1.2 OVERVIEW OF PROMPT METHODS

GPT-4V not only possesses powerful natural language processing capabilities, but also incorporates advanced computer vision techniques, which makes it excel in handling fusion tasks of images and text. It is trained to understand questions and extract information from images to generate accurate answers. However, the performance of GPT also depends on how the design of the prompt.

To ensure that GPT-4V accurately grasps the answer style of the VQA-RAD dataset, we provided seven examples to guide the model in generating responses consistent with the dataset's format. Without these examples, GPT-4V tends to produce more unconstrained answer text, complicating the task of comparing predicted answers with the ground truth.

We Designed the prompt by following the template in Figure 5:

VQA Prompt

Input an X-ray image along with a question related to that image. Questions can fall into one of two categories: closed-ended or open-ended.

Closed-ended questions require a "Yes" or "No" response.
Open-ended questions require an answer that may consist of a single word or a sentence, providing a more detailed explanation.

Based on the X-ray image and the accompanying question, determine whether the question is closed-ended or open-ended and provide an appropriate response.

Examples

Closed-ended Question
question: Is subcutaneous air present in the right side of the neck?
answer: Yes

question: Is there evidence of metastatic tissue on organs surrounding the liver?
answer: no

Open-ended Question
question: Describe the pathology visible in the image.
answer: Cardiomegaly with pulmonary edema.

question: What is the vascular distribution of these infarcts?
answer: all three vascular distributions

question: How large is the mass?
answer: 5mm

question: What modality is used in this image?
answer: CT

question: How many kidneys are visualizable in this image?
answer: 2

Please directly provide the answer to the question without any additional explanations or information.

question: **{{question}}**

Figure 5: VQA Prompt Method. Elements in double braces are replaced with specific questions

4.1.3 COMPARISON WITH SOTA

Upon scrutinizing the results of GPT-4V on the VQA-RAD dataset's test set, it is calculated that the accuracy for closed-end questions is 61.4%, the result shows in table2, which is significantly lower than other

Table 2: Visual Question Answering Method Comparison

Dataset	Reference Methods	Fusion Method	Close-end
VQA-RAD	StAn (He et al., 2020)	SAN	57.2
	BiAn (He et al., 2020)	BAN	67.9
	MAML (Finn et al., 2017)	SAN	69.7
		BAN	72.4
	MEVF (Nguyen et al., 2019)	SAN	74.1
		BAN	75.1
	MMQ (Do et al., 2021)	SAN	75.7
		BAN	75.8
	PubMedCLIP (Eslami et al., 2021)	-	80
	MMBERT (Khare et al., 2021)	-	77.9
Q2ATransformer (Liu et al., 2023)	-	81.2	
GPT-4V (OpenAI, 2023)	-	61.40	

published results. In terms of open-end questions, the calculated BLEU score is 0.1155, which also does not reach a high standard. The majority of currently available research primarily employs classification based model to tackle Visual Question Answering (VQA) problems. This approach results in a lack of evaluations using the BLEU score, making it challenging to draw comparisons between different methods. However, upon analyzing the cases provided by GPT-4V, it is postulated that the low BLEU score may be attributed to the excessive flexibility of GPT-4V, resulting in substantial deviations from the correct answers. This might be due to some clear limitations of BLEU itself. BLEU lacks semantic understanding, as it mainly relies on the literal matching of n-grams and does not deeply understand context and semantics. It is insensitive to synonyms and diverse ways of expression. Even if two sentences mean the same thing, if they use different words or ways of expression, the BLEU score might end up being quite low. In simpler terms, BLEU struggles to recognize when different words mean the same thing, and this can lead to unfairly low scores even when the answers are correct. We hope that in the future, more advanced methods capable of deeply understanding the semantics of text will be developed, providing more accurate and reliable assessments.

4.2 CASE STUDY

We present few case study of VQA in Figure 6 7 From the case study, we can tell that the GPT-4V showed some limitations in the Medical VQA domain. It showed strong ability in determining whether a question was close-end or open-end, and was almost always able to make a correct judgment. However, in answering some open-end questions, it did not make full use of the image information, relying instead on the medical terms mentioned in the question itself, and failing to make effective reference to the information in the medical images. For example, in the last case, the GPT-4V only expanded on the nouns that appeared in the question without taking the medical images into account, resulting in an incorrect answer. There were also some instances of incorrect responses to close-end questions. These questions did not perform as well as expected, and further improvements and optimizations are needed to improve performance in Medical VQA tasks.



Visual Question Answering Cases (Close-end Questions)	
<p>Text-Prompt: Input an X-ray image along with a question related to that image. Questions can fall into one of two categories: closed-ended or open-ended.</p> <ul style="list-style-type: none"> - Closed-ended questions require a "Yes" or "No" response. - Open-ended questions require an answer that may consist of a single word or a sentence, providing a more detailed explanation. <p>Based on the X-ray image and the accompanying question, determine whether the question is closed-ended or open-ended and provide an appropriate response.</p> <p><i>Examples</i> =====</p> <p>Closed-ended Question question: Is subcutaneous air present in the right side of the neck? answer: Yes</p> <p>question: Is there evidence of metastatic tissue on organs surrounding the liver? answer: no</p> <p>Open-ended Question question: Describe the pathology visible in the image. answer: Cardiomegaly with pulmonary edema.</p> <p>question: What is the vascular distribution of these infarcts? answer: all three vascular distributions</p> <p>question: How large is the mass? answer: 5mm</p> <p>question: What modality is used in this image? answer: CT</p> <p>question: How many kidneys are visualizable in this image? answer: 2</p> <p>=====</p> <p>Please directly provide the answer to the question without any additional explanations or information. =====</p> <p>question: Is this patient in a supine position?</p>	<p>Text-Prompt: Input an X-ray image along with a question related to that image. Questions can fall into one of two categories: closed-ended or open-ended.</p> <ul style="list-style-type: none"> - Closed-ended questions require a "Yes" or "No" response. - Open-ended questions require an answer that may consist of a single word or a sentence, providing a more detailed explanation. <p>Based on the X-ray image and the accompanying question, determine whether the question is closed-ended or open-ended and provide an appropriate response.</p> <p><i>Examples</i> =====</p> <p>Closed-ended Question question: Is subcutaneous air present in the right side of the neck? answer: Yes</p> <p>question: Is there evidence of metastatic tissue on organs surrounding the liver? answer: no</p> <p>Open-ended Question question: Describe the pathology visible in the image. answer: Cardiomegaly with pulmonary edema.</p> <p>question: What is the vascular distribution of these infarcts? answer: all three vascular distributions</p> <p>question: How large is the mass? answer: 5mm</p> <p>question: What modality is used in this image? answer: CT</p> <p>question: How many kidneys are visualizable in this image? answer: 2</p> <p>=====</p> <p>Please directly provide the answer to the question without any additional explanations or information. =====</p> <p>question: Is the lesion a solid or cystic lesion?</p>
 <p>Ground Truth: Yes</p> <p>GPT-4V: Closed-ended Question answer: Yes.</p>	 <p>Ground Truth: No</p> <p>GPT-4V: Closed-ended Question answer: No.</p>

Figure 6: VQA Prompt examples. By given few-shot prompts, GPT-4V can generate answers for the given image and question pairs, the result for the close-end question is better than open-end questions

4.3 DISCUSSION

Our extensive evaluation and in-depth case studies of GPT-4V's performance on the VQA-RAD dataset have highlighted its potential capabilities as well as the areas that necessitate substantial improvement within the Medical Visual Question Answering (VQA) field.

While GPT-4V demonstrates proficiency in distinguishing between closed-end and open-end questions, its accuracy rate of 61.4% for closed-end questions and low BLEU score of 0.1155 for open-end questions signify a performance level that is considerably below the published benchmarks in this domain. This discrepancy underscores the need for more refined and optimized models that can more accurately interpret and respond to medical imagery. The capability to accurately identify whether a question is open-ended or closed-ended demonstrates GPT's substantial reasoning skills. However, its occasional low accuracy could be attributed to an insufficient amount of training data. Acquiring general Visual Question Answering

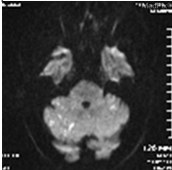
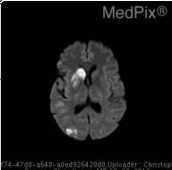
Visual Question Answering Cases (Open-end Questions)	
<p>Text-Prompt: Input an X-ray image along with a question related to that image. Questions can fall into one of two categories: closed-ended or open-ended.</p> <ul style="list-style-type: none"> - Closed-ended questions require a "Yes" or "No" response. - Open-ended questions require an answer that may consist of a single word or a sentence, providing a more detailed explanation. <p>Based on the X-ray image and the accompanying question, determine whether the question is closed-ended or open-ended and provide an appropriate response.</p> <p><i>Examples</i> =====</p> <p>Closed-ended Question question: Is subcutaneous air present in the right side of the neck? answer: Yes</p> <p>question: Is there evidence of metastatic tissue on organs surrounding the liver? answer: no</p> <p>Open-ended Question question: Describe the pathology visible in the image. answer: Cardiomegaly with pulmonary edema.</p> <p>question: What is the vascular distribution of these infarcts? answer: all three vascular distributions</p> <p>question: How large is the mass? answer: 5mm</p> <p>question: What modality is used in this image? answer: CT</p> <p>question: How many kidneys are visualizable in this image? answer: 2</p> <p>=====</p> <p>Please directly provide the answer to the question without any additional explanations or information.</p> <p>=====</p> <p>question: What organ system is shown in the above image?</p>	<p>Text-Prompt: Input an X-ray image along with a question related to that image. Questions can fall into one of two categories: closed-ended or open-ended.</p> <ul style="list-style-type: none"> - Closed-ended questions require a "Yes" or "No" response. - Open-ended questions require an answer that may consist of a single word or a sentence, providing a more detailed explanation. <p>Based on the X-ray image and the accompanying question, determine whether the question is closed-ended or open-ended and provide an appropriate response.</p> <p><i>Examples</i> =====</p> <p>Closed-ended Question question: Is subcutaneous air present in the right side of the neck? answer: Yes</p> <p>question: Is there evidence of metastatic tissue on organs surrounding the liver? answer: no</p> <p>Open-ended Question question: Describe the pathology visible in the image. answer: Cardiomegaly with pulmonary edema.</p> <p>question: What is the vascular distribution of these infarcts? answer: all three vascular distributions</p> <p>question: How large is the mass? answer: 5mm</p> <p>question: What modality is used in this image? answer: CT</p> <p>question: How many kidneys are visualizable in this image? answer: 2</p> <p>=====</p> <p>Please directly provide the answer to the question without any additional explanations or information.</p> <p>=====</p> <p>question: What brain structures would be affected by the lesion in the right frontal area of the brain?</p>
 <p>Ground Truth: Brain</p> <p>GPT-4V: Open-ended Question answer: Brain.</p>	 <p>Ground Truth: basal ganglia (caudate and putamen)</p> <p>GPT-4V: Open-ended Question answer: The lesion in the right frontal area of the brain would affect the right frontal lobe structures including the prefrontal cortex, primary motor cortex, and possibly the premotor and precentral gyrus.</p>

Figure 7: VQA Prompt examples. With the assistance of a few-shot prompts, GPT-4V has the capability to generate responses for open-ended questions, though there is room for refinement to enhance its performance.

(VQA) data is relatively easier compared to procuring medical VQA data. This discrepancy is due to the labor-intensive and expensive nature of labeling medical data. Consequently, as the volume of training data in the medical domain increases, we can anticipate an enhancement in the performance of VQA applications.

Furthermore, the limitations of the BLEU score as an evaluation metric, particularly its lack of semantic understanding and sensitivity to diverse expressions and synonyms, have been highlighted. This brings to light the urgent need for the development of more advanced and semantically aware evaluation methods to provide accurate and reliable assessments of model performance in this field.

Preprint (work in progress)

5 MEDICAL VISUAL GROUNDING

Visual Grounding is one of the important tasks in the field of computer vision, aimed at enabling computers to understand natural language descriptions and associate them with specific regions in an image. This technique has great potential in areas such as medical image analysis. In this paper, we presented the performance of GPT-4V on MS-CXR dataset for visual grounding applications and compare it with current SOTA methods.

5.1 EVALUATION

5.1.1 DATASET: MS-CXR

The MS-CXR (Boecking et al., 2022) dataset is a valuable resource for biomedical vision-language processing, featuring 1162 image-sentence pairs with bounding boxes and corresponding phrases. It was meticulously annotated by board-certified radiologists, covering eight cardiopulmonary radiological findings, each having an approximately equal number of pairs. This dataset offers both reviewed and edited bounding boxes/phrases and manually created bounding box labels from scratch. What sets MS-CXR apart is its focus on complex semantic modeling and real-world language understanding, challenging models with joint image-text reasoning and tasks like parsing domain-specific location references, complex negations, and variations in reporting style. It serves as a benchmark for phrase grounding and has been instrumental in demonstrating the effectiveness of principled textual semantic modeling for enhancing self-supervised vision-language processing.

5.1.2 OVERVIEW OF PROMPT METHODS

We've looked at many different ways to give instructions to GPT, and we've found a specific type that helps it understand better and makes it easier to create bounding boxes. We chose this prompt after carefully checking which one work best. We Designed the prompt by following the template in Figure 8:

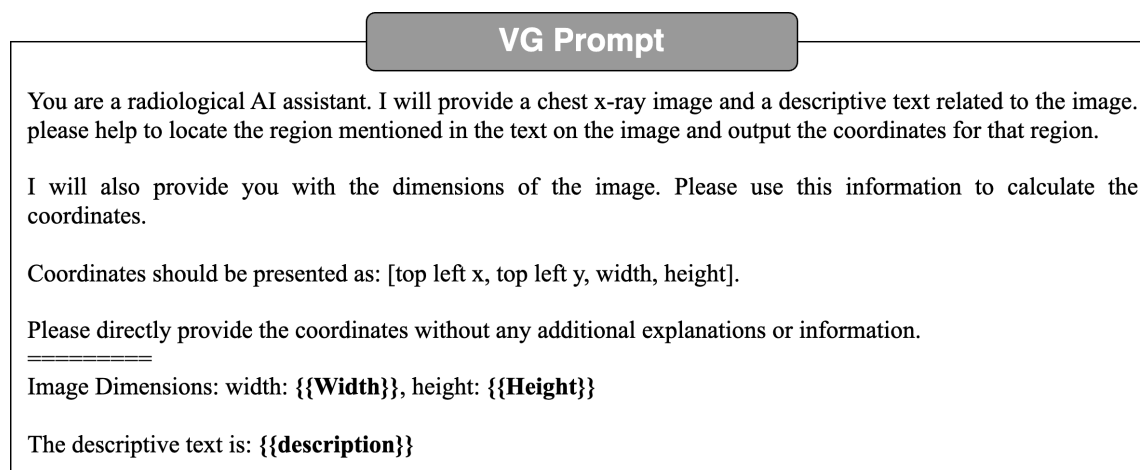


Figure 8: VG Prompt Method. Elements in double braces are replaced with specific image width, height and description text related to image

5.1.3 COMPARISON WITH SOTA

In order to compare with current existing models, we use mean Intersection-Over-Union(mIoU) as our evaluation metrics. Upon conducting an evaluation of GPT-4V’s performance on the MS-CXR dataset, the calculated mean Intersection over Union (mIoU) was found to be 0.0974. This result is markedly lower than all published benchmarks. Empirical evidence demonstrates that while GPT-4V possesses the capability to comprehend applications within Visual Grounding, it exhibits a deficiency in accurately identifying medical organs and pathological signs. Consequently, this results in imprecise bounding box predictions. Recently, SoM (Yang et al., 2023a) addressed this issue and made significant improvements. The approach in the paper involved first segmenting and labeling the image, and then proceeding with grounding, which led to substantial enhancements in performance. However, this method was applied to general images, and it’s not certain that it would yield equally impressive results for medical images, which require much finer-grained features. Further experiments will be necessary to validate its effectiveness in such contexts.

Table 3: Comparison MS-CXR datasets.

Dataset	Methods	mIoU
MS-CXR	BioViL (Boecking et al., 2022)	0.17
	BioViL-T (Bannur et al., 2023)	0.243
	RefTR (Li & Sigal, 2021)	50.11
	VGTR (Du et al., 2022)	53.58
	SeqTR (Zhu et al., 2022)	56.63
	TransVG (Deng et al., 2021)	58.91
	MedRPG (Chen et al., 2023)	59.37
	GPT-4V (OpenAI, 2023)	0.097

5.2 CASE STUDY

From the case study, it appears that the GPT-4V has the potential to generate bounding boxes, but notably, its accuracy performs rather poorly. Although it was able to attempt to calibrate the position of the object, there were serious errors and uncertainties in this task. This may be due to the fact that GPT-4V’s model has some limitations in processing the image information and is unable to fully understand and interpret the exact position of the object in the image. Especially for the medical image, which need more focus on fine grain feature. Another possible reason for GPT-4V’s poor performance could be that it was mainly trained using common, everyday images, and it didn’t have a lot of varied images to learn from. The GPT model needs a lot more data to work well and become reliable. So, because it didn’t have enough diverse data to learn from, it doesn’t perform very well.

5.3 DISCUSSION

Our comprehensive evaluation and case study of GPT-4V’s capabilities in Visual Grounding highlight both its potential and its current limitations. While the model shows promise in recognizing bounding boxes, it falls significantly short in terms of accuracy, as evidenced by its low mIoU score when compared to existing benchmarks and its performance on the MS-CXR dataset. Its inability to precisely identify medical organs and pathological signs leading to imprecise bounding box predictions, and this may caused by lack of training data. It is very hard to get enough labeled data for GPT to train.

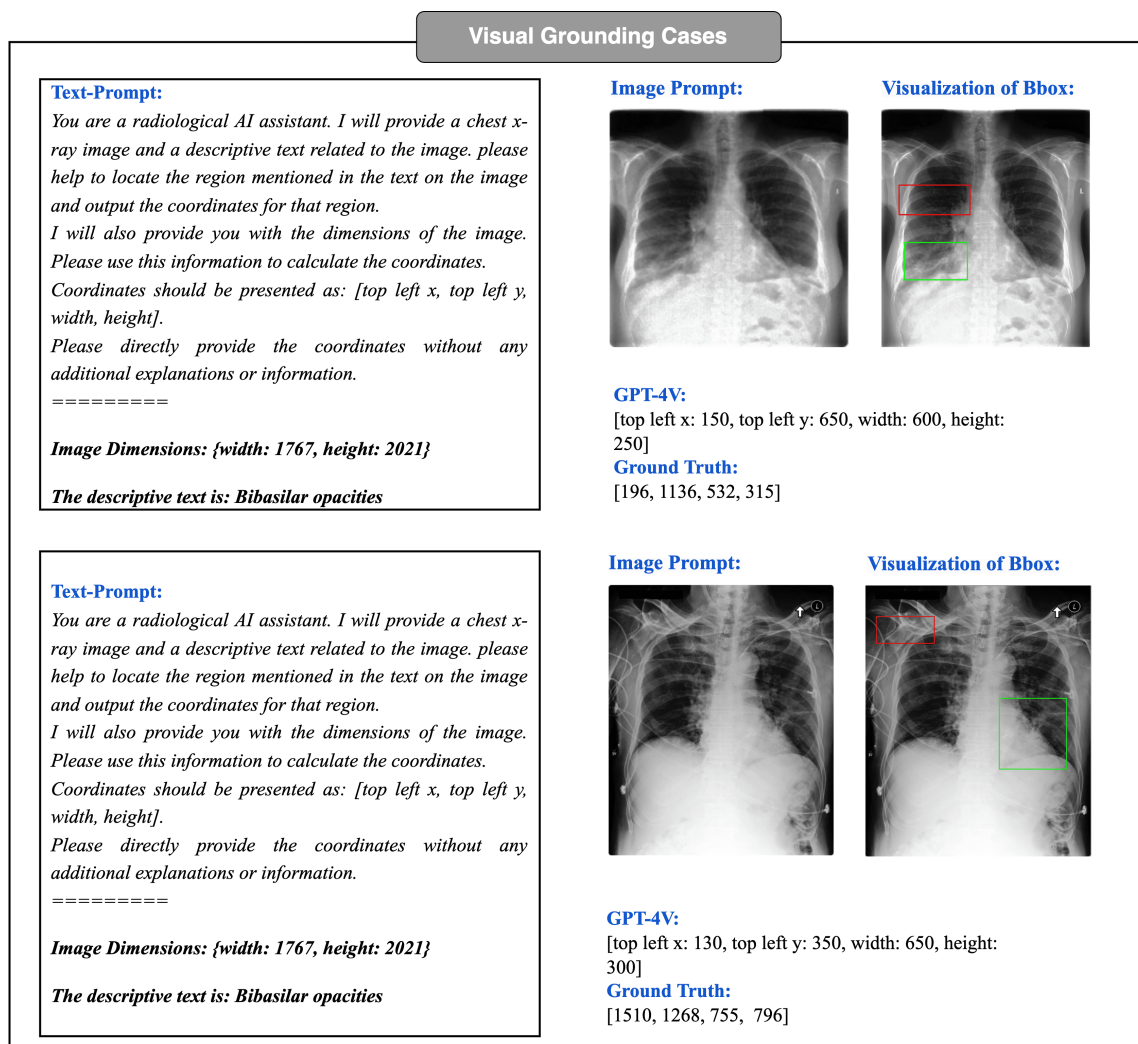


Figure 9: Visual Grounding Prompt examples. The bounding boxes in red color are predicted box by GPT-4V, and the green bounding boxes are ground truth boxes. GPT-4 is capable of generating and estimating the bounding box coordinates for the reference text within an image. However, the results show that the GPT-4V can not understand medical image properly.

In light of these findings, it is evident that GPT-4V requires further refinement and training to overcome its current limitations and to enhance its bounding box localization accuracy. In order to achieve better results in this area, further model improvement and more data is needed to increase the accuracy of its bounding box localization, thus making it more useful and reliable in various applications.


Doing so will undoubtedly make GPT-4V a more reliable and valuable tool in various applications, fostering its integration and utility in practical, real-world scenarios, especially within the medical field. This journey

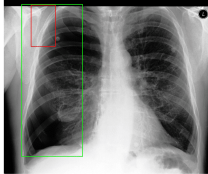
Visual Grounding Cases

Text-Prompt:
You are a radiological AI assistant. I will provide a chest x-ray image and a descriptive text related to the image. please help to locate the region mentioned in the text on the image and output the coordinates for that region. I will also provide you with the dimensions of the image. Please use this information to calculate the coordinates. Coordinates should be presented as: [top left x, top left y, width, height]. Please directly provide the coordinates without any additional explanations or information.
=====

Image Dimensions: {width: 1767, height: 2021}

The descriptive text is: *Large right-sided pneumothora*

Image Prompt: 

Visualization of Bbox: 

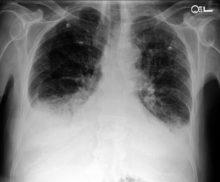
GPT-4V:
[top left x: 400, top left y: 100, width: 350, height: 600]

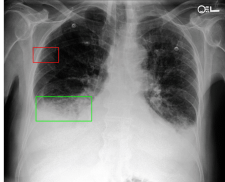
Ground Truth:
[265, 90, 880, 2198]

Text-Prompt:
You are a radiological AI assistant. I will provide a chest x-ray image and a descriptive text related to the image. please help to locate the region mentioned in the text on the image and output the coordinates for that region. I will also provide you with the dimensions of the image. Please use this information to calculate the coordinates. Coordinates should be presented as: [top left x, top left y, width, height]. Please directly provide the coordinates without any additional explanations or information.
=====

Image Dimensions: {width: 2539, height: 3050}

The descriptive text is: *The descriptive text is: Bilateral multifocal areas of consolidation*

Image Prompt: 

Visualization of Bbox: 

GPT-4V:
[top left x: 130, top left y: 350, width: 650, height: 300]

Ground Truth:
[1510, 1268, 755, 796]

Figure 10: There are some Visual Grounding Prompt examples. The bounding boxes in red color are predicted box by GPT-4V, and the green bounding boxes are ground truth boxes.

towards improvement is not only necessary but also a crucial step in advancing the field of Visual Grounding and in unlocking the full potential of models like GPT-4V.

6 CONCLUSION

The comprehensive assessment of GPT-4V's capabilities in Radiology Report Generation, Medical Visual Question Answering (VQA), and Visual Grounding offers a perspective on the model's potential and areas for improvement within the medical domain. GPT-4V's ability to generate radiology reports based on chest X-ray images is commendable, particularly when furnished with detailed prompts. This underscores the capacity of language models to aid in radiology diagnosis. Nevertheless, its challenges in recognizing uncommon terms and subtle differences specific to the MIMIC-CXR dataset underscore the necessity for domain-specific training and fine-tuning to elevate its proficiency in medical reporting.

Preprint (work in progress)

Furthermore, although GPT-4V displays proficiency in distinguishing among various question types within the VQA-RAD dataset, its performance metrics, especially for open-ended questions, fall short of public benchmarks. This sub-optimal performance reveals a gap in its comprehension and response capabilities related to medical imaging. Moreover, the limitations of current evaluation metrics like the BLEU score underscore the significance of constructing semantically-aware evaluation methodologies to gain a holistic comprehension of the model's aptitude.

The Visual Grounding evaluation further explored the difficulties GPT-4V encounters in achieving high precision in bounding box localization within medical images. These limitations, particularly its struggles in identifying medical organs and pathological indicators, underscore the urgent requirement for specialized training and model improvements to enhance its grounding capabilities.

In summary, GPT-4V demonstrates remarkable potential across various medical image analysis domains. Nonetheless, its current limitations underscore the necessity for domain-specific enhancements. Exploring dedicated training on medical datasets, designing comprehensive prompt methodologies, and advancing evaluation techniques still need further research.

REFERENCES

- Rahul Ambati and Chakravaradhan Reddy Dudyala. A sequence-to-sequence model approach for image-clef 2018 medical domain visual question answering. In *2018 15th IEEE India Council International Conference (INDICON)*, pp. 1–6. IEEE, 2018.
- Rohan Anil, Andrew M Dai, Orhan Firat, Melvin Johnson, Dmitry Lepikhin, Alexandre Passos, Siamak Shakeri, Emanuel Taropa, Paige Bailey, Zhifeng Chen, et al. Palm 2 technical report. *arXiv preprint arXiv:2305.10403*, 2023.
- Anas Awadalla, Irena Gao, Josh Gardner, Jack Hessel, Yusuf Hanafy, Wanrong Zhu, Kalyani Marathe, Yonatan Bitton, Samir Gadre, Shiori Sagawa, et al. Openflamingo: An open-source framework for training large autoregressive vision-language models. *arXiv preprint arXiv:2308.01390*, 2023.
- Satanjeev Banerjee and Alon Lavie. METEOR: an automatic metric for MT evaluation with improved correlation with human judgments. In Jade Goldstein, Alon Lavie, Chin-Yew Lin, and Clare R. Voss (eds.), *Proceedings of the Workshop on Intrinsic and Extrinsic Evaluation Measures for Machine Translation and/or Summarization@ACL 2005, Ann Arbor, Michigan, USA, June 29, 2005*, pp. 65–72. Association for Computational Linguistics, 2005. URL <https://aclanthology.org/W05-0909/>.
- Shruthi Bannur, Stephanie Hyland, Qianchu Liu, Fernando Perez-Garcia, Maximilian Ilse, Daniel C Castro, Benedikt Boecking, Harshita Sharma, Kenza Bouzid, Anja Thieme, et al. Learning to exploit temporal structure for biomedical vision-language processing. In *Proceedings of the IEEE/CVF Conference on Computer Vision and Pattern Recognition*, pp. 15016–15027, 2023.
- Benedikt Boecking, Naoto Usuyama, Shruthi Bannur, Daniel C Castro, Anton Schwaighofer, Stephanie Hyland, Maria Wetscherek, Tristan Naumann, Aditya Nori, Javier Alvarez-Valle, et al. Making the most of text semantics to improve biomedical vision–language processing. In *European conference on computer vision*, pp. 1–21. Springer, 2022.
- Zhihao Chen, Yang Zhou, Anh Tran, Junting Zhao, Liang Wan, Gideon Su Kai Ooi, Lionel Tim-Ee Cheng, Choon Hua Thng, Xinxing Xu, Yong Liu, et al. Medical phrase grounding with region-phrase context contrastive alignment. In *International Conference on Medical Image Computing and Computer-Assisted Intervention*, pp. 371–381. Springer, 2023.
- Zhihong Chen, Yan Song, Tsung-Hui Chang, and Xiang Wan. Generating radiology reports via memory-driven transformer. In Bonnie Webber, Trevor Cohn, Yulan He, and Yang Liu (eds.), *Proceedings of the 2020 Conference on Empirical Methods in Natural Language Processing, EMNLP 2020, Online, November 16-20, 2020*, pp. 1439–1449. Association for Computational Linguistics, 2020. doi: 10.18653/v1/2020.emnlp-main.112. URL <https://doi.org/10.18653/v1/2020.emnlp-main.112>.
- Zhihong Chen, Yaling Shen, Yan Song, and Xiang Wan. Cross-modal memory networks for radiology report generation. In Chengqing Zong, Fei Xia, Wenjie Li, and Roberto Navigli (eds.), *Proceedings of the 59th Annual Meeting of the Association for Computational Linguistics and the 11th International Joint Conference on Natural Language Processing, ACL/IJCNLP 2021, (Volume 1: Long Papers), Virtual Event, August 1-6, 2021*, pp. 5904–5914. Association for Computational Linguistics, 2021. doi: 10.18653/v1/2021.acl-long.459. URL <https://doi.org/10.18653/v1/2021.acl-long.459>.
- Aakanksha Chowdhery, Sharan Narang, Jacob Devlin, Maarten Bosma, Gaurav Mishra, Adam Roberts, Paul Barham, Hyung Won Chung, Charles Sutton, Sebastian Gehrmann, et al. Palm: Scaling language modeling with pathways. *arXiv preprint arXiv:2204.02311*, 2022.

- Marcella Cornia, Matteo Stefanini, Lorenzo Baraldi, and Rita Cucchiara. Meshed-memory transformer for image captioning. In *2020 IEEE/CVF Conference on Computer Vision and Pattern Recognition, CVPR 2020, Seattle, WA, USA, June 13-19, 2020*, pp. 10575–10584. Computer Vision Foundation / IEEE, 2020. doi: 10.1109/CVPR42600.2020.01059. URL https://openaccess.thecvf.com/content_CVPR_2020/html/Cornia_Meshed-Memory_Transformer_for_Image_Captioning_CVPR_2020_paper.html.
- Damai Dai, Yutao Sun, Li Dong, Yaru Hao, Zhifang Sui, and Furu Wei. Why can gpt learn in-context? language models secretly perform gradient descent as meta optimizers. *arXiv preprint arXiv:2212.10559*, 2022.
- Jiajun Deng, Zhengyuan Yang, Tianlang Chen, Wengang Zhou, and Houqiang Li. Transvg: End-to-end visual grounding with transformers. In *Proceedings of the IEEE/CVF International Conference on Computer Vision*, pp. 1769–1779, 2021.
- Tuong Do, Binh X Nguyen, Erman Tjiputra, Minh Tran, Quang D Tran, and Anh Nguyen. Multiple meta-model quantifying for medical visual question answering. In *International Conference on Medical Image Computing and Computer-Assisted Intervention*, pp. 64–74. Springer, 2021.
- Ye Du, Zehua Fu, Qingjie Liu, and Yunhong Wang. Visual grounding with transformers. In *2022 IEEE International Conference on Multimedia and Expo (ICME)*, pp. 1–6. IEEE, 2022.
- Sedigheh Eslami, Gerard de Melo, and Christoph Meinel. Does clip benefit visual question answering in the medical domain as much as it does in the general domain? *arXiv preprint arXiv:2112.13906*, 2021.
- Chelsea Finn, Pieter Abbeel, and Sergey Levine. Model-agnostic meta-learning for fast adaptation of deep networks. In *International conference on machine learning*, pp. 1126–1135. PMLR, 2017.
- Xuehai He, Yichen Zhang, Luntian Mou, Eric Xing, and Pengtao Xie. Pathvqa: 30000+ questions for medical visual question answering. *arXiv preprint arXiv:2003.10286*, 2020.
- Weijian Huang, Hongyu Zhou, Cheng Li, Hao Yang, Jiarun Liu, and Shanshan Wang. Enhancing representation in radiography-reports foundation model: A granular alignment algorithm using masked contrastive learning. *arXiv preprint arXiv:2309.05904*, 2023.
- Huaizu Jiang, Ishan Misra, Marcus Rohrbach, Erik Learned-Miller, and Xinlei Chen. In defense of grid features for visual question answering. In *Proceedings of the IEEE/CVF Conference on Computer Vision and Pattern Recognition*, pp. 10267–10276, 2020.
- Alistair E. W. Johnson, Tom J. Pollard, Seth J. Berkowitz, Nathaniel R. Greenbaum, Matthew P. Lungren, Chih-ying Deng, Roger G. Mark, and Steven Horng. MIMIC-CXR: A large publicly available database of labeled chest radiographs. *CoRR*, abs/1901.07042, 2019. URL <http://arxiv.org/abs/1901.07042>.
- Aishwarya Kamath, Mannat Singh, Yann LeCun, Gabriel Synnaeve, Ishan Misra, and Nicolas Carion. Mdetr-modulated detection for end-to-end multi-modal understanding. In *Proceedings of the IEEE/CVF International Conference on Computer Vision*, pp. 1780–1790, 2021.
- Yash Khare, Viraj Bagal, Minesh Mathew, Adithi Devi, U Deva Priyakumar, and CV Jawahar. Mmbert: multimodal bert pretraining for improved medical vqa. In *2021 IEEE 18th International Symposium on Biomedical Imaging (ISBI)*, pp. 1033–1036. IEEE, 2021.
- Jason J Lau, Soumya Gayen, Asma Ben Abacha, and Dina Demner-Fushman. A dataset of clinically generated visual questions and answers about radiology images. *Scientific data*, 5(1):1–10, 2018.

Preprint (work in progress)

- Chunyuan Li, Cliff Wong, Sheng Zhang, Naoto Usuyama, Haotian Liu, Jianwei Yang, Tristan Naumann, Hoifung Poon, and Jianfeng Gao. Llava-med: Training a large language-and-vision assistant for biomedicine in one day. *arXiv preprint arXiv:2306.00890*, 2023a.
- Junnan Li, Dongxu Li, Silvio Savarese, and Steven Hoi. Blip-2: Bootstrapping language-image pre-training with frozen image encoders and large language models. *arXiv preprint arXiv:2301.12597*, 2023b.
- Mingjie Li, Bingqian Lin, Zicong Chen, Haokun Lin, Xiaodan Liang, and Xiaojun Chang. Dynamic graph enhanced contrastive learning for chest x-ray report generation. In *Proceedings of the IEEE/CVF Conference on Computer Vision and Pattern Recognition*, pp. 3334–3343, 2023c.
- Muchen Li and Leonid Sigal. Referring transformer: A one-step approach to multi-task visual grounding. *Advances in neural information processing systems*, 34:19652–19664, 2021.
- Yuan Li, Xiaodan Liang, Zhiting Hu, and Eric P. Xing. Hybrid retrieval-generation reinforced agent for medical image report generation. In Samy Bengio, Hanna M. Wallach, Hugo Larochelle, Kristen Grauman, Nicolò Cesa-Bianchi, and Roman Garnett (eds.), *Advances in Neural Information Processing Systems 31: Annual Conference on Neural Information Processing Systems 2018, NeurIPS 2018, December 3-8, 2018, Montréal, Canada*, pp. 1537–1547, 2018. URL <https://proceedings.neurips.cc/paper/2018/hash/e07413354875be01a996dc560274708e-Abstract.html>.
- Chin-Yew Lin. ROUGE: A package for automatic evaluation of summaries. In *Text Summarization Branches Out*, pp. 74–81, Barcelona, Spain, July 2004. Association for Computational Linguistics. URL <https://aclanthology.org/W04-1013>.
- Fenglin Liu, Xian Wu, Shen Ge, Wei Fan, and Yuexian Zou. Exploring and distilling posterior and prior knowledge for radiology report generation. In *IEEE Conference on Computer Vision and Pattern Recognition, CVPR 2021, virtual, June 19-25, 2021*, pp. 13753–13762. Computer Vision Foundation / IEEE, 2021. doi: 10.1109/CVPR46437.2021.01354. URL https://openaccess.thecvf.com/content/CVPR2021/html/Liu_Exploring_and_Distilling_Posterior_and_Prior_Knowledge_for_Radiology_Report_CVPR_2021_paper.html.
- Guanxiong Liu, Tzu-Ming Harry Hsu, Matthew McDermott, Willie Boag, Wei-Hung Weng, Peter Szolovits, and Marzyeh Ghassemi. Clinically accurate chest x-ray report generation. In *Machine Learning for Healthcare Conference*, pp. 249–269. PMLR, 2019.
- Yunyi Liu, Zhanyu Wang, Dong Xu, and Luping Zhou. Q2atransformer: Improving medical vqa via an answer querying decoder. In *International Conference on Information Processing in Medical Imaging*, pp. 445–456. Springer, 2023.
- Jiasen Lu, Caiming Xiong, Devi Parikh, and Richard Socher. Knowing when to look: Adaptive attention via a visual sentinel for image captioning. In *2017 IEEE Conference on Computer Vision and Pattern Recognition, CVPR 2017, Honolulu, HI, USA, July 21-26, 2017*, pp. 3242–3250. IEEE Computer Society, 2017. doi: 10.1109/CVPR.2017.345. URL <https://doi.org/10.1109/CVPR.2017.345>.
- Binh D Nguyen, Thanh-Toan Do, Binh X Nguyen, Tuong Do, Erman Tjiputra, and Quang D Tran. Overcoming data limitation in medical visual question answering. In *International Conference on Medical Image Computing and Computer-Assisted Intervention*, pp. 522–530. Springer, 2019.
- OpenAI. Gpt-4 technical report. *ArXiv*, abs/2303.08774, 2023. URL <https://api.semanticscholar.org/CorpusID:257532815>.

- Yingwei Pan, Ting Yao, Yehao Li, and Tao Mei. X-linear attention networks for image captioning. In *2020 IEEE/CVF Conference on Computer Vision and Pattern Recognition, CVPR 2020, Seattle, WA, USA, June 13-19, 2020*, pp. 10968–10977. Computer Vision Foundation / IEEE, 2020. doi: 10.1109/CVPR42600.2020.01098. URL https://openaccess.thecvf.com/content_CVPR_2020/html/Pan_X-Linear_Attention_Networks_for_Image_Captioning_CVPR_2020_paper.html.
- Kishore Papineni, Salim Roukos, Todd Ward, and Wei-Jing Zhu. Bleu: a method for automatic evaluation of machine translation. In *Proceedings of the 40th Annual Meeting of the Association for Computational Linguistics, July 6-12, 2002, Philadelphia, PA, USA*, pp. 311–318. ACL, 2002. doi: 10.3115/1073083.1073135. URL <https://aclanthology.org/P02-1040/>.
- Chantal Pellegrini, Matthias Keicher, Ege Özsoy, and Nassir Navab. Rad-restruct: A novel vqa benchmark and method for structured radiology reporting. In *International Conference on Medical Image Computing and Computer-Assisted Intervention*, pp. 409–419. Springer, 2023.
- Zhiliang Peng, Wenhui Wang, Li Dong, Yaru Hao, Shaohan Huang, Shuming Ma, and Furu Wei. Kosmos-2: Grounding multimodal large language models to the world. *arXiv preprint arXiv:2306.14824*, 2023.
- Fuji Ren and Yangyang Zhou. Cgmvqa: A new classification and generative model for medical visual question answering. *IEEE Access*, 8:50626–50636, 2020.
- Karan Singhal, Tao Tu, Juraj Gottweis, Rory Sayres, Ellery Wulczyn, Le Hou, Kevin Clark, Stephen Pfohl, Heather Cole-Lewis, Darlene Neal, et al. Towards expert-level medical question answering with large language models. *arXiv preprint arXiv:2305.09617*, 2023.
- Jinghan Sun, Dong Wei, Zhe Xu, Donghuan Lu, Hong Liu, Liansheng Wang, and Yefeng Zheng. You’ve got two teachers: Co-evolutionary image and report distillation for semi-supervised anatomical abnormality detection in chest x-ray. In *International Conference on Medical Image Computing and Computer-Assisted Intervention*, pp. 363–373. Springer, 2023a.
- Zhaoyi Sun, Mingquan Lin, Qingqing Zhu, Qianqian Xie, Fei Wang, Zhiyong Lu, and Yifan Peng. A scoping review on multimodal deep learning in biomedical images and texts. *Journal of Biomedical Informatics*, pp. 104482, 2023b.
- Hugo Touvron, Thibaut Lavril, Gautier Izacard, Xavier Martinet, Marie-Anne Lachaux, Timothée Lacroix, Baptiste Rozière, Naman Goyal, Eric Hambro, Faisal Azhar, et al. Llama: Open and efficient foundation language models. *arXiv preprint arXiv:2302.13971*, 2023.
- Maria Tsimpoukelli, Jacob L Menick, Serkan Cabi, SM Eslami, Oriol Vinyals, and Felix Hill. Multimodal few-shot learning with frozen language models. *Advances in Neural Information Processing Systems*, 34: 200–212, 2021.
- Ashish Vaswani, Noam Shazeer, Niki Parmar, Jakob Uszkoreit, Llion Jones, Aidan N. Gomez, Lukasz Kaiser, and Illia Polosukhin. Attention is all you need. In Isabelle Guyon, Ulrike von Luxburg, Samy Bengio, Hanna M. Wallach, Rob Fergus, S. V. N. Vishwanathan, and Roman Garnett (eds.), *Advances in Neural Information Processing Systems 30: Annual Conference on Neural Information Processing Systems 2017, December 4-9, 2017, Long Beach, CA, USA*, pp. 5998–6008, 2017. URL <https://proceedings.neurips.cc/paper/2017/hash/3f5ee243547dee91fbd053c1c4a845aa-Abstract.html>.
- Ramakrishna Vedantam, C. Lawrence Zitnick, and Devi Parikh. Cider: Consensus-based image description evaluation. In *IEEE Conference on Computer Vision and Pattern Recognition, CVPR 2015, Boston, MA, USA, June 7-12, 2015*, pp. 4566–4575. IEEE Computer Society, 2015. doi: 10.1109/CVPR.2015.7299087. URL <https://doi.org/10.1109/CVPR.2015.7299087>.

- Oriol Vinyals, Alexander Toshev, Samy Bengio, and Dumitru Erhan. Show and tell: A neural image caption generator. In *IEEE Conference on Computer Vision and Pattern Recognition, CVPR 2015, Boston, MA, USA, June 7-12, 2015*, pp. 3156–3164. IEEE Computer Society, 2015. doi: 10.1109/CVPR.2015.7298935. URL <https://doi.org/10.1109/CVPR.2015.7298935>.
- Xuezhi Wang, Jason Wei, Dale Schuurmans, Quoc Le, Ed Chi, Sharan Narang, Aakanksha Chowdhery, and Denny Zhou. Self-consistency improves chain of thought reasoning in language models. *arXiv preprint arXiv:2203.11171*, 2022a.
- Zhanyu Wang, Mingkang Tang, Lei Wang, Xiu Li, and Luping Zhou. A medical semantic-assisted transformer for radiographic report generation. In Linwei Wang, Qi Dou, P. Thomas Fletcher, Stefanie Speidel, and Shuo Li (eds.), *Medical Image Computing and Computer Assisted Intervention - MICCAI 2022 - 25th International Conference, Singapore, September 18-22, 2022, Proceedings, Part III*, volume 13433 of *Lecture Notes in Computer Science*, pp. 655–664. Springer, 2022b. doi: 10.1007/978-3-031-16437-8_63. URL https://doi.org/10.1007/978-3-031-16437-8_63.
- Zhanyu Wang, Lingqiao Liu, Lei Wang, and Luping Zhou. Metrtransformer: Radiology report generation by transformer with multiple learnable expert tokens. In *IEEE/CVF Conference on Computer Vision and Pattern Recognition, CVPR 2023, Vancouver, BC, Canada, June 17-24, 2023*, pp. 11558–11567. IEEE, 2023a. doi: 10.1109/CVPR52729.2023.01112. URL <https://doi.org/10.1109/CVPR52729.2023.01112>.
- Zhanyu Wang, Lingqiao Liu, Lei Wang, and Luping Zhou. R2gengpt: Radiology report generation with frozen llms. *arXiv preprint arXiv:2309.09812*, 2023b.
- Jason Wei, Yi Tay, Rishi Bommasani, Colin Raffel, Barret Zoph, Sebastian Borgeaud, Dani Yogatama, Maarten Bosma, Denny Zhou, Donald Metzler, et al. Emergent abilities of large language models. *arXiv preprint arXiv:2206.07682*, 2022a.
- Jason Wei, Xuezhi Wang, Dale Schuurmans, Maarten Bosma, Fei Xia, Ed Chi, Quoc V Le, Denny Zhou, et al. Chain-of-thought prompting elicits reasoning in large language models. *Advances in Neural Information Processing Systems*, 35:24824–24837, 2022b.
- Chenfei Wu, Jinlai Liu, Xiaojie Wang, and Ruifan Li. Differential networks for visual question answering. In *Proceedings of the AAAI Conference on Artificial Intelligence*, volume 33, pp. 8997–9004, 2019.
- Shengqiong Wu, Hao Fei, Leigang Qu, Wei Ji, and Tat-Seng Chua. Next-gpt: Any-to-any multimodal llm. *arXiv preprint arXiv:2309.05519*, 2023.
- Kelvin Xu, Jimmy Ba, Ryan Kiros, Kyunghyun Cho, Aaron C. Courville, Ruslan Salakhutdinov, Richard S. Zemel, and Yoshua Bengio. Show, attend and tell: Neural image caption generation with visual attention. In Francis R. Bach and David M. Blei (eds.), *Proceedings of the 32nd International Conference on Machine Learning, ICML 2015, Lille, France, 6-11 July 2015*, volume 37 of *JMLR Workshop and Conference Proceedings*, pp. 2048–2057. JMLR.org, 2015. URL <http://proceedings.mlr.press/v37/xuc15.html>.
- Jianwei Yang, Hao Zhang, Feng Li, Xueyan Zou, Chunyuan Li, and Jianfeng Gao. Set-of-mark prompting unleashes extraordinary visual grounding in gpt-4v. *arXiv preprint arXiv:2310.11441*, 2023a.
- S. Yang, X. Wu, S. Ge, X. Wu, S. K. Zhou, and L. Xiao. Radiology report generation with a learned knowledge base and multi-modal alignment. *Image and Video Processing*, 2021a.
- S. Yang, X. Wu, S. Ge, S. K. Zhou, and L. Xiao. Knowledge matters: Radiology report generation with general and specific knowledge. *Medical Image Analysis*, 2021b.

Preprint (work in progress)

Zhengyuan Yang, Linjie Li, Kevin Lin, Jianfeng Wang, Chung-Ching Lin, Zicheng Liu, and Lijuan Wang. The dawn of llms: Preliminary explorations with gpt-4v (ision). *arXiv preprint arXiv:2309.17421*, 2023b.

Qinghao Ye, Haiyang Xu, Guohai Xu, Jiabo Ye, Ming Yan, Yiyang Zhou, Junyang Wang, Anwen Hu, Pengcheng Shi, Yaya Shi, et al. mplug-owl: Modularization empowers large language models with multimodality. *arXiv preprint arXiv:2304.14178*, 2023.

Yixiao Zhang, Xiaosong Wang, Ziyue Xu, Qihang Yu, Alan Yuille, and Daguang Xu. When radiology report generation meets knowledge graph. *Proceedings of the AAAI Conference on Artificial Intelligence*, 2020.

Yang Zhao, Zhijie Lin, Daquan Zhou, Zilong Huang, Jiashi Feng, and Bingyi Kang. Bubogpt: Enabling visual grounding in multi-modal llms. *arXiv preprint arXiv:2307.08581*, 2023.

Chaoyang Zhu, Yiyi Zhou, Yunhang Shen, Gen Luo, Xingjia Pan, Mingbao Lin, Chao Chen, Liujuan Cao, Xiaoshuai Sun, and Rongrong Ji. Seqtr: A simple yet universal network for visual grounding. In *European Conference on Computer Vision*, pp. 598–615. Springer, 2022.

Deyao Zhu, Jun Chen, Xiaoqian Shen, Xiang Li, and Mohamed Elhoseiny. Minigpt-4: Enhancing vision-language understanding with advanced large language models. 2023.

Preprint (work in progress)

A APPENDIX

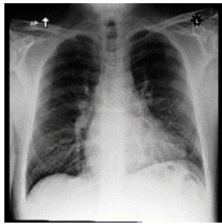
A.1 DETAILS OF PROMPT SETTINGS

In all prompts, we prompt GPT-4V to assume the role of a professional radiologist. Additionally, we explicitly instruct it to generate both the impression and findings sections.

A.1.1 ZERO-SHOT PROMPT

Figure 11 showcases a zero-shot prompt example. We did not add any additional information to the text prompt.

Zero-shot Prompt

<p>Text-Prompt:</p> <p>You are a professional radiologist. I will provide you with some chest X-ray images. Please generate a radiology report based on the provided image. The report needs to contain both the impression and findings sections. You should only generate reports and no other unnecessary information.</p>	<p>Image:</p> 
--	--

GPT-4V:

Impression: Normal chest radiograph with no acute cardiopulmonary abnormalities.
Findings:
Lungs: Clear bilaterally. No focal opacity, consolidation, or mass identified.
Cardiomediastinal silhouette: Normal size and contour. No mediastinal widening.
Bones: Intact without any appreciable fractures or bony lesions.
Diaphragm: Intact with no evidence of diaphragmatic hernia.
Soft tissues: Unremarkable.

Ground Truth:

impression: No acute intrathoracic process.
Findings:
The lungs are well expanded and clear. The cardiomediastinal silhouette, hilar contours, and pleural surfaces are normal. No pleural effusion or pneumothorax is present. Sternal wires are intact.

Figure 11: Zero-shot prompt. No additional information provided to GPT-4V.

A.1.2 FEW-SHOT PROMPT

Figure 12 showcases our few-shot prompt setting. We added two example reports to the prompt. We explored three different combinations: (1) exclusively using normal examples, (2) exclusively using abnormal examples, (3) combining one normal and one abnormal example. The example reports are displayed in Figure 13.

Preprint (work in progress)

Few-shot prompt

Few-shot normal examples prompt

You are a professional radiologist. I will provide you with some chest X-ray images. Please generate a radiology report based on the provided image. You should only generate reports and no other unnecessary information. The format of the output report should be similar to the example:

Examples:
=====

Impression: No acute cardiopulmonary process.
Findings: There is no focal consolidation, pleural effusion or pneumothorax, Bilateral nodular opacities that most likely represent nipple shadows. The cardiomeastinal silhouette is normal, Clips project over the left lung, potentially within the breast. The imaged upper abdomen is unremarkable. Chronic deformity of the posterior left sixth and seventh ribs are noted.

Impression: No evidence of pneumonia.
Findings: The lung volumes are normal. Normal hilar and mediastinal structures. No pneumonia, no pulmonary edema. No pleural effusions. Status post CABG with aligned median sternotomy wires and normal location of surgical clips. Status post right lung surgery with surgical material seen.

Few-shot abnormal examples prompt

You are a professional radiologist. I will provide you with some chest X-ray images. Please generate a radiology report based on the provided image. You should only generate reports and no other unnecessary information. The format of the output report should be similar to the example:

Examples:
=====

Abnormal Example 1
Abnormal Example 2

Few-shot mixed examples prompt

You are a professional radiologist. I will provide you with some chest X-ray images. Please generate a radiology report based on the provided image. You should only generate reports and no other unnecessary information. The format of the output report should be similar to the example:

Examples:
=====

Abnormal Example 1
Normal Example 1

Figure 12: Few-shot prompt. Example reports from MIMIC-CXR training dataset are added to the prompt text

Few-shot normal examples prompt In this prompt method, we curated reports from two normal samples within the MIMIC-CXR training set. To ensure comprehensiveness, we specifically chose reports that were richer in content.

Few-shot abnormal examples prompt In this prompt method, we carefully chose two reports originating from abnormal samples within the MIMIC-CXR training set.

Few-shot mixed examples prompt In this prompt method, we chose one normal and one abnormal report from the MIMIC-CXR training set. The sequence in which these two examples are presented is not anticipated to significantly impact the generated results. In this specific experiment, we positioned the abnormal report before the normal one.

Preprint (work in progress)

Few-shot abnormal examples prompt
<p>Case 1: Impression: Mediastinal widening more than expected given procedure, concerning for substantial mediastinal hemorrhage. Left chest tube in place with no pneumothorax. Findings: Mediastinum is widened and is more than expected status post bisegmentectomy concerning for substantial mediastinal hemorrhage with indentation of the left tracheal wall contour. Patient is status post left upper lobe bisegmentectomy with left chest tube in place. Bilateral low lung volumes. No pneumothorax. Pleural effusions little if any. Cardiac size appears enlarged and likely is exaggerated by low lung volumes.</p> <p>Case 2: Impression: Focal consolidation at the left lung base, possibly representing aspiration or pneumonia. Central vascular engorgement. Findings: PA and lateral views of the chest provided. The lungs are adequately aerated. There is a focal consolidation at the left lung base adjacent to the lateral hemidiaphragm. There is mild vascular engorgement. There is bilateral apical pleural thickening. The cardiomediastinal silhouette is remarkable for aortic arch calcifications. The heart is top normal in size.</p>
Few-shot normal examples prompt
<p>Case 1: Impression: No acute cardiopulmonary process. Findings: There is no focal consolidation. Pleural effusion or pneumothorax. Bilateral nodular opacities that most likely represent nipple shadows. The cardiomediastinal silhouette is normal. Clips project over the left lung, potentially within the breast. The imaged upper abdomen is unremarkable.</p> <p>Case 2: Impression: No evidence of pneumonia. Findings: The lung volumes are normal. Normal hilar and mediastinal structures. No pneumonia, no pulmonary edema. No pleural effusions. Status post CABG with aligned median sternotomy wires and normal location of surgical clips. Status post right lung surgery with surgical material seen.</p>
Few-shot mixed examples prompt
<p>Case 1: Impression: Retrocardiac opacity, potentially atelectasis, though infection cannot be excluded in the correct clinical setting. Persistent elevation of the right hemidiaphragm with right basilar atelectasis. Findings: Mild cardiomegaly with a left ventricular predominance is re-demonstrated. The mediastinal and hilar contours are unchanged. Pulmonary vasculature is normal. Elevation of the right hemidiaphragm is again noted with associated right basilar atelectasis. Retrocardiac patchy opacity may reflect atelectasis though infection is not excluded in the correct clinical setting. No pleural effusion or pneumothorax is detected. S-shaped rotary scoliosis of the thoracolumbar spine is again noted.</p> <p>Case 2: Impression: No evidence of pneumonia. Findings: Frontal and lateral views of the chest demonstrate no focal consolidation. Except for linear atelectasis in the right lower lung, the lungs are clear. The cardiomediastinal and hilar contours are normal. There is no pneumothorax or pleural effusion. Pleural surfaces are normal.</p>

Figure 13: Example reports in prompts: Three pairs of different example reports in few-shot prompt settings. We added these example reports to few-shot prompts to help GPT-4V generate radiology reports.

A.2 ABNORMAL PROMPT CASE

Figure 14 shows an abnormal chest X-ray image along with the corresponding reports generated by GPT-4V using three distinct prompt methodologies. Notably, we observe that GPT-4V tends to generate normal descriptions when the prompt examples exclusively consist of normal reports.

A.3 INCORRECT VIEWPOINT CASE

In Figure 15, it becomes evident that the chest X-ray image provided is a frontal view, whereas GPT-4V's generated report incorrectly labels it as a lateral view.

Abnormal Case

Text-Prompt:

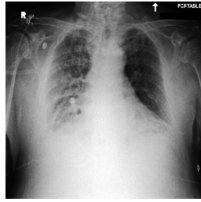
You are a professional radiologist. I will provide you with some chest X-ray images. Please generate a radiology report based on the provided image. You should only generate reports and no other unnecessary information. The format of the output report should be similar to the example:

Examples:
=====

Example 1

Example 2

Image:



Ground Truth:

Impression: **Increased opacity** projecting over the right hemi thorax likely due to increased right pleural effusion with overlying atelectasis, underlying infectious process not excluded. Findings: There relatively low lung volumes. **There is increased opacity projecting over the right hemi thorax** likely due to increased right pleural effusion with overlying atelectasis, underlying infectious process not excluded. Possible trace left pleural effusion. The cardiac silhouette is top-normal to mildly enlarged. Mediastinal contours are unremarkable. No pneumothorax is seen.

Few-shot mixed examples prompt:

Impression: **Bilateral interstitial opacities, potentially indicating interstitial lung disease or atypical infection**, Findings: **Frontal view of the chest shows bilateral interstitial opacities**, more prominent in the upper lobes. The cardiomeastinal silhouette is within normal limits. Pulmonary vasculature appears normal. Possible show pleural effusion. No evidence of pneumothorax. The diaphragms are at the appropriate levels, and bony thorax appears intact with no obvious fractures.

Few-shot normal examples prompt:

Impression: No acute cardiopulmonary abnormalities detected. Findings: **The lungs are clear without evidence of focal consolidation, pleural effusion, or pneumothorax**. The cardiomeastinal silhouette is within normal limits. No prominent hilar or mediastinal lymphadenopathy is seen. There is no evidence of pulmonary edema. The visualized bony structures appear intact without acute fractures or lesions. The imaged upper abdomen is unremarkable.

Few-shot abnormal examples prompt:

Impression: **Bilateral patchy opacities observed**, possibly indicative of a pneumonia or interstitial lung disease. Elevated right hemidiaphragm. Findings: The provided chest X-ray demonstrates bilateral patchy opacities predominantly involving the upper and mid lung zones. The right hemidiaphragm appears elevated compared to the left, suggesting possible diaphragmatic dysfunction or underlying right basal atelectasis. The heart size appears within normal limits. No overt pleural effusion is noted. The cardiomeastinal silhouette is unremarkable without any significant lymphadenopathy. The osseous structures are intact with no evident bony pathology.

Figure 14: Few-shot abnormal case. GPT-4V is more likely to generate normal reports when the prompt includes two normal examples. The sentences highlighted in red in the figure correspond to descriptions of normal conditions.

Viewpoints information case 2

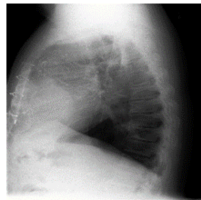
<p>Text-Prompt:</p> <p><i>You are a professional radiologist. I will provide you with some chest X-ray images. Please generate a radiology report based on the provided image. You should only generate reports and no other unnecessary information. The format of the output report should be similar to the example:</i></p> <p><i>Examples:</i> =====</p> <p><i>Example 1</i></p> <p><i>Example 2</i></p>	<p>Image:</p> 
<p>Ground Truth:</p> <p>Impression: No significant change since the prior study and no evidence of overt pulmonary edema. Findings: Since the prior radiograph there has been no significant change. There is no focal consolidation, pleural effusion, pneumothorax or pulmonary edema. Cardiomediastinal silhouette is unchanged and notable for tortuous aorta and mild cardiomegaly. Median sternotomy wires are present and intact. Clips are seen in the midline of the thorax. Bony structures are intact.</p>	
<p>Few-shot mixed examples prompt:</p> <p>Impression: Mild left-sided perihilar opacification, possibly representing atelectasis or infection. Findings: Frontal view of the chest reveals an opacification in the left perihilar region, which could represent atelectasis or an infectious process. The cardiomeastinal silhouette appears normal. Pulmonary vasculature is within normal limits. No signs of pneumothorax or pleural effusion are noted. The bony structures are unremarkable without any obvious fractures or dislocations.</p>	
<p>Few-shot normal examples prompt:</p> <p>Impression: Evidence of increased opacity in the left lung. Findings: The lung volumes appear to be within normal limits. There is increased opacity noted in the left mid and lower lung zones, suggesting possible consolidation or atelectasis. The cardiomeastinal silhouette is within normal limits. No visible pleural effusion or pneumothorax. The imaged upper abdomen is unremarkable. No evidence of bony abnormalities.</p>	
<p>Few-shot abnormal examples prompt:</p> <p>Impression: Diffuse haziness observed in the right lung field, suggestive of a possible consolidation or infiltrate. Findings: The image displays the chest in a PA orientation. The left lung appears largely clear without evidence of focal consolidation. The right lung field shows diffuse haziness which may represent consolidation or infiltrates. The cardiomeastinal silhouette appears unremarkable. The heart size appears within normal limits. No overt evidence of pneumothorax or pleural effusion on the visualized portions. Further clinical correlation and additional imaging modalities may be warranted to ascertain the underlying pathology.</p>	

Figure 15: Viewpoint information Case 2. While GPT-4V provides view information, it is inaccurate.