

Diagnostic Accuracy of Carotid Plaque Instability by Noninvasive Imaging: A Systematic Review and Meta-analysis

David Pakizer, MSc^a; Jiří Kozel, MSc^a; Patrick Taffé, MSc, PhD^b; Jolanda Elmers^c; Janusz Feber, Prof, MD^a; Patrik Michel, Prof, MD^d; David Školoudík, Prof, MD, PhD^{a*}; Gaia Sirimarco, MD, PhD^{d*}

a Center for Health Research, Faculty of Medicine, University of Ostrava, Ostrava, Czech Republic

b Center for Primary Care and Public Health, Division of Biostatistics, University of Lausanne, Lausanne, Switzerland

c Medical Library, Lausanne University Hospital and University of Lausanne, Lausanne, Switzerland

d Stroke Center, Service of Neurology, Department of Clinical Neurosciences, Lausanne University Hospital, Lausanne, Switzerland

(* = equal contribution)

Short title: Carotid plaque instability imaging: meta-analysis

Corresponding author

Prof. David Školoudík, M.D., Ph.D., FESO, FEAN

Centre for Health Research

Faculty of Medicine, University of Ostrava

Syllabova 19, CZ-703 00 Ostrava, Czech Republic

E-mail: skoloudik@hotmail.com

Tel: +420597375613, Fax: +420597375614

Total word count: 5997

Abstract

Background: There is increasing evidence that plaque instability in the extracranial carotid artery may lead to an increased stroke risk independently of the degree of stenosis. We aimed to determine diagnostic accuracy of vulnerable and stable plaque using noninvasive imaging modalities when compared to histology in patients with symptomatic and asymptomatic carotid atherosclerosis.

Methods: Medline Ovid, Embase, Cochrane Library, and Web of Science were searched for diagnostic accuracy of noninvasive imaging modalities (CT, MRI, US) in the detection of 1) vulnerable/stable plaque, and 2) vulnerable/stable plaque characteristics, compared to histology. The quality of included studies was assessed by QUADAS-2 and univariate and bivariate random-effect meta-analyses were performed.

Results: We included 36 vulnerable and 5 stable plaque studies in the meta-analysis, and out of 211 plaque characteristics from remaining studies, we classified 169 as vulnerable and 42 as stable characteristics (28 CT, 120 MRI, 104 US characteristics). We found that MRI had high accuracy (90% [95% CI:82–95%]) in the detection of vulnerable plaque, similar to CT (86% [95% CI:76–92%]; $p>0.05$), whereas US showed less accuracy (80% [95% CI:75–84%]; $p=0.013$). CT showed a high diagnostic accuracy to visualize characteristics of vulnerable or stable plaques (89% and 90%) similar to MRI (86% and 89%; $p>0.05$); however US had lower accuracy (77%, $p<0.001$ and 82%, $p>0.05$).

Conclusions: CT and MRI have a similar, high performance to detect vulnerable carotid plaques, whereas US showed significantly less diagnostic accuracy. Moreover, MRI visualized all vulnerable plaque characteristics allowing for a better stroke risk assessment.

Registration: PROSPERO ID CRD42022329690

(https://www.crd.york.ac.uk/prospero/display_record.php?RecordID=329690)

Keywords

Computed tomography, Magnetic resonance imaging, Ultrasound, Carotid atherosclerosis, Plaque instability.

Nonstandard Abbreviations

IPH = intraplaque hemorrhage

LRNC = lipid-rich necrotic core

US = ultrasound

PRISMA = Preferred Reporting Items for Systematic Reviews and Meta-analyses

STARD = Standards for Reporting of Diagnostic Accuracy Studies

QUADAS = Quality Assessment of Diagnostic Accuracy Studies

HSROC = hierarchical summary receiver operating characteristic

Introduction

Carotid artery atherosclerosis is one of the main causes of ischemic stroke in adults and also a marker of vascular health and for risk assessment.¹ In addition to the degree of focal carotid stenosis, plaque components are important risk factors for plaque instability and subsequent risk of transient ischemic attack or stroke.

Vulnerable or unstable plaques are plaques with a high likelihood of rapid progression, and a substantial risk of ruptures subsequently leads to thrombus formation and symptoms.²⁻⁵ Therefore, detection of plaque characteristics may help to identify patients at high risk for cerebrovascular events.

In general, a vulnerable plaque is characterized by the presence of intraplaque hemorrhage (IPH), a thin or ruptured fibrous cap overlying a large lipid-rich necrotic core (LRNC), inflammation and neovascularization, and an ulcerated or fissured surface.⁶⁻⁸ It has been demonstrated that an increasing size of LRNC and presence of thin/ruptured fibrous cap are strongly associated with risk of stroke.⁹⁻¹⁰ Moreover, the presence of IPH predicted plaque progression and cerebrovascular events in asymptomatic and symptomatic patients with a hazard ratio of 3.6 and of 4.8, respectively.¹¹⁻¹³ Inflammation also plays an important part in the risk of plaque instability by causing structural changes in the vessel wall, destabilization and plaque rupture.¹⁴ On the other hand, fibrous tissue provides structural integrity of a stable carotid plaque and calcification is considered to be the main marker of stability, when lipids are either absent or present in only small amounts.¹⁴⁻¹⁵

Therefore, the performance of diagnostic imaging techniques to evaluate carotid plaques can have a major impact on risk assessment and management of patients. Noninvasive modalities such as ultrasound (US), computed tomography (CT) and magnetic resonance imaging (MRI) play a key role, because of their availability and high diagnostic accuracy.¹⁶

The aim of this study was to determine diagnostic accuracy of noninvasive imaging modalities (US, CT, MRI) for vulnerable and stable carotid atherosclerotic plaques compared to histology in adult patients with symptomatic and asymptomatic carotid plaques.

Methods

PROSPERO (International Prospective Register of Systematic Reviews) was used for the prospective registration of our study (ID CRD42022329690).¹⁷ This systematic review and meta-analysis was performed according to the PRISMA (Preferred Reporting Items for Systematic Reviews and Meta-analyses) 2020 statement¹⁸ and the STARD (Standards for Reporting of Diagnostic Accuracy Studies) 2015 statement.¹⁹

Study eligibility criteria

We included human studies that investigated atherosclerotic carotid artery disease *in vivo* using selected noninvasive modalities (US, CT or MRI as index test) to assess plaque composition compared to histology. Inclusion criteria were as follows: human subject research studies (retrospective or prospective); age of patients ≥ 18 years; studies evaluating patients with an atherosclerotic plaque in the cervical carotid arteries, including the extracranial internal and/or common carotid artery; studies using US, CT or MRI at the cervical carotid arteries to assess specific plaque features; studies that investigated correlations of the characteristics of the index plaque with histological analysis of the plaque (specimens were obtained from carotid endarterectomy or autopsy); reported number of true positive (TP), false positive (FP), false negative (FN), and true negative (TN) results for the diagnosis of any plaque characteristic, and available data to calculate sensitivity and specificity.

Histology was used as the reference standard for the evaluation of plaque composition. Studies with a time window > 4 weeks (1 month) between carotid plaque imaging and histological assessment were excluded.

Database searching

A systematic search strategy to find eligible studies was designed by a medical librarian (J.E.), using a combination of controlled vocabulary terms and free text terms covering the four overarching concepts of the study: "atherosclerotic carotid artery disease" AND "atherosclerotic plaque" AND "Imaging" AND "histology". The search strategy was translated for the following databases: Medline Ovid ALL, Embase.com, Central – Cochrane Library Wiley, and Web of Science Core collection. A second medical librarian peer-reviewed all search equations before the searches were conducted (27/06/2022). Searches were performed without limits for publication date or language and the search strategies and search engines are available in the Supplement material.²⁰ Deduplication from downloaded references from databases was done using EndNote. As a complementary search: a search strategy was designed and used for Google Scholar, where the first 500 references were screened with no study selected for inclusion; citation searches on key studies were conducted.

Two independent reviewers (D.P., J.K.) screened the references in three phases (title/abstract, full-text, and detailed analysis during data extraction) according to the inclusion and exclusion criteria. Systematic process and blinded screening were performed using Rayyan²¹, and all disagreements were resolved by consensus.

Assessment of risk of bias

For the assessment of study quality including the risk of bias and applicability concerns of included studies, the QUADAS-2 tool (Quality Assessment of Diagnostic Accuracy Studies)²² was used by two blinded investigators (D.P., G.S.). We excluded studies

with a high risk of bias from our meta-analysis, whereas studies with an unclear risk of bias were marked and included in the analysis, along with studies labeled as low risk. The evaluation of noninvasive imaging (index test) of carotid plaques was blinded to histological evaluation (reference test) in studies.

Data extraction

TP, TN, FP, and FN outcomes, and sensitivity and specificity were extracted from included studies by two independent readers (D.P., J.K.). The data extraction was performed according to the following criteria: when different techniques for plaque characteristic imaging were used in a study, we extracted data separately for each imaging modality; when the results of multiple reviewers were published in a study, we extracted one value as the sum of the results; when several different accuracy values were given based on cutoff points, the highest accuracy was extracted; when multiple plaque characteristics by imaging were compared to one plaque characteristic by pathology or one plaque characteristic by imaging compared to multiple plaque characteristics by histology, the finding with the highest accuracy was extracted to minimize the risk of bias in the calculation of the overall diagnostic accuracy of plaque characteristics; the study with the largest sample size was included to minimize duplicates or overlapping samples when authors published data from a single cohort or medical center more than once.

Disagreements between two readers were solved by consensus or by an independent decision of two senior team members (P.M., D.Š.) in all phases (reference screening, risk of bias, data extraction).

Plaque instability and plaque characteristics

In *analysis 1*, we analyzed data of studies in which the investigators classified the plaques based on histology as vulnerable or stable according to their own definition, and evaluated the accuracy of MRI, CT, and/or US with regard to this histological classification.

In *analysis 2*, we first selected all studies in which specific histological plaque characteristics were assessed and studied the correlations of these plaque characteristics with MRI, CT, and/or US. Then we classified these studies into groups of vulnerable and stable plaque characteristics based on histology and evaluated the accuracy of imaging techniques. Vulnerable plaque characteristics were IPH (overall, acute/fresh, subacute/recent, old), LRNC, ruptured fibrous cap, ulceration, inflammation, and neovascularization, as in previous publications.^{3-5,23} In contrast, stable plaque characteristics were a predominant fibrous part, calcifications, intact fibrous cap, and loose matrix. If we found that some characteristic was alternatively considered to be vulnerable and stable in different published studies, we searched for more studies. For inclusion of the characteristic into one of the two groups, we had to find at least 80% studies indicating that the plaque characteristic was considered as stable, respective vulnerable. The assignment of a specific characteristics to one of the two groups also reflected the definitions used by investigators of the studies included in *analysis 1*.

Statistics

Only studies with available data to calculate sensitivity and specificity and/or numbers of TP, TN, FP, and FN for any plaque characteristics were included in the meta-analysis. In case of incomplete data, corresponding or first authors were contacted to obtain the required information. In addition, we used formulas to compute TP, FP, FN, and TN values based on numbers of sensitivity, specificity, prevalence, positive predictive value, and negative predictive value.

First, we conducted separate univariate random-effects analyses of sensitivity and specificity to investigate the presence of heterogeneity in each index.²⁴ Then, Rutter and Gatsonis's hierarchical summary receiver operating characteristic (HSROC) curves were

estimated for each imaging modality based on the bivariate random-effects model.²⁵⁻²⁶ The diagnostic performance (i.e. sensitivity and specificity) of the imaging modalities was assessed by comparing the HSROC curves. To facilitate the interpretation of results, the accuracy was also analyzed using univariate random-effects analyses based on the binomial distribution and logit transformation.

The pointwise confidence bands around the summary ROC curves were computed based on the multivariate delta method and tests of equality of the curves of Wald statistics. Studies reporting several pairs of sensitivity and specificity (because of the use of different imaging intensities) were considered independent given the sparsity of the data and convergence issues due to the complexity of the models. P-values < 0.05 were considered to indicate statistical significance.

The between-study variance τ^2 was used to assess the heterogeneity. All the analyses were performed using Stata version 17 (Stata Corporation, College Station, TX, USA).

Results

We identified 5960 studies by the literature search in four large databases. Supplementary searches were conducted in Google Scholar along with citation searching and five more studies were included. Finally, after the three-phase screening, 109 studies were found eligible. The details of the search strategy and study inclusion are presented in the PRISMA flow diagram in Figure 1 and in the Supplement.

Before qualitative analysis, we evaluated the quality of the included studies and the possible risk of bias using QUADAS-2. Of the 109 included studies, we found two studies with a high risk of bias that we excluded. The overall results of the QUADAS-2 evaluation

are presented in Figure 2 and detailed results are available in the Supplement (Data and Table S1).

For the qualitative analysis (meta-analysis) of the diagnostic accuracy in the included 107 studies, we found a total of 253 specific comparisons (28 CT, 120 MRI, and 105 US studies) of plaque instability and plaque characteristics from 6136 patients (Tables S2 and S3).

For *analysis 1* looking at classifying *plaques according to author-defined instability*, we identified 36 comparisons of vulnerable plaques and/or five comparisons of stable plaques in a total of 20 studies. The studies with the imaging technique taken into account, and definitions used for histological and imaging classification of plaques into vulnerable and stable are shown in Table 1, and the diagnostic accuracy of each comparison is shown in Figures 3, S3 and S4.

For *analysis 2* assessing *several plaque characteristics*, the 212 remaining comparisons were divided into vulnerable (169) and stable (42) plaques as depicted in Table S3. One characteristic with insufficient details (mixed plaque) was excluded. Details of all evaluated characteristics by studies are available in Table S2. Most of the studies evaluated multiple characteristics.

Univariate analyses

In *analysis 1* (*plaque instability according to the author's definition*), we found that MRI had a very high diagnostic accuracy in visualizing vulnerable plaque, with a pooled accuracy of 90%, followed by CT (86%) and US (80%) as presented in Figure 4 and Table 2. Regarding the imaging of stable plaques, a very high accuracy was noted in one identified MRI study (95%). No CT-based study was found, and four US-based studies yielded an accuracy of 81% (Figure S5, Table 2).

In *analysis 2 (several plaque characteristics)*, CT had the highest accuracy in the detection of vulnerable and stable carotid plaque characteristics (89% and 90%, respectively). However, the results with CT showed a wider range of the 95% confidence interval (CI) (84–92%) for vulnerable plaque characteristics compared to MRI (84–88%) and even for stable plaque characteristics (66–98% with CT vs 85–92% with MRI). CT and MRI had similar accuracy for vulnerable (89% and 86%, respectively) and stable (90% and 89%, respectively) plaque characteristics. Findings with the US modality showed the lowest sensitivity and specificity of all studied modalities in the diagnosis of vulnerable (specificity 79% and specificity 76%) and stable plaque characteristics (specificity 77% and specificity 86%). Detailed data are available in Table 2.

Bivariate analyses

For *analysis 1* regarding vulnerable plaque, Figure 4 (top) shows that CT and MRI always outperform US by a higher specificity for a given sensitivity: the overall comparison of the three curves resulted in $p=0.013$, between CT and MRI in $p=0.907$, between CT and US in $p=0.432$, and between MRI and US in $p=0.003$. For stable plaque (Figure S5, top), it was only possible to estimate an HSROC curve for the US modality.

For *analysis 2*, Figure 4 (bottom) shows that CT and MRI again were the most accurate imaging techniques for detecting vulnerable plaque characteristics, with the US modality always showing the lowest specificity. The comparison between the three curves resulted in $p<0.001$, between CT and MRI in $p=0.201$, between CT and US in $p<0.001$, and between MRI and US in $p<0.001$. For stable plaque characteristics (Figure S5, bottom), the comparison between the three curves showed $p=0.146$, between CT and MRI $p=0.812$, between CT and US $p=0.287$, and between MRI and US $p=0.054$. This is in line with the results regarding the accuracy parameters provided in Table 2.

Finally, Figures S6–S8 show that there was large heterogeneity among the studies for all three imaging techniques.

Discussion

Our study showed that the CT imaging technique had the highest accuracy for detecting vulnerable plaque and vulnerable plaque characteristics, not statistically significant, and the MRI was able to identify all vulnerable plaque characteristics with similar accuracy as CT. Regarding the stable plaque characteristics, CT and MRI showed almost the same accuracy (90% vs 89%, respectively). US proved to have significantly lower performance for detection of vulnerable plaque/plaque characteristics and nonsignificantly lower diagnostic accuracy for detection of stable plaque characteristics.

Although some studies have suggested that CT performs less well in identifying high-risk plaque characteristics,²⁷ in our study CT showed good diagnostic accuracy in visualizing both vulnerable and stable plaque. Previous systematic reviews confirmed that CT is an accurate noninvasive modality in atherosclerotic lesions evaluation.²⁸ However, compared to MRI, CT failed to detect all vulnerable components, but the most common at-risk plaque characteristics (IPH, LRNC, or ulceration) could be identified. CT may represent a good choice in carotid plaque diagnostics due to its excellent spatial resolution, precision, and widespread availability and short examination time.²⁹ It also has been demonstrated that the identification of vulnerable characteristics using CT can predict 10-year atherosclerotic cardiovascular disease risk.³⁰⁻³¹ According to our results, CT is an accurate diagnostic modality to evaluate vulnerable or stable plaque with an accuracy of 89% and 90%, respectively.

MRI demonstrated the highest performance with good diagnostic accuracy for most plaque characteristics in our study and a previous one.¹⁶ Imaging of carotid arteries by MRI is an established, fast, reliable, and accurate diagnostic modality, which has many advantages over other imaging techniques. Most of the known vulnerable and stable plaque characteristics can be visualized using MRI.³² The results of our meta-analysis confirmed these previously reported results because MRI visualized all 13 vulnerable and stable plaque characteristics evaluated in the included studies (compared to 5 using CT and 9 using US). It was proven that MRI is a good accurate noninvasive imaging modality for vulnerable plaque diagnosis (accuracy of 90% compared to 86% of CT and 80% of US). We could not assess the performance of MRI for the detection of stable plaques as there was only one MRI study that evaluated stable plaque (sensitivity 93%, specificity 100%). It was demonstrated that CT was a useful modality to visualize both vulnerable and stable plaque characteristics.

Imaging by the US technique is widely employed in clinical practice and often represents the first choice of carotid artery stenosis examination, because of low cost, its repeatability and there are no contraindications.³³ Therefore, US is recommended as a screening modality for carotid atherosclerosis.³⁴ In our study, US was the noninvasive imaging modality with less diagnostic accuracy for stable or vulnerable carotid plaque features. Nevertheless, the accuracy compared to histology as the reference standard was still high (over 75%). US could be used as a screening and first-line modality to assess carotid plaque instability or plaque progression.

There were several limitations that must be taken into account. First, we did not analyze different imaging techniques separately (e.g. non non-contrast US and contrast-enhanced US; MRI sequences) or different used thresholds separately which may represent a potential bias. However, the objective of the meta-analysis was to provide the overall diagnostic accuracy of noninvasive imaging modalities, regardless of differences between

techniques or cutoff points. Second, the accuracy of imaging modalities with better resolution increased over time due to technical progress. Therefore, older included studies may have influenced the results of the overall accuracy of imaging modalities. Third, the publication date of the included studies in the analysis was not restricted. Although this point could have led to a potential bias due to advances in imaging technology, Figures S1 and S2 showed that the diagnostic accuracy of the studies included in the stable or vulnerable plaque characteristics group not changed clearly over time. Finally, a few studies were available for certain characteristics, therefore the diagnostic accuracy may be less reliable.

Conclusion

In our study, it was proven that CT and MRI were good noninvasive modalities for detection of vulnerable plaques with similar, high diagnostic accuracy. However, all vulnerable plaque characteristics were visualized with MRI leading to a comprehensive assessment of plaque instability. The US technique showed significantly less accuracy and could be considered for baseline screening and follow-up. CT and MRI should be used to better identify plaque instability and guide management to reduce the stroke risk.

Acknowledgment

We are very thankful to Aristeidis H. Katsanos, Karen Von Deneen, Di Dong, Yukari Yamada, Šárka Kostecká and Cecile Jaques for their help with our study.

Sources of funding

None related to the research, authorship, and/or publication of this article. David Pakizer was supported by VIA PhD grant University of Ostrava for travel related to this analysis. Statistical analysis was supported by grants NV19-04-00270, NU22-04-00389, SGS11/LF/2022; and by University of Lausanne, Faculty of Biology and Medicine.

Disclosures

None.

Supplemental material

Supplemental Statistics

Supplemental Results

Tables S1–S3

Figures S1–S8

References S1–S117

References

1. RANGEL-CASTILLA L, P NAKAJI, AH SIDDIQUI, et al. Decision Making in Neurovascular Disease. Stuttgart: Thieme, 2018.
2. RUSSO C, Z JIN, T RUNDEK, S HOMMA, et al. Atherosclerotic Disease of the Proximal Aorta and the Risk of Vascular Events in a Population-Based Cohort. *Stroke*. 2009. 40(7):2313-2318.
3. MORENO PR. Vulnerable Plaque: Definition, Diagnosis, and Treatment. *Cardiol Clinics*. 2010, 28(1):1-30.
4. SABA L, T SAAM, HR JÄGER, et al. Imaging biomarkers of vulnerable carotid plaques for stroke risk prediction and their potential clinical implications. *Lancet Neurol*. 2019, 18(6):559-572.
5. KUME S, S HAMA, K YAMANE, et al. Vulnerable carotid arterial plaque causing repeated ischemic stroke can be detected with B-mode ultrasonography as a mobile component: Jellyfish sign. *Neurosurg Rev*. 2010, 33(4):419-430.
6. MUGHAL MM, MK KHAN, JK DEMARCO, et al. Symptomatic and asymptomatic carotid artery plaque. *Expert Rev Cardiovasc Ther*. 2014, 9(10):1315-1330.
7. NAGHAVI M, P LIBBY, E FALK, et al. From Vulnerable Plaque to Vulnerable Patient: A Call for New Definitions and Risk Assessment Strategies: Part I. *Circulation*. 2003, 108(14):1664–1672.
8. SABA L, M ANZIDEI, BC MARINCOLA, et al. Imaging of the Carotid Artery Vulnerable Plaque. *Cardiovasc Intervent Radiol*. 2014, 37(3):572-585.
9. SUN J, XO ZHAO, N BALU, et al. Carotid Plaque Lipid Content and Fibrous Cap Status Predict Systemic CV Outcomes. *JACC Cardiovasc Imaging*. 2017, 10(3):241-249.
10. SPAGNOLI LG. Extracranial Thrombotically Active Carotid Plaque as a Risk Factor for Ischemic Stroke. *JAMA*. 2004, 292(15):1845-1852.

11. SINGH N, AR MOODY, DJ GLADSTONE, et al. Moderate Carotid Artery Stenosis: MR Imaging–depicted Intraplaque Hemorrhage Predicts Risk of Cerebrovascular Ischemic Events in Asymptomatic Men. *Radiology*. 2009, 252(2):502-508.
12. ALTAF N, ST MACSWEENEY, J GLADMAN and DP AUER. Carotid Intraplaque Hemorrhage Predicts Recurrent Symptoms in Patients With High-Grade Carotid Stenosis. *Stroke*. 2007, 38(5):1633-1635.
13. TAKAYA N, C YUAN, B CHU, et al. Presence of Intraplaque Hemorrhage Stimulates Progression of Carotid Atherosclerotic Plaques. *Circulation*. 2005, 111(21):2768-2775.
14. VAN DER WAL AC. Atherosclerotic plaque rupture – pathologic basis of plaque stability and instability. *Cardiovasc Research*. 1999, 41(2):334-344.
15. NANDALUR KR, AD HARDIE, P RAGHAVAN, et al. Composition of the Stable Carotid Plaque. *Stroke*. 2007, 38(3):935-940.
16. HUIBERS A, GJ DE BORST, S WAN, et al. Non-invasive Carotid Artery Imaging to Identify the Vulnerable Plaque: Current Status and Future Goals. *Eur J Vasc Endovasc Surg*. 2015, 50(5):563-572.
17. PAKIZER D, P MICHEL, G SIRIMARCO, et al. Sensitivity and Specificity of Atherosclerotic Plaque Components in Carotid Arteries Detectable by CT, MRI, and Sonography – Comparison with Histology: A Systematic Review and Meta-analysis. *PROSPERO*. 2022.
18. PAGE MJ, JE MCKENZIE, PM BOSSUYT, et al. The PRISMA 2020 statement: an updated guideline for reporting systematic reviews. *BMJ*. 2021, 372(n71):1-9.
19. COHEN JF, DA KOREVAAR, DG ALTMAN, et al. STARD 2015 guidelines for reporting diagnostic accuracy studies: explanation and elaboration. *BMJ Open*. 2016, 6(11):1-17.

20. PAKIZER D, G SIRIMARCO, J ELMERS et al. Search strategies related to: Sensitivity and Specificity of Atherosclerotic Plaque Components in Carotid Arteries Detectable by CT, MRI, PET, and Sonography – Comparison with Histology: A Systematic Review and Meta-analysis (Version 1). *Zenodo*. 2022.
21. OUZZANI M, Hossam H, Z FEDOROWICZ and A ELMAGARMID. Rayyan—a web and mobile app for systematic reviews. *Syst Rev*. 2016, 5(1):1-10.
22. WHITING PF. QUADAS-2: A Revised Tool for the Quality Assessment of Diagnostic Accuracy Studies. *Ann Intern Med*. 2011, 155(8):529-536.
23. SABA L, AR MOODY, T SAAM, et al. Vessel Wall–Imaging Biomarkers of Carotid Plaque Vulnerability in Stroke Prevention Trials. *JACC Cardiovasc Imaging*. 2020, 13(11):2445-2456.
24. TAKWOINGI Y, RD RILEY and JJ DEEKS. Meta-analysis of diagnostic accuracy studies in mental health. *Evid Based Ment Health*. 2015, 18(4):103-109.
25. RUTTER CM and CA GATSONIS. A hierarchical regression approach to meta-analysis of diagnostic test accuracy evaluations. *Stat Med*. 2001, 20(19):2865-2884.
26. ARENDS LR, TH HAMZA, JC VAN HOUWELINGEN, et al. Bivariate Random Effects Meta-Analysis of ROC Curves. *Med Decis Making*. 2008, 28(5):621-638.
27. REHMAN ZU. Vulnerable Carotid Artery Plaques in Asymptomatic Patients—A Narrative Review. *Arab J Intervent Radiol*. 2022, 06(01):21-24.
28. HOLLINGWORTH W, AB NATHENS, JP KANNE, et al. The diagnostic accuracy of computed tomography angiography for traumatic or atherosclerotic lesions of the carotid and vertebral arteries: a systematic review. *Eur J Radiol*. 2003, 48(1):88-102.
29. MURGIA A, M ERTA, JS SURI, et al. CT imaging features of carotid artery plaque vulnerability. *Ann Transl Med*. 2020, 8(19):1261-1274.

30. SHEAHAN M, X MA, D PAIK, et al. Atherosclerotic Plaque Tissue: Noninvasive Quantitative Assessment of Characteristics with Software-aided Measurements from Conventional CT Angiography. *Radiology*. 2018, 286(2):622-631.
31. LI Y, G ZHU, V DING, et al. Carotid Artery Imaging Is More Strongly Associated With the 10-Year Atherosclerotic Cardiovascular Disease Score Than Coronary Artery Imaging: comparison between monochromatic and polychromatic energies with pathology correlation. *J Comput Assist Tomogr*. 2019, 43(5):679-685.
32. SINGH N, AR MOODY, I ROIFMAN, et al. Advanced MRI for carotid plaque imaging. *Int J Cardiovasc Imaging*. 2016, 32(1):83-89.
33. ZHANG L, X LI, Q LYU and G SHI. Imaging diagnosis and research progress of carotid plaque vulnerability. *J Clin Ultrasound*. 2022, 50(7):905-912.
34. STEIN JH, CE KORCARZ, RT HURST, et al. Use of Carotid Ultrasound to Identify Subclinical Vascular Disease and Evaluate Cardiovascular Disease Risk: A Consensus Statement from the American Society of Echocardiography Carotid Intima-Media Thickness Task Force Endorsed by the Society for Vascular Medicine. *J Am Soc Echocardiogr*. 2008, 21(2):93-111.
35. DI LEO N, L VENTURINI, V DE SOCCIO, et al. Multiparametric ultrasound evaluation with CEUS and shear wave elastography for carotid plaque risk stratification. *J Ultrasound*. 2018, 21(4):293-300.
36. LUKANOVA DV, NK NIKOLOV, KZ GENOVA, et al. The Accuracy of Noninvasive Imaging Techniques in Diagnosis of Carotid Plaque Morphology. *Open Access Maced J Med Sci*. 2015, 3(2):224-230.
37. GRAY-WEALE AC, JC GRAHAM, JR BURNETT, et al. Carotid artery atheroma: comparison of preoperative B-mode ultrasound appearance with carotid endarterectomy specimen pathology. *J Cardiovasc Surgery (Torino)*. 1988, 29(6):676-681.

38. STARY HC, AB CHANDLER, RE DINSMORE, et al. A Definition of Advanced Types of Atherosclerotic Lesions and a Histological Classification of Atherosclerosis. *Circulation*. 1995, 92(5):1355-1374.
39. CAPPENDIJK VC, KBJM CLEUTJENS, AGH KESSELS, et al. Assessment of Human Atherosclerotic Carotid Plaque Components with Multisequence MR Imaging: Initial Experience. *Radiology*. 2005, 234(2):487-492.
40. HONDA M, I KAWAHARA, N KITAGAWA, et al. Asymptomatic carotid artery plaques: use of magnetic resonance imaging to characterize vulnerable plaques in 6 cases. *Surg Neurol*. 2007, 67(1):35-39.
41. MILLON A, L BOUSSEL, M BREVET, et al. Clinical and Histological Significance of Gadolinium Enhancement in Carotid Atherosclerotic Plaque. *Stroke*. 2012, 43(11):3023-3028.
42. LOVETT JK, PJ GALLAGHER, LJ HANDS, et al. Histological Correlates of Carotid Plaque Surface Morphology on Lumen Contrast Imaging. *Circulation*. 2004, 110(15):2190-2197.
43. WATANABE Y, M NAGAYAMA, T SUGA, et al. Characterization of atherosclerotic plaque of carotid arteries with histopathological correlation: Vascular wall MR imaging vs. color Doppler ultrasonography (US). *J Magn Reson Imaging*. 2008, 28(2):478-485.
44. GEROULAKOS G, G RAMASWAMI, A NICOLAIDES, et al. Characterization of symptomatic and asymptomatic carotid plaques using high-resolution real-time ultrasonography. *Br J Surg*. 1993, 80(10):1274-1277.
45. YOSHIDA K, M GOTO, T FUNAKI, et al. Noninvasive carotid plaque characterization by black blood MRI. *No Shinkei Geka*. 2005, 33(3):235-241.

46. YOSHIDA K, O NARUMI, M CHIN, et al. Characterization of Carotid Atherosclerosis and Detection of Soft Plaque with Use of Black-Blood MR Imaging. *AJNR*. 2008, 29(5):868-874.
47. YUAN C, LM MITSUMORI, MS FERGUSON, et al. In Vivo Accuracy of Multispectral Magnetic Resonance Imaging for Identifying Lipid-Rich Necrotic Cores and Intraplaque Hemorrhage in Advanced Human Carotid Plaques. *Circulation*. 2001, 104(17):2051-2056.
48. BALZER K. PTA oder Operation bei der Therapie von Karotisstenosen?. *Herz*. 2004, 29(1):90-103.
49. DENZEL C, F FELLNER, R WUTKE, et al. Ultrasonographic analysis of arteriosclerotic plaques in the internal carotid artery. *Eur J Ultrasound*. 2003, 16(3):161-167.
50. HUANG S, X WU, L ZHANG, et al. Assessment of Carotid Plaque Stability Using Contrast-Enhanced Ultrasound and Its Correlation With the Expression of CD147 and MMP-9 in the Plaque. *Front Comput Neurosci*. 2021, 15:778946.
51. FABIANI, I, C PALOMBO, D CARAMELLA, et al. Imaging of the vulnerable carotid plaque. *Neurology*. 2020, 94(21):922-932.
52. NAGHAVI M, P LIBBY, E FALK, et al. From Vulnerable Plaque to Vulnerable Patient. *Circulation*. 2003, 108(14):1664-1672.
53. IEZZI R, G PETRONE, A FERRANTE, et al. The role of contrast-enhanced ultrasound (CEUS) in visualizing atherosclerotic carotid plaque vulnerability: Which injection protocol? Which scanning technique?. *Eur J Radiol*. 2015, 84(5):865-871.
54. KIM GE, YP CHO, TW KWON, et al. B-mode Ultrasound Imaging in Symptomatic Internal Carotid Artery Stenosis: Correlation with Clinical and Operative Findings. *Vasc Surg*. 1999, 33(6):611-616.

55. LI H, Y KAN, B NING, et al. Correlations of contrast enhanced ultrasound manifestations, pathological features and vulnerability of carotid artery plaque. *Chinese J Med Imaging Technol.* 2021, 37(6):857-861.
56. LIU F, Q YONG, Q ZHANG, et al. Real-Time Tissue Elastography for the Detection of Vulnerable Carotid Plaques in Patients Undergoing Endarterectomy: A Pilot Study. *Ultrasound Med Biol.* 2015, 41(3):705-712.
57. ITOH A, E UENO, E TOHNO, et al. Breast Disease: Clinical Application of US Elastography for Diagnosis. *Radiology.* 2006, 239(2):341-350.
58. LYU Q, X TIAN, Y DING, et al. Evaluation of Carotid Plaque Rupture and Neovascularization by Contrast-Enhanced Ultrasound Imaging: an Exploratory Study Based on Histopathology. *Transl Stroke Res.* 2021, 12(1):49-56.
59. REDGRAVE JNE, JK LOVETT, PJ GALLAGHER and PM ROTHWELL. Histological Assessment of 526 Symptomatic Carotid Plaques in Relation to the Nature and Timing of Ischemic Symptoms. *Circulation.* 2006, 113(19):2320-2328.
60. MURAKI M, T MIKAMI, T YOSHIMOTO, et al. Sonographic Detection of Abnormal Plaque Motion of the Carotid Artery: Its Usefulness in Diagnosing High-Risk Lesions Ranging from Plaque Rupture to Ulcer Formation. *Ultrasound Med Biol.* 2016, 42(2):358-364.
61. REITER M, R HORVAT, S PUCHNER, et al. Plaque imaging of the internal carotid artery - correlation of B-flow imaging with histopathology. *AJNR.* 2007, 21(8):122-126.
62. BELETSKY VY, RE KELLEY, M FOWLER and T PHIFER. Ultrasound Densitometric Analysis of Carotid Plaque Composition. *Stroke.* 1996, 27(12):2173-2177.
63. XIAOJIE T, H PINJING, L QI, et al. A feasibility study of Doppler ultrasonography in evaluating the vulnerability of carotid atherosclerotic plaque. *Chinese J Cerebrovasc Dis.* 2020, 17(6), 291-298.

Figure legends

Figure 1. PRISMA flow chart diagram describing the publication search and selection algorithm.¹⁸

Figure 2. The risk of bias and the applicability concerns of included studies according to the QUADAS-2.²²

Figure 3. Diagnostic accuracy of 41 studies included in analysis 1 (A: vulnerable, B: stable).

Figure 4. HSROC curves of analysis 1 (top) and analysis 2 (bottom) for visualization of vulnerable plaque and vulnerable plaque characteristics, respectively, based on HSROC curves.

Tables

Table 1. Studies (41 studies) identified for analysis 1 (“vulnerable” and “stable” plaques).

First author	Year	Imaging	Details of imaging	Nr of patients	Plaque characteristic (imaging)	Plaque characteristic (histology)
Vulnerable plaque						
Di Leo ³⁵	2018 ^a	CT	native CT, CTA (130 ml)	43	negative HU (pre-contrast); >20 HU CE (post-contrast)	vulnerable plaque
	2018 ^b	US	Doppler, CEUS		vulnerable plaque	
	2018 ^c		shear-wave elastography		vulnerable plaque (11-65 kPa)	
Lukanova ³⁶	2015 ^a	US	duplex B-mode, color flow and power Doppler	100	unstable plaque: type I or II by Gray-Weale ³⁷	soft unstable plaque
	2015 ^b	CT	native CT, CTA (80 ml)		unstable plaque (<149 HU)	
	2015 ^c	MRI	pre-/post-contrast T1w, ECG-triggered T2w + PDw		unstable plaque (AHA class IV-V and VI) ³⁸	
Cappendijk ³⁹	2005 ^a	MRI	quantitative analysis	11	hemorrhage and lipid core/vulnerable plaque	vulnerable plaque
	2005 ^b		semi-quantitative analysis			
Honda ⁴⁰	2006 ^a	MRI	2D TOF	17	high signal intensity	unstable plaque (AHA class \geq IV) ³⁸
	2006 ^b		PDw			
	2006 ^c		T1w			
	2006 ^d		T2w			
Millon ⁴¹	2012	MRI	3D TOF, T1w, PDw, CE-T1w	69	plaque CE	vulnerable plaque (AHA class VI or Lovett ⁴² grade 3-4)
Watanabe ⁴³	2008 ^a	US	GSM of B-mode, Doppler	57	at-risk soft plaque – type 1 or 2 by Geroulakos scale ⁴⁴	at-risk soft plaque
	2008 ^b	MRI	3D TOF, T1w, T2w		soft plaque	
Yoshida ⁴⁵	2005 ^a	MRI	ECG-gated T1w + T2w	26	soft plaque	soft plaque
Yoshida ⁴⁶	2008	MRI	3D GE, T1w, T2w	70	soft plaque (T1w cutoff: 1.25)	soft plaque
Yuan ⁴⁷	2001	MRI	3D TOF, T1w, cardiac-gated PDw + T2w	18	soft plaque	soft plaque
Balzer ⁴⁸	2004 ^a	US	B-mode,	368	soft plaque	soft plaque

			Doppler			
Denzel ⁴⁹	2003 ^a	US	B-mode GSM, duplex US	15	GSM <35	soft plaque
Huang ⁵⁰	2021 ^a	US	CEUS	38	vulnerable plaque – grade III–IV	vulnerable plaque (presence of one major or two minor criteria of Naghavi ⁵²)
	2021 ^b		2D US		vulnerable plaque (score >4 by Fabiani ⁵¹)	
Iezzi ⁵³	2015 ^a	US	low-dose early-phase (dynamic) CEUS (2 ml)	50	enhancement flow	vulnerable (unstable) plaque prone to rupture
	2015 ^b		low-dose late-phase (flash) CEUS (2 ml)		enhancement	
	2015 ^c		high-dose early-phase (dynamic) CEUS (4 ml)		enhancement flow	
	2015 ^d		high-dose late-phase (flash) CE US (4 ml)		enhancement	
Kim ⁵⁴	1999	US	duplex, Doppler	65	echolucent plaque	soft plaque
Li H. ⁵⁵	2021	US	GSM of US, color/pulsed Doppler, CE US	124	enhancement (grade II)	vulnerable plaque
Liu F. ⁵⁶	2014 ^a	US	B-mode	19	vulnerable plaque	vulnerable plaque
	2014 ^b		real-time elastography		vulnerable plaque (score of 1-3 on Itoh scale) ⁵⁷	
	2014 ^c		B-mode + real-time elastography		vulnerable plaque	
Lyu ⁵⁸	2020	US	standard US, CEUS	70	enhancement (grade 2–3)	vulnerable plaque (Oxford plaque study ⁵⁹ grade 3–4)
Muraki ⁶⁰	2016	US	standard US	50	fine trembling motion of echogenic structures inside the plaque	soft content within plaque
Reiter ⁶¹	2007 ^a	US	B-mode	28	soft plaque by Beletsky ⁶² : group 1	soft plaque/organized thrombus by Beletsky ⁶²
	2007 ^b		B-flow imaging			
Xiaojie ⁶³	2020	US	Doppler	44	vulnerable plaque (score >4 by Fabiani ⁵¹)	vulnerable plaque (presence of one major or two minor criteria of Naghavi ⁵²)
Stable plaque						
Yoshida ⁴⁵	2005 ^b	MRI	EKG-gated T1w + T2w	26	hard plaque	hard plaque
Balzer ⁴⁸	2004 ^b	US	B-mode, Doppler	368	hard plaque	hard plaque
Denzel ⁴⁹	2003 ^b	US	B-mode,	15	GSM >65	hard plaque (calcium-

			duplex US, GSM			rich)
Huang ⁵⁰	2021 ^c	US	CE US	38	stable plaque – grade I–II	stable plaque (absence of one major or two minor criteria of Naghavi ⁵²)
	2021 ^d		2D US		stable plaque (score ≤ 4 by Fabiani ⁵¹)	

CE – contrast enhanced/enhancement; ECG – echocardiography; GE – gradient echo; GSM – Gray Scale Median; HU – Hounsfield unit; IPH – intraplaque hemorrhage; TOF – time of flight, PD – proton dense

Table 2. Meta-analysis of diagnostic accuracy of vulnerable and stable plaque (analysis 1), and of vulnerable and stable plaque characteristics (analysis 2).

Plaque features	CT			MRI			US		
	Sensitivity % (95% CI) τ^2	Specificity % (95% CI) τ^2	Accuracy % (95% CI) τ^2	Sensitivity % (95% CI) τ^2	Specificity % (95% CI) τ^2	Accuracy % (95% CI) τ^2	Sensitivity % (95% CI) τ^2	Specificity % (95% CI) τ^2	Accuracy % (95% CI) τ^2
	Author-defined plaque instability (Analysis 1)								
Vulnerable plaque	86 (73-93) 0.00	87 (66-96) 0.00	86 (76-92) 0.00	91 (80-96) 1.21	91 (80-96) 1.58	90 (82-95) 0.91	84 (78-90) 0.77	73 (67-78) 0.11	80 (75-84) 0.28
Stable plaque	NA			93* (69-99) NA	100* (68-100) NA	95* (78-99) NA	75 (55-88) 0.21	81 (76-85) 0.00	81 (77-84) 0.00
Several plaque characteristics (Analysis 2)									
Vulnerable plaque characteristics	81 (74-87) 0.58	94 (87-97) 2.37	89 (84-92) 0.72	83 (81-86) 0.41	88 (86-91) 0.90	86 (84-88) 0.39	80 (75-84) 1.14	76 (71-81) 1.15	77 (74-81) 0.66
Stable plaque characteristics	87 (74-97) 0.37	93 (63-99) 5.32	90 (66-98) 3.30	83 (79-87) 0.05	92 (86-96) 1.25	89 (85-92) 0.46	75 (67-82) 0.38	86 (78-91) 0.92	82 (75-88) 0.71

* = Wilson 95% CI based on results from only one study; NA = not applicable; CI = confidence interval;

τ^2 = between-study variance

Figures

Figure 1. PRISMA flow chart diagram describing the publication search and selection algorithm.¹⁸

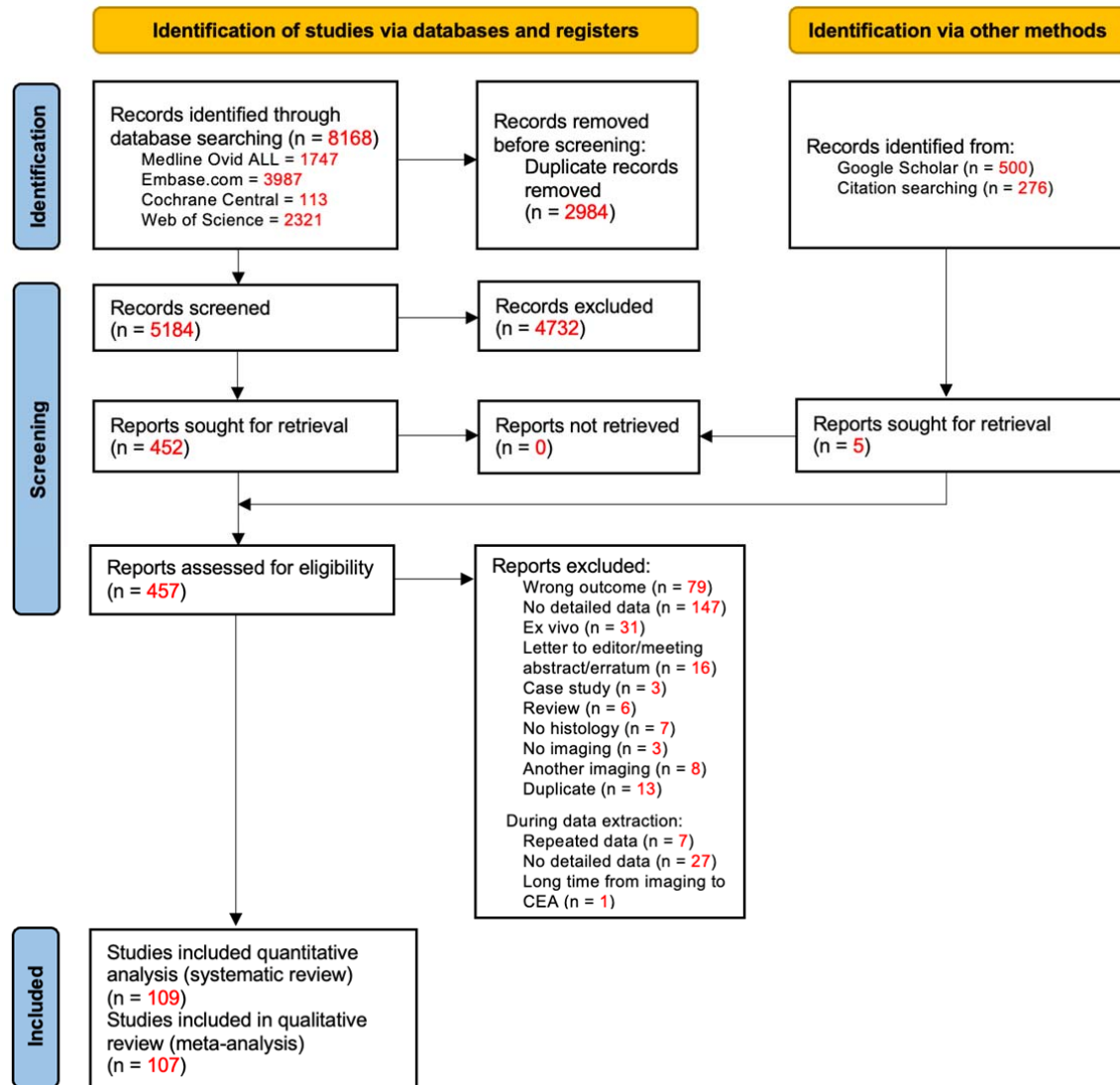


Figure 2. The risk of bias and the applicability concerns of included studies according to the QUADAS-2.²²

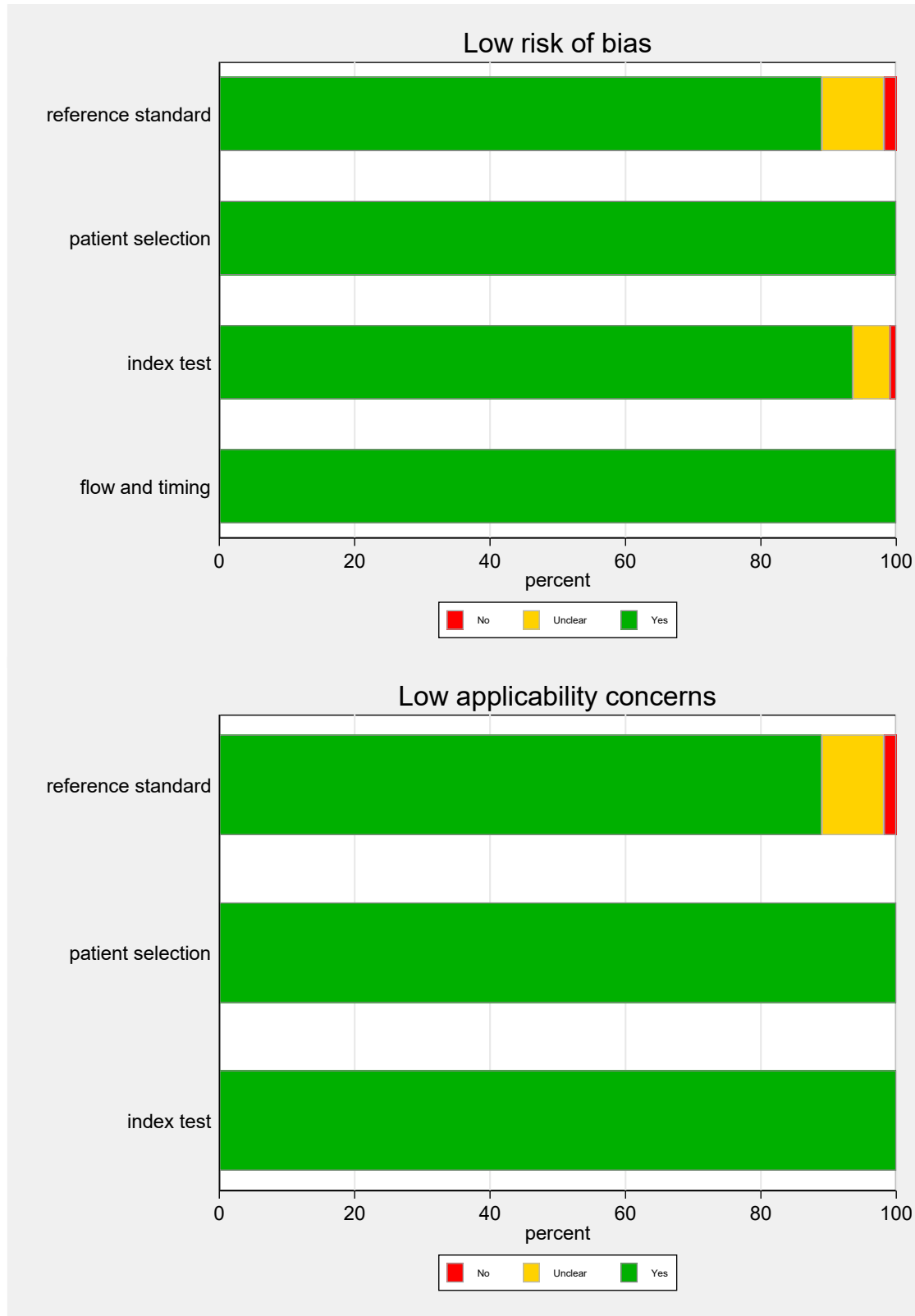


Figure 3. Diagnostic accuracy of 41 studies included in analysis 1 (A: vulnerable, B: stable).

First author	Year	Imaging modality	Final nr of slices	TP	FP	FN	TN	Sensitivity (%)	Specificity (%)	PPV (%)	NPV (%)	Accuracy (%)
Vulnerable plaque												
Di Leo ³⁵	2018 ^a	CT	43	27	0	4	12	87.1	100.0	100.0	75.0	90.7
	2018 ^b	US	43	27	5	4	7	87.1	58.3	84.4	63.6	79.0
	2018 ^c		43	27	4	4	8	87.1	66.7	87.1	66.7	81.4
Lukanova ³⁶	2015 ^a	US	59	29	2	2	26	93.6	92.9	93.6	92.9	93.2
	2015 ^b	CT	29	15	3	3	8	83.3	72.7	83.3	72.7	79.3
	2015 ^c	MRI	30	21	1	0	8	100.0	88.9	95.5	100.0	96.7
Cappendijk ³⁹	2005 ^a	MRI	79	27	2	2	48	93.1	96.0	93.1	96.0	94.9
	2005 ^b		79	22	0	7	50	75.9	100.0	100.0	87.7	91.1
Honda ⁴⁰	2006 ^a	MRI	18	9	0	0	9	100.0	100.0	100.0	100.0	100.0
	2006 ^b		18	4	4	5	5	44.4	55.6	50.0	50.0	50.0
	2006 ^c		18	9	5	0	4	100.0	44.4	64.3	100.0	72.2
	2006 ^d		16	9	0	0	7	100.0	100.0	100.0	100.0	100.0
Millon ⁴¹	2012	MRI	59	31	4	8	16	79.5	80.0	88.6	66.7	79.7
Watanabe ⁴³	2008 ^a	US	54	18	11	6	19	75.0	63.3	62.1	76.0	68.5
	2008 ^b	MRI	54	23	2	1	28	95.8	93.3	92.0	96.6	94.4
Yoshida ⁴⁵	2005 ^a	MRI	22	8	1	0	13	100.0	92.9	88.9	100.0	95.5
Yoshida ⁴⁶	2008	MRI	66	27	7	5	27	84.4	79.4	79.4	84.4	81.8
Yuan ⁴⁷	2001	MRI	90	56	2	10	22	84.9	91.7	96.6	68.8	86.7
Balzer ⁴⁸	2004 ^a	US	368	176	33	32	127	84.6	79.4	84.2	79.9	82.3
Denzel ⁴⁹	2003 ^a	US	15	2	3	3	7	40.0	70.0	40.0	70.0	60.0
Huang ⁵⁰	2021 ^a	US	38	25	2	3	8	89.3	80.0	92.6	72.7	86.8
	2021 ^b		38	24	4	4	6	85.7	60.0	85.7	60.0	79.0
Iezzi ⁵³	2015 ^a	US	50	29	6	5	10	85.3	62.5	82.7	66.7	78.0
	2015 ^b		50	12	4	22	12	35.3	75.0	75.0	35.3	48.0
	2015 ^c		50	32	5	2	11	94.1	68.8	86.5	84.6	86.0
	2015 ^d		50	19	5	15	11	55.9	68.8	79.2	42.3	60.0
Kim ⁵⁴	1999	US	48	31	2	8	7	79.5	77.8	93.9	46.7	79.2
Li H. ⁵⁵	2021	US	60	29	8	10	13	74.4	61.9	78.4	56.5	70.0
Liu F. ⁵⁶	2014 ^a	US	19	15	3	0	1	100.0	25.0	83.3	100.0	84.2
	2014 ^b		19	15	2	0	2	100.0	50.0	88.2	100.0	89.5
	2014 ^c		19	15	1	0	3	100.0	75.0	93.8	100.0	94.7
Lyu ⁵⁸	2020	US	51	29	5	8	9	78.4	64.3	85.3	52.9	74.5
Muraki ⁶⁰	2016	US	50	37	4	3	6	90.2	60.0	90.2	66.7	86.0
Reiter ⁶¹	2007 ^a	US	28	6	2	2	18	75.0	90.0	75.0	90.0	85.7
	2007 ^b		28	6	2	2	18	75.0	90.0	75.0	90.0	85.7
Xiaojie ⁶³	2020	US	46	32	2	4	8	88.9	80.0	94.1	66.7	87.0

It is made available under a [CC-BY-NC-ND 4.0 International license](#) .

Stable plaque												
Yoshida ⁴⁵	2005 ^b	MRI	22	13	0	1	8	92.9	100.0	100.0	88.9	95.5
Balzer ⁴⁸	2004 ^b	US	368	112	47	22	187	83.6	79.9	70.4	89.5	81.3
Denzel ⁴⁹	2003 ^b	US	15	2	3	3	7	40.0	70.0	40.0	70.0	60.0
Huang ⁵⁰	2021 ^c	US	38	8	3	2	25	80.0	89.3	72.7	92.6	86.8
	2021 ^d		38	6	4	4	24	60.0	85.7	60.0	85.7	79.0

Figure 4. HSROC curves of analysis 1 (top) and analysis 2 (bottom) for visualization of vulnerable plaque and vulnerable plaque characteristics, respectively, based on HSROC curves.

