

1 **Endobronchial ultrasound-guided transbronchial mediastinal**  
2 **cryobiopsy: Insights and technical tips from our early experience**  
3 **with 30 patients**

4 Chun Ian Soo <sup>1</sup> ¶\* , Sze Shyang Kho <sup>2</sup> ¶

5

6 <sup>1</sup> Division of Respiratory Medicine, Department of Medicine, University Malaya Medical  
7 Center, University Malaya, Kuala Lumpur, Malaysia

8 <sup>2</sup> Division of Respiratory Medicine, Department of Medicine, Sarawak General Hospital,  
9 Kuching, Malaysia

10

11 Short title: Endobronchial ultrasound guided cryobiopsy

12

13

14

15

16

17

18

19

20 **\*Corresponding Author**

21 Name: Chun Ian Soo

22 Email: [scianray@gmail.com](mailto:scianray@gmail.com)

23

24 ¶These authors contributed equally to this work.

25 NOTE: This preprint reports new research that has not been certified by peer review and should not be used to guide clinical practice.

26 **Abstract**

27

28 **Background**

29

30 Endobronchial ultrasound-guided transbronchial needle aspiration (EBUS-TBNA) is  
31 commonly used to diagnose and stage lung cancer. In real-life practice, limitations are  
32 seen with cytology samples from EBUS-TBNA. Obtaining adequate samples can be  
33 challenging when faced with necrotic lesions with low cellular yield and the evolving  
34 landscape of targeted therapy, necessitating additional samples for comprehensive  
35 testing. Hence, transbronchial mediastinal cryobiopsy guided by endobronchial  
36 ultrasound (EBUS-TBMC) has emerged as a promising approach for obtaining larger  
37 tissue samples. In retrospective review, our aim is to present our early experience  
38 regarding the feasibility of performing EBUS-TBMC, employing a similar approach to  
39 EBUS-TBNA, followed by the outcomes of our procedures. We include a step-by-step  
40 explanation and some recommendations to conduct a successful EBUS-TBMC.

41

42 **Method**

43 Single center retrospective analysis to evaluate the feasibility and utility of EBUS-  
44 TBMC cases over six months from July to December 2022.

45

46 **Results**

47 36 EBUS-TBMC procedures on 30 patients. Moderate sedation was used in 80% of  
48 cases. Majority (83.4%) of the patients had biopsy of a single lesion with a median of  
49 3 cryobiopsies (Interquartile range 3-4). The median cryo-activation time was 6  
50 seconds (Interquartile range 6-8). EBUS-TBMC demonstrated a positive yield of 86.1%

51 with an overall diagnostic yield of 83.3%. Mild bleeding occurred in six biopsies (16.7%)  
52 which did not required further intervention. No other major complications were  
53 observed.

54

## 55 **Conclusion**

56 EBUS-TBMC is a safe and effective alternative to EBUS-TBNA. Histology samples  
57 obtained through EBUS-TBMC have the potential to increase confidence in diagnosing  
58 and staging lung cancer, thereby alleviating concerns about tissue inadequacy.

59

## 60 **1.Introduction**

61 Endobronchial ultrasound-guided transbronchial needle aspiration (EBUS-TBNA)  
62 is a minimally invasive technique commonly employed for diagnosing and staging  
63 lung cancer [1-2]. However, diagnostic challenges of EBUS-TBNA are seen when  
64 dealing with low-cellularity lesions, particularly those involving necrosis or non-  
65 malignant conditions [3]. With the emergence of targeted therapy in non-small cell  
66 lung carcinoma (NSCLC), additional samples are necessary for immunological  
67 profiling and molecular testing. Although transbronchial forceps biopsy and larger  
68 cytology needles have been attempted in such cases, their efficacy remains  
69 uncertain [3].

70 A newer technique, transbronchial mediastinal cryobiopsy guided by  
71 endobronchial ultrasound (EBUS-TBMC), has recently gained popularity for  
72 obtaining larger tissue samples. Despite its growing use, the feasibility, optimal  
73 sampling strategy, diagnostic accuracy, and safety profile of EBUS-TBMC are

74 subjects of ongoing debate. As regular EBUS-endoscopists, we have also explored  
75 EBUS-TBMC. In this short commentary, we share our early experience with the  
76 feasibility and utility of EBUS-TBMC. In addition, we offer a detailed exposition of  
77 the employed technique, with the intent of enriching readers' comprehension and  
78 offering invaluable insights into the procedure and its clinical applications.

## 79 **2. Methods**

80 We conducted a retrospective analysis of EBUS-TBMC cases performed at a  
81 single tertiary center between July and December 2022. The clinical data of the  
82 patients, including radiological images and EBUS-TBMC findings were traced  
83 using the hospital's electronic medical records. The authors had access to  
84 participants information during data collection.

85 An experienced operator carried out the EBUS-TBMC procedure using a 1.1-mm  
86 flexible cryoprobe (Erbecryo 20402-401, Tübingen, Germany). The procedure was  
87 conducted under either moderate sedation or general anesthesia, following  
88 established guidelines [4]. The entry point and biopsy track (BT) for the cryoprobe  
89 were created using a needle (19, 21, or 22-gauge), followed by an unspecified  
90 number of cryo-activations per biopsy. The choice of needle size was based on the  
91 operator's assessment of the type and location of the lesion, while the number of  
92 cryo-activations per biopsy was determined at the operator's discretion. The frozen  
93 biopsy tissue was retracted en-bloc with the scope and probe, and the thawed  
94 samples were fixed in formalin. Rapid onsite cytology examination was not  
95 available during the procedures. For our analysis, we defined a positive yield as a  
96 definitive histology diagnosis from each biopsy, while the diagnostic yield was  
97 based on diagnoses from available histology samples. The study protocol received

98 approval from the Medical Research and Ethics Committee, Ministry of Health  
99 Malaysia (NMRR ID-23-00577-6XP), and informed consent was waived for this  
100 retrospective study.

### 101 **3.Results**

102 A total of 36 EBUS-TBMC procedures were performed on 30 patients. Moderate  
103 sedation was utilized in 80% of cases. On average, 3 EBUS-TBMCs were  
104 conducted per patient (interquartile range [IQR]: 3-4), with an activation time of 6  
105 seconds (IQR: 6-8). In the majority of cases, EBUS-TBMC was performed on a  
106 single lesion, accounting for 83.4% (25 patients) of the total. Among the biopsies  
107 conducted, 83.3% (30 biopsies) targeted lymph nodes, while the remaining 16.7%  
108 (6 biopsies) were performed on masses. Only two instances of failure in cryoprobe  
109 insertion were observed.

110 The median cumulative tissue size retrieved during EBUS-TBMC procedures was  
111 6 mm (IQR: 5-8). Notably, the positive yield of EBUS-TBMC was 86.1% (31  
112 lesions), contributing to an overall diagnostic yield of 83.3% (25 cases). Table 1  
113 presents the baseline characteristics and diagnostic yield. Mild bleeding occurred  
114 in six cases (16.7%) but did not require any intervention. Fortunately, no  
115 pneumothoraces, pneumomediastinum, mediastinitis, or other complications were  
116 observed.

117 Table 1. Baseline characteristics and diagnostic yield of EBUS-TBMC  
118

<b>Variable</b>	<b>Number (%)</b>
Number of patients	30
Number of cryobiopsy	36
Sex	
Male	19 (63.3)

Female	11 (36.7)	
Sedation		
Moderate sedation	24 (80.0)	
General anaesthesia	6 (20.0)	
Number of EBUS-TBMC attempted/patient	Total	Fail
1	25 (83.4)	2 (6.7)
2	4 (13.3)	0
3	1 (3.3)	0
Number of EBUS-TBMC activation,		
2	7 (19.4)	
3	12 (33.3)	
4	11 (30.6)	
5	4 (11.1)	
6	2 (5.6)	
EBUS-TBMC activation time		
<7 (4-6sec)	21 (58.3)	
>7 (8-10 sec)	15 (41.7)	
Type of lesions		
Lymph nodes	30 (83.3)	
Mass	6 (16.7)	
Lymph nodes (station)		
4R	9 (30.0)	
11/10R	2 (6.7)	
7	16 (53.4)	
11/10L	1 (3.3)	
4L	1 (3.3)	
Others	1 (3.3)	
Mass		
Paratracheal mass	2 (33.3)	
Posterior tracheal lesion	2 (33.3)	
Hilar mass	2 (33.3)	
Positive yield	31 (86.1)	
Positive diagnosis	25 (83.3)	
Malignancy	15 (50.0)	
Non malignancy	10 (33.3)	
Malignancy		
Adenocarcinoma	11 (73.3)	
Squamous carcinoma	1 (6.7)	

Small cell carcinoma	3 (20.0)
Non-malignant	
Tuberculosis	2 (20.0)
Sarcoidosis	2 (20.0)
Granulomatous	2 (20.0)
Reactive	4 (40.0)

119 Note: Values are presented as number (%)

120 Abbreviation: Transbronchial mediastinal cryobiopsy guided by endobronchial ultrasound= EBUS-  
121 TBMC

122

## 123 **4.Discussion**

### 124 4.1 Technical aspect

125 EBUS-TBMC, akin to EBUS-TBNA, can be carried out with moderate sedation [5-  
126 6]. For enhanced patient tolerance or when dealing with small or multiple lesions,  
127 the procedure is preferably performed under deep sedation or general anaesthesia  
128 [7]. In our study, we primarily conducted EBUS-TBMC under moderate sedation,  
129 as regular anaesthesia support was unavailable.

130 When EBUS-TBMC is employed as an ancillary test for EBUS-TBNA, it is  
131 advisable to conduct EBUS-TBMC as the initial procedure. This approach allows  
132 for the precise identification of a proper and consistent entry point and BT created  
133 by repeated punctures of the TBNA needle. In our procedures, we did not use high-  
134 frequency needle knives, in line with a previous studies [6]. However, using a  
135 needle knife may potentially reduce the overall procedural duration [5-6]. Using a  
136 21-gauge needle, around 5-6 agitations over the capsule than the cortex, following  
137 a similar trajectory visible on ultrasound and bronchoscopic vision, are required to  
138 create a BT after puncturing the membranous part of the tracheobronchial wall.  
139 The number of agitations may need to be adjusted depending on whether a larger

140 or smaller needle is used. The cryoprobe is then inserted precisely perpendicular  
141 to the BT into the lesion.

142 EBUS-TBMC can be conveniently performed at lymph node stations commonly  
143 sampled via EBUS-TBNA. However, our experience reveals that EBUS-TBMC  
144 presents challenges for posterior tracheal lesions due to the difficulty of rotating  
145 the scope 180 degrees. Nevertheless, we believe that mastering EBUS-TBMC  
146 requires a steep learning curve. Fig 1 provides a pictorial narrative of the procedure,  
147 and Fig 2 depicts the landmarks corresponding to the complexity level of  
148 performing EBUS-TBMC.

149 Figure caption

150 Fig 1:

151 Pictorial narrative of the EBUS-TBMC procedure (In alphabetical sequence)  
152 (A) Biopsy track created by TBNA needle seen on ultrasound (blue arrow), (B and C)  
153 Biopsy track (blue arrow) and TBNA needle (red arrow) seen at the same trajectory  
154 and different depth, (D) Entry point seen after a 22 gauge TBNA needle puncture  
155 (black arrow), (E) Avoiding entry of cryoprobe at obtuse angle, (F) Maintain  
156 perpendicular entry of cryoprobe, (G) Ensure cryoprobe is clearly visible in lesion, (H)  
157 Samples thawed in saline and fixed in formalin, (I) Sample size obtained at different  
158 cryo-activation time.

159

160 Fig 2:

161 Landmarks and the complexity degree of performing EBUS-TBMC

162 Abbreviation: Transbronchial mediastinal cryobiopsy guided by endobronchial ultrasound =EBUS-  
163 TBMC, Transbronchial needle aspiration =TBNA



164

## 165 4.2 Diagnostic yield

166 Various studies have demonstrated that incorporating EBUS-TBMC alongside  
167 conventional EBUS-TBNA can significantly improve the diagnostic yield, especially  
168 for benign disorders, lymphomas, and rare mediastinal conditions [5-6,8-9].  
169 However, it is essential to acknowledge that intra-lesion necrosis or fibrotic lymph  
170 nodes may occasionally limit tissue availability, resulting in a potential reduction in  
171 diagnostic yield [10]. Another limitation of EBUS-TBMC involves addressing the  
172 heterogeneity of lymph nodes, as the procedure may not allow for biopsies at  
173 multiple sites, unlike EBUS-TBNA, which can sample a larger area through  
174 different needle entry points or the fanning technique [11].

175 Despite this limitation, EBUS-TBMC offers several advantages. Histology samples  
176 obtained from EBUS-TBMC enable more comprehensive testing compared to  
177 cytology examination, especially when dealing with poorly differentiated tumours.  
178 This aspect is particularly crucial for obtaining accurate diagnoses and guiding  
179 treatment decisions. One of the most significant clinical implications of EBUS-  
180 TBMC lies in its ability to provide sufficient tissue for complete molecular profiling  
181 before initiating targeted therapy for non-small cell lung carcinoma (NSCLC) [8].  
182 Additionally, in cases of multiple synchronous/metachronous lung cancers, large  
183 tissue specimens are often required for comprehensive testing, underscoring the  
184 indispensability of EBUS-TBMC in such clinical scenarios.

185 In our study, we achieved an overall diagnostic yield of 83.3% (25 cases) with an  
186 83.3% diagnostic yield for malignancy. All 12 patients diagnosed with NSCLC had

187 adequate samples from EBUS-TBMC for next-generation sequencing testing.  
188 Nonetheless, it is essential to acknowledge that EBUS-TBMC did not establish a  
189 diagnosis in four cases. The contributing factors include poor patient tolerance,  
190 imprecise biopsy location, and extensive necrosis.

#### 191 4.3 Complication

192 Minor bleeding was observed in six cases, but no intervention was required,  
193 indicating a manageable and self-limiting complication. To further mitigate the risk  
194 of bleeding, we recommend conducting Doppler assessments for vascular  
195 evaluation before the biopsy. This approach helps identify potential vascular  
196 structures and allows for safer probe placement during the procedure.

197 While rare, pneumothorax and pneumomediastinum have been reported in some  
198 cases [5]. As a precautionary measure, we routinely perform post-procedure chest  
199 radiographs to promptly detect any signs of air leak. Fortunately, no instances of  
200 pneumothorax, pneumomediastinum, mediastinitis, or mortality were observed in  
201 our cohort, which is consistent with previous studies demonstrating the overall  
202 safety of EBUS-TBMC [5-8].

203 In our study, we did not administer prophylactic antibiotics, even when sampling  
204 large necrotic lesions. This decision aligns with current guidelines and is supported  
205 by the lack of observed infections or complications related to the absence of  
206 antibiotic prophylaxis. Nevertheless, we emphasize the importance of cautious and  
207 skilled execution of EBUS-TBMC to minimize the risk of adverse events. While the  
208 procedure offers valuable benefits in obtaining larger tissue samples, operators

209 should be well-trained and familiar with the technique's intricacies to ensure patient  
210 safety.

#### 211 4.4 Advantage and disadvantages

212 Despite some studies reporting mixed outcomes regarding procedure time [5-7],  
213 our observations suggest that EBUS-TBMC and EBUS-TBNA may have  
214 comparable overall procedure times. We have an ongoing study to validate this  
215 hypothesis. One significant drawback of EBUS-TBMC is its cost, necessitating  
216 careful consideration and justification of its use. The expense of a single-use  
217 cryoprobe is more than twice that of a TBNA needle, rendering an EBUS-TBMC  
218 procedure to cost almost three times more expensive. However, it is noteworthy  
219 that the future development of a cryo-needle may offer a potential solution to  
220 address this cost concern [12]. Table 2 provides an overview of the advantages  
221 and disadvantages of EBUS-TBMC. Notably, EBUS-TBMC has the potential to be  
222 advantageous in cases with low diagnostic yields using EBUS-TBNA, as it may  
223 help avoid repeat procedures, ultimately leading to cost savings. Further  
224 prospective studies are necessary to ascertain its efficacy.

225 Table 2. Advantages and disadvantages of EBUS-TBMC and the proposed solution.

226

<b>Advantages of EBUS-TBMC</b>	
Providing histology sample whereas TBNA provides cytology sample.	
Increase diagnostic yield when used alone or combined with TBNA for benign and malignant lesions [5-6,8].	
Improved sample suitability for full molecular profiling [6,8].	
Larger sample [5-9].	
Less crush artifact compare to forcep biopsy.[9]	
Does not require the support of ROSE.	
Can be performed by experience operator under moderate sedation.	
<b>Disadvantages of EBUS-TBMC</b>	<b>Proposed solution</b>
Challenging for certain landmarks. Refer to Fig 2.	EBUS-TBNA to be used for challenging landmarks.

Sampling from single area of a lesion.	Deep sedation or general anaesthesia support for challenging cases (small lesion, multiple lesions or multiple sampling from different area of a lesion).
Not feasible to apply fanning technique.	
Not well explored through EUS-B compare to TBNA.	Potentially feasible [13-14]. Further studies are required.
Higher cost of procedure.	EBUS-TBMC can be considered when anticipating lower yield with TBNA or inconclusive when ROSE is available.

227 Abbreviation: Endobronchial ultrasound-guided transbronchial needle aspiration = EBUS-TBNA,  
228 Transbronchial mediastinal cryobiopsy guided by endobronchial ultrasound =EBUS-TBMC,  
229 Endoscopic ultrasound using EBUS scope = EUS-B, Rapid on site examination = ROSE  
230

#### 231 4.5 Limitation of current study

232 The current study has several limitations that require consideration. One limitation  
233 of the study is the relatively small sample size, and the fact that it was conducted  
234 at a single center. As a result, the findings may not be fully generalizable to broader  
235 populations or diverse clinical settings. Conducting larger multi-center studies can  
236 help validate and enhance the robustness of the results. Another limitation arises  
237 from the retrospective nature of the study design, which may introduce potential  
238 biases such as selection bias, information bias, and recall bias. The reliance on  
239 existing data and historical records may impact the accuracy and completeness of  
240 the findings. Despite these limitations, the study provides valuable insights into the  
241 feasibility and utility of EBUS-TBMC. Recognizing and addressing these limitations  
242 in future research endeavours will contribute to a more comprehensive  
243 understanding of the clinical implications and benefits of EBUS-TBMC.

#### 244 5. Conclusion

245

246 In conclusion, our study demonstrates the feasibility and safety of endobronchial  
247 ultrasound-guided transbronchial mediastinal cryobiopsy (EBUS-TBMC) through the  
248 biopsy track created by a TBNA needle. The procedure, performed under moderate  
249 sedation, provides a high diagnostic yield, offering valuable insights into mediastinal  
250 disorders and lung cancers. The favourable safety profile and larger tissue samples  
251 obtained through EBUS-TBMC enhance diagnostic accuracy and molecular testing,  
252 potentially optimizing therapeutic decision-making. As evidence continues to emerge,  
253 EBUS-TBMC has the potential to transition from an ancillary test to a primary method,  
254 complementing or even replacing EBUS-TBNA in certain clinical scenarios.

255

256 In summary, our study contributes valuable insights into the growing evidence on  
257 EBUS-TBMC. The procedure's diagnostic capabilities, safety, and ease of  
258 implementation underscore its potential significance in diagnosing various mediastinal  
259 disorders and lung cancers. As the field advances, EBUS-TBMC holds promise as a  
260 key diagnostic modality shaping the future of diagnostic bronchoscopy.

261

## 262 **Disclosure**

263 The authors have no conflict of interest relevant to this article to report

264

## 265 **References:**

266

267 1. Detterbeck FC, Jantz MA, Wallace M, Vansteenkiste J, Silvestri GA. Invasive  
268 mediastinal staging of lung cancer: ACCP evidence-based clinical practice guidelines.  
269 Chest. 2007;132(3):202S-20S

270

- 271 2. Wahidi MM, Herth F, Yasufuku K, Shepherd RW, Yarmus L, Chawla M, et al.  
272 Technical aspects of endobronchial ultrasound-guided transbronchial needle  
273 aspiration: CHEST guideline and expert panel report. *Chest*. 2016;149(3):816-35.  
274
- 275 3. Eapen GA, Shah AM, Lei X, Jimenez CA, Morice RC, Yarmus L, et al.  
276 Complications, consequences, and practice patterns of endobronchial ultrasound-  
277 guided transbronchial needle aspiration: results of the AQUIRE registry. *Chest*.  
278 2013;143(4):1044-53.  
279
- 280 4. Du Rand IA, Barber PV, Goldring J, Lewis RA, Mandal S, Munavvar M, et al.  
281 British Thoracic Society guideline for advanced diagnostic and therapeutic flexible  
282 bronchoscopy in adults. *Thorax*. 2011; 66(Suppl 3):iii1-21.  
283
- 284 5. Zhang J, Guo JR, Huang ZS, Fu WL, Wu XL, Wu N, et al. Transbronchial  
285 mediastinal cryobiopsy in the diagnosis of mediastinal lesions: a randomised trial.  
286 *Eur Respir J*. 2021;58(6).  
287
- 288 6. Ariza-Prota M, Pérez-Pallarés J, Fernández-Fernández A, García-Alfonso L,  
289 Cascón JA, Torres-Rivas H, et al. Endobronchial ultrasound-guided transbronchial  
290 mediastinal cryobiopsy in the diagnosis of mediastinal lesions: safety, feasibility and  
291 diagnostic yield—experience in 50 cases. *ERJ Open Res*. 2023;9(2).  
292
- 293 7. Maturu VN, Prasad VP, Vaddepally CR, Dommata RR, Sethi S. Endobronchial  
294 Ultrasound-guided Mediastinal Lymph Nodal Cryobiopsy in Patients With

- 295 Nondiagnostic/Inadequate Rapid On-site Evaluation: A New Step in the Diagnostic  
296 Algorithm. *J Bronchology Interv Pulmonol.* 2023:10-97  
297
- 298 8. Fan Y, Zhang AM, Wu XL, Huang ZS, Kontogianni K, Sun K, et al. Transbronchial  
299 needle aspiration combined with cryobiopsy in the diagnosis of mediastinal diseases:  
300 a multicentre, open-label, randomised trial. *Lancet Respir Med.* 2023;11(3):256-64.  
301
- 302 9. Kho SS, Soo CI, Nasaruddin MZ, Ngan KW, Abdul Rahaman JA. Multimodal  
303 linear endobronchial ultrasound guided mediastinal lymph node biopsy in the  
304 diagnosis of isolated mediastinal lymphadenopathy. *Proc Singapore Healthc.*  
305 2022;31:20101058221111655.  
306
- 307 10. Tian Q, Chen LA, Wang RT, Yang Z, An Y. The reasons of false negative results  
308 of endobronchial ultrasound-guided transbronchial needle aspiration in the diagnosis  
309 of intrapulmonary and mediastinal malignancy. *Thoracic Cancer.* 2013;4(2):186-90.  
310
- 311 11. Parthiban S, Sczaniecka A, Dillard D, Gonzalez X. Comparison of Fanning and  
312 No-Fanning Sampling Techniques for Endobronchial Ultrasound-Guided  
313 Transbronchial Needle Aspiration in an Ex Vivo Tissue Model. *Chest.*  
314 2017;152(4):A964.  
315
- 316 12. Franke KJ, Nilius G, Ruehle KH, Enderle MD, Linzenbold W, von Weyhern CH.  
317 The cryo-needle: a new tool for histological biopsies. A feasibility study. *Lung.*  
318 2013;191:611-7  
319

- 320 13. Huang ZS, Zhou D, Zhang J, Fu WL, Wang J, Wu XL, et al. Mediastinal nodular  
321 lymphocyte predominant Hodgkin lymphoma achieved by endoscopic  
322 transesophageal cryobiopsy. *Respiration*. 2022;101(2):190-4.
- 323 14. Ariza-Prota MA, de Santis M, López-González F. Successful Diagnostic  
324 Mediastinal Cryobiopsy by Transesophageal Endoscopy Without Using the Needle  
325 Knife. *Arch. Bronconeumo*. 2023 Jul 10.



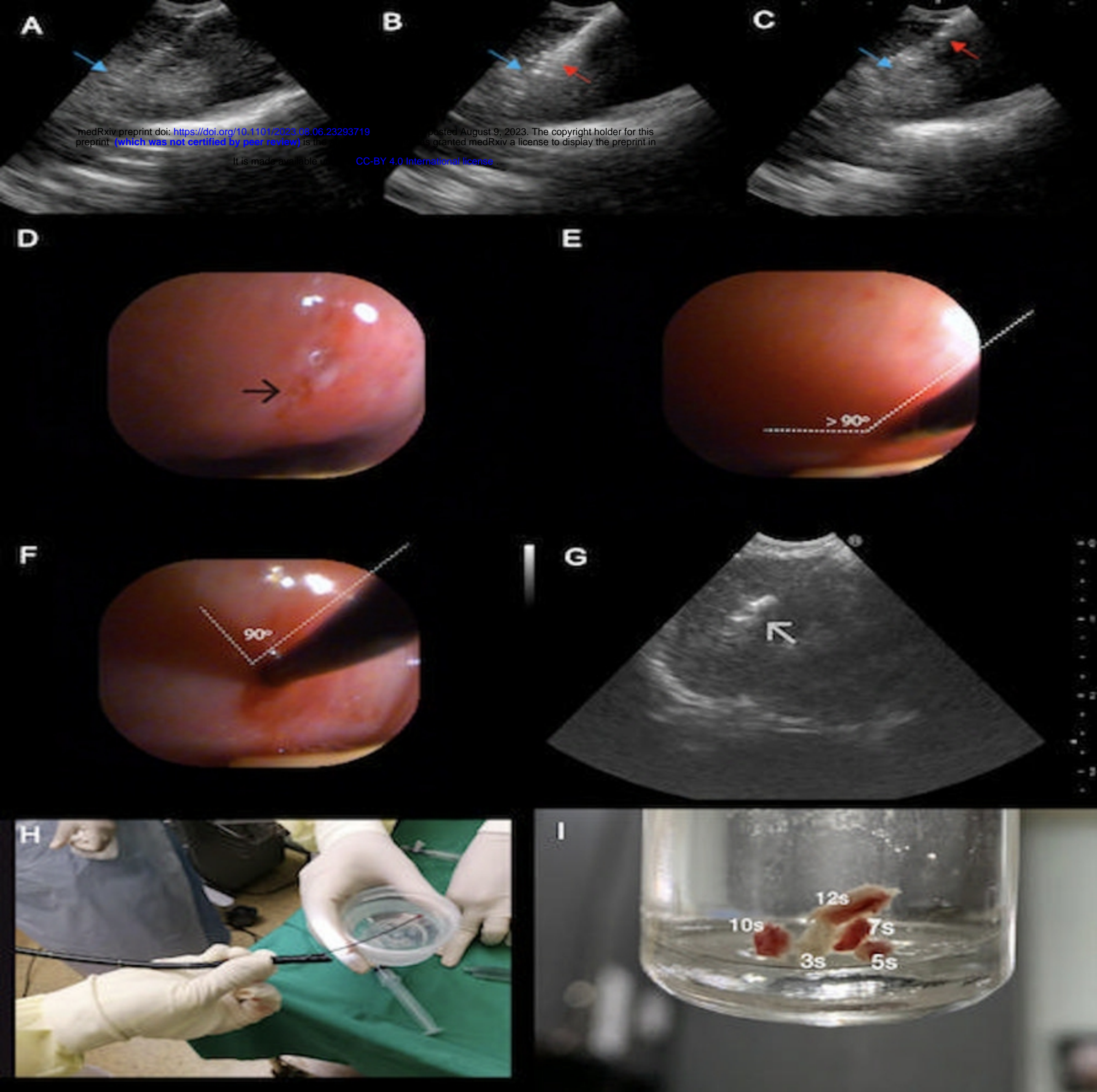
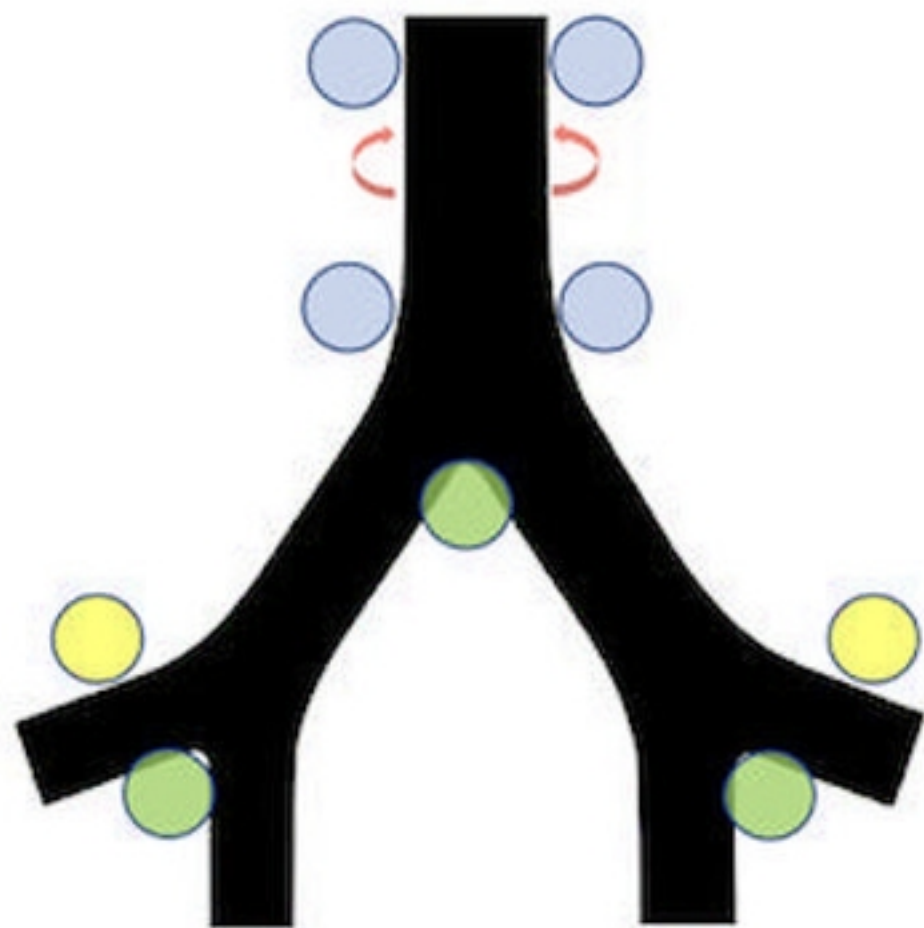


Figure 1



Landmarks and complexity degree for EBUS-TMC





-  Interlobar and subcarinal: Low
-  Upper and lower paratracheal: Reasonable
-  Hilar: Can be challenging
-  Posterior tracheal: Challenging

Figure 2