

**SUPPLEMENTARY MATERIAL: “Assessment of fetal corpus callosum biometry by
3D super-resolution reconstructed T2-weighted MRI”**

Samuel Lamon^{1,2,3}, Priscille de Dumast^{1,2}, Vincent Dunet¹, Léo Pomar^{3,4}, Yvan Vial³, Mériam Koob^{1,†}, Meritxell Bach Cuadra^{2,1,*,†}

¹Department of Radiology, Lausanne University Hospital and University of Lausanne, Lausanne, Switzerland

²CIBM Center for Biomedical Imaging, Lausanne, Switzerland

³Ultrasound and Fetal Medicine, Department Woman-Mother-Child, Lausanne University Hospital and Lausanne University, Lausanne, Switzerland

⁴School of Health Sciences (HESAV), University of Applied Sciences and Arts Western Switzerland, Lausanne, Switzerland

† Equally contributed

* **Correspondence:** Meritxell Bach Cuadra
meritxell.bachcuadra@unil.ch

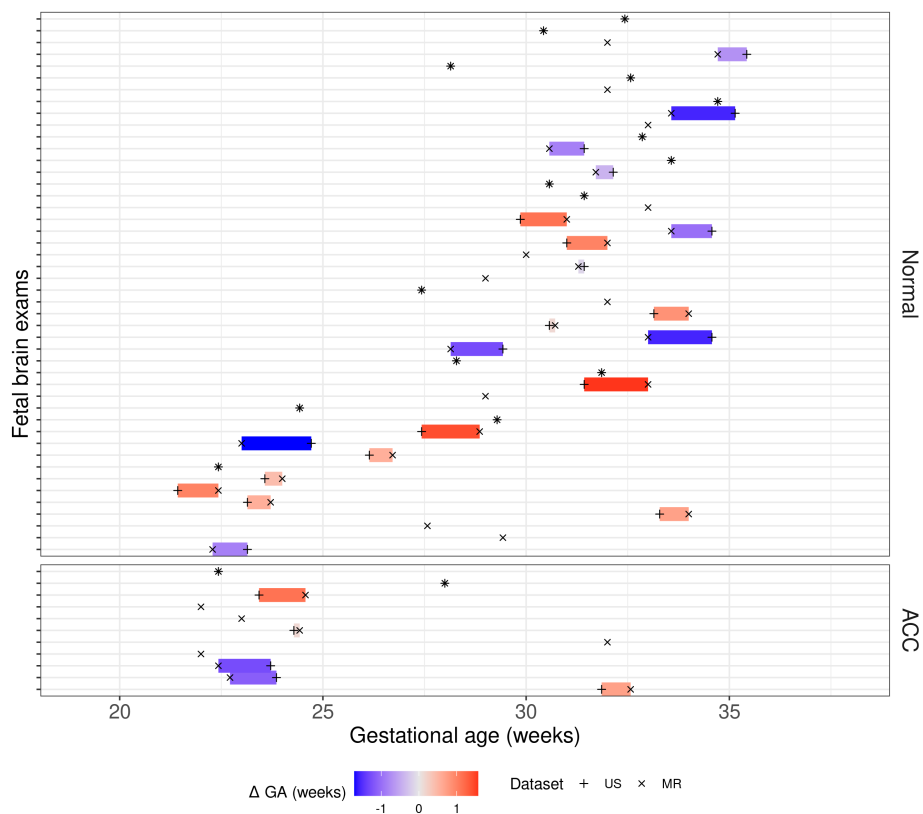


Figure S1 Gestational age at moment of Ultrasound (+) and MR (x) acquisition. Dark colors (blue or red) illustrate the largest time difference.

Table S1 Intra class correlation coefficient (ICC) for observer 1. Average on 9 normal and 3 pCCA repeated measurements.

ICC (Obs1)	US	T2WS	SR
LCC	0.999	0.996	0.995
Splenium	0.979	0.993	0.979
Body	0.832	0.707	0.145
Genu	0.821	0.812	0.536
Rostrum	0.887	0.903	0.579
Overall	1	0.99	0.99

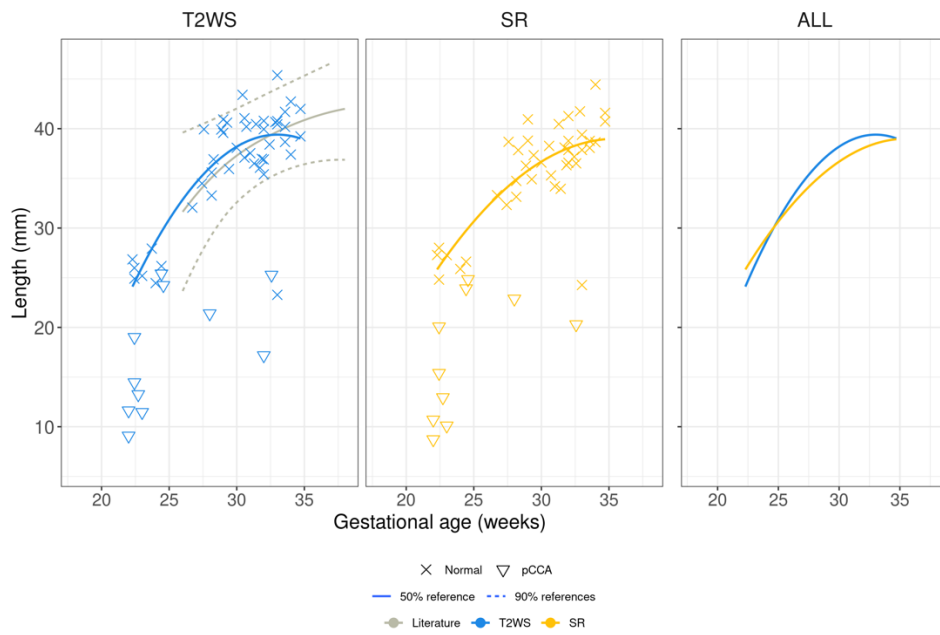


Figure S2 Regression of LCC measurements of Obs2 (expert MR) with gestational age.

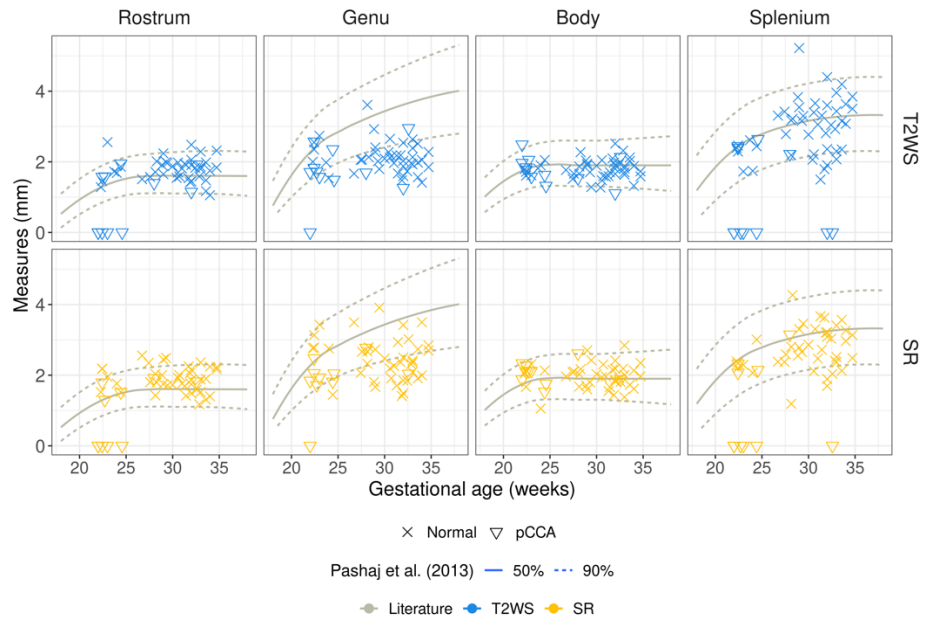


Figure S3 Regression of CC heights measurements (Rostrum, Genu, Body and Splenium) of Obs2 (expert MR) with gestational age.