

Full Title: Diagnosis of left atrial appendage thrombus using cardiac computed tomography:

new insights from thrombi locations

Authors: Chuxian Guo, MD^{ad*}; Zhi Jiang, PhD^{a*}; Jionghong He, MD^{ab}; Haiyan Ma, PhD^c; Yuquan Wang, MBBS^c; Jing Tan, MD^{ab}; Qiaoqiao Ou, MD^{ad}; Ye Tian, MD^a; Longhai Tian, MD^a, Qifang Liu, PhD^a; Jing Huang, PhD^a; Long Yang, PhD^a

Affiliations: From ^a Cardiology Department, Guizhou Provincial People's Hospital, Guiyang, China; ^b Echocardiography Department, Guizhou Provincial People's Hospital, Guiyang, China; ^c Radiology Department of Guizhou Provincial People's Hospital, Guiyang City, China; ^d Guizhou Medical University, Guiyang, China.

* Chuxian Guo and Zhi Jiang contributed equally to the study.

Short title: The ability of cardiac CT to detect thrombi.

Corresponding author: Long Yang, Department of Cardiology, Guizhou Provincial People's Hospital, NO. 83 East Zhongshan Road, Guizhou Province, Guiyang City, 550002, China.

E-mail: yanglong1001@outlook.com. Telephone: +86-18198169283. Fax: +86 0851-85924943

Total word count: 4788

Title: Diagnosis of left atrial appendage thrombus using cardiac computed tomography: new insights from thrombi locations

Abstract

Background Cardiac computed tomography (CCT) is an emerging non-invasive modality for assessing left atrial appendage (LAA) thrombus, but the results were conflicting. Our study aims to evaluate the accuracy of CCT for detecting LAA thrombus in patients undergoing catheter ablation of atrial fibrillation (AF), using transesophageal echocardiography (TEE) as the reference standard.

Methods From May 2017 to December 2022, 726 patients (male: 60.2%, age: 61±11 years) who had both TEE and CCT before catheter ablation of AF were retrospectively included. The CCT protocol consisted of one angiographic phase and one delayed scan 30 seconds later. LAA thrombi were defined as solid masses on TEE or persistent defects on CCT. The thrombus dimension and location, the LAA filling and emptying flow velocity were assessed by TEE.

Results Of the 57(7.9%) patients with LAA thrombi identified by TEE, 29(50.9%) were located at the LAA ostium, and 28(49.1%) were in the LAA. The former showed higher motility following blood flow and heartbeats than the latter. The CCT detected 14(48.3%) of the LAA-ostium thrombi but 25(89.3%) of those in the LAA ($p = 0.001$). The LAA-ostium thrombi with the LAA mean flow velocity higher than 0.35m/s and maximum diameters shorter than 10mm were more prone to have CCT false-negative results.

Conclusion For patients undergoing catheter ablation for AF, CCT with a 30s delay scan is less sensitive to LAA thrombi than TEE, especially LAA-ostium thrombi with smaller sizes and higher LAA flow velocity.

Keywords stroke; thrombosis; pulmonary vein isolation; cardiac imaging techniques; ultrasound.

Clinical perspective section

What are new?

1. Over half of the LAA thrombi were located at the LAA ostium.
2. The CCT was less sensitive to the LAA-ostium thrombi with smaller sizes and higher LAA flow velocity.

What is the clinical implication?

1. The CCT using a 30s delay scan did not reliably exclude the LAA thrombi for the patients scheduled for pulmonary vein isolation, especially those located at the LAA ostium.

Non-standard Abbreviations and Acronyms

AF	Atrial fibrillation
CCT	Cardiac computed tomography
CHA ₂ DS ₂ -VASc	Congestive heart failure, hypertension, age ≥ 75 years (doubled), diabetes, previous stroke/transient ischemic attack/thromboembolism (doubled), vascular disease, age 65–74 years, and sex category (female).
LAA	Left atrial appendage
LAAMFV	Left atrial appendage mean flow velocity
LAAPD	Left atrial anterior-posterior diameter
LVEDD	Left ventricular end-diastolic diameter
LVEF	Left ventricular ejection fraction

TEE	Transesophageal echocardiography
TIA	Transient ischemic attack

Title: Diagnosis of left atrial appendage thrombus using cardiac computed tomography: new insights from thrombi locations

Introduction

Transesophageal echocardiology (TEE) is currently the gold standard for the assessment of left atrial appendage (LAA) thrombi in patients undergoing catheter ablation of atrial fibrillation (AF)¹. In the past decades, cardiac computed tomography (CCT) has been widely studied for detecting LAA thrombus²⁻⁵. Recently, the delayed contrast-enhanced CCT at 6 minutes was reported to reach 100% sensitivity and negative predictive value in detecting LAA thrombus⁶. For patients who are not tolerant of the discomfort associated with TEE, CCT is proposed as a reliable alternative⁷. However, the accuracy of CCT varied between studies^{2-5, 8}, raising the safety concern and limiting the routine use of CCT.

The left atrial thrombi were classified into a movable ball, fixed ball, and mountain according to their morphology⁹. Around 1/3 of the thrombi in the left atrium were movable. Although CCT is of high spatial resolution, its temporal resolution is 4~17Hz, and it takes 60ms ~ 250ms to acquire one slice^{8, 10-12}. Compared to TEE, which allows live display with a high spatiotemporal resolution (<1mm, 20~30Hz)¹³, CCT is theoretically inferior for identifying moving objects in the left atrium. In addition, the circulatory stasis and the fibrillation of the atrial wall during AF also increase the difficulty of detecting movable thrombi¹⁴. In previous studies, the presence of LAA thrombus was 2(0.24%) ~16(19.04%)^{2-5, 15}. The high sensitivity and negative predictive value of CCT could be attributed to the low incidence of movable thrombus. Therefore, it is essential to investigate the diagnostic

accuracy of CCT in a larger cohort with a higher incidence of LAA thrombus.

In the current study, we retrospectively included 726 patients who had both TEE and CCT before catheter ablation for AF. 57(7.9%) patients were diagnosed with LAA thrombi using TEE. We aimed to evaluate the sensitivity of CCT in detecting LAA thrombus and to analyze the risk factors of false-negative results.

Methods

Study population

From May 2017 to December 2022, patients were routinely scheduled for TEE and CCT before catheter ablation of AF in Guizhou Provincial People's Hospital. Those who had both examinations within a 12-hour interval on the same day were retrospectively included. All the patient characteristics and images were acquired from the clinical database. The CHA₂DS₂-VASc score was calculated following the 2020 ESC guideline¹. The study was approved by the institutional ethics committee of Guizhou Provincial People's Hospital. The informed consent was waived due to the retrospective nature, and no identified information was collected.

CCT protocol

All patients were examined with a third-generation dual-source CT (SOMATOM Force, Siemens Healthineers, Forchheim, Germany). The imaging protocol included a standard

angiographic-phase acquisition to assess the anatomy of the left atrium and one delayed-phase acquisition at 30 s after contrast injection to detect thrombi. No electrocardiography gating was used. The tube voltage and current were automatically adapted using the CARE kV or CARE DOSE 4D with the reference of 100kV and 250mA. The gantry rotation time was 250ms, and the detector collimator was 192×0.6 mm. The scanning image covers the range from the aortic arch to the cardiac base. The monitoring site was localized within the left atrium. The contrast material containing 350 mg/ml of iodine was administered intravenously at 4-5 ml/s with a total dose of 35 ml by a double-barrel syringe, followed by the same amount of 0.9% saline. For the angiographic phase, the scanning was triggered when the monitoring site reached 90 HU. Then the delayed phase was acquired 30 s later. All images were reconstructed using the ADMIRE algorithm grade 3 with a layer thickness of 1 mm and interlayer spacing of 0.7 mm. The 3D left atrium and pulmonary veins were reconstructed using the Syngo.via software (Siemens Healthcare, Forchheim, Germany).

CCT image analysis

Images were transferred to an external workstation (Syngo VPCT body, Siemens Healthcare, Forchheim, Germany). Two independent radiologists with more than eight years of cardiovascular imaging, blinded to all patients' data, retrospectively evaluated the presence of LAA thrombus and LAA morphology. Thrombus was defined as a persistent filling defect in the 30s-delayed scans. The LAA morphology was classified into simple or complex according to their main and branching structures on the 3D reconstructions¹⁶. In disagreement,

the consensus was achieved in a final joint reading.

Transesophageal echocardiology

A PhilipsiEPIQ7C color Doppler ultrasound diagnostic instrument (Philips, Amsterdam, the Netherlands) and an X7-2t probe were used. The left atrium and LAA were scanned using a complete 2D, colored, pulsed, and continuous-wave Doppler echocardiogram according to the EACVI recommendations¹⁷. Thrombi were defined as circumscribed echogenic or echolucent masses distinct from the atrial wall. LAA ostium was defined as within the 5mm range of the junction between the smooth atrial wall and trabeculated LAA. The dimensions and locations of thrombi were assessed if present. The LAA filling and emptying velocity was averaged by ten consecutive measurements of the backward and forward flow rates using the pulsed wave Doppler. LAA mean flow velocity (LAAMFV) was calculated by halving the sum of the LAA filling and emptying velocity. Two independent cardiologists with more than five years of experience in echocardiology evaluated the presence of LAA thrombus and measured the flow velocity. Disagreements were resolved by consensus.

Statistical analysis

Continuous variables were expressed as mean \pm SD deviation. The Student's t-test was used for comparison if normally distributed; otherwise, the Mann-Whitney U test was used. Categorical variables were expressed as frequency (percentage). The Chi-square test was used for comparison if the expected frequency is more than 5; otherwise, Fisher's exact test was used. A two-tailed *p* value of less than 0.05 was considered statistically significant.

Using TEE as the reference standard, the diagnostic performance of CCT for LAA thrombi was calculated. All statistical analysis was performed using SPSS 26.0.

Results

Patient characteristics

A total of 726 patients (age: 61±11 years; male gender: 60.2%) with 57(7.9%) LAA thrombi diagnosed by TEE were included in the study (Figure 1). The patients with LAA thrombus had a higher incidence of previous stroke/transient ischemic attack (TIA), larger left atrial size, worse left ventricular function and a higher rate of complex LAA morphology than those without LAA thrombus ($p < 0.05$) (Table 1).

29(50.9%) of the thrombi were located at the LAA ostium and 28(49.1%) were in the LAA. The clinical characteristics and maximum thrombus diameter were similar between the patients. The thrombi at the LAA ostium were accompanied by higher LAA filling and emptying velocities than those in the LAA (Table 2). The former also showed significantly higher mobility following the blood flow and cardiac motion than the latter (Supplementary material online, Video S1).

Diagnostic accuracy of CCT

The CCT had an overall sensitivity of 68.4% and a specificity of 99.4% to the LAA thrombi (Table 1). However, the CCT was less sensitive to the thrombi at LAA ostium than

those in the LAA (48.3% vs. 89.3%, $p = 0.001$) (Table 2). Representative images are shown in Figure 2.

Given that high sensitivity is essential to exclude LAA thrombus, the CCT results of the LAA thrombi underwent further analysis. Compared with the CCT true-positive thrombi, the false-negative ones more frequently located at the LAA ostium (83.3% vs. 35.9%, $p = 0.001$), were shorter in the maximum diameters ($8\pm 2\text{mm}$ vs. $14\pm 9\text{mm}$, $p < 0.001$), and were accompanied by higher LAA filling and emptying velocities (0.53 ± 0.15 m/s vs. 0.38 ± 0.19 m/s, $p = 0.001$; 0.55 ± 0.21 m/s vs. 0.37 ± 0.14 m/s, $p < 0.001$) (Table 3). By scattering the CCT results on the 2-D plane that consisted of LAAMFV and thrombus maximum diameter, the thrombi at the LAA ostium with the LAAMFVs higher than 0.35m/s and maximum diameters shorter than 10mm were more prone to have CCT false-negative results (Figure 3A). The CCT false-negative thrombi in the LAA had maximum diameters shorter than 8mm (Figure 3B).

Discussion

Major findings

We reevaluated the accuracy of CCT for detecting LAA thrombus in the 726 patients undergoing catheter ablation for AF. TEE identified 57(7.9%) patients with LAA thrombi, of which 29(50.9%) were at the LAA ostium and 28(49.1%) in the LAA. The CCT was less sensitive in detecting LAA-ostium thrombi with smaller maximum diameters and higher

LAAMFV.

Concordance

LAA thrombus is thought to form initially inside the LAA, where circulatory stasis is the greatest, and then extends towards the ostium. However, we found over half of the thrombi located at the LAA ostium. The result was concordant with a previous study that 46.3% of the thrombi were at the entrance section of LAA⁹. The presence of pits and troughs adjacent to the LAA orifice was reported in 57.7% of the human heart specimens¹⁸. It could be the anatomic basis for thrombosis. Another study using TEE discovered small recesses proximal to the entry of LAA in a significant number of patients, but no thrombus related to these structures was detected following LAA occlusion¹⁹. The discrepancy could be due to patient selection bias. Nonetheless, our findings raised concerns about the role of LAA-ostium recesses in thrombosis.

Although the third-generation 64-slice dual-source CT was employed in the current study, its sensitivity to LAA thrombi was not improved. The sensitivity of 89.3% to the thrombi in the LAA was comparable to the previous studies^{2, 10, 11, 20-22}. However, the sensitivity significantly decreased for the LAA-ostium thrombi, which showed higher motility following blood flow and heartbeats than those in the LAA (Supplementary material online, Video S1). We further identified that the LAA-ostium thrombi with smaller sizes and higher LAA flow velocity were more prone to be missed using the CCT. As a higher temporal resolution is essential to detect movable objects²³, our findings suggested the impact of thrombus motility on CCT imaging. By calculating the gantry rotation time of 250ms, the CCT had a temporal

resolution of 4Hz, significantly less than that of the TEE (20~40Hz). Thus, the low sensitivity of CCT in our study could be presumed to: (1) inadequate temporal resolution, (2) the high proportion of movable LAA-ostium thrombi, (3) the lack of ECG gating, (4) only one 30s delayed scan was used. The 4 CCT false-positive results in our study could be the misdiagnosis of thrombus due to circulatory stasis during AF^{6, 24}.

Discordance

Several studies reported that the CCT had 100% sensitivity in detecting LAA thrombi using ECG gating and single-segment reconstruction algorithm^{25, 26}, or multiple delayed-phase scans^{3, 14, 27}. However, these studies have the following limitations: (1) Although the single-segment reconstruction algorithm increased the CCT's temporal resolution to 12Hz, the low incidence of LAA thrombus [2(0.24%) ~16(19.04%)] and the less variation of thrombus location could have overestimated the sensitivity of CCT for detecting LAA thrombi in a broader range of patients. (2) The multiple delayed-phase scans distinguished the thrombi from filling defects due to circulatory stasis. Still, the technique could not necessarily increase the sensitivity to smaller and movable thrombi located at the LAA ostium. We suggest that the CCT approach to detect LAA thrombi could differ according to their location. For static thrombi in LAA, persistent filling defects in multiple delayed-phase scans have been well established. For thrombi at LAA ostium, a temporal resolution comparable to TEE and even dynamic visualization could be necessary due to their higher motility.

Clinical implication

Our study found that the CCT with a 30s delayed scan did not reliably exclude LAA thrombus, especially those located at the LAA ostium. We did not find any clinical characteristics associated with the thrombus location. TEE is the only recommendation for stroke risk management for patients undergoing catheter ablation of AF in the 2020 ESC guideline¹. For those who do not tolerate TEE, intracardiac echocardiography could be considered²⁸.

Limitations

Firstly, this retrospective single-center study included only patients undergoing catheter ablation for AF. The study's findings may not be generalizable to other patients with AF. Secondly, the CCT protocol contained only one delayed-phase scan. Whether multiple delayed-phase scans reduce false-negative CCT results is unclear. Thirdly, other factors unaccounted for in this analysis – heart rhythm, atrial/ventricular rate, and blood pressure during the TEE and CCT – could affect the conclusions. Fourthly, although the interval between the TEE and CCT was less than 12 hours, it is theoretically possible for thrombi to form or disappear within this timeframe. Lastly, the incidence of LAA thrombus was higher than that in previous studies (partially due to less adherence to anticoagulation treatment), which could have affected the thrombus location and motility.

Conclusions

In patients undergoing catheter ablation of AF, CCT with a 30s delay scan is less

sensitive than TEE in detecting LAA thrombi, especially those located at LAA ostium with smaller sizes and higher LAA flow velocity.

Acknowledgements

We thank Nicholas Tan and Jason Tri from Mayo Clinic for their dedicated help in preparing the manuscript.

Sources of Funding

This study has received funding from the Science and Technology Support plan of Guizhou Province [No. (2017)2885 and (2018)2794], the Clinical Special Projects in Guizhou Province [NO. (2019)4430], and the Clinical Research Center Project of the Department of science and technology of Guizhou Province [NO. (2017)5405].

Disclosure: No potential conflict of interest relevant to this article to report.

Supplementary Material

Video S1

References

1. Hindricks G, Potpara T, Dagres N, Arbelo E, Bax JJ, Blomström-Lundqvist C,

- Boriani G, Castella M, Dan GA, Dilaveris PE, et al. 2020 esc guidelines for the diagnosis and management of atrial fibrillation developed in collaboration with the european association for cardio-thoracic surgery (eacts): The task force for the diagnosis and management of atrial fibrillation of the european society of cardiology (esc) developed with the special contribution of the european heart rhythm association (ehra) of the esc. *Eur Heart J*. 2021;42:373-498
2. Dorenkamp M, Sohns C, Vollmann D, Lütjhe L, Seegers J, Wachter R, Puls M, Staab W, Lotz J, Zabel M. Detection of left atrial thrombus during routine diagnostic work-up prior to pulmonary vein isolation for atrial fibrillation: Role of transesophageal echocardiography and multidetector computed tomography. *International Journal of Cardiology*. 2013;163:26-33
 3. Zhai Z, Tang M, Zhang S, Fang P, Jia Y, Feng T, Wang J. Transoesophageal echocardiography prior to catheter ablation could be avoided in atrial fibrillation patients with a low risk of stroke and without filling defects in the late-phase mdct scan: A retrospective analysis of 783 patients. *Eur Radiol*. 2018;28:1835-1843
 4. Li W, Yu F, Zhu W, Zhang W, Jiang T. Detection of left atrial appendage thrombi by third-generation dual-source dual-energy ct: Iodine concentration versus conventional enhancement measurements. *Int J Cardiol*. 2019;292:265-270
 5. Guha A, Dunleavy MP, Hayes S, Afzal MR, Daoud EG, Raman SV, Harfi TT. Accuracy of contrast-enhanced computed tomography for thrombus detection prior to atrial fibrillation ablation and role of novel left atrial appendage enhancement index in appendage flow assessment. *Int J Cardiol*. 2020;318:147-152
 6. Spagnolo P, Giglio M, Di Marco D, Cannà PM, Agricola E, Della Bella PE, Monti CB, Sardanelli F. Diagnosis of left atrial appendage thrombus in patients with atrial fibrillation: Delayed contrast-enhanced cardiac ct. *Eur Radiol*. 2021;31:1236-1244
 7. Yu S, Zhang H, Li H. Cardiac computed tomography versus transesophageal echocardiography for the detection of left atrial appendage thrombus: A systemic review and meta-analysis. *J Am Heart Assoc*. 2021;10:e022505
 8. Kottmaier M, Jilek C, Berglar S, Reents T, Bourier F, Semmler V, Telishevska M, Koch-Büttner K, Lengauer S, Kornmayer M, et al. Exclusion of left atrial thrombus

- by dual-source cardiac computed tomography prior to catheter ablation for atrial fibrillation. *Clin Res Cardiol*. 2019;108:150-156
9. Abe Y, Asakura T, Gotou J, Iwai M, Watanabe Y, Sando M, Ishikawa S, Nagata K, Saito T, Maehara K, et al. Prediction of embolism in atrial fibrillation: Classification of left atrial thrombi by transesophageal echocardiography. *Jpn Circ J*. 2000;64:411-415
 10. Kim YY, Klein AL, Halliburton SS, Popovic ZB, Kuzmiak SA, Sola S, Garcia MJ, Schoenhagen P, Natale A, Desai MY. Left atrial appendage filling defects identified by multidetector computed tomography in patients undergoing radiofrequency pulmonary vein antral isolation: A comparison with transesophageal echocardiography. *Am Heart J*. 2007;154:1199-1205
 11. Tang RB, Dong JZ, Zhang ZQ, Li ZA, Liu XP, Kang JP, Yu RH, Long DY, Ma CS. Comparison of contrast enhanced 64-slice computed tomography and transesophageal echocardiography in detection of left atrial thrombus in patients with atrial fibrillation. *J Interv Card Electrophysiol*. 2008;22:199-203
 12. Martinez MW, Kirsch J, Williamson EE, Syed IS, Feng DL, Ommen S, Packer DL, Brady PA. Utility of nongated multidetector computed tomography for detection of left atrial thrombus in patients undergoing catheter ablation of atrial fibrillation. *JACC: Cardiovascular Imaging*. 2009;2:69-76
 13. Vegas A. Three-dimensional transesophageal echocardiography: Principles and clinical applications. *Ann Card Anaesth*. 2016;19:S35-S43
 14. Maltagliati A, Pontone G, Annoni A, Formenti A, Galli CA, Tamborini G, Alimento M, Andreini D, Tondo C, Pepi M. Multidetector computed tomography vs multiplane transesophageal echocardiography in detecting atrial thrombi in patients candidate to radiofrequency ablation of atrial fibrillation. *Int J Cardiol*. 2011;152:251-254
 15. Budoff MJ, Shittu A, Hacioglu Y, Gang E, Li D, Bhatia H, Alvergue J, Karlsberg RP. Comparison of transesophageal echocardiography versus computed tomography for detection of left atrial appendage filling defect (thrombus). *Am J Cardiol*. 2014;113:173-177
 16. He J, Fu Z, Yang L, Liu W, Tian Y, Liu Q, Jiang Z, Tian L, Huang J, Tian S, et al.

- The predictive value of a concise classification of left atrial appendage morphology to thrombosis in non-valvular atrial fibrillation patients. *Clin Cardiol*. 2020;43:789-795
17. Flachskampf FA, Decoodt P, Fraser AG, Daniel WG, Roelandt JR. Guidelines from the working group. Recommendations for performing transesophageal echocardiography. *Eur J Echocardiogr*. 2001;2:8-21
 18. Su P, McCarthy KP, Ho SY. Occluding the left atrial appendage: Anatomical considerations. *Heart*. 2008;94:1166-1170
 19. Meincke F, Schmidt-Salzmann M, Kreidel F, Kuck KH, Bergmann MW. New technical and anticoagulation aspects for left atrial appendage closure using the watchman device in patients not taking warfarin. *Eurointervention*. 2013;9:463-468
 20. Homsy R, Nath B, Luetkens JA, Schwab JO, Schild HH, Naehle CP. Can contrast-enhanced multi-detector computed tomography replace transesophageal echocardiography for the detection of thrombogenic milieu and thrombi in the left atrial appendage: A prospective study with 124 patients. *Rofa*. 2016;188:45-52
 21. Shapiro MD, Neilan TG, Jassal DS, Samy B, Nasir K, Hoffmann U, Sarwar A, Butler J, Brady TJ, Cury RC. Multidetector computed tomography for the detection of left atrial appendage thrombus: A comparative study with transesophageal echocardiography. *J Comput Assist Tomogr*. 2007;31:905-909
 22. Hur J, Kim YJ, Lee HJ, Nam JE, Ha JW, Heo JH, Chang HJ, Kim HS, Hong YJ, Kim HY, et al. Dual-enhanced cardiac ct for detection of left atrial appendage thrombus in patients with stroke: A prospective comparison study with transesophageal echocardiography. *Stroke*. 2011;42:2471-2477
 23. Jung B, Föll D, Böttler P, Petersen S, Hennig J, Markl M. Detailed analysis of myocardial motion in volunteers and patients using high-temporal-resolution mr tissue phase mapping. *J Magn Reson Imaging*. 2006;24:1033-1039
 24. Fukushima K, Fukushima N, Kato K, Ejima K, Sato H, Fukushima K, Saito C, Hayashi K, Arai K, Manaka T, et al. Correlation between left atrial appendage morphology and flow velocity in patients with paroxysmal atrial fibrillation. *Eur Heart J Cardiovasc Imaging*. 2016;17:59-66
 25. Kapa S, Martinez MW, Williamson EE, Ommen SR, Syed IS, Feng D, Packer DL,

- Brady PA. Ecg-gated dual-source ct for detection of left atrial appendage thrombus in patients undergoing catheter ablation for atrial fibrillation. *J Interv Card Electrophysiol*. 2010;29:75-81
26. Kuronuma K, Matsumoto N, Suzuki Y, Makita A, Ashida T, Yokoyama K, Yoda S, Okumura Y. Usefulness of dual-phase snapshot 320-detector computed tomography for the detection of a left atrial appendage thrombus. *Int Heart J*. 2019;60:849-853
27. Wang L, Kadiyala M, Koss E, Yarramaneni A, Rapelje K, Kampfer S, Reichek N, Hoch D, Jayam V, Levine J, et al. Cta detection of left atrial stasis and thrombus in patients with atrial fibrillation. *Pacing Clin Electrophysiol*. 2016;39:1388-1393
28. He G, Liu H, Huang X, Deng X, Yang G, Luo D, Cai L. Intracardiac versus transesophageal echocardiography for diagnosis of left atrial appendage thrombosis in atrial fibrillation: A meta-analysis. *Clin Cardiol*. 2021;44:1416-1421

Figure legends

Figure 1 Patient flowchart.

Abbreviations: AF = atrial fibrillation; CCT = cardiac computed tomography; LAA = left atrial appendage; TEE = transesophageal echocardiography.

Figure 2 Representative TEE and CCT images of the LAA thrombi.

The upper panel shows CCT images. The lower panel shows TEE images. A-B.

Representative false-negative CCT result. The thrombus was located in the LAA. C-D.

Representative false-negative CCT result. The thrombus was located at the LAA ostium. E-F.

Representative true-positive CCT result. The thrombus was located in the LAA. G-H.

Representative true-positive CCT result. The thrombus was located at the LAA ostium. White arrows denote the thrombi.

Figure 3 Scatter plots of CCT results of LAA thrombi.

Red dots denote the CCT false-negative thrombi. Green dots denote the CCT true-positive thrombi. The LAAMFV was calculated by halving the sum of the LAA emptying and filling velocity. A. The CCT false-positive thrombi at the LAA ostium had the LAAMFV over 0.35 m/s and the maximum diameters over 10 mm. B. The CCT false-positive thrombi in the LAA ostium had a maximum diameter over 8 mm.

Abbreviations: CCT = cardiac computed tomography; LAA = left atrial appendage;

LAAMFV = left atrial appendage mean flow velocity.

Supplementary Legend

Supplementary Video1 Thrombi imaging of different location in TEE

A-C Thrombus located at the LAA ostium. D-F Thrombus located in the LAA.

Table 1 Patient characteristics.

Characteristics	Overall (n=726)	LAA thrombus *		P value
		Positive (n=57)	Negative (n=669)	
Age, year	61±11	64±10	61±11	0.129
Male	437(60.2)	36(63.2)	401(59.9)	0.634
Paroxysmal AF	436(60.1)	30(52.6)	406(60.7)	0.233
AF course, month	42±83	39±45	43±85	0.540
CHA ₂ DS ₂ -VASc score	2±2	3±2	2±2	0.089
Congestive heart failure	116(16.0)	18(31.6)	98(14.6)	0.001
Hypertension	346(47.7)	25(43.9)	321(48.0)	0.550
Diabetes mellitus	107(14.7)	10(17.5)	97(14.5)	0.534
Previous Stroke/TIA	91(12.5)	14(24.6)	77(11.5)	0.004
Vascular disease	292(40.2)	22(38.6)	270(40.4)	0.795
LAAPD, mm	36±7	41±9	36±7	<0.001
LVEDD, mm	46±5	49±7	46±5	0.006
LVEF, %	60±8	56±11	60±7	0.005
Complex LAA morphology	289(39.8)	35(61.4)	254(38.0)	0.001
CCT results				
Filling defects	43(5.9)	39(68.4)	4(0.6)	<0.001
No filling defects	683(94.1)	18(31.6)	665(99.4)	

Values are mean ± SD or n (%).

* The thrombi were detected using the TEE.

Abbreviations: AF = atrial fibrillation; CCT = cardiac computed tomography; CHA₂DS₂-VASc = congestive heart failure, hypertension, age ≥ 75 years (doubled), diabetes, previous stroke/transient ischemic attack/thromboembolism (doubled), vascular disease, age 65–74 years and sex category (female); LAA = left atrial appendage; LAAPD = left atrial anterior-posterior diameter; LVEDD = left ventricular end-diastolic diameter; LVEF = left ventricular ejection fraction; TEE = transesophageal echocardiography; TIA = transient ischemic attack.

Table 2 Patient characteristics between thrombus locations.

Characteristics	Thrombus location *		P value
	LAA ostium (n=29)	In LAA(n=28)	
Age, years	63±10	64±10	0.886
Male	20(69.0)	16(57.1)	0.355
Paroxysmal AF	18(62.1)	12(42.9)	0.146
AF course, month	40±52	39±35	0.648
CHA ₂ DS ₂ -VASc score	2±2	3±2	0.220
Congestive heart failure	9(31.0)	9(32.1)	0.928
Hypertension	10(34.5)	15(53.6)	0.147
Diabetes mellitus	5(17.2)	5(17.9)	1.000
Previous Stroke/TIA	7(24.1)	7(25.0)	0.940
Vascular disease	9(31.0)	13(46.4)	0.233
LAAPD, mm	41±10	40±8	0.873
LVEDD, mm	49±6	49±8	0.492
LVEF, %	57±11	55±11	0.424
Complex LAA	17(58.6)	18(64.3)	0.661
LAA filling velocity, m/s	0.48±0.19	0.37±0.19	0.021
LAA emptying velocity, m/s	0.47±0.20	0.38±0.16	0.050
Thrombus maximum diameter, mm	10±4	14±10	0.045
CCT results			
Filling defects	14(48.3)	25(89.3)	0.001
No filling defects	15(51.7)	3(10.7)	

Values are mean ± SD or n (%).

* The thrombus locations were determined using the TEE.

Abbreviations: AF = atrial fibrillation; CCT = cardiac computed tomography;

CHA₂DS₂-VASc = congestive heart failure, hypertension, age ≥ 75 years (doubled),

diabetes, previous stroke/transient ischemic attack/thromboembolism (doubled), vascular

disease, age 65–74 years and sex category (female); LAA = left atrial appendage; LAAPD=

left atrial anterior-posterior diameter; LVEDD = left ventricular end-diastolic diameter;

LVEF = left ventricular ejection fraction; TEE = transesophageal echocardiography; TIA =

transient ischemic attack.

Table3 Patient characteristics between CCT true-positive and false-negative results.

Characteristics	LAA thrombus *		P value
	CCT false-negative result (n=18)	CCT true-positive result (n=39)	
Age, years	64±9	64±10	0.810
Male	11(61.1)	25(64.1)	0.828
Paroxysmal AF	12(66.7)	18(46.2)	0.149
AF course, month	42±54	38±40	0.952
CHA ₂ DS ₂ -VASc score	3±2	3±2	0.450
Congestive heart failure	5(27.8)	13(33.3)	0.675
Hypertension	10(55.6)	15(38.5)	0.227
Diabetes mellitus	5(27.8)	5(12.8)	0.168
Previous Stroke/TIA	5(27.8)	9(23.1)	0.702
Vascular disease	7(38.9)	15(38.5)	0.975
LAAPD, mm	41±9	41±9	0.770
LVEDD, mm	49±6	49±7	0.336
LVEF, %	59±9	55±12	0.331
Complex LAA	9(50.0)	26(66.7)	0.230
LAA filling velocity, m/s	0.53±0.15	0.38±0.19	0.002
LAA emptying velocity, m/s	0.55±0.21	0.37±0.14	0.001
Thrombi maximum diameter, mm	8±2	14±9	<0.001
Thrombus location			
LAA ostium	15(83.3)	14(35.9)	0.001
In LAA	3(16.7)	25(64.1)	

Values are mean ± SD or n (%).

* The thrombi were detected using the TEE.

Abbreviations: AF = atrial fibrillation; CCT = cardiac computed tomography; CHA₂DS₂-VASc = congestive heart failure, hypertension, age ≥ 75 years (doubled), diabetes, previous stroke/transient ischemic attack/thromboembolism (doubled), vascular disease, age 65–74 years and sex category (female); LAA = left atrial appendage; LAAPD = left atrial anterior-posterior diameter; LVEDD = left ventricular end-diastolic diameter; LVEF = left ventricular ejection fraction; TEE = transesophageal echocardiography; TIA = transient ischemic attack.

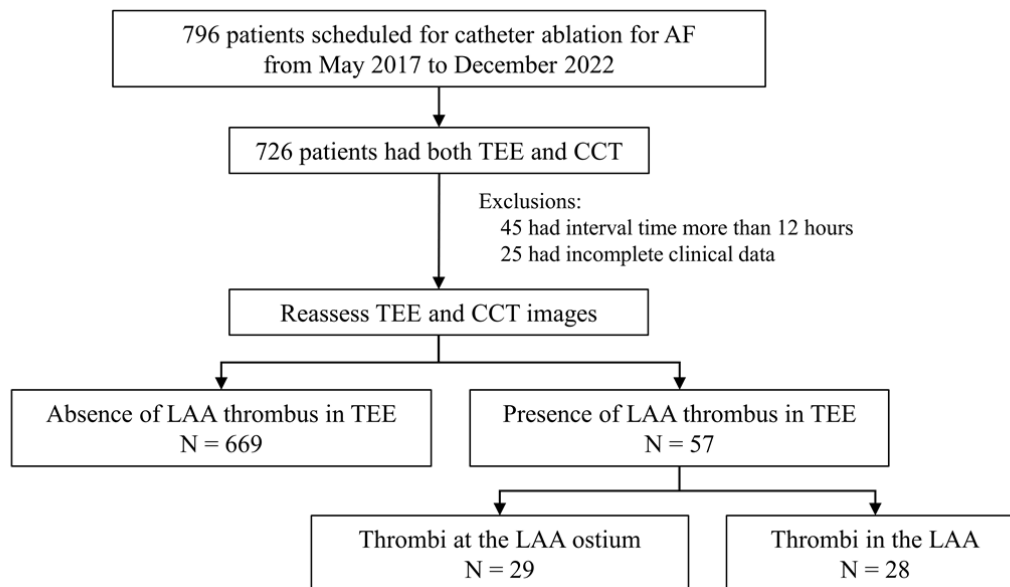


Figure 1 Patient flowchart.

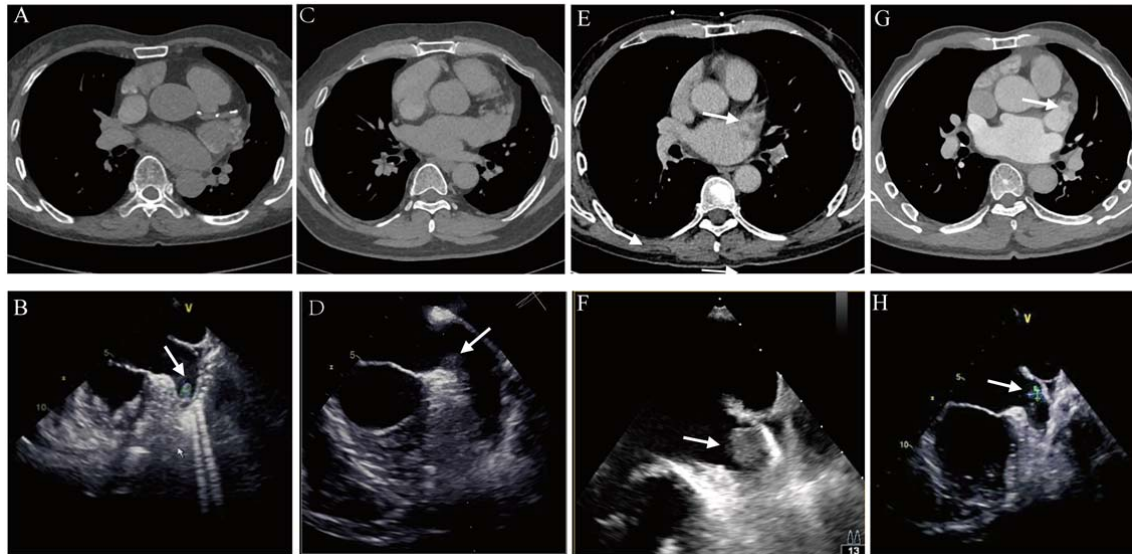


Figure 2 Representative TEE and CCT images of the LAA thrombi.

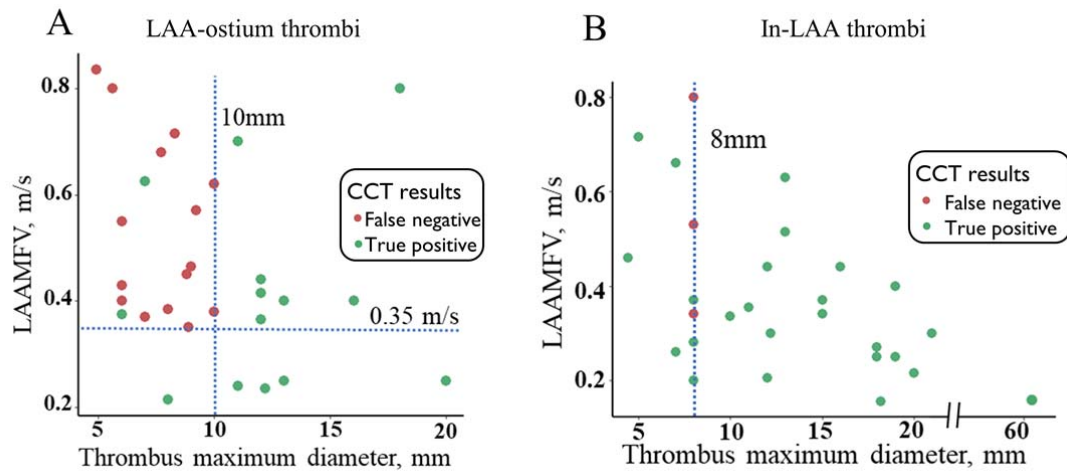


Figure 3 Scatter plots of CCT results of LAA thrombi.