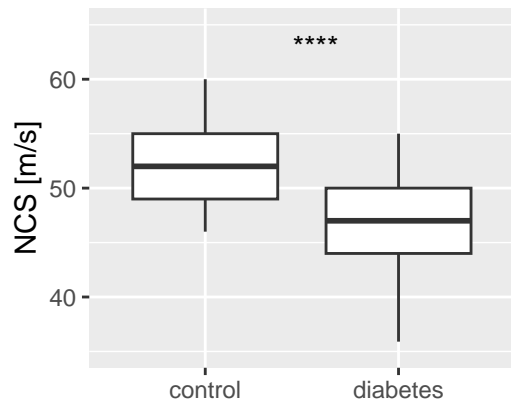
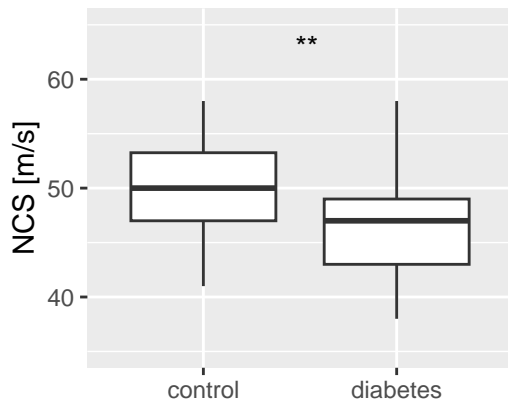


Figure 1

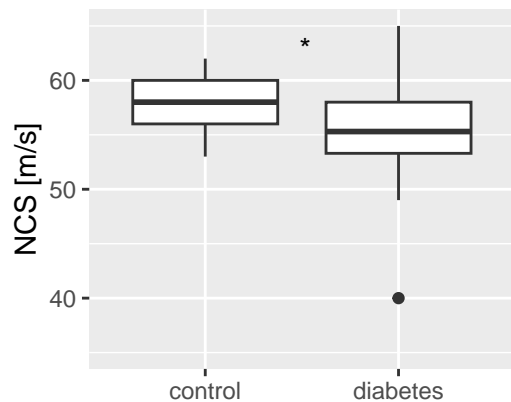
**A** N. peroneus



**B** N. tibialis



**C** N. medianus (motor)



**D** N. medianus (sensory)

