

1
2
3
4
5
6
7
8
9
10
11
12
13
14
15
16
17
18
19
20

The accuracy of machine learning models using ultrasound images in prostate cancer diagnosis: A systematic review

Retta C Sihotang¹, Claudio Agustino¹, Ficky Huang¹, Dyandra Parikesit², Fakhri
Rahman¹, Agus Rizal AH Hamid¹

¹ Department of Urology, Faculty of Medicine Universitas Indonesia, Cipto
Mangunkusumo Hospital, Jakarta, Indonesia

² Urology Medical Staff Group, Universitas Indonesia Hospital, Universitas Indonesia,
Depok, Indonesia.

Corresponding author: Agus Rizal A. Hamid
Mailing address: Faculty of Medicine, Universitas Indonesia, No.6, Salemba Raya Road,
DKI Jakarta, 10430, Indonesia
Tel.: +621-3912477
Mobile Phone: +628111803377
Email: rizalhamid.urology@gmail.com

21 **ABSTRACT**

22 Prostate Cancer (PCa) is the third most commonly diagnosed cancer worldwide, and its
23 diagnosis requires many medical examinations, including imaging. Ultrasound offers a
24 practical and cost-effective method for prostate imaging due to its real-time availability at
25 the bedside. Nowadays, various Artificial Intelligence (AI) models, including Machine
26 learning (ML) with neural networks, have been developed to make an accurate diagnosis.
27 In PCa diagnosis, there have been many developed models of ML and the model
28 algorithm using ultrasound images shows good accuracy. This study aims to analyse the
29 accuracy of neural network machine learning models in prostate cancer diagnosis using
30 ultrasound images. The protocol was registered with PROSPERO registration number
31 CRD42021277309. Three reviewers independently conduct a literature search in five
32 online databases (MEDLINE, EBSCO, Proquest, Sciencedirect, and Scopus). We
33 screened a total of 132 titles and abstracts that meet our inclusion and exclusion criteria.
34 We included articles published in English, using human subjects, using neural networks
35 machine learning models, and using prostate biopsy as a standard diagnosis. Non
36 relevant studies and review articles were excluded. After screening, we found six articles
37 relevant to our study. Risk of bias analysis was conducted using QUADAS-2 tool. Of the
38 six articles, four articles used Artificial Neural Network (ANN), one article used Recurrent
39 Neural Network (RNN), and one article used Deep Learning (DL). All articles suggest a
40 positive result of ultrasound in the diagnosis of prostate cancer with a varied ROC curve
41 of 0.76-0.98. Several factors affect AI accuracy, including the model of AI, mode and type
42 of transrectal sonography, Gleason grading, and PSA level. Although there was only
43 limited and low-moderate quality evidence, we managed to analyse the predominant

44 findings comprehensively. In conclusion, machine learning with neural network models is
45 a potential technology in prostate cancer diagnosis that could provide instant information
46 for further workup with relatively high accuracy above 70% of sensitivity/specificity and
47 above 0.5 of ROC-AUC value. Image-based machine learning models would be helpful
48 for doctors to decide whether or not to perform a prostate biopsy.

49

50 **Keywords:** Machine learning, Artificial Intelligence, Neural Networks, Prostate Cancer,
51 Ultrasonography

52

53 Introduction

54 Prostate cancer (PCa) is the third most common cancer globally and the second most
55 common cancer in men. In 2020, there were an estimated 1,4 million new cases and
56 375,000 new prostate cancer deaths worldwide.[1] There are several modalities to
57 diagnose PCa, including digital rectal examination (DRE), prostate-specific antigen (PSA)
58 levels, biomarkers, imaging, and histopathology. The current gold standard for PCa
59 detection in core needle biopsy, performed under transrectal ultrasound (TRUS)
60 guidance.[2-5] The role of ultrasound (US) in this procedure is not for targeting PCa but
61 for anatomical navigation. Aside from the complications associated with the biopsy, high
62 levels of underdiagnosed and overtreatment have been reported.[6-7]

63

64 Ultrasound is a potential candidate for PCa imaging because it is cost-effective, practical,
65 and widely available. The problem of ultrasound images interpretation is that hypoechoic
66 areas suspected of cancer can be normal or cancerous histologically. Most prostate

67 cancers are hypoechoic on TRUS, whereas 30%-40% of prostate cancer are isoechoic,
68 and 1.5% are hyperechoic.[8] The sensitivity and specificity of TRUS are limited, ranging
69 between 40% and 50% for detecting PCa.[8,9] Several studies depict that using grey
70 mode US alone is inadequate for PCa screening.[10] However, there are several new
71 modes of US in prostate gland imaging, such as contrast-enhanced ultrasound (CEUS),
72 color Doppler and ultrasound elastography. CEUS is an ultrasound technique that uses
73 intravenous injected gas-filled microbubbles as a contrast agent to provide microvascular
74 and tissue perfusion information.[11] Color Doppler mode has capability to detect motion
75 or blood flow using a color map to show the speed and direction of blood flow through
76 vessel.[12] Ultrasound elastography is a non-invasive imaging technique to measure
77 changes in soft tissue elasticity.[13] Those new modes increase overall accuracy in
78 detecting PCa in comparison to grey mode.[10-17] However, the diagnostic performance
79 of those modes is still not quite satisfactory with a wide range of sensitivity (67% to 93%)
80 and specificity (59% to 93%).[12-13,16-17]

81

82 Artificial Intelligence (AI) is defined as an ability of a computer to perceive the surrounding
83 environment and make the same decisions as a human intellect on an action to reach a
84 particular goal.[18] AI is now a revolutionising technology in the healthcare field and is
85 gaining interest. Machine learning (ML) is a branch of AI that focuses on using data and
86 algorithms to improve accuracy. To train machine learning, it is enough to acquire
87 structured datasets consisting of input variables and outcomes. AI has a vital role in
88 interpreting large amounts of data. Neural networks (such as artificial neural networks –
89 ANN, convolutional neural networks – CNN, recurrent neural networks – RNN) are

90 machine learning models which work like human biological neuron. They have ability to
91 learn and model non-linear and complex relationships that enable them to generate
92 relationships between inputs and outputs in a complex pattern. The developed algorithm
93 of machine learning may help urologists to reduce the number of unnecessary prostate
94 biopsies without missing the diagnosis of aggressive PCa.[19]

95
96 In PCa, AI has been shown to aid in a standardised pathological grading to assess cancer
97 stratification and treatment. Numerous studies have evaluated the utility of prostate
98 specific antigen (PSA) and/or magnetic resonance imaging (MRI) in the setting of AI in
99 detecting prostate cancer. Nitta et al.[20] and Djavan et al.[21] applied machine learning
100 models to predict prostate cancer based on PSA levels. Machine learning tends to be
101 superior to the conventional methods with ROC-AUC ranging from 0.63-0.91 based on
102 the machine learning models and PSA categories. Aldoj et al.[22] utilized AI using MRI
103 with 3D combinations (apparent diffusing coefficient (ADC), diffusion weighted imaging
104 (DWI), and T2 weighted images) which generated sensitivity at 81.2% and specificity at
105 90.5%. The high diagnostic performance is also found in a study by Yoo et al.[23] using
106 deep CNN analysis of DWI sequence with ROC-AUC of 0.84-0.87. However, the
107 accuracy of machine learning using ultrasound data as the primary modality remains
108 debatable. This review aims to analyse the accuracy of neural networks ML models using
109 ultrasound images in prostate cancer diagnosis.

110

111 **Methods**

112 **Protocol Registration**

113 The protocol for this systematic review was registered with PROSPERO registration
114 number CRD42021277309.

115

116 **Search Strategy**

117 Three reviewers independently (RC, CA, FH) conducted a literature search in five online
118 databases (MEDLINE, EBSCO, Proquest, ScienceDirect, and Scopus) on November
119 19th, 2021. The keywords used were “Prostate Cancer” AND “Machine Learning” AND
120 “Diagnosis” AND “Ultrasonography with various combinations as written in **Table 1**. The
121 researcher also reviewed the reference list of chosen articles from the literature search
122 to identify relevant studies.

123

124 **Table 1.** Literature search strategy

Database	Keywords	Result	Date attempt
PubMed	((((prostate cancer or prostate carcinoma) AND (((imaging) OR (Ultrasonography)) OR (transrectal ultrasonography)) OR (TRUS))) AND ((diagnostic outcome) AND (diagnosis))) AND (((machine learning) OR (deep learning)) OR (artificial neural network)) OR (convolutional	78	November 19 th , 2021

	neural network))		
EBSCO	machine learning or artificial intelligence or deep learning or neural network AND prostate cancer AND ultrasound or sonography or ultrasonography [Title]	7	November 19 th , 2021
Proquest	ab(prostate cancer) AND ab(ultrasound) AND ab(artificial neural network OR machine learning) AND ab(diagnosis)	4	November 19 th , 2021
Sciencedirect	Title, abstract, keywords: (prostate cancer) AND (ultrasound) AND (machine learning OR neural network) AND (diagnosis) [research articles]	13	November 19 th , 2021
Scopus	TITLE-ABS-KEY (machine AND learning AND ultrasound AND prostate AND cancer AND diagnosis)	43	November 19 th , 2021

126 **Study Selection and Data Extraction**

127 We included all available articles about machine learning use in prostate cancer diagnosis
128 that used ultrasound images. We restricted our search to articles published in English
129 without a publication date limit. A study was considered relevant if it fulfilled our inclusion
130 criteria: using human subjects, using neural networks machine learning models, and
131 using prostate biopsy as a standard diagnosis. We included cohort, case-control, and
132 cross-sectional studies. An article was excluded from the selection if it was a
133 conference/review article, combination examination with MRI, or no diagnostic parameter
134 in the article. All reviewers screened the title and abstract of the selected papers
135 independently. Discrepancies between the reviewers were solved through discussion
136 with the senior reviewers (DP, ARAH, and FR) until the consensus was reached. All
137 authors agreed on the final list of selected papers for extraction. The PRISMA flow
138 diagram is used to guide the article selection process.

139

140 **Risk of Bias Assessment**

141 Three reviewers independently evaluated the methodological quality of the studies using
142 the QUADAS-2 Tool in Review Manager software 5.4 version. The reviewers were not
143 blinded for the author, journal, or publication identities of each article. The risk of bias
144 assessment consists of three categories: high, unclear, or low risk of bias based on the
145 pre-listed questions in the QUADAS-2 Tools.

146

147

148

149 **Results**

150 Our electronic search identified 145 articles and only 6 that met our inclusion and
151 exclusion criteria (**Fig 1**). Four articles use the artificial neural networks (ANN) method,
152 one article uses the recurrent neural network (RNN) method, and one article uses the
153 deep learning (DL) method. The characteristics of each study are described in Table 2.
154 The six included studies used a cross-sectional study design. All articles studied adult
155 male human subjects with an unknown age range due to the unclear data. The sample
156 size ranges from 61 to 1077 patients; however, a study from Ronco et al.[24] only
157 provided the number of cases.

158

159 **Figure 1.** Prisma Flow Diagram

160

161 The quality assessment of the six included articles is shown in **Fig 2** using the QUADAS-2
162 Tool. Several articles have an unclear and high risk of bias. However, we still included
163 the articles in our analysis. The unclear risk of bias is most commonly found in Index Test
164 parameters because of the unclear threshold of the Index test. The high risk of bias is
165 also most commonly found in Index Test parameters due to the results were interpreted
166 with the knowledge of reference standard results in several articles.[24-26]

167

168 **Figure 2.** Risk of Bias Assessment using QUADAS-2 Tool

169

170 Three articles used TRUS data only for the input parameter and the rest three articles
171 used combination input data from clinical findings. The included studies showed various

172 parameters of accuracy analysis, including ROC-area the curve (AUC), positive
173 predictive value (PPV), negative predictive value (NPV), sensitivity, and specificity (**Table**
174 **2**). However, a study from Loch et al.²⁵ used percentage only. The performance results
175 can be seen in **Table 2**. Due to the varied parameters, a quantitative analysis could not
176 be performed. Most of the articles used ROC-AUC as the accuracy parameters.

177 **Table 2.** Characteristics and Performance Result of Included Studies

No	Author, year	Country	Samples	Imaging	ML Method	Input Data	Outcome	Performance Results
1	Ronco, 1999[24]	Uruguay	442 cancer and benign cases	Transrectal ultrasonography	ANN	Ultrasonographic variables: <ul style="list-style-type: none"> • Transverse axis • Anteroposterior axis • Longitudinal axis • Prostatic volume • Central zone • Echoic level 	Accuracy of detecting prostate cancer	PPV 81.82% NPV 96.95%

					<ul style="list-style-type: none">• Volume of the pathological area• Major diameter of the pathological area• Minor diameter of the pathological area• Presence/absence of calcifications		
--	--	--	--	--	--	--	--

- | | | | | | | | |
|--|--|--|--|--|--|--|--|
| | | | | | <ul style="list-style-type: none">• Degree of bladder impression• PSA density (PSA/volume)• Ultrasonographic diagnosis | | |
|--|--|--|--|--|--|--|--|

Non-ultrasonographic variables:

- Age
- Previous clinical diagnosis

						<ul style="list-style-type: none"> Prostatic specific antigen level Number of biopsies		
2	Loch, 1999[25]	Nevada	553 specimens from 61 patient with confirmed prostate cancer	Transrectal ultrasonography	ANN	TRUS Findings	Accuracy of detecting prostate cancer	Benign pathology: 99% classified correctly; Cancer: 71% classified correctly
3	Lee, 2006[26]	Korea	684 patients who had	Transrectal ultrasonography	ANN	Model 1: <ul style="list-style-type: none"> Age 	Diagnostic performance	Model 2 showed

		undergone TRUS-guided prostate biopsy	y and Doppler ultrasonography	<ul style="list-style-type: none"> • DRE findings • PSA level • PSA density • Transitional zone volume • PSA density in the transitional zone <p>Model 2:</p> <ul style="list-style-type: none"> • Age • DRE findings • PSA level • PSA density • Transitional zone volume 	e of 2 ANN models	<p>better accuracy than Model 1.</p> <p>Accuracy M1</p> <ul style="list-style-type: none"> • AUC PSA 0-4: 0.738 • PSA 4-10: 0.753 • PSA>10:0.774 <p>Accuracy M2</p> <ul style="list-style-type: none"> • AUC PSA 0-4: 0.859 • PSA 4-10:
--	--	---------------------------------------	-------------------------------	--	-------------------	---

						<ul style="list-style-type: none"> • PSA density in the transitional zone • TRUS findings (positive, suspicious, negative) 		0.797 PSA>10:0.89 4
4	Lee,2009 [27]	Korea	1077 patients who had undergone TRUS guided prostate biopsy	Transrectal ultrasonography and Doppler ultrasonography	MLRA, ANN, SVM	<ul style="list-style-type: none"> • Age • DRE findings • PSA level • PSA density • Transitional zone volume • PSA density in 	Accuracy of each model	ROC MLRA 0.768 ROC ANN 0.778 ROC SVM 0.847

						<p>the transitional zone</p> <ul style="list-style-type: none"> • TRUS findings (Class I-V based on lesion location, outline, shape, and vascularity) 		
5	Azizi, 2018 [28]	Canada	157 subjects who had undergone prostate biopsy	Temporal enhanced ultrasound	RNN comparing LTSM, GRU, Vanilla RNN, and	TeUS findings	Accuracy of detecting prostate cancer	LTSM <ul style="list-style-type: none"> • Specificity 0.98 • Sensitivity 0.76 • Accuracy

					Spectral		0.93
							• AUC 0.96
							GRU
							• Specificity
							0.95
							• Sensitivity
							0.70
							• Accuracy
							0.86
							• AUC 0.92
							Vanilla RNN
							• Specificity
							0.72
							• Sensitivity

								0.69
								• Accuracy
								0.75
								• AUC 0.76
								Spectral
								• Specificity
								0.73
								• Sensitivity
								0.63
								• Accuracy
								0.78
								• AUC 0.76

6	Wildeboer, 2020[29]	Netherlands	48 men with confirmed prostate cancer	B-mode US, SWE, and DCE- US	DL	TRUS findings	Accuracy of multiparametric ultrasound	ROC-AUC for Prostate Cancer 0.75 ROC-AUC for Gleason > 3+ 4 0.90
---	---------------------	-------------	---------------------------------------	-----------------------------	----	---------------	--	---

178 (**ANN**: Artificial Neural Network; **AUC**: Area under the Curve; **DCE-U**: Dynamic contrast-enhanced ultrasound; **DL**: Deep
179 Learning; **DRE**: Digital Rectal Examination; **GRU**: Gated Recurrent Units; **LTSM**: Long Short-Term Memory; **MLRA**: Multiple
180 Logistic Regression Analysis; **NPV**: Negative Predictive Value; **PPV**: Positive Predictive Value; **PSA**: Prostate Specific
181 Antigen; **RNN**: Recurrent Neural Network; **ROC**: Receiver Operating Characteristic; **SVM**: Support Vector Machine; **SWE**:
182 Shear-wave Elastography; **TRUS**: Transrectal sonography)

183 **Discussion**

184 **Ultrasound in Prostate Cancer**

185 PCa may be suspected when the PSA level increases above normal or if the digital rectal
186 examination (DRE) is abnormal.[2,3] After that, further examinations are carried out to
187 make the diagnosis, including imaging and biopsy as a standard diagnosis. Ultrasound
188 and MRI have been assessed for their ability to reliably detect PCa in men suspected with
189 PCa. MRI allows better visualization of prostate anatomical zones and location of tumor
190 with the extension within the gland. It is useful to allow lesion detection and enable
191 functional imaging of the prostate.[30] The use of MRI as a single modality to detect PCa
192 has been evaluated. Several studies revealed MRI carries a relatively high sensitivity, but
193 poor specificity. Multiparametric MRI has been used widely and shows good sensitivity in
194 larger tumors. However, it is less sensitive to detect lower grade PCa (ISUP Grade 1)
195 with pooled sensitivity of 0.70 and pooled specificity of 0.27.[31] From the current
196 recommendation, multiparametric MRI become the clinical routine examination for
197 patients with suspected PCa and PCa staging.[32-34]

198
199 Ultrasound is a cost-effective and widely available imaging modality. However, standard
200 TRUS is not a reliable imaging method due to the low sensitivity and specificity in
201 detecting prostate cancer.[5,9,35] TRUS was initially developed with the aim to guide
202 transperineal biopsies. After being evaluated for years, it became evident that cancers of
203 the prostate were most often anechoic or hypoechoic. However, prostatitis and focal
204 infarct also have been reported to have the appearance of hypoechoic lesions on
205 ultrasound, which cause false positive results.[36]

206

207 TRUS has several limitations in basic modes, such as similar backscatter signals of
208 cancerous and normal prostate parenchyma and heterogeneity of the transitional
209 zone.[37] Other modes of TRUS such as color Doppler, CEUS, TeUS, and elastography
210 revealed better performance than B-mode.[29,38-39] Recently, innovations have been
211 made to improve accuracy in detecting prostate cancer. Foster et al. developed
212 ultrasound biomicroscopy, performed at frequencies ranging between 14 and 29 MHz,
213 with theoretical spatial resolution at this frequency being between 50 and 70um. This
214 innovation allowed the visualisation of prostate anatomy details that usually could not be
215 seen in conventional US examinations.[40,41] Despite the limitations, TRUS guided
216 biopsy is still the gold standard for the diagnosis of prostate cancer.

217

218 Although MRI has excellent ability to identify clinically significant PCa, MRI is quite
219 expensive, not portable, and not readily available in healthcare centers. In addition, MRI
220 could not provide real time imaging compared to ultrasound. With such disadvantages,
221 TRUS still has a potential role as imaging modality in prostate cancer diagnosis.[30] A
222 comparative study by Zhang et al showed multiparametric TRUS (grayscale, color
223 Doppler, shear wave elastography, and contrast enhanced ultrasound) had higher
224 sensitivity, negative predictive value, and accuracy than multiparametric MRI (T2-
225 weighted, diffusion-weighted, and dynamic contrast-enhanced MRI) in detecting localized
226 PCa.[42] From evidences, TRUS has some advantages in detecting localized PCa from
227 MRI with lower cost, real time, and higher availability.

228

229 **Machine Learning increasing the Role of TRUS in Prostate**

230 **Cancer Diagnosis**

231 Ultrasound imaging is limited by operator dependence and poor reproducibility. To read
232 ultrasound images, it requires years of experience and training. To overcome the
233 limitations, machine learning have been developed in medical imaging to accelerate
234 ultrasound image analysis and generate an objective disease classification.[43] In recent
235 years, applications of ML to US is developing and rapidly progressing. ML can help by
236 decreasing the time of reader that interprets the amount of data to make a conclusion.[44]
237 ML is a subdiscipline of AI where computer programs learn associations of predictive
238 power from examples of data.[45] Several methods such as classification, regression,
239 registration, and segmentation applied to analyse ultrasound images. However, neural
240 networks algorithms have been shown to significantly improve performance when
241 compared to other classifiers.[43] Neural networks, which work like human brain, gives
242 capability to solve problems based on the available data. This model can incorporate
243 many variables and produce results in more complex situations.[45] In PCa diagnosis,
244 ML can generate input data from various variables to classify whether the patient is
245 suspected of having prostate cancer or not (**Fig 3**).

246

247 **Figure 3.** Schematic Machine Learning Model in Prostate Cancer Diagnosis

248 Input data includes all available variables that could be beneficial to generate a
249 conclusion. Machine learning modeling consists of complex hidden layers which take an
250 essential role in data processing. The result part is a conclusion of the machine learning
251 build-up algorithm based on the input data.

252

253 Based on our included studies, the overall accuracy of machine learning shows promising
254 results. ROC-AUC values of five studies showed a number greater than 0.5 with a range
255 of 0.75 to 0.98. Wildeboer et al.[29] assessed the potential DL model based on TRUS's
256 B-mode, SWE, and DCE-US. The multiparametric classifier reached ROC-AUC of 0.90
257 compared to 0.75 of the best performing individual parameter for PCa and Gleason >3 +
258 4 significant PCa. The study revealed that combinations of the available modes were
259 favoured compared to single-mode. Lee et al.[26] evaluated the accuracy of the multiple
260 logistic regression model, ANN model, and support vector machine model to predict
261 prostate biopsy outcomes. The models were constructed from the input data of age, DRE
262 findings, PSA parameters, and TRUS findings. This study showed that image-based
263 clinical decision support systems (ANN and SVM) have better accuracy than the multiple
264 logistic regression model. However, SVM was superior to the performance of both ANN
265 and the multiple logistic regression model. Lee et al.[27] evaluated the diagnostic
266 performance of the ANN model with and without TRUS data. This study included 684
267 patients who underwent prostate biopsy, with 214 confirmed to have prostate cancer.
268 ANN model was used with primary input data of age, PSA levels, and DRE findings.
269 However, with additional TRUS data, the accuracy of the ANN model was found to be
270 more accurate with a higher value of ROC-AUC. Azizi et al.[28] proposed temporal
271 modeling of TeUS using RNN to improve cancer detection accuracy. TeUS data were
272 acquired from 157 subjects during fusion prostate biopsy. This model achieves a ROC-
273 AUC value of 0.96.

274

275 The various levels of accuracy are affected by several factors, including the model of AI,
276 modes of TRUS, amount of input data, Gleason grading, and PSA levels. Modes of TRUS
277 are significantly associated with accuracy, where the DCE-US/SWE/TeUS will improve
278 the visualisation and differentiation of prostate tissues compared to the B-mode. The
279 amount of input data is also an essential factor in making an accurate result in ANN
280 models. More complex data will create a more precise diagnosis.[44] Studies by Lee et
281 al.[27] and Wildeboer et al.[29] revealed that more data combinations would increase the
282 ROC-AUC value, increasing accuracy. Wildeboer et al.[29] showed a significant
283 relationship in Gleason score > 3+4, but no significant result in Gleason score 3+3 or 3+4.
284 This might be due to a bias in patient selection; tumors in 3+3 are considered
285 disproportionately large for clinicians, thus, not included in the study. Based on a study
286 by Lee et al.[27], the ROC-AUC of ANN models is consistently higher in PSA levels above
287 10. This might be associated with serum PSA levels which correlate with the extent of
288 cancer and histological grade.[46] Thus, TRUS is not reliable to detect PCa as a single
289 tool. However, with utilization of machine learning and combinations of relevant input
290 data, TRUS has a potential role.

291

292 **Future Development of Machine Learning-TRUS Model**

293 The machine learning field is advancing rapidly and is supported by new hardware and
294 software technology development. High-resolution and multiparametric imaging can be
295 fused and integrated with other data sets to diagnose prostate cancer better.[47,48] The
296 utilization of machine learning with TRUS data could have a potential role as a diagnostic
297 modality, especially where MRI is not available. Based on the current guidelines, T2-

298 weighted imaging remains the most useful imaging method for local imaging on MRI.[49]
299 However, a meta-analysis by Rooij et al.[50] MRI has high specificity but poor sensitivity
300 for local PCa staging with sensitivity and specificity for extracapsular extension (ECE),
301 seminal vesicle invasion (SVI), and overall stage T3 detection of 0.57 (95% confidence
302 interval [CI] 0.49-0.64) and 0.91 (95% CI 0.88-0.93), 0.58 (95% CI 0.47-0.68) and 0.96
303 (95% CI 0.95-0.97), and 0.61 (95% CI 0.54-0.67) and 0.88 (95% CI 0.85-0.91),
304 respectively. Our findings showed that machine learning with TRUS other relevant data
305 could increase the diagnostic performance. Thus, it will become more affordable and
306 easier to diagnose PCa by not performing MRI. Furthermore, the use of TRUS with
307 machine learning can be implemented as a fused combination with MRI to do a prostate
308 biopsy and intraoperative mapping to register preoperative MRI during robotic surgery.
309 This feature allows the surgeon to visualize the suspected lesions on the instrument
310 display during the procedure.

311

312 **Limitation of the Study**

313 We provide all available evidence about machine learning models of human ultrasound
314 images in prostate cancer diagnosis. However, none of the articles shows the same
315 output parameters to generate a quantitative analysis. Our approach included a
316 comprehensive search of multiple databases as well as other sources for relevant
317 publications. Since we restricted our literature search in English, some articles in other
318 languages may be missed out. The major weakness of this study is low to moderate
319 quality of included studies and the limited number of studies. Although there was only
320 limited evidence, we managed to analyse the predominant findings comprehensively.

321

322 **Conclusions**

323 Machine learning with neural network models is a potential technology in prostate cancer
324 that could provide instant information for further workup with relatively high accuracy
325 above 70% of sensitivity/specificity and above 0.5 of ROC-AUC value. Image-based
326 machine learning models would be helpful for doctors to decide whether or not to perform
327 a prostate biopsy. Future development of this technology will be further beneficial in
328 making a diagnosis and treatment evaluation and patient prognosis.

329

330 **Acknowledgement**

331 Technical assistance and critical advice are provided by the staff of the Department of
332 Urology, Ciptomangunkusumo National Hospital.

333

334 **Conflict of Interest**

335 The authors report no conflict of interest. The authors alone are responsible for the
336 content and writing of this article.

337 **Funding**

338 We have no funding providers on this paper.

339 **REFERENCES**

- 340 1. Sung H, Ferlay J, Siegel RL, Laversanne M, Soerjomataram I, Jemal A, et al.
341 Global cancer statistic 2020: GLOBOCAN estimates of incidence and mortality

- 342 worldwide for 36 cancers in 185 countries. *Cancer Journal for Clinicians*.
343 2021;71(3):209-249.
- 344 2. Hayes JH, Barry MJ. Screening for prostate cancer with the prostate-specific
345 antigen test: a review of current evidence. *JAMA*. 2014;311:1143.
346 <https://pubmed.ncbi.nlm.nih.gov/24643604>
- 347 3. Naji L, Randhawa H, Sohani Z, Dennis B, Lautenbach D, Kavanagh O, et al.
348 Digital Rectal Examination for Prostate Cancer Screening in Primary Care: A
349 Systematic Review and Meta-Analysis. *Ann Fam Med*. 2018;16:149.
350 <https://pubmed.ncbi.nlm.nih.gov/29531107>
- 351 4. Kretschmer A, Tilki D. Biomarkers in prostate cancer - Current clinical utility and
352 future perspectives. *Crit Rev Oncol Hematol*. 2017;120:180.
353 <https://pubmed.ncbi.nlm.nih.gov/29198331>
- 354 5. Bratan F, Niaf E, Melodelima C, Chesnais AL, Souchon R, Mege-Lechevallier F,
355 et al. Influence of imaging and histological factors on prostate cancer detection
356 and localisation on multiparametric MRI: a prospective study. *Eur Radiol*. 2013;23
357 2019. <https://pubmed.ncbi.nlm.nih.gov/23494494>
- 358 6. Loeb S, Vellekoop A, Ahmed HU, Catto J, Emberton M, Nam R, et al. Systematic
359 review of complications of prostate biopsy. *Eur Urol*. 2013;64:876–892. <https://doi.org/10.1016/j.eururo.2013.05.049>
- 360
361 7. Ukimura O, Coleman JA, de la Taille A, Emberton M, Epstein JI, Freedland SJ, et
362 al. Contemporary role of systematic prostate biopsies: indications, techniques,
363 and implications for patient care. *Eur Urol*. 2013;63:214–230

- 364 8. Ganie FA, Wanie MS, Ganie SA, Lone H, Gani M, Mir MF, et al. Correlation of
365 transrectal ultrasono- graphic findings with histopathology in prostatic cancer. *J*
366 *Educ Health Promot.* 2014;3:38.
- 367 9. Chen FK, Abreu ALC, Palmer SL. Utility of ultrasound in the diagnosis, treatment
368 and follow-up of prostate cancer: State of the art. *J Nucl Med.* 2016;57:13S-18S.
- 369 10. Kuligowska E, Barish MA, Fenlon HM, Blake M. Predictors of prostate carcinoma:
370 accuracy of gray-scale and color dopples US and serum markers. *Radiology.*
371 2001;220(3):757-64.
- 372 11. Leen E, Averkiou M, Arditi M, Burns P, Bokor D, Gauthier T, et al. Dynamic
373 contrast enhanced ultrasound assessment of the vascular effects of novel
374 therapeutics in early stage trials. *Eur Radiol.* 2012;22:1442–1450.
- 375 12. Sen J, Choudhary L, Marwah S, Godara R, Marwah N, Sen R. Role of colour
376 doppler imaging in detecting prostate cancer. *Asian J Surg.* 2008;31(1):16-19.
- 377 13. Sang L, Wang X, Xu D, Cai Y. Accuracy of shear wave elastography for the
378 diagnosis of prostate cancer: a meta-analysis. *Scientific Reports.* 2017;7.
- 379 14. Lin CY, Yi T, Gao YZ, Zhou JH, Huang QH. Early detection and assessment of
380 liver fibrosis by using ultrasound RF time series. *Journal of Medical and Biological*
381 *Engineering.* 2017;37(5):717–729.
- 382 15. Lin Q, Zhou J, Wang J, Li Q, Li A, Lin C, et al. Ultrasonic RF time series for early
383 assessment of tumor response to chemotherapy: First in vivo studies on mice
384 breast cancer model. *Ultrasound in Medicine and Biology.* 2017;43:p. S3.

- 385 16. Liu G, Wu S, Huang L. Contrast-enhanced ultrasound evaluation of the prostate
386 before transrectal ultrasound-guided biopsy can improve diagnostic sensitivity.
387 *Medicine*. 2020;99(19):e19946.
- 388 17. Li H, Xia J, Xie S, Guo Y, Xin M, Li F. Prostate cancer: a comparison of the
389 diagnostic performance of transrectal ultrasound versus contrast enhanced
390 transrectal ultrasound in different clinical characteristics. *Int J Clin Exp*.
391 2015;8(11):21428-21434.
- 392 18. Russell Stuart J, Norvig P. Artificial Intelligence: A Modern Approach; Prentice
393 Hall: Upper Saddle River, NJ, USA, 2009; ISBN 0-13-207148-7
- 394 19. Nichols JA, Chan HWH, Baker MAB. Machine learning: applications of artificial
395 intelligence to imaging and diagnosis. *Biopsy Rev*. 2019;11(1):111-118.
- 396 20. Nitta S, Tsutsumi M, Sakka S, Endo T, Hashimoto K, Hasegawa M, et al. Machine
397 learning methods can more efficiently predict prostate cancer compared with
398 prostate-specific antigen density and prostate-specific antigen velocity. *Prostat*
399 *Intl*. 2019;7(3):114-118.
- 400 21. Djavan B, Remzi M, Zlotta A, Seitz C, Snow P, Marberger M. Novel artificial neural
401 network for early detection of prostate cancer. *J Clin Oncol*. 2002;20:921–929.
402 doi:10.1200/JCO.2002.20.4.921
- 403 22. Aldoj N, Lukas S, Dewey M, Penzkofer T. Semi-Automatic Classification of Prostate
404 Cancer on Multi-Parametric MR Imaging Using a Multi-Channel 3D Convolutional
405 Neural Network. *Eur Radiol*. 2020, 30, 1243–1253.

- 406 23. Wang J, Wu CJ, Bao ML, Zhang J, Wang XN, Zhang YD. Machine learning-based
407 analysis of MR radiomics can help to improve the diagnostic performance of PI-
408 RADS v2 in clinically relevant prostate cancer. *Eur Radiol.* 2017;27:4082–4090.
- 409 24. Ronco AL, Fernandez R. Improving ultrasonographic diagnosis of prostate cancer
410 with neural networks. *Ultrasound in Med and Biol.* 1999;25(5):729-733.
- 411 25. Loch T, Leuschner I, Genberg C, Weichert-Jacobsen K, Kuppers F, Yfantis E, et
412 al. Artificial neural network analysis of prostatic transrectal ultrasound. *The*
413 *prostate.* 1999;39(1):198-204.
- 414 26. Lee JH, Hwang SI, Han SM, Park SH, Kim SH, Cho JY, Seong CG. Imaged-based
415 clinical decision support for transrectal ultrasound in the diagnosis of prostate
416 cancer: comparison of multiple logistic regression, artificial neural network, and
417 support vector machine. *Eur Radiol.* 2010;20(1):1476-1484.
- 418 27. Lee HJ, Kim KG, Lee SE, Byun SS, Hwang SI, Jung SI, et al. Role of transrectal
419 ultrasonography in the prediction of prostate cancer: artificial neural network
420 analysis. *J Ultrasound Med.* 2006;25(7):815-21.
- 421 28. Azizi S, Bayat S, Yan P, Tahmasebi A, Kwak JT, Xu S, et al. Deep recurrent neural
422 networks for prostate cancer detection: Analysis of temporal enhanced
423 ultrasound. *IEEE Transactions on Medical Imaging.* 2018;37(12):2695-2703.
- 424 29. Wildeboer RR, Mannaerts CK, Sloun RJG, Budaus L, Tilki D, Wijkstra H, et al.
425 Automated multiparametric localisation of prostate cancer based on B-mode,
426 shear-wave elastography, and contrast-enhanced ultrasound radiomics. *Eur*
427 *Radiol.* 2020;30(1):806-815.

- 428 30. Ghose S, Oliver A, Marti R, Llado X, Freixenet J, et al. A survey of prostate
429 segmentation methodologies in ultrasound, magnetic resonance and computed
430 tomography images. *Comput Methods Programs Biomed.* 2012;108(1):262-87.
- 431 31. Drost FH, Osses DF, Nieboer D, Steyerberg EW, Bangma CH, Roobol MJ, et al.
432 Prostate MRI, with or without MRI-targeted biopsy, and systematic biopsy for
433 detecting prostate cancer. *Cochrane Database Syst Rev.* 2019;4: CD012663.
- 434 32. Sun Y, Reynolds HM, Parameswaran B, Wraith D, Finnegan M, Williams S, et al.
435 Multiparametric MRI and radiomics in prostate cancer: a review. *Australian Phys
436 Eng Sci Med.* 2019;42:3–25.
- 437 33. van der Leest M, Cornel E, Israël B, Hendriks R, Padhani AR, Hoogenboom M, et
438 al. Head-to-head comparison of transrectal ultrasound-guided prostate biopsy
439 versus multiparametric prostate resonance imaging with subsequent magnetic
440 resonance-guided biopsy in biopsy-naïve men with elevated prostate-specific
441 antigen: a large prospective multicenter clinical study. *Eur Urol.* 2019;75:570–578.
- 442 34. Winoker JS, Pinto PA, Rastinehad AR. MRI to guide biopsies or avoid biopsies?
443 *Curr Opin Urol.* 2018;28:522–528.
- 444 35. Smeenge M, Barentsz J, Cosgrove D, de la Rosette J, de Reijke T, Eggener S, et
445 al. Role of transrectal ultrasonography (TRUS) in focal therapy of prostate cancer:
446 report from a Consensus Panel. *BJU Int.* 2012;110: 942-8.
- 447 36. Taneja SS. Imaging in the diagnosis and management of prostate cancer. *Rev
448 Urol.* 2004;6(3):101-113.
- 449 37. Correas JM, Halpern EJ, Barr RG, Ghai S, Walz J, Bodard S, et al. Advanced
450 ultrasound in the diagnosis of prostate cancer. *World J Urol.* 2020.

- 451 38. Claudon M, Cosgrove D, Albrecht T. Guidelines and good clinical practice
452 recommendations for contract enhanced ultrasound. *Ultraschall in der Medizin-*
453 *European Journal of Ultrasound*. 2008;29(1):28-44.
- 454 39. Kuenen MPJ, Mischi M, Wijkstra H. Contrast-ultrasound diffusion imaging for
455 localisation of prostate cancer. *IEEE Transactions on Medical Imaging*.
456 2011;30(8):1493.
- 457 40. Lughezzani G, Saita A, Lazzeri M, Paciotti M, Maffei D, Lista G, et al. Comparison
458 of the diagnostic accuracy of micro-ultrasound and magnetic resonance
459 imaging/ultrasound fusion targeted biopsies for the diagnosis of clinically
460 significant prostate cancer. *Eur Urol Oncol*. 2019;2:329–332.
- 461 41. Loch T. Computerized transrectal ultrasound (C-TRUS) of the prostate: detection
462 of cancer in patients with multiple negative systematic random biopsies. *World J*
463 *Urol*. 2007;25:375–380.
- 464 42. Zhang M, Tang J, Luo Y, Wang Y, Wu M, Memmott B, et al. Diagnostif
465 performance of multiparametric transrectal ultrasound in localized prostate
466 cancer: A comparative study with magnetic resonance imaging. *J Ultrasound in*
467 *Med*. 2018;38(7):1823-1830.
- 468 43. Brattain LJ, Telfer BA, Dhyani M, Grajo JR, Samir AE. Machine learning for
469 medical ultrasound: status, method, and future opportunities. *Abdom Radiol*.
470 2018;43(4):786-799.
- 471 44. Noorbakhsh-Sabet N, Zand R, Zhang Y, Abedi V. Artificial Intelligence Transforms
472 the Future Healthcare. *Am J Med*. 2019;132(7):795-801.

- 473 45. Alaloul WS, Qureshi AH. Data processing using artificial neural networks. *Intech*
474 *Open*. 2020.
- 475 46. Carter HB. Differentiation of lethal and non-lethal prostate cancer: PSA and PSA
476 isoforms and kinetics. *Asian J Androl*. 2012;14(3):355-360.
- 477 47. Tătaru OS, Vartolomei MD, Rassweiler JJ, Virgil O, Lucarelli G, Porpiglia F, et al.
478 Artificial intelligence and machine learning in prostate cancer patient
479 management—current trends and future perspectives. *Diagnostics*.
480 2021;11(2):1–20.
- 481 48. Goldenberg SL, Nir G, Salcudean SE. A new era: artificial intelligence and
482 machine learning in prostate cancer. *Nat Rev Urol*. 2019;16(7):391–403.
- 483 49. Mottet N, Conford P, van den Bergh RCN, Briers E, Santis MD, Gillessen S, et al.
484 EAU-EANM-ESTRO-ESUR-ISUP-SIOG Guidelines on Prostate Cancer.
485 EAU;2021.
- 486 50. Rooij M, Hamoen EHJ, Futterer JJ, Barentsz JO, Roovers MM. Accuracy of
487 magnetic resonance imaging for local staging of prostate cancer: a diagnostic
488 meta-analysis. *AJR Am J Roentgenol*. 2016;70(2):233-45.

Figure 1. Prisma Flow Diagram

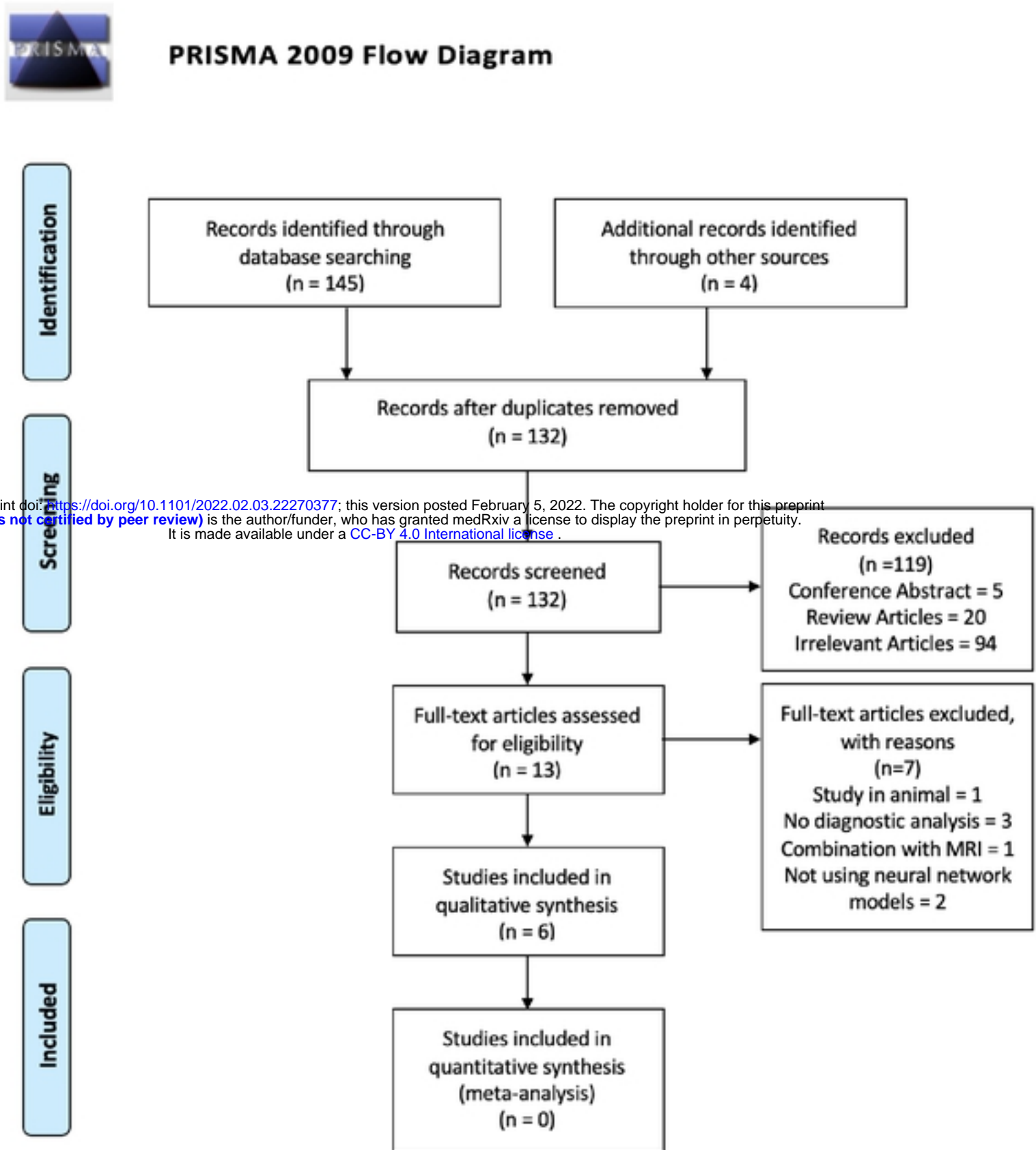


Figure 1

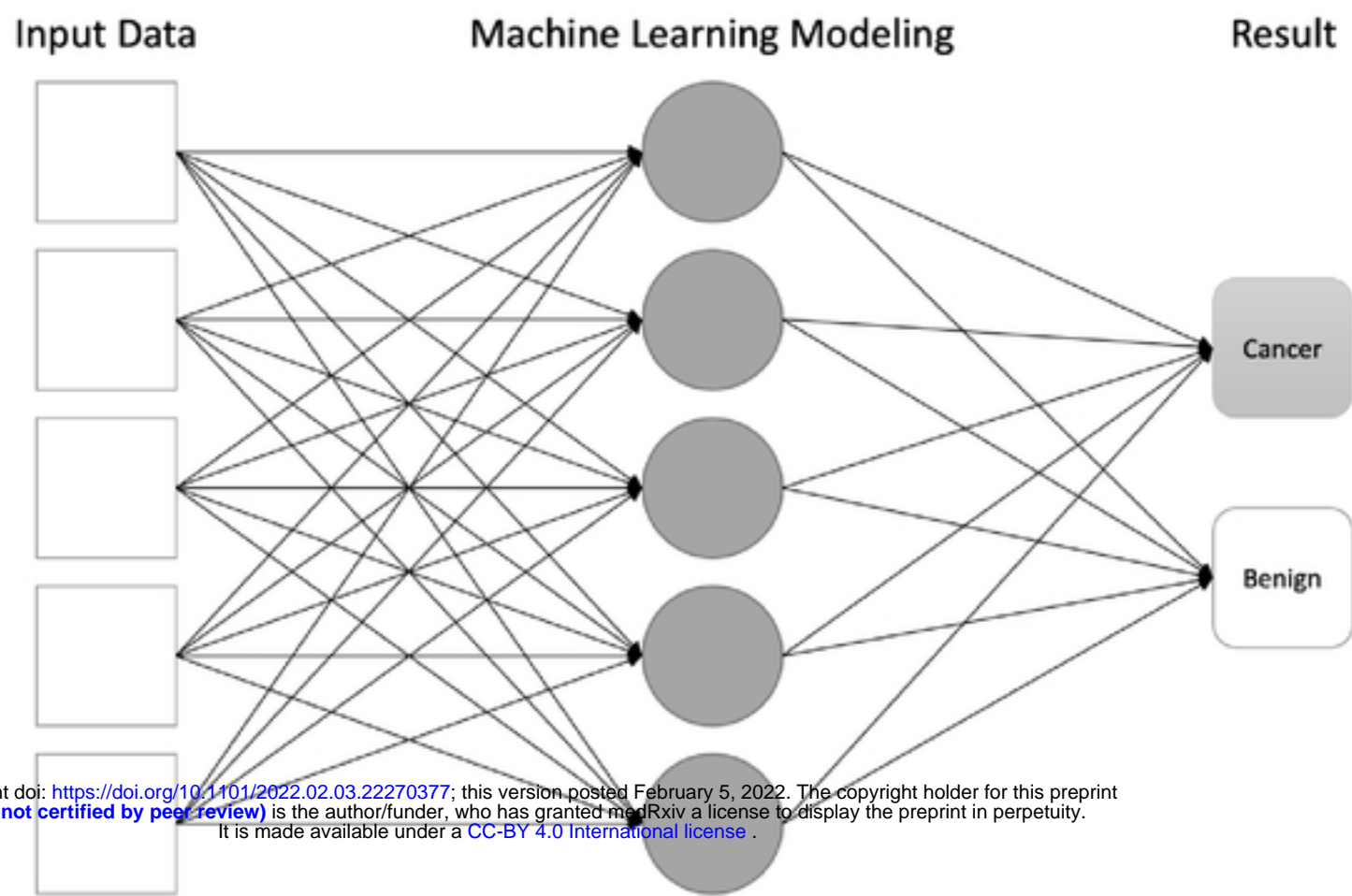
Figure 2. Risk of Bias Assessment using QUADAS-2 Tool

	<u>Risk of Bias</u>				<u>Applicability Concerns</u>		
	Patient Selection	Index Test	Reference Standard	Flow and Timing	Patient Selection	Index Test	Reference Standard
Azizi 2018	+	?	+	+	+	+	+
Lee 2006	+	?	+	+	+	?	+
Lee 2009	-	-	+	?	-	?	+
Loch 1999	?	-	+	+	?	-	+
Ronco 1999	+	-	+	+	+	-	+
Wilcox 2020	+	?	+	+	+	?	+

medRxiv preprint doi: <https://doi.org/10.1101/2022.02.03.22270377>; this version posted February 5, 2022. The copyright holder for this preprint (which was not certified by peer review) is the author/funder, who has granted medRxiv a license to display the preprint in perpetuity. It is made available under a [CC-BY 4.0 International license](https://creativecommons.org/licenses/by/4.0/).

- High
 ? Unclear
 + Low

Figure 3. Schematic Machine Learning Model in Prostate Cancer Diagnosis



medRxiv preprint doi: <https://doi.org/10.1101/2022.02.03.22270377>; this version posted February 5, 2022. The copyright holder for this preprint (which was not certified by peer review) is the author/funder, who has granted medRxiv a license to display the preprint in perpetuity. It is made available under a [CC-BY 4.0 International license](#).