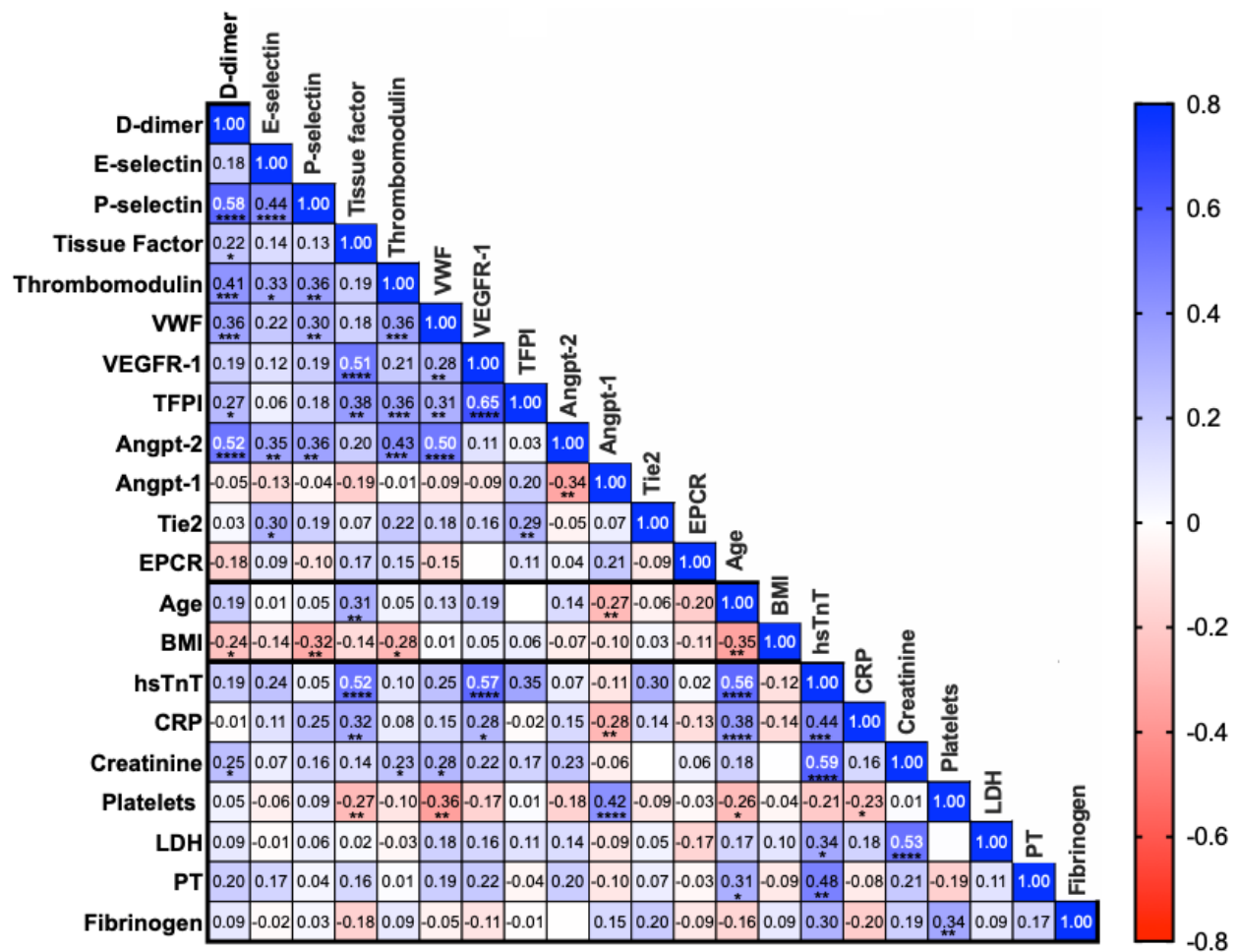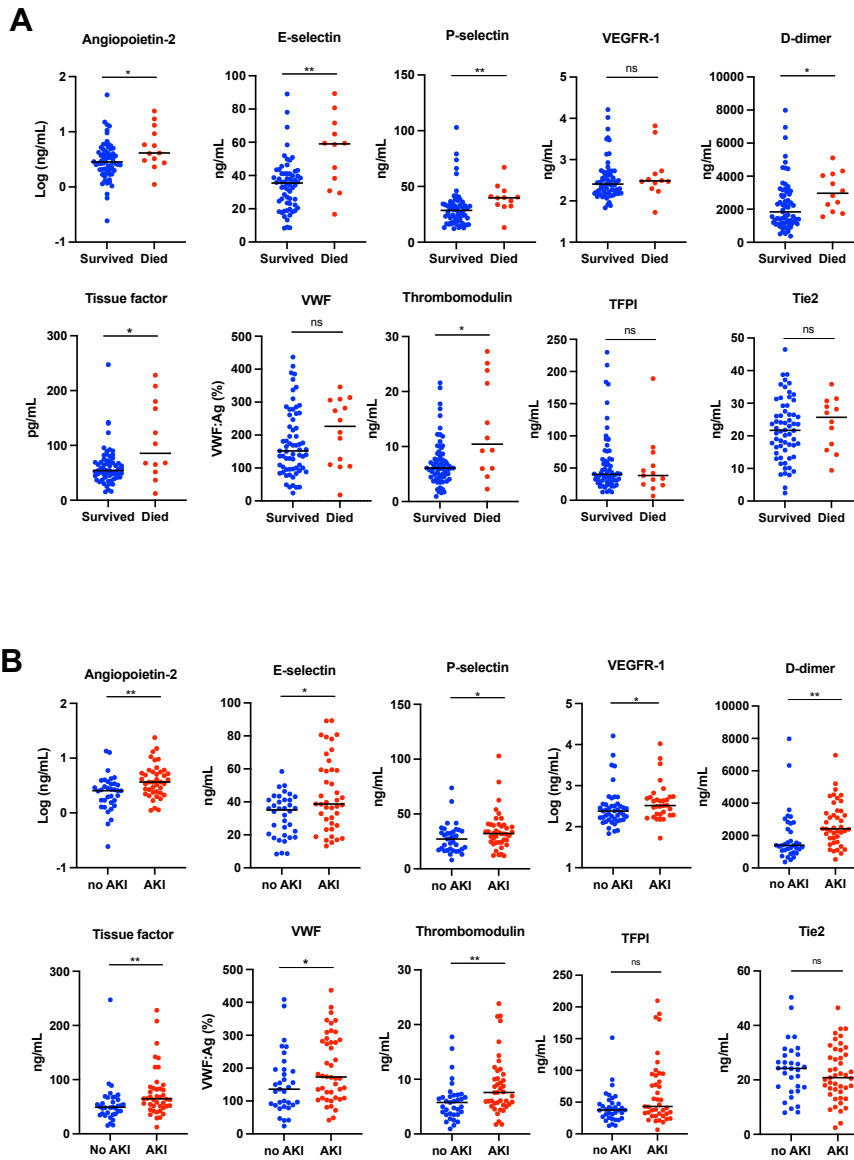


Supplemental Figure 1. Correlation matrix of measured analytes among hospitalized COVID-19 patients. Spearman rank correlations were performed for markers of endothelial and thrombotic activation, demographics, and clinical metrics. Positive correlations are indicated in blue and negative correlations indicated in red. Numbers within the square indicate r values. Angpt, angiotensin; BMI, body mass index; CRP, C-reactive protein; EPCR, endothelial protein C receptor; hsTnT, high-sensitivity troponin, LDH, lactate dehydrogenase; PT, prothrombin time; TFPI, tissue factor pathway inhibitor; VEGFR1, vascular endothelial growth factor receptor 1; VWF, Von Willebrand Factor, * $P < 0.05$, ** $P < 0.01$, *** $P < 0.001$, **** $P < 0.0001$.



Supplemental Figure 2. Endothelial and thrombotic activation and clinical endpoints among patients hospitalized with COVID-19. Plasma samples obtained from patients hospitalized with COVID-19 and values of measured proteins are shown for patients according to death (**A**) or development of acute kidney injury (**B**). Acute kidney injury (AKI) was defined as a rise in serum creatinine of ≥ 0.3 mg/dL or ≥ 1.5 times baseline. TFPI, tissue factor pathway inhibitor; VEGFR-1, vascular endothelial growth factor receptor 1; VWF, Von Willebrand Factor. Bar indicates median value. Significance was determined by a 2-tailed Mann-Whitney test. * $P < 0.05$, ** $P < 0.01$,

Supplemental appendix

COVID-19 Autopsy specimens

Three characteristic findings were apparent in the lung specimens isolated from COVID-19 autopsies—1) alveolar spaces with pulmonary edema and fresh hemorrhage, without significant interstitial inflammation 2) chronic interstitial inflammation and edema, with type II pneumocyte hyperplasia and multinucleation, and 3) diffuse alveolar damage with organizing fibrin in alveolar spaces and associated microvascular thrombi³²

Patient 1 (10 day admission) presented with low-grade fever and malaise, and initially a negative chest x-ray without pulmonary symptoms. Labs showed lymphopenia and elevated inflammatory markers. He had profound hypotension and progressive decline in strength and mental status. He was transitioned to comfort measures and died on day 10. Autopsy findings showed lungs with patchy pulmonary edema and acute alveolar hemorrhage.

Patient 2 (16 day admission) presented with fever, hypoxia, and respiratory distress requiring oxygen supplementation and metabolic acidosis. After response to fluid resuscitation, she tested positive for COVID-19 by swab and was discharged to in-patient hospice where her respiratory status declined until death. Autopsy findings matched the clinical picture of lung injury. The lungs showed diffuse alveolar damage and microvascular thrombosis. In less involved areas, sections showed a prominent septal lymphocytic infiltrate and type-II pneumocyte hyperplasia with multinucleated forms.

Patient 3 (40 day admission) presented with 10 days of fever, chills, and dry cough as well as nausea/vomiting and diarrhea, followed by worsening dyspnea. At presentation she had bilateral lung field infiltrates on x-ray, lymphopenia and rapidly progressing hypoxia with positive COVID-19 test. She was intubated and required pressor support to treat hypotension. She required mechanical ventilation and hemodialysis for acute kidney injury. At autopsy, the lungs with prominent interstitial lymphocytic infiltrate and abundant alveolar macrophages likely related to recent pneumonias.

Case 4 (15 day admission) presented with 2 days of shortness of breath, cough and fatigue. On arrival she was hypoxemic, and chest x-ray demonstrated multifocal pneumonia and COVID testing was positive. She was intubated on day 2 with persistent hypoxemia and she developed acute respiratory distress syndrome (ARDS) and persistent shock requiring pressor support and died. At autopsy, her lungs showed patchy pulmonary edema and acute alveolar hemorrhage with prominent interstitial lymphocytic pneumonia with type-II pneumocyte hyperplasia and abundant alveolar macrophages and fibrin deposition in the microvasculature.

Case 5 (31 day admission) presented with 4 days of fever and malaise and was admitted for COVID-19-positive pneumonia requiring intubation. He required vasopressor support throughout his admission. He developed renal failure requiring hemodialysis. At autopsy, his lungs showed diffuse alveolar damage with associated microvascular thrombosis and organizing alveolar hemorrhage which correspond to diffuse radiographic infiltrates seen on daily chest x-rays.

Supplementary Appendix Table 1. Clinical characteristics and laboratory values for patients included in the cohort. Highest value during hospitalization is listed. (HTN – hypertension, ESRD – end stage renal disease, PE – pulmonary emboli, DM2 – diabetes mellitus type 2, TIA – transient ischemic attack, CKD – chronic kidney disease, AFib – atrial fibrillation).

	Age range / gender	Hospital admission length	Intubated	Comorbidities	D- Dimer	cTropnT
1	85-90, M	10	no	ESRD on dialysis, HTN	1174	0.17
2	80-85, F	16	no	HTN, DM2, TIA	>21600	0.08
3	55-60, F	40	yes	HTN, DM2, obesity, mild CKD	>21600	0.25
4	75-80, F	15	no	ESRD on dialysis, HTN	>21600	0.23
5	70-75, M	31	yes	HTN, AFib	20937	1.35

Supplemental acknowledgments

MGH COVID-19 Collection & Processing Team Participants

Collection Team: Kendall Lavin-Parsons¹, Blair Parry¹, Brendan Lilley¹, Carl Lodenstein¹, Brenna McKaig¹, Nicole Charland¹, Hargun Khanna¹, Justin Margolin¹, Edward DeMers⁶, Kelly Judge⁶, Bruce D. Walker⁶, Peggy Lai⁶, Musie S. Ghebremichael⁶

Processing Team: Anna Gonye², Irena Gushterova², Tom Lasalle², Nihaarika Sharma², Brian C. Russo³, Maricarmen Rojas-Lopez³, Moshe Sade-Feldman⁴, Kasidet Manakongtreecheep⁴, Jessica Tantivit⁴, Molly Fisher Thomas⁴

Massachusetts Consortium on Pathogen Readiness: Betelihem A. Abayneh⁵, Patrick Allen⁵, Diane Antille⁵, Katrina Armstrong⁵, Siobhan Boyce⁵, Joan Braley⁵, Karen Branch⁵, Katherine Broderick⁵, Julia Carney⁵, Andrew Chan⁵, Susan Davidson⁵, Michael Dougan⁵, David Drew⁵, Ashley Elliman⁵, Keith Flaherty⁵, Jeanne Flannery⁵, Pamela Forde⁵, Elise Gettings⁵, Amanda Griffin⁵, Sheila Grimmel⁵, Kathleen Grinke⁵, Kathryn Hall⁵, Meg Healy⁵, Deborah Henault⁵, Grace Holland⁵, Chantal Kayitesi⁵, Vlasta LaValle⁵, Yuting Lu⁵, Sarah Luthern⁵, Jordan Marchewka (Schneider)⁵, Brittani Martino⁵, Roseann McNamara⁵, Christian Nambu⁵, Susan Nelson⁵, Marjorie Noone⁵, Christine Ommerborn⁵, Lois Chris Pacheco⁵, Nicole Phan⁵, Falisha A. Porto⁵, Edward Ryan⁵, Kathleen Selleck⁵, Sue Slaughenhaupt⁵, Kimberly Smith Sheppard⁵, Elizabeth Suschana⁵, Vivine Wilson⁵, Galit Alter⁶, Alejandro Balazs⁶, Julia Bals⁶, Max Barbash⁶, Yannic Bartsch⁶, Julie Boucau⁶, Josh Chevalier⁶, Fatema Chowdhury⁶, Kevin Einkauf⁶, Jon Fallon⁶, Liz Fedirko⁶, Kelsey Finn⁶, Pilar Garcia-Broncano⁶, Ciputra Hartana⁶, Chenyang Jiang⁶, Paulina Kaplonek⁶, Marshall Karpell⁶, Evan C. Lam⁶, Kristina Lefteri⁶, Xiaodong Lian⁶, Mathias Lichtenfeld⁶, Daniel Lingwood⁶, Hang Liu⁶, Jinqing Liu⁶, Natasha Ly⁶, Ashlin Michell⁶, Ilan Millstrom⁶, Noah Miranda⁶, Claire O'Callaghan⁶, Matthew Osborn⁶, Shiv Pillai⁶, Yelizaveta Rassadkina⁶, Alexandra Reissis⁶, Francis Ruzicka⁶, Kyra Seiger⁶, Libera Sessa⁶, Christianne Sharr⁶, Sally Shin⁶, Nishant Singh⁶, Weiwei Sun⁶, Xiaoming Sun⁶, Hannah Ticheli⁶, Alicja Trocha-Piechocka⁶, Daniel Worrall⁶, Alex Zhu⁶, George Daley⁷, David Golan⁷, Howard Heller⁷, Arlene Sharpe⁷, Nikolaus sJilg⁸, Alex Rosenthal⁸, Colline Wong⁸

¹Department of Emergency Medicine, Massachusetts General Hospital, Boston, MA, USA.

²Massachusetts General Hospital Cancer Center, Boston, MA, USA.

³Division of Infectious Diseases, Department of Medicine, Massachusetts General Hospital, Boston, MA, USA.

⁴Massachusetts General Hospital Center for Immunology and Inflammatory Diseases, Boston, MA, USA.

⁵Massachusetts General Hospital, Boston, MA, USA.

⁶Ragon Institute of MGH, MIT and Harvard, Cambridge, MA, USA.

⁷Harvard Medical School, Boston, MA, USA.

⁸Brigham and Women's Hospital, Boston, MA, USA.