

# 1 **Anatomic and Functional Outcomes of Lamellar Macular** 2 **Hole Surgery: Predictive Factors and Associated** 3 **Complications**

4 Yosra Er-reguyeg<sup>1</sup>, Sihame Doukkali<sup>1</sup>, Mélanie Hébert<sup>2</sup>, Eunice Linh You<sup>2</sup>, Serge Bourgault<sup>2</sup>,  
5 Mathieu Caissie<sup>2</sup>, Éric Tourville<sup>2</sup>, Ali Dirani<sup>2</sup>

6

7 <sup>1</sup> Faculty of Medicine, Laval University, Quebec City, Quebec, Canada

8 <sup>2</sup> Department of Ophthalmology, Hospital Saint-Sacrement, Laval University, Quebec City,  
9 Quebec, Canada

10

## 11 **ABSTRACT**

12 **Purpose:** To analyze the anatomic and functional outcomes of lamellar macular hole (LMH)  
13 surgery.

14 **Patients and methods:** This is a retrospective interventional cohort study of ninety patients with  
15 unilateral idiopathic LMH who underwent pars plana vitrectomy (PPV) with membrane peeling for  
16 LMH between 2014 and 2021. We evaluated the anatomic and functional success of PPV with  
17 membrane peeling for treating LMH, compared surgical outcomes between the two LMH subtypes  
18 (“true” LMH and epiretinal foveoschisis (ERMF)), and identified predictive factors for anatomical  
19 and functional success. Primary outcomes included final postoperative best-corrected visual acuity  
20 (BCVA) and LMH closure. Variables associated with final BCVA were assessed using a multiple  
21 linear regression model.

22 **Results:** 51 subjects presented with ERMF, while 39 presented with “true” LMH. LMH closure  
23 occurred in 80 cases. “True” LMH cases had a lower rate of closure (“true” LMH closure rate:  
24 76.9%, vs. ERMF closure rate: 94.2%,  $p=0.005$ ) and were more at risk of developing a  
25 postoperative macular hole ( $p=0.008$ ). A significant difference was observed between median [Q1,  
26 Q3] preoperative BCVA (0.42 [0.26, 0.61]) and final BCVA (0.31 [0.14, 0.48],  $p=0.024$ ). “True” LMH  
27 without epiretinal proliferation ( $\beta=0.194$ ,  $p=0.040$ ) was associated with worse final BCVA in  
28 multivariate analysis.

29 **Conclusion:** Results support the effectiveness of PPV as a treatment for LMH. “True” LMHs had  
30 worse anatomic outcomes than ERMFs.

## 31 Introduction

32 Lamellar macular hole (LMH) is characterized as a partial-thickness defect in the inner  
33 layers of the fovea. Since J.D. Gass first documented the disease in 1975, the diagnostic criteria  
34 for LMH changed considerably.<sup>1</sup> Established as the gold standard in LMH assessment, the  
35 emergence of spectral domain optical coherence tomography (SD-OCT) led to new diagnostic  
36 criteria including an irregular foveal contour, a break in the inner fovea, dehiscence of the inner  
37 foveal retina from the outer retina and absence of a full-thickness foveal defect with preservation  
38 of foveal photoreceptors.<sup>2</sup>

39 Govetto et al. later divided LMHs into “tractional” and “degenerative” subtypes.<sup>3</sup> Recently,  
40 Hubschman et al. separated lesions previously called LMH into two entities: epiretinal membrane  
41 foveoschisis (ERMF) and “true” LMH.<sup>4</sup> ERMF, which is comparable to what was previously  
42 considered as tractional LMH, occurs in the presence of a contractile epiretinal membrane (ERM)  
43 and a foveoschisis at the level of the Henle's fiber layer (HFL), two mandatory diagnosis criteria.  
44 Three optional criteria were also suggested: the presence of microcystoid spaces in the inner  
45 nuclear layer (INL), retinal thickening, and retinal wrinkling.

46 In contrast to ERMF, “true” LMH, which is comparable to what was previously considered  
47 degenerative LMH, requires the presence of an irregular foveal contour, a foveal cavity with  
48 undermined edges, and at least one other sign evoking loss of foveal tissue. Associated  
49 pathological changes can include epiretinal proliferation (ERP), foveal bump, and ellipsoid zone  
50 (EZ) disruption.

51 It is unclear whether ERMF and “true” LMH are two distinct entities, as the latest findings  
52 suggest that both originate from a tractional event and that the ERP often found in “true” LMH may  
53 be a repair process derived from a tractional impairment to the foveolar Müller cells.<sup>5-9</sup> Moreover,  
54 Su et al.'s findings indicate that in LMHs displaying ERP, epiretinal traction is commonly  
55 observed.<sup>10</sup>

56 Disagreement remains regarding the surgical treatment of LMH involving integral membrane  
57 peeling. While surgery may prevent visual acuity (VA) loss and further deterioration of the foveal

58 profile, some studies report outcomes that vary based on the morphological features of the  
59 LMH.<sup>11,12</sup> The fovea-sparing and flap embedding techniques are new methods recently developed  
60 to address complications commonly associated with standard integral membrane peeling, showing  
61 promising postoperative outcomes. However, standard peeling remains widely used in LMH  
62 surgery.<sup>13,14</sup> Thus, we aimed to assess the anatomic and functional outcomes of LMH surgery,  
63 assess which LMH-related factors best predict final VA, and document postoperative  
64 complications.

## 65 **Material and methods**

### 66 ***Study Design and Population***

67 This retrospective interventional study includes medical records of patients with LMH who  
68 underwent PPV between 2014 and 2021 at the Centre Hospitalier Universitaire (CHU) de Québec  
69 – Université Laval. Approval from the Ethics Committee was obtained, and the study adhered to  
70 the tenets of the Declaration of Helsinki. We excluded eyes with macular pseudohole (MPH), Full  
71 thickness macular hole (MH), history of ocular trauma leading to LMH formation, wet age-related  
72 macular degeneration (AMD), active proliferative diabetic retinopathy (PDR), advanced glaucoma,  
73 high myopia (HM) (>4 diopters), history of retinal detachment (RD), and active uveitis. Patients with  
74 less than one month of postoperative follow-up and patients with missing preoperative or  
75 postoperative best-corrected VA (BCVA) and optical coherence tomography (OCT) data were also  
76 excluded.

### 77 ***LMH SD-OCT Diagnosis***

78 We defined and diagnosed LMH using the OCT diagnostic criteria of Witkin et al. as these  
79 were adopted by the International Vitreomacular Traction Study Group.<sup>15</sup> Anatomic characteristics  
80 were collected using SD-OCT (Cirrus HD-OCT; Carl Zeiss Meditec, Inc). Patients diagnosed with  
81 LMH were further classified into ERMFs and “true” LMHs according to Hubschman et al.’s  
82 consensus.<sup>4</sup> We analyzed the following parameters using Cirrus’ OCT 512×128 macular cube scan:

83 preoperative central foveal thickness (CFT), average foveal thickness (AFT), minimal foveal  
84 thickness (MFT), base diameter and apex diameter of the hole, presence of ERM and ERP, EZ  
85 disruption, external limiting membrane (ELM) disruption, presence of intraretinal cysts (IRCs),  
86 postoperative MH formation (stages 1, 2, 3 and 4), and foveal profile evolution. As previously  
87 described, LMH closure was defined as a reconstituted foveal contour with no retinal splitting.<sup>16</sup>  
88 The preoperative CFT, AFT and MFT were measured automatically by Zeiss' OCT software. Base  
89 and apex diameters were measured manually using Zeiss' OCT software caliper. Since lamellar  
90 macular defects often exhibit asymmetry and irregularity, measurements of base diameter were  
91 made to the largest horizontal extent of the intraretinal split, as performed in similar studies.<sup>17,18</sup>

## 92 ***Surgical procedure***

93 All patients underwent 25-gauge PPV by one of five fellowship-trained vitreoretinal  
94 surgeons. ERM peeling with or without internal membrane (ILM) peeling was performed.  
95 Phacoemulsification was also combined to the primary PPV in some cases. A conventional peeling  
96 technique was performed on all patients, consisting of removing the epiretinal membrane or  
97 epiretinal proliferation if present from the surface of the retina using staining agents. Indocyanine  
98 green or methylene blue were used as staining agents based on surgeons' preference. ILM peeling  
99 and restaining were done following the removal of ERM or ERP. In exceptional cases where the  
100 ILM could not be visualized after extensive ERM peeling, the ILM was not removed. Vitrectomy  
101 was completed with a 360° inspection of the peripheral retina using scleral depression, followed by  
102 complete fluid-air exchange with or without gas tamponade at the surgeon's discretion. The gases  
103 used for tamponade were either air, sulfur hexafluoride (SF<sub>6</sub>), or perfluoropropane (C<sub>3</sub>F<sub>8</sub>) for larger  
104 LMHs, chosen at the discretion of the operating surgeon. Sclerotomies were sutured if they were  
105 not self-sealing and leakage occurred. Patients who received gas tamponade (SF<sub>6</sub> and C<sub>3</sub>F<sub>8</sub>) were  
106 instructed to maintain prone positioning following surgically.

## 107 ***Statistical analysis***

108 We conducted the statistical analysis using SPSS Statistics Version 26 (IBM, Armonk, NY,  
109 USA). The normality of continuous variables was tested with Q-Q plots and Shapiro-Wilk tests.  
110 Means and standard deviations were used to present normally distributed continuous variables,  
111 medians and quartiles [first quartile (Q1), third quartile (Q3)] for non-normally distributed continuous  
112 variables, and percentages for categorical variables. We compared preoperative characteristics  
113 and outcomes between patients using independent Student's t-tests for normally distributed  
114 continuous variables, Mann-Whitney U tests for non-normally distributed continuous variables,  
115 Pearson chi-square tests for categorical variables, and Wilcoxon signed-rank tests for paired  
116 comparisons of preoperative and postoperative continuous variables.

117 To analyze which variables were most predictive of final postoperative BCVA, we built a  
118 multiple linear regression model using backwards elimination with an F-to-remove at 0.2. Variables  
119 that we considered for inclusion were age, sex, idiopathic LMH, preoperative BCVA, use of phaco-  
120 vitrectomy, type of peel (e.g., ERM peel, ILM peel, and/or ERP peel), tamponade agent, staining,  
121 LMH closure, preoperative central foveal thickness, lesion type (i.e., ERMF or "true" LMH), LMH  
122 base and apex diameters, preoperative OCT characteristics if they were not significantly collinear  
123 with lesion type (i.e., ERP, EZ disruption, ELM disruption, IRC, vitreomacular traction (VMT),  
124 partial/complete posterior vitreous detachment (PVD), cystoid macular edema (CME), and  
125 development of postoperative MH). Unstandardized coefficients with 95% confidence intervals (CI)  
126 and standardized coefficients were produced for all variables included in the final model. Baseline  
127 demographics including preoperative BCVA, age, and sex were retained in the final model to adjust  
128 for these variables. The type of lesion (ERMF vs "true" LMH) and LMH closure were included to  
129 assess the impact of these anatomical characteristics on final BCVA. Additionally, we favored the  
130 use of phaco-vitrectomy over other lens status variables and preoperative central foveal thickness  
131 over other preoperative thickness parameters (i.e., minimal foveal thickness, average foveal  
132 thickness) due to their stronger association with final BCVA and to avoid collinearity in the  
133 regression model. Statistical significance was set at a p-value of <0.05.

## 134 **Results**

### 135 ***Characteristics of the Studied Population***

136 This study included 90 patients. Out of them, 57 (63.3%) were women. The mean age at  
137 surgery was  $71 \pm 8$  years. Of these, 51 (56.7%) subjects presented with ERMF, while 39 (43.3%)  
138 presented with “true” LMH. Comparisons of baseline characteristics between both types of lesions  
139 are presented in **Table 1**. Out of the 39 patients presenting “true” LMH, 28 (71.8%) were subject to  
140 an ERP and ILM peeling, 6 (15.4%) had an ERP peeling, and 5 (12.8%) had an ILM peeling. The  
141 subset of “true” LMH patients who underwent solely an ILM peeling did not have ERP at  
142 presentation. Out of the subjects presenting ERMF, 46 (90.2%) had an ERM and an ILM peeling,  
143 while 5 (9.8%) had only an ERM peeling. Following the ERM or ERP peeling, the decision to peel  
144 ILM was at the discretion of the surgeon. In the entire cohort, 58 (64.4%) subjects received SF<sub>6</sub>, 30  
145 (33.3%) received air, and 2 (2.2%) received C<sub>3</sub>F<sub>8</sub>. Concomitant phacoemulsification and intraocular  
146 lens (IOL) implantation were performed in 24 (26.7%) subjects. The median [Q1, Q3] follow-up  
147 period was 14 [6, 29] months.

### 148 ***Anatomic Outcomes***

149 Lamellar macular hole closure was achieved in 80 (88.9%) cases. **Figure 1** depicts the  
150 preoperative and postoperative OCT images of a patient who achieved complete LMH closure,  
151 compared to a patient who did not. The characteristics of patients who did or did not achieve LMH  
152 closure are summarized in **Table 2**. In addition to restoring foveal profile, surgery significantly  
153 decreased the number of patients presenting IRCs, which went from 60 (66.7%) preoperatively to  
154 32 (35.6%) postoperatively ( $p < 0.001$ ). The number of patients with EZ disruption who achieved  
155 restoration of EZ integrity postoperatively was 6 (representing a decrease of 20.7%) ( $p = 0.238$ ),  
156 while the number of patients presenting CME decreased from 6 (6.6%) to 5 (5.6%) postoperatively  
157 ( $p = 1.000$ ).

158 Of the 10 patients who did not achieve LMH closure, 7 (70.0%) of them were men  
159 ( $p=0.020$ ). “True” LMH was associated with a lower rate of LMH closure than ERMF ( $p=0.002$ ).  
160 Subjects who did not achieve LMH closure had significantly worse preoperative BCVA (LMH  
161 closure group: 0.40 [0.26, 0.56], Snellen 20/50 vs. LMH non-closure group: 0.66 [0.47, 0.80],  
162 Snellen 20/100;  $p=0.009$ ). No significant association was found between LMH closure and the type  
163 of tamponade agents. Patients who achieved LMH closure had higher CFT values, although not  
164 reaching statistical significance (LMH closure group: 354 [299, 413], LMH non-closure group: 295  
165 [271, 360],  $p=0.065$ ). The preoperative apex diameter was smaller in patients who achieved LMH  
166 closure (421 [314, 608]  $\mu\text{m}$ ) than in the ones who did not (632 [385, 827]  $\mu\text{m}$ ,  $p=0.052$ ). Age,  
167 preoperative base diameter, preoperative presence of ELM disruption, EZ disruption, vitreomacular  
168 traction, intraretinal retinal cysts, and PVD were not significantly associated with LMH closure.

169 When considering the “true” LMH subgroup alone, the proportion of patients with ERP that  
170 did not achieve LMH closure ( $n=9$ , 100% of LMH non-closure cases) was significantly higher than  
171 the proportion of patients with ERP that achieved LMH closure ( $n=18$ , 60% of LMH closure cases),  
172 highlighting a negative association between the presence of ERP and LMH closure. There was no  
173 other preoperative anatomic characteristic associated with LMH closure for “true” LMH cases.

## 174 ***Functional Outcomes***

175 Surgery significantly improved BCVA from a preoperative median [Q1, Q3] BCVA of (0.42  
176 [0.26, 0.61]) (Snellen: 20/50) to a final postoperative BCVA of (0.31 [0.14, 0.48]) (Snellen: 20/40)  
177 ( $p=0.024$ ). **Table 3** summarizes the factors associated with final BCVA when adjusted for  
178 preoperative BCVA in a multiple linear regression model. Variables not included in the model were  
179 rejected by the backward elimination method.

180 Multiple linear regression analysis indicated that, placed in order of magnitude of impact,  
181 masculine sex ( $\beta=0.358$ ,  $p<0.001$ ) and “true” LMH with no ERP ( $\beta=0.194$ ,  $p=0.040$ ) were significant  
182 predictors negatively affecting final postoperative BCVA. On the other hand, phaco-vitreotomy ( $\beta=-$   
183 0.343,  $p<0.001$ ) was a significant predictor positively affecting final postoperative BCVA. LMH type,

184 whether “true” LMH or ERMF, was not a significant predictor of postoperative BCVA. All other  
185 variables were not significantly associated with final postoperative BCVA.

## 186 **Postoperative Complications**

187 Preoperatively, 61 (67.0%) patients were phakic, among whom 24 (39%) underwent phaco-  
188 vitrectomy. The number of subjects who presented cataracts increased significantly after surgery  
189 ( $p<0.001$ ), rising from 53 (58.9%) to 80 (88.9%). After surgery, one patient (1.1%) developed  
190 uveitis. MH occurred in 5 (5.5%) cases postoperatively. **Figure 2** depicts preoperative and  
191 postoperative OCT images of a patient who experienced an MH postoperatively and subsequently  
192 underwent a secondary vitrectomy. **Table 4** summarizes the characteristics of the patients who  
193 experienced postoperative MH development.

194 Postoperative MH was associated with “true” LMH as all 5 patients who developed the  
195 complication were “true” LMH subjects ( $p=0.008$ ). Sex was also associated with postoperative MH  
196 as 4 (80.0%) subjects who developed MH were males ( $p=0.036$ ). Patients with postoperative MH  
197 had a significantly worse preoperative median [Q1, Q3] BCVA (postoperative MH group: 0.76 [0.45,  
198 1.11], no postoperative MH group: 0.42 [0.26, 0.56],  $p=0.033$ ). Other parameters were not  
199 significantly associated with postoperative MH.

## 200 **Discussion**

201 The purpose of this study was to analyze the functional and anatomic outcomes of LMH  
202 surgery using the latest classification.<sup>4</sup> Results indicate that LMH surgery is an effective treatment  
203 for LMH, resulting in high rates of closure (88.9%) and improved visual outcomes (median gain of  
204 1 line on the Snellen chart), which confirms previous meta-analysis findings.<sup>19</sup> Whether ERMF and  
205 “true” LMH have different surgical outcomes was unclear. Previous studies showed heterogenous  
206 results; with some indicating a postoperative discrepancy between the two entities and some not  
207 reporting differences.<sup>12, 19–24</sup> Hubschman et al.’s reclassification implied that LMH and ERMF might  
208 have different surgical outcomes as they may follow distinct pathological pathways.<sup>4</sup> Thus, the  
209 present study also aimed at investigating that matter. LMH surgery had positive functional



210 outcomes for both ERMF and “true” LMH as lesion type was not significantly associated with  
211 postoperative final BCVA when adjusted for confounding variables. However, “true” LMH cases  
212 represented 90.0% of the cases which did not achieve LMH closure and 100% of the cases which  
213 developed postoperative MH.

214 Venkatesh et al. associated the presence of ERP in LMH with lower visual acuity, larger  
215 LMH size, thinner residual retinal tissue, larger EZ disruption, and larger inner segment/outer  
216 segment (IS/OS) defects.<sup>23</sup> The results of the present study align with the latter, as cases  
217 presenting with ERP had worse baseline BCVA, a higher incidence of ELM and EZ defects, a  
218 thinner central fovea, a higher LMH non-closure rate, as well as a higher incidence of postoperative  
219 MH. “True” LMH patients were older and waited longer to undergo surgery, which may suggest that  
220 “true” LMH could be a subsequent manifestation or a more advanced stage of the condition, as  
221 proposed by Lee et al.<sup>7</sup> Omoto et al. reported that the presence of ERP was not significantly related  
222 to postoperative VA, which contrasts with the findings of the current study.<sup>20</sup> When adjusted for  
223 preoperative BCVA, “true” LMH patients without ERP had worse final BCVA in the present report.  
224 These “true” LMH cases had solely undergone an ILM peeling.

225 Patients with higher CFT values had better anatomic results, as they presented a milder loss  
226 of foveal tissue. While not reaching statistical significance, EZ disruption was related to worse final  
227 postoperative BCVA, and subjects who did not achieve LMH closure tended to have larger base  
228 diameter and apex diameter of the LMH. These findings emphasize the importance of evaluating  
229 anatomic foveal features before proceeding with surgery.

230 Moreover, a significant worsening predictor of both functional and anatomic outcomes was  
231 masculine sex. Age at presentation was not significantly different between sexes, neither was the  
232 frequency of a specific lesion type.

233 Haave et al. suggested that if cataract is present, combining phaco-vitreotomy during surgical  
234 intervention could optimize functional outcomes.<sup>25</sup> Coassin et al. conducted a retrospective study  
235 of patients who underwent surgical treatment for symptomatic LMHs where pseudophakic patients  
236 exhibited better outcomes than phakic patients.<sup>16</sup> The current study’s results are consistent with  
237 those findings as postoperative BCVA was significantly improved with phaco-vitreotomy. Haave et

238 al. further reported that gas tamponade should be avoided as patients who were exclusively  
239 administered a balanced salt solution (BSS) achieved the most favorable outcomes.<sup>25</sup> However, no  
240 significant relationship was found between air, SF<sub>6</sub> or C<sub>3</sub>F<sub>8</sub> tamponade and postoperative outcomes  
241 in the present study. These results suggest that similarly to what was recently reported for idiopathic  
242 macular holes in Dervenis et al.'s systematic review and meta-analysis, the choice of tamponade  
243 does not affect visual outcomes or closure rates in lamellar macular hole surgery.<sup>26</sup>

244 All postoperative FTMH cases were “true” LMH cases. Other studies have also reported  
245 the occurrence of postoperative FTMH in “true” LMH cases, as the ERP often present in such cases  
246 is more challenging to peel.<sup>27, 28</sup> Thus, the fovea sparing and the flap embedding peeling techniques  
247 have emerged as alternatives for treating LMH.<sup>29,30</sup> The rationale behind them is to avoid peeling  
248 the edges of the LMH which are oftentimes connected to the ERP. Such studies have reported  
249 positive outcomes and no postoperative FTMH, but further comparative studies are warranted to  
250 establish the superiority of a peeling technique over the other.<sup>29,30</sup>

251 Limitations of this study include its retrospective nature. The surgery was performed by  
252 multiple surgeons, which might induce heterogeneity in outcomes. However, surgical technique did  
253 not differ between surgeons. The study's strengths include its relatively large cohort size (n=90),  
254 making it one of the largest in comparison to similar research, and the largest using the latest  
255 classification of LMH.<sup>4</sup> The study also examined how the OCT subtype of LMH and the used  
256 surgical technique affected visual and anatomical outcomes, which was not done in previous  
257 studies. Furthermore, the study benefits from a relatively long median follow-up period, enabling  
258 comprehensive evaluation of surgical outcomes over an extended duration. Finally, various  
259 controversial factors that could influence surgical outcomes were examined, providing valuable  
260 insights of the key considerations for evaluating the likelihood of surgical success.

## 261 **Conclusion**

262 In conclusion, this study sheds light on the characteristics and outcomes of patients  
263 undergoing surgery for “true” LMH and ERMF. It further supports the effectiveness of primary  
264 vitrectomy as a viable treatment option for LMH patients, particularly those undergoing concomitant

265 cataract treatment. “True” LMH and ERMF patients had significantly different anatomic  
266 characteristics at presentation. Although functional outcomes did not significantly differ between  
267 the two groups, anatomic outcomes were worse in “true” LMH. Therefore, specific considerations  
268 should be given to OCT biomarkers and patients presenting “true” LMH to optimize surgical  
269 outcomes and limit postoperative complications.

## 270 **Acknowledgments**

271 The patients included in this study for enabling advancement in the field.

## 272 **Disclosure**

273 The authors report no conflicts of interest in this work.

## 274 **References**

- 275 1. John Donald G. Lamellar Macular Hole A Complication of Cystoid Macular Edema After  
276 Cataract Extraction. *Arch Ophthalmol.* 1976;94(5):231-250.  
277 doi:<https://doi.org/10.1001/archopht.1976.03910030391008>
- 278 2. Witkin AJ, Ko TH, Fujimoto JG, et al. Redefining Lamellar Holes and the Vitreomacular  
279 Interface: An Ultrahigh-Resolution Optical Coherence Tomography Study. *Ophthalmology.*  
280 2006;113(3):388-397. doi:<https://doi.org/10.1016/j.optha.2005.10.047>.
- 281 3. Govetto A, Dacquay Y, Farajzadeh M, et al. Lamellar Macular Hole: Two Distinct Clinical  
282 Entities? *Am J Ophthalmol.* 2016;164:99-109. doi:10.1016/j.ajo.2016.02.008
- 283 4. Hubschman JP, Govetto A, Spaide RF, et al. Optical coherence tomography-based  
284 consensus definition for lamellar macular hole. *Br J Ophthalmol.* 2020;104(12):1741.  
285 doi:10.1136/bjophthalmol-2019-315432
- 286 5. Hsia Y, Lee CY, Ho TC, Yang CH, Yang CM. The development and evolution of lamellar  
287 macular hole in highly myopic eyes. *Eye.* Published online May 13, 2022. doi:10.1038/s41433-022-  
288 02086-3

- 289 6. Wu L, Evans T, Arevalo JF. Idiopathic macular telangiectasia type 2 (idiopathic  
290 juxtafoveolar retinal telangiectasis type 2A, Mac Tel 2). *Surv Ophthalmol*. 2013;58(6):536-559.  
291 doi:10.1016/j.survophthal.2012.11.007
- 292 7. Lee CY, Hsia Y, Yang CM. Formation and evolution of idiopathic lamellar macular hole-a  
293 pilot study. *BMC Ophthalmol*. 2022;22(1):432. doi:10.1186/s12886-022-02669-4
- 294 8. Compera D, Entchev E, Haritoglou C, et al. Lamellar Hole–Associated Epiretinal  
295 Proliferation in Comparison to Epiretinal Membranes of Macular Pseudoholes. *Am J Ophthalmol*.  
296 2015;160(2):373-384.e1. doi:10.1016/j.ajo.2015.05.010
- 297 9. Bringmann A, Unterlauff JD, Wiedemann R, Rehak M, Wiedemann P. Morphology of  
298 partial-thickness macular defects: presumed roles of Müller cells and tissue layer interfaces of low  
299 mechanical stability. *Int J Retina Vitre*. 2020;6(1):28. doi:10.1186/s40942-020-00232-1
- 300 10. Su YT, Yang CM, Lai TT. Multimodal imaging evidence of traction component in lamellar  
301 macular hole with epiretinal proliferation. *Ophthalmic Res*. 2023;66(1):828-838.  
302 doi:10.1159/000530529
- 303 11. Parolini B, Schumann RG, Cereda MG, Haritoglou C, Pertile G. Lamellar macular hole: a  
304 clinicopathologic correlation of surgically excised epiretinal membranes. *Invest Ophthalmol Vis Sci*.  
305 2011;52(12):9074-9083. Published 2011 Nov 25. doi:10.1167/iovs.11-8227
- 306 12. Ko J, Kim GA, Lee SC, et al. Surgical outcomes of lamellar macular holes with and without  
307 lamellar hole-associated epiretinal proliferation. *Acta Ophthalmol (Copenh)*. 2017;95(3):e221-  
308 e226.
- 309 13. Morescalchi F, Russo A, Gambicorti E, et al. PEELING OF THE INTERNAL LIMITING  
310 MEMBRANE WITH FOVEAL SPARING FOR TREATMENT OF DEGENERATIVE LAMELLAR  
311 MACULAR HOLE. *Retina*. 2020;40(6):1087-1093. doi:10.1097/IAE.0000000000002559
- 312 14. Takahashi K, Morizane Y, Kimura S, et al. Results of lamellar macular hole-associated  
313 epiretinal proliferation embedding technique for the treatment of degenerative lamellar macular  
314 hole. *Graefes Arch Clin Exp Ophthalmol*. 2019;257(10):2147-2154. doi:10.1007/s00417-019-  
315 04425-9
- 316 15. Duker JS, Kaiser PK, Binder S, et al. The International Vitreomacular Traction Study Group

- 317 Classification of Vitreomacular Adhesion, Traction, and Macular Hole. *Ophthalmology*.  
318 2013;120(12):2611-2619. doi:10.1016/j.ophtha.2013.07.042
- 319 16. Coassin M, Mastrofilippo V, Stewart JM, et al. Lamellar macular holes: surgical outcome  
320 of 106 patients with long-term follow-up. *Graefes Arch Clin Exp Ophthalmol*. 2018;256:1265-1273.
- 321 17. Marques MF, Rodrigues S, Raimundo M, et al. Epiretinal proliferations associated with  
322 lamellar macular holes: clinical and surgical implications. *Ophthalmologica*. 2018;240(1):8-13.
- 323 18. Mariacristina Parravano, Francesco Oddone, Barbara Boccassini, et al. Functional and  
324 structural assessment of lamellar macular holes. *Br J Ophthalmol*. 2013;97(3):291.  
325 doi:10.1136/bjophthalmol-2011-301219
- 326 19. Parisi G, Fallico M, Maugeri A, et al. Primary vitrectomy for degenerative and tractional  
327 lamellar macular holes: A systematic review and meta-analysis. *PloS One*. 2021;16(3):e0246667.  
328 doi:10.1371/journal.pone.0246667
- 329 20. Omoto T, Asahina Y, Zhou HP, et al. Visual outcomes and prognostic factors of vitrectomy  
330 for lamellar macular holes and epiretinal membrane foveoschisis. *PloS One*. 2021;16(2):e0247509.  
331 doi:10.1371/journal.pone.0247509
- 332 21. Pang CE, Spaide RF, Freund KB. EPIRETINAL PROLIFERATION SEEN IN  
333 ASSOCIATION WITH LAMELLAR MACULAR HOLES: A Distinct Clinical Entity. *Retina*.  
334 2014;34(8):1513-1523. doi:<https://doi.org/10.1097/IAE.000000000000163>
- 335 22. Lai TT, Chen SN, Yang CM. Epiretinal proliferation in lamellar macular holes and full-  
336 thickness macular holes: clinical and surgical findings. *Graefes Arch Clin Exp Ophthalmol Albrecht*  
337 *Von Graefes Arch Klin Exp Ophthalmol*. 2016;254(4):629-638. doi:10.1007/s00417-015-3133-9
- 338 23. Venkatesh R, Pereira A, Jain K, Kumar Yadav N. Structural and Functional Outcomes of  
339 Surgery for Lamellar Macular Holes with or without Epimacular Proliferations. *J Ophthalmic Vis*  
340 *Res*. 2022;17(1):42-50. doi:10.18502/jovr.v17i1.10169
- 341 24. Caretti L, La Gloria Valerio A, Verzola G, Badin G, Monterosso C, Daniele AR. Functional  
342 and morphological outcomes after surgery in lamellar macular holes versus epiretinal membrane  
343 foveoschisis. *Eur J Ophthalmol*. 2021;31(6):3294-3299. doi:10.1177/1120672120974287
- 344 25. Haave H, Petrovski BÉ, Zajac M, et al. Outcomes from the Retrospective Multicenter

345 Cross-Sectional Study on Lamellar Macular Hole Surgery. *Clin Ophthalmol Auckl NZ*.  
346 2022;16:1847-1860. doi:10.2147/OPTH.S351932

347 26. Dervenis N, Dervenis P, Sandinha T, Murphy DC, Steel DH. Intraocular Tamponade  
348 Choice with Vitrectomy and Internal Limiting Membrane Peeling for Idiopathic Macular Hole: A  
349 Systematic Review and Meta-analysis. *Ophthalmol Retina*. 2022 Jun;6(6):457-468. doi:  
350 10.1016/j.oret.2022.01.023. Epub 2022 Feb 7. PMID: 35144020.

351 27. Figueroa MS, Govetto A, Steel DH, Sebag J, Virgili G, Hubschman JP. PARS PLANA  
352 VITRECTOMY FOR THE TREATMENT OF TRACTIONAL AND DEGENERATIVE LAMELLAR  
353 MACULAR HOLES: Functional and Anatomical Results. *Retina*. 2019;39(11):2090-2098.  
354 doi:10.1097/IAE.0000000000002326

355 28. Ko J, Kim GA, Lee SC, et al. Surgical outcomes of lamellar macular holes with and without  
356 lamellar hole-associated epiretinal proliferation. *Acta Ophthalmol*. 2017;95(3):e221-e226.  
357 doi:10.1111/aos.13245

358 29. Morescalchi F, Russo A, Gambicorti E, Cancarini A, Scaroni N, Bahja H, Costagliola C,  
359 Semeraro F. PEELING OF THE INTERNAL LIMITING MEMBRANE WITH FOVEAL SPARING  
360 FOR TREATMENT OF DEGENERATIVE LAMELLAR MACULAR HOLE. *Retina*. 2020  
361 Jun;40(6):1087-1093.

362 30. Kanai M, Sakimoto S, Takahashi S, Nishida K, Maruyama K, Sato S, et al. Embedding  
363 Technique versus Conventional Internal Limiting Membrane Peeling for Lamellar Macular Holes  
364 with Epiretinal Proliferation. *Ophthalmol. Retina*. 2023 Jan;7(1):44–51.

365

366

367

368

369

370

371

372

**Table 1** Comparison of Preoperative Clinical and Optical Coherence Tomography Findings of ERMF and “true” LMH Patients

Variable	ERMF	“True” LMH	p-value
	N = 51	N = 39	
Age at surgery (years), mean ± SD	69 ± 9	74 ± 8	<b>0.005</b>
Preop period (days), median [Q1, Q3]	97 [46, 181]	146 [69, 595]	<b>0.021</b>
BCVA (logMAR), median [Q1, Q3], Snellen	0.32 [0.20, 0.54], 20/42	0.52 [0.40, 0.74], 20/66	<b>0.001</b>
Base diameter of LMH (µm), median [Q1, Q3]	758 [576, 1424]	1144 [762, 1298]	0.136
Apex diameter of LMH (µm), median [Q1, Q3]	399 [303, 537]	530 [346, 702]	<b>0.019</b>
CFT of LMH (µm), median [Q1, Q3]	389 [330, 436]	308 [271, 354]	<b>&lt;0.001</b>
AFT of LMH (µm), median [Q1, Q3]	322 [300, 340]	295 [275, 317]	<b>0.001</b>
MFT of LMH (µm), median [Q1, Q3]	293 [267, 314]	263 [250, 284]	<b>&lt;0.001</b>
Presence of ELM disruption, N (%)	6 (11.5)	11 (28.2)	<b>0.044</b>
Presence of EZ disruption, N (%)	12 (23.1)	18 (46.2)	<b>0.020</b>
Presence of IRCs, N (%)	41 (80.4)	19 (48.7)	<b>0.002</b>
Presence of PVD, N (%)	27 (54.0)	16 (43.2)	0.280
Presence of VMT, N (%)	2 (3.9)	6 (15.4)	0.128

**Notes:** Bold values were considered statistically significant.

**Abbreviations:** AFT, average foveal thickness; BCVA, best corrected visual acuity; CFT, central foveal thickness; ELM, external limiting membrane; EZ, ellipsoid zone; IRC, intraretinal cyst; LMH, lamellar macular hole; MFT, minimal foveal thickness; PVD, posterior vitreous detachment; preop, preoperative; SE, standard error; VMT, vitreomacular traction.

**Table 2** Comparison of patient characteristics between cases which did and did not lead to lamellar macular hole (LMH) closure

Variable	LMH closure	LMH non-closure	p-value
	N = 80	N = 10	
Age at surgery (years), mean ± SD	71 ± 9	76 ± 8	0.084
Masculine sex, N (%)	26 (32.5)	7 (70.0)	<b>0.020</b>
“True” LMH, N (%)	30 (37.5)	9 (90.0)	<b>0.002</b>
SF <sub>6</sub> tamponade, N (%)	52 (65.0)	6 (54.5)	0.499
Indocyanine green staining, N (%)	53 (67.1%)	8 (80.0%)	0.407
Follow-up period (months), median [Q1, Q3]	15 [6, 29]	6 [2, 26]	0.180
Preop BCVA (logMAR), median [Q1, Q3], Snellen	0.40 [0.26, 0.56], 20/50	0.66 [0.47, 0.80], 20/100	<b>0.009</b>
Preop base diameter of LMH (µm), median [Q1, Q3]	854 [620, 1315]	1253 [767, 1453]	0.176
Preop apex diameter of LMH (µm), median [Q1, Q3]	421 [314, 608]	632 [385, 827]	0.052
Preop CFT of LMH (µm), median [Q1, Q3]	354 [299, 413]	295 [271, 360]	0.065
Preop AFT of LMH (µm), median [Q1, Q3]	316 [285, 331]	305 [287, 321]	0.472
Preop MFT of LMH (µm), median [Q1, Q3]	282 [253, 304]	282 [252, 299]	0.990
Preop presence of EZ disruption, N (%)	25 (31.3)	4 (40.0)	0.577
Preop presence of VMT, N (%)	8 (10.0)	0 (0.0)	0.295
Exclusive ILM peeling (“true” LMH patients with no ERP), N (%)	5 (5.6)	0 (0.0)	0.416

**Notes:** Bold values were considered statistically significant.

**Abbreviations:** AFT, average foveal thickness; BCVA, best corrected visual acuity; CFT, central foveal thickness; ELM, external limiting membrane; EZ, ellipsoid zone; LMH, lamellar macular hole; MFT, minimal foveal thickness; preop, preoperative; SE, standard error; SF<sub>6</sub>, sulfur hexafluoride; VMT, vitreomacular traction.



**Table 3** Multiple linear regression model for final best-corrected visual acuity (BCVA) following surgery for lamellar macular hole (LMH) in 90 patients

Variable	B	95% CI	$\beta$	p-value
Age at surgery	0.005	-0.004, 0.013	0.108	0.266
Sex	0.275	0.134, 0.415	0.358	<b>&lt;0.001</b>
Preop BCVA	0.188	-0.067, 0.443	0.144	0.146
Phaco-PPV	-0.281	-0.437, -0.125	-0.343	<b>&lt;0.001</b>
No ILM peeling	0.226	-0.101, 0.552	0.129	0.173
Exclusive ILM peeling (“true” LMH patients with no ERP)	0.304	0.015, 0.594	0.194	<b>0.040</b>
SF <sub>6</sub> tamponade	0.109	-0.037, 0.255	0.141	0.142
LMH closure	-0.048	-0.274, 0.177	-0.042	0.671
Preop CFT of LMH	-0.001	-0.002, 0.000	-0.128	0.192
Lesion type (ERMF/“true” LMH)	-0.037	-0.205, 0.131	-0.050	0.665
Preop base diameter of LMH	0.000	0.000, 0.000	-0.142	0.131
Preop presence of EZ disruption	0.144	-0.006, 0.295	0.182	0.060
Preop presence of IRCs	-0.118	-0.268, 0.032	-0.150	0.123

**Notes:** Bold values were considered statistically significant.

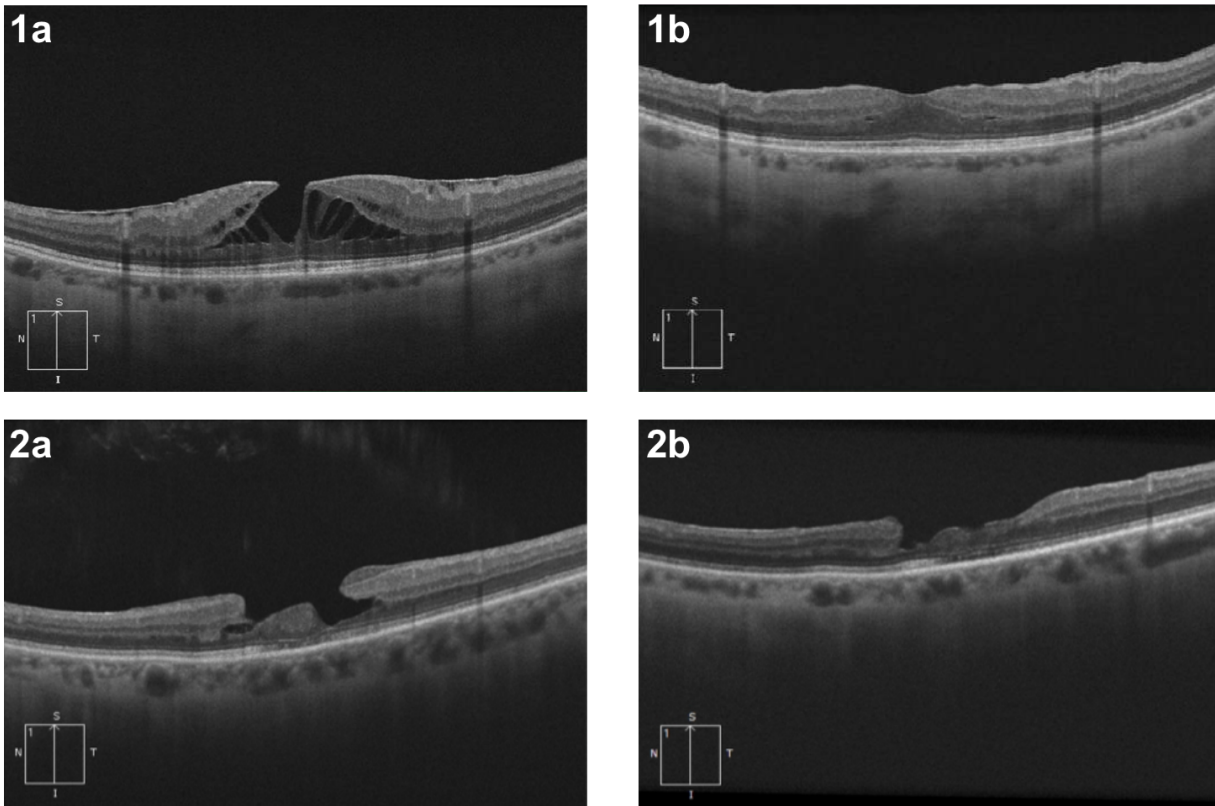
**Abbreviations:** AFT, average foveal thickness; BCVA, best corrected visual acuity; B, unstandardized coefficients;  $\beta$ , standardized coefficients; CI, confidence interval; CFT, central foveal thickness; ERM, epiretinal membrane; ERMF, epiretinal membrane foveoschisis; ERP, epiretinal proliferation; EZ, ellipsoid zone; ILM, internal limiting membrane; IRC, intraretinal cyst; LMH, lamellar macular hole; PPV, pars plana vitrectomy; preop, preoperative; SF<sub>6</sub>, sulfur hexafluoride.

**Table 4** Clinical data and optical coherence tomography (OCT) characteristics of postoperative macular hole cases

Patient/ Sex	LMH type	BCVA (logMAR, Snellen)		Surgical modalities			Preop OCT characteristics		
		Preop	Postop (final)	Peeling	Tamponade	Prone positioning	CFT/AFT ( $\mu\text{m}$ )	Base/apex diameter ( $\mu\text{m}$ )	Preop EZ disruption
1/M	“true” LMH	1.3, 20/400	0.64, 20/80 <sup>-2</sup>	ERP + ILM	SF <sub>6</sub>	No	289/305	1246/233	Yes
2/M	“true” LMH	0.92, 20/150 <sup>-2</sup>	0.88, 20/150	ERP + ILM	SF <sub>6</sub>	No	354/305	1514/347	Yes
3/F	“true” LMH	0.28, 20/40 <sup>+1</sup>	0.28, 20/40 <sup>+1</sup>	ERP + ILM	SF <sub>6</sub>	Yes	271/313	1303/780	Yes
4/M	“true” LMH	0.76, 20/100 <sup>-3</sup>	0.66, 20/30 <sup>+2</sup>	ERP + ILM	Air	Yes	293/309	1432/633	No
5/M	“true” LMH	0.62, 20/80 <sup>-1</sup>	1.28, 20/400 <sup>+1</sup>	ERP + ILM	SF <sub>6</sub>	Yes	379/528	1200/899	No

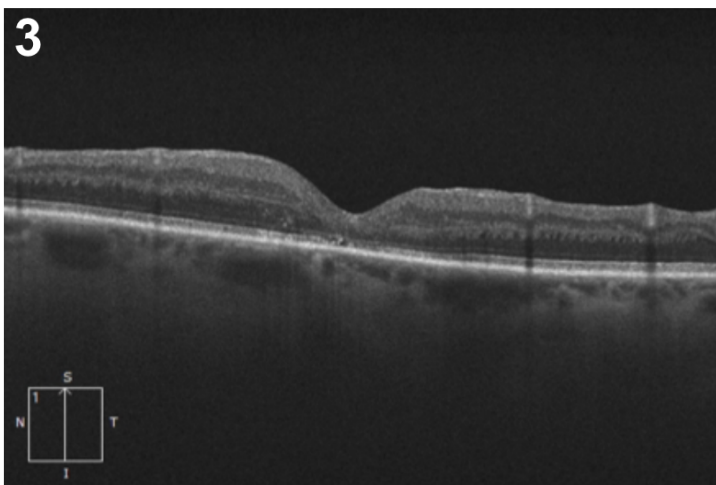
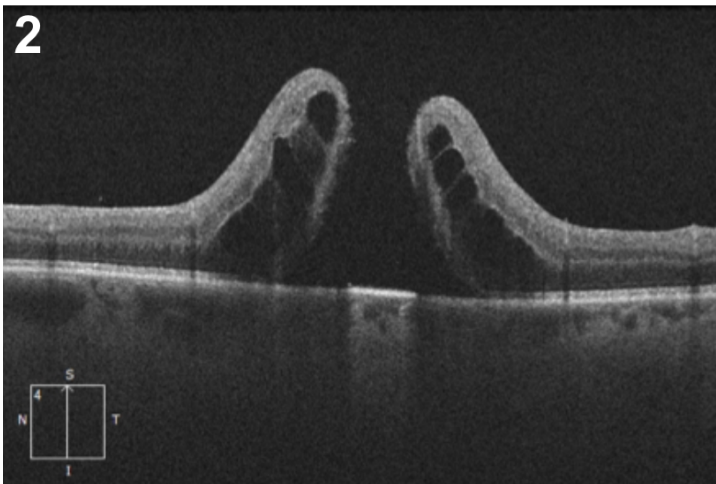
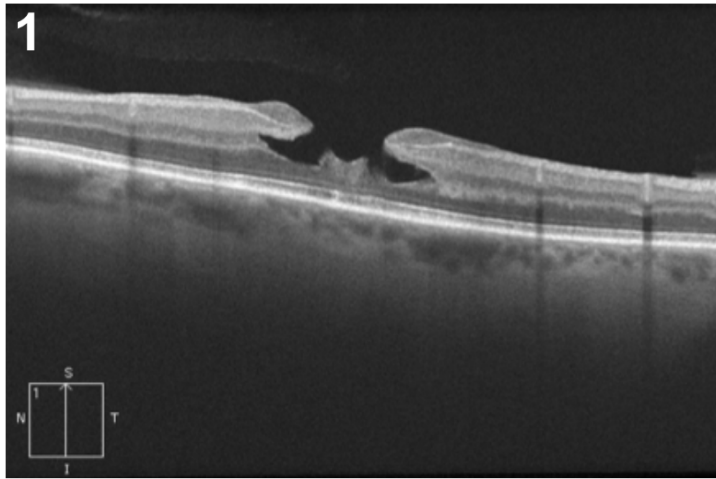
**Abbreviations:** AFT, average foveal thickness; AMD, age-related macular degeneration; BCVA, best corrected visual acuity; CFT, central foveal thickness; ERP, epiretinal proliferation; EZ, ellipsoid zone; GA: geographic atrophy; ILM, internal limiting membrane; LMH, lamellar macular hole; OCT, optical coherence tomography; postop, postoperative; preop, preoperative; SF<sub>6</sub>, sulfur hexafluoride.

**Figure 1** Optical coherence tomography features of cases of lamellar macular hole (LMH) closure and non-closure postoperatively.



**Figure 1.** The patient who achieved LMH closure initially presented with epiretinal membrane foveoschisis (1a). Restoration of the retinal layers was achieved following surgery (1b). The patient who did not achieve LMH closure initially presented with “true” LMH and epiretinal proliferation (2a). Although the epiretinal proliferation was successfully removed during surgery, the patient did not achieve full LMH closure following surgery, as a break in the inner layers of the retina remained.

**Figure 2** Optical coherence tomography features of a “true” lamellar macular hole patient undergoing surgery and experiencing postoperative full-thickness macular hole postoperatively.



**Figure 2.** The patient initially presented with idiopathic “true” lamellar macular hole and epiretinal proliferation of medium reflectivity (1). Posterior vitreous detachment had to be induced surgically. The

patient received sulfur hexafluoride (SF<sub>6</sub>) tamponade and was instructed to maintain prone positioning for three days following surgery. The patient underwent a secondary revision surgery 36 days postoperatively as he developed stage 4 MH that was discovered during his two-week postoperative appointment (2). Following the second surgery, normalisation of the foveolar profile was achieved in the patient (3).