

ENTAgents: AI Agents for Complex Knowledge Otolaryngology

Tsz Kin Chan¹ and Ngoc-Duy Dinh¹

¹Department of Biomedical Engineering, The Chinese University of Hong Kong, Shatin, N.T., Hong Kong,

Correspondence to: ngocduy dinh@cuhk.edu.hk; dinhngocduy@u.nus.edu

January 02, 2025

Abstract

Various healthcare applications based on large language models (LLMs) have emerged as LLMs show improved efficiency and error reduction. Recently, retrieval augmented generation (RAG) has been adopted frequently for LLM applications to solve the problem of hallucinations. Despite the success of RAG, it has its drawbacks, including incomplete semantic meanings, and large-scale dataset requirements. AI Agents have shown great potential in medicine and healthcare applications by leveraging their rich background knowledge and reasoning capabilities. In this paper, we introduce ENTAagents, a framework that utilizes both the RAG and multi-agent systems. To achieve better decision-making and enhanced explainability, we use the verbal reinforcement learning framework, Reflexion, as a reference for the task planning of ENTAagents. With the verbal feedback received from the last agent node, the agentic system can decide the best agent to utilize to improve the response of ENTAagents. We tested ENTAagents with various types of questions, including short questions, essay questions, and multiple-choice questions. ENTAagents improve accuracy by over 11.3% in handling short questions, with 2.78 folds in the length of the text and explaining clearly. ENTAagents shows higher accuracy and is more comprehensive in its answer compared to other LLM models. ENTAagents also demonstrates its ability to refine its answer with additional information to make it more thorough and educational. It also presents the capability to change its response to the correct answer in multiple-choice questions according to its self-reflection. Overall, ENTAagents is easy to use, can self-correct, and can provide detailed information in complex knowledge to users. We look forward to integrating ENTAagents into various healthcare scenarios, such as medical education and clinical decision support, particularly otolaryngology.

Keywords: LLM Agents, Multi-Agents, ENT, Otolaryngology, LLMs

NOTE: This preprint reports new research that has not been certified by peer review and should not be used to guide clinical practice.

1. Introduction

Large language models (LLMs) have been in the spotlight in different industries since the release of ChatGPT, with the healthcare sector being one of the potential industries that can unlock the power of LLMs and new opportunities in medical applications. Numerous utilizations of LLMs have been proposed in the healthcare system, including health record management [1-2], medical image analysis [3-4], and medical research [5-6]. These applications have made significant impacts on the healthcare systems by minimizing human errors, enhancing efficiency, and providing medical research support [6-7]. Nevertheless, there are still concerns in LLM-based medical applications. Since LLMs often generate hallucinations, which is a response that is either factually incorrect or nonsensical. The hallucination rate of top LLM models is from 1.3% to 4.3% [8]. Although these values are not significant, concerns could be raised when an inaccurate response is generated by the LLM application, especially when it comes to clinical decision support, as reliability and trustfulness of a system are the most important principles in the healthcare sector.

To eliminate hallucinations in LLM, several techniques have been proposed in which the retrieval augmented generation (RAG) is one of the easiest and most cost-effective methods to deal with hallucinations. RAG is a technique that provides related accurate data from the external knowledge base to the LLMs. With the advancements of RAG techniques, RAG has shown promising results in alleviating hallucinations and a wide range of applications in healthcare [9-14]. Long et al introduced ChatENT, which is an AI framework specialized in otolaryngology, with the use of ChatGPT 4.0 and Retrieval-Augmented Language Modeling (RALM) [14], demonstrated a good capability of answering otolaryngology questions. Despite the success of the RAG systems, information loss, the need of large-scale dataset and time-consuming are the issues when building a RAG system. Often RAG fails to deliver the complete significant information to the LLM as the context is separated by the chunk size but not the contextual meaning, and a large volume of manipulated dataset is required to cover all the knowledge in one specialty [14,15]. It has evolved very fast in the medical field, it is not feasible to update the knowledge database frequently for RAG, especially for comprehensive healthcare applications. Therefore, there is a need to produce an LLM system that can be reliable and handle different tasks in the healthcare industry. Agentic systems have emerged as a popular approach in different applications due to their scalability and robustness, and these advantages are crucial to address the dynamic healthcare environments. Several agentic

systems have been proposed to the healthcare industry, offering medical knowledge, diagnosis, clinical record management and more [16-20]. Nevertheless, the existing agentic systems use information from their database or repository to handle clinical diagnosis and treatment. They lack the ability to generate insights into specialized medications and unseen diseases [17,21-23]. In addition, the current agentic system is not capable of examining their answer or understanding the question, including irrelevant contexts as a result [24].

Here, we introduce an innovative LLM agentic framework, ENTAgents, which is a system addressing the medical specialty in otolaryngology and utilizing RAG and multiple agents to optimize its response. We take Reflexion, the verbal reinforcement learning framework, as a reference for the task planning of our agents [25]. ENTAgents demonstrate the ability to self-correct their answer based on the question, with the aid of information found by the agents. We show that ENTAgents can utilize different agents successfully and perform excellently in different types of questions. It is a cost-efficient, ease-of-use, time-saving approach to handling medical specialty questions without any need for fine-tuning and has great potential for medical education and clinical support for all medical specialties.

2. Methods

2.1 Overview

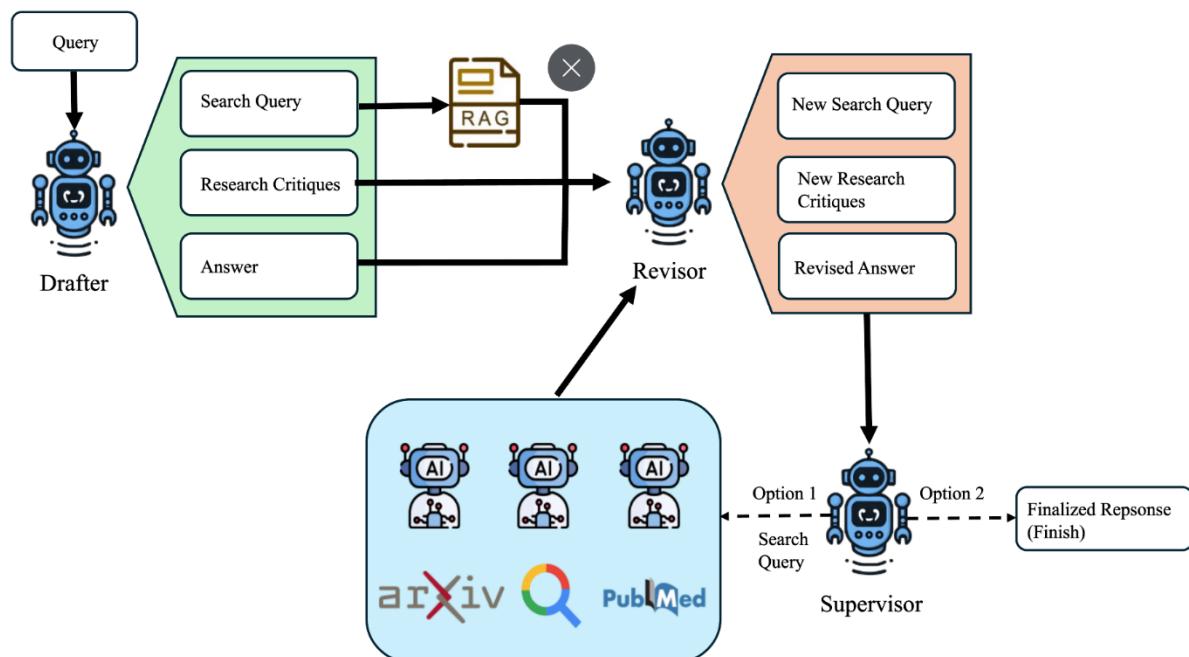


Figure 1: ENTAgents flow diagram from question input to answer generation

Fig. 1 shows the pipeline of our proposed ENTAgents framework. The first node, “Drafter”,

generates an initial answer based on the question by LLM. After that, the LLM model examines its answer and generates critiques in our designated format for reflection, followed by the search queries according to the reflection critiques. Subsequently, RAG is performed to extract relevant information from our knowledge base to search queries in the second agent node. For the third node, we call a “Revisor,” which revises the drafted answer based on the reflection critiques and extracted information. Then, the LLM will provide new reflection critiques and search queries if they decide the revised answer is not the best. The “Supervisor” node will examine the question and the revised answer to choose the best agent to acquire new information or finish the execution. The agent searches for information or data with their tool and summarizes it. They are then passed back to the Revisor, and hence, a loop is created until the Supervisor decides that the answer does not need to be adjusted. Llama 3.1 70B model from Meta is used for the Drafter and Revisor, and Llama-3-Groq-70b-Tool-Use from Groq is used for the Supervisor and the agents, built for tool use and function calling. ENTAgent is built on the LangGraph platform.

2.2 RAG

To perform RAG, a knowledge base is first built with a variety of sources, including clinical guidelines, textbooks, and published articles, being chunked with the size of 1024 and chunk overlap of 200, including the whole knowledge base as a part of query extends the latency enormously and reaches the context window of Llama model easily. We used Voyage AI’s voyage-large-2-instruct to embed the chunked documents as vectors that represent their semantic meanings, and they were stored in a vector store initiated by the Facebook AI Similarity Search (FAISS) library. Having received the search queries, the embedding model also converts them into embedding vectors. For each of the queries, six chunks from the knowledge base are selected with the highest similarity between their embedding vectors and search queries’ embedding vectors

2.3 Task Planning: Reflexion

We adopted the Reflexion framework proposed by the reinforcement learning proposed by Shinn et al [25] as the reinforcement learning of our ENTAgents. By leveraging Reflexion, AgenticENT can reflect on their answer and provide verbal feedback, which is stored in the episodic memory and added to the message passed to the next episode. The critiques of what is missing and what is superfluous in the answer were used in the self-reflection for short questions and essay questions, while critiques of inaccuracy and unnecessary were used for

multiple choice questions. The Revisor reduces the redundant information in the last answer based on the critique of unnecessary and adds additional information provided by RAG or agents or changes the chosen answer according to the critique of missing and inaccuracy, respectively.

2.4 Multi-Agent System

We have three agents that use different tools to search for information from three tools: Google Search, ArXiv, and Pubmed. ArXiv tool searches for relevant articles from its database, which contains preprint and postprint scholarly articles, while the Pubmed tool finds published biomedical literature from the Pubmed database. Google Search tool uses the search engine to find the most relevant information from the website to the query. When the Supervisor decides the best agent to act on next, the search query is passed to that agent. The agent then executes the search query with its tool and concludes what it has found and how it can address the search query in a summary. Finally, the summary is sent to the revisor for revision again.

3. Results

The effectiveness and the capability of ENTAgents were evaluated using various types of questions, which are short answer questions, essay questions, and multiple-choice questions.

3.1 Short Answer Questions

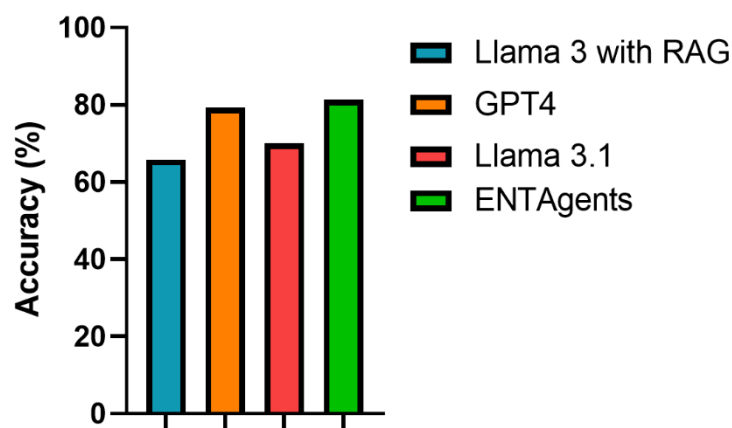


Figure 2: Accuracy rate of various LLM models for the short questions from the Royal College of Physicians and Surgeons of Canada (RCPSC)

19 short answer questions were used to assess the response of ENTAgents in otolaryngology, which includes 11 sample questions from the Royal College of Physicians and Surgeons of Canada (RCPSC). The accuracy of ENTAgents was evaluated with these 11 questions.

ENTAgents based on Llama 3.1 scored 30.5 out of 37.5, a correct percentage of 81.3%, which is significantly higher than Llama 3.1 without Agentic, which is 70% (Figure 2). We can see the correct percentage of ENTAagents based on Llama 3.1 is a little higher than the paid model ChatGPT 4.0, which is 79.3%, but there are significant differences between ChatGPT 4.0 (ChatENT based on ChatGPT 4.0) and ENTAagents. The responses from ChatENT and ENTAagents were compared, as shown in Table 1. As ChatENT is not an open-source model, the responses from ChatENT were extracted from the supplementary information of the original paper. The average length of ENTAagents’s responses was approximately 258.3 and that of ChatENT’s responses was 92.5. The average latency of ENTAagents was 118.7 seconds. From Table 1, it can be observed that ENTAagents provided a more thorough answer than ChatENT did. The ChatENT failed to identify the number of sub-questions in this question, and it was only able to answer the second part of the question, while our ENTAagents provided complete answers for two parts of the question. For the first part of the question, both correct answers and explanations were provided by ENTAagents, making the answer understandable to the user. Both ENTAagents and ChatENT were able to generate three techniques required from the question and their functions were also provided. However, ENTAagents generated additional information related to the question and its answer. For instance, ENTAagents gave an example of intraoperative imaging and its functions during surgery so that the third technique could be explained clearly. Extra information related to preventing complications and the advantages of osteoplastic flap procedures was also provided.

Question	ChatENT	ENTAgents
<p>You are performing an osteoplastic flap procedure using a bi-coronal approach for drainage of mucoceles.</p> <p>a. In which soft tissue planes will you elevate the bicoronal flap?</p> <p>b. Once the frontal bone is exposed, list THREE techniques to identify the margins of the frontal sinus prior to making the bony cuts for the osteoplastic flap.</p>	<p>Once the frontal bone is exposed, three techniques to identify the margins of the frontal sinus prior to making the bony cuts for the osteoplastic flap include:</p> <ul style="list-style-type: none"> - Caldwell view X-ray obtained from a distance of 6 feet: This radiographic view helps visualize the frontal sinus and its margins. - Navigation system: Image- 	<p>To answer the question, I will break it down into two parts: a) the soft tissue planes for elevating the bicoronal flap, and b) techniques for identifying the margins of the frontal sinus prior to making the bony cuts for the osteoplastic flap.</p> <p>a) The bicoronal flap is elevated in the subgaleal plane, taking care to avoid injury to the pericranium.</p>

	<p>guided navigation equipment can be used to accurately identify the position of the frontal sinus and guide the surgeon during the procedure.</p> <p>- Shining an endoscope transnasally: By inserting an endoscope through the nasal cavity, the surgeon can visualize the frontal sinus and its margins directly.</p>	<p>This plane is chosen to minimize bleeding and maximize exposure of the frontal bone.</p> <p>b) Once the frontal bone is exposed, there are several techniques that can be used to identify the margins of the frontal sinus prior to making the bony cuts for the osteoplastic flap. These techniques include:</p> <ol style="list-style-type: none">1) Using a 6-foot Caldwell radiograph to outline the frontal sinus on the bone prior to making the bony cuts. This technique allows for precise localization of the frontal sinus and helps to avoid injury to the surrounding bone.2) Using a combination of anatomical landmarks and palpation to identify the margins of the frontal sinus. This technique relies on the surgeon's knowledge of the anatomy of the frontal bone and the location of the frontal sinus.3) Using a navigation system to identify the margins of the frontal sinus in real-time. This technique uses intraoperative imaging to provide precise localization of the frontal sinus and helps to minimize the risk of complications. <i>Intraoperative imaging, such as MRI and CT</i>
--	---	---

		<p><i>scans, can be used to provide real-time feedback during the surgery, helping to identify potential complications and adjust the surgical plan accordingly.</i></p> <p><i>Additionally, the osteoplastic flap procedure is effective in managing complications such as frontal outflow stenosis, mucocele, infection, and paresthesia. Careful preoperative evaluation, precise surgical techniques, and postoperative care are recommended to manage these complications. Endoscopic sinus surgery and the osteoplastic flap procedure with frontal sinus obliteration are also effective methods for dealing with complications. Obtaining patient consent for possible complications and discussing management strategies preoperatively is also important. Furthermore, the osteoplastic flap can help improve outcomes and manage hydrocephalus. The osteoplastic flap procedure with frontal sinus obliteration is a viable option for managing frontal sinus pathology and preventing complications.</i></p> <p><i>Overall, a comprehensive approach that includes careful preoperative evaluation, precise surgical techniques, and postoperative care is recommended to manage</i></p>
--	--	--

		<i>complications and improve outcomes in osteoplastic flap procedures.</i>
--	--	--

Table 1: Comparison of the responses from ChatENT and ENTAgents to a short answer question. The italics paragraphs are the relevant additional information generated by the ENTAgents besides answering the question.

3.2 Essay Questions

The ability to understand and generate subject matter content was also examined with 24 essay questions. The result shows that ENTAgents generated a significant number of relevant words compared to other LLM models (Figure 3). The ENTAgents generated answers with an average of 425.08 words, and the average latency ENTAgents required was 118.67 seconds. An average of 2.67 agents was invoked for ENTAgents to handle an essay question.

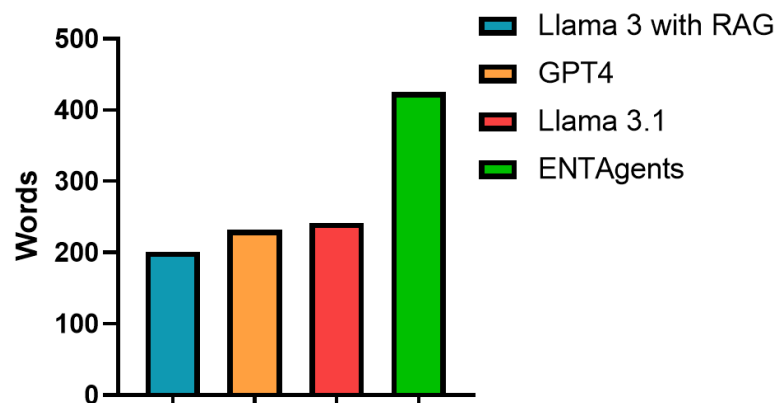


Figure 3: Length of responses from different LLMs to the essay questions

The workflow of the ENTAgents is demonstrated in Table 2. In the initial response, ENTAgents reflected on its answer and stated that the information on aetiopathogenesis was insufficient and that the answer should be more concise and remove repetitive language. The search query was also generated based on the critiques of what is missing. After relevant information was found with the search query, the Revisor edited the previous answer based on the reflection critiques with the aid of the information. The Revisor reviewed its answer again and provided new critiques if it decided the answer required improvements. The supervisor received all the fields from the Revisor and decided that the Google agent should be used. Having revised the answer with the information provided by the agent, the Supervisor saw the answer being the best and finished the execution.

Example: Discuss the aetiopathogenesis, clinical features and management of tubotympanictype of chronic suppurative otitis media.	
Step 1: LLM Drafter	<p>Answer: Tubotympanic chronic suppurative otitis media (CSOM) is a type of infection that affects the middle ear. [...] This may include the treatment of allergies, the use of nasal decongestants, and the avoidance of upper respiratory tract infections.</p> <p>Reflection:</p> <ol style="list-style-type: none"> 1. Missing: One potential critique of this answer is that it lacks specific information on the microbiology of tubotympanic CSOM, including the most common pathogens involved and the antibiotic resistance patterns. Additionally, the answer could benefit from a more detailed discussion of the role of biofilms in the pathogenesis of CSOM. 2. Superfluous: The answer could be improved by removing some of the repetitive language and condensing the information into more concise paragraphs. <p>Search query: What are the most common pathogens involved in tubotympanic chronic suppurative otitis media and what are the current antibiotic resistance patterns?</p>
Step 2: RAG	<p>[...] These pathogens have been mentioned above and include <i>P. aeruginosa</i>, in a moist mastoid cavity, although patients may become sensitized to sulfamethoxazole or amphotericin. Systemic antibiotics should be used in refractory cases when specific pathogens are found on culture. Several quinolones such as ciprofloxacin, ofloxacin, and norfloxacin may be useful in these patients. Ideally, an ear with a tympanic membrane perforation should be free from infection for 3 months before tympanoplasty. [...]</p>
Step 3: Revisor	<p>Revised Answer: [...] <i>The most common pathogens involved in tubotympanic CSOM include Pseudomonas aeruginosa, followed by Proteus mirabilis and Staphylococcus aureus. [...] Furthermore, it is crucial to consider the role of biofilms in the pathogenesis of CSOM, as well as the potential for antibiotic resistance among the causative pathogens.</i> In conclusion, tubotympanic CSOM is a complex condition that requires a comprehensive management approach. By understanding the aetiopathogenesis, clinical features, and management options, healthcare providers can provide effective treatment and improve patient outcomes.</p> <p>Reflection:</p> <ol style="list-style-type: none"> 1. Missing: One potential critique of this revised answer is that it could

	<p>benefit from a more detailed discussion of the role of biofilms in the pathogenesis of CSOM, as well as the potential for antibiotic resistance among the causative pathogens. Additionally, the answer could be improved by including more information on the prevention and treatment of complications associated with tubotympanic CSOM.</p> <p>2. Superfluous: The answer could be improved by removing some of the repetitive language and condensing the information into more concise paragraphs."</p> <p>Search query: What are the current treatment options for biofilm-related infections in tubotympanic chronic suppurative otitis media?</p>
Step 4: Supervisor	Next: Google
Step 5: Google Agent	<p>[...] The management of CSOM is complex and can involve medical and/or surgical approaches. Medical management for a dry ear is essential before surgical treatment, as biofilms are most prevalent in CSOM. [...]</p> <p>Globally, CSOM occurs in 4.76% of the population, with hearing impairment present in 30 children per 10,000.</p>
Step 6: Revisor	<p>Revised Answer: [...] <i>Globally, CSOM affects 4.76% of the population, with hearing impairment present in 30 children per 10,000. The tubotympanic type of CSOM is characterized by a chronic infection of the middle ear, with a perforated tympanic membrane and a discharge.</i> [...]</p> <p>Reflection:</p> <p>1. Missing: One potential critique of this revised answer is that it could benefit from a more detailed discussion of the role of biofilms in the pathogenesis of CSOM, as well as the potential for antibiotic resistance among the causative pathogens. Additionally, the answer could be improved by including more information on the prevention and treatment of complications associated with tubotympanic CSOM</p> <p>2. Superfluous: The answer could be improved by removing some of the repetitive language and condensing the information into more concise paragraphs.</p> <p>Search query: What are the current treatment options for biofilm-related infections in tubotympanic chronic suppurative otitis media?</p>
Step 7: Supervisor	Next: FINISH

Table 2: Process of ENTAgents handling a question. The bold texts are the revised content in the latest answer compared to the previous answer.

An example of the answers to an essay question from Llama 3.1 and ENTAgents was compared

in Table 3. The ENTAgents provided a more comprehensive answer to the question than Llama 3.1. In the pathogenesis part, the answers of ENTAgents included detailed and specific pathological processes and consequences of cholesteatoma and covered the impact on surrounding structures. In addressing the etiology of cholesteatoma, Llama 3.1 provided only a list of factors associated with the condition, whereas ENTAgents offered a detailed explanation. ENTAgents not only detailed how these factors contribute to cholesteatoma development but also discussed the different types of cholesteatoma and their specific causes. Additionally, while Llama 3.1 produced a simple list of clinical features, ENTAgents elaborated on the underlying causes of these features. It then presented a thorough response, addressing complications seen in both typical and advanced cases. In terms of cholesteatoma management, ENTAgents described not only the primary approaches and surgical techniques based on the size and location of the cholesteatoma but also mentioned the use of imaging tools to aid in management. Overall, ENTAgents provided a more comprehensive and structured response that covered all aspects of the query with detailed explanations.

Questions	What is cholesteatoma? Describe its pathogenesis, etiology, clinical features and management.	
Models	Llama 3.1-70b	ENTAgents
What is cholesteatoma?	A cholesteatoma is a type of skin cyst located in the middle ear. It is a sac filled with skin cells and other debris, which can cause destruction of the surrounding bone and tissue.	Cholesteatoma is a type of skin cyst located in the middle ear. It is characterized by the abnormal growth of skin cells within the middle ear, which can lead to the destruction of surrounding bone and tissue.
Pathogenesis	The pathogenesis of cholesteatoma involves the accumulation of skin cells in the middle ear, which can occur due to a blockage in the Eustachian tube, a perforation in the eardrum, or other factors.	The pathogenesis of cholesteatoma involves the formation of an inflamed ectopic mass of keratinizing squamous epithelium in the middle ear and mastoid bone. This can lead to the erosion of adjacent bony structures and is often associated with chronic suppurative otitis media.

Etiology	<p>The etiology of cholesteatoma can be congenital or acquired, with the latter being more common.</p> <p>Acquired cholesteatomas are often associated with chronic otitis media, Eustachian tube dysfunction, and other conditions.</p>	<p>The etiology of cholesteatoma is multifactorial and can be attributed to various factors such as chronic otitis media, eustachian tube dysfunction, and congenital abnormalities. Chronic otitis media can lead to the formation of a cholesteatoma by causing a perforation in the eardrum, which allows skin cells to enter the middle ear. Eustachian tube dysfunction can also contribute to the development of cholesteatoma by causing a buildup of mucus and debris in the middle ear, which can become infected and lead to the growth of skin cells.</p> <p>There are three main types of cholesteatoma: congenital, primary acquired, and secondary acquired. Congenital cholesteatoma is a rare condition that is present at birth and is thought to be caused by a genetic mutation. Primary acquired cholesteatoma is the most common type and is caused by a perforation in the eardrum or by the migration of skin cells into the middle ear through the eustachian tube. Secondary acquired cholesteatoma is caused by the implantation of skin cells into the middle ear through trauma or surgery.</p>

<p>Clinical Features</p>	<p>Clinical features of cholesteatoma include hearing loss, ear fullness, discharge, and vertigo.</p>	<p>The clinical features of cholesteatoma can vary depending on the size and location of the cyst. Common symptoms include hearing loss, ear fullness, and discharge. In advanced cases, cholesteatoma can cause more serious complications such as facial paralysis, vertigo, and meningitis.</p>
<p>Management</p>	<p>Management of cholesteatoma typically involves surgical removal of the cyst, as well as treatment of any underlying conditions. In some cases, antibiotics or other medications may be prescribed to manage symptoms and prevent complications.</p>	<p>The management of cholesteatoma primarily involves surgical intervention, aiming to eliminate the disease, control infection, and preserve or restore hearing. Long-term monitoring and follow-up are crucial to prevent recurrence.</p> <p>Different surgical approaches are used depending on the size and location of the cholesteatoma, including atticotomy, atticoantrostomy, or limited mastoidectomy. In cases where the cholesteatoma is present in an only hearing ear, a more conservative approach is often recommended to minimize the risk of developing a postoperative sensorineural hearing loss.</p> <p>Imaging studies, such as CT scans, can be useful in the diagnosis and management of cholesteatoma. These studies can help to identify the size and</p>

		location of the cyst, as well as any damage to surrounding tissue and bone.
--	--	---

Table 3: Comparison of the responses from ENTAgents and Llama 3.1 to an essay question.

3.3 Multiple Choice Question (MCQ)

Finally, we challenged our ENTAgents with 992 MCQs from BoardVitals, which are US board review practice questions that follow the exam content outline for US otolaryngology qualifying examinations. The MCQ question banks consist of 9 sections, each with three levels of difficulty, which are hard, moderate, and easy, and questions from subspecialties including Allergy, Endocrine, Head and Neck, Laryngology, Otolaryngology, Pediatrics, Pharmacology, Plastic and Reconstructive and Sleep. The distributions of questions in different subspecialties in the question banks are presented in Table 4.

	Allergy	Endocrine	Head & Neck	Laryngology	Otolaryngology	Pediatrics	Pharmacology	Plastic & Reconstructive	Sleep
Hard	18	21	56	24	64	28	18	99	15
Moderate	20	16	40	18	77	37	22	83	8
Easy	20	14	53	35	68	44	16	61	17
	58	51	149	77	209	109	56	243	40

Table 4: Distributions of the MCQs in 9 subspecialties of otolaryngology

The performance of ENTAgents in answering questions from all specialties is summarized in Figure 4. The results were sorted by the score of ENTAgents from lowest to highest. ENTAgents obtained scores above 70% in all specialties, with the score in Plastic and Reconstructive being the lowest, 68.4%. ENTAgents's highest score was in Allergy, which is 91.4%. The overall performance of ENTAgents was also calculated and compared to the average correct percentage of humans, obtained from the publicly available data from BoardVitals. ENTAgents had an overall performance of 75.5, 4.5% better than humans, scoring 71%.

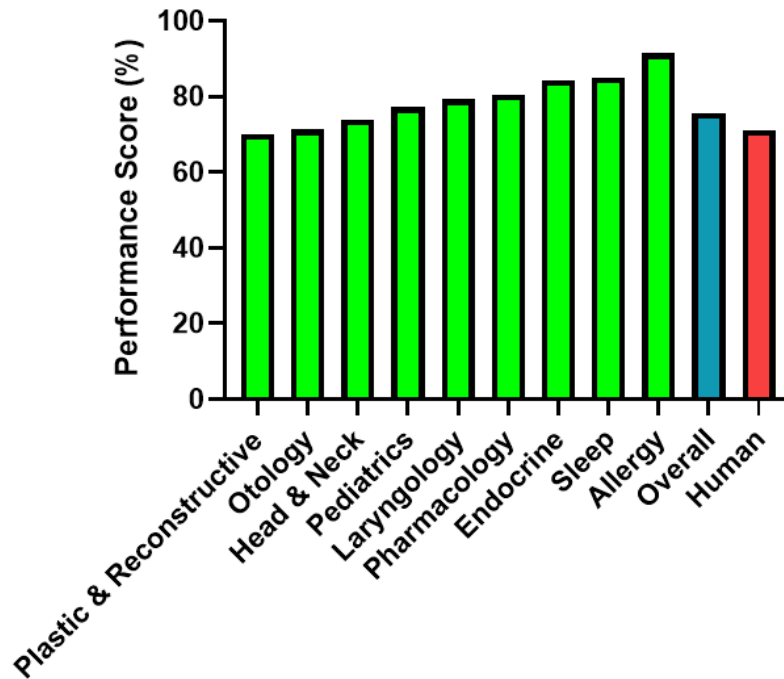


Figure 4: The scores of ENTAgent for the otolaryngology MCQ

Table 5 shows an example of the response of ENTAgents to an MCQ. Without RAG and the agents, Llama 3.1 initially chose option B as its answer. Then, the answer was considered as not thorough by ENTAgents. With the retrieval from the knowledge base, it was discovered that the actual likelihood should be 45%. The revisor agent immediately changed its choice to C, which was the correct answer. ArXiv agent was invoked, and it summarized the scholar articles it searched for about ultrasound of the nodule to its response.

<p>Example: A 35-year-old female with Graves' disease is referred for evaluation of a palpable thyroid nodule. Radioactive iodine scan shows hypofunctioning nodule. What is the likelihood of this nodule being well differentiated thyroid carcinoma? A. 10% B. 25% C. 45% D. 60% E. 75%</p>	
<p>Step 1: LLM Draft</p>	<p>Answer: The likelihood of a hypofunctioning thyroid nodule being a well-differentiated thyroid carcinoma in a patient with Graves' disease is around 20-30%. [...] Therefore, the correct answer is B. 25%.</p> <p>Reflection:</p> <ol style="list-style-type: none"> Inaccurate: The answer provided is based on general information, but it would be better to provide more specific information related to the patient's condition and the characteristics of the nodule. Moreover, the exact likelihood might vary depending on several factors such as the size and ultrasound characteristics of the nodule. Superfluous: None <p>Search query: Hypofunctioning thyroid nodule and well differentiated thyroid</p>

	carcinoma, Graves' disease and thyroid nodule cancer risk, Thyroid nodule characteristics and cancer likelihood
Step 2: RAG	[...] 52 When a palpable, hypofunctional thyroid nodule is found in a patient with Graves disease, it has about a 45% probability of being a thyroid malignancy. [...]
Step 3: Revisor	<p>Revised Answer: The likelihood of a hypofunctioning thyroid nodule being a well-differentiated thyroid carcinoma in a patient with Graves' disease is around 45%. Therefore, the correct answer is C. 45%. [...]</p> <p>Reflection:</p> <ol style="list-style-type: none"> 1. Inaccurate: The initial answer was incorrect, and it was based on general information. The revised answer is based on specific information related to the patient's condition and the characteristics of the nodule. However, it would be better to provide more information about the size and ultrasound characteristics of the nodule to give a more accurate answer. 2. Superfluous: The initial answer contained superfluous information that was removed in the revised answer. <p>Search query: [...] "Ultrasound characteristics of malignant thyroid nodules"</p>
Step 4: Supervisor	Next: ArXiv
Step 5: ArXiv Agent	<p>[...]1. "Segmentation of Ultrasound Images of Thyroid Nodule for Assisting Fine Needle Aspiration Cytology" (2012) - This paper discusses [...]</p> <p>2. "A Systematic Review on the Role of Artificial Intelligence in Sonographic Diagnosis of Thyroid Cancer: Past, Present and Future" (2020) - This systematic review presents [...]</p> <p>3. "Extracting Thyroid Nodules Characteristics from Ultrasound Reports Using Transformer-based Natural Language Processing Methods" (2023) - This study focuses [...]</p>
Step 6: Revisor	<p>Revised Answer: [...] The use of these technologies can improve the diagnostic rate of thyroid nodules and assist in the diagnosis of thyroid cancer</p> <p>Reflection:</p> <ol style="list-style-type: none"> 1. Inaccurate: [...] However, the search information has provided more context on the use of ultrasound and artificial intelligence in the diagnosis of thyroid cancer 2. Superfluous: None <p>Search query: [...] Artificial intelligence in thyroid cancer diagnosis</p>
Step 7: Supervisor	Next: FINISH

Table 5: Example of the self-correction of ENTAgents to an MCQ

4. Discussion

These results show that ENTAgents has the capability to provide comprehensive answers with the aid of reflection critiques. The reflection critiques enable ENTAgents to comment on its answers and suggest what can be improved. In answering short questions and essay questions, ENTAgents can provide the relevant additional information only and remove the abundant texts, making the answer more informative but also concise. ENTAgents provides more informative responses than other AI models, demonstrating enhanced accuracy. For the MCQ question, ENTAgents demonstrates the ability to change its option to the correct one, the Revisor examines these messages from RAG and agents to adjust its answer if needed. Utilizing agents and RAG can supplement the AI framework with up-to-date, highly specific, and detailed information, improving the accuracy and completeness of its responses. Since the RAG database contains knowledge of otolaryngology, ENTAgents is therefore able to draw from verified information and provides accurate answers for this field. The multi-agent system is critical for complex queries, which requires a diverse range of answers and the latest information. The agents can search websites and the literature database to find up-to-date developments related to the question. This approach can effectively address essay questions, allowing inquirers to gain insights into recent advancements and research developments in otolaryngology rather than relying solely on static, pre-existing information from RAG. Thus, our framework offers three distinct advantages over the other LLM agent applications. The first one is extensive search capabilities. For example, ENTAgents draws information from both the RAG knowledge base and external sources through the use of agents. Therefore, it does not require the continuous update of the pertinent sources from the field. This enhances the accuracy, completeness and timeliness of its responses, offering ENTAgents the ability to address a wide range of questions, from fundamental concepts to the latest advancements. The second is self-correction. This means that the reflection framework allows ENTAgents to evaluate their responses according to linguistic feedback. As the use of agents is iterative, the framework ensures that agents are leveraged only when flaws or inaccuracies are detected in the response. Furthermore, it removes superfluous information, ensuring that the final answer is both comprehensive and free of redundancies. Finally, ENTAgents is ease of use. Since the RAG knowledge base is built by external sources and ENTAgents's ability to self-correct derived from its own reflective critiques, generated through prompting alone, fine-tuning is not required within our framework. The reflection critiques and search queries are provided along with the answers so that users can understand clearly the generation of the response of

ENTAgents, enhancing its explainability. There are many opportunities for ENTAagents to be utilized across different fields or situations; adjustments to the knowledge base and the reflection prompts only allow ENTAagents to provide its response according to other criteria as needed. In addition, the model we used, Llama 3.1, is an open source LLM model, which offers full access and capability to develop advanced solutions, unlike other proprietary models, and hence we can modify ENTAagents easily for future applications.

Our work illustrates the potential applications of ENTAagents, including medical education, patient education, and clinical support. First, ENTAagents can be leveraged to provide medical education to students effectively. With the ability to retrieve solid knowledge from guidelines, books or academic papers in the knowledge base in a second, the learning process can be streamlined, and students can absorb concentrated information efficiently. ENTAagents can also be used in revision for medical students, given its ability to respond to various types of questions comprehensively. Healthcare professionals can also benefit from learning about the advancements in their field. The latest literature and academic symposiums can be found by the agents, and they will be summarized to the users. Professionals can then learn about cutting-edge technology and recent developments in the field. On top of that, the public can be educated by ENTAagents. The flexibility of ENTAagents to change its response makes it easy to explain difficult medical terms or knowledge to the layman, and it can be developed into the mobile application. The patients can thus easily access ENTAagents to have a better understanding of precautions and treatments of the diseases. Lastly, the accessibility of ENTAagents to various sources of scholarly articles provides insights to clinicians to handle rare cases and assist them in decision-making. Since the explainable concerns can be dampened with the reflection critiques provided, physicians can understand the workflow of ENTAagents and be assured to take the recommendations of ENTAagents.

Although our framework excels in generating comprehensive responses to users, the latency of ENTAagents needs to be improved. ENTAagents consumes a lot of time searching the information and revising the answers by the agents. Thus, it will not be a user-friendly application to wait such a long time for its response, further improvement in its speed is paramount. Moreover, the responses of ENTAagents deviated from the prescribed format several times. While the response structure is organized into distinct sections such as answer, reflective critique, and search query, the agent occasionally produces reflective content as an answer, resulting in wrong outputs and altering the workflow. Prompting techniques should be refined

to ensure consistent adherence to the designated response format. Lastly, ENTAgents focuses on integrating verbal reinforcement learning within a multi-agent system to deliver comprehensive responses. Therefore, it lacks multimodal capabilities to store visual or audio information within its knowledge base and respond to queries beyond text-based inputs. Despite these limitations, the ENTAgents presents an advanced framework capable of generating accurate and thorough responses, demonstrating significant potential for diverse applications.

Our future research will first emphasize enhancing the multimodal capabilities of ENTAgents to enable the interpretation of visual data, particularly medical images sourced from both the RAG and the agents, and provide visual explanations to the users. As a result, ENTAgents will be better equipped to tackle complex medical cases across different modalities, offering clearer and more comprehensible responses for users. In addition, we aim to scale our knowledge database to encompass diverse entities, including diseases and conditions, imaging data, anatomical features, and more. This data will be structured well and interlinked to organize a healthcare knowledge graph for ENTAgents. With this approach, ENTAgents will deliver higher quality and more relevant answers effectively.

Conflicts of interest

There are no conflicts to declare.

Data availability

Acknowledgements

We gratefully acknowledge the funding provided by the Research Grant Council of Hong Kong, General Research Fund (Ref No. 14211223).

References

1. Gebreab SA, Salah K, Jayaraman R, et al. LLM-based framework for Administrative Task Automation in Healthcare. 2024 12th International Symposium on Digital Forensics and Security (ISDFS). 2023 Apr 29;1–7. DOI:10.1109/isdfs60797.2024.10527275
2. Goel A, Gueta A, Omry Gilon et al. LLMs Accelerate Annotation for Medical Information Extraction. arXiv (Cornell University). 2023 Dec 4; DOI:10.48550/arXiv.2312.02296
3. Panagoulas, Dimitrios P, Virvou M, Tsihrintzis GA. Evaluating LLM -- Generated Multimodal Diagnosis from Medical Images and Symptom Analysis. arXiv (Cornell University). 2024 Jan 28; DOI:10.48550/arXiv.2402.01730
4. Wang S, Zhao Z, Ouyang X, Wang Q, Shen D. ChatCAD: Interactive Computer-Aided Diagnosis on Medical Image using Large Language Models. 2023 Feb 14; DOI: 10.48550/arXiv.2302.07257
5. Kim JK, Chua M, Rickard M, Lorenzo A. Chatgpt and Large Language Model (LLM) Chatbots: The current state of acceptability and a proposal for guidelines on utilization in Academic Medicine. *Journal of Pediatric Urology*. 2023 Sept 26;19(5):598–604. DOI:10.1016/j.jpuro.2023.05.018
6. Cascella M, Montomoli J, Bellini V, Bignami E. Evaluating the feasibility of CHATGPT in Healthcare: An analysis of multiple clinical and research scenarios. *Journal of Medical Systems*. 2023 Mar 4 ;47(1). DOI:10.1007/s10916-023-01925-4
7. Thirunavukarasu AJ, Ting DS, Elangovan K, Gutierrez L, Tan TF, Ting DS. Large language models in medicine. *Nature Medicine*. 2023 Jul 17;29(8):1930–40. DOI:10.1038/s41591-023-02448-8
8. Hallucination Leaderboard. 2024 Nov 6. Available from: <https://github.com/vectara/hallucination-leaderboard>
9. Li J, Yuan Y, Zhang Z. Enhancing LLM Factual Accuracy with RAG to Counter Hallucinations: A Case Study on Domain-Specific Queries in Private Knowledge-Bases. arXiv.org. 2024. DOI:10.48550/arXiv.2403.10446
10. Shi L, Kazda M, Sears B, Shropshire N, Puri R. Ask-EDA: A Design Assistant Empowered by LLM, Hybrid RAG and Abbreviation De-hallucination. arXiv (Cornell University). 2024 Jun 3. DOI:10.48550/arXiv.2406.06575
11. Niu C, Wu Y, Zhu J, et al. Ragtruth: A hallucination corpus for developing trustworthy retrieval-augmented language models. *Proceedings of the 62nd Annual Meeting of the Association for Computational Linguistics (Volume 1: Long Papers)*. 2024 Aug;10862–78.

DOI:10.18653/v1/2024.acl-long.585

12. Alkhalaf M, Yu P, Yin M, Deng C. Applying generative AI with retrieval augmented generation to summarize and extract key clinical information from electronic health records. *Journal of Biomedical Informatics*. 2024 Aug;156:104662. DOI:10.1016/j.jbi.2024.104662
13. Miao J, Thongprayoon C, Suppadungsuk S, Garcia Valencia OA, Cheungpasitporn W. Integrating retrieval-augmented generation with large language models in nephrology: Advancing Practical Applications. *Medicina*. 2024 Mar 8;60(3):445. DOI:10.3390/medicina60030445
14. Long C, Subburam D, Lowe K et al. Chatent: Augmented large language model for expert knowledge retrieval in otolaryngology - head and Neck Surgery. *American Academy of Otolaryngology—Head and Neck Surgery*. 2023 Jun 19; DOI:10.2139/ssrn.4571725
15. 1. Unlu O, Shin J, Maily CJ, Oates MF, Tucci MR, Varugheese M, et al. Retrieval-augmented generation-enabled GPT-4 for clinical trial screening. *NEJM AI*. 2024 Jun 27;1(7). DOI:10.1056/aioa2400181
16. Kaur D, Uslu S, Durresi M, Durresi A. LLM-based agents utilized in a trustworthy artificial conscience model for controlling AI in medical applications. *Lecture Notes on Data Engineering and Communications Technologies*. 2024 Apr 10;198–209. DOI:10.1007/978-3-031-57870-0_18
17. Mahyar Abbasian, Azimi I, Rahmani AM, Jain R. Conversational Health Agents: A Personalized LLM-Powered Agent Framework. *arXiv (Cornell University)*. 2023 Oct 3. DOI: 10.48550/arXiv.2310.02374
18. Pandey HG, Amod A, Kumar S. Advancing Healthcare Automation: Multi-agent system for medical necessity justification. *Proceedings of the 23rd Workshop on Biomedical Natural Language Processing*. 2024 Aug 16;39–49. DOI:10.18653/v1/2024.bionlp-1.4
19. Tang X, Zou A, Zhang Z, et al. MedAgents: Large language models as collaborators for Zero-Shot Medical Reasoning. *Findings of the Association for Computational Linguistics ACL 2024*. 2024 Jun 4;599–621. DOI:10.18653/v1/2024.findings-acl.33
20. Schmidgall S, Ziaei R, Harris C, Reis E, Jopling J, Moor M. AgentClinic: a multimodal agent benchmark to evaluate AI in simulated clinical environments. *arXiv (Cornell University)*. 2024 May 13; DOI:10.48550/arXiv.2405.07960
21. Alghamdi HM, Mostafa A. Towards reliable healthcare LLM agents: A case study for pilgrims during Hajj. *Information*. 2024 Jun 26;15(7):371. DOI:10.3390/info15070371
22. Borkowski A, Alon Ben-Ari. Muli-Agent AI Systems in Healthcare: Technical and Clinical Analysis. 2024 Oct 2. DOI:10.20944/preprints202410.0182.v1

23. Li J, Wang S, Zhang M, et al. Agent Hospital: A Simulacrum of Hospital with Evolvable Medical Agents. arXiv.org. 2024 May 5. DOI: 10.48550/arXiv.2405.02957
24. Hiesinger W, Zakka C, Chaurasia A, et al. Almanac: Retrieval-augmented language models for Clinical Medicine. NEJM AI. 2024 Jan 25;1(2). DOI:10.1056/AIoa2300068
25. Shinn N, Labash B, Gopinath A. Reflexion: Language Agents with Verbal Reinforcement Learning. arXiv (Cornell University). 2023 Mar 20;1(1). DOI: 10.48550/arXiv.2303.11366

Supplementary Material 1: Used documents for RAG knowledge base

Rosenfeld RM, Schwartz SR, Cannon CR, et al. Clinical practice guideline: acute otitis externa executive summary. *Otolaryngol Head Neck Surg.* 2014;150(2):161-168. DOI:10.1177/0194599813517659

Rosenfeld RM, Schwartz SR, Cannon CR, et al. Clinical practice guideline: acute otitis externa [published correction appears in *Otolaryngol Head Neck Surg.* 2014 Mar;150(3):504]. *Otolaryngol Head Neck Surg.* 2014;150(1 Suppl):S1-S24. DOI:10.1177/0194599813517083

Almeida JR de, Guyatt GH, Sud S, et al. Management of Bell palsy: clinical practice guideline. *CMAJ.* 2014;186(12):917-922. DOI:[10.1503/cmaj.131801](https://doi.org/10.1503/cmaj.131801)

Bhattacharyya N, Baugh RF, Orvidas L, et al. Clinical practice guideline: benign paroxysmal positional vertigo. *Otolaryngol Head Neck Surg.* 2008;139(5 Suppl 4):S47-S81. DOI:10.1016/j.otohns.2008.08.022

Califano L, Salafia F, Mazzone S, Melillo MG, Califano M. Anterior canal BPPV and apogeotropic posterior canal BPPV: two rare forms of vertical canalolithiasis. *Acta Otorhinolaryngol Ital.* 2014;34(3):189-197.

Roland PS, Smith TL, Schwartz SR, et al. Clinical practice guideline: cerumen impaction. *Otolaryngol Head Neck Surg.* 2008;139(3 Suppl 2):S1-S21. DOI:10.1016/j.otohns.2008.06.026

Stachler RJ, Chandrasekhar SS, Archer SM, et al. Clinical practice guideline: sudden hearing loss. *Otolaryngology–Head and Neck Surgery.* 2012;146(3_suppl):S1-S35. DOI:10.1177/0194599812436449

Basura GJ, Adams ME, Monfared A, et al. Clinical practice guideline: Ménière's Disease executive summary.

Otolaryngology–Head and Neck Surgery. 2020;162(4):415-434. DOI:[10.1177/0194599820909439](https://doi.org/10.1177/0194599820909439)

Bhattacharyya N, Gubbels SP, Schwartz SR, et al. Clinical practice guideline: benign paroxysmal positional vertigo (Update). Otolaryngol Head Neck Surg. 2017;156(3_suppl):S1-S47.

DOI:[10.1177/0194599816689667](https://doi.org/10.1177/0194599816689667)

Chandrasekhar SS, Tsai Do BS, Schwartz SR, et al. Clinical practice guideline: sudden hearing loss (update) executive summary. Otolaryngol Head Neck Surg. 2019;161(2):195-210. DOI:[10.1177/0194599819859883](https://doi.org/10.1177/0194599819859883)

Tunkel DE, Bauer CA, Sun GH, et al. Clinical practice guideline: tinnitus executive summary. Otolaryngol Head Neck Surg. 2014;151(4):533-541. DOI:[10.1177/0194599814547475](https://doi.org/10.1177/0194599814547475)

Lempert T, Olesen J, Furman J, et al. Vestibular migraine: diagnostic criteria. J Vestib Res. 2012;22(4):167-172. DOI:[10.3233/VES-2012-0453](https://doi.org/10.3233/VES-2012-0453)

Laursen BB, Danstrup CS, Hoffmann S, Nørskov-Lauritsen N, Christensen ALB, Ovesen T. The effect of pneumococcal conjugate vaccines on incidence and microbiology associated with complicated acute otitis media. International Journal of Pediatric Otorhinolaryngology. 2017;101:249-253.

DOI:[10.1016/j.ijporl.2017.07.002](https://doi.org/10.1016/j.ijporl.2017.07.002)

Nieminen TA, Kivekäs I, Artama M, Nohynek H, Kujansivu J, Hovi P. Sudden hearing loss following vaccination against COVID-19. JAMA Otolaryngology–Head & Neck Surgery. 2023;149(2):133-140.

DOI:[10.1001/jamaoto.2022.4154](https://doi.org/10.1001/jamaoto.2022.4154)

Yanir Y, Doweck I, Shibli R, Najjar-Debbiny R, Saliba W. Association between the BNT162b2 messenger RNA COVID-19 vaccine and the risk of sudden sensorineural hearing loss. JAMA Otolaryngology–Head & Neck Surgery. 2022;148(4):299-306. DOI:[10.1001/jamaoto.2021.4278](https://doi.org/10.1001/jamaoto.2021.4278)

Coelho DH, Lalwani AK. Medical management of Ménière’s Disease. The Laryngoscope.

2008;118(6):1099-1108. DOI:[10.1097/MLG.0b013e31816927f0](https://doi.org/10.1097/MLG.0b013e31816927f0)

Hadjipanayis CG, Carlson ML, Link MJ, et al. Congress of Neurological Surgeons systematic review and

evidence-based guidelines on surgical resection for the treatment of patients with vestibular schwannomas.

Neurosurgery. 2018;82(2):E40. DOI:[10.1093/neuros/nyx512](https://doi.org/10.1093/neuros/nyx512)

Tunkel DE, Bauer CA, Sun GH, et al. Clinical practice guideline: tinnitus executive summary.

Otolaryngology–Head and Neck Surgery. 2014;151(4):533-541. DOI:[10.1177/0194599814547475](https://doi.org/10.1177/0194599814547475)

Schwartz SR, Magit AE, Rosenfeld RM, et al. Clinical practice guideline (update): earwax (cerumen impaction) executive summary. Otolaryngology–Head and Neck Surgery. 2017;156(1):14-29.

DOI:[10.1177/0194599816678832](https://doi.org/10.1177/0194599816678832)

Tucci DL, McCoul ED, Rosenfeld RM, et al. Clinical consensus statement: balloon dilation of the eustachian tube. Otolaryngology–Head and Neck Surgery. 2019;161(1):6-17. DOI:[10.1177/0194599819848423](https://doi.org/10.1177/0194599819848423)

Haugen BR, Alexander EK, Bible KC, et al. 2015 American Thyroid Association management guidelines for adult patients with thyroid nodules and differentiated thyroid cancer. Thyroid. 2016;26(1):1-133.

DOI:[10.1089/thy.2015.0020](https://doi.org/10.1089/thy.2015.0020)

Wells SA Jr, Asa SL, Dralle H, et al. Revised American Thyroid Association guidelines for the management of medullary thyroid carcinoma. Thyroid. 2015;25(6):567-610. DOI:10.1089/thy.2014.0335

American Thyroid Association Taskforce On Radioiodine Safety, Sisson JC, Freitas J, et al. Radiation safety in the treatment of patients with thyroid diseases by radioiodine 131I : practice recommendations of the American Thyroid Association [published correction appears in Thyroid. 2011 Jun;21(6):689]. Thyroid. 2011;21(4):335-346. DOI:10.1089/thy.2010.0403

American Thyroid Association (ATA) Guidelines Taskforce on Thyroid Nodules and Differentiated Thyroid Cancer, Cooper DS, Doherty GM, et al. Revised American Thyroid Association management guidelines for patients with thyroid nodules and differentiated thyroid cancer [published correction appears in Thyroid. 2010 Aug;20(8):942. Hauger, Bryan R [corrected to Haugen, Bryan R]] [published correction appears in Thyroid. 2010 Jun;20(6):674-5]. Thyroid. 2009;19(11):1167-1214. DOI:10.1089/thy.2009.0110

The American Thyroid Association Guidelines Task Force

on Thyroid Nodules and Differentiated Thyroid Cancer, Haugen BR, Alexander EK, Bible KC, et al. 2015

American Thyroid Association management guidelines for adult patients with thyroid nodules and

differentiated thyroid cancer. *Thyroid*. 2016;26(1):1-133. DOI: 10.1089/thy.2015.0020

Wells SA Jr, Asa SL, Dralle H, et al. Revised American Thyroid Association guidelines for the management

of medullary thyroid carcinoma. *Thyroid*. 2015;25(6):567-610. DOI:10.1089/thy.2014.0335

Bible KC, Kebebew E, Brierley J, et al. 2021 American Thyroid Association guidelines for management of

patients with anaplastic thyroid cancer: American Thyroid Association Anaplastic Thyroid Cancer

Guidelines Task Force. *Thyroid*. 2021;31(3):337-386. DOI:[10.1089/thy.2020.0944](https://doi.org/10.1089/thy.2020.0944)

van Dijk SPI, Coerts HI, Gunput STG, et al. Assessment of radiofrequency ablation for papillary

microcarcinoma of the thyroid: A systematic review and meta-analysis. *JAMA Otolaryngology–Head &*

Neck Surgery. 2022;148(4):317-325. DOI:[10.1001/jamaoto.2021.4381](https://doi.org/10.1001/jamaoto.2021.4381)

Alexander EK, Pearce EN, Brent GA, et al. 2017 Guidelines of the American Thyroid Association for the

diagnosis and management of thyroid disease during pregnancy and the postpartum. *Thyroid*.

2017;27(3):315-389. DOI:[10.1089/thy.2016.0457](https://doi.org/10.1089/thy.2016.0457)

Chandrasekhar SS, Randolph GW, Seidman MD, et al. Clinical practice guideline: improving voice outcomes

after thyroid surgery. *Otolaryngol Head Neck Surg*. 2013;148(6 Suppl):S1-S37.

DOI:10.1177/0194599813487301

Tunkel DE, Anne S, Payne SC, et al. Clinical practice guideline: nosebleed (epistaxis) executive summary.

Otolaryngology–Head and Neck Surgery. 2020;162(1):8-25. DOI:[10.1177/0194599819889955](https://doi.org/10.1177/0194599819889955)

Zidar N, Gale N. Update from the 5th Edition of the World Health Organization classification of head and

neck tumors: hypopharynx, Larynx, trachea and parapharyngeal space. *Head and Neck Pathol*.

2022;16(1):31-39. DOI:[10.1007/s12105-021-01405-6](https://doi.org/10.1007/s12105-021-01405-6)

Cibas ES, Ali SZ. The 2017 Bethesda system for reporting thyroid cytopathology. *Thyroid*.

2017;27(11):1341-1346. DOI:[10.1089/thy.2017.0500](https://doi.org/10.1089/thy.2017.0500)

Zhang SL, Ng HW. Primary thrombolysis for free flap surgery in head and neck reconstruction: a case report and review. *Arch Plast Surg*. 2021;48(5):511-517. DOI:[10.5999/aps.2021.00171](https://doi.org/10.5999/aps.2021.00171)

Seethala RR, Baloch ZW, Barletta JA, et al. Noninvasive follicular thyroid neoplasm with papillary-like nuclear features: a review for pathologists. *Mod Pathol*. 2018;31(1):39-55.

DOI:[10.1038/modpathol.2017.130](https://doi.org/10.1038/modpathol.2017.130)

Robbins KT, Clayman G, Levine PA, et al. Neck dissection classification update: revisions proposed by the American Head and Neck Society and the American Academy of Otolaryngology-Head and Neck Surgery.

Arch Otolaryngol Head Neck Surg. 2002;128(7):751-758. DOI:[10.1001/archotol.128.7.751](https://doi.org/10.1001/archotol.128.7.751)

Maghami E, Ismaila N, Alvarez A, et al. Diagnosis and management of squamous cell carcinoma of unknown primary in the head and neck: ASCO Guideline. *JCO*. 2020;38(22):2570-2596.

DOI:[10.1200/JCO.20.00275](https://doi.org/10.1200/JCO.20.00275)

Robbins KT, Shaha AR, Medina JE, et al. Consensus statement on the classification and terminology of neck dissection. *Archives of Otolaryngology-Head & Neck Surgery*. 2008;134(5):536-538.

DOI:[10.1001/archotol.134.5.536](https://doi.org/10.1001/archotol.134.5.536)

Dellon ES, Gonsalves N, Hirano I, et al. ACG clinical guideline: Evidenced based approach to the diagnosis and management of esophageal eosinophilia and eosinophilic esophagitis (EoE). *Am J Gastroenterol*.

2013;108(5):679-693. DOI:[10.1038/ajg.2013.71](https://doi.org/10.1038/ajg.2013.71)

Stachler RJ, Francis DO, Schwartz SR, et al. Clinical practice guideline: hoarseness (dysphonia) (update)

executive summary. *Otolaryngol Head Neck Surg*. 2018;158(3):409-426. DOI:[10.1177/0194599817751031](https://doi.org/10.1177/0194599817751031)

Chandrasekhar SS, Randolph GW, Seidman MD, et al. Clinical practice guideline: improving voice outcomes after thyroid surgery. *Otolaryngol Head Neck Surg*. 2013;148(6 Suppl):S1-S37.

DOI:[10.1177/0194599813487301](https://doi.org/10.1177/0194599813487301)

O'Hara J, Stocken DD, Watson GC, et al. Use of proton pump inhibitors to treat persistent throat symptoms: multicentre, double blind, randomised, placebo controlled trial. *BMJ*. 2021;372:m4903.

DOI:[10.1136/bmj.m4903](https://doi.org/10.1136/bmj.m4903)

Cergan R, Dumitru M, Vranceanu D, Neagos A, Jeican II, Ciuluvica RC. Ultrasonography of the larynx: novel use during the SARS-CoV-2 pandemic (review). *Exp Ther Med*. 2021;21(3):273.

DOI:[10.3892/etm.2021.9704](https://doi.org/10.3892/etm.2021.9704)

Khan NC, Vukkadala N, Saxena A, Damrose EJ, Nekhendzy V, Sung CK. Safety and utility of transnasal humidified rapid-insufflation ventilatory exchange (THRIVE) for laser laryngeal surgery. *Otolaryngol--head neck surg*. Published online April 6, 2023:ohn.324. DOI:[10.1002/ohn.324](https://doi.org/10.1002/ohn.324)

Biller HF, Barnhill Jr. FR, Ogura JH, Perez CA. Hemilaryngectomy following radiation failure for carcinoma of the vocal cords. *The Laryngoscope*. 1970;80(2):249-253. DOI:[10.1288/00005537-197002000-00009](https://doi.org/10.1288/00005537-197002000-00009)

Hu A, Morrison M, Honey CR. Hemi-laryngopharyngeal spasm (HeLPS): defining a new clinical entity. *Ann Otol Rhinol Laryngol*. 2020;129(9):849-855. DOI:[10.1177/0003489420916207](https://doi.org/10.1177/0003489420916207)

Kuhn MA, Gillespie MB, Ishman SL, et al. Expert consensus statement: management of dysphagia in head and neck cancer patients. *Otolaryngol--head neck surg*. 2023;168(4):571-592. DOI:[10.1002/ohn.302](https://doi.org/10.1002/ohn.302)

Lund VJ. European Position Paper on the Anatomical Terminology of the Internal Nose and Paranasal Sinuses. 2014.

Gupta S, Lee JJ, Perrin A, et al. Efficacy and safety of saline nasal irrigation plus theophylline for treatment of COVID-19-related olfactory dysfunction: The SCENT2 Phase 2 Randomized Clinical Trial. *JAMA Otolaryngol Head Neck Surg*. 2022;148(9):830-837. DOI:[10.1001/jamaoto.2022.1573](https://doi.org/10.1001/jamaoto.2022.1573)

Bichakjian CK, Olencki T, Aasi SZ, et al. Basal cell skin cancer, version 1.2016, NCCN clinical practice guidelines in oncology. *Journal of the National Comprehensive Cancer Network*. 2016 May;14(5):574-97.
DOI:[10.6004/jnccn.2016.0065](https://doi.org/10.6004/jnccn.2016.0065)

Jozwik M, Bednarczuk K, Osierda Z. Dermatofibrosarcoma protuberans: An updated review of the literature.

Cancers. 2024 Sept 11;16(18):3124. DOI:10.3390/cancers16183124

Pfister DG, Spencer S, Brizel DM, et al. Head and neck cancers, version 1.2015. Journal of the National

Comprehensive Cancer Network. 2015 Jul;13(7):847–56. DOI:10.6004/jnccn.2015.0102

Coit DG, Thompson JA, Algazi A, et al. Melanoma, version 2.2016, NCCN clinical practice guidelines in oncology. Journal of the National Comprehensive Cancer Network. 2016 Apr;14(4):450–73.

DOI:10.6004/jnccn.2016.0051

Zaggana E, Konstantinou MP, Krasagakis GH, et al. Merkel cell carcinoma—update on diagnosis,

management and future perspectives. Cancers. 2022 Dec 23;15(1):103. DOI:10.3390/cancers15010103

Schmults CD, Blitzblau R, Aasi SZ, Alam M, Andersen JS, Baumann BC, et al. NCCN Guidelines® insights:

Squamous cell skin cancer, version 1.2022. Journal of the National Comprehensive Cancer Network. 2021

Dec;19(12):1382–94. DOI:10.6004/jnccn.2021.0059

Haddad RI, Lydiatt WM, Ball DW, Busaidy NL, Byrd D, Callender G, et al. Anaplastic thyroid carcinoma,

version 2.2015. Journal of the National Comprehensive Cancer Network. 2015 Sept;13(9):1140–50.

DOI:10.6004/jnccn.2015.0139

Wald ER, Applegate KE, Bordley C, et al. Clinical practice guideline for the diagnosis and management of

acute bacterial sinusitis in children aged 1 to 18 years. Pediatrics. 2013;132(1):e262–e280.

DOI:10.1542/peds.2013-1071

Lieberthal AS, Carroll AE, Chonmaitree T, et al. The diagnosis and management of acute otitis media.

Pediatrics. 2013;131(3):e964–e999. DOI:[10.1542/peds.2012-3488](https://doi.org/10.1542/peds.2012-3488)

Le Saux N, Robinson JL; Canadian Paediatric Society, Infectious Diseases and Immunization Committee.

Management of acute otitis media in children six months of age and older. *Paediatr Child Health*.

2016;21(1):39-50. DOI:10.1093/pch/21.1.39

American Academy of Family Physicians, American Academy of Otolaryngology-Head and Neck Surgery,

American Academy of Pediatrics Subcommittee on Otitis Media With Effusion. Otitis media with effusion.

Pediatrics. 2004;113(5):1412-1429. DOI:[10.1542/peds.113.5.1412](https://doi.org/10.1542/peds.113.5.1412)

Rosenfeld RM, Shin JJ, Schwartz SR, et al. Clinical practice guideline: otitis media with effusion executive summary (update). *Otolaryngology–Head and Neck Surgery*. 2016;154(2):201-214.

DOI:10.1177/0194599815624407

Roland PS, Rosenfeld RM, Brooks LJ, et al. Clinical practice guideline: polysomnography for sleep-disordered breathing prior to tonsillectomy in children. *Otolaryngol Head Neck Surg*. 2011;145(1 Suppl):S1-

S15. DOI:10.1177/0194599811409837

Baugh RF, Archer SM, Mitchell RB, et al. Clinical practice guideline: tonsillectomy in children. *Otolaryngol Head Neck Surg*. 2011;144(1 Suppl):S1-S30. DOI:10.1177/0194599810389949

Mitchell RB, Archer SM, Ishman SL, et al. Clinical practice guideline: tonsillectomy in children (update)- executive summary. *Otolaryngol Head Neck Surg*. 2019;160(2):187-205. DOI:10.1177/0194599818807917

Rosenfeld RM, Schwartz SR, Pynnonen MA, et al. Clinical practice guideline: tympanostomy tubes in children--executive summary. *Otolaryngol Head Neck Surg*. 2013;149(1):8-16.

DOI:10.1177/0194599813490141

Rosenfeld RM, Tunkel DE, Schwartz SR, et al. Executive summary of clinical practice guideline on

tympanostomy tubes in children (update). *Otolaryngol Head Neck Surg.* 2022;166(2):189-206.

DOI:10.1177/01945998211065661

Joint Committee on Infant Hearing. Year 2007 Position Statement: Principles and guidelines for early hearing detection and intervention programs. *Pediatrics.* 2007;120(4):898-921. DOI:[10.1542/peds.2007-2333](https://doi.org/10.1542/peds.2007-2333)

van de Berg R, Widdershoven J, Bisdorff A, et al. Vestibular migraine of childhood and recurrent vertigo of childhood: diagnostic criteria consensus document of the Committee for the Classification of Vestibular Disorders of the Bárány Society and the International Headache Society. *J Vestib Res.* 2021;31(1):1-9.

DOI:10.3233/VES-200003

Francis GL, Waguespack SG, Bauer AJ, et al. Management guidelines for children with thyroid nodules and differentiated thyroid cancer. *Thyroid.* 2015;25(7):716-759. DOI:[10.1089/thy.2014.0460](https://doi.org/10.1089/thy.2014.0460)

Baldassari CM, Lam DJ, Ishman SL, et al. Expert consensus statement: pediatric drug-induced sleep endoscopy. *Otolaryngol Head Neck Surg.* 2021;165(4):578-591. DOI:[10.1177/0194599820985000](https://doi.org/10.1177/0194599820985000)

Ishman SL, Maturo S, Schwartz S, et al. Expert consensus statement: management of pediatric persistent obstructive sleep apnea after adenotonsillectomy. *Otolaryngol--head neck surg.* 2023;168(2):115-130.

DOI:[10.1002/ohn.159](https://doi.org/10.1002/ohn.159)

Messner AH, Walsh J, Rosenfeld RM, et al. Clinical consensus statement: ankyloglossia in children.

Otolaryngol--head neck surg. 2020;162(5):597-611. DOI:[10.1177/0194599820915457](https://doi.org/10.1177/0194599820915457)

The Joint Committee on Infant Hearing. Year 2019 position statement: principles and guidelines for early hearing detection and intervention programs. *JEHDI.* 2019;4(2):1-44.

Desrosiers M, Evans GA, Keith PK, et al. Canadian clinical practice guidelines for acute and chronic rhinosinusitis. *Allergy Asthma Clin Immunol.* 2011;7(1):2. Published 2011 Feb 10. DOI:10.1186/1710-1492-

Rosenfeld RM, Piccirillo JF, Chandrasekhar SS, et al. Clinical practice guideline (update): adult sinusitis executive summary. *Otolaryngol Head Neck Surg.* 2015;152(4):598-609. DOI:10.1177/0194599815574247

Seidman MD, Gurgel RK, Lin SY, et al. Clinical practice guideline: allergic rhinitis. *Otolaryngol Head Neck Surg.* 2015;152(1 Suppl):S1-S43. DOI:10.1177/0194599814561600

Brozek JL, Bousquet J, Baena-Cagnani CE, et al. Allergic rhinitis and its impact on asthma (ARIA) guidelines: 2010 revision. *J Allergy Clin Immunol.* 2010;126(3):466-476. DOI:10.1016/j.jaci.2010.06.047

Fokkens WJ, Lund VJ, Hopkins C, et al. European Position Paper on rhinosinusitis and nasal polyps 2020. *Rhinology.* 2020;58(Suppl S29):1-464. Published 2020 Feb 20. DOI:10.4193/Rhin20.600

Kaplan A. Canadian guidelines for acute bacterial rhinosinusitis: clinical summary. *Can Fam Physician.* 2014;60(3):227-234.

Wormald PJ, Hoseman W, Callejas C, et al. The international frontal sinus anatomy classification (IFAC) and classification of the extent of endoscopic frontal sinus surgery (EFSS). *Int Forum Allergy Rhinol.* 2016;6(7):677-696. DOI:10.1002/alr.21738

Orlandi RR, Kingdom TT, Smith TL, et al. International consensus statement on allergy and rhinology: rhinosinusitis 2021 [published correction appears in *Int Forum Allergy Rhinol.* 2022 Jul;12(7):974]. *Int Forum Allergy Rhinol.* 2021;11(3):213-739. DOI:10.1002/alr.22741

Butowt R, Bilinska K, Bartheld CS von. Olfactory dysfunction in COVID-19: new insights into the underlying mechanisms. *Trends in Neurosciences.* 2023;46(1):75-90. DOI:[10.1016/j.tins.2022.11.003](https://doi.org/10.1016/j.tins.2022.11.003)

Grayson JW, Cavada M, Harvey RJ. Clinically relevant phenotypes in chronic rhinosinusitis. *J Otolaryngol*

Head Neck Surg. 2019;48(1):23. DOI:[10.1186/s40463-019-0350-y](https://doi.org/10.1186/s40463-019-0350-y)

Piccirillo JF, Payne SC, Rosenfeld RM, et al. Clinical consensus statement: balloon dilation of the sinuses.

Otolaryngol Head Neck Surg. 2018;158(2):203-214. DOI:[10.1177/0194599817750086](https://doi.org/10.1177/0194599817750086)

Thamboo A, Kilty S, Witterick I, et al. Canadian Rhinology Working Group consensus statement: biologic therapies for chronic rhinosinusitis. J of Otolaryngol - Head & Neck Surg. 2021;50(1):15.

DOI:[10.1186/s40463-021-00493-2](https://doi.org/10.1186/s40463-021-00493-2)

Pinkiewicz M, Dorobisz K, Zatoński T. A comprehensive approach to facial reanimation: a systematic review. J Clin Med. 2022;11(10):2890. DOI:[10.3390/jcm11102890](https://doi.org/10.3390/jcm11102890)

Anne S, Mims JW, Tunkel DE, et al. Clinical Practice Guideline: Opioid prescribing for analgesia after common otolaryngology operations-executive summary. Otolaryngol Head Neck Surg. 2021;164(4):687-703.

DOI:[10.1177/0194599821996303](https://doi.org/10.1177/0194599821996303)

American Society of Anesthesiologists Task Force on Operating Room Fires, Caplan RA, Barker SJ, et al.

Practice advisory for the prevention and management of operating room fires. Anesthesiology.

2008;108(5):786-972. DOI:[10.1097/01.anes.0000299343.87119.a9](https://doi.org/10.1097/01.anes.0000299343.87119.a9)

Wu Q, Wang X, Liang G, et al. Advances in image-based artificial intelligence in otorhinolaryngology-head and neck surgery: a systematic review. Otolaryngol-head neck surg. Published online June 8, 2023:ohn.391.

DOI:[10.1002/ohn.391](https://doi.org/10.1002/ohn.391)

Bur AM, Shew M, New J. Artificial intelligence for the otolaryngologist: a state of the art review.

Otolaryngol-head neck surg. 2019;160(4):603-611. DOI:[10.1177/0194599819827507](https://doi.org/10.1177/0194599819827507)

Gölaç H, Atalık G, Özcebe E, Gündüz B, Karamert R, Kemalöglü YK. Vocal outcomes after COVID-19 infection: acoustic voice analyses, durational measurements, self-reported findings, and auditory-perceptual evaluations. Eur Arch Otorhinolaryngol. 2022;279(12):5761-5769. DOI:[10.1007/s00405-022-07468-7](https://doi.org/10.1007/s00405-022-07468-7)

Sommer DD, Cote D, McHugh T, et al. Revised recommendations from the CSO-HNS taskforce on

performance of tracheotomy during the COVID-19 pandemic – what a difference a year makes. *J of Otolaryngol - Head & Neck Surg.* 2021;50(1):59. DOI:[10.1186/s40463-021-00531-z](https://doi.org/10.1186/s40463-021-00531-z)

Position Statements. CSOHNS. Published June 29, 2023. Accessed June 29, 2023. <https://www.entcanada.org/cso/position-statements/>

Otolaryngology. Choosing Wisely Canada. Published June 29, 2023. Accessed June 29, 2023. <https://choosingwiselycanada.org/recommendation/otolaryngology/>

John R. de Almeida, Gordon H. Guyatt, Sachin Sud, et al. Management of Bell palsy: clinical practice guideline. *CMAJ.* 2014;186(12):917. DOI:[10.1503/cmaj.131801](https://doi.org/10.1503/cmaj.131801)

Almeida JR de, Guyatt GH, Sud S, et al. Management of Bell palsy: clinical practice guideline. *CMAJ.* 2014;186(12):917-922. DOI:[10.1503/cmaj.131801](https://doi.org/10.1503/cmaj.131801)

Baugh RF, Basura GJ, Ishii LE, et al. Clinical practice guideline: Bell's Palsy executive summary. *Otolaryngol Head Neck Surg.* 2013;149(5):656-663. DOI:[10.1177/0194599813506835](https://doi.org/10.1177/0194599813506835)

Bilezikian JP, Brandi ML, Eastell R, et al. Guidelines for the management of asymptomatic primary hyperparathyroidism: summary statement from the fourth international workshop. *J Clin Endocrinol Metab.* 2014;99(10):3561-3569. DOI:[10.1210/jc.2014-1413](https://doi.org/10.1210/jc.2014-1413)

Sauve L, Forrester AM, Top KA. Group A streptococcal pharyngitis: a practical guide to diagnosis and treatment. *Paediatrics & Child Health.* 2021;26(5):319-319. DOI:[10.1093/pch/pxab025](https://doi.org/10.1093/pch/pxab025)

Fitzgerald N, Hussain S, Memon S, et al. Evaluating clinical and cost impacts of achieving 90% HPV vaccination rate against cervical cancer in Canada using the OncoSim cancer simulation model. *JGO.* 2018;4(Supplement 2):21s-21s. DOI:[10.1200/jgo.18.27600](https://doi.org/10.1200/jgo.18.27600)

Khurshid M, Ansari I, Ahmad H, et al. Development of facial palsy following COVID-19 vaccination: A systematic review. *Ann Med Surg (Lond).* 2022;82:104758. DOI:[10.1016/j.amsu.2022.104758](https://doi.org/10.1016/j.amsu.2022.104758)

Irwin RS, French CL, Chang AB, et al. Classification of cough as a symptom in adults and management

algorithms. *Chest*. 2018;153(1):196-209. DOI:[10.1016/j.chest.2017.10.016](https://doi.org/10.1016/j.chest.2017.10.016)

Allori AC, Mulliken JB, Meara JG, Shusterman S, Marcus JR. Classification of cleft lip/palate: then and now. *The Cleft Palate-Craniofacial Journal*. 2017;54(2):175-188. DOI:[10.1597/14-080](https://doi.org/10.1597/14-080)

Kahrilas PJ, Altman KW, Chang AB, et al. Chronic cough due to gastroesophageal reflux in adults: CHEST guideline and expert panel report. *Chest*. 2016;150(6):1341-1360. DOI:[10.1016/j.chest.2016.08.1458](https://doi.org/10.1016/j.chest.2016.08.1458)

Classification and approach to patients with functional voice disorders. DOI:[10.1177/000348948209100409](https://doi.org/10.1177/000348948209100409)

Canadian Headache Society Guideline for Migraine Prophylaxis: Supplement 2. *Canadian Journal of Neurological Sciences*. 2012;39(S2):i-63. DOI:[10.1017/S0317167100015109](https://doi.org/10.1017/S0317167100015109)

Table 1: Short questions and answers from ENTAgent

Questions	ENTAgent
<p>A 6-year-old boy is referred to you by his family physician. He has had 3 episodes of painful swelling of the right parotid gland over the past 18 months. Each episode lasted 5 to 7 days and has been accompanied by a low grade fever. Two of the episodes were managed with amoxicillin. One of the episodes was not treated with antibiotics, and spontaneously resolved. There was complete resolution of symptoms between episodes. The child is otherwise healthy.</p> <p>a. What is the MOST likely diagnosis?</p> <p>b. List FOUR treatment measures that are MOST commonly employed in the management of this condition.</p>	<p>Based on the symptoms presented, the most likely diagnosis is recurrent parotitis, which is a chronic inflammation of the parotid gland. This condition is often seen in children and can be caused by various factors, including bacterial or viral infections, salivary duct stones, or anatomical abnormalities. The treatment measures commonly employed in the management of this condition include:</p> <ol style="list-style-type: none"> 1) antibiotics for bacterial infections, 2) sialogogues to stimulate salivary flow, 3) analgesics to manage pain, and 4) surgical intervention for complications such as abscesses or stones. <p>Additionally, sialendoscopy has been shown to be an effective treatment for juvenile recurrent parotitis in children, as it allows for a minimally invasive approach to diagnose and treat anatomical abnormalities, remove small stones, and potentially improve outcomes with ductal corticosteroid infusion.</p> <p>Based on the symptoms presented, the most likely diagnosis is recurrent parotitis. Recurrent parotitis is a condition characterized by recurring episodes of inflammation of the parotid gland, often</p>

	<p>accompanied by pain, swelling, and fever. The fact that the child has experienced three episodes of painful swelling of the right parotid gland over the past 18 months, with complete resolution of symptoms between episodes, supports this diagnosis.</p> <p>Four common treatment measures employed in the management of recurrent parotitis include:</p> <ol style="list-style-type: none">1) antibiotics to treat bacterial infections,2) analgesics to manage pain and discomfort,3) warm compresses to reduce swelling and promote drainage, and4) sialogogues to stimulate saliva production and help clear the ducts. <p>The specific antibiotic treatment options for recurrent parotitis in children include the use of intravenous (IV) hydration, analgesics, and 7 to 10 days of IV antibiotics. For community-acquired infections, ampicillin-sulbactam or clindamycin are recommended. For hospital-acquired infections, vancomycin or linezolid may be used. It's important to consult with a pediatrician for the appropriate treatment plan. To prevent recurrent parotitis, several strategies can be employed, including maintaining good oral hygiene, staying hydrated, avoiding irritants, providing a balanced diet, considering antibiotics, regular dental check-ups, gland massage, and pain management. Long-term consequences of recurrent parotitis in children may include chronic, nonspecific parotitis leading to painful parotid inflammation and a significant impact on quality of life. Treatment for recurrent parotitis in children typically involves a multidisciplinary approach and may include antibiotics, sialendoscopy, and lifestyle changes. The causes of recurrent parotitis in children are not fully understood, but may include underproduction of saliva, congenital malformation of the salivary ducts, and a history of bacterial or viral infections. To support your child in managing recurrent parotitis, follow these steps: encourage regular dental check-ups, practice good oral hygiene, avoid sugary snacks and drinks, monitor your child's diet, teach your child to avoid chewing on hard objects, encourage your child to drink plenty of water, consider a humidifier, teach your child to avoid smoking and alcohol, and consider consulting a pediatrician or a dentist. Parents should be aware of the potential underlying conditions that may be contributing to the recurrent parotitis in their child, including an underproduction of saliva, congenital abnormalities, and genetic predisposition.</p>
--	--

Regarding the long-term clinical course of this disease, recurrent parotitis can be a challenging condition to manage. Episodes can recur over several years, and the frequency and severity of episodes can vary widely between patients. In some cases, the condition may resolve spontaneously, while in others, it may require ongoing treatment to manage symptoms. Parents should be advised that their child may need to undergo further testing, such as imaging studies or blood tests, to rule out underlying conditions that may be contributing to the recurrent parotitis. They should also be counselled on the importance of good oral hygiene and regular dental check-ups to reduce the risk of complications.

In addition to the previous answer, it is also important to note that recurrent parotitis can be associated with underlying conditions such as Sjögren's syndrome or IgG4-related disease. Therefore, parents should be advised to seek medical attention if their child experiences any new or worsening symptoms, such as persistent swelling, fever, or difficulty swallowing.

Treatment options for recurrent parotitis may include antibiotics, anti-inflammatory medications, and surgical interventions. In some cases, sialendoscopic removal of small stones or fragmenting smaller stones to facilitate removal may be necessary. Transoral excision of submandibular stones or combined endoscopic transcuteaneous excision of parotid stones may also be considered. Gland excision may be necessary in severe cases. Antibiotics may be prescribed if an infection is present.

It is also important to note that prompt clinical improvement does not occur, when fluctuance of the gland increases, or with an intraparotid abscess.

Furthermore, the most common underlying causes of recurrent parotitis in children include an underproduction of saliva, congenital malformation of the salivary ducts, history of bacterial or viral infections, and autoimmune disorders. The condition can also be linked to dental malocclusion, genetic factors, and immune deficiency. In terms of treatment, over-the-counter pain medication, careful oral

	<p>hygiene, and massage of the parotid gland are often recommended. Sialendoscopy with or without ductal corticosteroid infusion has been found to be effective in the treatment of JRP and autoimmune parotitis. For neonates, treatment may involve intravenous antibiotics such as gentamicin or levofloxacin and anti-MRSA antistaphylococcal antibiotics.</p> <p>In addition, recent developments in the treatment of recurrent parotitis in children include the use of sialendoscopy with corticosteroid application, which has been shown to be effective in the treatment of JRP and autoimmune parotitis. Other treatments range from conservative to invasive surgical procedures, with conservative treatment being initially indicated due to the natural history of JRP. Additionally, surgical interventions such as parotidectomy, duct ligation, and radiation have been suggested. It's also important to consider Sjögren's syndrome in the child with recurrent parotitis for timely and appropriate referral and treatment.</p>
<p>You are performing an osteoplastic flap procedure using a bicoronal approach for drainage of mucoceles.</p> <p>a. In which soft tissue planes will you elevate the bicoronal flap?</p> <p>b. Once the frontal bone is exposed, list THREE techniques to identify the margins of the frontal sinus prior to making the bony cuts for the osteoplastic flap.</p>	<p>To answer the question, I will break it down into two parts: a) the soft tissue planes for elevating the bicoronal flap, and b) techniques for identifying the margins of the frontal sinus prior to making the bony cuts for the osteoplastic flap.</p> <p>a) The bicoronal flap is elevated in the subgaleal plane, taking care to avoid injury to the pericranium. This plane is chosen to minimize bleeding and maximize exposure of the frontal bone.</p> <p>b) Once the frontal bone is exposed, there are several techniques that can be used to identify the margins of the frontal sinus prior to making the bony cuts for the osteoplastic flap. These techniques include:</p> <p>1) Using a 6-foot Caldwell radiograph to outline the frontal sinus on the bone prior to making the bony cuts. This technique allows for precise localization of the frontal sinus and helps to avoid injury to the surrounding bone.</p> <p>2) Using a combination of anatomical landmarks and palpation to identify the margins of the frontal sinus. This technique relies on the surgeon's knowledge of the anatomy of the frontal bone and the</p>

	<p>location of the frontal sinus.</p> <p>3) Using a navigation system to identify the margins of the frontal sinus in real-time. This technique uses intraoperative imaging to provide precise localization of the frontal sinus and helps to minimize the risk of complications. Intraoperative imaging, such as MRI and CT scans, can be used to provide real-time feedback during the surgery, helping to identify potential complications and adjust the surgical plan accordingly. Additionally, the osteoplastic flap procedure is effective in managing complications such as frontal outflow stenosis, mucocele, infection, and paresthesia. Careful preoperative evaluation, precise surgical techniques, and postoperative care are recommended to manage these complications. Endoscopic sinus surgery and the osteoplastic flap procedure with frontal sinus obliteration are also effective methods for dealing with complications. Obtaining patient consent for possible complications and discussing management strategies preoperatively is also important. Furthermore, the osteoplastic flap can help improve outcomes and manage hydrocephalus. The osteoplastic flap procedure with frontal sinus obliteration is a viable option for managing frontal sinus pathology and preventing complications. Overall, a comprehensive approach that includes careful preoperative evaluation, precise surgical techniques, and postoperative care is recommended to manage complications and improve outcomes in osteoplastic flap procedures.</p>
<p>List the THREE MOST common complications associated with the placement of tympanostomy tubes in children</p>	<p>The three most common complications associated with the placement of tympanostomy tubes in children are:</p> <ol style="list-style-type: none"> 1) Otorrhea, which is the discharge of pus from the ear, affecting approximately 10-20% of children. 2) Tube occlusion, where the tube becomes blocked, which occurs in around 10-15% of cases. 3) Persistent perforation, where the eardrum does not heal after the tube is removed, affecting around 2-5% of children. It is essential for parents to monitor their child's ear health and follow up with the otolaryngologist as directed to minimize the risk of these complications. The provided references highlight the importance of proper patient selection, surgical indications, and perioperative management to reduce the occurrence of these complications.
<p>Name FOUR local oncologic</p>	<p>Four local oncologic contraindications to supra-cricoid laryngectomy</p>

<p>contraindications to supra-cricoid laryngectomy</p>	<p>are:</p> <ol style="list-style-type: none"> 1) Tumor involvement of the cricoid cartilage, 2) Invasion of the interarytenoid muscle, 3) Postcricoid involvement, and 4) Extension to the hyoid bone or thyroid cartilage. <p>These contraindications are crucial to consider as they can significantly impact the success of the surgical procedure and the patient's overall prognosis. Additionally, the importance of immune system surveillance in preventing cancer development should be considered in surgical planning and patient management. Restoring immune activity through checkpoint inhibitors may be crucial in preventing oral potentially malignant disorders transformation.</p> <p>Four local oncologic contraindications to supra-cricoid laryngectomy are:</p> <ol style="list-style-type: none"> 1) fixed vocal cord, 2) invasion of the hyoid bone, 3) thyroid cartilage invasion, and 4) extralaryngeal soft tissue invasion. The provided references highlight the importance of considering anatomic differences in laryngeal size when assessing resectability. Additionally, supra-cricoid laryngectomy can be a successful salvage procedure for irradiation failures, with major contraindications including fixation of the ipsilateral arytenoid cartilage, cricoid cartilage invasion, extralaryngeal spread of tumor, and infraglottic spread to the cricoid cartilage. The clinical implications of local oncologic contraindications to supra-cricoid laryngectomy are significant, including tumor invasion of the thyroid cartilage, cricoid cartilage, hyoid bone, pre-epiglottic space, post-cricoid region, piriform sinus, interarytenoid muscle, vocal cord, epiglottis, and vallecula. These contraindications are crucial in determining the suitability of the patient for this surgical procedure and impact the surgical outcome. Accurate staging and surgical planning are essential for optimal patient outcomes.
<p>A patient presents with an anterior glottic web. Name FIVE treatment options, used alone or in combination, for the management of this lesion</p>	<p>An anterior glottic web is a rare congenital or acquired lesion that can cause voice changes, dyspnea, and feeding difficulties in children. The treatment options for this condition depend on the size and severity of the web. Here are five treatment options, used alone or in combination, for the management of an anterior glottic web:</p>

1. Endoscopic CO2 laser division: This is a minimally invasive procedure that uses a CO2 laser to divide the web under endoscopic guidance. The indications for CO2 laser division include thin anterior commissure webs that can be successfully excised with a carbon dioxide laser.

2. Laryngoplasty: This surgical procedure involves making an incision in the larynx to access and divide the web. It may be performed open or endoscopically.

3. KTP laser ablation: This is a less invasive procedure that uses a potassium titanyl phosphate (KTP) laser to ablate the web.

4. Microlaryngoscopy: This is a surgical procedure that uses a microscope to visualize the web and remove it using specialized instruments.

5. Tracheostomy: In severe cases, a tracheostomy may be necessary to bypass the obstruction caused by the web. The microtrapdoor flap technique is useful in treating anterior and posterior glottic webs, as well as subglottic stenosis. This technique involves making an incision in the scar tissue, raising a mucosal flap, vaporizing the scar tissue, and replacing the flap to prevent reformation of scar. Mitomycin-C may also be applied to reduce scar formation. The goal of management is to establish a stable airway and provide a good voice.

The potential complications and outcomes of CO2 laser division in the treatment of anterior glottic webs include a range of surgical techniques that have been proposed. These include endoscopic approaches such as the use of knife and/or scissor division (cold steel), CO2 laser division, and other minimally invasive methods. The outcomes vary depending on the technique used and the individual case, but generally, they aim to improve vocal function and quality of life for patients with this condition. Post-operative care involves improving breathing or voice quality as the primary indications for surgery. It's crucial to note that surgery carries a risk of worsening the condition. Continued monitoring is necessary to determine whether

	<p>there is a recurrence of readhesion of the anterior glottic web or glottic cancer. This highlights the importance of regular check-ups and monitoring post-surgery.</p> <p>The long-term outcomes for patients with anterior glottic webs can vary, but generally, respiratory symptoms are predominant in posterior glottic stenosis, while anterior glottic webs mainly present dysphonia. Patients with anterior glottic webs may experience varying degrees of respiratory symptoms and dysphonia over time. The condition can have a significant impact on the quality of life, especially in terms of speech and breathing.</p>
<p>Name THREE techniques used to prevent or cure pharyngoesophageal spasm after total laryngectomy.</p>	<p>Three techniques used to prevent or cure pharyngoesophageal spasm after total laryngectomy are:</p> <ol style="list-style-type: none"> 1) Botulinum toxin injection into the cricopharyngeus muscle, which has been shown to be effective in alleviating symptoms; 2) cricopharyngeal myotomy, a surgical procedure that involves dividing the cricopharyngeus muscle to relieve spasm; and 3) pharyngeal dilation, which involves gradually stretching the pharynx to improve swallowing function and reduce spasm. These techniques can be used alone or in combination to manage pharyngoesophageal spasm after total laryngectomy. The provided references suggest that botulinum toxin injection is an effective treatment option, and surgical myotomy is rarely necessary. Additionally, pharyngeal dilation can be used to improve swallowing function and reduce spasm. It is important to note that botulinum toxin injection can have potential complications and contraindications, including transient worsening of dysphagia, and the overall complication rate is minimal. Biopsy specimens of the cricopharyngeus muscle have shown inflammation and fibrosis, suggesting that botulinum toxin may have a direct effect on the muscle. Videofluoroscopy can be used to guide botulinum toxin injections for pharyngoesophageal spasm after total laryngectomy. Botulinum toxin is often used off-label for treating pain, abnormal muscle spasm, and excessive glandular secretions.
<p>What is the MAIN arterial supply to EACH of the following flaps once they are elevated? a. Pectoralis major flap</p>	<p>The main arterial supply to each of the following flaps once they are elevated is as follows:</p> <ol style="list-style-type: none"> a. Pectoralis major flap: The main arterial supply is the pectoral branch of the thoracoacromial artery.

<p>b. Latissimus dorsi flap c. Lower island trapezius flap d. Paramedian forehead flap e. Deltopectoral flap f. Fibular free flap g. Iliac osteomyocutaneous free flap</p>	<p>b. Latissimus dorsi flap: The main arterial supply is the thoracodorsal artery. c. Lower island trapezius flap: The main arterial supply is the transverse cervical artery. d. Paramedian forehead flap: The main arterial supply is the supratrochlear artery and the supraorbital artery. e. Deltopectoral flap: The main arterial supply is the second and third perforating branches of the internal mammary artery. f. Fibular free flap: The main arterial supply is the peroneal artery. g. Iliac osteomyocutaneous free flap: The main arterial supply is the deep circumflex iliac artery.</p>
<p>A 49-year-old patient with T3N2b squamous cell carcinoma of the hypopharynx is scheduled to receive combined chemotherapy and radiation. What is the MOST important potential long-term sequela of this treatment that must be disclosed to the patient?</p>	<p>The most important potential long-term sequela of combined chemotherapy and radiation for treating T3N2b squamous cell carcinoma of the hypopharynx is dysphagia. This can lead to significant morbidity, affecting the patient's quality of life, and even mortality. It is essential to disclose this risk to the patient, as it may impact their decision-making process and necessitate proactive swallowing rehabilitation. Furthermore, the patient should be informed about the potential need for long-term gastrostomy tube dependence, malnutrition, and aspiration pneumonia. It is crucial for the patient to understand these risks to make informed decisions about their treatment. While research suggests that prophylactic swallowing exercises can improve swallowing function and quality of life in patients with head and neck cancer undergoing chemoradiation, the most effective exercises for this specific patient group are not yet identified and require further investigation. Patient education should include prevention and management of osteoradionecrosis, as per the ISOO-MASCC-ASCO guideline, and a multidisciplinary clinical pathway with regular monitoring and early intervention should be established to optimize dysphagia management. Effective monitoring and adjustment of dysphagia management strategies should consider regular assessments, patient feedback, progression of the disease, side effects of treatment, nutritional status, collaboration with healthcare providers, adaptation to changing needs, education and support, use of technology, and patient-centered care.</p>
<p>List FOUR genera of fungi that cause mucormycosis</p>	<p>Four genera of fungi that cause mucormycosis are: Rhizopus, Mucor, Lichtheimia, and Rhizomucor. These fungi are commonly found in soil, decaying organic matter, and on surfaces, and can enter the body</p>

	<p>through cuts, wounds, or inhalation. The infection can affect various parts of the body, including the sinuses, brain, lungs, and skin, and can be life-threatening if left untreated. The diagnosis of mucormycosis typically requires a combination of clinical suspicion, imaging studies, and biopsy. The treatment involves antifungal therapy and surgical debridement of affected tissues. It is crucial to manage the underlying immunocompromised state to improve prognosis.</p> <p>The key characteristics of each species that make them pathogenic and contribute to their virulence in mucormycosis are: <i>Rhizopus</i> is homothallicus with fast-growing and spreading mold, white mycelia, and black sporangia; <i>Mucor</i> species are fast growers with aseptate or irregularly septate sporangiophores; <i>Lichtheimia</i> species are known for their role in causing mucormycosis; and <i>Rhizomucor</i> is a very-fast-growing, spreading type of mold with white mycelia and black sporangia.</p>
<p>List the TWO functions of the superior laryngeal nerve</p> <p>Where do the recurrent laryngeal nerve and the internal branch of the superior laryngeal nerve enter the larynx respectively?</p>	<p>The superior laryngeal nerve has two main functions: it provides motor innervation to the cricothyroid muscle, which tenses the vocal cord, and it provides sensory innervation to the laryngeal mucosa above the vocal folds.</p> <p>The recurrent laryngeal nerve enters the larynx behind the cricothyroid joint, whereas the internal branch of the superior laryngeal nerve enters the larynx through a small aperture in the thyroid cartilage. The injury to the superior laryngeal nerve can significantly impact both voice and swallowing functions. For voice, the injury can lead to a contraction of pitch range and affect vocal fold vibratory patterns. Regarding swallowing, the superior laryngeal nerve plays an important role in a successful swallow, and bilateral lesions can lead to significant swallowing difficulties. As for treatment options, there are several approaches, including surgery, speech therapy, and rehabilitation programs aimed at improving vocal and swallowing functions. The superior laryngeal nerve injury can be caused by various factors such as surgery, trauma, and certain medical conditions. Diagnosing SLN injury can be challenging, but it typically involves a combination of clinical findings, such as hoarseness, vocal fatigue, and breathiness, along with specialized tests like laryngoscopy and electromyography. Voice therapy is often recommended as a treatment option, although</p>

	the effectiveness of this approach is largely anecdotal.
List all of the neural and vascular structures that pass through the sphenopalatine foramen.	<p>The sphenopalatine foramen is a passage in the skull that allows for the transmission of various neural and vascular structures between the pterygopalatine fossa and the nasal cavity. The structures that pass through the sphenopalatine foramen include:</p> <ol style="list-style-type: none">1. The nasopalatine nerve, which is a branch of the maxillary nerve (V2) that provides sensory innervation to the nasal septum and the hard palate. The nasopalatine nerve emerges through the sphenopalatine foramen, passes along the nasal septum, and emerges through the median incisive foramen to reach the palate.2. The sphenopalatine artery, which is a branch of the maxillary artery that supplies blood to the nasal mucosa and the surrounding structures. This artery has two main branches: the posterior lateral nasal and posterior septal branches. These branches supply the mucosa of the nasal cavity.3. The posterior superior lateral nasal nerve, which is a branch of the maxillary nerve (V2) that provides sensory innervation to the nasal cavity. <p>Passage through the sphenopalatine foramen allows these structures to access the nasal cavity and surrounding areas, enabling them to perform their respective functions. The sphenopalatine foramen is located within the superior meatus, between the basal lamella of the middle turbinate and the basal lamella of the superior turbinate, up to 90% of the time, at a distance of roughly 6 cm from the nasal sill. A septal branch of the SPA traverses the anterior face of the sphenoid rostrum inferior to the sphenoid ostium.</p> <p>The clinical significance of the structures passing through the sphenopalatine foramen includes their role in supplying blood and innervation to the nasal mucosa and surrounding areas. Understanding the anatomy of these structures is crucial for surgeons to avoid complications during surgical procedures, such as internal maxillary artery ligation. Additionally, knowledge of the variations in the branching of the sphenopalatine artery is essential to ensure complete ligation of the SPA.</p> <p>The sphenopalatine foramen is also related to several surgical procedures, including the Caldwell-Luc procedure and the transnasal endoscopic approach for the resection of sphenopalatine foramen schwannomas. These procedures are crucial in dentistry, impacting</p>

	<p>procedures such as impacted tooth removal, cyst surgeries, and implants. Accurately identifying this anatomical feature facilitates post-surgery issues and improves patient outcomes.</p> <p>Potential complications of these surgeries include bleeding, infection, and damage to the surrounding structures. In the Caldwell-Luc procedure, the most common complications are bleeding, infection, and damage to the infraorbital nerve. In the transnasal endoscopic approach, complications may include bleeding, cerebrospinal fluid leaks, and damage to the surrounding structures such as the sphenoid sinus and the cavernous sinus.</p>
<p>4 a) How will you decide whether boy should have SMR or septoplasty?</p> <p>b) Enumerate four complications of SMR.</p>	<p>A: To determine whether a boy should undergo Submucous Resection (SMR) or septoplasty, a thorough evaluation of his nasal passages and overall health is necessary. As an otolaryngologist, I would consider the following factors:</p> <ol style="list-style-type: none"> 1) Nasal obstruction: If the boy is experiencing significant nasal congestion, difficulty breathing, or recurrent sinus infections, surgical intervention may be necessary. 2) Septal deviation: A deviated septum can cause nasal obstruction and may be corrected with septoplasty. 3) Turbinate bone size: Enlarged turbinate bones can contribute to nasal congestion and may be reduced in size during SMR. 4) Nasal polyps or other anatomical abnormalities: Presence of polyps or other abnormalities may require septoplasty or SMR to improve nasal function. 5) Age and overall health: The boy's age, medical history, and overall health will influence the decision between SMR and septoplasty. A thorough physical examination, nasal endoscopy, and imaging studies (e.g., CT scans) would be necessary to make an informed decision. <p>B: Enumerating four complications of submucous resection of the nasal septum, they are: 1. Hemorrhage: Bleeding during or after the surgery can occur, which may require further surgical intervention. 2. Infection: Bacterial or fungal infections can develop at the surgical site, leading to further complications. 3. Nasal Septal Perforation: A hole in the nasal septum can occur, causing nasal congestion, crusting, and bleeding. 4. Loss of Smell: Damage to the olfactory nerves during surgery can result in a permanent loss of smell. Additionally, it is essential to approach turbinate resection judiciously and cautiously to</p>

	<p>prevent complications. Nasal septal hematoma is a rare but serious issue that can occur due to nasal or facial trauma, and it's crucial to be aware of this complication and take necessary precautions to prevent it. Furthermore, intracranial complications, although rare, can be very serious and include anosmia, visual disturbances, cavernous sinus thrombosis, meningitis, etc. The current best practices for preventing and managing complications in submucous resection of the nasal septum include a judicious and cautious approach to turbinate resection to prevent complications. For more detailed information, you can refer to this article: [Surgical Interventions for Inferior Turbinate Hypertrophy: A Systematic Review and Meta-Analysis](https://www.ncbi.nlm.nih.gov/pmc/articles/PMC8038107/) . Regarding the complications, you can read this article: [Intracranial complications of submucous resection of the nasal septum](https://www.sciencedirect.com/science/article/pii/S0196070985800247).</p>
<p>A 13 years old girl complains of permanent nasal obstruction. Examination reveals that septum is deviated to right side with some hypertrophy of inferior turbinate. Her Hb is 10gm/dl.</p> <p>a) What is best surgical treatment for her?</p> <p>b) What is the difference between SMR and septoplasty?</p>	<p>The best surgical treatment for the 13-year-old girl would be a septoplasty with turbinate reduction. This is because the septum is deviated to the right side, and there is hypertrophy of the inferior turbinate, causing permanent nasal obstruction. Septoplasty would help to correct the deviated septum, and turbinate reduction would reduce the size of the inferior turbinate, thus improving nasal breathing. It's essential to consider her Hb level of 10 gm/dl before surgery to ensure that she doesn't have any underlying anemia that might affect the surgical outcome. In terms of differences between SMR (Submucous Resection) and septoplasty, SMR is a more invasive procedure that involves removing parts of the nasal septum and vomer bone, whereas septoplasty is a less invasive procedure that focuses on repositioning and reshaping the deviated septum. Septoplasty is generally preferred over SMR due to its lower risk of complications and better cosmetic outcomes. Additionally, septoplasty and turbinate reduction can significantly improve airflow and breathing in adolescent patients. The surgical planning process takes into account the patient's age and growth development to ensure that the surgery does not interfere with the normal growth of the nasal passages. It's important to consult with a healthcare professional to discuss the potential risks and benefits in detail.</p>
<p>What are indications and</p>	<p>Endoscopic sinus surgery (ESS) is a minimally invasive surgical</p>

<p>complications of endoscopic sinus surgery?</p> <p>Bronchoscopy</p>	<p>procedure used to treat various sinus-related disorders. The indications for ESS include chronic sinusitis, nasal polyps, deviated septum, and tumors in the nasal or sinus cavities. The goal of ESS is to restore normal sinus function, alleviate symptoms, and improve the quality of life for patients. Complications of ESS can include bleeding, infection, cerebrospinal fluid leak, orbital injury, and nasal septal perforation. Additionally, patients may experience temporary side effects such as nasal congestion, headaches, and facial pain. In rare cases, ESS can also lead to more severe complications, such as visual disturbances, meningitis, or even brain abscess. It is essential to carefully weigh the benefits and risks of ESS and discuss them with an otolaryngologist or a qualified healthcare professional. Based on the search results, endoscopic sinus surgery is commonly used to treat various sinus-related disorders, including chronic sinus infections, nasal polyps, and tumors. It aims to remove blockages in the sinuses that cause pain, drainage, infections, impaired breathing, or loss of smell.</p>
<p>Give indications and complications of bronchoscopy</p>	<p>Bronchoscopy is a diagnostic and therapeutic procedure that involves the visualization of the airways using a flexible or rigid tube called a bronchoscope. The indications of bronchoscopy include the diagnosis of respiratory symptoms such as cough, hemoptysis, and dyspnea, as well as the investigation of abnormalities detected on chest radiographs or computed tomography scans. Other indications include the removal of foreign bodies, the collection of bronchial washings or brushings for microbiological or cytological examination, and the placement of stents or other devices to maintain airway patency. Complications of bronchoscopy may include mucosal trauma, laryngospasm, bradycardia, pneumothorax, bleeding, and edema, any of which may contribute to the loss of the ability to oxygenate or ventilate the patient. There are two main types of bronchoscopes: flexible and rigid. Flexible bronchoscopy is a more common procedure that uses a flexible tube to visualize the airways, while rigid bronchoscopy uses a stiff tube and is often used for more complex procedures. Recent advancements in bronchoscopy include the development of innovative real-time frameworks for accurate branch-level localization, such as BronchoTrack, which can track the airway lumen in real-time. Additionally, teleoperated robotic bronchoscopy systems are being designed to enhance accuracy and safety during bronchoscopy procedures. These advancements have the potential to</p>

	<p>reduce the risks associated with bronchoscopy, such as injury to the teeth, pharyngeal injury, laceration, contusion, or edema of the tongue, laryngeal injury, or tracheal injury. Mortality rates in the literature vary from 0.2% to 1.0%. The benefits of BronchoTrack include its ability to accurately track the airway lumen in real-time, which can improve the accuracy and safety of bronchoscopy procedures. Teleoperated robotic bronchoscopy systems have also been shown to maintain better bronchus centring than expert teleoperation, further enhancing the safety and accuracy of these procedures. Furthermore, the comparison of flexible and rigid bronchoscopy highlights the advantages of flexible bronchoscopic intubation and its potential future role in awake airway management. The use of a rigid flexible laryngoscope to facilitate endotracheal intubation is also a promising development.</p>
<p>a) What are indications of tonsillectomy? b) What is management of primary, secondary and reactionary hemorrhage after tonsillectomy?</p>	<p>The indications of tonsillectomy include recurrent tonsillitis, sleep disorders, and peritonsillar abscess. The management of primary, secondary, and reactionary hemorrhage after tonsillectomy involves a step-by-step approach. Primary hemorrhage occurs immediately after surgery, secondary hemorrhage occurs within 2-3 weeks, and reactionary hemorrhage occurs within 24 hours. Management includes maintaining a patent airway, applying pressure to the bleeding site, using hemostatic agents, and in severe cases, returning to the operating room for further surgical intervention.</p> <p>Additionally, the surgical techniques used in tonsillectomy include cold dissection, hot dissection using electrocautery, and other methods such as laser and radiofrequency devices. The choice of technique may depend on the surgeon's preference and the individual patient's needs. The postoperative pain associated with tonsillectomy has led to the development of various surgical techniques, including adenotonsillectomy, and the use of different devices such as the microdebrider.</p> <p>Common complications of tonsillectomy include postoperative infection, bleeding, edema of the tongue, glossopharyngeal nerve injury, and sudden pneumothorax. In adults, about 20% of patients who undergo a tonsillectomy will experience a complication, with 10% visiting an emergency department and approximately 1.5% requiring hospitalization. For pediatric patients, tonsillectomy and</p>

	<p>adenoidectomy are associated with an increased risk of complications, including postoperative bleeding and respiratory complications. Recent advancements in tonsillectomy surgical techniques include the use of pediatric intracapsular tonsillectomy, which has shown promising results. Modern techniques such as the BRC and PB methods are also being compared with conventional CD technique, with no significant advantage in terms of postoperative pain. Additionally, transoral robotic radical tonsillectomy is a minimally invasive procedure that has been introduced for the treatment of tonsil tumors. These advancements aim to improve patient outcomes and reduce recovery time.</p>
<p>2. A child 8 years of age is brought to emergency with bleeding from mouth and pain during swallowing. Child looks pale, pulse is 120/min and temperature is 102 Fahrenheit. He had undergone tonsillectomy operation 5 days ago.</p> <p>a) What is your clinical diagnosis? b) How will you manage the child? c) Enumerate four different methods of tonsillectomy.</p>	<p>Based on the symptoms presented, my clinical diagnosis is a post-tonsillectomy hemorrhage, which is a common complication of tonsillectomy. The child's pale appearance, rapid pulse, and elevated temperature suggest significant blood loss.</p> <p>As an otolaryngologist, I would manage the child by first stabilizing their airway, breathing, and circulation. Then, I would perform a thorough examination of the oral cavity to identify the source of bleeding. Depending on the severity of the bleeding, I may need to take the child to the operating room for control of the bleeding or to perform a packing of the tonsillar bed. Additionally, I would administer fluid resuscitation, pain management, and antibiotics as necessary.</p> <p>In terms of tonsillectomy methods, there are several approaches including:</p> <ol style="list-style-type: none"> 1) Traditional tonsillectomy with cold steel instruments, 2) Electrocautery tonsillectomy, 3) Harmonic scalpel tonsillectomy, and 4) Laser tonsillectomy. Each method has its own advantages and disadvantages, and the choice of method depends on the child's specific needs. Furthermore, I would like to emphasize the importance of post-operative care and follow-up for the child after the bleeding is controlled. This includes monitoring for any signs of bleeding, managing pain, and ensuring proper nutrition. The provided resources on post-tonsillectomy hemorrhage management, pediatric tonsillectomy complications, and tonsillectomy recovery in children will be useful in guiding the management and care of the child.

<p>1. a) For planning of radiotherapy in a patient with cancer, what do you understand by</p> <ul style="list-style-type: none">i) Curative radiotherapyii) Palliative radiotherapyiii) Combination type radiotherapy <p>b) Enumerate four early complications of radiotherapy.</p>	<p>In the context of radiotherapy for cancer patients, I understand curative radiotherapy to be a type of treatment aimed at completely eliminating the tumor or cancer cells, with the goal of curing the patient.</p> <p>On the other hand, palliative radiotherapy is a type of treatment focused on alleviating symptoms and improving the patient's quality of life, rather than curing the cancer.</p> <p>Combination type radiotherapy, as the name suggests, involves combining different types of radiotherapy, such as external beam radiation therapy (EBRT) and brachytherapy, to achieve a more effective treatment outcome. This combined approach can help enhance the effectiveness of treatment while minimizing side effects.</p> <p>As a professional otolaryngologist, it is essential to carefully evaluate each patient's condition and develop a personalized treatment plan that takes into account their unique needs and circumstances. The latest advancements in radiotherapy for cancer treatment include the development of Stereotactic Body Radiation Therapy (SBRT), which is a new External Beam Radiation Therapy (EBRT) technique. This method is made possible by improved radiation accuracy and therapeutic ratios for many tumor sites. The advantages of SBRT include improved target coverage and critical organ sparing, which can potentially enhance the therapeutic ratio, especially for tumors located near critical organs. However, the implementation of SBRT using pencil-beam scanning (PBS) proton therapy (PBSPT) is more challenging due to concerns about amplified uncertainties at larger doses per fraction. The disadvantages of SBRT include the need for volumetric image guidance and multiple CT-based robust optimization and robustness tools to minimize the impact of uncertainties associated with respiratory motion. Advances in direct motion analysis techniques are urgently needed to supplement current motion management techniques. Future directions for improving SBRT include combining SBRT with immunotherapy to enhance treatment outcomes, advancements in technology such as image guidance and motion management, improving treatment outcomes and reducing costs by comparing SBRT with other forms of radiation therapy, and continuing research and development in SBRT.</p>
---	---

<p>List three side effects of radiotherapy in Head & Neck Cancers</p>	<p>Radiotherapy in head and neck cancers can cause various side effects. Three common side effects are mucositis, which is the inflammation of the mucous membranes in the mouth, throat, and digestive tract, leading to pain, difficulty swallowing, and mouth sores.</p> <p>Another side effect is xerostomia, or dry mouth, which can lead to tooth decay, gum disease, and difficulty speaking.</p> <p>Lastly, radiation-induced dysphagia, which is difficulty swallowing, can occur due to the radiation damaging the muscles and tissues involved in swallowing. In managing these side effects, it is essential to practice good oral hygiene, use topical anesthetics, and maintain a healthy diet. Furthermore, sparing the salivary glands during radiation therapy and using intensity-modulated radiation therapy (IMRT) can help minimize the risk of xerostomia. Additionally, medications such as pilocarpine and amifostine can be used to stimulate salivary production and reduce the severity of xerostomia. According to the latest guidelines, the management of mucositis, xerostomia, and radiation-induced dysphagia should follow the recommendations outlined in the MASCC/ISOO clinical practice guidelines for the management of mucositis, the ISOO-MASCC-ASCO guideline for the prevention and management of xerostomia and osteoradionecrosis, and the same guideline for radiation-induced dysphagia. These guidelines provide comprehensive information on the prevention and treatment of these side effects.</p>
---	---

Table 2: Essay questions and answers from ENTAgent

Essay questions	ENTAgent
<p>Discuss the aetiopathogenesis, Clinical features and Management of tubotympanictype of chronic suppurative otitis media.</p>	<p>The tubotympanic type of chronic suppurative otitis media (CSOM) is a complex condition that affects the middle ear. Aetiopathogenesis: The tubotympanic type of CSOM is primarily caused by recurrent or persistent infection of the middle ear, often due to Eustachian tube dysfunction or nasopharyngeal infection. Other factors that contribute to the development of this condition include allergies, adenoid hypertrophy, and anatomic abnormalities of</p>

	<p>the Eustachian tube. Biofilms may play a role in the aetiopathogenesis of tubotympanic CSOM.</p> <p>Clinical Features: Patients with tubotympanic CSOM often present with symptoms such as otorrhea (discharge from the ear), hearing loss, and discomfort or pain in the affected ear. Otoscopy may reveal a perforated tympanic membrane, and tympanometry may show a type V tympanogram.</p> <p>Management: The management of tubotympanic CSOM involves addressing the underlying cause of the condition, as well as managing the symptoms and preventing complications. This may include antibiotics, nasal decongestants, and tympanocentesis (drainage of the middle ear). In some cases, surgical intervention such as tympanoplasty may be necessary to repair the perforated tympanic membrane and restore hearing.</p> <p>Additionally, addressing Eustachian tube dysfunction through balloon dilation or other methods may be beneficial in preventing recurrence of the condition. Effective treatment of biofilms depends on restoration of the normal physiology of the middle ear combined with topical and systemic therapy. A recent study suggests that xylitol nasal spray may be an effective prophylactic treatment for preventing recurrent acute otitis media in children, which could potentially be beneficial in preventing the development of tubotympanic CSOM.</p>
<p>Discuss the aetiology, pathogenesis, clinical features and Management of Retropharyngeal abscess.</p>	<p>A retropharyngeal abscess is a serious infection that occurs in the tissues at the back of the throat.</p> <p>The aetiology of a retropharyngeal abscess can be attributed to various factors, including bacterial or viral infections, trauma, or the spread of infection from adjacent structures such as the sinuses, teeth, or</p>

	<p>ears.</p> <p>The pathogenesis involves the invasion of the infection into the retropharyngeal space, which is a potential space that contains fatty tissue and lymph nodes.</p> <p>The clinical features of a retropharyngeal abscess may include severe throat pain, difficulty swallowing, fever, and neck stiffness. In severe cases, it can lead to airway obstruction, sepsis, or even death if left untreated.</p> <p>Management of a retropharyngeal abscess typically involves prompt surgical drainage of the abscess, followed by administration of broad-spectrum antibiotics and supportive care such as hydration and pain management. However, in pediatric patients, conservative treatment with intravenous antibiotics and corticosteroids is often preferred, especially in children under five years old, as it can avoid complications associated with surgical drainage. In adult patients, the treatment options are more complex and often depend on the underlying cause of the abscess. In cases where the abscess is associated with esophageal fistula, especially in patients with a history of esophagopharyngeal cancer, the treatment approach may involve dorsal instrumentation, ventral debridement, and in some cases, explantation of ventral implants. The outcomes can vary greatly, with some patients experiencing neurological complications or even death during the hospital stay. Early recognition and treatment are essential to prevent complications and improve outcomes. The diagnosis of retropharyngeal abscess can be made using imaging studies such as CT and MR imaging, which can evaluate the extent of the infection and differentiate it from other conditions such as adenitis.</p>
--	---

	<p>The imaging findings should be correlated with the clinical history to ensure accurate diagnosis.</p> <p>Considering tuberculosis in the differential diagnosis is also important, especially in patients with unusual presentations and predisposing factors. Effective surgical drainage of the abscess can be achieved through an incision in the posterior oropharyngeal wall under local anesthesia. Long-term outcomes and complications of retropharyngeal abscesses can include quadriplegia, especially in cases of extrapulmonary spinal tuberculosis. Therefore, it is essential to consider the potential complications and outcomes when managing retropharyngeal abscesses.</p>
<p>Discuss the aetiopathology of conductive deafness. Describe the types of tympanoplasty.</p>	<p>Conductive deafness refers to a type of hearing loss that results from problems in the middle ear, which is responsible for transferring sound vibrations from the outside environment to the inner ear.</p> <p>The aetiopathology of conductive deafness can be attributed to various factors, including otosclerosis, chronic otitis media, cholesteatoma, otitis externa, traumatic injuries, congenital anomalies, and foreign bodies in the ear canal. These conditions can cause damage to the tympanic membrane, the three ossicles (malleus, incus, and stapes), or the middle ear cavity, leading to impaired sound conduction and hearing loss.</p> <p>The treatment of conductive deafness often involves surgical intervention, specifically tympanoplasty, which aims to repair or replace the damaged structures in the middle ear.</p> <p>There are five types of tympanoplasty, each with a different focus:</p> <p>Type I - Repair of the tympanic membrane only; Type II - Repair of the tympanic membrane and the middle ear ossicles;</p>

	<p>Type III - Repair of the tympanic membrane and the middle ear cavity, with the removal of the stapes and the use of a prosthesis to connect the incus to the inner ear;</p> <p>Type IV - Repair of the tympanic membrane and the middle ear cavity, with the removal of the incus and the stapes, and the use of a prosthesis to connect the malleus to the inner ear; and</p> <p>Type V - Repair of the tympanic membrane and the middle ear cavity, with the removal of all the middle ear ossicles and the use of a prosthesis to connect the tympanic membrane to the inner ear. The choice of tympanoplasty type depends on the extent and location of the damage, as well as the surgeon's preference and experience.</p> <p>In addition, cartilage tympanoplasty has proven to be a very effective material for the reconstruction of the tympanic membrane in cases of advanced middle ear pathology. The wealth of literature that supports cartilage tympanoplasty as a superior technique to achieve anatomical success with no detriment to hearing leads to the question of not when to use cartilage, but, rather, when not to use cartilage. It is particularly useful for the management of an atelectatic ear, cholesteatoma, high-risk perforation; for pediatric patients; and for reinforcement of the tympanic membrane in conjunction with ossiculoplasty. Although postoperative tube insertion is rarely needed, it can prove to be difficult when the entire tympanic membrane is reconstructed with cartilage, emphasizing the importance of proper surgical technique.</p> <p>Furthermore, a comprehensive understanding of the potential complications and risks associated with each type of tympanoplasty, such as facial nerve injury, chorda tympani injury, worsening of</p>
--	--

	<p>conductive hearing loss, sensorineural hearing loss, cerebrospinal fluid leak, vertigo, and infection, is crucial for effective treatment. Proper surgical technique, patient selection, and postoperative care can help mitigate these risks. Additionally, the use of advanced surgical techniques, such as endoscopic tympanoplasty, and the development of new materials and technologies, such as bioengineered grafts, may help improve the outcomes of tympanoplasty. The latest advancements in surgical techniques for tympanoplasty include the use of robotic surgery, which allows for more precision and control in complex procedures. Other advancements include the development of new graft materials, such as bacterial cellulose, and the use of endoscopic techniques to improve visualization and access during surgery. These advancements aim to improve the success rate of the surgery and reduce the need for revision surgeries. In terms of technologies, there have been advancements in light delivery technologies and lens optics, which enhance the visualization of the surgical site during tympanoplasty.</p> <p>Additionally, the development of new biomimetic technologies, such as the PhonoGraft, aim to improve the outcomes of tympanoplasty by providing a more effective and less invasive method for repairing the eardrum. These technological advancements aim to reduce pain, drainage, and hearing loss associated with ear surgery. Overall, the treatment of conductive deafness through tympanoplasty is a complex process that requires careful consideration of the underlying cause of the hearing loss, the extent and location of the damage, and the most appropriate surgical technique and materials to use. By staying up to date with the latest advancements in surgical techniques and</p>
--	--

	<p>technologies, otolaryngologists can provide the best possible outcomes for their patients.</p>
<p>Discuss the aetiopathology of malignant tumors of the maxilla. Add a note on investigations and its surgical management.</p>	<p>Malignant tumors of the maxilla are neoplasms that originate from the maxillary bone or surrounding tissues. The aetiopathology of these tumors involves a combination of genetic, environmental, and lifestyle factors. Common types of malignant tumors affecting the maxilla include squamous cell carcinoma, adenocarcinoma, and sarcomas.</p> <p>Squamous cell carcinoma is the most common type of maxillary tumor, often associated with tobacco use and alcohol consumption. It arises from the mucosal lining of the maxillary sinus and can invade surrounding bone and tissue. Adenocarcinoma, on the other hand, originates from glandular tissue and is more commonly seen in the minor salivary glands of the maxilla. Sarcomas, including osteosarcoma and chondrosarcoma, are rare but aggressive tumors that arise from mesenchymal tissue.</p> <p>Investigations for malignant tumors of the maxilla include imaging studies such as computed tomography (CT) and magnetic resonance imaging (MRI) to assess tumor extent and invasion. Biopsy is essential for definitive diagnosis and histopathological examination. Other investigations may include endoscopy, ultrasound, and positron emission tomography (PET) scans.</p> <p>Surgical management of malignant tumors of the maxilla involves a multidisciplinary approach, including otolaryngology, maxillofacial surgery, and neurosurgery. Surgery aims to achieve complete tumor resection while preserving surrounding tissue and function. Common surgical procedures include maxillectomy, which may be partial or total, and reconstruction using free flaps or local tissue.</p> <p>Adjuvant therapy, including radiotherapy and</p>

	<p>chemotherapy, may be necessary to treat residual disease or prevent recurrence.</p> <p>The molecular biology of malignant tumors of the maxilla has shed light on the role of various biomarkers and genetic mutations in the development and progression of these tumors. For example, the expression of certain cell surface antigens and the presence of specific genetic mutations have been associated with the development of squamous cell carcinoma. Understanding the molecular biology of these tumors can help guide treatment decisions and improve patient outcomes.</p> <p>Immunohistochemistry plays a significant role in the diagnosis and treatment of malignant maxillary tumors, particularly in differentiating between benign and malignant tumors and aiding in the development of targeted therapies. Complications of surgical management are often related to surgery and reconstruction, and surgical excision is crucial for complete tumor excision. The outcomes of treatment, including survival rates and recurrence, vary widely depending on the specific type of tumor and the effectiveness of treatment.</p> <p>In conclusion, the management of malignant tumors of the maxilla requires a comprehensive approach, including a thorough evaluation of the patient's overall health and potential comorbidities. A multidisciplinary team should work together to develop an individualized treatment plan for each patient, taking into account the type and extent of the tumor, as well as the patient's overall health and preferences.</p>
<p>What are the causes of Epistaxis? Describe the Clinical features and Management of Juvenile Nasopharyngeal Angiofibroma.</p>	<p>The causes of Epistaxis can be attributed to various factors such as dry air, trauma, infections, allergies, anatomical abnormalities, hypertension, bleeding</p>

	<p>disorders, and the use of certain medications like anticoagulants or antiplatelets. Another cause is the presence of tumors like Juvenile Nasopharyngeal Angiofibroma (JNA). JNA is a rare, benign but locally aggressive vascular tumor primarily affecting adolescent males. The clinical features of JNA include recurrent and severe epistaxis, nasal obstruction, facial deformity, and nasal voice. The management of JNA typically involves a multidisciplinary approach consisting of preoperative embolization to reduce bleeding, followed by surgical excision of the tumor via various approaches like endoscopic, open, or combined methods. Adjuvant therapies such as chemotherapy or radiation may be required for recurrent or residual tumors. The choice of treatment depends on the tumor's size, extent, and the patient's overall health. A thorough diagnosis by imaging studies like CT or MRI, biopsy, and preoperative assessment is essential for effective management of JNA. Surgical outcomes are better with endoscopic surgery for JNA, as it reduces the risk of complications and recurrence. Radiation therapy may be used in cases where surgical excision is not possible due to the patient's medical condition or refusal of surgery. Chemotherapy and hormone therapy are not effective in the management of JNA. The primary treatment for JNA is surgical extirpation, with endoscopic surgery replacing open approaches for most tumors. The greatest challenge in surgery is controlling bleeding during the procedure. The management of JNA requires a multidisciplinary approach, and the choice of treatment depends on the tumor's size, extent, and the patient's overall health. Preoperative embolization is a crucial step in JNA treatment to minimize blood loss during surgery. Endoscopic endonasal surgery is the preferred approach for JNA, offering less invasive and more precise removal of</p>
--	---

	<p>the tumor. Adjuvant therapies, such as radiation therapy and chemotherapy, are not typically used in the management of JNA due to its benign nature. However, adjuvant therapies may be considered in cases where the tumor is not completely resected or in rare instances of malignant transformation.</p>
<p>Describe the etiology, pathology, clinical features and management of otosclerosis.</p>	<p>Otosclerosis is a condition characterized by abnormal bone growth in the middle or inner ear, leading to hearing loss and potentially affecting balance. It is categorized into two types: fenestral and retrofenestral/cochlear, with the latter being less common and often occurring without the former. The condition can be treated with hearing aids, cochlear implants, or surgery, such as a stapedectomy. It is often inherited and affects more than three million Americans. The symptoms include gradual hearing loss, ringing in the affected ear (tinnitus), and vertigo or dizziness.</p> <p>The pathophysiology of otosclerosis involves abnormal bone remodeling in the otic capsule, which normally has very little bone turnover. The early otosclerotic lesion exhibits both increased bone absorption by osteoclasts and new bone deposition by osteoblasts. The osteocytes are found at the advancing edge of the lesion, which extends into the otic capsule in finger-like projections. The new bone formation is hyper-vascular at first and sclerotic later, but it remains disorganized.</p> <p>The clinical features of otosclerosis include progressive hearing loss, often in the low-frequency range, and may be accompanied by tinnitus or dizziness.</p> <p>Management of otosclerosis typically involves surgical intervention, such as stapedotomy or stapedectomy, to replace the affected stapes bone</p>

	<p>with a prosthetic device. In some cases, hearing aids or other assistive devices may be recommended to improve communication. It's worth noting that otosclerosis can be associated with pregnancy, and women with a history of otosclerosis may experience worsening of symptoms during pregnancy.</p>
<p>What is cholesteatoma? Describe its pathogenesis, etiology, clinical features and management.</p>	<p>Cholesteatoma is a type of skin cyst located in the middle ear. It is characterized by the abnormal growth of skin cells within the middle ear, which can lead to the destruction of surrounding bone and tissue.</p> <p>The pathogenesis of cholesteatoma involves the formation of an inflamed ectopic mass of keratinizing squamous epithelium in the middle ear and mastoid bone. This can lead to the erosion of adjacent bony structures and is often associated with chronic suppurative otitis media.</p> <p>The management of cholesteatoma primarily involves surgical intervention, aiming to eliminate the disease, control infection, and preserve or restore hearing. Long-term monitoring and follow-up are crucial to prevent recurrence. Different surgical approaches are used depending on the size and location of the cholesteatoma, including atticotomy, atticoantrostomy, or limited mastoidectomy. In cases where the cholesteatoma is present in an only hearing ear, a more conservative approach is often recommended to minimize the risk of developing a postoperative sensorineural hearing loss.</p> <p>The etiology of cholesteatoma is multifactorial and can be attributed to various factors such as chronic otitis media, eustachian tube dysfunction, and congenital abnormalities. Chronic otitis media can lead to the formation of a cholesteatoma by causing a perforation in the eardrum, which allows skin cells to</p>

	<p>enter the middle ear. Eustachian tube dysfunction can also contribute to the development of cholesteatoma by causing a buildup of mucus and debris in the middle ear, which can become infected and lead to the growth of skin cells.</p> <p>There are three main types of cholesteatoma: congenital, primary acquired, and secondary acquired. Congenital cholesteatoma is a rare condition that is present at birth and is thought to be caused by a genetic mutation. Primary acquired cholesteatoma is the most common type and is caused by a perforation in the eardrum or by the migration of skin cells into the middle ear through the eustachian tube. Secondary acquired cholesteatoma is caused by the implantation of skin cells into the middle ear through trauma or surgery.</p> <p>The clinical features of cholesteatoma can vary depending on the size and location of the cyst. Common symptoms include hearing loss, ear fullness, and discharge. In advanced cases, cholesteatoma can cause more serious complications such as facial paralysis, vertigo, and meningitis.</p> <p>Imaging studies, such as CT scans, can be useful in the diagnosis and management of cholesteatoma. These studies can help to identify the size and location of the cyst, as well as any damage to surrounding tissue and bone.</p>
<p>A male patient aged 60 yrs chronic smoker, comes with hoarseness of voice of 1 year duration. How do you investigate and treat him.</p>	<p>A 60-year-old male patient presenting with a 1-year history of hoarseness of voice, coupled with a history of chronic smoking, warrants a comprehensive investigation to rule out potentially serious underlying conditions. The initial evaluation would involve a thorough medical history and physical examination, including a flexible laryngoscopy. Given the patient's smoking history, there is an</p>

	<p>increased risk of laryngeal cancer, and thus, a high index of suspicion should be maintained.</p> <p>Further investigations would likely include a direct laryngoscopy under general anesthesia, allowing for a detailed examination of the larynx and the collection of biopsy specimens if necessary. Imaging studies such as a CT scan or MRI of the larynx may also be ordered to evaluate for any masses or lesions. Treatment would be guided by the underlying diagnosis. If the hoarseness is attributed to a benign cause such as vocal cord nodules or polyps, voice therapy and/or surgical intervention may be recommended. However, if a malignant process is identified, a multidisciplinary approach involving oncology, radiation oncology, and surgery would be necessary. Smoking cessation counseling would also be an integral part of the treatment plan. The patient would be closely monitored for response to treatment and any signs of disease progression or recurrence.</p> <p>In terms of specific treatment modalities for laryngeal cancer, surgery and radiation therapy have long been the two most important treatment options. In recent decades, however, further therapeutic options have become available with the introduction of new surgical techniques for conservation laryngeal surgery (partial laryngectomy) and chemotherapy combined with radiation therapy (CRT), which may be used in a neoadjuvant, concurrent, or adjuvant role. As a general principle, early stage laryngeal cancer (stage I or II) is treated with single-modality therapy, either surgery or radiation therapy.</p> <p>Advanced laryngeal cancer (stage III or IV) is treated with combined-modality therapy, either primary surgery followed by postoperative radiation plus or minus chemotherapy. High-level evidence favors</p>
--	--

	<p>combined chemotherapy and radiation over radiation alone as a primary treatment modality for advanced stage cancers. For high-volume tumors, total laryngectomy with postoperative radiation plus or minus chemotherapy may be necessary. Laryngeal preservation with supracricoid partial laryngectomy results in improved quality of life when compared with total laryngectomy.</p> <p>Tumor staging of laryngeal and hypopharyngeal carcinomas with functional spiral CT, comparison with nonfunctional CT, histopathology, and microlaryngoscopy is crucial for accurate evaluation. Positron emission tomography in the detection of residual laryngeal carcinoma is also an important diagnostic tool. Recently, a novel automatic framework using 3D-large-scale pretrained models for laryngeal cancer detection has been proposed, which achieved promising performance in detecting laryngeal cancer with an accuracy of 92.4%, sensitivity of 95.6%, precision of 94.1%, and F₁ of 94.8%. This technology may potentially aid in the early detection and diagnosis of laryngeal cancer, allowing for more timely and effective treatment interventions.</p>
<p>What is Stridor? Enumerate the causes of Stridor. Describe briefly the management modalities of Stridor</p>	<p>Stridor is a high-pitched sound that occurs during breathing, typically due to an obstruction in the upper airway. It is a medical emergency that requires immediate attention. There are three main types of stridor: inspiratory, expiratory, and biphasic. Inspiratory stridor is associated with blockages above the vocal cords, expiratory stridor is related to blockages below the vocal cords, and biphasic stridor indicates a blockage at or below the vocal cords.</p> <p>The causes of stridor can be divided into two main categories: congenital and acquired.</p>

	<p>Congenital causes include laryngomalacia, tracheomalacia, and vocal cord paralysis. Acquired causes include foreign body aspiration, epiglottitis, croup, and angioedema.</p> <p>Other causes of stridor include tumors, goiter, and anaphylaxis. The pathophysiological mechanisms of stridor can vary, but common causes include laryngomalacia, croup, retropharyngeal abscess, epiglottitis, and craniofacial anomalies. These conditions can lead to turbulent airflow through the partially obstructed airway, resulting in the high-pitched wheezing sound known as stridor.</p> <p>The management modalities of stridor depend on the underlying cause. In general, securing the airway is the first priority, which may involve endotracheal intubation or a tracheostomy. Oxygen therapy and humidification may also be necessary to help manage symptoms. In some cases, medications such as corticosteroids, bronchodilators, or antihistamines may be prescribed to reduce inflammation and alleviate symptoms. In severe cases, surgical intervention may be necessary to remove any obstructions or repair any anatomical abnormalities.</p> <p>For inspiratory stridor, effective management strategies include treatment for symptom triggers and speech therapy.</p> <p>For expiratory stridor, strategies such as rigid bronchoscopy and inhaler devices are recommended. In the case of biphasic stridor, management strategies include treatment for symptom triggers, speech therapy, and, in some cases, surgical intervention. Additionally, educating patients on avoidance and prevention strategies, as well as managing comorbidities, is crucial for effective management.</p>
--	--

<p>Mention the differential diagnosis of white patch in Tonsil.</p>	<p>The differential diagnosis of a white patch in the tonsil can be caused by various conditions. Some of the possible causes include:</p> <ol style="list-style-type: none">1. Tonsilloliths: Also known as tonsil stones, these are small, hard white deposits that can form on the surface of the tonsils due to the accumulation of debris, bacteria, and dead cells.2. Oral candidiasis: This is a fungal infection caused by <i>Candida</i> species, which can produce white patches on the tonsils and other parts of the oral cavity.3. Leukoplakia: This is a condition characterized by the presence of white patches or plaques on the mucous membranes of the oral cavity, including the tonsils. It can be caused by chronic irritation, tobacco use, or other factors.4. Lichen planus: This is an inflammatory condition that can affect the mucous membranes of the oral cavity, including the tonsils, and produce white patches or lesions.5. Squamous cell carcinoma: In rare cases, a white patch on the tonsil can be a sign of squamous cell carcinoma, a type of cancer that can affect the tonsils and other parts of the oral cavity.6. Mononucleosis: Infectious mononucleosis, caused by the Epstein-Barr virus, can produce white patches on the tonsils due to the accumulation of lymphoid tissue.7. Streptococcal pharyngitis: This bacterial infection can produce white patches on the tonsils, as well as other symptoms such as sore throat and fever.8. Diphtheria: This bacterial infection can produce a white patch or membrane on the tonsils, as well as other symptoms such as sore throat and fever.9. Syphilis: In rare cases, a white patch on the tonsil can be a sign of syphilis, a sexually transmitted infection caused by the bacterium <i>Treponema pallidum</i>.
---	---

	<p>10. HIV/AIDS: People with HIV/AIDS may be more susceptible to various infections, including those that can cause white patches on the tonsils.</p> <p>These are just a few possible causes of a white patch on the tonsil. A proper diagnosis requires a thorough medical evaluation and may involve laboratory tests, imaging studies, and other diagnostic procedures. The specific characteristics of each condition, such as the size, shape, and color of the white patch, as well as any associated symptoms, can help narrow down the differential diagnosis. The importance of a thorough medical history and physical examination in making a diagnosis should also be emphasized. In addition, the possibility of other conditions such as leukoedema, traumatic granuloma, melanotic macule, and Bowen's disease should be considered in the differential diagnosis.</p> <p>It is also important to note that some white patches may be normal and benign, such as the ones caused by sebaceous glands. However, it is always best to consult a healthcare professional for a proper evaluation and diagnosis.</p>
Describe the diagnosis, complications and treatment of acute follicular tonsillitis.	<p>Acute follicular tonsillitis is a common condition characterized by inflammation of the tonsils, typically caused by a bacterial or viral infection. The diagnosis is often made based on clinical presentation, including symptoms such as sore throat, fever, and swollen tonsils with white or yellow patches. The Centor score is a useful tool in diagnosing acute tonsillitis, with a score of 3 or higher indicating a high likelihood of group A beta-hemolytic streptococcal infection. Laboratory tests, such as throat swabs and blood work, may also be used to confirm the diagnosis.</p> <p>Complications of acute follicular tonsillitis can</p>

	<p>include peritonsillar abscess, otitis media, and sinusitis.</p> <p>Treatment usually involves antibiotics, such as penicillin or amoxicillin, for bacterial infections, while viral infections are typically managed with supportive care, including pain management and hydration. In some cases, tonsillectomy may be necessary for recurrent or severe cases. Prevention of acute follicular tonsillitis can be achieved through good hygiene practices, such as frequent handwashing and avoiding close contact with individuals who are infected.</p> <p>Vaccination against certain bacterial infections, such as Haemophilus influenzae type b, can also help prevent acute follicular tonsillitis. There is limited information available on the long-term consequences of untreated or recurrent acute follicular tonsillitis, and no known impact on mental health. Further research is needed to fully understand the effects of this condition.</p>
<p>Give an account of aetiology, clinical features and treatment of Glue Ear</p>	<p>Glue ear, also known as otitis media with effusion (OME), is a condition in which the middle ear is filled with a thick, sticky fluid. The aetiology of glue ear is multifactorial, involving Eustachian tube dysfunction, infection, and allergy. Genetic predisposition has also been suggested to play a role in the development of glue ear.</p> <p>Clinical features of glue ear include hearing loss, ear fullness, and a sensation of blockage in the ear. In some cases, glue ear can cause discomfort, ear pain, or a feeling of pressure in the ear.</p> <p>The treatment of glue ear usually involves a combination of medical and surgical interventions. In some cases, the fluid may resolve on its own with</p>

	<p>time, but if the condition persists, treatment may be necessary. Medical treatments include the use of antibiotics, antihistamines, and decongestants. Surgical interventions include the insertion of tympanostomy tubes (grommets) to drain the fluid from the middle ear. This procedure is usually performed in children, as it helps to restore hearing and prevent complications. In some cases, adenoidectomy may also be recommended to remove the adenoids, which can contribute to Eustachian tube dysfunction.</p> <p>Additionally, alternative treatments such as autoinflation devices and nasal balloons can be used to alleviate Eustachian tube dysfunction. Genetic counseling can also play a crucial role in families with a history of glue ear, as it can help identify genetic mutations that may contribute to the development of OME. Genetic testing can be beneficial in identifying genetic risks, especially if there is a family history of early hearing loss.</p> <p>Overall, the treatment of glue ear should be individualized based on the severity of the condition, the age of the patient, and the presence of any underlying medical conditions. Early detection and treatment are crucial to prevent long-term complications, such as hearing loss, speech delay, and learning disabilities.</p>
<p>Define Menier's disease. Discuss the etiopathology, clinical features and management of the same.</p>	<p>Meniere's disease is a chronic and debilitating inner ear disorder characterized by a group of symptoms that include vertigo, tinnitus, hearing loss, and ear fullness.</p> <p>The etiopathology of Meniere's disease is not fully understood, but it is believed to be related to the abnormal production or regulation of endolymph, a fluid in the inner ear. This can lead to an increase in endolymphatic pressure, causing damage to the hair</p>

	<p>cells in the cochlea and vestibular system.</p> <p>The clinical features of Meniere's disease can vary in severity and frequency, but typically include recurring episodes of vertigo lasting from 20 minutes to several hours, tinnitus, hearing loss, and ear fullness.</p> <p>The management of Meniere's disease typically involves a combination of lifestyle modifications, medical therapies, and surgical interventions. Lifestyle modifications may include a low-sodium diet, avoidance of triggers such as caffeine and nicotine, and stress management techniques. Medical therapies may include diuretics, vestibular suppressants, and intratympanic injections of steroids or gentamicin. Surgical interventions may include endolymphatic sac surgery, labyrinthectomy, or cochlear implantation. Vestibular rehabilitation therapy (VRT) is also a valuable treatment option for patients with Meniere's disease, as it can help to improve balance and reduce symptoms of vertigo. There are different types of Meniere's disease, including classic Meniere's disease, vestibular Meniere's disease, and cochlear Meniere's disease. Each type has distinct clinical features and management strategies. Magnetic resonance imaging (MRI) may be used in the diagnosis of Meniere's disease to exclude retrocochlear pathology, such as a vestibular schwannoma. The goal of management is to reduce the frequency and severity of symptoms, improve hearing and balance function, and enhance the patient's quality of life.</p>
<p>Discuss the etiology, spread, clinical presentation and management of juvenile nasopharyngeal angiofibroma.</p>	<p>Juvenile nasopharyngeal angiofibroma (JNA) is a rare, benign, and highly vascular tumor that primarily affects adolescent males. The etiology of JNA is unknown, but it is believed to be related to hormonal influences, particularly androgens, as it</p>

	<p>often occurs during puberty and regresses after puberty. The tumor arises from the nasopharynx, specifically from the pterygopalatine foramen, and can extend into adjacent structures such as the nasal cavity, maxillary sinus, and orbit.</p> <p>The clinical presentation of JNA typically includes nasal obstruction, epistaxis, facial deformity, and hearing loss. The diagnosis is often made using imaging studies such as CT or MRI scans, which demonstrate the extent of the tumor and its relationship to surrounding structures.</p> <p>The management of JNA typically involves surgical excision, which can be challenging due to the tumor's vascularity and proximity to critical structures. Preoperative embolization may be used to reduce blood flow to the tumor, making surgical excision safer and more effective. Radiation therapy may be used in cases where surgical excision is not possible or in cases of residual or recurrent disease. Surgical approaches for JNA include endoscopic, endoscopic-assisted, and open resection. Endoscopic resection is often used for small- to intermediate-sized tumors, while open resection is typically used for larger tumors or those with significant intracranial or orbital extension. The choice of surgical approach depends on the stage of the tumor and the surgeon's experience.</p> <p>Recent studies have shown that endoscopic resection can be effective and safe, with decreased blood loss and lower recurrence rates compared to open resection. However, the surgical approach should be individualized based on the patient's specific tumor characteristics and medical history. Potential complications of surgical excision for JNA include bleeding, recurrence, and intracranial extension. To</p>
--	--

	<p>minimize these complications, preoperative embolization is recommended to decrease blood loss and related surgical complications. Intra-arterial embolization of JNA prior to surgical resection is the preferred approach to minimize complications.</p> <p>Advances in endoscopic surgery have also reduced overall surgical complications and post-surgical morbidity. It is crucial to have an experienced surgeon who is prepared to deal with many potential complications associated with current JNA open surgical approaches. The long-term outcomes and prognosis for patients with JNA are generally positive, with a high success rate in treatment, especially with surgery and radiotherapy. However, there may be side effects from treatment, and the condition can recur in some cases. Molecular markers and genetic testing may play a role in the diagnosis and management of JNA, particularly in females. A multidisciplinary approach to care is recommended to ensure optimal outcomes for patients with JNA.</p>
<p>Discuss the aetiopathology, of malignant tumors of the maxilla. Add a note on investigations and its surgical management</p>	<p>Malignant tumors of the maxilla are abnormal growths that originate from the cells lining the maxillary sinus. The aetiopathology of these tumors can be attributed to various factors, including genetic predisposition, environmental factors, and exposure to carcinogens. The most common types of malignant tumors affecting the maxilla are squamous cell carcinoma, adenocarcinoma, and adenoid cystic carcinoma. The symptoms of these tumors can include nasal obstruction, epistaxis, facial pain, and swelling.</p> <p>The investigations for diagnosing malignant tumors of the maxilla include computed tomography (CT) scans, magnetic resonance imaging (MRI), and positron emission tomography (PET) scans. A biopsy</p>

	<p>is also necessary to confirm the diagnosis and determine the type of tumor. \n\nThe surgical management of malignant tumors of the maxilla depends on the type, size, and location of the tumor. The primary goal of surgery is to remove the tumor completely, while preserving the surrounding tissues and structures. The surgical approaches can include a maxillectomy (removal of the maxilla), a partial maxillectomy (removal of a portion of the maxilla), or an endoscopic approach. Reconstruction of the maxilla and surrounding tissues may also be necessary to restore function and aesthetics.</p> <p>Recent research has shown that some genetic modifications have been researched to perhaps show some neoplastic potential of various odontogenic tumors to include the ameloblastoma. Whether this becomes Ameloblastoma: Intraosseous Type. Tumors of the posterior maxilla that involve the orbit are the most difficult to treat and manage. Undoubtedly such lesions will be present with unique and specific problems related to the individual case.</p> <p>Genetic mutations and environmental factors contribute to the development of malignant tumors of the maxilla. These include genetic predisposition, environmental exposures, and viral infections such as HPV. For surgical approaches, the choice of treatment depends on factors like the location and size of the tumor, patient's overall health, and the surgeon's preference. Common surgical approaches include open surgery, endoscopic surgery, and robotic surgery. The treatment options for head and neck cancers include surgery, chemotherapy, radiation therapy, targeted therapy, and immunotherapy.</p> <p>Malignant tumors of the maxilla can lead to</p>
--	---

	<p>complications such as osteonecrosis of the jaw, dental issues, and potentially poor quality of life. The overall 5-year survival rate for patients with maxillary sinus cancer is 30% to 50%. The most common locations for these tumors are the nasal cavity and the maxillary sinus. Treatment options may include surgery, radiation therapy, and chemotherapy, with a mean duration of follow-up of 38.9 months. The 3- and 5-year survival estimates are 60.7% and 52.4% for overall survival, 62.6% and 57.2% for disease-specific survival, and 47.5% and 41.0% for recurrence-free survival.</p>
<p>Discuss in etiology, clinical features, and management of StictureOesophagus</p>	<p>Etiology of Stricture Oesophagus:</p> <p>Stricture oesophagus, also known as oesophageal stricture, is a condition where the oesophagus narrows due to the formation of scar tissue. The most common causes of oesophageal stricture include gastroesophageal reflux disease (GERD), where stomach acid flows back into the oesophagus and causes inflammation and scarring, and oesophageal cancer. Other causes include swallowing corrosive substances, radiation therapy, and certain medications.</p> <p>Clinical Features of Stricture Oesophagus:</p> <p>The main symptom of oesophageal stricture is difficulty swallowing, which can lead to malnutrition and weight loss. Other symptoms include regurgitation of food, chest pain, and coughing. The symptoms may worsen over time as the stricture becomes narrower.</p> <p>Management of Stricture Oesophagus:</p> <p>The main goal of treatment is to relieve the obstruction and restore normal swallowing. The</p>

	<p>treatment options include endoscopic dilation, where a flexible tube with a balloon or dilator is inserted through the mouth to widen the stricture, and stenting, where a metal or plastic tube is placed in the stricture to keep it open. In some cases, surgery may be necessary to remove the stricture and repair the oesophagus.</p> <p>Medications such as proton pump inhibitors may be prescribed to reduce acid production in the stomach and prevent further scarring.</p> <p>In severe cases, a feeding tube may be inserted through the nose or abdomen to provide nutrition until the stricture can be treated.</p> <p>Diagnostic Tests:</p> <p>The diagnosis of oesophageal stricture is typically made using endoscopy and barium swallow. Endoscopy allows for the direct visualization of the oesophagus and the collection of tissue samples for biopsy. Barium swallow is a radiographic test that uses a contrast agent to visualize the oesophagus and detect any narrowing or obstruction.</p> <p>Potential Complications:</p> <p>Oesophageal stricture can lead to several complications, including perforation, bleeding, and narrowing of the oesophagus. In severe cases, the stricture can cause complete obstruction of the oesophagus, leading to severe malnutrition and weight loss.</p> <p>Treatment of Esophageal Strictures:</p> <p>Early studies employing the treatment of esophageal</p>
--	--

	<p>strictures were obtained by resting the oesophagus, which may be accomplished by performing a gastrostomy and using antibiotics. Another method is passing a string through the oesophagus and bringing it out through the gastrostomy. The upper end of the string is brought out through the nose and tied to the lower end, so that there is a continuous loop of string through the oesophagus. If possible, the patient can facilitate placement of the string by swallowing it. If not, it can be done during oesophagoscopy.</p> <p>Retrograde bougienage may be started after three to six weeks, after the first oesophagogram, when the gastrostomy stoma is mature enough and when there is less risk of perforation.</p> <p>Extrinsic Compression:</p> <p>Extrinsic compression of the oesophagus can be caused by degenerative disease of the spine, infection, or other conditions. The most frequent source of external compression of the pharynx and oesophagus is degenerative disease of the spine. Anterior vertebral osteophytes create an undulating posterior impression on fluoroscopy. In severe cases, cervical osteophytes may cause dysphagia or may interfere with inversion of the epiglottis and cause aspiration.</p> <p>Assessment of Stricture:</p> <p>Fluoroscopy is considered superior to endoscopy for the assessment of strictures. Patients may be given a 13-mm barium tablet to determine whether a stricture is functionally obstructing. Videofluoroscopy using barium provides a qualitative assessment of oesophageal motility and the presence of a stricture.</p> <p>Long-term Management:</p>
--	---

	<p>Long-term management options for oesophageal stricture include stenting, dilation, and surgery. Potential complications of treatment can range from minor issues like delayed skin healing and suture site infection to more significant concerns such as distal stent migration.</p> <p>Innovative Conservative Treatment:</p> <p>An innovative conservative treatment involving combined radial incision and steroid injection has been found to be effective in avoiding potential complicated redo pull-through surgery for colorectal stenosis after pull-through surgery in Hirschsprung disease. This method has shown promising results in improving refractory anastomotic stenosis, with a significant portion of patients experiencing improvement and avoiding further surgery. However, it is essential to note that some cases may require additional treatments or even a redo pull-through.</p>
<p>Complications of Chronic Otitis Media-Factors in the spread of infection, classification. Discuss in detail about Lateral Sinus Thrombosis.</p>	<p>Chronic Otitis Media (COM) is a persistent and recurring infection of the middle ear that can lead to various complications if left untreated or inadequately managed. One of the severe complications of COM is Lateral Sinus Thrombosis (LST), which occurs when an infection spreads from the middle ear to the sigmoid sinus, causing thrombophlebitis. This can lead to serious consequences such as cavernous sinus thrombosis, brain abscess, and sepsis. The pathophysiology of LST involves the formation of a thrombus in the sigmoid sinus, which can be caused by erosion of bone from coalescent mastoiditis or cholesteatoma, or by osteothrombophlebitic extension via small venules that thrombose and propagate into the sinus.</p> <p>Recent studies have highlighted the importance of</p>

	<p>early and accurate diagnosis of LST, as well as the need for comprehensive treatment strategies to prevent severe complications and improve treatment outcomes. Considering Tuberculous Otitis Media (TOM) in the differential diagnosis of chronic ear infections is crucial, especially in cases of persistent otorrhea unresponsive to standard antimicrobial therapy. Prompt recognition and initiation of appropriate antituberculous treatment, along with surgical intervention when indicated, can prevent severe complications such as Bezold's abscess.</p> <p>The management of LST is complex and requires careful consideration of the underlying pathophysiology, as well as the potential risks and benefits of different treatment modalities. Antimicrobial therapy, anticoagulation, and surgical intervention may be necessary to manage the infection and prevent further complications. However, larger, prospective cohort studies are required to provide more definitive insights into the prevention strategies for Lateral Sinus Thrombosis in patients with Chronic Otitis Media.</p> <p>In conclusion, LST is a serious complication of COM that requires prompt diagnosis and treatment. A comprehensive approach to diagnosis and treatment, including consideration of TOM and other potential causes of LST, is essential for preventing severe complications and improving treatment outcomes.", "reflection": {"missing": "A more detailed discussion on the molecular mechanisms underlying the development of LST and the role of molecular mechanisms in the development of this complication would strengthen the answer. Additionally, a comparison of different treatment modalities and their outcomes would provide a more comprehensive understanding of LST management.</p>
--	--

<p>Acquired Immuno Deficiency Syndrome-AIDS in ENT – Discuss</p>	<p>Acquired Immuno Deficiency Syndrome (AIDS) is a condition that affects the immune system, making it challenging for the body to fight off infections and diseases. In the field of Ear, Nose, and Throat (ENT), AIDS can manifest in various ways, affecting the head and neck region. ENT specialists play a crucial role in diagnosing and managing these conditions, often in collaboration with other healthcare professionals.</p> <p>Current treatment guidelines for ENT-related conditions in AIDS patients include the use of antifungal medications, such as posaconazole, to treat oropharyngeal candidiasis. Radiation therapy is recommended for patients with nasopharyngeal carcinoma, often combined with chemotherapy. Surgical management is considered when necessary, and leading-edge treatments are available for various ENT disorders.</p> <p>Additionally, hearing aids are a viable option for patients with hearing loss, with a high satisfaction rate amongst patients. ENT specialists provide comprehensive care, including audiology services, for all aspects of head and neck disease. A thorough understanding of the complex interplay between AIDS and ENT-related conditions is essential for providing optimal care to affected individuals. ENT specialists must stay up-to-date with the latest research and treatment guidelines to ensure that patients receive the best possible outcomes. By working collaboratively with other healthcare professionals and acknowledging the social and psychological impact of AIDS, ENT specialists can improve patient outcomes and quality of life. The latest advancements in antiretroviral therapies and immunotherapy for HPV-related cancers in AIDS patients are primarily focused on enhancing</p>
--	---

	<p>predictive capabilities for treatment outcomes.</p> <p>Researchers are exploring new methods to weigh mutations, taking into account their historical occurrence, and concomitant viral load measurements. This approach demonstrates a superior discriminative ability with a higher ROC-AUC score compared to models not using historical information.</p> <p>Furthermore, there is ongoing research on various strategies to enhance treatment outcomes, including the potential unintended consequences of disability grants programs on HIV/AIDS recovery. ENT specialists should be aware of these developments and consider the complex interplay between AIDS, ENT-related conditions, and social factors when providing care to affected individuals. Reflection on the current treatment options for ENT-related conditions in AIDS patients highlights the need for a comprehensive approach to care, including antifungal medications, radiation therapy, surgical management, and preventive measures. Furthermore, ENT specialists should be aware of the current research in the field, including the development of new antiretroviral therapies and the use of immunotherapy for HPV-related cancers</p>
<p>Enumerate the peripheral vestibular causes of vertigo. Discuss the pathophysiology, clinical features and management of Benign Positional Paroxysmal Vertigo.</p>	<p>Peripheral vestibular causes of vertigo include Benign Positional Paroxysmal Vertigo (BPPV), Meniere's disease, Vestibular neuritis, Labyrinthitis, and Perilymph fistula. BPPV is the most common cause of peripheral vestibular vertigo.</p> <p>The pathophysiology of BPPV involves the dislodgement of small calcium particles called otoconia from the utricular macula and their subsequent movement into the semicircular canals, where they can cause abnormal stimulation of the</p>

	<p>vestibular hair cells. This leads to brief but intense episodes of vertigo, lasting from a few seconds to a few minutes, triggered by specific head movements. The Dix-Hallpike maneuver is a diagnostic test used to diagnose BPPV.</p> <p>Management of BPPV includes Canalith repositioning procedures (CRP), such as the Epley maneuver, which involves a series of head and body movements to move the otoconia back into their normal position in the utricle. CRP has been shown to be effective in improving symptoms of BPPV, with studies demonstrating significant improvements in patients undergoing this procedure. Vestibular rehabilitation exercises, such as those used in Vestibular Rehabilitation Therapy (VRT), can also be beneficial in reducing balance issues and improving quality of life.</p> <p>Additionally, anti-vertigo medications, such as prochlorperazine and antihistamines, can help alleviate symptoms of vertigo. However, it is essential to note that some medications can also cause vertigo, and therefore, it is crucial to carefully evaluate the potential benefits and risks of any medication before prescribing it. The age of onset of BPPV is usually during the fifth through seventh decades of life, and the elderly are at an increased risk.</p> <p>Several clinical features may suggest a central cause of vertigo rather than BPPV, including downbeating nystagmus on the Dix-Hallpike maneuver and direction-changing nystagmus. Clinicians must consider the possibility of more than one vestibular disorder being present in any patient who does not clearly have the specific symptoms of a single vestibular entity. Proper diagnosis and treatment of</p>
--	--

	<p>BPPV are crucial for preventing complications and improving patient outcomes. A thorough medical history and physical examination are essential tools in diagnosing BPPV, as they can help distinguish between benign and urgent causes of vertigo and guide the development of appropriate treatment plans.</p>
<p>Write an essay on the operative procedure of Tracheostomy, its complications and types of Tracheostomy tubes.</p>	<p>A tracheostomy is a surgical procedure that involves creating an airway in the trachea, or windpipe, to facilitate breathing. The procedure is typically performed in an operating room under general anesthesia, although it can also be done at the bedside in emergency situations.</p> <p>The operative procedure of tracheostomy involves making a small incision in the skin of the neck, followed by a vertical incision through the pretracheal fascia. The thyroid gland is then retracted upwards, and the pretracheal muscles are divided to expose the trachea. A tracheal hook is used to retract the trachea upwards, and a tracheostomy tube is inserted through the opening. The tube is secured in place with sutures or ties. There are several types of tracheostomy tubes, including cuffed and uncuffed tubes. Cuffed tubes have an inflatable cuff that prevents air from leaking around the tube, while uncuffed tubes do not have a cuff and are used for patients who require long-term ventilation.</p> <p>Tracheostomy tubes can also be classified as fenestrated or non-fenestrated. Fenestrated tubes have holes in the tube that allow air to pass through, while non-fenestrated tubes do not have holes.</p> <p>The indications for the use of fenestrated tracheostomy tubes include the need for airflow through the larynx to facilitate speech, and the need for airflow through the nasopharynx to allow for filtration and humidification of inspired air.</p>

	<p>Complications of tracheostomy include bleeding, infection, and subcutaneous emphysema. Bleeding can occur due to injury to the anterior jugular vein or other surrounding vessels. Infection can occur due to bacterial colonization of the tube or surrounding tissue. Subcutaneous emphysema occurs when air leaks into the tissue surrounding the trachea. Other complications include tracheal stenosis, granulation tissue formation, and accidental decannulation.</p> <p>Tracheal stenosis occurs when the trachea narrows due to scarring or inflammation. Granulation tissue formation occurs when tissue grows over the tracheostomy tube, causing obstruction. Accidental decannulation occurs when the tube becomes dislodged, which can lead to respiratory distress.</p> <p>To prevent these complications, proper technique during the tracheostomy procedure is crucial, such as avoiding opening the trachea above the second ring and excessive removal of the anterior wall. Additionally, maintaining optimal cuff pressure, regularly cleaning and changing the tracheostomy tube, and ensuring the tube is properly secured can help reduce the risk of complications. Regular follow-up with healthcare providers and adherence to their advice is also important in preventing complications.</p> <p>The tracheostomy procedure involves several techniques, including open tracheostomy, percutaneous tracheostomy, and bedside tracheostomy. Each technique has its own set of risks and complications. For instance, open tracheostomy carries a higher risk of bleeding and wound infection compared to percutaneous tracheostomy, which is associated with a higher risk of tracheal stenosis.</p>
--	--

	<p>Bedside tracheostomy, on the other hand, is less invasive and has a lower risk of complications compared to open tracheostomy. To minimize the risk of complications, it is essential to choose the appropriate technique based on the patient's condition and the surgeon's expertise. Additionally, proper preoperative preparation, careful surgical technique, and postoperative care can significantly reduce the risk of complications. The main advantages of open tracheostomy include the ability to talk and the potential elimination of the need for care in an intensive care unit. Percutaneous dilatational tracheostomy (PDT) offers advantages such as simplicity, smaller incision, less tissue trauma, lower incidence of wound infection, lower incidence of wound complications, and lower mortality. It is also less invasive and faster to perform than surgical tracheostomy. However, it has potential drawbacks like the risk of foreign body aspiration through the open tracheostomy tube. Minimally invasive tracheotomy has been shown to have several benefits, including reduced peristomal problems, and combines with it the advantages of surgical tracheostomy.</p>
<p>Describe the aetiology, clinical features and management of Rhinosporidiosis.</p>	<p>Rhinosporidiosis is a chronic, granulomatous infection of the mucous membranes caused by <i>Rhinosporidium seeberi</i>, an organism that was once thought to be a fungus but is now classified as a protist.</p> <p>The aetiology of Rhinosporidiosis is not fully understood, but it is believed to be aquatic in origin and is often associated with exposure to contaminated water.</p> <p>The clinical features of Rhinosporidiosis typically include the formation of polypoid masses on the nasal mucosa, conjunctiva, or other mucous</p>

	<p>membranes, which can cause symptoms such as nasal obstruction, epistaxis, and blurred vision.</p> <p>The diagnosis of Rhinosporidiosis is typically made based on histopathological examination of tissue samples, which reveal the characteristic sporangia of <i>Rhinosporidium seeberi</i>.</p> <p>The management of Rhinosporidiosis usually involves surgical excision of the affected tissue with electrocoagulation of the base, which is the main treatment. Dapsone therapy is also recommended as an adjunct treatment option to prevent recurrence. Other treatment options include Coblation EVAC 70, a novel surgical tool that has shown promising results in the management of this disease. Medical treatment alone is generally ineffective, and screening antiparasitic drugs may improve the treatment outcomes.</p> <p>Rhinosporidiosis can manifest in different forms, including nasal, ocular, mucosal, cutaneous, or disseminated, and treatment options may vary depending on the form of the disease. Prevention and control measures include avoiding potential sources of infection, such as contaminated water and contact with infected animals. Potential complications of the disease include recurrence, dissemination to adjacent anatomic sites, and local secondary bacterial infections. Early medical attention is essential to minimize the risk of these complications.</p>
<p>Enumerate in detail the various causes of epistaxis. How will you manage epistaxis in a 6 year old child?</p>	<p>The causes of epistaxis can be broadly classified into two main categories: traumatic and non-traumatic.</p> <p>Traumatic causes include nasal trauma, foreign body insertion, and nasal or facial fractures. Non-traumatic causes include dry air, allergies, colds, sinusitis, high blood pressure, bleeding disorders, and the use of</p>

	<p>certain medications such as anticoagulants and NSAIDs. In children, the most common cause of epistaxis is digital trauma, also known as nose picking. Other causes in children include allergies, upper respiratory tract infections, and foreign body insertion.</p> <p>To manage epistaxis in a 6-year-old child, the first step is to remain calm and reassure the child. The child should be seated upright and leaned forward to prevent blood from flowing down the back of the throat. The nose should be pinched shut using a clean cloth or gauze for 5-10 minutes to apply pressure to the nasal septum. If the bleeding does not stop, the process can be repeated for another 10 minutes. If the bleeding persists, the child should be taken to a healthcare professional for further evaluation and management. The healthcare professional may use topical anesthetics and vasoconstrictors, such as lidocaine and oxymetazoline, to help control the bleeding. In some cases, nasal packing or cauterization may be necessary to control the bleeding.</p> <p>In terms of nasal packing, it may be performed using gauze or nasal tampons that expand with the addition of saline. A nasal tampon is placed by first applying topical anesthetic/analgesic intranasally, and coating the pack with antibiotic ointment, sliding the tampon into place, and expanding with saline application.</p> <p>Cauterization is also an effective method for controlling bleeding in children. In cooperative children, the addition of silver nitrate cautery has been shown to be highly effective in addressing prominent septal vessels.</p> <p>In addition to treating the acute episode of epistaxis,</p>
--	--

	<p>it is also important to identify and address any underlying causes of the bleeding. This may include treating allergies or infections, and educating the child and parents on how to prevent future episodes of epistaxis.</p> <p>In terms of prevention, educating the child on the importance of not picking their nose and avoiding blowing their nose too forcefully can help to reduce the risk of future episodes of epistaxis. Using a humidifier in the home, especially during the dry winter months, can also help to keep the nasal passages moist and reduce the risk of bleeding.</p> <p>\n\nIn cases of recurrent severe epistaxis, further investigation for hematologic disorder, tumor, or other rare conditions should be warranted.</p> <p>Approximately 6% of the population will experience a nosebleed that requires medical intervention. Nasal cautery, septoplasty, and nasal packing are common treatments for epistaxis in children. These interventions are often used when other treatments fail or if the bleeding is more severe, such as in the case of posterior epistaxis.</p>
<p>Describe in detail etiopathogenesis, clinical features and management of a patient with nasopharyngeal carcinoma.</p>	<p>Nasopharyngeal carcinoma (NPC) is a rare type of cancer that originates in the nasopharynx, which is the upper part of the pharynx (throat) behind the nasal cavity.</p> <p>The etiopathogenesis of NPC involves a combination of genetic and environmental factors, including Epstein-Barr virus (EBV) infection, which is detected in the tumor cells of most patients with NPC. Other risk factors include a family history of NPC, tobacco smoking, and consumption of salted fish, which contains carcinogenic compounds. The clinical features of NPC include nasal symptoms such as nasal obstruction, epistaxis (nosebleeds), and rhinorrhea (runny nose), as well as otological</p>

	<p>symptoms such as hearing loss, tinnitus (ringing in the ears), and otalgia (ear pain). Patients may also experience neck masses or pain, and in advanced cases, cranial nerve palsies and metastatic disease.</p> <p>The diagnosis of NPC is typically made by a combination of imaging studies, including computed tomography (CT) and magnetic resonance imaging (MRI), and biopsy of the tumor.</p> <p>The management of NPC involves a multidisciplinary approach, including surgery, radiation therapy, and chemotherapy. Early-stage NPC is typically treated with radiation therapy, while advanced-stage disease may require a combination of radiation and chemotherapy. Surgery may be necessary for patients with residual or recurrent disease. Palliative care is also an essential aspect of NPC management, as many patients experience significant symptoms and side effects from their disease and treatment. The molecular biology of NPC is closely linked with the role of EBV in the development of the disease. EBV infection is a major risk factor for NPC, particularly in southern China and Southeast Asia. The interplay between EBV infection and genetic factors contributes to the pathogenesis of NPC. High endothelial venules are also seen in NPC tissues, suggesting a potential role in NPC metastasis. Further studies are needed to understand the molecular basis of NPC and the role of EBV genomic variations in the pathogenesis of NPC.</p> <p>In terms of treatment, a better understanding of the molecular biology of NPC may lead to the development of targeted therapies, such as EBV-specific vaccines or gene therapy. Additionally, early detection and screening for NPC, particularly in</p>
--	--

	<p>high-risk populations, may improve treatment outcomes and survival rates. Recent studies have also shed light on the importance of endothelial cell networks and cell development in understanding the pathogenesis of NPC. For instance, mathematical models of endothelial cell networks have been developed to quantify the connectivity of these networks and their relation to function. Furthermore, studies on cell development have shown that the optimization of eukaryotic cell development obeys maximal intracellular flux of messenger proteins, which may have implications for understanding the development of NPC.</p> <p>Overall, a comprehensive understanding of the molecular biology of NPC, including the role of EBV, endothelial cell networks, and cell development, is crucial for the development of effective treatment strategies and improvement of patient outcomes. NPCs have been shown to promote the formation of stable vascular networks when co-cultured with endothelial cells. Additionally, NPCs can be used to improve kidney function and replenish the renal cortex by inducing the growth of new endothelial cells. In conclusion, the molecular biology of NPC is a complex and multifaceted field that requires further research to understand the role of EBV, endothelial cell networks, and cell development in the pathogenesis of NPC. A comprehensive understanding of these factors is crucial for the development of effective treatment strategies and improvement of patient outcomes.</p>
Briefly discuss the functions and indications of Tracheostomy.	A tracheostomy is a surgical procedure that involves creating an airway in the trachea, or windpipe, to facilitate breathing. It is typically performed in patients who have difficulty breathing due to an obstruction in the upper airway or who require long-term mechanical ventilation.

	<p>The primary function of a tracheostomy is to provide a safe and stable airway, allowing for the removal of secretions and the delivery of oxygen and anesthetics. There are different types of tracheostomy procedures, including percutaneous tracheostomy and open tracheostomy. Percutaneous tracheostomy is a bedside procedure that involves inserting a tracheostomy tube through the skin and into the trachea using a dilational technique. Open tracheostomy, on the other hand, is a surgical procedure that involves making an incision in the neck and opening a hole in the trachea to insert the tracheostomy tube. The choice of procedure depends on the individual patient's needs and medical condition.</p> <p>The indications for tracheostomy include upper airway obstruction, respiratory failure, and the need for prolonged mechanical ventilation. Other indications include severe maxillofacial trauma, severe burns, and neurological disorders that affect breathing. Post-operative care is crucial to prevent complications, such as bleeding, infection, and accidental decannulation. Studies have shown that percutaneous tracheostomy is as safe as open tracheostomy in critically ill patients, with similar long-term complications. However, there is a lack of prospective data, and some critics argue that potentially complicated airways require open procedures.</p> <p>Additionally, there is a risk of crushing tracheal rings during percutaneous tracheotomy, which can cause long-term tracheal stenosis and/or tracheomalacia. Long-term care and management of tracheostomy patients is a complex process that requires comprehensive healthcare needs, including upper</p>
--	---

	<p>airway and tracheostomy management, and patients often require special medical equipment, supplies, and treatments. The presence of a healthcare provider is crucial for training the family and surrogate on ventilator management and tracheostomy care. Better coordinated management of tracheostomy patients is necessary to improve patient outcomes and reduce healthcare costs.</p> <p>For invasive long-term mechanical ventilation in the home, a tracheostomy tube is required, along with certain medical supplies to facilitate care. These supplies may include a specific number of units for billing purposes and claim adjudication and may be covered under various insurance plans or programs.</p> <p>It is recommended to rent equipment for a trial or short-term period if the medical professional and/or the member is not certain the medical equipment will be useful. Tracheostomy care and equipment costs can vary, but standardizing tracheostomy tubes can reduce healthcare costs. A typical tracheostomy care kit includes face masks, airway adjuncts, supraglottic airway devices, laryngoscopes, endotracheal tubes, suction devices, and other supplies. Tracheostomy care guidelines emphasize the importance of routine care to prevent infection and obstruction, frequent suctioning to maintain a patent airway, and the use of minimum occlusive volume/minimum cuff pressure for tracheostomy cuffs. Healthcare providers and family members caring for a patient with a tracheostomy can receive practical help, guidance, and support from professional organizations and clinics specializing in tracheostomy care.</p> <p>Tracheostomy care in community settings has high rates of readmission and mortality due to airway-related adverse events, highlighting the need for</p>
--	---

	<p>proper care and equipment. Pediatric tracheostomy care requires specialized equipment and supplies, as well as specific guidelines for their management and care. A tracheostomy is a surgical opening in the anterior wall of the trachea to facilitate ventilation, and the opening is usually maintained by use of a tracheostomy tube. Insurance coverage for tracheostomy care and equipment is available through Medicare and other health insurance providers if prescribed by a doctor for home use. Patients can rent or buy the necessary equipment, and standardizing tracheostomy tubes can reduce healthcare costs. Overall, tracheostomy is a life-saving procedure that can significantly improve the quality of life for patients with severe respiratory disorders.</p>
--	---