

1 Variants in *NR6A1* cause a novel oculo-vertebral-renal (OVR) syndrome

2

3 Uma M. Neelathi^{1*}, Ehsan Ullah^{1*}, Aman George¹, Mara I. Maftai², Elangovan Boobalan¹, Daniel
4 Sanchez-Mendoza¹, Chloe Adams¹, David McGaughey¹, Yuri V. Sergeev¹, Ranya AI Rawi¹, Amelia Naik
5 ¹, Chelsea Bender¹, Irene H. Maumenee³, Michel Michaelides^{2,4}, Tun Giap Tan⁵, Siying Lin^{2,4}, Rafael
6 Villasmil⁶, Delphine Blain¹, Robert B. Hufnagel^{1,7}, Gavin Arno^{2,8}, Rodrigo M. Young^{2,9**}, Bin Guan^{1**},
7 Brian P. Brooks^{1,10**}

8

- 9 1. Ophthalmic Genetics & Visual Function Branch, National Eye Institute, National Institutes of
10 Health, Bethesda, MD 20892.
11 2. UCL Institute of Ophthalmology, University College, London, London, UK
12 3. Harkness Eye Institute, Columbia University, 622 W 168th St., New York, NY 10032
13 4. Moorfields Eye Hospital, NHS Foundation Trust, London, UK
14 5. Torbay Hospital, Torbay and South Devon NHS Foundation Trust, Devon, UK
15 6. Flow Cytometry Core, National Eye Institute, Bethesda, MD 20892
16 7. Center for Integrated Health Care Research, Kaiser Permanente Hawai'i; Hawai'i
17 Permanente Medical Group, Honolulu, HI
18 8. Greenwood Genetic Center, Greenwood, SC 29646
19 9. Center for Integrative Biology, Universidad Mayor, Santiago, Chile
20 10. To whom correspondence should be addressed

21 *Co-first authors

22 **Co-senior authors

23 Uma M. Neelathi (0000-0003-4870-4747), Ehsan Ullah (0000-0003-0107-6608), Aman George
24 (0000-0003-4315-7617), Mara I. Maftai (0009-0000-4370-759X), Elangovan Boobalan (0009-0000-
25 2494-0927), Daniel Sanchez-Mendoza (0009-0005-1941-3205), Chloe Adams (0009-0007-0785-
26 5641), David McGaughey (0000-0002-9224-2888), Yuri Sergeev (0000-0002-7204-6572), Amelia
27 Naik (0000-0001-7764-3619), Michel Michaelides (0000-0001-9435-2389), Tun Giap Tan (0000-
28 0002-7033-9662), Siying Lin (0000-0003-1122-8396), Rafael Villasmil (0000-0002-8956-2979),
29 Delphine Blain (0000-0002-9275-5827), Robert B. Hufnagel (0000-0003-3015-3545), Gavin Arno
30 (0000-0002-6165-7888), Rodrigo M. Young (0000-0001-5765-197X), Bin Guan (0000-0001-5986-
31 5189), Brian P. Brooks (0000-0002-1926-7551)

32

33 **Abstract**

34 Colobomatous microphthalmia is a potentially blinding congenital ocular malformation that can present
35 either in isolation or together with other syndromic features. Despite a strong genetic component to
36 disease, many cases lack a molecular diagnosis. We describe a novel autosomal dominant oculo-vertebral-
37 renal (OVR) syndrome in six independent families characterized by colobomatous microphthalmia,
38 missing vertebrae and congenital kidney abnormalities. Genome sequencing identified six rare variants in
39 the orphan nuclear receptor gene *NR6A1* in these families. We performed in silico, cellular and zebrafish
40 experiments to demonstrate the *NR6A1* variants were pathogenic or likely pathogenic for OVR syndrome.
41 Knockdown of either or both zebrafish paralogs of *NR6A1* results in abnormal eye and somite
42 development, which was rescued by wild-type but not variant *NR6A1* mRNA. Illustrating the power of
43 genomic ascertainment in medicine, our study establishes *NR6A1* as a critical factor in eye and vertebral
44 development and a pleiotropic gene responsible for OVR syndrome.

45

46 **Introduction**

47 Uveal coloboma is a congenital ocular malformation caused by failure of the ventral optic fissure
48 to close during early eye morphogenesis and is usually considered on a phenotypic continuum with
49 microphthalmia and anophthalmia¹⁻⁵. A rare condition⁶⁻¹¹, coloboma may nonetheless account for up to
50 10% of childhood blindness¹². Although significant progress has been made in identifying genes
51 associated with syndromic and non-syndromic coloboma, the yield of diagnostic testing remains low,
52 especially for isolated, non-syndromic coloboma, suggesting other genes are yet to be discovered¹³⁻¹⁵. To
53 identify novel coloboma genes, the National Eye Institute has conducted a natural history study since
54 2006, on the genetics of coloboma that includes systematic deep phenotyping of probands and first-
55 degree family members. We have previously identified a novel syndrome characterized by missing
56 vertebrae (in the thoracic and/or lumbar spine) and uveal coloboma, inherited in an autosomal dominant
57 fashion with incomplete penetrance and variable expressivity¹⁶.

58 We identified structural and sequence variants in the transcription factor gene *NR6A1* (*Nuclear*
59 *receptor subfamily 6, group A, member 1*, OMIM*602778) in three families by genome sequencing (GS).
60 These results were extended via analysis of the Genomics England 100,000 Genomes Project (UK100KGP),
61 where three additional individuals with microphthalmia/anophthalmia/coloboma were identified¹⁷.

62 Originally termed germ cell nuclear factor (*GCNF*)/retinoid receptor-related testis-associated
63 receptor (*RTR*), *NR6A1* is an orphan member of the nuclear hormone receptor family of transcription
64 factors, often acting as a transcriptional repressor. *NR6A1* is highly expressed in embryonic and other stem
65 cells from various tissues (especially testes) and is repressed upon differentiation¹⁸. *NR6A1* plays an
66 important role in somite and subsequent vertebral development in mice, and in livestock species it is
67 correlated with vertebral number¹⁹⁻²². To our knowledge there are no reports on the role of *NR6A1* in eye
68 or kidney development.

69 Here we described a novel autosomal dominant oculo-vertebral-renal (OVR) syndrome caused by
70 variants in the orphan nuclear receptor gene *NR6A1*, supporting the pathogenicity of variants through a
71 combination of in silico, in vitro and in vivo investigations. To our knowledge, this is first mendelian trait
72 in humans characterized by missing vertebrae.

73 **Methods**

74 **Patients and clinical studies**

75 Complete eye examinations and genetic testing at the National Eye Institute (NEI) were conducted
76 under IRB-approved clinical protocols (NCT01778543, NCT01087320, NCT02077894,
77 www.clinicaltrials.gov). Probands underwent systemic testing as clinically indicated, which include
78 physical exam, kidney ultrasound, routine blood chemistries, audiology, and spine x-ray. Eye
79 examinations included age-appropriate testing of visual acuity, refraction, ocular motility/alignment, slit
80 lamp exam, dilated fundus exam and ophthalmic photography. Specific informed consent for
81 exome/genome sequencing was obtained under an IRB-approved protocol along with pre- and post-test
82 genetic counseling (NCT02077894). Family COL005 and COL034 were previously reported as Family 1 and
83 2, respectively, without molecular characterization and detailed individual phenotyping data¹⁶. For
84 patients and relatives recruited from the Genomics England 100,000 Genomes Project (UK100KGP),
85 informed consent for whole genome sequencing (GS) was obtained in accordance with approval from the

86 HRA committee East of England-Cambridge south (REC 14/EE/1112)¹⁷. Details of gene/protein expression,
87 bioinformatic, molecular modeling, and zebrafish experiments are described in detail in Supplemental
88 Materials and Methods.

89

90 **Results**

91 ***Variants in NR6A1 cause an oculo-vertebral-renal (OVR) syndrome***

92 We identified three rare *NR6A1* variants in three families affected by uveal coloboma (COL005,
93 COL034, COL171) with or without microphthalmia, cataract, and missing vertebrae through genome
94 sequencing. In cases where multiple generations are affected, transmission is autosomal dominant with
95 incomplete penetrance and variable expressivity (Fig. 1A). (Note that, in compliance with MedRx policy
96 regarding potentially identifying information, all panels of Figure 1 have been deleted from the preprint
97 server but are available upon request from the corresponding author). Clinical data for all the participants
98 with a positive molecular result is shown Table 1. No other candidate pathogenic variants in *NR6A1* were
99 identified in the NEI coloboma cohort consisting of a total of 224 probands (66 analyzed by genome
100 sequencing, 57 by exome sequencing, and 101 by amplicon sequencing).

101 The proband of the family (COL005.1) was presented with bilateral uveal colobomas (Fig. 1B, C).
102 Family history was notable for a sibling (COL005.4), and relatives (COL005.10), (COL005.17) with uveal
103 coloboma. The deletion breakpoints were in intron 2 and 6 removing the coding sequence for amino acids
104 (aa) Ile48-Gly275 and likely causing a frameshift (p.Ile48Asnfs*3, Fig. 1H). The status of the heterozygous
105 deletion was determined by breakpoint PCR among family members available, which revealed complete
106 segregation with the missing vertebrae with an estimated LOD score of 3.6 (Fig. 1A, Supplementary Fig.
107 S1). Four family members were also affected by coloboma in addition to missing vertebra, of which one
108 (COL005.17) also had, by report, only one kidney. The proband of family (COL034.1) was presented with
109 bilateral uveal colobomas and microphthalmia OS (Fig. 1E). Genome sequencing revealed a heterozygous
110 c. 274C>T p. (Arg92Trp) variant in *NR6A1*, which was found in the affected parent and essentially
111 unaffected grandparent (Fig. 1A, H). The proband of family (COL171.1) was presented with bilateral
112 colobomatous microphthalmia affecting the iris, retina/choroid and optic nerve. Slit lamp exam was
113 notable for bilateral microcornea, bilateral posterior subcapsular and nuclear cataracts and missing
114 zonules inferiorly OU (Fig. 1F). Genome sequencing revealed a heterozygous c.1306C>T p.(Arg436Cys)
115 variant in the proband which was absent in his unaffected parent (Fig. 1H). Detailed study of the probands
116 and their family members available for evaluation, were described in clinical vignettes in the **extended**
117 **data**. No convincing pathogenic variants in known coloboma genes were identified in any of these
118 subjects.

119 ***Genome-first approach for NR6A1 variants corroborates MAC phenotypes***

120 We performed an unbiased disease association analysis of rare pLoF variants using the UK100KGP
121 dataset¹⁷. After removing variants resulting from calling artifacts or mis-annotation, only three pLoF
122 variants were found in the cohort with approximately 126,700 alleles (Supplementary Table 4,
123 Supplementary Fig. 2). We found three probands, Proband (A1) with bilateral chorioretinal coloboma
124 (*forme fruste* OD) and OS coloboma of the optic nerve (Supplementary Fig. 2B). Genome sequencing
125 revealed a heterozygous c.965_980del p.(Ser322Ter), present in both the proband and unaffected parent.

126 Proband (B1), presented with a severe form of bilateral microphthalmia with a vestigial remnant of eye,
127 delayed motor development, intellectual disability, abnormal behavior, and schwannoma. This proband
128 carried a heterozygous c.902G>A p.(Trp301Ter) variant. These two nonsense variants are expected to
129 cause loss of protein function either through nonsense-mediated decay or truncation of the putative
130 nuclear receptor ligand binding domain (NR-LBD, Fig. 1H). Proband D (Supplementary Table 4) had a
131 disorder of sex development carried variant c.288dup p.(Cys96TrpfsTer4), which was absent in either
132 parent. One of the parents, was also affected with a disorder of sex development, suggesting that the
133 NR6A1 variant is likely not associated with the condition.

134 The UK100KGP MAC cohort, which consists of 215 probands, was queried for rare missense and
135 in-frame insertion/deletion variants. Proband C1, presented with bilateral microcornea and coloboma
136 affecting the iris, choroid/retina, and optic nerve. One sibling had a similar condition by report. Both
137 parents, and the two other siblings of the proband had no history of coloboma by report. Genome
138 sequencing revealed a heterozygous variant c.227_229del p.(Ser76del) present in the proband (Fig. 1H,
139 Supplementary Table 4). This variant leads to an in-frame deletion of a serine within the Zn-finger motif.
140 Within the three MAC patients we report, no candidate pathogenic variants were found in the known
141 MAC genes present in the current Genomics England PanelApp (ocular coloboma v1.47, anophthalmia or
142 microphthalmia v1.51, structural eye disease v3.79). Thus, these cases further support that rare variants
143 in NR6A1 can cause MAC with reduced penetrance.

144

145 ***Molecular Modeling Suggests Missense Variants Disrupt Important Intramolecular Interactions***

146 The NR6A1 amino acid sequence is well-conserved between human, mouse, and zebrafish;
147 specifically, the residues Ser76, Arg92 and Arg436 are conserved across multiple species (Supplementary
148 Fig. 3). To understand the effects, missense variants had on protein stability and function, we created an
149 *in silico* model of a complex of NR6A1 with DNA (Supplementary Fig. 4A). The AlphaFold model of NR6A1
150 is shown by the composition of Zn-finger (residues 60-172) and NR_LBD (residues 246-480) domains
151 shown in orange and green, respectively. The rest of the model shown in gray is predicted as an irregular
152 structure by AlphaFold. The locations of variants R92W and R436C are labeled. In wild-type (WT) NR6A1,
153 a positively charged arginine residue 92 interacts with negatively charged DNA (Supplementary Fig. 4B).
154 The R92W variant replaces the R92 residue with hydrophobic tryptophan (W), interrupting the
155 electrostatic interaction with DNA and possibly reducing the DNA binding of the Zn-finger motif. The
156 R436C variant affects the putative nuclear receptor ligand binding domain NR_LBD. In NR6A1, hydrogen
157 atom 1HH2 of arginine R436 closely interacts with the oxygen atom of glutamic acid E388 (Supplementary
158 Fig. 4C). The Variant R436C breaks this bond creating a cysteine residue instead of an arginine. In this
159 variant domain, residues C443, C391, and C422 are distanced at 8-12 Å from C436. In the native state of
160 protein, the reduced state of cysteine residues is protected. However, any oxidative damage could cause
161 the formation of non-native disulfide bonds affecting protein structure and ligand binding.

162

163 ***Missense variants alter NR6A1 protein subcellular localization***

164 To study the functional impact of the missense variants on protein localization in the cell, the
165 R92W and R436C mutations were introduced in WT NR6A1 cDNA fused to a GFP coding sequence. All

166 experiments were performed in context to the *NR6A1* isoform NM_033334.4 and repeated at least three
167 times. Transfection efficiencies were between 50-60% and not significantly different between WT and
168 variant constructs as analyzed by flow-cytometry and Western blotting (Supplementary Fig. 5, 6). The
169 WT-*NR6A1* when over-expressed in HEK293 cells was consistently observed to localize in the nucleus (Fig.
170 2A, B), consistent with a previous report. The R92W variant, although nuclear, was not uniform in its
171 distribution, forming apparent protein aggregates. In contrast, the R436C variant localized exclusively in
172 the cytoplasm (Fig. 2A). The above-described localization pattern of the WT and variant isoforms was
173 consistent in all transfected cells and across multiple rounds of transfection. Taken together these results
174 suggest that both missense variants likely interfere with *NR6A1* function due to improper subcellular
175 localization.

176

177 **Expression pattern of mouse and zebrafish *NR6A1* homologs suggests a role in early eye, kidney, and** 178 **somite development**

179 Analysis of bulk RNA-Seq datasets from ocular and non-ocular tissues demonstrates modest
180 expression of *NR6A1* in most tissues and relatively higher levels of expression in embryonic stem
181 cells/induced pluripotent stem cells (compared to adult ocular tissues) and in bone marrow and testis
182 systemically (Fig. 3A, D)^{23,24}. In the Human Retinal Cell Atlas single nucleus RNA-Seq dataset, *NR6A1* is
183 highly expressed in adult horizontal cells and low in microglia and RPE (Fig. 3B)²⁵. Expression of *NR6A1* is
184 strongly correlated (>5 fold enrichment, $p = 0.0024$) with that of other coloboma-associated genes in fetal
185 ocular tissues (Fig. 3C). This strength of enrichment was not seen in Genotype-Tissue Expression (GTEx)
186 body tissue ($p=0.361$) or adult eye tissue ($p=0.451$)^{23,24}. We note that several of the enriched genes-*SALL4*
187 (Duane-Radial Ray Syndrome), *PAX2* (Papillorenal syndrome), *ACGT1* (Baraitser-Winter Syndrome 2),
188 *SALL1* (Townes-Brocks Syndrome 1) can also present with congenital renal anomalies.

189 To establish plausible causation for *NR6A1* variants, we studied the embryonic expression of its
190 orthologs in mouse and zebrafish model systems at developmentally relevant time points. Previous work
191 has demonstrated widespread expression of *Nr6a1* in mouse at E8.5 and E9.5 (including the optic vesicle)
192 that becomes nearly undetectable by E12.5. To study expression in the optic cup around the time of optic
193 fissure closure, we used a probe that detects all validated transcripts of mouse *Nr6a1* at embryonic day
194 10.5 (E10.5, early optic cup) and E11.5 (time of optic fissure closure). At E10.5, we noted diffuse low-
195 level expression throughout the early optic cup and surrounding tissues that becomes significantly
196 decreased by the time optic fissure closure commences (E11.5) (Supplementary Fig. 7).

197 In zebrafish, *nr6a1* has two paralogs, *nr6a1a* and *nr6a1b*, both of which are maternally expressed.
198 At 11hpf, when the optic vesicle evaginates, *nr6a1a* is widely expressed throughout the embryo, especially
199 rostrally, showing less expression towards the posterior embryo axis (Fig. 4A). At 16hpf, *nr6a1a* remains
200 widely expressed becoming restricted to the ventral regions of the brain, epiphysis, periocular tissues,
201 heart and in the notochord and neural tube (Fig. 4B). Notably, *nr6a1a* expression is absent from the
202 neural-mesodermal progenitor region in the tail of zebrafish embryos, consistent with its role in the trunk
203 differentiation program. By 19hpf the expression appears to decrease overall but remains present in the
204 ventral brain regions, notochord, somites, and the pronephric duct (Fig. 4C). At 24hpf, expression is
205 prominent in the anterior diencephalon, tegmentum, midbrain, and along most of the length of the
206 embryo in the neural tube; interestingly, expression is nearly absent from the neural retina and retina
207 pigmented epithelia but is prominent in the lens (Fig. 4D-D''), a pattern not noted in the mouse *Nr6a1*

208 expression. After 26hpf and up to 72hpf we observed no detectable *nr6a1a* expression, consistent with
209 published single-cell mRNA expression during zebrafish development.

210 Unlike *nr6a1a*, *nr6a1b* expression at 11hpf is limited to a patch in the posterior neuroectoderm
211 of the embryo but excluded from the most caudal region (Fig. 4E). At 16hpf and 19hpf, *nr6a1b* expression
212 is prominent in the neural tube, somites, and pronephric duct and, like *nr6a1a*, is excluded from the
213 neural-mesodermal progenitor region in the tail (Fig. 4F, G). By 24hpf, expression is decreased in most
214 tissues but remains in the tegmentum, cranial ganglia, neural tube, and somites in the distal region of the
215 trunk (Fig. 4H-H"). By 36hpf and through 72hpf, *nr6a1b* is notably expressed in the developing lens, brain,
216 and cranial ganglions. (Supplementary Fig. 8).

217

218 ***Morpholino knockdown of zebrafish nr6a1a/nr6a1b recapitulates human phenotypes which are not*** 219 ***rescued by pathogenic variant mRNA***

220 All the morpholinos experiments are carried out following the guidelines set forth for their use in
221 zebrafish. To test the functional consequences of *nr6a1a* and *nr6a1b* knockdown, we designed translation
222 (TB) and splice blocking (SB) morpholinos for each paralog of the gene. Morphants were divided into four
223 phenotypes: normal, mild (normal/near normal body axis w/ microphthalmia), moderate (slightly
224 shortened and mildly curved body axis, microphthalmia ± coloboma and heart edema) or severe
225 (significantly shortened and curved body axis, microphthalmia ± coloboma, heart edema) (Fig. 5A-D,
226 Supplementary Fig. 9, 10). Embryos were scored at 72 hpf (after optic fissure closure and initial stages of
227 eye growth are normally completed) to ensure microphthalmia/coloboma represents a true phenotype
228 and not because of developmental delay or undergoing growth compensation.

229 Knockdown of *nr6a1a* (Supplementary Fig. 9E) or *nr6a1b* (Supplementary Fig. 10E) with either TB-
230 MO or SB-MO resulted in a significant number of moderate/severe phenotypes with few mild phenotypes.
231 Although the effect of TB-MO and SB-MO were similarly potent for *nr6a1b* knockdown, the SB-MO had a
232 stronger effect than the TB-MO for *nr6a1a*. SB-MO knockdown of the gene was validated for both
233 paralogs by reverse transcription-PCR experiments (Supplementary Fig. 9F, 10F). The phenotypic
234 spectrum was not affected by co-injection with p53 morpholino, suggesting widespread cell death was
235 not the primary cause of our observations (data not shown).

236 Overexpression of 100 pg of human *NR6A1* mRNA in zebrafish shows no overt phenotype
237 (Supplementary Fig. 11A, B). Co-injection of 2 ng and 1.25ng of *nr6a1a* and *nr6a1b*, TB-MO respectively
238 along with 100 pg of WT human mRNA (hWT-*NR6A1*), resulted in a rescue, with over 60% embryos
239 exhibiting a normal/control-injected phenotype (Supplementary Fig. 9G, S10G). In contrast, co-injection
240 with either hR92W or the hR436C missense variants of *NR6A1* identified in coloboma patients were
241 significantly less effective in rescuing the zebrafish *nr6a1a/b* knockdown, indicating that the missense
242 variants are deleterious (Supplementary Fig. 9G, 10G).

243 To study the effect of knocking down both *nr6a1a* and *nr6a1b* zebrafish paralogues, we co-
244 injected 0.75 ng of TB-MO for each paralog (1.5 ng total), resulting in a similar spectrum of phenotypes
245 compared to the knockdown of individual paralogues (Fig. 5A-D, A'-D'). While injection of TB-MO resulted
246 in >60% embryos having a moderate or severe phenotype, co-injection of 100 pg hWT-*NR6A1* mRNA,
247 resulted in >50% normal embryos. Neither the hR92W or hR436C *NR6A1* mRNAs resulted in significant

248 rescue, confirming the pathogenicity of these variants (Fig. 5E). Injection of 0.75 ng of either *nr6a1a* TB-
249 MO or *nr6a1b* TB-MO resulted in a significantly milder phenotype, suggesting that co-injection of these
250 had at least an additive phenotypic effect in the combined MO injection experiment (Supplementary Fig.
251 12).

252 Because a prior study reported that both overexpression and loss-of-function of *nr6a1* can result
253 in developmental phenotypes in *Xenopus laevis*, we also evaluated the effect of injection of human *NR6A1*
254 mRNA on zebrafish development. Overexpression of 150 pg of *hNR6A1* mRNA resulted in microphthalmia
255 and heart edema with a straight body axis (n=91/108) (Supplementary Fig. 11C). At 200 pg,
256 overexpression of *hNR6A1* mRNA, phenotypes were more severe including colobomatous
257 microphthalmia, heart edema and a bent body axis (n=60/92), with 26% (n=24/92) exhibiting noticeable
258 shortening and loss of chevron-shaped somites (Supplementary Fig. 13); a minority of embryos (n=8/92)
259 developed no discernible eyes (Supplementary Fig. 11F). Taken together, these experiments demonstrate
260 that normal zebrafish eye development is sensitive to *nr6a1* dosage and both reduced and increased
261 *nr6a1* expression result in developmental phenotypes analogous to human colobomatous
262 microphthalmia.

263

264 Discussion

265 Here we describe six *NR6A1* variants that cause an autosomal dominant syndromic form of
266 colobomatous microphthalmia and missing vertebrae with or without congenital kidney abnormalities,
267 that we term OVR syndrome. As with many other cases of syndromic and non-syndromic
268 microphthalmia/coloboma, the OVR syndrome show incomplete penetrance and variable expressivity¹.
269 By 2015 ACMG/AMP variant interpretation criteria, we considered chr9:g.124536516_124643457del
270 pathogenic (criteria: PVS1, PP1_Strong, PM2) and other MAC-associated variants likely pathogenic
271 (criteria: Ser76del, PM1, PM2, PM4, PP3; Arg92Trp, PS3, PM1, PM2, PP3; Arg436Cys, PS3, PM2, PP3;
272 Ser301Ter & Ser322Ter, PVS1, PM2). Thus, *NR6A1* variants were causative among 1.3% - 1.4% families in
273 two independent patient cohorts (3 out of 224 in the NEI coloboma cohort and 3 out of 215 in the MAC
274 cohort in the UK100KGP).

275 The NEI study, which specifically recruits patients with coloboma/microphthalmia, performs
276 extensive phenotypic analysis on probands including complete eye examination, kidney ultrasound,
277 neuropsychological testing, physical exam/dysmorphology exam, spine x-ray, routine
278 bloodwork/urinalysis, ECHO (in the presence of a murmur), and audiology. Additional testing (e.g., brain
279 MRI) may be performed on an as needed basis. In addition, all available first-degree relatives undergo a
280 complete dilated fundus exam. As such, we have greater certainty that a patient is truly unaffected, say,
281 by coloboma, rather than being simply asymptomatic. Indeed, the mother of the proband in family
282 COL034 (COL034.2), for example, was visually asymptomatic and unaware of a *forme fruste* of coloboma
283 or a missing thoracic vertebra prior to her exam with us. Conversely, the Genomics England database
284 spans an entire population in a gene and phenotype agnostic manner but may contain incomplete or
285 unrelated phenotypic information. As such, phenotypes such as intellectual disability (Individual B1, Table
286 S4) may be spurious associations or may be uncommon manifestations of an *NR6A1*-related syndrome.
287 Confirmation of these and other possible phenotypes awaits description of additional cases. We include
288 congenital renal disease as part of this new syndrome not only because two individuals in two separate

289 pedigrees exhibited these phenotypes, but also because Rasouly et al. have simultaneously identified
290 presumed loss-of-function variants in thirteen individuals with congenital renal abnormalities, with or
291 without congenital eye abnormalities, providing further validation of our findings (personal
292 communication).

293 The genotypes and functional data we present suggest haploinsufficiency as the primary
294 mechanism of disease, although we cannot rule out that missense variants may have other, dominant-
295 negative effects, by dimerizing with the wildtype protein or interacting with other transcription regulators.
296 The differences in subcellular localization of the two missense variants in *NR6A1* may indeed hint at more
297 than one mechanism of disease.

298 The early expression of *NR6A1* homologs in mouse and zebrafish are consistent with the previous
299 data and suggest that the colobomatous microphthalmia observed in our patients may result from effects
300 on early eye morphogenesis rather than a defect in optic fissure closure *per se*. However, given the
301 expression of *nr6a1a/nr6a1b* in the lens vesicle in zebrafish, a non-cell autonomous effect on optic fissure
302 closure cannot be excluded. In fact, evidence from Mexican surface and cave fish (*Astyanax mexicanus*)
303 experiments show that early neural retina development and maintenance relies on a healthy lens^{26,27}.

304 Recently, *NR6A1* has been shown to be important for somite development and, consequently,
305 vertebral number, thus strengthening the phenotyping link with missing vertebrae we describe in
306 humans^{19–22,28}. Vertebrae differentiate from somites which develop their stereotyped segmentation
307 pattern in an anterior to posterior progression during early development, with successive *HOX* genes
308 specifying different regions of the spine via a process called temporal collinearity. Homozygous germline
309 inactivation of *Nr6a1* in mice results in embryonic lethality around E10.5 with cardiovascular, neural tube
310 and hindgut abnormalities as well as fewer somites (13, rather than the normal 25). In *Sus domesticus*
311 (pig), *NR6A1* was identified as a quantitative trait locus for vertebral number, which is known to vary
312 between breeds^{19,21}. In *Equus assinus* (donkey), an *NR6A1* intronic polymorphism is associated with body
313 size/vertebral number and a single nucleotide polymorphism in exon 8 is associated with the number of
314 lumbar vertebrae in Kazakh sheep^{20,28}. In developing *Xenopus*, *NR6A1* is expressed in late tailbud and
315 neurula stages; overexpression results in posterior defects and disturbed somite formation, while
316 expression of a dominant negative form of the receptor results in abnormal neural tube differentiation,
317 loss of head structure including eyes, and downregulation of a retinoic acid receptor (RAR γ 2) anteriorly.
318 Retinoic acid treatment of embryos upregulates expression of *NR6A1*, increasing primary neurogenesis
319 via factors such as NeuroD, XDelta1 and x-ngnrl. Retinoic acid is a known and important regulator of both
320 ocular and kidney development^{29,30}; whether retinoic acid receptor signaling is disrupted in model
321 systems of *Nr6a1/nr6a1* is currently under investigation. However, all phenotypes previously observed
322 when modulating the activity of *NR6A1* in animal models are consistent with the developmental defects
323 in the eyes, kidneys, and vertebrae that we observe in patients carrying deleterious mutations in *NR6A1*.

324 In conclusion, genome sequencing identified novel *NR6A1* variants in three unrelated families
325 which are associated with a novel OVR syndrome, these findings were further corroborated in an
326 independent cohort using a genome first approach. Using *in silico* prediction and molecular studies we
327 demonstrated that these highly conserved variants disrupt *NR6A1* protein structure leading to mis-
328 localization at the cellular level. We further demonstrated enrichment of coloboma-associated genes with
329 *NR6A1* in fetal, but not adult tissues. Expression of *NR6A1* homologs in mouse and zebrafish embryos
330 suggests disease relevant tissue-specific gene expression pattern. This was further confirmed by *in vivo*

331 experiments where the knockdown of zebrafish *nr6a1a* and *nr6a1b* resulted in ocular and systemic
332 phenotypes that were partially rescued with WT human *NR6A1* mRNA but not with the two variants
333 tested. This data implicates the human *NR6A1* gene variants with the OVR syndrome.

334 **Acknowledgment**

335 We are grateful to the patients and their families for participation in this research. We thank the
336 staff at the NIH Clinical Center and the NEI Eye Clinic for patient phenotyping, ophthalmic testing, and
337 ophthalmic imaging. We are grateful to Drs. Hila Milo Rasouly, Krishna Murthy, Ali Gharavi for their critical
338 reading of this manuscript and for facilitating publishing our similar findings in parallel. We thank Dr. Amy
339 Hodson-Thompson for her expert assistance in designing and formatting figures, and Dr. Thomas Hawkins
340 and Dr. Gareth Powell for advice on the interpretation of zebrafish expression patterns. We thank Dr.
341 Robert Fariss and members of the NEI Imaging Core for use of their confocal imaging facility and Dr. Elena
342 Semina for helpful discussions on this project.

343 This research was made possible through access to data in the National Genomic Research Library,
344 which is managed by Genomics England Limited (a company owned by the Department of Health and
345 Social Care). The National Genomic Research Library holds data provided by patients and collected by the
346 NHS as part of their care and data collected as part of their participation in research. The National Genomic
347 Research Library is funded by the National Institute for Health Research and NHS England. The Wellcome
348 Trust Cancer Research UK, and the Medical Research Council have also funded research infrastructure.
349 This research was supported by the NIHR Moorfields Biomedical Research Centre (GA, MM, SL).

350 **Authors Contribution:** EU, RBH, MIM, GA, RY and BG performed exome/genome analysis and variant
351 confirmation in the NIH and UK100KGP populations. RA, AN and CB performed variant confirmation,
352 including confirmation of deletion breakpoints. IHM, DB, SL, TGT, MM and BPB performed patient
353 examination/phenotyping. RY and MIM provided phenotypic data from the UK100KGP. YVS performed
354 molecular dynamic modeling. DM performed bioinformatic analyses of *NR6A1*. UMN and DSM performed
355 zebrafish *in situ* hybridization, morpholino knockdown and mRNA rescue experiments. RY assisted in
356 interpretation of zebrafish data. AG and CA performed cell culture and transfection experiments. AG
357 performed confocal microscopy. RV performed flow cytometry. All co-authors provided draft language
358 and experimental design for their portions of the manuscript, as well as a critical review of the entire
359 manuscript. BPB provided overall project conception and experimental design, drafting of the manuscript
360 and project support.

361 **Funding:** This study was supported by the Intramural Research Program of the NIH. GA is supported by a
362 Fight For Sight (UK) Early Career Investigator Award (5045/46), the National Institute of Health Research
363 Biomedical Research Centre (NIHR-BRC) at Moorfields Eye Hospital, and the UCL Institute of
364 Ophthalmology, and Moorfields Eye Charity (Stephen and Elizabeth Archer in memory of Marion Woods)
365 and NIH-P20GM139769. RY was supported by the Moorfields Eye Charity Career Development Award and
366 Springboard (GR001155 and GR001210), Medical Research Council (MR/X001067/1) and FODNECYT
367 (1221843). MIM was supported by Moorfields Eye Charity PhD Studentship (GR001661).

368

369 **References**

- 370 1. Williamson, K.A., and FitzPatrick, D.R. (2014). The genetic architecture of microphthalmia,
371 anophthalmia and coloboma. *Eur. J. Med. Genet.* *57*, 369–380.
- 372 2. Chang, L., Blain, D., Bertuzzi, S., and Brooks, B.P. (2006). Uveal coloboma: clinical and basic science
373 update. *Curr. Opin. Ophthalmol.* *17*, 447–470.
- 374 3. Patel, A., and Sowden, J.C. (2019). Genes and pathways in optic fissure closure. *Semin. Cell Dev. Biol.*
375 *91*, 55–65.
- 376 4. ALSomiry, A.S., Gregory-Evans, C.Y., and Gregory-Evans, K. (2019). An update on the genetics of ocular
377 coloboma. *Hum. Genet.* *138*, 865–880.
- 378 5. Chan, B.H.C., Moosajee, M., and Rainger, J. (2020). Closing the Gap: Mechanisms of Epithelial Fusion
379 During Optic Fissure Closure. *Front Cell Dev Biol* *8*, 620774.
- 380 6. Nakamura, K.M., Diehl, N.N., and Mohny, B.G. (2011). Incidence, ocular findings, and systemic
381 associations of ocular coloboma: a population-based study. *Arch. Ophthalmol.* *129*, 69–74.
- 382 7. Roos, L., Jensen, H., Grønsvov, K., Holst, R., and Tümer, Z. (2016). Congenital Microphthalmia,
383 Anophthalmia and Coloboma among Live Births in Denmark. *Ophthalmic Epidemiol.* *23*, 324–330.
- 384 8. Skriapa Manta, A., Olsson, M., Ek, U., Wickström, R., and Teär Fahnehjelm, K. (2019). Optic Disc
385 Coloboma in children - prevalence, clinical characteristics and associated morbidity. *Acta Ophthalmol.*
386 *97*, 478–485.
- 387 9. Morrison, D., FitzPatrick, D., Hanson, I., Williamson, K., van Heyningen, V., Fleck, B., Jones, I.,
388 Chalmers, J., and Campbell, H. (2002). National study of microphthalmia, anophthalmia, and coloboma
389 (MAC) in Scotland: investigation of genetic aetiology. *J. Med. Genet.* *39*, 16–22.
- 390 10. Källén, B., and Tornqvist, K. (2005). The epidemiology of anophthalmia and microphthalmia in
391 Sweden. *Eur. J. Epidemiol.* *20*, 345–350.
- 392 11. Das, A.V., Rauniyar, D., Chaurasia, S., Jalali, S., and Padhi, T.R. (2022). Clinical and Demographic
393 Profile of Uveal Coloboma: A Hospital-Based Study of 14,371 Eyes of 9557 Indian Patients. *Am. J.*
394 *Ophthalmol.* *242*, 1–6.
- 395 12. Maumenee, I.H., and Mitchell, T.N. (1990). Colobomatous malformations of the eye. *Trans. Am.*
396 *Ophthalmol. Soc.* *88*, 123–132; discussion 133-5.
- 397 13. Patel, A., Hayward, J.D., Tailor, V., Nyanhete, R., Ahlfors, H., Gabriel, C., Jannini, T.B., Abbou-Rayyah,
398 Y., Henderson, R., Nischal, K.K., et al. (2019). The Oculome Panel Test: Next-Generation Sequencing to
399 Diagnose a Diverse Range of Genetic Developmental Eye Disorders. *Ophthalmology* *126*, 888–907.
- 400 14. Kalaskar, V.K., Alur, R.P., Li, L.K., Thomas, J.W., Sergeev, Y.V., Blain, D., Hufnagel, R.B., Cogliati, T.,
401 and Brooks, B.P. (2020). High-throughput custom capture sequencing identifies novel mutations in
402 coloboma-associated genes: Mutation in DNA-binding domain of retinoic acid receptor beta affects
403 nuclear localization causing ocular coloboma. *Hum. Mutat.* *41*, 678–695.

- 404 15. Jackson, D., Malka, S., Harding, P., Palma, J., Dunbar, H., and Moosajee, M. (2020). Molecular
405 diagnostic challenges for non-retinal developmental eye disorders in the United Kingdom. *Am. J. Med.*
406 *Genet. C Semin. Med. Genet.* *184*, 578–589.
- 407 16. Huynh, N., Blain, D., Glaser, T., Doss, E.L., Zein, W.M., Lang, D.M., Baker, E.H., Hill, S., Brewer, C.C.,
408 Kopp, J.B., et al. (2013). Systemic diagnostic testing in patients with apparently isolated uveal coloboma.
409 *Am. J. Ophthalmol.* *156*, 1159-1168.e4.
- 410 17. Genomics England (2019). The National Genomics Research and Healthcare Knowledgebase v5.
- 411 18. Agoulnik, I.Y., Cho, Y., Niederberger, C., Kieback, D.G., and Cooney, A.J. (1998). Cloning, expression
412 analysis and chromosomal localization of the human nuclear receptor gene GCNF. *FEBS Lett.* *424*, 73–78.
- 413 19. Carmen Burgos, Pedro Latorrea, Juan Altarribab, José Alberto Carrodegua, Luis Varona, Pascual
414 López-Buesa (2015). Allelic frequencies of NR6A1 and VRTN, two genes that affect vertebrae number in
415 diverse pig breeds: a study of the effects of the VRTN insertion on phenotypic traits of a Duroc ×
416 Landrace-Large White cross. *Meat Sci.* *100*, 150–155.
- 417 20. Fang, X., Lai, Z., Liu, J., Zhang, C., Li, S., Wu, F., Zhou, Z., Lei, C., and Dang, R. (2019). A Novel 13 bp
418 Deletion within the NR6A1 Gene Is Significantly Associated with Growth Traits in Donkeys. *Animals* *9*,
419 681.
- 420 21. Mikawa, S., Morozumi, T., Shimanuki, S.-I., Hayashi, T., Uenishi, H., Domukai, M., Okumura, N., and
421 Awata, T. (2007). Fine mapping of a swine quantitative trait locus for number of vertebrae and analysis
422 of an orphan nuclear receptor, germ cell nuclear factor (NR6A1). *Genome Res.* *17*, 586–593.
- 423 22. Chang, Y.-C., Manent, J., Schroeder, J., Wong, S.F.L., Hauswirth, G.M., Shylo, N.A., Moore, E.L.,
424 Achilleos, A., Garside, V., Polo, J.M., et al. (2022). Nr6a1 controls Hox expression dynamics and is a
425 master regulator of vertebrate trunk development. *Nat. Commun.* *13*, 7766.
- 426 23. Bryan, J.M., Fufa, T.D., Bharti, K., Brooks, B.P., Hufnagel, R.B., and McGaughey, D.M. (2018).
427 Identifying core biological processes distinguishing human eye tissues with precise systems-level gene
428 expression analyses and weighted correlation networks. *Hum. Mol. Genet.* *27*, 3325–3339.
- 429 24. GTEx Consortium, Laboratory, Data Analysis & Coordinating Center (LDACC)-Analysis Working Group,
430 Statistical Methods groups-Analysis Working Group, Enhancing GTEx (eGTEx) groups, NIH Common
431 Fund, NIH/NCI, NIH/NHGRI, NIH/NIMH, NIH/NIDA, Biospecimen Collection Source Site-NDRI, et al.
432 (2017). Genetic effects on gene expression across human tissues. *Nature* *550*, 204–213.
- 433 25. Li, J., Wang, J., Ibarra, I.L., Cheng, X., Luecken, M.D., Lu, J., Monavarfeshani, A., Yan, W., Zheng, Y.,
434 Zuo, Z., et al. (2023). Integrated multi-omics single cell atlas of the human retina. *BioRxiv*org 2023–2011.
- 435 26. Yamamoto, Y., and Jeffery, W.R. (2000). Central role for the lens in cave fish eye degeneration.
436 *Science* *289*, 631–633.
- 437 27. Strickler, A.G., Yamamoto, Y., and Jeffery, W.R. (2007). The lens controls cell survival in the retina:
438 Evidence from the blind cavefish *Astyanax*. *Dev. Biol.* *311*, 512–523.

- 439 28. Zhang, X., Li, C., Li, X., Liu, Z., Ni, W., Cao, Y., Yao, Y., Islamov, E., Wei, J., Hou, X., et al. (2019).
440 Association analysis of polymorphism in the NR6A1 gene with the lumbar vertebrae number traits in
441 sheep. *Genes Genomics* 41, 1165–1171.
- 442 29. Cvekl, A., and Wang, W.-L. (2009). Retinoic acid signaling in mammalian eye development. *Exp. Eye*
443 *Res.* 89, 280–291.
- 444 30. Burrow, C.R. (2000). Retinoids and renal development. *Exp. Nephrol.* 8, 219–225.
- 445 31. Richards, S., Aziz, N., Bale, S., Bick, D., Das, S., Gastier-Foster, J., Grody, W.W., Hegde, M., Lyon, E.,
446 Spector, E., et al. (2015). Standards and guidelines for the interpretation of sequence variants: a joint
447 consensus recommendation of the American College of Medical Genetics and Genomics and the
448 Association for Molecular Pathology. *Genet. Med.* 17, 405–424.
- 449 32. Jarvik, G.P., and Browning, B.L. (2016). Consideration of cosegregation in the pathogenicity
450 classification of genomic variants. *Am. J. Hum. Genet.* 98, 1077–1081.
- 451 33. Kimmel, C.B., Ballard, W.W., Kimmel, S.R., Ullmann, B., and Schilling, T.F. (1995). Stages of embryonic
452 development of the zebrafish. *Dev. Dyn.* 203, 253–310.
- 453 34. Boobalan, E., Thompson, A.H., Alur, R.P., McGaughey, D.M., Dong, L., Shih, G., Vieta-Ferrer, E.R.,
454 Onojafe, I.F., Kalaskar, V.K., Arno, G., et al. (2022). Zfp503/Nlz2 Is Required for RPE Differentiation and
455 Optic Fissure Closure. *Invest. Ophthalmol. Vis. Sci.* 63, 5.
- 456

Family	Member*	Sex	Iris coloboma	Retinal/choroidal coloboma	Optic nerve coloboma	Other ocular findings	Vertebral findings	Renal findings	Audiology findings	Other positive medical findings	Negative medical findings
COL005	COL005.1	F	OS	OU (OD is forme fruste with a small pigmented area inferior to the disc)	OS (slightly anomalous disc)	Amblyopia requiring patching; strabismus requiring surgery; retinal tear OS requiring laser retinopexy; anterior lens pigment and small lens coloboma OS	11 thoracic vertebrae, spina bifida occulta at S1 and minimal scoliosis	None	Not done	Small jaw and abnormal dentition requiring minor surgeries; mitral valve prolapse; limited left sided proctitis (inflammatory bowel disease), internal hemorrhoids; abnormal contour of the left globe on brain MRI	Normal brain MRI (aside from left globe), serum vitamin A, bone age, cholesterol levels, thyroid function, karyotype
	COL005.2	F	None	None	None	Myopia, astigmatism and presbyopia	11 thoracic vertebrae and cervical spondylosis	Not done	Non-congenital low frequency hearing loss by report	History of unexplained relapsing fevers with rash	Normal thyroid function
	COL005.4	M	None	OD	OU (OS is forme fruste with an anomalous disk with small inferior crescent)	None	11 thoracic vertebrae, 4 lumbar vertebrae and minimal scoliosis	None	Not done	No further testing done	Normal brain MRI, serum vitamin A, bone age, cholesterol levels, urinalysis
	COL005.8	M	None	None	None	BCVA was not corrected to 20/20	11 thoracic vertebrae and scoliosis	None	Not done	No further testing done	No further testing done
	COL005.10	F	OU (OD: forme fruste with focal iris transillumination inferiorly)	OU	OU (anomalous discs)	Posterior subcapsular cataract OS; mild heterochromia; history of increased intraocular pressures, treated with latanoprost; best-corrected visual acuity OS 20/40	Transitional thoracolumbar and lumbosacral vertebral bodies	None	Notched configuration of audiogram in left ear at 2000Hz, with evidence of a slight air-bone gap at that frequency	Abnormal contour of the globes on brain MRI	Normal brain MRI (aside from globes), serum vitamin A, cholesterol levels, serum chemistries, liver function tests, urinalysis, karyotype
	COL005.13	F	None	None	None	Myopia	11 thoracic vertebrae and scoliosis of upper thoracic spine	Not done	Not done	History of hypothyroidism	No further testing done
	COL005.17	M	Not done	Coloboma (unsp.) per report	Not done	Not done	One missing vertebra per report	Missing kidney per report	Not done	No further testing done	No further testing done
	COL005.18	M	None	None	None	Myopia	11 thoracic vertebrae	Not done	Not done	No further testing done	No further testing done

COL034	COL034.1	M	OS	OU	OU	Microphthalmia OS; microcornea OU with pigment deposition on endothelium OS; shallow anterior chamber OS with elevated intra ocular pressure; inferonasal cortical cataract OD; moderate amplitude, low frequency nystagmus with an anomalous head posture	10 thoracic vertebrae	Missing left kidney	None	Small size of the optic chiasm and optic nerves, and abnormal contour of the globes on brain MRI; curvature to superior prominence to the ears; history of left undescended testicle; history of growth hormone deficiency and hypothyroidism	Normal chromosomal microarray; normal pituitary gland on pituitary gland MRI; normal echocardiogram
	COL034.2	F	None	OS (retinal thinning and pigment inferior to disc)	None	Non-visually significant anterior subcapsular cataracts and anterior pigment OU	11 thoracic vertebrae and spina bifida occulta at L4, L5, and S1	None	Not done	None	Normal serum chemistries
	COL034.6	M	None	None	OU (slightly dysplastic and borderline small optic nerves)	Early stage nuclear and cortical cataracts OU; midperipheral temporal patchy deep depigmentation OD, possibly from old infection	Minimal disc space narrowing noted posteriorly at C5-6 with small anterior soft tissue ossification at C5-6, C6-7; minimal degenerative changes in the lumbar spine	Not done	Not done	History of parathyroid surgery; hypercholesterolemia	No further testing done
COL171	COL171.1	M	OU	OU	OU	Nystagmus and mild abduction deficits; bilateral microcornea; bilateral posterior subcapsular and nuclear cataracts and missing zonules inferiorly	Mild anterior longitudinal ligament calcification at C5-6 and C6-7 and possible vascular calcification noted within the soft tissues anterior to the L4-5 disc level	None	Mild to moderate sensorineural hearing loss across all frequencies in the right eye and mild sensorineural hearing loss in high frequencies of the left ear	Mild elevation of liver function tests; mild elevation of calcium level on mineral panel	Normal urinalysis

457

458

459

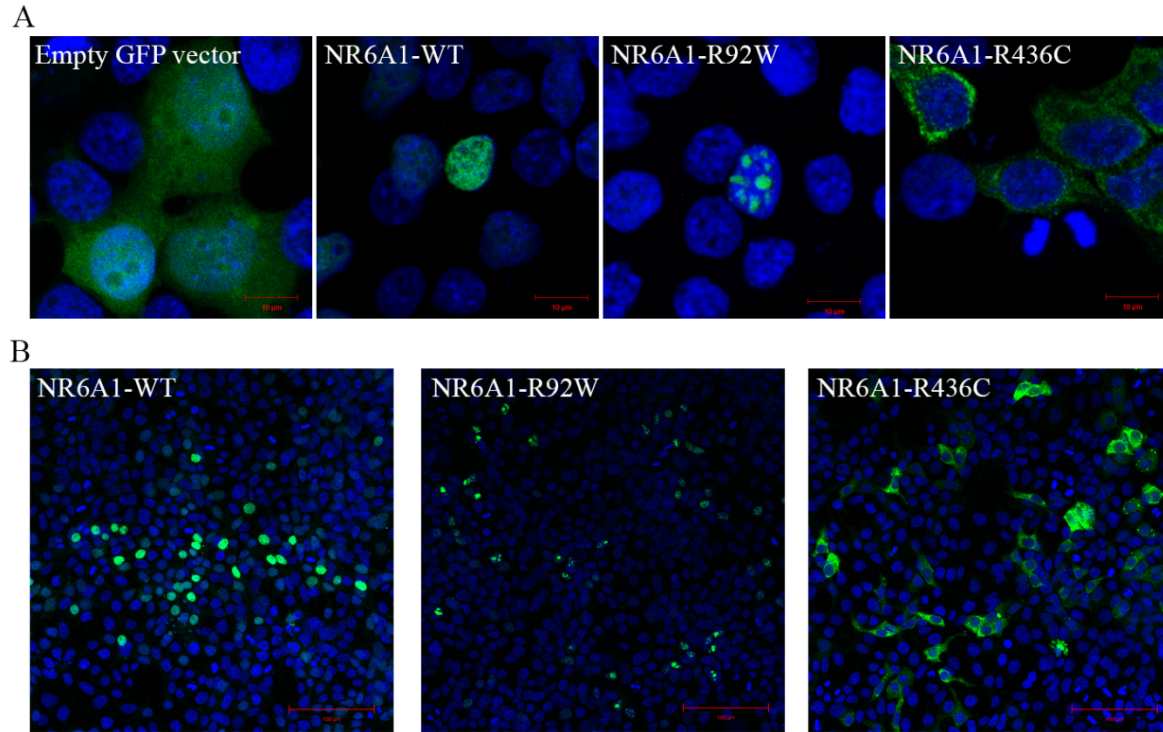
460 **Figures and Legends**

461 **Pedigrees of the Probands and clinical images of eyes and spine are available upon request from the**
462 **corresponding author.**

463 **Fig. 1: Phenotypes associated with variants in *NR6A1*.** **A.** Pedigrees of three families (COL005; COL034;
464 COL171) from the NEI cohort demonstrating coloboma with or without microphthalmia and cataract,
465 missing vertebrae, and congenital renal anomalies. Inheritance is autosomal dominant with incomplete
466 penetrance and variable expressivity. **B.** Linear pigmentary disturbance representing a *forme fruste* of
467 coloboma (arrow) in COL005.1 (right eye). **C.** Larger chorioretinal coloboma in the left eye of COL005.1
468 demonstrating a retinal tear in the far periphery (arrowhead). **D.** Iris coloboma of the left eye of
469 COL005.10. **E.** Microphthalmia of the left eye in COL034.1. **F.** Retroillumination image of the left eye of
470 COL171.1 demonstrating iris coloboma and posterior subcapsular cataract (open arrow). **G.** Spine x-ray
471 of COL005.4 demonstrating 11 thoracic (normal 12) and 4 lumbar (normal 5) vertebrae. **H.** Schematic of
472 *NR6A1* variants detected in the NEI and UK Genomics England cohorts. +, individual with variant; -,
473 individual without variant. DNA binding domain (DBD) and putative nuclear receptor ligand binding
474 domain (NR-LBD) are noted.

475

476

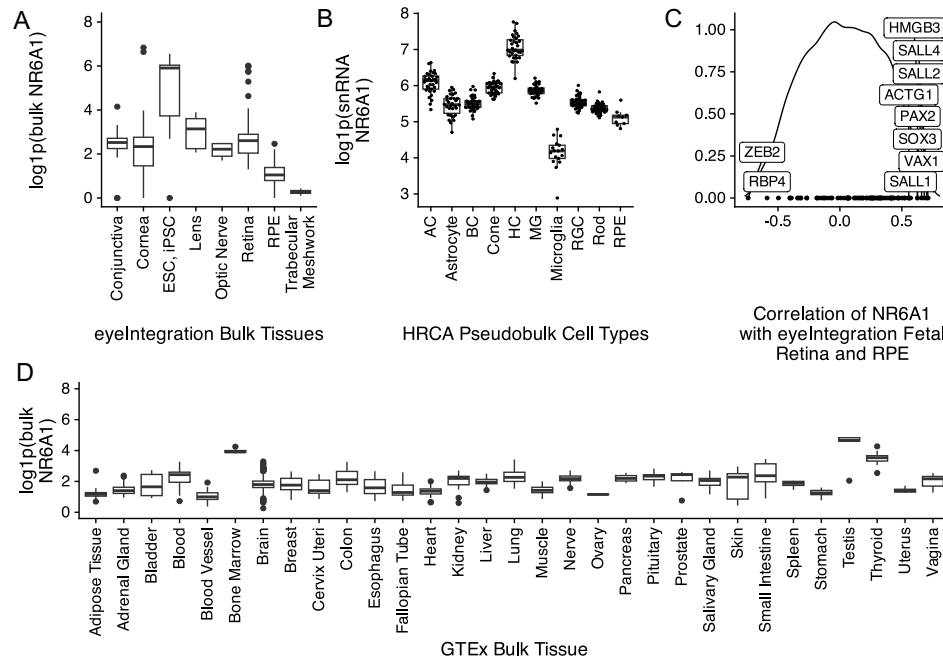


477

478 **Fig. 2: Subcellular localization of wild-type (WT) and mutant forms of NR6A1.** NR6A1 variant localization
479 pattern was studied by overexpression in HEK293 cells and representative high magnification (63X)
480 images are shown from three different trials (A). Scale bar = 10 μm . The localization pattern for the WT and the
481 two variant isoforms was observed to be consistent across three transfection experiments. (Cells counted:
482 WT=387, R92W=350 and R436C=217). Scale bar = 100 μm .

483

484



485

486 **Fig. 3:** A. Comparative levels of NR6A1 from publicly available bulk human tissue RNA-sequencing (RNA-
 487 Seq) datasets accessed on the eyeIntegration website (<https://eyeintegration.nei.nih.gov/>). On average,
 488 expression is higher in embryonic and induced pluripotent stem cells (ESC, iPSC, respectively) than in
 489 adult ocular tissues. B. In adult retina, expression of NR6A1 is highest in horizontal cells (HC) compared
 490 to other cell types in the Human Retinal Cell Atlas (HRCA) (AC, amacrine cell; BC, bipolar cell; MG, Müller
 491 glia; RGC, retinal ganglion cell; RPE, retinal pigment epithelium). C. Correlation of NR6A1 expression
 492 with fetal retina and RPE RNA-Seq data demonstrates association with several known coloboma
 493 associated genes (boxed labels). D. Among systemic tissues, NR6A1 is expressed most highly in bone
 494 marrow and testes.

495

496

497

498

499

500

501

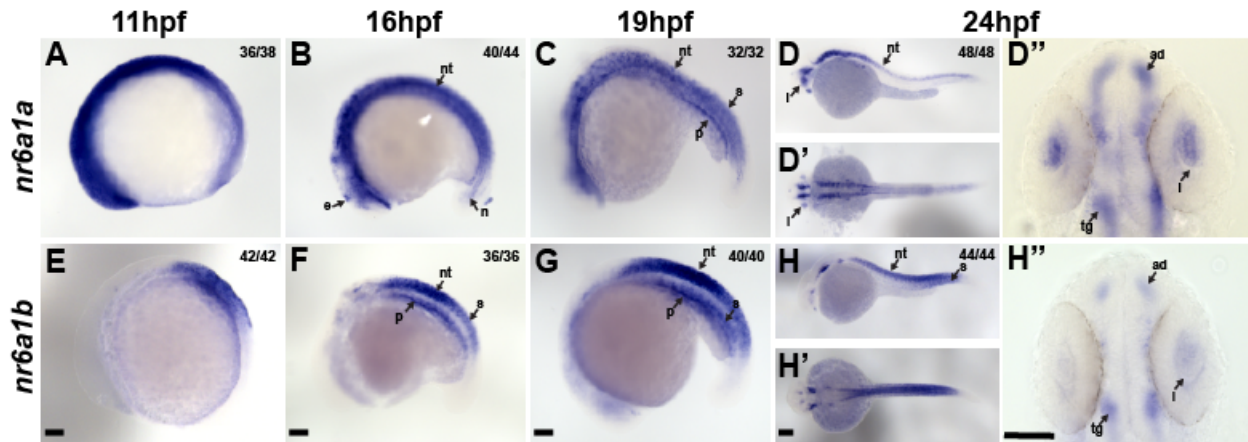
502

503

504

505

506

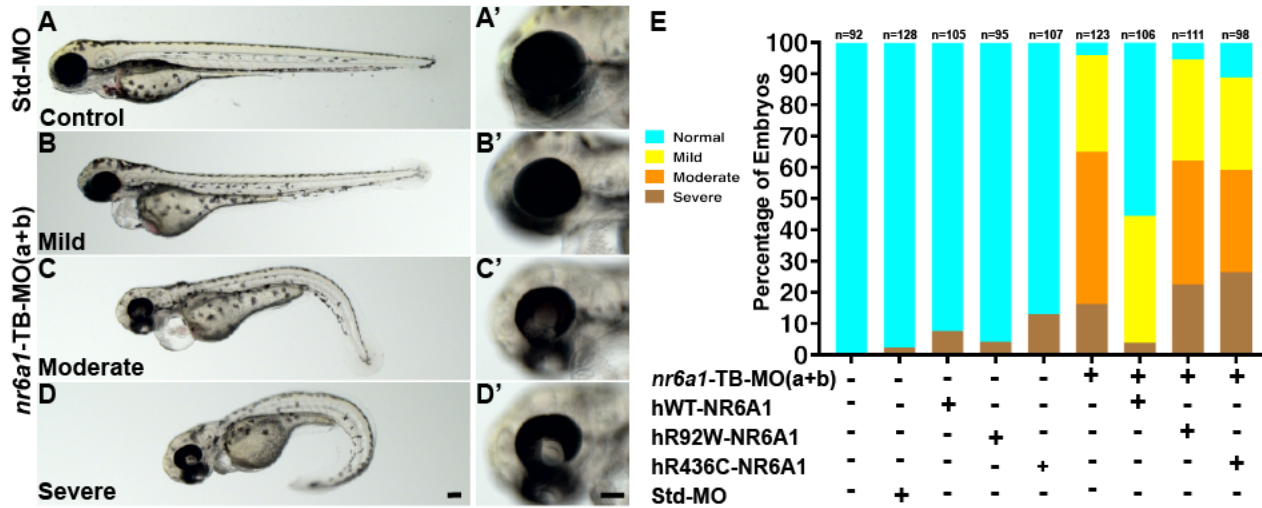


507
508

509 **Fig. 4: Expression pattern of *nr6a1a* and *nr6a1b* paralogs in zebrafish.** *nr6a1a* is expressed ubiquitously
510 at 11 hours post-fertilization (hpf) (A). By 16-19 hpf (B, C) expression is present in the somites (S), neural
511 tube (NT), and notochord (N). At 24 hpf, expression remains in the NT but is decreased in the S and N.
512 Expression in the lens (L) is first noted at 19 hpf and is particularly prominent by 24 hpf (D-D''). *nr6a1b*
513 expression at 11 hpf is anterior trunk, localizing to neural tube and somites from 16 hpf (F) and 19 hpf (G).
514 At 24hpf (H-H'') it remains expressed in the neural tube and somites, with faint expression can be seen in
515 the lens. All embryos are oriented in a lateral view, anterior to the left and dorsal up, except D' and H'
516 shown in dorsal views. Scale bar = 100 μ M. e-epiphysis, l-lens, p-pronephros, n-notochord, s-somite, nt-
517 neural tube, ad-anterior diencephalon, tg-tegumentum.

518
519

520



521

522

523 **Fig. 5: Rescue of *nr6a1+nr6a1b* zebrafish morphant phenotypes with wildtype and mutant human**
 524 **NR6A1 mRNA:** Controls (A, A') have a straight body axis and the optic fissure (OF) is closed. The
 525 ***nr6a1+nr6a1b*** morphants that have a mild phenotype (B, B') have close to a normal body with
 526 microphthalmia and heart edema; a moderate phenotype (C, C') with a slightly bent body axis with smaller
 527 eyes, coloboma and a severe heart edema; and severe morphants (D, D'') have a curved body axis with
 528 smaller eyes, coloboma and heart edema. The morphant phenotype was rescued when the morpholinos
 529 were co-injected along with the human-*NR6A1*-wild type mRNA. However, there was no significant rescue
 530 in the morphant phenotype when the morpholinos were injected with either R92W or R436C human
 531 disease-causing variants (E). Morpholinos were injected at 0.75 ng each (1.5 ng total). Scale bar = 100µM

532

533

534

535

536

537

538

539

540

541

542

543

544

545

546 **Extended Data**

547 *COL005*

548 The proband of family COL005 (COL005.1) presented with bilateral uveal colobomas (Figure 1B,
549 C). Past ocular history was remarkable for strabismus surgery and amblyopia OS treated with patching.
550 Past medical history was notable for a “small jaw requiring minor reconstruction for proper dentition”,
551 “abnormal enamel to teeth, requiring capping”, and speech therapy. Family history was notable for a
552 sibling (COL005.4) and relatives (COL005.10), (COL005.17) with uveal coloboma. Best-corrected visual
553 acuity was 20/15 OD and 20/60- OS (Snellen). Ocular motility was full with small exophorias at distance
554 and near. Pupils were remarkable for a left iris coloboma. Dilated fundus examination showed a linear
555 pigment disturbance inferior to the optic nerve OD (likely a *forme fruste* of coloboma) and a large
556 chorioretinal coloboma OS inferior to the nerve and macula with hyperpigmentation in its periphery.
557 Several years later, a retinal tear developed in the inferior periphery OS that was treated with laser and
558 has remained stable. Systemic examination was remarkable for 11 thoracic vertebrae, mild scoliosis and
559 spina bifida occulta of S1 on spine x-ray. Mitral valve prolapse was noted on ECHO. Kidney ultrasound,
560 brain MRI, bone age, serum cholesterol, vitamin A, karyotype/sub-telomeric FISH and thyroid function
561 were normal. Genome sequencing in two distantly related family members COL005.1 and COL005.10
562 revealed the same heterozygous 107kb deletion in *NR6A1* (chr9:g.124536516_124643457del, GRCh38).
563 The deletion breakpoints were in intron 2 and 6 removing the coding sequence for amino acids (aa) Ile48-
564 Gly275 and likely causing a frameshift (p.Ile48Asnfs*3, Figure 1H). The status of the heterozygous deletion
565 was determined by breakpoint PCR among family members available, which revealed complete
566 segregation with the missing vertebra with an estimated LOD score of 3.6 (Figure 1A, Figure S1). Four
567 family members were also affected by coloboma in addition to missing vertebra, of which one (COL005.17)
568 also had, by report, only one kidney.

569

570 *COL034*

571 The proband of family COL034 (COL034.1) presented with bilateral uveal colobomas,
572 microphthalmia OS (Figure 1E) and a moderate amplitude, low frequency nystagmus with an anomalous
573 head posture. Prenatal history was remarkable for maternal oral contraceptive use at time of pregnancy
574 and a prenatal ultrasound that showed a two-vessel umbilical cord and inability to visualize the left kidney.
575 Delivery was at term and unremarkable with a birth weight of 5lbs, 3oz. Subsequent growth was slow,
576 requiring growth hormone injections. Ocular examination was remarkable for bilateral microcornea
577 (horizontal diameter 9mm OD, 6mm OS), a left iris coloboma, left sensory esotropia, an inferonasal
578 cortical cataract OD, and bilateral chorioretinal and optic nerve colobomas. Best-corrected visual acuity
579 as a kid was 20/400 OD and <20/800 OS by ETDRS chart. By teens, the left lens began to dislocate slightly
580 and develop mild/moderate nuclear opacity. Spine x-ray demonstrated 10 thoracic vertebrae. Kidney
581 ultrasound showed a normal right kidney and a missing left kidney (normal retroperitoneal or pelvic).
582 Physical exam was remarkable for curvature to superior prominence to the ears, and a left undescended
583 testicle. Chromosomal microarray was normal. Audiology examination and an echocardiogram were
584 unremarkable. Subsequent endocrine workup showed hypothyroidism requiring replacement (in addition
585 to his growth hormone deficiency). In late teens, developed intraocular pressures in the low/mid-twenties
586 with a history of slowly progressive vision loss to hand motion, prompting initiation of intraocular pressure
587 lowering drops. A brain MRI showed small optic nerves/chiasm, no parenchymal abnormalities, and a

588 normal-appearing pituitary. Genome sequencing revealed a heterozygous c. 274C>T p. (Arg92Trp) variant
589 in *NR6A1*, which was found in the affected mother and essentially unaffected grandfather (Figure 1A, H).

590 *COL171*

591 The proband of family COL171 (COL171.1) presented with bilateral colobomatous microphthalmia
592 affecting the iris, retina/choroid and optic nerve. Visual acuity was 20/640 OD and 20/250 OS. Nystagmus
593 and mild abduction deficits were noted. Slit lamp exam was notable for bilateral microcornea, bilateral
594 posterior subcapsular and nuclear cataracts and missing zonules inferiorly OU (Figure 1F). By report,
595 kidney ultrasound, ECHO and physical exam were normal at birth. Spine x-ray showed normal number
596 and morphology of vertebrae. Audiology examination was notable for mild to moderate sensorineural
597 hearing loss across all frequencies in the right ear and mild sensorineural hearing loss in high frequencies
598 of the left ear. Blood chemistries notable for mild elevation of liver function tests and calcium. Genome
599 sequencing revealed a heterozygous c.1306C>T p.(Arg436Cys) variant in the proband which was absent in
600 his unaffected mother (Figure 1H). Additional family members were not available for segregation analysis,
601 but his father had no history of coloboma by report.

602

603 **Supplementary Methods**

604 **Genetic testing**

605 Genomic DNA samples prepared from blood or saliva from NEI patients, and their family members
606 were subjected to short-read Next-generation sequencing (NGS) using Illumina platforms. In total, 101
607 proband samples were subjected to amplicon sequencing of the *NR6A1* gene (Table S1) using a MiSeq
608 sequencer (2 x 300 bp paired-end), 57 samples subjected to exome sequencing (2 x 150 bp paired-end,
609 xGen exome v1 supplemented with additional probes, Blueprint Genetics), 66 samples subjected to GS (2
610 x 150 bp paired-end, PCR-free library, NIH Intramural Sequencing Center). Reads were aligned to the
611 GRCh38 reference genome, small variants and structural variants were then called, annotated, and
612 prioritized using a custom NGS analysis pipeline (https://github.com/NIH-NEI/NGS_genotype_calling &
613 https://github.com/NIH-NEI/variant_prioritization).

614 Sanger sequencing was performed to confirm select variants in probands and family members
615 using the BigDye-direct sequencing kit (Thermo Fisher) using primers provided in Table S1. The deletion
616 breakpoint in family COL005 was also determined by PCR and Sanger sequencing (Table S1). Breakpoint
617 PCR was further used for genotyping of the COL005 family. The logarithm of the odds (LOD) score in family
618 COL005 was estimated using the formula $\log_{10}(1/0.5^{\text{Segregations}})$.

619 Additional patients and family members underwent Genome Sequencing (GS) as part of the
620 UK100KGP including the clinical variant interpretation pipeline (The National Genomics Research Library
621 v5.1, Genomics England. doi:10.6084/m9.figshare.4530893/7. 2020.). Genome data from affected
622 individuals recruited with a clinical phenotype in keeping with microphthalmia, anophthalmia or
623 coloboma were interrogated for rare (minor allele frequency <0.001, gnomAD v3.1 dataset) biallelic or *de*
624 *novo* protein altering variants across the genome. Candidate variants underwent manual curation
625 including *in silico* prediction, literature search and pathway analysis to establish biological plausibility as a
626 pathogenic variant in developmental eye disease. Additional analyses of all rare protein altering variants
627 in *NR6A1* across the entire UK100KGP was performed to identify any individuals outside of the

628 ophthalmology cohort who harbored a candidate pathogenic variant. All variants were manually
629 inspected in the Integrative Genomics Viewer (IGV) after loading sample bam files. Variants appeared to
630 be artifacts were not reported.

631 **Variant classification**

632 The 2015 ACMG/AMP sequence variant interpretation guidelines were followed for variant
633 classification^{31,32}. The PM1 (functional domain) criterion was applied to variants in part of the DNA binding
634 domain, a.a. Thr68-Lys119, as the region is highly constrained for missense variations in gnomAD (v2.1.1,
635 missense observed/expected = 0.19, p-value = 6×10^{-6}). The PP3 criterion was applied to missense variants
636 based on a collection of in-house in silico prediction tools ([https://github.com/NIH-
637 NEI/variant_prioritization](https://github.com/NIH-NEI/variant_prioritization)) and the inframe deletion variant based on five in silico prediction tools
638 (CAPICE, FATHMM-indel, MutationTaster, MutPred-Indel, and SIFT).

639 **Molecular modeling**

640 A structural model of NR6A1 was generated using the AlphaFold server, AF-Q15405-F1-
641 model_v4). The Zn-finger domain (ZFD) and nuclear receptor ligand binding domain (NR_LBD) were saved
642 as two PDB files. The binding of DNA to the ZFD of NR6A1 was modeled using a single ZFD domain of the
643 retinoid X receptor alpha-liver X receptor beta (PDB ID: 4NQA) in a complex with DNA. Two variants (R92W
644 and R436C) were generated using the Edit > Swap > Residue function on the respective domain PDB files
645 in YASARA (<http://www.yasara.org/>). Variant models were optimized and minimized using gradient
646 descent. All two minimized mutants and the two WT, ZFD and NR_LBD models were subjected to 10 ns of
647 Molecular Dynamics (MD) using YASARA's 'run.mcr' macro. Ion concentration was added as a mass
648 fraction with 0.9% NaCl. The simulation temperature was set to 310 K with a water density of 0.997 g/mL.
649 For each domain, the cell size extended to 10 Å beyond each side of the protein in the shape of a cube.
650 Dimensions were 90.2Å x 90.2Å x 90.2 Å and 82.5 Å x 82.6 Å x 82.6 Å for the nuclear receptor Zn-finger
651 and ligand-binding domains, respectively. Each simulation was run in YASARA using an AMBER14
652 forcefield, with a timestep of 2.5 fs. Simulation snapshots were outputted for every 0.1 ns, resulting in
653 100 simfiles for each simulation.

654 **Fish maintenance and zebrafish strains**

655
656 *Danio rerio* were maintained under standard conditions. Embryos were staged according to
657 Kimmel et al., 1995³³. ABTL stocks were used for all the experiments, which were carried out in
658 accordance with National Eye Institute, Animal Care and Use Committee Protocol Number NEI-648.
659

660 **Zebrafish *in situ* hybridization**

661 Embryo were fixed in 4% paraformaldehyde (PFA) overnight at 4°C and dehydrated in methanol
662 for 1h at -30°C. The embryos were rehydrated, treated with proteinase-K and re-fixed with 4% PFA. Pre-
663 hybridization and hybridization were carried out at 65°C. RNA probes were synthesized using a DIG
664 labeling kit (Millipore-Sigma, 112770739) following manufacturer's protocol. *nr6a1a* RNA probe was
665 synthesized from a CDS clone in TOPO TA vector (ThermoFischer Scientific), while *nr6a1b* was synthesized
666 using PCR product as a template. Primers are noted in [Table S2](#). Samples were hybridized overnight with
667 RNA probes at 65°C, washed, incubated with Anti-DIG antibody (Millipore-Sigma, 1109327490); color was

668 developed using BCIP/NBT substrate (Millipore-Sigma, 11681451001) in alkaline phosphatase buffer.
669 Embryos were imaged with Leica DM6 dissecting microscope.

670

671 **Morpholino gene knockdown and rescue experiments in zebrafish**

672 All morpholinos (MO) were obtained from Gene Tools LLC. MOs used to target zebrafish *nr6a1a*
673 and *nr6a1b* are given in **Table S3**. Human *NR6A1*-wild type, variants *NR6A1*-R92W and *NR6A1*-R436C DNA
674 fragments were synthesized and cloned in pCS2+ (Azena Life Sciences). Plasmids were linearized with
675 *Not I* restriction enzyme and capped mRNA was synthesized using mMessage mMachine T7 Transcription
676 kit (ThermoFischer Scientific). MOs and mRNA were co-injected into zebrafish embryos at single cell stage.
677 *nr6a1a* and *nr6a1b* translation blocking (TB) MOs were used at 2ng and 1.25ng respectively. Nr6a1a and
678 nr6a1b, SB-MOs were injected at 2ng and 1ng respectively. Human *NR6A1*-wild type was used at 100pg
679 and 150-200pg for RNA rescue and over expression studies respectively. *NR6A1*-R92W and *NR6A1*-R436C
680 RNAs were used at 100pg for rescue experiments. For over-expression experiments, doses of 100pg-
681 200pg *hNR6A1* mRNA were injected at the single cell stage. Embryo phenotypes were scored and imaged
682 at 72 hours post-fertilization (hpf) using Leica DM6 dissecting microscope.

683

684 **Cell culture and transfection studies**

685 HEK293T cells maintained in DMEM with 10% FBS and 1% penicillin-streptomycin were seeded
686 onto 4-well chamber slides, maintained for 24 hr and transiently transfected with GFP tagged WT and/or
687 mutant *NR6A1* constructs (Azena Life Science, Burlington, MA, USA) using X-treme Gene HP (Roche,
688 Indianapolis, IN, USA) following manufacturers' instructions. After 24-48 hrs of transfection, transfected
689 cells were fixed for 15 mins in 4% paraformaldehyde (PFA) in PBS. After washing with 1× PBS cells were
690 incubated for 1 hr at room temperature with Hoechst33342 (1:250 dilution in PBST). Subsequently, the
691 slides were washed and mounted with Fluoromount-G® (SouthernBiotech, Birmingham, AL, USA). Zeiss
692 confocal microscopes 880 coupled with an Airyscan® detector was used for confocal imaging. The images
693 were analyzed using ZEN Software (Carl Zeiss Microscopy LLC, Thornwood, NY). The cell culture
694 experiments were repeated at least three times for each for variant localization studies.

695 **Flow cytometry**

696 Transfection efficiency was determined by measuring the expression of GFP after 48 hrs post
697 transfection. HEK293 cells were detached from the plates using Trypsin for 5 mins followed by
698 neutralization with serum containing media. The cells were then fixed for 15 mins in 4% paraformaldehyde
699 (PFA) in PBS and then collected in 1xPBS containing 2% FBS (FACS buffer) and washed 2 times by
700 centrifugation. The cell suspension was filtered through a 50 µm cell strainer. Data was acquired with a
701 CytoFlex NUV instrument (Beckman Coulter, Brea CA) using the blue light excitation and 525 nm emission
702 to detect GFP and violet light excitation and 450 nm emission to detect DAPI detection. Data analysis was
703 done using CytExpert software Version 2.5 (Beckman Coulter, Brea CA). Interesting cells were identified
704 as DAPI negative, in the whole cell cluster in a FSC vs. SSC plot and being in a single cell state in the FSC-A
705 vs. FSC-Width. Transfection efficiency was quantified as the Stain Index of GFP fluorescence intensity,
706 which was calculated using the median fluorescent intensity and robust Standard Deviation as
707 described.¹⁴ The cell culture experiments were repeated at least three times for each for variant
708 localization studies.

709

710 **Mouse Embryo *in situ* Hybridization**

711 *Nr6a1* mRNA expression in mouse was assayed by RNA *in situ* hybridization with *Nr6a1*(Cat:
712 1314941-C1) probe using the RNAScope Assay, Multiplex fluorescent Reagent Kit V2 (Advanced Cell
713 Diagnostics (ACD), Newark, CA, USA) on E10.5 and E11.5 cryosection as previously described³⁴.

714 **Gene expression analysis of *NR6A1***

715 The h5ad (d27a79a1-8a5f-404d-8063-52e19122ef49.h5ad for adult and 88444d73-7f55-4a62-
716 bcfe-e929878c6c78.h5ad for fetal) from the HRCA project were downloaded from
717 cellxgene.cziscience.com and the raw counts were summed at the sample and cell type level to create a
718 pseudobulk matrix with the python package ADPBulk (<https://github.com/noamteyssier/adpbulk>). The
719 eyeIntegrations (which includes GTEx) gene counts and metadata were downloaded from
720 eyeIntegrations.nei.nih.gov (https://hpc.nih.gov/~mcgaugheyd/eyeIntegrations/2023/gene_counts.csv.gz
721 and
722 [https://hpc.nih.gov/~mcgaugheyd/eyeIntegrations/2023/eyeIntegrations23_meta_2023_09_01.built.csv.
723 gz](https://hpc.nih.gov/~mcgaugheyd/eyeIntegrations/2023/eyeIntegrations23_meta_2023_09_01.built.csv.gz)).

724 The pseudobulk and bulk RNA-seq counts were normalized with by CPM and transformed in R/4.3 to have
725 a mean of zero and a standard deviation of one. The first four principal components were removed with
726 the WGCNA tool removePrincipalComponents. The correlation matrix was created with the base R cor
727 function. The correlation scores were expression transformed with the spqn package's normalize
728 correlation function. Plots of the expression of *NR6A1* were created in R/4.3 with the ggplot2, cowplot,
729 and ggbeeswarm packages.

730

731

732

733

734

735 **Supplementary Tables**

736 [See Excel Spreadsheet]

737 Supplementary Table 1: PCR primers used for human DNA sequencing

738 Supplementary Table 2: Primers used in zebrafish in situ experiments

739 Supplementary Table 3: Morpholinos used in zebrafish gene knock-down experiments.

740 Supplementary Table 4: Variant and phenotypic information of rare NR6A1 variant carriers in the
741 UK100KGP cohort

742 Supplementary Table 5: Detailed breakdown of zebrafish morpholino experiments

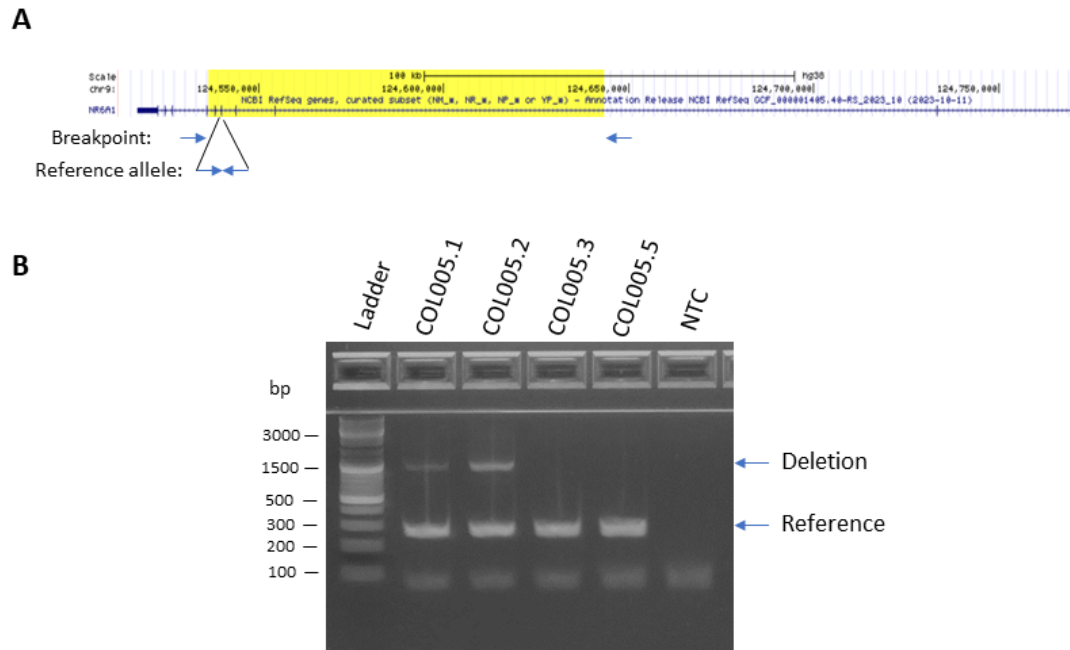743

744

745 **Supplementary Figures and Legends**

746

747



748

749

750 **Supplementary Fig. 1: NR6A1 genotyping for the deletion in family COL005 (A),** Diagram of the 107-kb
751 deletion (yellow-highlighted) and primer binding sites. (B), Example image of the agarose gel
752 electrophoresis of duplex PCR.

753


754

755 **Pedigrees of the Probands and clinical images of eyes are available upon request form the**
756 **corresponding author.**

757 **Supplementary Fig. 2: Phenotypes associated with NR6A1 variants in UK100KGP. A.** Pedigrees of three
758 families (A; B; C) from the UK100KGP cohort demonstrating coloboma with or without microphthalmia.
759 Inheritance is autosomal dominant with incomplete penetrance and variable expressivity. **B.** Chorioretinal
760 coloboma found in individual A1; *forme fruste* on the right eye (arrow). **C.** Iris coloboma and chorioretinal
761 coloboma found in individual C1. +, individual with variant; -, individual without variant. See
762 **Supplementary Table S5** for variant information.

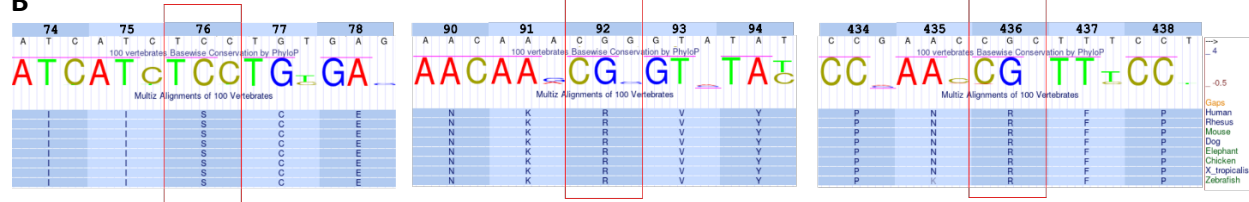
763

A



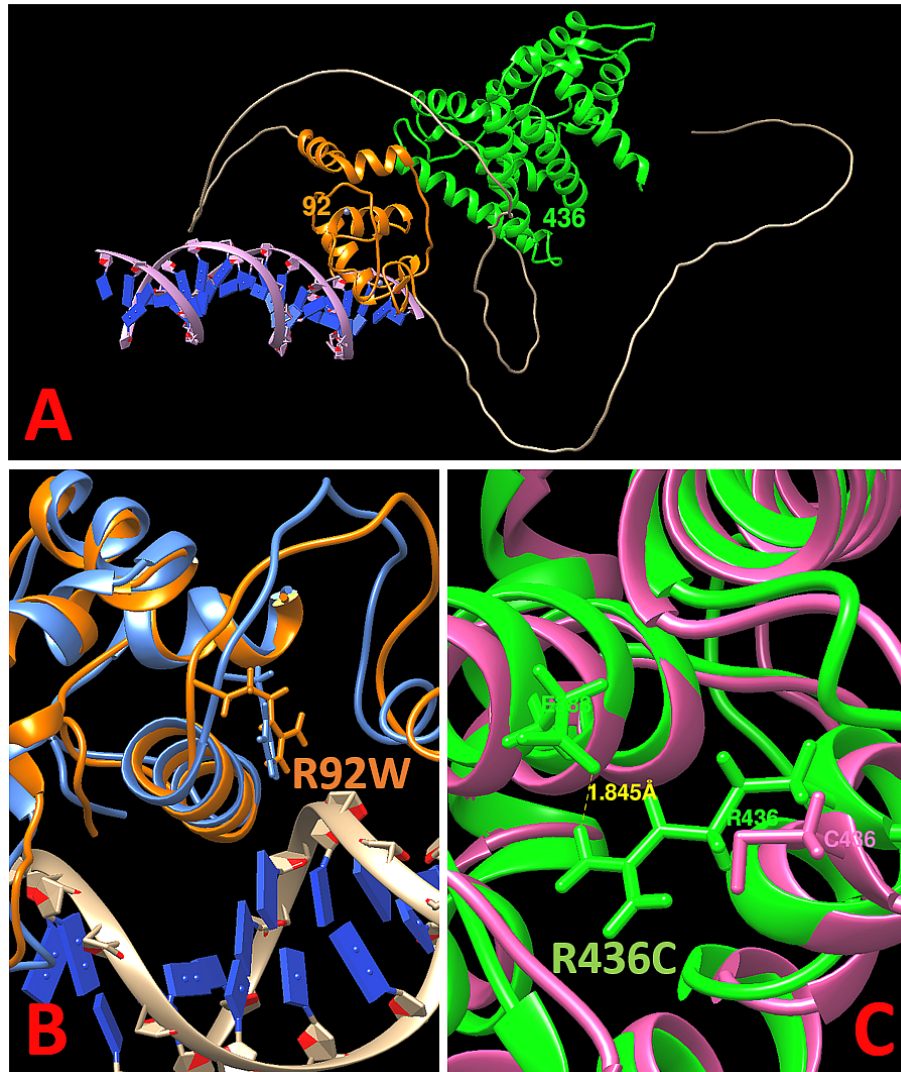
764

B



765

766 **Supplementary Fig. 3: NR6A1 conservation A.** Multiple species alignment (MSA) of the canonical
 767 transcript of human, mouse, and zebrafish *NR6A1/Nr6a1/nr6a1* (a and b paralogs) showing a high degree
 768 of conservation. **B.** Conservation of Ser76, Arg92 and Arg436 residues during vertebrate evolution. The
 769 images for 100 vertebrates Basewise Conservation by PhyloP and Multiple Tissue Alignments of 100 Vertebrates
 770 were adapted from the UCSC genome browser. Human NR6A1 cDNA sequence and amino acid numbers
 771 are listed on the top.

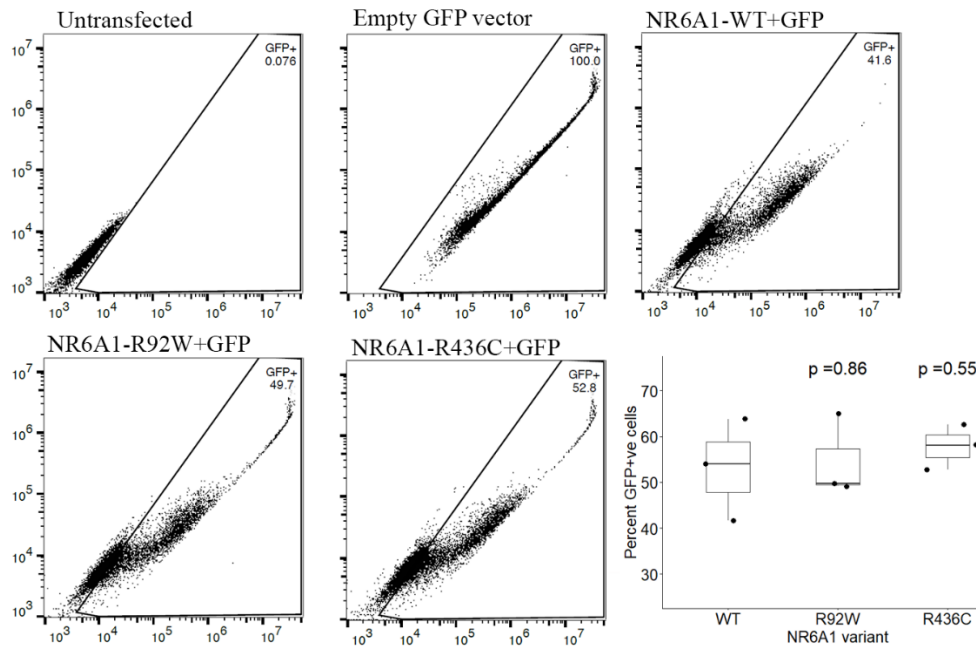


772

773 **Supplementary Fig. 4:** A. *In silico* molecular modeling of NR6A1 with DNA (lilac helix with blue base
774 pairs). The predicted DNA-binding domain and ligand-binding domain are shown in orange and green,
775 respectively. The positions of R92W and R436 are noted. B. The R92W variant changes a positively
776 charged Arg to a hydrophobic Trp and is expected to disrupt interaction with the negatively charged DNA
777 helix. C. The R436C variant is predicted to disrupt a hydrogen bond between R436 and E388 and
778 substitute a Cys residue that could form abnormal disulfide bridges within the protein.

779

780

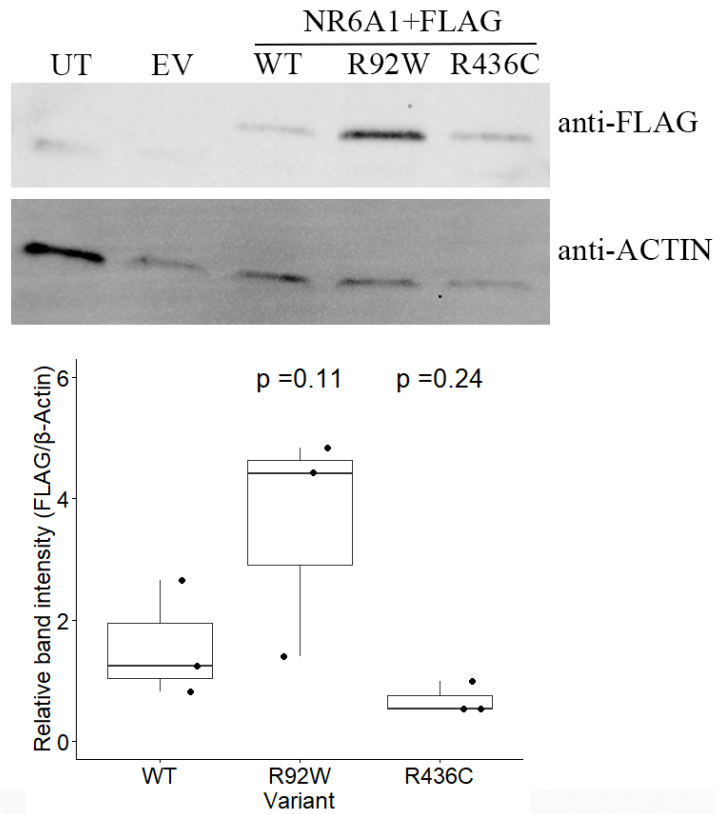


781

782 **Supplementary Fig. 5:** Flow cytometry of wild-type (WT) and mutant (R92W, R436C) forms of NR6A1
783 demonstrating comparable transfection efficiencies.

784

785



786

787

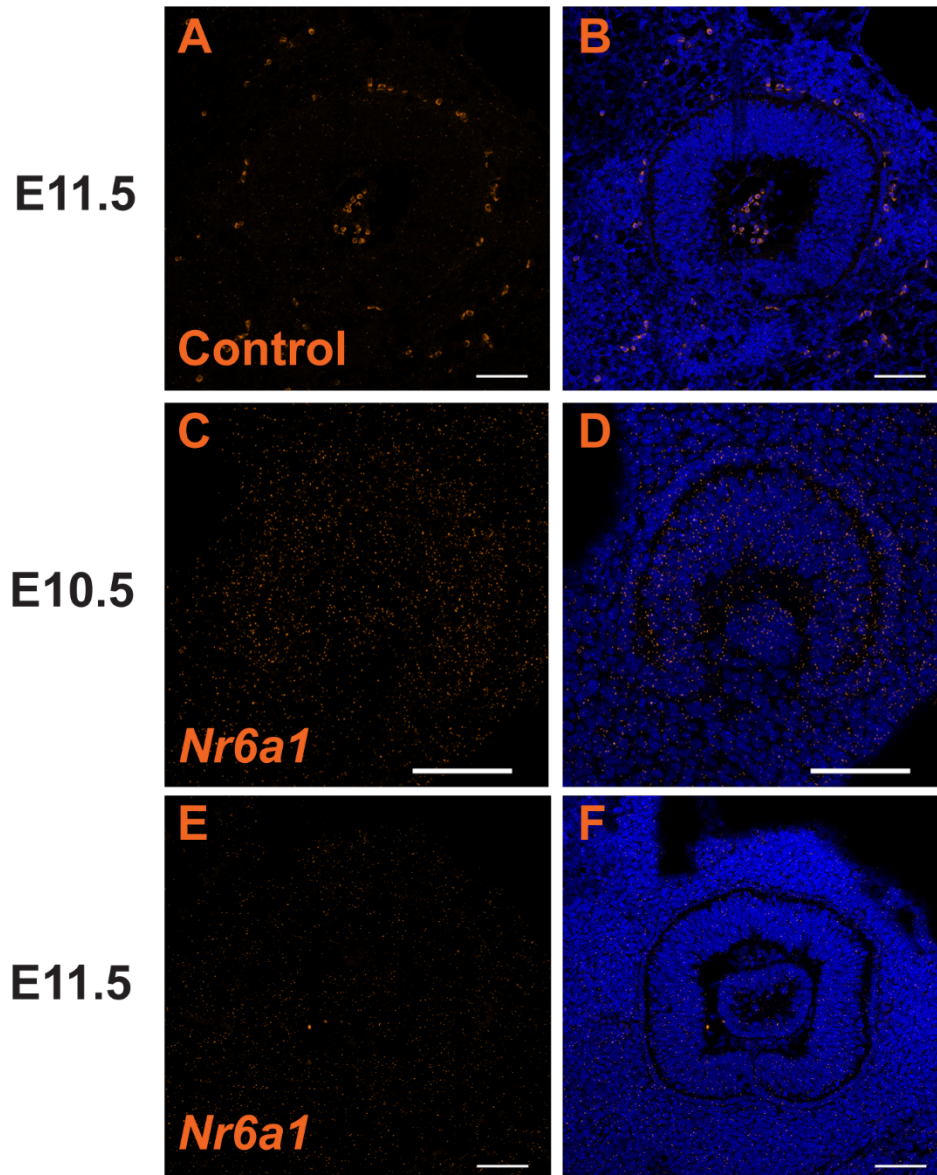
788 **Supplementary Fig. 6:** Western blot of HEK293 cells transfected with wild-type (WT) or mutant (R92W,
789 R436W) forms of *NR6A1*, demonstrating comparable transfection efficiencies.

790

791

792

793

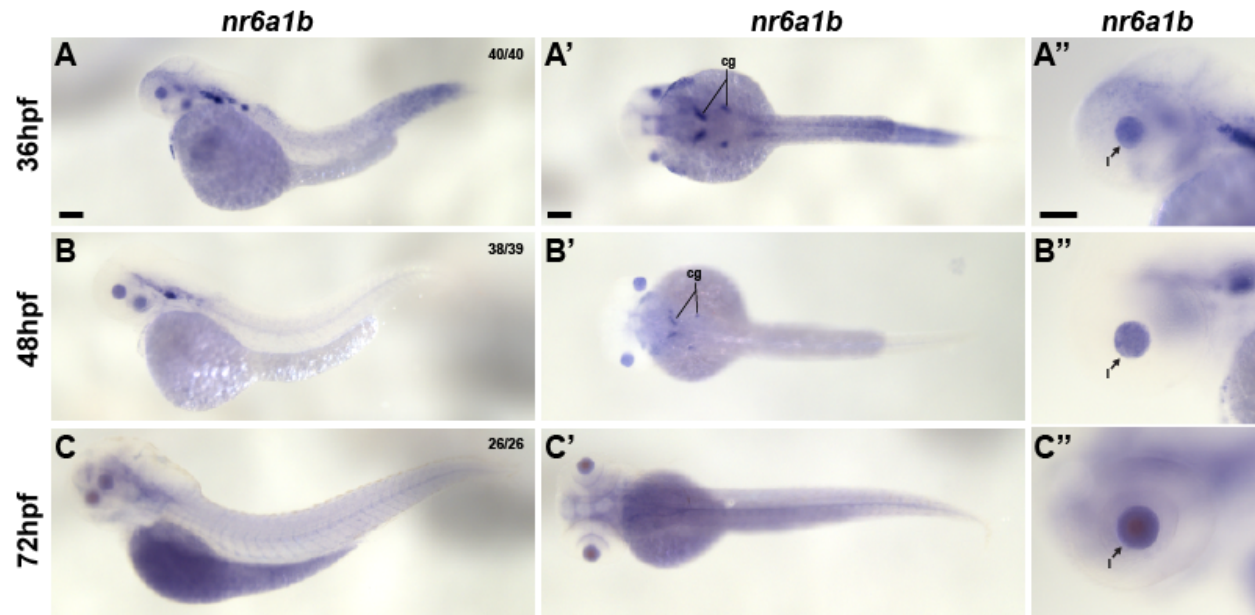


794

795

796 **Supplementary Fig. 7:** Expression of *Nr6a1* in sagittal sections of mouse embryonic eye before (E10.5)
797 and during (E11.5) optic fissure closure. Low level expression throughout the tissue at E10.5 (C,D)
798 becomes significantly downregulated by E11.5. (E,F). Expression shown with and without DAPI
799 counterstain along with control samples (A,B). Scale bar = 100 μ m.

800



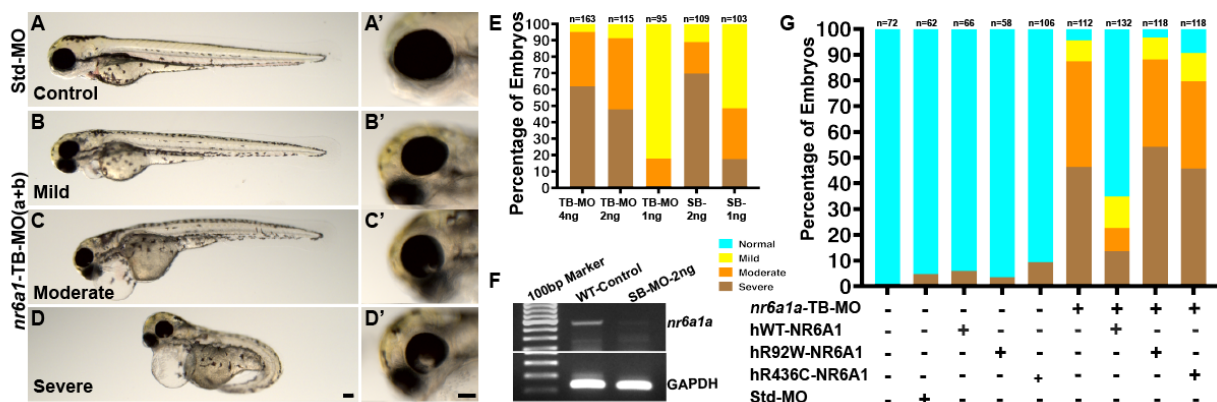
801

802 **Supplementary Fig. 8:** *nr6a1b* mRNA expression during later developmental stages (36 hpf (A-A''), 48 hpf
803 (B-B''), and 72 hpf (C-C'')) of zebrafish development. Note prominent expression in the developing lens
804 (arrow) at all time points and decreased expression in the somites and neural tube, compared to earlier
805 time points. cg-cranial ganglia, l-lens. Scale bar = 100 μ M.

806

807

808



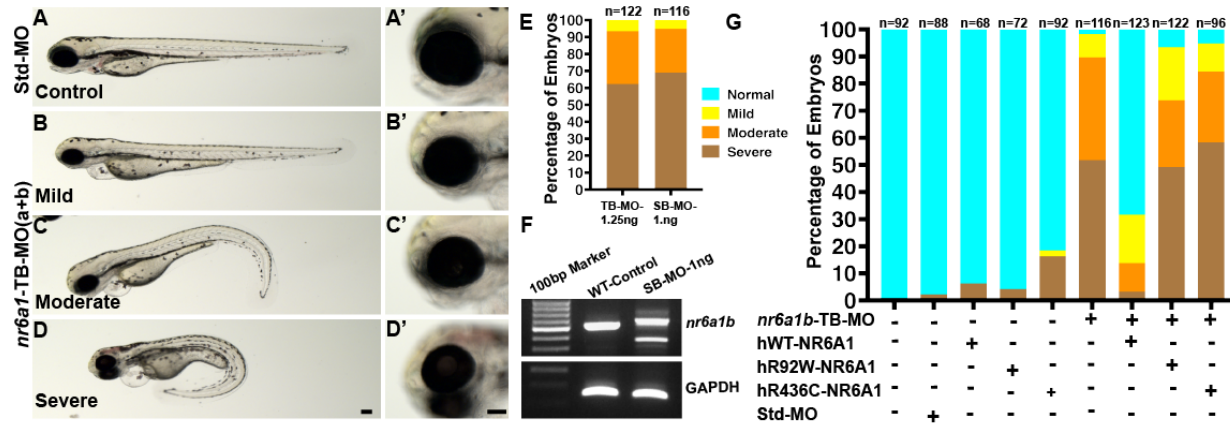
809

810 **Supplementary Fig. 9:** Morpholino (MO) mediated knockdown of the *nr6a1a* paralog with either
 811 translation blocking (TB-MO) or splice-blocking (SB-MO) results in a spectrum of phenotypes including
 812 colobomatous microphthalmia, shortened/bent body axis and heart edema (A-D, with higher
 813 magnification of the eye in the corresponding A'-D' panel). 2ng of either TB-MO or SB-MO was sufficient
 814 to cause 80-90% of embryos to have a moderate or severe phenotype (E). Efficient blocking of the splicing
 815 by the SB-MO was confirmed with reverse-transcriptase PCR (F). Although 100pg human wild-type (hWT)
 816 mRNA resulted in dramatic phenotypic rescue of the TB-MO (>60% with a normal phenotype), rescue with
 817 either hR92W- or hR436W-mRNA was considerably less effective (F). Scale bar = 100µM.

818

819

820



821

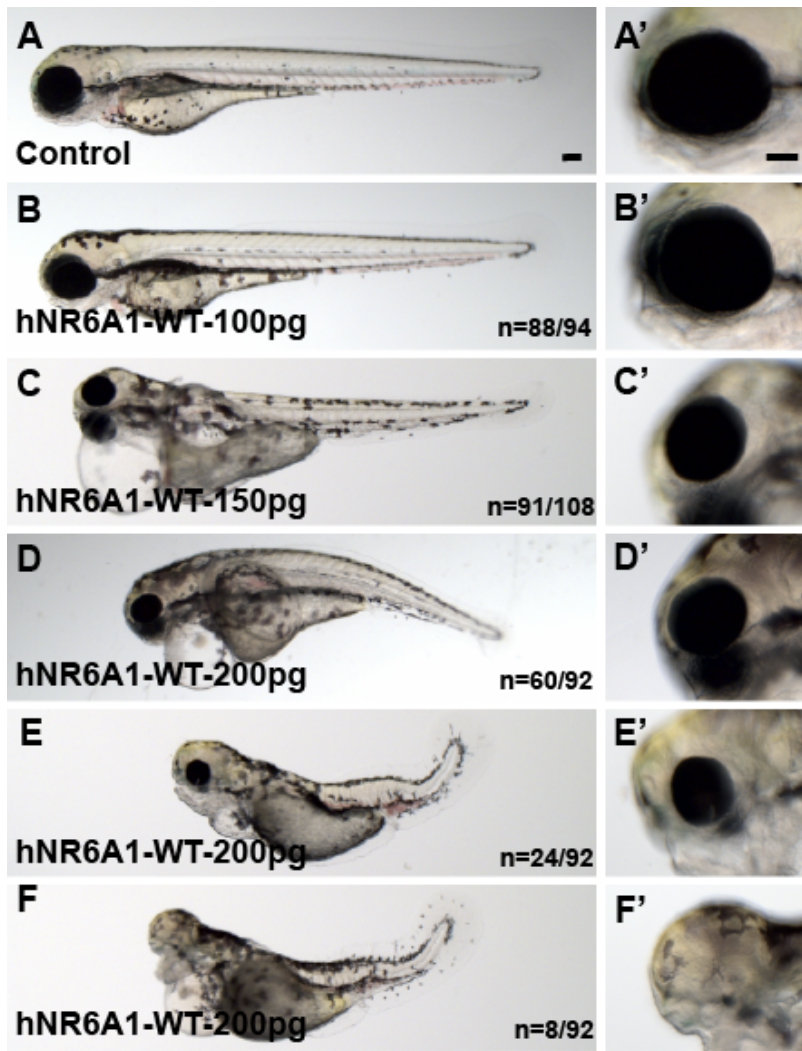
822 **Supplementary Fig. 10:** Morpholino mediated (MO) knockdown of the *nr6a1b* paralog with either
 823 translation blocking (TB-MO) or splice-blocking (SB-MO) results in a spectrum of phenotypes including
 824 microphthalmia, shortened/bent body axis and heart edema (A-D, with higher magnification of the eye in
 825 the corresponding A'-D' panel). 1.25ng and 1ng of TB-MO and SB-MO respectively, was sufficient to cause
 826 80-90% of embryos to have a moderate or severe phenotype (E). Efficient blocking of the splicing by the
 827 SB-MO was confirmed with reverse-transcriptase PCR (F). Although 100pg human wild-type (hWT) mRNA
 828 resulted in dramatic phenotypic rescue of the TB-MO (>60% with a normal phenotype), rescue with either
 829 hR92W- or hR436W-mRNA was considerably less effective (F). Scale bar = 100µM.

830

831

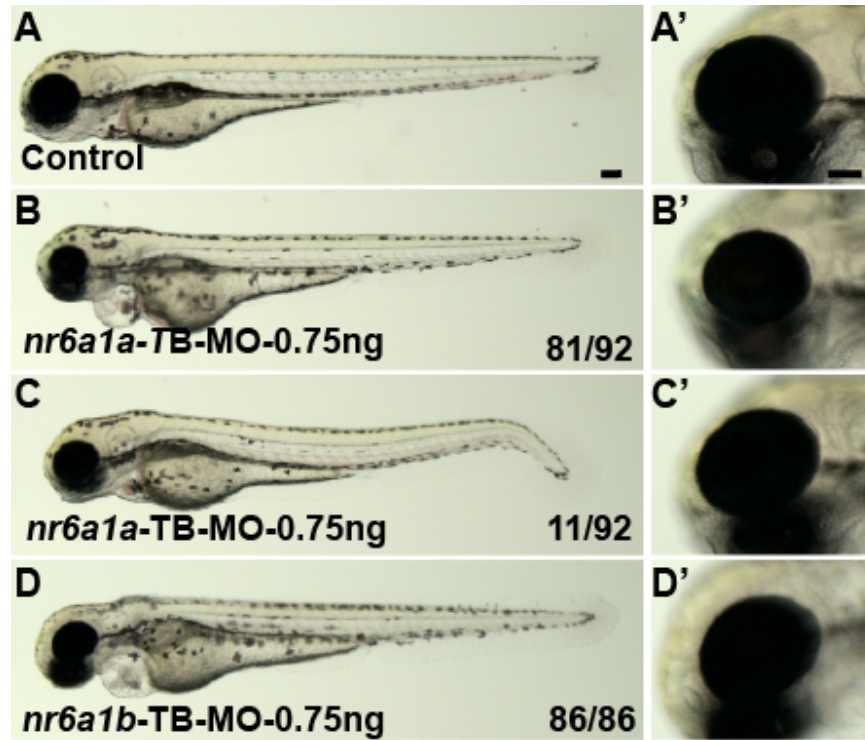
832

833



834

835 **Supplementary Fig. 11: Overexpression of human NR6A1 (*hNR6A1*) in zebrafish:** Control and 100pg
836 injected embryos have a normal body with closed OF (A-B'). Embryos injected with 150pg of *hNR6A1* have
837 a shortened but straight body axis, microphthalmia and heart edema (C, C'). A variable phenotype is
838 observed with 200pg of *hNR6A1* RNA, including a bent body axis, heart edema and colobomatous
839 microphthalmia (D, D') The remaining embryos have a curved body axis with somites losing their chevron
840 shape, microphthalmia with coloboma, and in some cases, lack of eyes and heart edema (E-F'). WT = wild
841 type. Scale bar = 100µM.



842

843 **Supplementary Fig. 12: Effect of individual TB-MO for *nr6a1a* and *nr6a1b* at 0.75ng.** Control embryos
844 have a straight body and a closed OF (A, A'). Both *nr6a1a* and *nr6a1b* TB morphants at 0.75ng dosage, had
845 straight bodies and microphthalmia, except a few embryos from the *nr6a1a* group which had a slightly
846 curved tail (B-D'). Scale bar = 100 μ M.

847

848

849

850

851

852

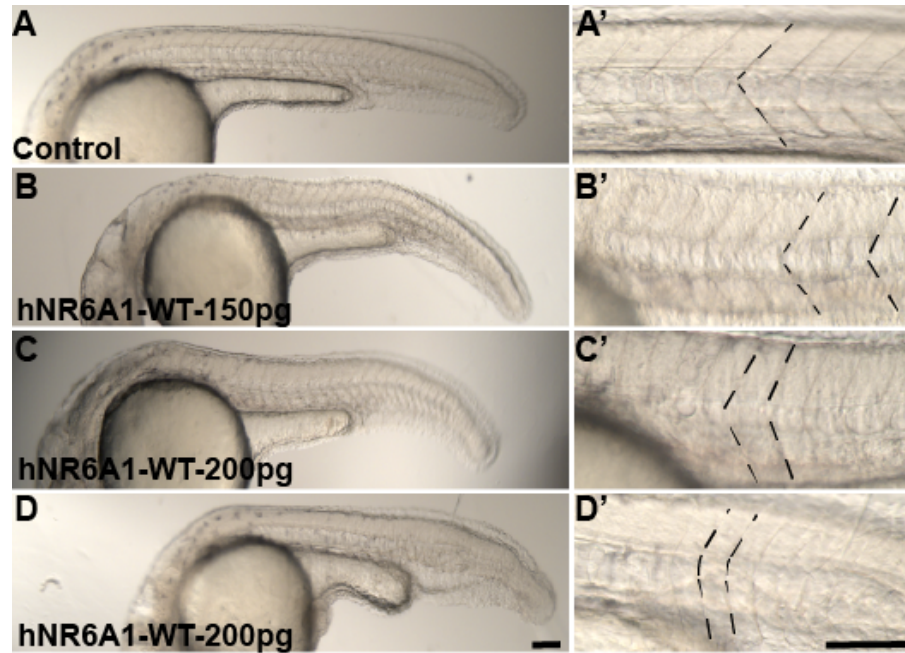
853

854

855

856

857



858

859 **Supplementary Fig. 13: Phenotype of somites in zebrafish embryos over expressed with human NR6A1**
860 **(*hNR6A1*):** Control embryos have chevron shaped somites (A, A'), embryos injected with 150pg and 200pf
861 of *hNR6A1* lose the shape of their somites at varying degrees (B-D"). Scale bar = 100μM.

862

863

864