

Title: Evaluating the Etiology of Metallic Taste During Head and Neck Cancer Treatments: A Study of Facial and Glossopharyngeal Nerve Interactions

Short title: Are There Neural Origins in Metallic Taste in Cancer?

Authors: Guillaume Buiret^{1,2,3} MD, BRIGNOT H  l  ne³, SEPTIER Chantal³, FERON Gilles PhD³, THOMAS-DANGUIN Thierry PhD³

Affiliations:

1. Service ORL et Chirurgie Cervicofaciale, Centre Hospitalier de Valence, 179 Boulevard du Mar  chal Juin, 26953 Valence, France
2. Universit   de Bourgogne Franche Comt  , Esplanade Erasme, 21000 Dijon France
3. Centre des Sciences du Go  t et de l'Alimentation, 9^E Boulevard Jeanne d'Arc, France

Corresponding author:

G. Buiret, Service ORL et Chirurgie Cervicofaciale, Centre Hospitalier de Valence, 179 Boulevard du Mar  chal Juin, 26953 Valence, France. E-mail: gbuiret@ch-valence.fr. Fax: +334 75 75 71 10. N   ORCID 0000-0001-5425-6835

All authors contributed to the study conception and design. Material preparation, data collection and analysis were performed by Guillaume Buiret, Chantal Septier and H  l  ne Brignot. The first draft of the manuscript was written by Guillaume Buiret and all authors commented on previous versions of the manuscript. All authors read and approved the final manuscript.

Financial interests: *The authors have no relevant financial or non-financial interests to disclose.*

Funding to report to this submission : This work was supported by the Comit  s de la Dr  me et de l'Ard  che de lutte contre le Cancer.

Aknowledgements: to C.T. Molta, MD, for the English translation.

ABSTRACT

Metallic Taste (MT) is frequently described during head and neck cancer treatments but very little is known about its etiologies. One hypothesis to explain the MT is the removal of facial nerve inhibition on the glossopharyngeal nerve. Indeed, the decrease of taste afferents mediated by the facial nerve (anterior two-thirds of the tongue) due to cancer or its treatments, would reveal those mediated by the glossopharyngeal nerve (posterior one-third of the tongue) and thus lead to MT perception. The aim of this study was to evaluate the validity of this hypothesis.

Selective supraliminal taste tests on the tip and the base of the tongue were regularly performed on 44 patients with head and neck cancers before, during, and after their treatment. Sweet, salty, bitter, sour, and MT were tested. Patients were grouped based on whether they reported experiencing MT or not.

12 patients complained about MT (27.2%), always during the treatment phase. Most of them (83.3%) were treated by surgery and radiotherapy or radiochemotherapy. Supraliminal tastes were altered in every patient, especially during the treatment phase. Test results showed that perceived intensity was significantly reduced in patients reporting MT for salt, sweet and sour. This was observed more on the base of tongue than on the tip of the tongue. MT was significantly linked with mucositis ($p=0.027$) but with neither candidiasis ($p=0.38$) nor salivary flow ($p=0.63$).

The hypothesis of removal of facial nerve inhibition on the glossopharyngeal nerve cannot explain MT in head and neck cancer.

Keywords: metallic taste, head and neck cancers, glossopharyngeal nerve, facial nerve

INTRODUCTION

Head and Neck Cancers (HNC), encompassing a diverse range of malignant tumors affecting anatomical structures crucial for speech, swallowing, and breathing, present a substantial challenge in the field of oncology. First, even if the incidence is decreasing, they are the fifth most common cancers in men worldwide (1). HNC are characterized by their significant impact on patients' quality of life due to symptoms that impair essential oral and throat functions (2-4). Among the numerous manifestations associated with these cancers, Metallic Taste (MT) stands out as one of the most complex and poorly understood symptoms. MT is described by patients as a persistent sensation of metallic flavor in the mouth. It can manifest at various stages of the disease, whether during diagnosis, treatment, or remission. This disruption of the sense of taste has profound consequences on appetite, nutrition, and quality of life of patients and can even influence their adherence to treatment, as it may contribute to weight loss and malnutrition (5-7). While MT is widely acknowledged by healthcare professionals as a common side effect of cancers in general and Head and Neck Cancers (HNC) particularly (8, 9), its understanding, management, and underlying mechanisms remain inadequately explored. This knowledge gap hinders our ability to offer appropriate treatment strategies to alleviate this symptomatic manifestation.

According to Logan et al. (10) or Reith et al. (11), the causes of MT are not understood. It may be linked with oral health issues (mucositis, candidiasis), a neuropathy, the reduction in taste receptors, a direct stimulation of a specific MT receptor close to bitter receptors (T2R) or receptors of the TRPV1 family, the toxicity to salivary glands, the intra-oral lipoperoxidation. Among the possible causes, the removal of facial nerve inhibition on the glossopharyngeal nerve may be hypothesized (12). Under normal circumstances, the facial nerve may exert an inhibitory effect on the glossopharyngeal nerve to regulate taste sensation. Because of the cancer and/or its treatments, the decrease of taste afferents mediated by the facial nerve (anterior two-thirds of the tongue) would reveal those mediated by the glossopharyngeal nerve (posterior one-third of the tongue), leading to abnormal taste sensations such as MT. This lack of inhibition effect is commonly evoked after middle ear surgery (12-16) but has never been proven in HNC.

In case of release of inhibition of the facial nerve on the glossopharyngeal nerve, the following results are expected: for one or more tastes, the taste on the tongue base should be significantly more intense than on the tip of the tongue in case of MT. In this study, we tested this hypothesis by performing supraliminal taste tests in both territories of the taste nerves on the tongue in patients with HNC, regardless of their treatments. The perceived intensity of sweet, salty, bitter, sour, metallic tastes was recorded following the application of specific taste-eliciting compounds on the anterior and posterior parts of the tongue, as well as on both sides (left and right). Since MT could occur at various stages of the treatment protocol, each patient was tested at multiple time points before, during, and after treatment.

MATERIAL AND METHODS

Study population:

The prospective study involved a cohort of 44 patients diagnosed with HNC. These patients were included at the onset of their cancer, before the occurrence of MT and were followed-up during one year, unless a recurrence or another cancer occurs.

Supraliminal recognition then intensity taste testing:

Selective supraliminal taste tests were conducted on each patient at regular intervals. Identical tests were performed before any treatment ((m) moment 1); after surgery if any (m2); in the middle (m3) and at the end (m4) of the radiotherapy if any; at 3 (m5)-6 (m6)-9 (m7) and 12 (m8) months. Taste assessments were carried out on four distinct regions of the tongue: the tip (taste mediated by the facial nerve) and the base (taste mediated by the glossopharyngeal nerve) and each on the right and on the left. Figure S1 in the appendix presents the test locations on the tongue. A cotton swab, soaked in a solution of tastant diluted in Evian water, was applied to each of the predefined lingual locations (tip/base, left/right) following a sequence that avoided anticipation through iterative testing. The evaluation encompassed the following tastes (tastants): sweet (sucrose, 850g/l), salty (sodium chloride, 75g/l), bitter (anhydrous caffeine, 20g/l), sour (citric acid, 50g/l), and metallic (iron sulfate, 10 g/l). All tastants were purchased at Merck (Saint-Quentin-Fallavier, France). Each patient was asked first to identify the taste and then to rate the perceived intensity on a numerical scale from 0 (no perception) to 5 (very intense) at each of the four predefined lingual locations. The mouth was rinsed with Evian water between each test.

Other tests:

The oral mucositis and candidiasis were determined by oral examination by an ENT (0 if no, 1 if yes). The non-stimulated salivary flow was determined by weighing the saliva collected over a 10-minute period as described previously (15).

Data Analysis:

At the end of the study, patients were divided into two groups based on whether they reported experiencing metallic taste (MT) or not.

Confidence intervals by moments and tongue locations were calculated for different time points and tongue locations to compare taste intensity between patients who reported experiencing MT and those who did not. According to Neyman and Pearson (17), if the confidence intervals don't cross on the graph, the test was considered as significant.

Links between oral mucositis and MT status and candidiasis status and MT status were determined by chi-squared tests.

The potential link between salivary flow reduction and MT was determined by comparing the mean flow according to MT status by a t-test.

A p-value of <0.05 was considered statistically significant for every test in this study.

Ethical Considerations:

This study was conducted in accordance with the French ethical guidelines and principles related to biomedical research. An informed consent was obtained from all participating patients. The whole study received approval from the ethic committee CPP Est I, Dijon, France (2017-A03641-52). The protocol was registered on Clinicaltrials.gov (NCT03558789).

RESULTS

44 patients were recruited and followed up for one year. The flowchart is reported in figure 1. The characteristics of the population are presented in table 1. As in every study on HNC, the patients were predominantly male, middle-aged, and with advanced Tumor and Node stages. The treatment was predominantly multimodal.

| | |
|--|---|
| Sex: males n(%) ; females n(%) | 34 (77.3%), 10 (22.7%) |
| Mean age at diagnosis \pm SD (year) | 63.1 \pm 9.8 |
| Location n (%): Hypopharynx Larynx Oropharynx Oral Cavity Unknown primary | 3 (6.8%) 8 (18.2%) 14 (31.8%) 14 (31.8%) 5 (11.4%) |
| Tumor stage n (%): 1 2 3 4 x | 9 (20.4%) 18 (40.9%) 8 (18.2%) 4 (9.1%) 5 (11.4%) |
| Node stage n (%): 0 1 2a 2b 2c 3a | 20 (45.5%) 10 (22.7%) 4 (9.1%) 5 (11.4%) 2 (4.5%) 3 (6.8%) |
| Smoking at inclusion n (%): Yes No Quit | 20 (45.5%) 5 (11.4%) 19 (43.1%) |
| Treatment Withdrawal of consent before treatment Chemotherapy, surgery, radiotherapy Surgery Surgery, radiotherapy Surgery, radiochemotherapy | 5 (11.4%) 1 (2.2%) 14 (31.8%) 12 (27.3%) 12 (27.3%) |

Table 1 : population characteristics

Among the 23 patients who completed the whole study, 12 complained of MT (27.2%) ; they all reported MT during the treatment phase (moments 2 to 5, one patient still at moment 6). Ten of these patients (83.3%) were treated by surgery and radiotherapy or radiochemotherapy, and two others (16.7%) by surgery only.

The figures 2 to 5 represent the evolution of mean taste intensity as a function of the time of treatment, and according to the reported MT status for the bitter, salty, sour, sweet respectively. The figure S2 in the appendix represent the same results for the metallic taste. The results of all chi-2

tests to evaluate differences between groups of patients for taste recognition and t-tests for taste intensity are presented in the supplement (table S1 and S2) respectively. No differences were observed for taste recognition. Most of the intensities were not significantly different in function of MT status and tongue location. Nevertheless, intensities were significantly reduced in patients with metallic taste for salty (figure 3), sour (figure 4) and sweet (figure 5) tastes, during treatments (most of the time at the end of radio(chemo)therapy, i.e. moment 4). The differences were observed on the base of tongue locations as well as on the tip of the tongue.

There was only one patient who reported MT at moment 6 so no confidence interval was made possible and statistical significance was not retained.

For each taste, intensities recorded when applying stimuli on the tip of the tongue (i.e. facial nerve mediation) and on the tongue base (i.e. glossopharyngeal nerve mediation) were added up. The mean differences (posterior minus anterior) were then compared according to the MT status. The results are presented in Table 2.

| | patients reporting MT | patients reporting No MT | p-value |
|--------|-----------------------|--------------------------|---------|
| Bitter | 0.2 ± 1.5 | 0.7 ± 1.9 | 0.177 |
| Salty | -1.3 ± 2.1 | -0.1 ± 1.7 | 0.031 |
| Sour | -0.7 ± 2.0 | 0.4 ± 1.6 | 0.028 |
| Sweet | -1.3 ± 2.3 | -0.2 ± 1.4 | 0.056 |

Table 2: intensity differences (posterior minus anterior) of tastes according to metallic taste (MT) status

For salty and sour tastes, the mean intensity was significantly lower on the tongue base than on the tip of the tongue in the case of patients reporting MT ($p=0.031$ and 0.028 respectively). This was almost significant for sweet taste ($p=0.056$).

A negative value means that the intensity was higher on the tip of the tongue than on the tongue base. A positive value means that the intensity was higher on the tongue base than on the tip of the tongue.

To summarize, salty and sour tastes intensities on the tip of the tongue were lower than on the tongue base for patients reporting MT compared to patients who did not report MT. The difference was marginally significant for sweet taste but not significant for MT.

Besides, MT was significantly linked with mucositis ($p=0.027$) but with neither candidiasis ($p=0.38$) nor with salivary flow ($p=0.63$).

DISCUSSION

Our findings reveal that the intensities of all tastes decreased across various regions of the tongue during HNC treatments. Although the decline was more pronounced at the base of the tongue than at the tip, there were no significant differences for most of the tests. This disproves the hypothesis that the removal of facial nerve inhibition on the glossopharyngeal nerve is responsible for this phenomenon (12). Instead, this aligns with Deshpande et al. (18), who suggested that dysgeusia in HNC is more likely due to a reduced density of taste buds rather than nerve damage.

Changes in Taste Perception During HNC Treatments

The observed pattern of side-effects peaking during irradiation and then recovering, as seen in our study, is commonly reported in other series for taste intensity tests (20-23) and salivary flows (24). Sapir et al. also did not find any correlation between dysgeusia and salivary flow, although they did find a correlation between dysgeusia and xerostomia questionnaire responses (24).

All taste intensities decreased during HNC treatments, with a subsequent recovery. There were some differences between the two groups of patients based on reported MT, regarding salty and sour tastes, possibly due to higher alteration of ion channel receptors. Interestingly, our findings showed an inverse relationship between the expected results for different tongue regions. The base of the tongue, typically less sensitive to these tastes, showed a greater decrease in taste intensity compared to the tip. This could suggest a more complex mechanism involving different receptor types and their distribution across the tongue. Finally, the recovery phase observed in taste intensities mirrors patterns found in other studies (20-23).

Metallic Taste (MT) and Its Mechanisms

When specifically considering MT, its incidence in our study was 27.2%, which is consistent with other series (9). Previous studies on tympanic cord anesthesia, a branch of the facial nerve involved in taste, have shown a significant increase in bitter intensity at the base of the tongue and MT (13-16). However, our results do not support a potential link between bitter receptors and MT (19), as bitter intensity did not significantly differ between MT and non-MT patients (Figure 2, Tables S1 and S2). This lack of significant differences highlights the need for further research into the specific mechanisms underlying these changes in taste perception during and after HNC treatments. Moreover, MT was significantly associated with mucositis but not with candidiasis or salivary flow. Given that the removal of facial nerve inhibition on the glossopharyngeal nerve seems to be disproved and MT is linked to mucositis but not candidiasis, the most probable explanation for MT is inflammation, specifically lipoperoxidation. Malondialdehyde, a byproduct of lipoperoxidation, has been shown to be elevated in HNC patients (25). Our study included salivary samplings to measure salivary levels of malondialdehyde.

In summary, our study challenges existing hypotheses regarding the cause of MT in HNC patients and suggests that inflammation, rather than nerve damage, may play a significant role. The dynamic changes in taste perception, along with the interplay between different types of taste receptors and regions of the tongue, warrant further investigation. Understanding these mechanisms can lead to more effective interventions for managing dysgeusia in these patients. Furthermore, the complex interplay between taste perception and the altered microenvironment of the oral cavity in HNC patients, including changes in salivary composition and flow, remains a hypothesis that requires testing.

CONCLUSION

The hypothesis of removal of facial nerve inhibition on the glossopharyngeal nerve cannot explain metallic taste in HNC. MT was significantly linked with mucositis, suggesting a possible role of inflammation, potentially lipoperoxidation.

Figures

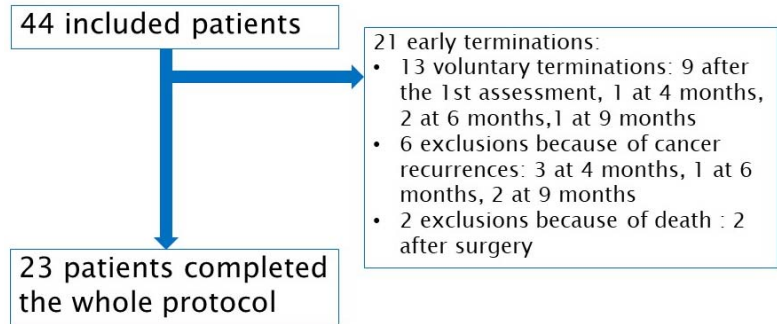


Figure 1 : study flowchart

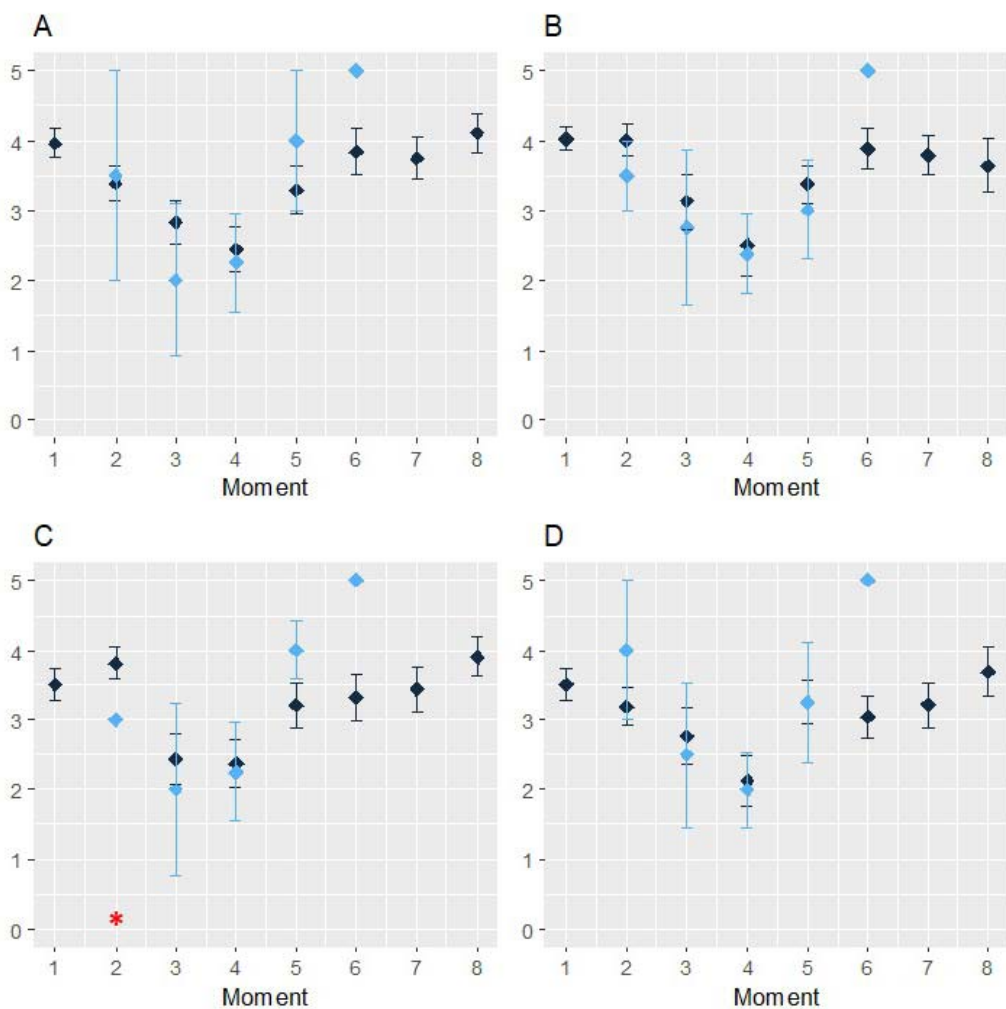


Figure 2: evolution of results for bitter taste according to the precise location on the tongue
 Blue = metallic taste, black = no metallic taste. A = right tongue base, B = left tongue base, C = left tip of the tongue, D = right tip of the tongue
 Red *: signficancy of t-test<0.05
 Moments: (m) moment 1); after surgery if any (m2); in the middle (m3) and at the end (m4) of the radiotherapy if any; at 3 (m5)-6 (m6)-9 (m7) and 12 (m8) months.

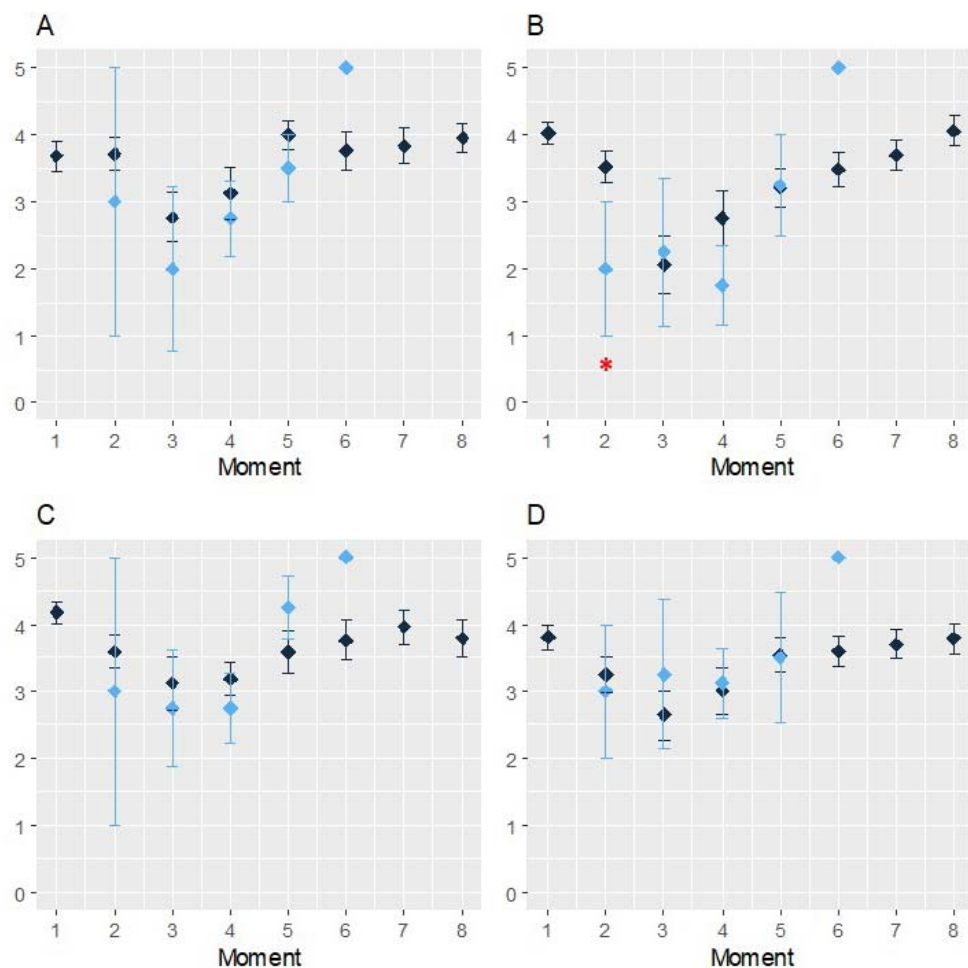


Figure 3: evolution of taste results for salty taste according to the precise location on the tongue
Blue = metallic taste, black = no metallic taste. A = right tongue base, B = left tongue base, C = left tip of the tongue, D = right tip of the tongue
Red *: signficancy of t-test<0.05
Moments: (m) moment 1); after surgery if any (m2); in the middle (m3) and at the end (m4) of the radiotherapy if any; at 3 (m5)-6 (m6)-9 (m7) and 12 (m8) months.

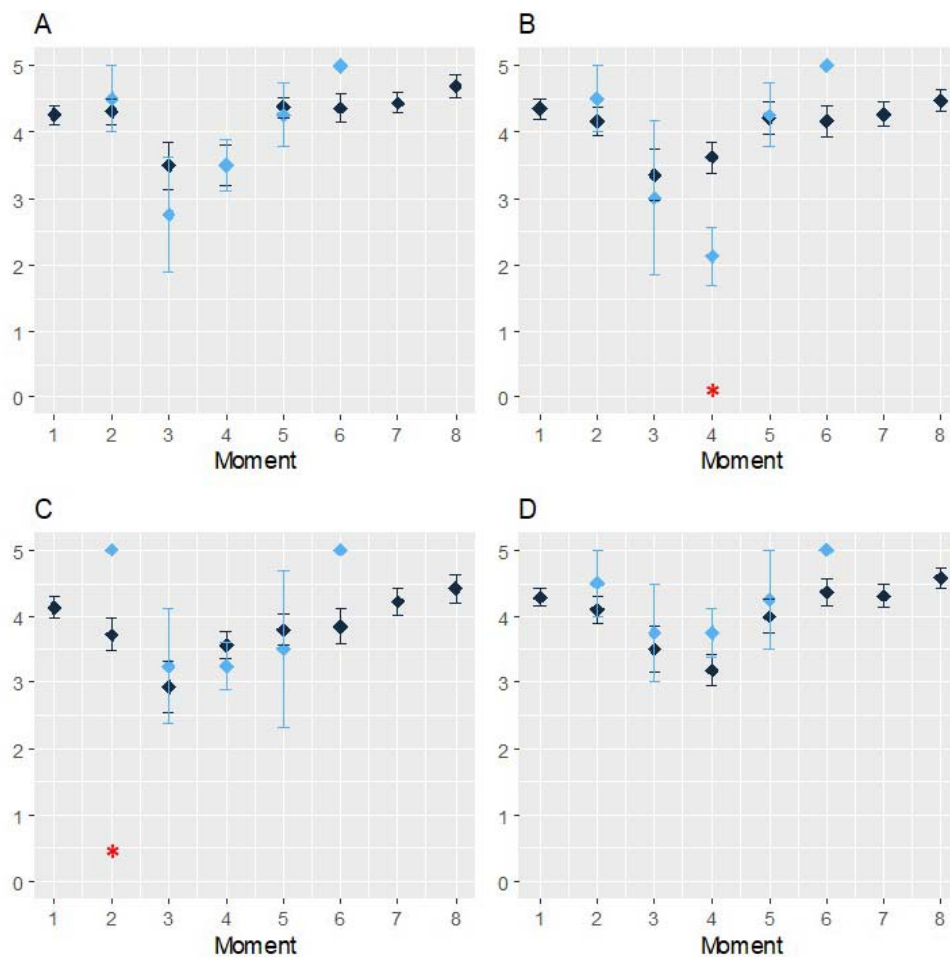


Figure 4: evolution of taste results for sour according to the precise location on the tongue
Blue = metallic taste, black = no metallic taste. A = right tongue base, B = left tongue base, C = left tip of the tongue, D = right tip of the tongue
Red *: significance of t-test < 0.05
Moments: (m) moment 1); after surgery if any (m2); in the middle (m3) and at the end (m4) of the radiotherapy if any; at 3 (m5)-6 (m6)-9 (m7) and 12 (m8) months.

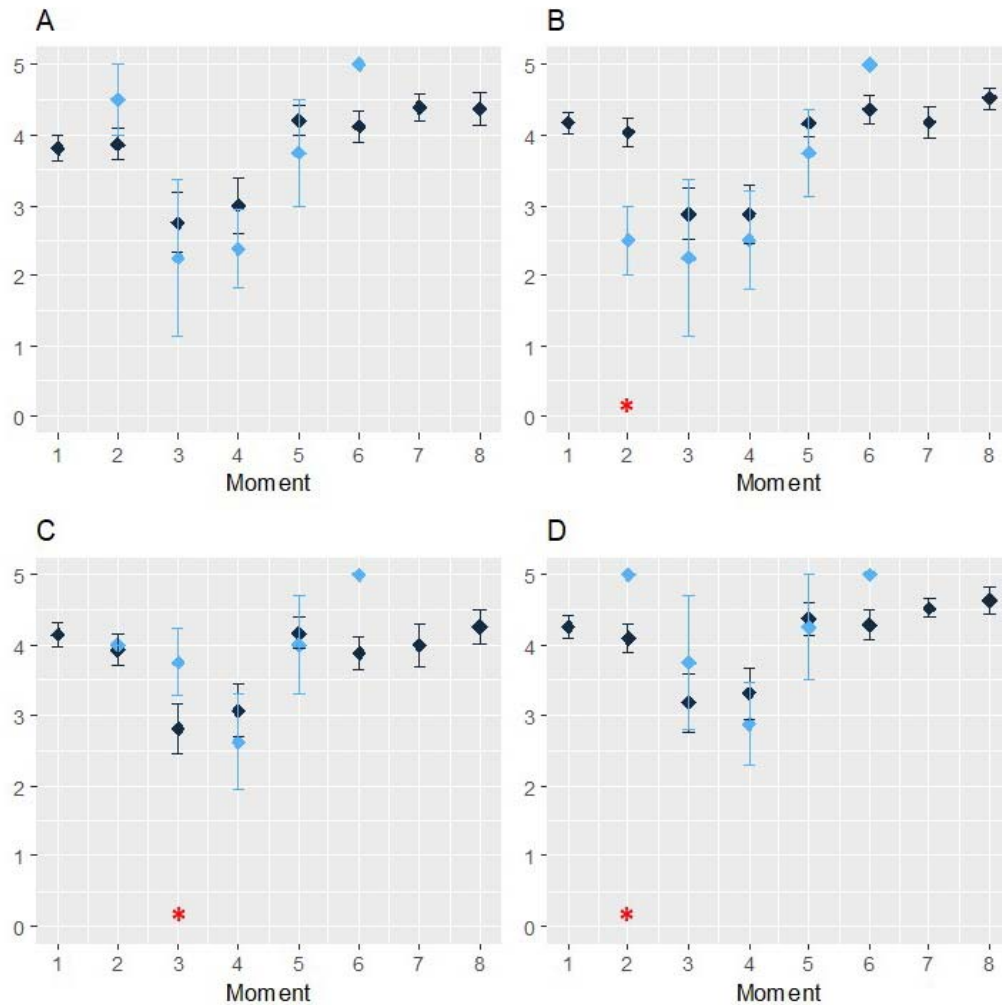


Figure 5: evolution of taste results for sweet according to the precise location on the tongue
Blue = metallic taste, black = no metallic taste. A = right tongue base, B = left tongue base, C = left tip of the tongue, D = right tip of the tongue
Red *: signficancy of t-test<0.05
Moments: (m) moment 1); after surgery if any (m2); in the middle (m3) and at the end (m4) of the radiotherapy if any; at 3 (m5)-6 (m6)-9 (m7) and 12 (m8) months.

REFERENCES

1. Wild CP, Weiderpass E, Stewart EW. World Cancer Report: Cancer Research for Cancer Prevention. Lyon, France: International Agency for Research on Cancer; 2020.
2. Birkhaug EJ, Aarstad HJ, Aarstad AK, Olofsson J. Relation between mood, social support and the quality of life in patients with laryngectomies. *Eur Arch Otorhinolaryngol.* 2002;259(4):197-204.
3. de Graeff A, de Leeuw JR, Ros WJ, Hordijk GJ, Blijham GH, Winnubst JA. Long-term quality of life of patients with head and neck cancer. *Laryngoscope.* 2000;110(1):98-106.
4. Wan Leung S, Lee TF, Chien CY, Chao PJ, Tsai WL, Fang FM. Health-related quality of life in 640 head and neck cancer survivors after radiotherapy using EORTC QLQ-C30 and QLQ-H&N35 questionnaires. *BMC Cancer.* 2011;11:128.
5. Tribius S, Raguse M, Voigt C, Munscher A, Grobe A, Petersen C, et al. Residual deficits in quality of life one year after intensity-modulated radiotherapy for patients with locally advanced head and neck cancer: Results of a prospective study. *Strahlenther Onkol.* 2015;191(6):501-10.
6. Ravasco P. Aspects of taste and compliance in patients with cancer. *Eur J Oncol Nurs.* 2005;9 Suppl 2:S84-91.
7. Sanchez-Lara K, Sosa-Sanchez R, Green-Renner D, Rodriguez C, Laviano A, Motola-Kuba D, et al. Influence of taste disorders on dietary behaviors in cancer patients under chemotherapy. *Nutr J.* 2010;9:15.
8. I I, Renken RJ, Ter Horst GJ, Reyners AK. Metallic taste in cancer patients treated with chemotherapy. *Cancer Treat Rev.* 2015;41(2):179-86.
9. Buiret G, Thomas-Danguin T, Feron G. Metallic taste prevalence in patients treated for cancer: a systematic literature review and meta-analysis. *Supportive care in cancer : official journal of the Multinational Association of Supportive Care in Cancer.* 2022;30(7):5691-702.
10. Logan HL, Bartoshuk LM, Fillingim RB, Tomar SL, Mendenhall WM. Metallic taste phantom predicts oral pain among 5-year survivors of head and neck cancer. *Pain.* 2008;140(2):323-31.
11. Reith AJM, Spence C. The Mystery of "Metal Mouth" in Chemotherapy. *Chemical senses.* 2020;45(2):73-84.
12. Bartoshuk LM, Catalanotto F, Hoffman H, Logan H, Snyder DJ. Taste damage (otitis media, tonsillectomy and head and neck cancer), oral sensations and BMI. *Physiology & behavior.* 2012;107(4):516-26.
13. Kveton JF, Bartoshuk LM. The effect of unilateral chorda tympani damage on taste. *Laryngoscope.* 1994;104(1 Pt 1):25-9.
14. Lehman CD, Bartoshuk LM, Catalanotto FC, Kveton JF, Lowlicht RA. Effect of anesthesia of the chorda tympani nerve on taste perception in humans. *Physiology & behavior.* 1995;57(5):943-51.
15. Sone M, Sakagami M, Tsuji K, Mishiro Y. Younger patients have a higher rate of recovery of taste function after middle ear surgery. *Arch Otolaryngol Head Neck Surg.* 2001;127(8):967-9.
16. Yanagisawa K, Bartoshuk LM, Catalanotto FA, Karrer TA, Kveton JF. Anesthesia of the chorda tympani nerve and taste phantoms. *Physiology & behavior.* 1998;63(3):329-35.
17. Neyman J, Pearson ES. On the problems of the most efficient tests of statistical hypotheses. *Philosophical Transactions of the Royal Society of London.* 1933;231A:289-338.

18. Deshpande TS, Blanchard P, Wang L, Foote RL, Zhang X, Frank SJ. Radiation-Related Alterations of Taste Function in Patients With Head and Neck Cancer: a Systematic Review. *Curr Treat Options Oncol*. 2018;19(12):72.
19. Hirai R, Takao K, Onoda K, Kokubun S, Ikeda M. Patients with phantogeusia show increased expression of T2R taste receptor genes in their tongues. *Ann Otol Rhinol Laryngol*. 2012;121(2):113-8.
20. McLaughlin L. Taste dysfunction and eating behaviors in survivors of head and neck cancer treatment. *Medsurg nursing : official journal of the Academy of Medical-Surgical Nurses*. 2014;23(3):165-70, 84.
21. Asif M, Moore A, Yarom N, Popovtzer A. The effect of radiotherapy on taste sensation in head and neck cancer patients - a prospective study. *Radiat Oncol*. 2020;15(1):144.
22. Maes A, Huygh I, Weltens C, Vandeveldel G, Delaere P, Evers G, et al. De Gustibus: time scale of loss and recovery of tastes caused by radiotherapy. *Radiother Oncol*. 2002;63(2):195-201.
23. Mossman KL, Henkin RI. Radiation-induced changes in taste acuity in cancer patients. *Int J Radiat Oncol Biol Phys*. 1978;4(7-8):663-70.
24. Sapir E, Tao Y, Feng F, Samuels S, El Naqa I, Murdoch-Kinch CA, et al. Predictors of Dysgeusia in Patients With Oropharyngeal Cancer Treated With Chemotherapy and Intensity Modulated Radiation Therapy. *Int J Radiat Oncol Biol Phys*. 2016;96(2):354-61.
25. Kaur R, Singh Z, Karthigesu IP, Singh P. Use of Malondialdehyde as a Biomarker for Assessing Oxidative Stress in Different Disease Pathologies: a Review. *Iran J Publ Health*. 2015;43:7-16.

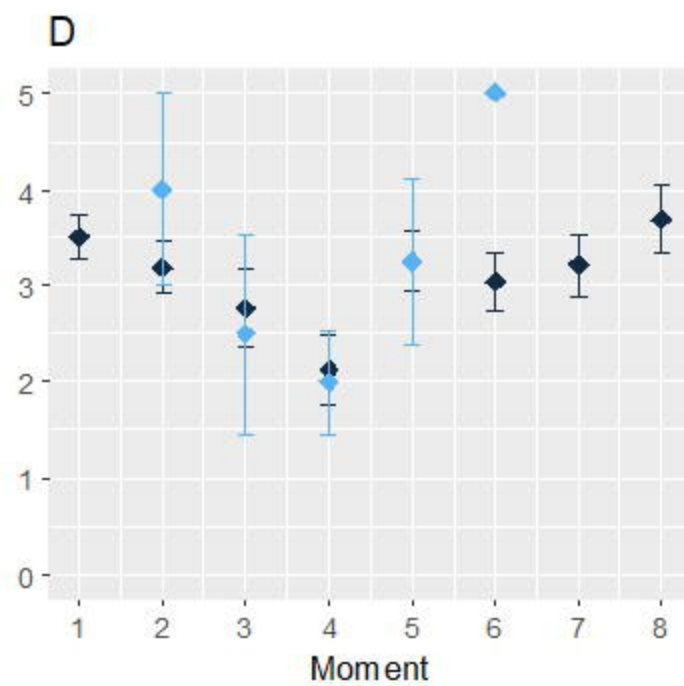
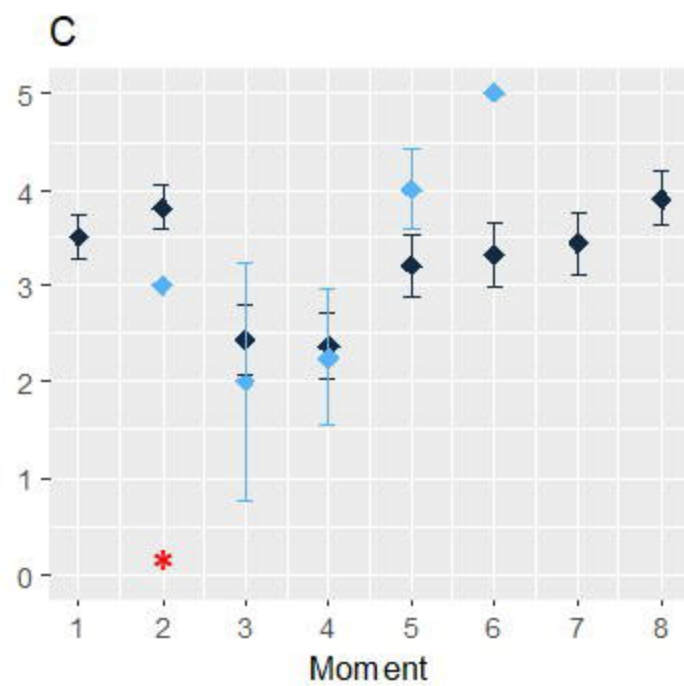
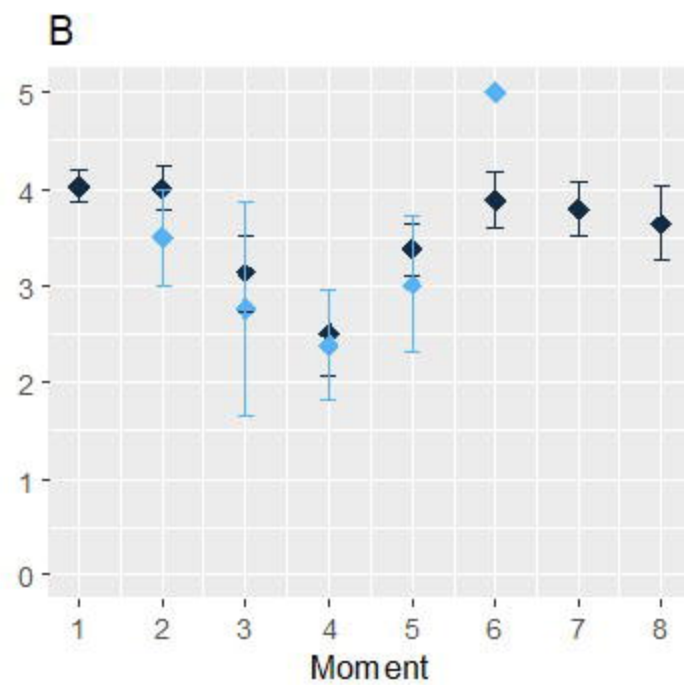
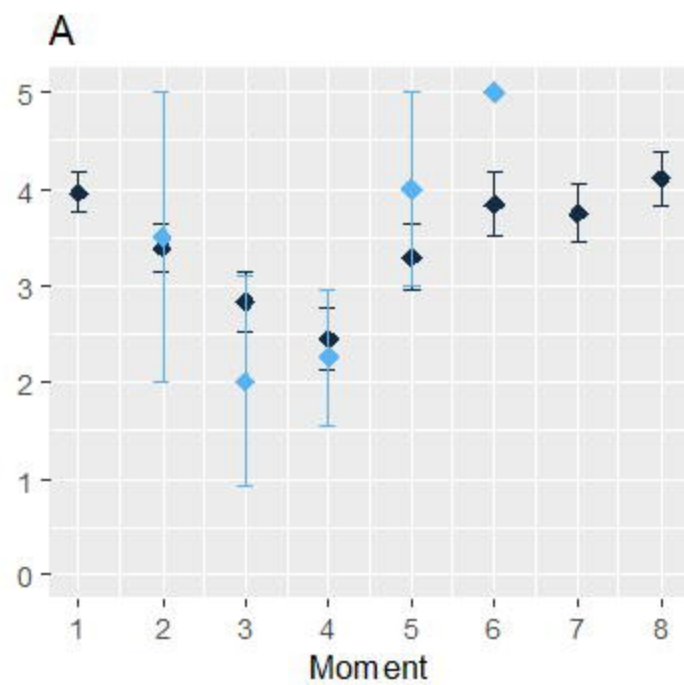
44 included patients

23 patients completed
the whole protocol

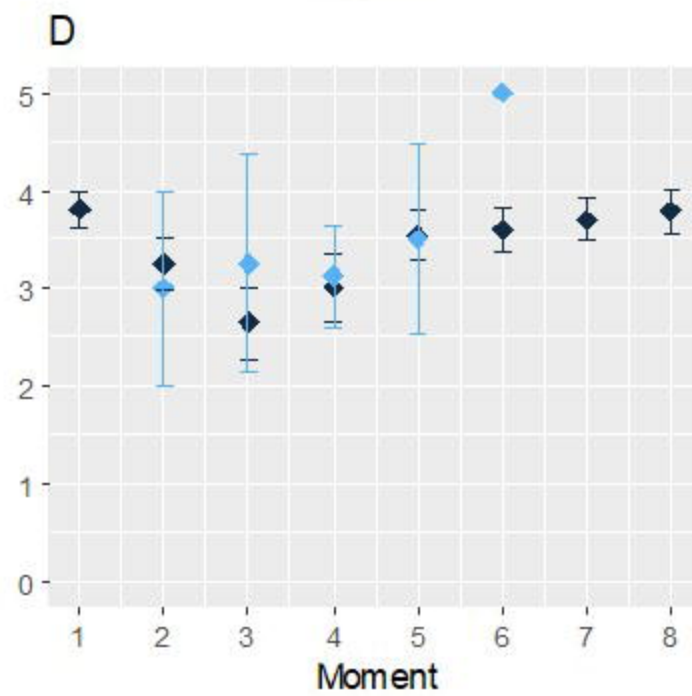
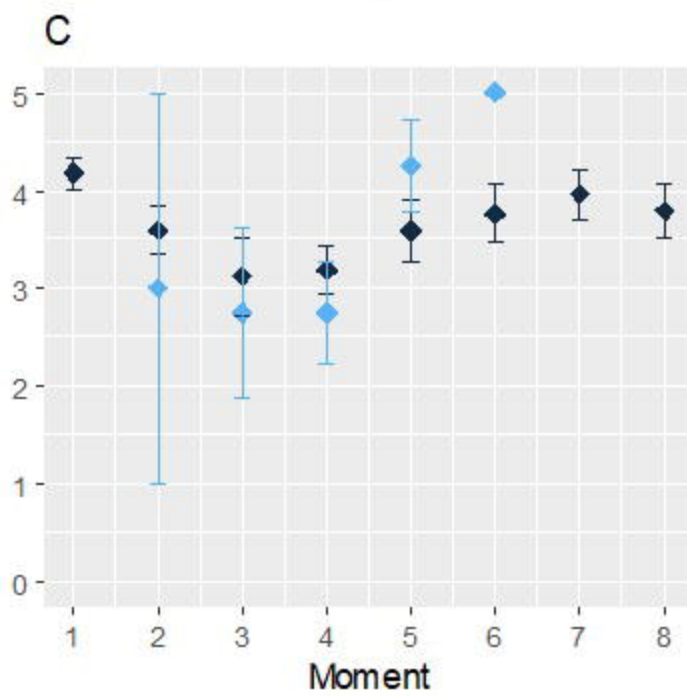
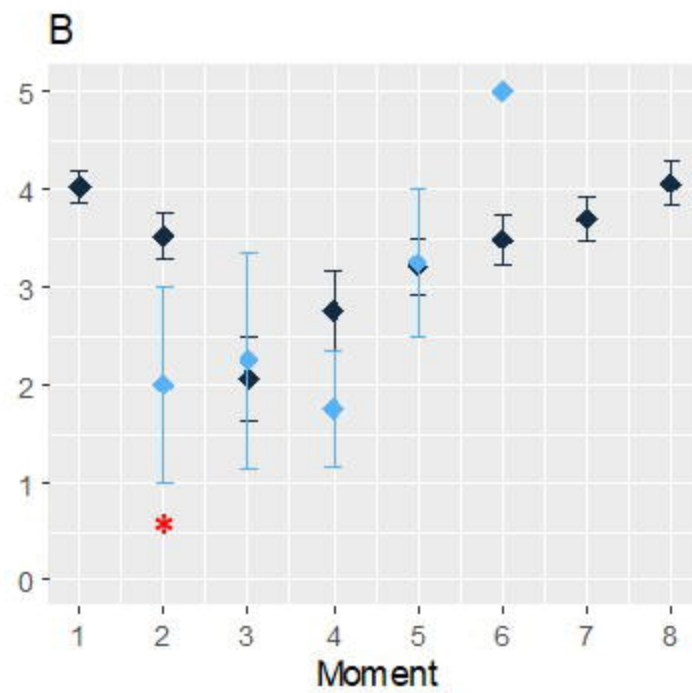
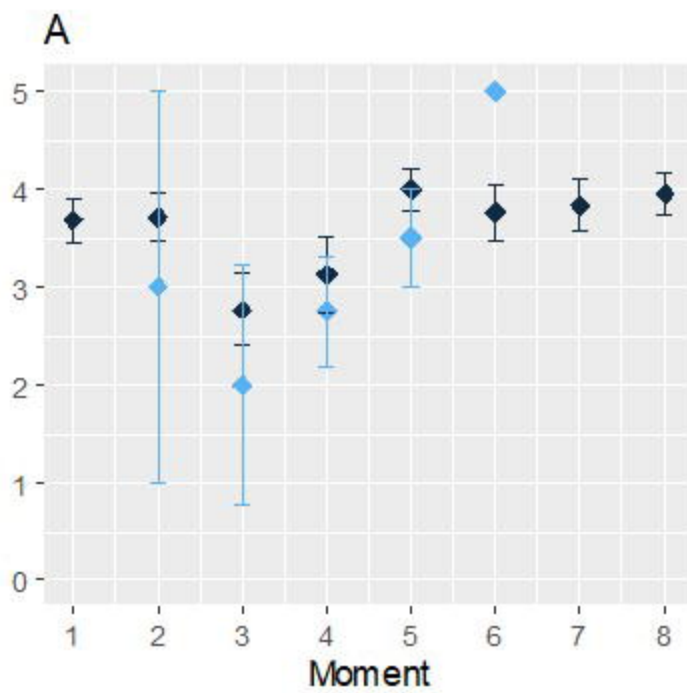
21 early terminations:

- 13 voluntary terminations: 9 after the 1st assessment, 1 at 4 months, 2 at 6 months, 1 at 9 months
- 6 exclusions because of cancer recurrences: 3 at 4 months, 1 at 6 months, 2 at 9 months
- 2 exclusions because of death : 2 after surgery

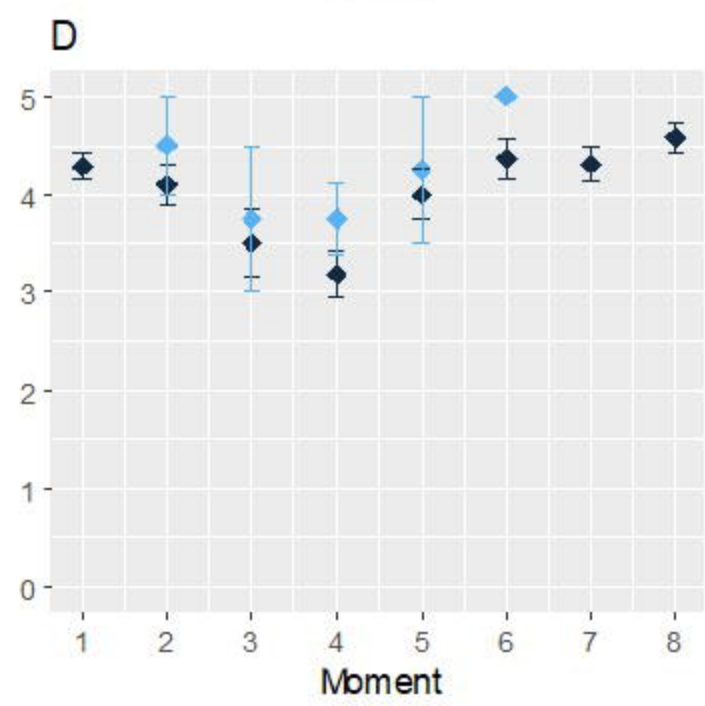
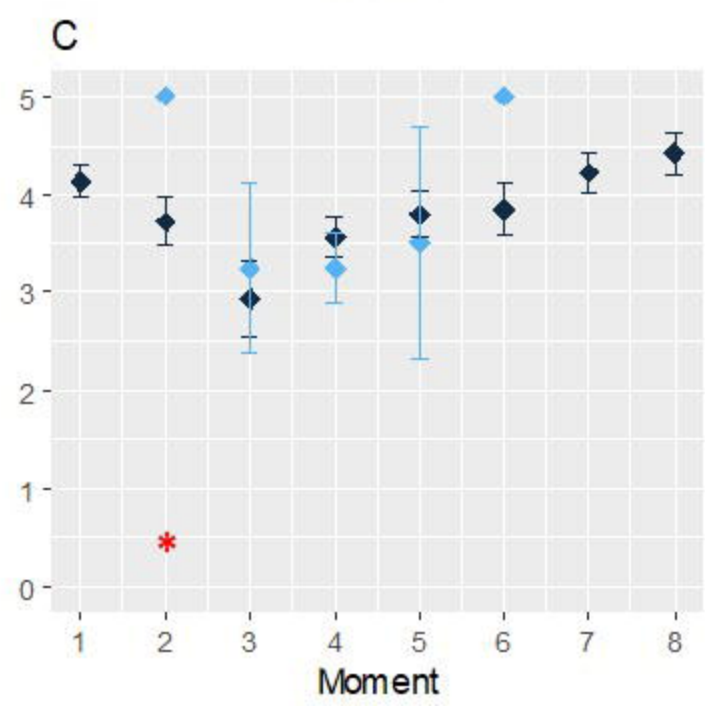
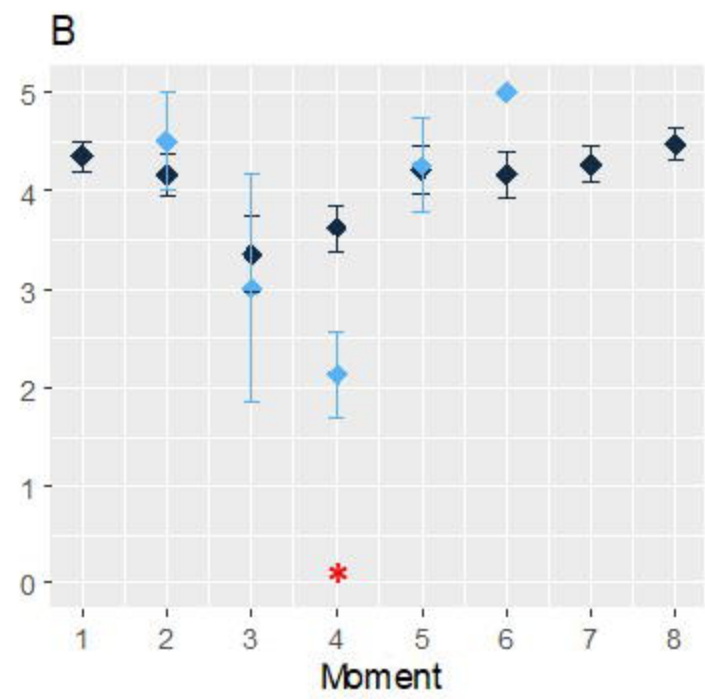
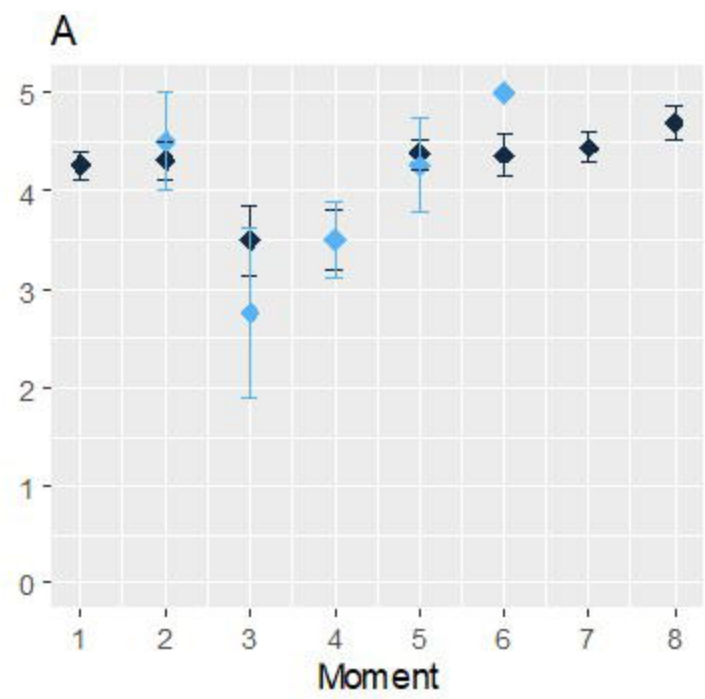
Bitter



Salty



Sour



Sweet

