

Alpha thalassemia/mental retardation X-linked (ATRX) protein expression in human pituitary neuroendocrine tumours and its reported correlation to prognosis and clinical outcomes: A systematic review.

Edward Wang^{1*}, Fabio Rotondo², Michael D. Cusimano^{1,3}

¹Department of Surgery, Division of Neurosurgery, St. Michael's Hospital; Injury Prevention Research Office, Li Ka Shing Knowledge Institute, Keenan Research Centre; University of Toronto; Toronto, Canada

²Department of Laboratory Medicine, Division of Pathology, Unity Health Toronto- St. Michael's Hospital, Toronto, ON, Canada

³Dalla Lana School of Public Health, University of Toronto, Toronto, Canada

*Corresponding author

Email: ewang242@uwo.ca (EW)

Abstract

Mutations in Alpha thalassemia/mental retardation X-linked (ATRX) have been implicated in several cancers, including gliomas, sarcomas, neuroendocrine tumors, and other mesenchymal malignancies. ATRX loss contributes to oncogenesis, accelerates tumor growth, and reduces survival by disrupting epigenetic and telomere mechanisms. Additionally, ATRX loss can increase tumor sensitivity to treatment therapies. While research has explored ATRX expression in many cancers, data on its relationship to prognosis in pituitary neuroendocrine tumors (PitNETs) remain inconsistent. This systematic review aims to summarize all available studies on ATRX mutations and expression in PitNETs. A systematic search of PubMed, Scopus, and EMBASE databases was conducted to identify publications between 2014 and 2024 that investigated ATRX mutations or expression in PitNETs, following PRISMA 2020 guidelines. Of 30 identified studies, nine met the inclusion criteria, covering a total of 500 PitNETs. Only 19 tumors (3.6%) showed a loss of ATRX expression. Among these, 58% exhibited corticotropic pathology, while 26% displayed lactotrophic pathology. A small subset of tumors (32%) was classified as pituitary carcinomas with aggressive and proliferative characteristics. Additionally, 16% demonstrated the alternative lengthening of telomeres (ALT) phenotype, 53% had concurrent TP53 mutations, and 21% had elevated Ki67 indices, indicating a higher proliferative index. Although ATRX mutations are rare in PitNETs, tumors with ATRX loss tend to be more aggressive and exhibit proliferative and transformative properties. Due to the limited number of cases, further studies with larger, prospective cohorts are needed to better understand the role of ATRX loss in PitNET progression and aggressiveness.

Introduction

Alpha thalassemia/mental retardation X-linked (ATRX) is an ATP-dependent chromatin remodelling protein within the switch/sucrose nonfermentable (SWI/SNF) family of chromatin remodelling proteins. The ATRX/DAXX complex, which includes death domain-associated protein (DAXX), modulates the deposition of histone H3.3 at guanine-rich heterochromatin regions with highly repetitive elements, including telomeres and pericentromeric regions. [1,2]. ATRX preferentially binds to the heterochromatin modification H3K9me3, facilitating histone H3.3 deposition and maintaining heterochromatin integrity [3,4]. When ATRX function is disrupted, its silencing action is impaired, leading to aberrant transcription across ATRX/DAXX-regulated regions, including genomic repeats [3]. ATRX mutations have also been linked to the progression of the alternative lengthening of telomeres (ALT) phenotype, a telomerase-independent mechanism for cancer cell immortality [5].

Somatic mutations disrupting ATRX function are associated with reduced disease-free survival, genome instability, and increased tumour mutation burden in gliomas, neuroendocrine neoplasms, and mesenchymal tumours [6–8]. Recent investigations have observed poorer prognoses in ATRX-mutated pancreatic neuroendocrine tumours (PanNETs), including shorter disease-free and survival time [6]. Loss of ATRX expression is also linked to increased sensitivity to radiation therapy, chemotherapy, and immunotherapeutic treatments [9]. The fifth edition of the WHO Classification of Tumours of the Central Nervous System (2021) recommends including ATRX status in diagnostic analyses for glioma variants and strongly supports it as a diagnostic marker for PanNET severity and prognoses [6,9].

Pituitary neuroendocrine tumours (PitNETs), traditionally known as pituitary adenomas, are common primary intracranial tumours of the adenohypophysis [10]. Like other neuroendocrine tumours, PitNETs are classified based on hormonal secretion. Overproduction and secretion of any adenohypophyseal hormones can cause debilitating effects associated with conditions such as acromegaly and Cushing's disease. Although most clinically apparent PitNETs are benign, some exhibit aggressive and invasive growth, leading to mass-effect symptoms from compression of adjacent intracranial structures [11,12]. Metastases are rare and can occur in tumours that appear benign histologically while other tumours that have histological features of aggressiveness can remain isolated to the sellar region. Aggressive and metastatic PitNETs are also resistant to traditional surgical and radiological treatments, with only temozolomide (TMZ) treatment showing moderately effective and often transient pharmacological results in less than half of patients [13,14]. As the use of ATRX as a prognostic marker for other neuroendocrine tumours increases, it is essential to also evaluate whether ATRX can predict the aggressiveness of PitNETs.

Currently, published data on the incidence of ATRX expression and its clinical significance in neuroendocrine tumours, particularly PitNETs, is limited. The role of ATRX protein expression in the prognosis of PitNETs remains unknown. In this systematic review, we interpret the existing literature on ATRX expression in PitNETs to better describe its relationship with the clinicopathological characteristics and prognosis of PitNET patients.

Methods

Search strategy

This systematic review was conducted following the Preferred Reporting Items for Systematic Reviews and Meta-Analyses (PRISMA) guidelines. The aim was to identify all English published studies on pituitary tumours exhibiting a loss of ATRX expression. The strategy involved searching the PubMed, Embase, and Scopus databases to identify relevant studies published in English from January 1, 2014 to October 1, 2024, using MeSH terms combined with free search terms. A combination of the following keywords was used: ATRX, pituitary, alpha thalassemia X-linked, ATRX, PitNET. No other restrictions were imposed, and no attempt was made to obtain unpublished results. All references and supplementary data from all selected articles were also considered. The review was not registered, nor was a review protocol prepared. All data collected and analyzed has been reported in the manuscript.

Study selection

The selection of published material was conducted based on initial screening of titles or abstracts followed by screening of full-text reviews. Manuscripts were considered eligible if they met the following criteria: (i) the study was published in a peer-reviewed medical journal within the last ten years, (ii) the study was published in English, (iii) the study described human case studies involving pituitary tumours/PitNETs and ATRX, and (iv) the study observed a loss of ATRX expression or mutation in the ATRX gene (Fig 1). Studies were omitted from review based on the following exclusion criteria: (i) studies with publication types other than original research articles, such as review articles, editorials, letters, commentaries, and conference abstracts. Duplicate files were removed following export of database search results to Covidence. Risk of bias

assessments were evaluated using the Joanna Briggs Institute (JBI) Critical Appraisal Checklist for Studies Reporting Prevalence Data and the JBI Critical Appraisal Checklist for Case Reports [15]. Quality assessment was not performed, and therefore no papers were excluded due to poor quality.

Fig 1. Identification and selection of studies via databases.

Data extraction and quality assessment

Data was extracted from selected articles and included the following characteristics:

- Study: year of publication, journal of publication, country, type of study
- Sample Data: sample size, tumour type studied, mean age of participants at the time of tumour resection, sex, evaluation strategies,
- Study Results and Analysis: tumour classification, ALT status, Ki-67 index, identification of other mutations within tumour sample

The analyzed data, including methods and results of each full-length publication, were reviewed to satisfy the selection criteria and assess the quality of the text. No studies were excluded as a result of poor quality of methods or unsatisfactory results. Results were independently extracted by one author (EW) and assessed by another independent author (FR) to ensure accuracy and inclusion of complete data. Any discrepancies were resolved by discussion.

Synthesis of data

All relevant patient demographics and tumour data were collected and tabulated in Excel®. Tumours that were referred to as ACTH-secreting tumours, ACTH-omas, or exhibited T-PIT expression were tabulated as corticotrophs. Null cell pituitary tumours were recorded as nonfunctional pituitary adenomas. Similarly, gonadotrophs included tumours categorized by LH/FSH secretion or SF1 expression. One study recorded gonadotrophs as nonfunctional pituitary adenomas and did not specify the number of adenomas recorded [16]. Pit-1 lineage tumours were further categorized into GH-secreting somatotroph and PRL-secreting lactotrophs. Thyrotrophs included TSH-secreting adenomas and thyrotrophic adenomas. Any tumours that did not fall under these categories were tabulated under “Other Tumour Type,” including all plurihormonal tumours, pituitary carcinomas, and pituitary rhabdomyosarcoma. Tumours exhibiting ATRX within the included categories were indicated within square brackets. Analytical techniques and evaluation strategies were indicated in Table 1 while data that was unspecified or not measured was recorded in Table 2. The statistical analysis included Fisher’s exact test for associations between tumour recurrence, and other tumour characteristics and ATRX loss. No other statistical or sensitivity analyses were conducted.

Table 1. Characteristics of included publications examining the prevalence of ATRX loss in human pituitary neuroendocrine tumours.

Author	Year	Journal	Country	Type of study	Sample size	Tumour Type	Evaluation Strategy	Loss of ATRX observed (# if not specified)
Casar-Borota (Trouillas)	2017	The American Journal of Surgical Pathology	Denmark	Case report & descriptive cross-sectional study	248	152 clinically nonfunctioning pituitary adenomas, 2 pituitary carcinomas	Immunohistochemical analysis; NextGen Sequencing	Yes corticotroph pituitary carcinomas

								cortico tum
Lamback (Gadelha)	2024	Journal of Endocrinology and Metabolism Case Reports	Brazil	Case report	1	Pituitary adenoma	Immunohistochemical analysis	Yes, 1 n pitu aden

** One patient was omitted from the sample, as it was repeated from Casar-Borota et al. (2017)

Table 2. Demographic and clinical patient data examined in the included publications.

Author (Date)	Average Age	Sex	Recurrent Tumour	Non- recurrent Tumour	Clinically Non- functional	Corticotroph	Somatotroph
Casar- Borota (2017)	Unspecified [39]	Unspecified [F]	Unspecified	Unspecified	152	22	60
Guo (2018)	[55]	[M]	[1]	0	0	0	0
Chen (2019)	17.64 [unspecified]	27 F, 15 M [2 F, 1 M]	5	37 [3]	9	9	6
Sbiera (2019)	53.7 [52.5]	10 F, 8 M [2 F]	Unspecified	Unspecified	0	18	0

Heaphy (2020)	53.4 [unspecified]	41 M, 65 F [unspecified]	18 [unspecified]	88 [unspecified]	83	1	15
Casar-Borota (2021)*	45 [45]	14 F, 33 M [2F, 6M]	47 [8]	0	1	10 [3]	2
Lu (2021)	[77]	[M]	[1]	0	0	0	0
Alzoubi (2022)	Adult: 52.9 Pediatric: 13 [Adult: 60]	Adult: 12 F, 12 M Pediatric: 9 F, 3 M [1 M]	24 adults [1 adult]	12 pediatric	0	6 adults + 2 pediatric [1 adult]	1 adult
Lamback (2024)	63	[M]	[1]	0	[1]	0	0

147 Values in square brackets indicate samples with ATRX loss reported. ALT-positive = alternative-
148 lengthening of telomeres was present in the tumour sample

149 * One pituitary carcinoma was excluded as the patient was shared with Casar-Borota (2017)

150 ** Information regarding tumour type and status were incomplete and could not be determined

*** 4 pituitary carcinomas exhibited ATRX loss (2 corticotrophs, 1 silent corticotroph, 1 somato-lactotroph)

Potential for bias and risk of bias assessment

Preliminary screening was accomplished by one of the authors (EW) and then reassessed by a second author (FR) according to the defined criteria to ensure that the same data items were collected. The information was extracted from the full text independently by each author. These efforts were directed toward conducting the analysis with minimal bias. The study quality and presence of biases were determined using the Joanna Briggs Institute (JBI) Critical Appraisal Checklist for Studies Reporting Prevalence Data (see Table 3) and the JBI Critical Appraisal Checklist For Case Reports (see Table 4) [15].

Table 3: Quality assessment using the Joanna Briggs Institute (JBI) Critical Appraisal Checklist for Prevalence Studies

	Casar-Borota (2017)	Chen (2019)	Sbiera (2019)	Heaphy (2020)	Casar-Borota (2021)	Alzoubi (2022)
Was the sample frame appropriate to address the target population?	Yes	Yes	Yes	Yes	Yes	Yes
Were study participants sampled in an appropriate way?	No	Yes	No	No	Yes	Yes
Was the sample size adequate?	Unclear	Unclear	Unclear	Unclear	Unclear	Unclear
Were the study subjects and the setting described in detail?	No	Yes	Yes	No	Yes	Yes

Was the data analysis conducted with sufficient coverage of the identified sample?	Unclear	Yes	Yes	No	Yes	Yes
Were valid methods used for the identification of the condition?	Yes	Yes	Yes	Yes	Yes	Yes
Was the condition measured in a standard, reliable way?	Yes	Yes	Yes	Yes	Yes	Yes
Was there appropriate statistical analysis	No	Yes	Yes	Yes	No	Yes
Was the response rate adequate, and if not, was the low response rate managed appropriately?	N/A	N/A	N/A	N/A	N/A	N/A
Final Scores	3/8	7/8	6/8	4/8	6/8	7/8

N/A = Not applicable; the checklist item was not applicable to the study design

Studies with final scores ≥ 6 are reported as “great” quality. Studies with final scores ≤ 4 are reported as “poor” quality. Studies with final scores = 5 are reported as “moderate” quality.

Table 4: The Joanna Briggs Institute (JBI) Critical Appraisal Checklist for Risk of Bias for Case Reports that were identified

	Casar-Borota (2017)	Guo (2018)	Lu (2021)	Lamback (2024)
Were patient’s demographic characteristics clearly described?	Yes	Yes	Yes	Yes
Was the patient’s history clearly described and presented as a timeline?	Yes	Yes	Yes	Yes
Was the current clinical condition of the patient on presentation clearly described?	Yes	Yes	Yes	Yes

Were diagnostic tests or assessment methods and the results clearly described?	Yes	Yes	Yes	Yes
Was the intervention(s) or treatment procedure(s) clearly described?	Yes	Yes	Yes	Yes
Was the post-intervention clinical condition clearly described?	Yes	Yes	No	Yes
Were adverse events (harms) or unanticipated events identified and described?	Unclear	Yes	Unclear	Yes
Does the case report provide takeaway lessons?	Yes	Yes	Yes	Yes
Final Score	7/8	8/8	6/8	8/8

Studies with final scores ≥ 6 are reported as “great” quality. Studies with final scores ≤ 4 are reported as “poor” quality. Studies with final scores = 5 are reported as “moderate” quality.

Results

Description of studies

A total of 46 studies were identified from database search after duplicates were removed. Following screening of titles and abstracts, 16 irrelevant studies were excluded. All 30 of the remaining studies were retrieved and assessed for inclusion. Of these, 21 publications failed to meet our inclusion criteria and were subsequently excluded. Fourteen studies were excluded due to wrong patient population, of which eleven studies did not examine samples including PitNETs for ATRX expression and mutations, while three studies were excluded due to ATRX mutations occurring outside of the pituitary tumour. Additionally, seven studies were excluded due

incorrect study design, as the studies lacked inclusion of novel cases. Consequently, a total of nine publications were included based on the predetermined criteria [16–24].

Quality assessments were conducted for the nine studies deemed eligible for inclusion in our review study. Given that the selected descriptive cross-sectional studies were retrospective, analyzing tissue samples and existing medical records, subject response rate was not applicable and thus excluded from the risk of bias assessment. Accordingly, both case reports and descriptive studies were evaluated using an 8-point scale across various checklist parameters [15]. Of the nine human studies that analyzed the prevalence of ATRX loss in PitNETs, three studies presented case reports of a novel case that exhibited ATRX loss, while five were descriptive cross-sectional studies. One study presented both a novel case report and a descriptive cross-sectional study and was evaluated under both quality assessments [16]. Of the six descriptive studies included in the review, 4/6 (67%) studies received “great” scores (≥ 6), while 2/6 (33%) studies were categorized as “poor” quality (< 4) [16,20]. All four case reports received “great” scores (see Tables 1 and 2).

Table 3 summarizes the characteristics of the studies examined, including demographic data, sample size, and evaluation strategies. All studies examined were published since 2017. A study was published in each of Canada, China, Denmark, Germany, Italy, Sweden, and Brazil, and three studies published in the USA. Eight studies conducted immunohistochemical analysis to determine ATRX protein presence, while four studies conducted NextGen sequencing to determine the presence and location of ATRX gene mutations. One study did not conduct either immunohistochemical analysis or NextGen sequencing. Instead, the study examined selected tumours using whole-exome sequencing and Sanger sequencing [19].

As 7/9 (78%) of the studies were conducted on data collected prior to the change in pituitary tumour classification, the tumours were referred to as pituitary adenomas. Four studies examined adult pituitary tumour patients [17,19,22,24], while one study examined pediatric pituitary adenoma patients [18]. Three studies included both adult and pediatric pituitary adenoma patients [20,21,23]. One study did not disclose the age range of the patients included in their study [16]. In total, 20 pituitary carcinoma patients were also included from three studies in addition to their pituitary adenoma patients [16,17,21]. Additionally, one study presented a novel case study regarding a pituitary rhabdomyosarcoma arising from a pituitary adenoma that was identified to have a mutation in ATRX [22].

Patient data from the studies were summarized in Table 4, including basic patient information and tumour types. A total of 500 tumours were examined across the nine studies included. 246 tumours were clinically non-functional adenomas, 84 somatotroph adenomas, 68 corticotroph adenomas, 50 lactotroph adenomas, 13 gonadotroph adenomas, 2 thyrotroph adenomas, and 6 pituitary adenomas present with Pit-1. Several plurihormonal tumours were also included and were described in Table 4. The studies also reported 20 pituitary carcinomas, including 14 classified as corticotroph, 3 as lactotroph, 2 as somatotroph, and 1 as plurihormonal. It was noted that in 3 of the studies reviewed, data involving age (average), sex, and tumour recurrence was incomplete [16,19,20]. Of the reported ages, the weighted average age of patients was 44. Among the publications that included sex distribution data, there were 138 female patients and 115 male patients. Additionally, 97 tumors were identified as recurrent, while 138 were classified as non-recurrent.

Histopathological data regarding all tumours exhibiting ATRX loss included in this review were summarized in Table 5. Only 19/500 (3.8%) tumours exhibited ATRX loss, of which 11/19 (58%) tumours were classified as corticotrophs while 4/19 (21%) lactotrophs. One study reported a loss of ATRX protein expression in one tumour and partial loss in four other tumours, but did not describe the patient or tumour type of the tumours that exhibited loss of ATRX protein expression [20]. Furthermore, the researchers sequenced only the tumour sample that exhibited full loss of ATRX expression and did not reveal any ATRX genetic abnormalities. They also did not evaluate further the four cases that showed partial loss, and no information was provided regarding the extent of the loss, so they were not classified as ATRX-negative tumors. 16/19 (84%) of the tumours lacking ATRX expression were collected from adult patients, with the remaining three reported as pediatric cases [18].

Table 5. Demographic and histopathological characteristics of tumours exhibiting ATRX.

	Source	Tumour Classification	Age	Sex	Evaluation	Recurrence Status	ALT Status	Ki67	Mutations Identified
Tumour 1	Casar-Borota (2017)	Corticotroph pituitary carcinoma	39	F	IHC, NGS	NA	NA	NA	c.134_5217del; p.D45-K
Tumour 2	Guo (2018)	Corticotroph pituitary carcinoma	55	M	IHC, NGS	+	NA	80%	unspecified ATRX mutation
Tumour 3**	Chen (2019)	Lactotroph	NA	F	IHC	-	NA	<3%	NA
Tumour 4**	Chen (2019)	Lactotroph	NA	F	IHC	-	NA	<3%	NA
Tumour 5**	Chen (2019)	Lactotroph	NA	M	IHC	-	NA	>3%	NA
Tumour 6	Sbiera (2019)	Corticotroph	56	F	WES	NA	NA	1-2%	c.622G>C; p.Asp208His
Tumour 7	Sbiera (2019)	Corticotroph	40	F	WES	NA	NA	5-6%	g.7577127C>A; p.Glu27

Tumour 8	Heaphy (2020)	NA	NA	NA	IHC, WES, FISH	NA	+	NA	no mutations in ATRX g
Tumour 9	Casar-Borota (2021)	Corticotroph pituitary carcinoma	45***	M	IHC, NGS	+	NA	NA	c.748C>T; p.Arg250Ter
Tumour 10	Casar-Borota (2021)	Corticotroph pituitary carcinoma	45***	M	IHC, NGS	+	NA	NA	c.6679delG; p.Asp2227 c.3583delA; p.Arg1195f
Tumour 11	Casar-Borota (2021)	Corticotroph pituitary carcinoma	45***	F	IHC, NGS	+	NA	NA	c.4048_4049delGG; p.G c.6661G>T; p.Glu2221T
Tumour 12	Casar-Borota (2021)	Somato-lactotroph carcinoma	45***	M	IHC, NGS	+	NA	NA	c.595_6669del, p.N199
Tumour 13	Casar-Borota (2021)	Corticotroph	45***	M	IHC, NGS	+	NA	NA	c.2422C>T, p.Arg808Te
Tumour 14	Casar-Borota (2021)	Corticotroph	45***	M	IHC, NGS	+	NA	NA	c.839_840insCATG, p.A
Tumour 15	Casar-Borota (2021)	Silent corticotroph	45***	M	IHC, NGS	+	NA	NA	c.5938T>A,c.5939delC, p.Ser1980fs
Tumour 16	Casar-Borota (2021)	Lactotroph APT	45***	F	IHC, NGS	+	NA	NA	c.21_6699del, p.E8-K22
Tumour 17	Lu (2021)	Pituitary rhabdomyosarcoma arising from pituitary adenoma	77	M	NGS	+	NA	NA	c.5406dup, p.R1803Tfs*
Tumour 18	Alzoubi (2022)	Corticotroph	60	M	IHC, FISH	+	+	1%	NA
Tumour 19	Lamback (2024)	Nonfunctional null-cell pituitary adenoma	63	M	IHC	+	NA	11%	NA

240 NA = Statistic was not reported or not made available, + = Status associated with column was

241 present, - = Status was evaluated but not present at the time of reporting, IHC =

242 immunohistochemical analysis, NGS = NextGen sequencing, FISH = fluorescent in-situ

243 hybridization, WES = whole exome sequencing

* Mutation was collected from Casar-Borota et al. (2021)

** The three lactotrophs in Chen (2019) reported to lack ATRX expression did not specify which of the three cases exhibited a Ki67 index > 3%.

*** Only average age was reported for the 8 tumours reported to lack ATRX expression. Range of ages was reported as 23-72

Two studies [20,22] reported the number of patients exhibiting the ALT phenotype, of which a total of 14 cases were identified and only 2/14 (14%) tumours exhibited ATRX loss. 5/9 studies reported the presence of other mutations within ATRX-negative tumours, of which *TP53* was the most frequently reported mutation (10/18). One study investigated the presence of 20 common glioma mutations, including IDH1, IDH2, and ATRX, within the analyzed pituitary tumours, of which 1/248 tumours exhibited a loss of ATRX due to a large deletion within the gene [16]. It was not specified, however, what the other 17 mutations the tumour was screened for or if any other mutations were observed. Ki-67 index was also reported by five studies [17–19,23,24] with different parameters, in which two studies reported proliferation indices greater than 3% as elevated [18,19], whereas another study reported indices greater than 2% as elevated [23]. One study reported an increase in their Ki-67 index by 80% from a prior examination but did not disclose what the absolute values were [17]. One study also reported indices greater than 10% as a marker of high proliferation but did not specify what they determined to be the threshold for an elevated index [24]. One study investigated aggressive pituitary adenomas and pituitary carcinomas, which were both characterized by increased proliferation [21].

Of the 20 pituitary carcinomas included in the review, 6/20 (30%) exhibited a loss of ATRX expression. 5/6 (83%) carcinomas with ATRX loss were corticotroph in nature while 1/6 (17%) presented as a somato-lactotroph. The remaining 14 pituitary carcinomas shared a similar distribution, with 9/14 (64%) of the carcinomas reported to be corticotroph in nature, 3/14 (21%) as lactotroph in nature, and 2/14 (14%) as somatotroph in nature. The average age of pituitary carcinoma patients was between 16 and 69, with an average age of 42.5. Unfortunately, average age of carcinomas exhibiting ATRX loss cannot be calculated due to incomplete reporting by one study [21]. All carcinomas exhibited aggressive and transformative properties concomitant with their diagnosis, including elevated proliferative growth, need for repeated surgical procedures, resistance to drug therapies, and development of metastases. None of the studies that included pituitary carcinomas examined the presence of the ALT phenotype. Only one study [17] measured Ki-67 and reported an increase by 80% from a previous examination but did not provide information regarding the absolute value itself.

In the analysis of the relationship between ATRX loss and tumour recurrence [Table 6A], tumour hormone secretion [Table 6B], and patient sex [Table 6C], one study was excluded due to incomplete data regarding tumour recurrence, tumour type, and sex of patients with ATRX loss [20]. Two other studies were excluded from tumour recurrence and sex analysis due to incomplete reporting on the two parameters [16,19]. We did not find any significant relationship between loss of ATRX expression and tumour recurrence status [Table 6A]. Sex was also not a significant factor in ATRX expression [Table 6C]. However, tumour type was associated with ATRX expression status. As described in Table 6B, the proportion of ACTH-secreting tumours (corticotroph adenomas and corticotrophic pituitary carcinomas) exhibiting loss of ATRX

expression was significantly different from the proportion of other tumours that exhibited ATRX loss ($p < 0.0005$). No other significant associations were observed.

Table 6. Fisher’s exact tests comparing ATRX expression status and tumour recurrence (A), tumour hormone secretion type (B), and sex of patient (C).

A		Status of ATRX Expression			
Tumour Recurrence**		ATRX Loss	ATRX Intact	Total	p-value
Recurrent		12	67	79	0.071
Non-recurrent		3	46	49	
Total		15	113	128	

B		Status of ATRX Expression			
Tumour Hormone Secretion***		ATRX Loss	ATRX Intact	Total	p-value
ACTH		11	72	83	1.49E-04*
Other		7	305	312	
Total		18	376	395	

C		Status of ATRX Expression			
Sex****		ATRX Loss	ATRX Intact	Total	p-value
Male		10	63	73	0.152
Female		7	66	73	
Total		17	129	146	

* Indicates significant p-value ($p < 0.05$)

** Casar-Borota et al. (2017), Sbiera et al. (2019), and Heaphy et al. (2020) were excluded due to incomplete data reporting regarding tumour recurrence status

*** Heaphy et al. (2020) was excluded due to incomplete data reporting regarding tumour type. The nonfunctional case presented by Lamback et al. (2024) was included under “Other”.

**** Casar-Borota et al. (2017) and Heaphy et al. (2020) were excluded due to incomplete data reporting regarding patient sex

Discussion

In the current study, we reviewed all available literature on ATRX expression in PitNETs. Our analysis revealed a loss of ATRX expression in approximately 3.8% of the 500 cases that were studied. Although ATRX is rarely mutated within PitNETs, patients with functioning PitNETs, especially corticotrophs, are over-represented ($p < 0.0005$).

We observed ATRX loss in 4 PitNETs exhibiting the ALT phenotype. However, not all ALT-positive tumours exhibited ATRX loss, suggesting that ATRX loss is not required for the ALT phenotype to progress within the PitNETs studied. While ATRX loss has been strongly associated with the ALT phenotype tumour types such as gliomas and pancreatic tumours, we cannot determine a relationship between ATRX function and the progression of the ALT phenotype in PitNETs from currently published data.

Given ATRX's critical role in sustaining methylation of repetitive DNA regions, a loss of ATRX expression may lead to errors in DNA replication and transcription during cell division. Coupled with an increased propensity for the development of the ALT phenotype, impaired ATRX function may promote the aberrant proliferative and transformative qualities observed in the analysis. Similar trends have also been identified in Pancreatic NETs, where the loss of ATRX/DAXX expression is associated with an increased propensity for proliferative development and poor survival [6]. All studies reviewed herein reported an increase in proliferative or transformative properties in tumours lacking ATRX expression. Four studies reported an elevated

incidence of ATRX loss in recurrent or aggressive PitNETs, both of which presented with elevated proliferative traits [20,21,23,24]. However, given the multitude of factors, including initial degree of tumour resection and tumour location, the data we collected and analyzed from the publications demonstrated a non-significant trend with ATRX loss and recurrence in PitNETs.

Loss of ATRX expression was also noted in 30% of the 20 pituitary carcinomas presented across the studies included in this review. Pituitary carcinomas exhibit significant proliferative and transformative properties. The elevated prevalence of ATRX mutations among pituitary carcinomas supports the proposed association between ATRX loss and increased propensity for aggressive and proliferative development of tumours. It was also identified that 83% of the ATRX-negative carcinomas were corticotroph in nature, similar to the trends identified in the data from other ATRX-negative pituitary tumours collected in the review. However, as corticotrophic carcinomas were overrepresented across the samples, making up 70% of all reported pituitary carcinomas, it is difficult to draw any conclusions from this observation. It is also important to note that in one excluded study, a pituitary carcinoma was found to exhibit ATRX mutations and expression loss in a liver metastasis but not in the original tumour, highlighting the potential for pituitary carcinomas to gain ATRX mutations [25].

It is worth noting that mutations in TP53, a well-established oncogene, were identified in 53% of tumours lacking ATRX expression in this study. As one of the most frequently mutated genes in cancer, TP53 mutants are strongly associated with proliferative development [26]. The concomitant presence of TP53 and ATRX mutations complicates the selective examination of ATRX loss on the development and prognosis of PitNETs. Given the role of p53 in DNA repair and

tumour suppression, TP53 alterations may increase the propensity for ATRX mutations, thereby promoting proliferative development in pituitary tumours. Future studies may consider investigating ATRX expression in PitNETs and the interplay with TP53 mutations in prognosis of these patients.

All tumours exhibiting ATRX mutations and loss discussed in this review were identified using either immunohistochemical analysis (IHC), next-generation sequencing (NGS), or a combination of both. The use of IHC for pathological analysis is a standard practice for endocrine and neurological tumour diagnoses as a relatively inexpensive means of detecting changes in protein expression. As ATRX mutations commonly result in truncated proteins, IHC is used to identify loss of ATRX protein expression common in several tumour types [27,28]. However, certain ATRX mutations have been found to result in false ATRX positivity during IHC due to positive staining for protein expression despite loss in protein function [29]. As IHC is limited by the antibodies available for detection, unusual mutations can limit the accuracy and effectiveness of such analyses for ATRX mutations. Furthermore, there is also a lack of standardization regarding determination of ATRX loss in tumours like gliomas, where specific thresholds for positive ATRX expression detected by IHC are not well enforced and vary between studies [30]. NGS allows for more comprehensive detection of tumour mutations and can detect multiple mutations across many genes in a single analysis. However, NGS is more costly and time intensive, making it less accessible [31]. NGS may also miss mutations outside of the gene that are impairing ATRX expression. Heaphy et al. identified a loss of ATRX expression in one case by IHC but did not identify any mutations from NGS, suggesting an external mechanism affecting

ATRX expression [20]. A combination of IHC and NGS should be applied to provide comprehensive tumour examination.

Three studies also used a combination of IHC, fluorescence in-situ hybridization (FISH), and whole exome sequencing (WES for detection of ATRX mutations [19,20,23]. While FISH offers a cost-effective means of detecting large mutations, it is not sensitive enough to detect small intergenic changes that may affect ATRX expression [31]. WES applies similar practices to NGS, but instead examines a sample's entire exome sequence, leading to far higher costs and time detection [29]. Thus, both FISH and WES are not as effective for frequent detection of ATRX mutations in PitNETs.

Limitations

The aim of this study was to review all published research on ATRX mutation and expression in pituitary neuroendocrine tumours. To do so we must accept that we are limited to the type and quality of the published articles from other leading researchers within the field. With regards to our study, we found that the main limitation we identified was the heterogeneity in reporting of results, hampering the ability to perform analyses regarding outcome. For example, one study [20] did not report the tumour type or demographic data of the tumours exhibiting ATRX expression loss, while two other studies [16,19] did not report the average age, sex, and tumour recurrence status of patients in the study. Information regarding duration of follow-up following prognosis and treatment were also incomplete across the study reported in this review. Five studies reported varying follow-up periods between 6 months to 24 years, with many limited by patient loss and time between evaluation and publication [17,18,21,22,24]. Two studies also reported on the recurrent tumour characteristics and did not describe any

evaluations of ATRX expression in the initial tumour [20,23]. Two studies did not present follow-up reports and data of the pituitary tumours [16,19]. The limited data presented regarding past visits and follow-up periods for patients included in each study hinders investigations on links to aggressive behaviour and recurrence. As a diagnostic marker of aggressive behaviour is recurrence, limited reporting and length of follow-up results may be omitting potential tumours exhibiting ATRX loss. Measurement variability also limited investigations, as the included studies used different parameter thresholds for evaluation. The lack of a standard for declaring ATRX loss and the limited reporting on thresholds used during IHC affect the validity of IHC evaluations of ATRX loss. Furthermore, reporting on proliferative markers like Ki67 were inconsistent, with varied standards for elevated values. As mentioned earlier, two studies reported elevated Ki67 as values greater than 3% [18,19], while one study reported values greater than 2% as being elevated [23]. The inconsistent reporting of measurements limited any analyses and investigations. Additionally, the limited research available regarding ATRX expression loss in pituitary tumours further restricted the statistical power of the review, as very few centres were involved in the collection of pituitary tumour samples used in the eight studies examined in the review. As most patients were collected from neurosurgical centres, patient data may be biased towards more severe and aggressive tumour cases.

Future research

Our literature search revealed that all identified studies were published since 2017, highlighting this as an emerging field that requires further investigation. By comparing larger cohorts of PitNETs with ATRX loss to those with intact ATRX function, along with adequate long-

term follow-up on outcomes, we can better understand the clinical significance of ATRX loss in PitNETs.

Conclusions

Both ATRX loss and mutations are uncommon in PitNETs but when they do occur, they primarily affect functional tumours, particularly those of the ACTH lineage. Furthermore, tumours lacking ATRX expression exhibit increased proliferative or transformative characteristics, including a higher incidence of ATRX loss in pituitary carcinomas. While previous research has shown that ATRX represses the activation of the ALT phenotype, we identified the ALT phenotype in some tumours with ATRX loss. However, not all tumours exhibiting the ALT phenotype showed ATRX loss, suggesting a more complex relationship between ATRX expression and ALT phenotype activation in PitNETs. This is an emerging area of study, and larger, prospective studies with long follow-up and consistent reporting are crucial to further investigate the implications of ATRX expression loss in PitNETs.

Acknowledgment

Authors are grateful to the Lloyd Carr-Harris Foundation for their continuous support.

References

1. Xue Y, Gibbons R, Yan Z, Yang D, McDowell TL, Sechi S, et al. The ATRX syndrome protein forms a chromatin-remodeling complex with Daxx and localizes in promyelocytic

leukemia nuclear bodies. Proceedings of the National Academy of Sciences. 2003;100: 10635–10640. doi:10.1073/pnas.1937626100

2. Voon HPJ, Wong LH. New players in heterochromatin silencing: histone variant H3.3 and the ATRX/DAXX chaperone. Nucleic Acids Res. 2016;44: 1496–1501. doi:10.1093/nar/gkw012

3. Iwase S, Xiang B, Ghosh S, Ren T, Lewis PW, Cochrane JC, et al. ATRX ADD domain links an atypical histone methylation recognition mechanism to human mental-retardation syndrome. Nat Struct Mol Biol. 2011;18: 769–76. doi:10.1038/nsmb.2062

4. Eustermann S, Yang J-C, Law MJ, Amos R, Chapman LM, Jelinska C, et al. Combinatorial readout of histone H3 modifications specifies localization of ATRX to heterochromatin. Nat Struct Mol Biol. 2011;18: 777–782. doi:10.1038/nsmb.2070

5. Darmusey L, Pérot G, Thébault N, Le Guellec S, Desplat N, Gaston L, et al. ATRX Alteration Contributes to Tumor Growth and Immune Escape in Pleomorphic Sarcomas. Cancers (Basel). 2021;13: 2151. doi:10.3390/cancers13092151

6. Singhi AD, Liu T-C, Roncaioli JL, Cao D, Zeh HJ, Zureikat AH, et al. Alternative Lengthening of Telomeres and Loss of DAXX/ATRX Expression Predicts Metastatic Disease and Poor Survival in Patients with Pancreatic Neuroendocrine Tumors. Clinical Cancer Research. 2017;23: 600–609. doi:10.1158/1078-0432.CCR-16-1113

7. Nandakumar P, Mansouri A, Das S. The Role of ATRX in Glioma Biology. Front Oncol. 2017;7. doi:10.3389/fonc.2017.00236

8. Ren X, Tu C, Tang Z, Ma R, Li Z. Alternative lengthening of telomeres phenotype and loss of ATRX expression in sarcomas (Review). Oncol Lett. 2018. doi:10.3892/ol.2018.8318

- 448 9. Xie Y, Wang H, Wang S, Feng Y, Feng Y, Fan S, et al. Clinicopathological Significance of
449 ATRX Expression in Nasopharyngeal Carcinoma Patients: A Retrospective Study. J Cancer.
450 2021;12: 6931–6936. doi:10.7150/jca.63333
- 451 10. Asa SL, Mete O, Perry A, Osamura RY. Overview of the 2022 WHO Classification of
452 Pituitary Tumors. Endocr Pathol. 2022;33: 6–26. doi:10.1007/s12022-022-09703-7
- 453 11. Russ S, Anastasopoulou C, Shafiq I. Pituitary Adenoma. StatPearls; 2024.
- 454 12. Nishioka H. Aggressive pituitary tumors (PitNETs). Endocr J. 2023;70: EJ23-0007.
455 doi:10.1507/endocrj.EJ23-0007
- 456 13. Raverot G, Burman P, McCormack A, Heaney A, Petersenn S, Popovic V, et al. European
457 Society of Endocrinology Clinical Practice Guidelines for the management of aggressive
458 pituitary tumours and carcinomas. Eur J Endocrinol. 2018;178: G1–G24. doi:10.1530/EJE-
459 17-0796
- 460 14. Raverot G, Ilie MD, Lasolle H, Amodru V, Trouillas J, Castinetti F, et al. Aggressive
461 pituitary tumours and pituitary carcinomas. Nat Rev Endocrinol. 2021;17: 671–684.
462 doi:10.1038/s41574-021-00550-w
- 463 15. Aromataris E, Lockwood C, Porritt K, Pilla B, Jordan Z. JBI Manual for Evidence Synthesis.
464 Aromataris E, Lockwood C, Porritt K, Pilla B, Jordan Z, editors. JBI; 2024.
465 doi:10.46658/JBIMES-24-01
- 466 16. Casar-Borota O, Botling J, Granberg D, Stigare J, Wikström J, Boldt HB, et al. Serotonin,
467 ATRX, and DAXX Expression in Pituitary Adenomas: Markers in the Differential Diagnosis
468 of Neuroendocrine Tumors of the Sellar Region. Am J Surg Pathol. 2017;41: 1238–1246.
469 doi:10.1097/PAS.0000000000000908

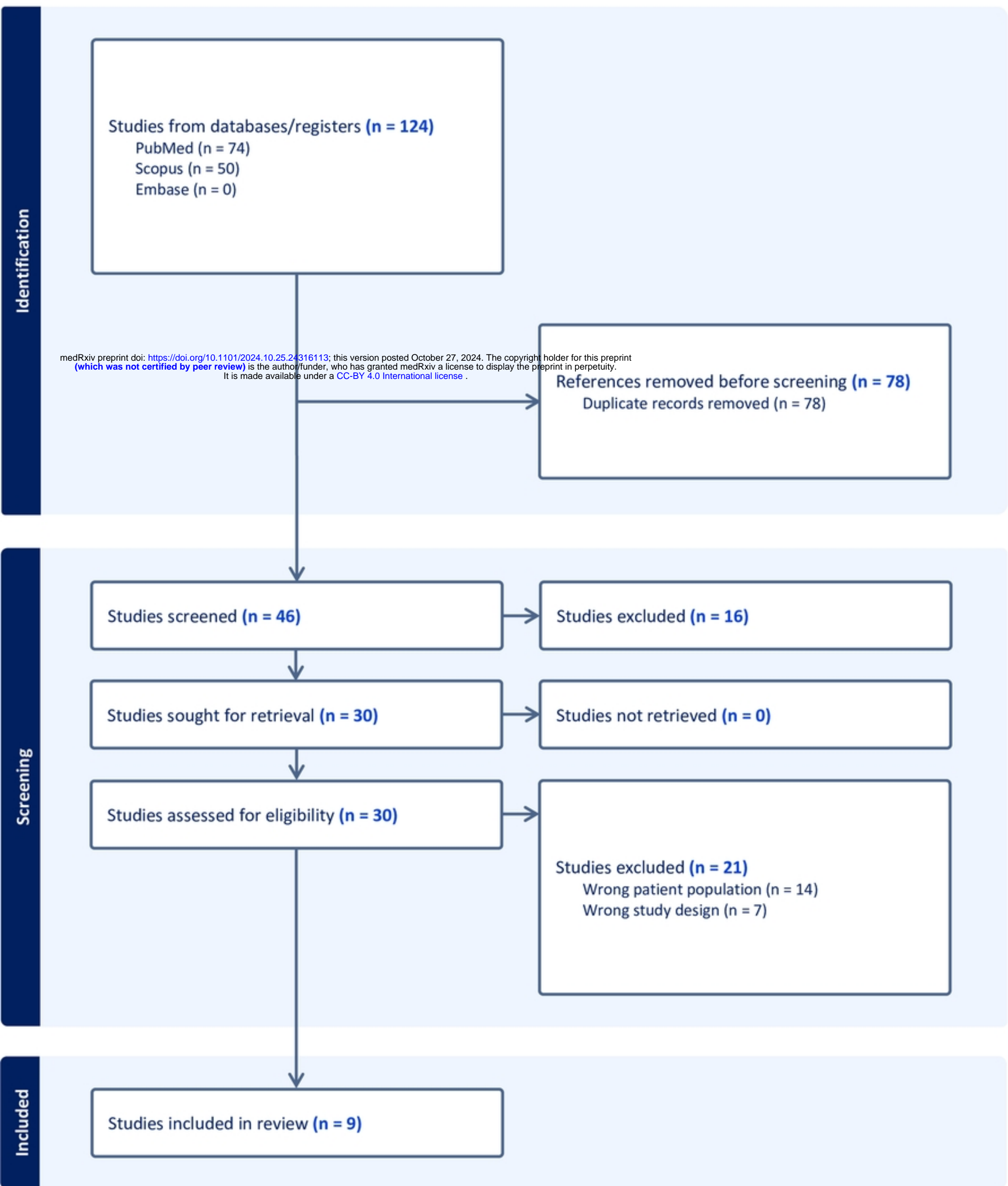
17. Guo F, Wang G, Wang F, Xu D, Liu X. Identification of Novel Genes Involved in the Pathogenesis of an ACTH-Secreting Pituitary Carcinoma: A Case Report and Literature Review. *Front Oncol.* 2018;8: 510. doi:10.3389/fonc.2018.00510
18. Chen J, Schmidt RE, Dahiya S. Pituitary Adenoma in Pediatric and Adolescent Populations. *J Neuropathol Exp Neurol.* 2019;78: 626–632. doi:10.1093/jnen/nlz040
19. Sbiera S, Perez-Rivas LG, Taranets L, Weigand I, Flitsch J, Graf E, et al. Driver mutations in USP8 wild-type Cushing’s disease. *Neuro Oncol.* 2019;21: 1273–1283. doi:10.1093/neuonc/noz109
20. Heaphy CM, Bi WL, Coy S, Davis C, Gallia GL, Santagata S, et al. Telomere length alterations and ATRX/DAXX loss in pituitary adenomas. *Mod Pathol.* 2020;33: 1475–1481. doi:10.1038/s41379-020-0523-2
21. Casar-Borota O, Boldt HB, Engström BE, Andersen MS, Baussart B, Bengtsson D, et al. Corticotroph Aggressive Pituitary Tumors and Carcinomas Frequently Harbor ATRX Mutations. *J Clin Endocrinol Metab.* 2021;106: 1183–1194. doi:10.1210/clinem/dgaa749
22. Lu J, Chen L. Molecular Profile of a Pituitary Rhabdomyosarcoma Arising From a Pituitary Macroadenoma: A Case Report. *Front Endocrinol (Lausanne).* 2021;12: 752361. doi:10.3389/fendo.2021.752361
23. Alzoubi H, Minasi S, Gianno F, Antonelli M, Belardinilli F, Giangaspero F, et al. Alternative Lengthening of Telomeres (ALT) and Telomerase Reverse Transcriptase Promoter Methylation in Recurrent Adult and Primary Pediatric Pituitary Neuroendocrine Tumors. *Endocr Pathol.* 2022;33: 494–505. doi:10.1007/s12022-021-09702-0

24. Lamback E, Miranda RL, Ventura N, Chimelli L, Gadelha MR. Loss of ATRX Protein Expression in an Aggressive Null Cell Pituitary Tumor. JCEM Case Reports. 2024;2. doi:10.1210/jcemcr/luae143
25. Sumislowski P, Rotermund R, Klose S, Lautenbach A, Wefers AK, Soltwedel C, et al. ACTH-secreting pituitary carcinoma with TP53, NF1, ATRX and PTEN mutations Case report and review of the literature. Endocrine. 2022;76: 228–236. doi:10.1007/s12020-021-02954-0
26. Olivier M, Hollstein M, Hainaut P. TP53 Mutations in Human Cancers: Origins, Consequences, and Clinical Use. Cold Spring Harb Perspect Biol. 2010;2: a001008–a001008. doi:10.1101/cshperspect.a001008
27. Heaphy CM, de Wilde RF, Jiao Y, Klein AP, Edil BH, Shi C, et al. Altered Telomeres in Tumors with *ATRX* and *DAXX* Mutations. Science (1979). 2011;333: 425–425. doi:10.1126/science.1207313
28. Wiestler B, Capper D, Holland-Letz T, Korshunov A, von Deimling A, Pfister SM, et al. ATRX loss refines the classification of anaplastic gliomas and identifies a subgroup of IDH mutant astrocytic tumors with better prognosis. Acta Neuropathol. 2013;126: 443–451. doi:10.1007/s00401-013-1156-z
29. Reuss DE, Sahm F, Schrimpf D, Wiestler B, Capper D, Koelsche C, et al. ATRX and IDH1-R132H immunohistochemistry with subsequent copy number analysis and IDH sequencing as a basis for an “integrated” diagnostic approach for adult astrocytoma, oligodendroglioma and glioblastoma. Acta Neuropathol. 2015;129: 133–146. doi:10.1007/s00401-014-1370-3

30. Tanboon J, Williams EA, Louis DN. The Diagnostic Use of Immunohistochemical Surrogates for Signature Molecular Genetic Alterations in Gliomas. J Neuropathol Exp Neurol. 2016;75: 4–18. doi:10.1093/jnen/nlv009
31. Scheie D, Kufaishi HHA, Broholm H, Lund EL, de Stricker K, Melchior LC, et al. Biomarkers in tumors of the central nervous system – a review. APMIS. 2019;127: 265–287. doi:10.1111/apm.12916

Supporting Information

Figure S1. PRISMA 2020 Checklist



Figure