

Major keywords: Dermatofibroma, Dermatofibrosarcoma protuberans, Immunohistochemistry, Diagnostic markers

Title: Immunohistochemical profiles of dermatofibroma and dermatofibrosarcoma protuberans: A scoping review

Authors: Céline S. C. Hardy^{1,2#}, Ali Razavi¹, Natalie Nunez¹, William Fitzmaurice¹, Loma Dave¹, Amy R. Slutzky³, Kaitlin Vanderbeck⁴, Ramsay Farah⁵.

Affiliations: ¹ College of Medicine, Upstate Medical University, Syracuse, New York.

²Department of Microbiology and Immunology, Upstate Medical University, Syracuse, New York, USA. ³ Health Sciences Library, Upstate Medical University, Syracuse, New York.

⁴Department of Laboratory Medicine and Pathobiology, University of Toronto, Toronto, Ontario.

⁵ Division of Dermatology, Upstate Medical University, Syracuse, New York

#Address correspondence to hardyce@upstate.edu

Conflicts of interest: the authors have no conflicts to declare.

Acknowledgements: the authors have no acknowledgements to report.

Author contributions: Céline S. C. Hardy, Conceptualization, Data curation, Formal analysis, Investigation, Methodology, Visualization, Writing – original draft, Writing – review and editing | Ali S. Razavi, Conceptualization, Data curation, Investigation, Methodology, Writing – review and editing | Natalie Nunez, Data curation, Investigation, Writing – review and editing | William Fitzmaurice, Data curation, Investigation, Writing – review and editing | Loma Dave, Data curation, Investigation, Writing – review and editing | Amy R. Slutzky, Data curation, Methodology, Supervision, Writing – review and editing | Kaitlin Vanderbeck, Conceptualization, Data curation, Investigation, Methodology, Supervision, Writing – review and editing | Ramsay Farah, Conceptualization, Investigation, Methodology, Supervision, Writing – review and editing

1 **Immunohistochemical profiles of dermatofibroma and dermatofibrosarcoma protuberans:**

2 **A scoping review**

3

4 **Keywords:** Dermatofibroma, Dermatofibrosarcoma protuberans, Immunohistochemistry,

5 Diagnostic markers

6

7 **ABSTRACT**

8 This review summarizes the immunohistochemical profiles of dermatofibroma (DF) and
9 dermatofibrosarcoma protuberans (DFSP) as reported by primary literature in the past 10 years.
10 63 studies were included in the review, with staining information for a total of 99 unique IHC
11 markers reported. The most commonly reported stains were CD34, SMA, S100, and FXIIIa.
12 Most studies applied IHC either to explore descriptive features of DF or DFSP or to determine
13 their utility in diagnostic identification of the lesions. A number of studies applied novel
14 biomarkers which may hold promise for distinguishing DF and DFSP, namely WT1, Cx43, LSP-
15 1, and PHH3, which demonstrated considerable expression differences between the two lesions.
16 This review highlights the need for validation of existing and emerging IHC markers for the
17 diagnosis of DF and DFSP.

18

19 **1.INTRODUCTION**

20 Dermatofibroma (DF) and dermatofibrosarcoma protuberans (DFSP) are spindle cell lesions with
21 overlapping clinical and histologic features. DF, also known as benign fibrous histiocytoma
22 (BFH), are benign soft tissue tumors with good prognosis. Contrastingly, DFSP are locally
23 aggressive tumors which frequently recur. Additionally, DFSPs may undergo fibrosarcomatous
24 transformation, which portends a higher rate recurrence and increased risk of metastasis^{1,2}.
25 Appropriate identification of DFs and DFSPs from each other and their histologic mimics is of
26 critical importance to ensure proper clinical management. Despite their clinical divergence, these
27 two lesions share many histologic and morphologic features. Morphologically, both are spindled
28 lesions which may show increased cellularity and mixed fascicular, whorled or storiform growth
29 patterns. Given their clinical and histologic similarities, it may be challenging to differentiate
30 these two entities on histologic grounds alone, particularly in limited biopsies. Therefore,
31 immunohistochemistry (IHC) is often used to differentiate DF from DFSP and is a mainstay in

32 their diagnosis. Key immunohistochemical markers classically include cluster of differentiation
33 34 (CD34) and Factor XIIIa (FXIIIa), where CD34 is known to be strongly positive in over 90%
34 of DFSP^{3,4}, while DFs are known to be negative for CD34 but positive for factor XIIIa^{5,6}.
35 Additional markers used to distinguish between these lesions from each other and their mimics
36 include smooth muscle actin (SMA), S-100, and Desmin. Within both DF and DFSP, IHC can
37 also inform or validate the presence of histologic subtypes, pathogenic/driving gene fusions, and
38 specific pathogenic mechanisms within these lesions.

39
40 However, despite the elaborate use of IHC in classifying and studying DF and DFSP, the
41 diagnostic specificity of the currently employed markers is imperfect. Although a number of
42 novel markers have been suggested, constantly emerging literature coupled with a lack of
43 validated data can lead to confusion about which markers are the most effective. For this reason,
44 we conducted a scoping review of the literature in order to systematically report IHC staining
45 data on these lesions, summarize the utility of existing markers, and highlight emerging markers
46 specifically useful for distinguishing DF and DFSP. An effective summary of the current
47 literature on the IHC staining profiles of these lesions is useful for consolidating information and
48 providing insight into prospective biomarkers which require additional validation.

49

50 **2.METHODS**

51 **2.1 Study design**

52 This review was conducted and reported in accordance with the Preferred Reporting Items for
53 Systematic Reviews and Meta-Analyses Extension for Scoping Reviews (PRISMA-ScR)
54 guidelines⁷. An a priori study protocol was registered in the Open Science Framework
55 (<https://doi.org/10.17605/OSF.IO/92EWY>).

56

57 **2.2 Information sources and search strategy**

58 Four databases – PubMed, Embase (Elsevier), Scopus (Elsevier), and the Cochrane Library –
59 were searched for relevant articles. For each database, key concepts were defined using
60 combinations of controlled vocabulary (where available) and keywords, to maximize search
61 sensitivity. The PubMed search strategy is given below; full search strategies are given in
62 Appendix X.

63 PubMed search strategy:
64 ("Histiocytoma, Benign Fibrous"[Mesh] OR "Dermatofibrosarcoma"[Mesh]
65 OR "histiocytoma*" [tiab] OR dermatofibro* [tiab] OR DFSP [tiab] OR "nodular
66 subepidermal fibrosis" [tiab])
67 AND
68 ("Immunohistochemistry"[Mesh] OR immunohistochem* [tiab] OR IHC [tiab] OR
69 immunostain* [tiab])
70 Database search strategies limited search results to publication dates over the past 20 years
71 (2003-present). Final searches for all databases were run on June 24, 2024.
72

73 **2.3 Eligibility criteria**

74 Studies were selected for inclusion in the review if they:

- 75 • evaluated protein expression by immunohistochemistry (IHC), specifically
76 immunoperoxidase staining, of tissue specimens from human subjects of histologically
77 confirmed cases of cutaneous DF (including benign fibrous histiocytoma, cutaneous
78 fibrous histiocytoma, and epithelioid fibrous histiocytoma) or DFSP;
- 79 • reported the number of lesions evaluated and the fraction of lesions positive or negative
80 for a given marker for greater than 5 lesions;
- 81 • focused on evaluating the tumor cell compartment (as opposed to stromal or immune cell
82 profiling); and
- 83 • were published in English, French, or Spanish.

84 The following types of studies were excluded from the review: review articles, case reports,
85 conference abstracts, in vitro studies, and animal studies.
86

87 **2.4 Article screening**

88 Results from all database searches were uploaded to Covidence (Veritas Health Innovation,
89 Melbourne, Australia). Duplicate records were identified and removed automatically by
90 Covidence, with all duplicate pairs manually confirmed (AS). Then two reviewers (AR, WF,
91 NN, and/or LD) independently screened each title/abstract for inclusion in the review, with any
92 conflicts resolved via discussion with content experts (RF and/or KV). After title/abstract
93 screening was complete, a decision was made to limit the review to studies published over the

94 past 10 years (2013-present), and to exclude case studies and case series evaluating fewer than
95 five lesions. These decisions were made both due to practical/time constraints and in
96 consideration of the relevance of IHC markers evaluated, pertinence and consistency of antibody
97 clones and staining protocols used. Full-text articles were then screened independently by two
98 reviewers (AR, WF, NN, and/or CH), with any conflicts resolved as described above.

99

100 **2.5 Data abstraction**

101 Data collection was performed first by one of two independent reviewers (CH, AR) and then
102 independently verified by the second reviewer. The following data were collected and charted
103 using Microsoft Excel:

- 104 • Study characteristics (article title, publication date, study aim, study geographic location)
- 105 • Lesion information (type and number of lesions studied, sample/specimen type,
106 histologic information if available)
- 107 • IHC characteristics (IHC stains performed, method of IHC evaluation, specific antibodies
108 used, staining expression results for lesions of interest)

109

110 **3.RESULTS**

111 **3.1 Selection and characteristics of sources of evidence**

112 Database searches identified 2506 distinct articles. Following title/abstract and full text
113 screening, 63 articles were selected for inclusion in the review⁸⁻⁷⁰ (**Fig. 1**). Of those 63 studies,
114 15 contained IHC data for DF only, 28 for DFSP only, and 20 studies contained data for both DF
115 and DFSP. Complete characteristics of data extracted from all articles -- including geographic
116 location, date of sample collection, and study aim -- are summarized in supplemental **Table S1**.

117

118 **3.2 Immunohistochemical markers applied in DF and DFSP**

119 Across all studies, a total of 99 IHC markers were evaluated, of which the most discussed
120 markers included CD34, SMA, S100, FXIIIa, Desmin, and Ki-67 (**Fig. 2**). Cluster of
121 differentiation 68 (CD68), anaplastic lymphoma kinase (ALK), epithelial membrane antigen
122 (EMA), and pan-cytokeratin (PanCK) were also frequently discussed (**Fig. 2**). The purpose of
123 IHC application in these studies could be broadly categorized as descriptive, diagnostic, or
124 prognostic. Summary tables of IHC biomarkers applied and their indication or purpose of

125 application in DF and DFSP are summarized in **Table 1** and **Table 2**, respectively. The majority
126 of IHC markers were applied for descriptive or diagnostic purposes. Descriptive studies focused
127 primarily on characterizing expression of a given marker in specific entities, determining
128 associations of expression with variant histology, or evaluating the role of expression in disease
129 pathogenesis. Of the studies evaluating IHC staining with respect to its diagnostic utility, 37
130 studies assessed a role for IHC in distinguishing histologic mimics from either DF or DFSP,
131 while 15 studies contained data focused specifically on distinguishing DF and DFSP from each
132 other.

133

134 **3.3 Immunohistochemical markers for distinguishing DF and DFSP**

135 When focusing on studies aiming to characterize differences in immunohistochemical expression
136 between DF and DFSP (n=13), a total of 30 IHC markers were evaluated. CD34 and Factor XIIIa
137 were the most frequently employed markers for distinguishing DF and DFSP in the reviewed
138 studies (**Fig. S1**). Summary statistics of the staining expression of classical markers in DF
139 compared to DFSP across all studies are provided in **Table 3**. CD34 was frequently strongly
140 positive in DFSPs (95.8%), while negative in DF (15.5%), and contrastingly Factor XIIIa was
141 positive in DF (86.2%) but more frequently negative in DFSP (24.9%) (**Table 3**). SMA, ALK,
142 CD99, and CD68 were more frequently positive in DF than DFSP, while S100 and Desmin
143 tended to be negative in both (**Table 3**). Many studies also provided data regarding more novel
144 markers evaluated for distinguishing between the two lesions, these included: Wilm's tumor 1
145 (WT1), ETS transcription factor (ERG), podoplanin (D2-40), phosphohistone H3 (PHH3), p75,
146 connexin 43 (Cx43), fibroblast growth factor 2 (FGF2), fibroblast growth factor receptor 4
147 (FGFR4), lymphocyte specific protein 1 (LSP-1), p16, and Ki-67 (**Table 4**). Of these, studies
148 evaluating WT1, Cx43 and LSP-1 demonstrated the greatest difference in expression between
149 DF and DFSP. Complete expression data for all markers across all studies are available in
150 supplemental **Table S2**.

151

152 **4.DISCUSSION**

153 In this study, we summarize the applications of IHC markers in DF and DFSP and their utility
154 for distinguishing these lesions as reported in the literature over the past 10 years. In this review
155 a total of 99 unique IHC markers were reported in the 63 studies evaluated. Interpretation of the

156 expression data of these markers and the utility of key markers for distinguishing DF and DFSP
157 will be elaborated upon in the following sections.

158

159 **4.1 Accuracy of classical markers for distinguishing DF and DFSP**

160 Classical markers for diagnosis of DF and DFSP such as CD34, FXIIIa, S-100, and Desmin all
161 demonstrated expression in expected proportions and patterns according to the literature⁷¹.
162 However, it is important to note that despite these overall trends there was marked intra-study
163 variability for most markers. For example, even CD34, one of the most specific markers positive
164 in DFSP, was weakly or focally positive in ~15% of DFs^{42,53,64}. Most commonly, conventional
165 DFs did show negativity for CD34, however many DFs which contained variant histology were
166 specifically noted to have focal CD34 expression. This highlights previous observations that
167 application of CD34 alone is insufficient, and the need for additional markers to clarify the
168 identity of lesions where CD34 expression is ambiguous or present focally. Interestingly,
169 expression of classical markers CD99 and CD68 were reported of variable diagnostic utility to
170 distinguish DF and DFSP. While one study showed that DFs have higher frequency of CD99
171 positivity compared to DFSPs³⁷ and additional data supports there being evidently low
172 expression of CD99 in DFSPs (0% positivity)^{23,69}, data from Song et al. shows 50% positivity in
173 both lesions^{23,37,60,69}. Altogether, there remains work to be done to determine the expression in
174 DF compared to DFSP of classical markers using additional sample sets. Beyond these
175 diagnostic applications, there is a need to better understand the expression of classical markers
176 within these lesion types in regions with variant histology.

177

178 **4.2 Emerging markers for distinguishing DF and DFSP**

179 Given the imperfect specificity of classical markers, there is an inherent need to identify and
180 validate the utility of more novel markers for diagnostic dilemmas. A number of the reviewed
181 studies assessed a role for novel markers in distinguishing DF and DFSP from each other or their
182 mimics. Promising emerging IHC markers included WT1, LSP-1, Cx43, and a combined Ki67
183 and PHH3 score, which warrant further investigation^{12,26,34,50}. Piombino et al. assessed the
184 expression of WT1, a master transcriptional/translational regulator in cell differentiation in a
185 series of soft tissue neoplasms of mesenchymal origin. They found that cytoplasmic WT1
186 expression was absent in all evaluated DFs, but positive in 94.7% of DFSPs⁵⁰. Similar to WT1,

187 connexin 43 (Cx43) was evaluated by Fernandez-Flores et al. because of its suspected role in
188 pathogenesis. Specifically, with respect to propensity for invasion given that connexins are
189 involved in mediating cell-cell adhesion. Cx43 demonstrated excellent specificity for the lesions,
190 with 100% positivity in DF and 0% positivity in DFSP²⁶. Another promising marker studied was
191 Leukocyte specific protein 1 (LSP-1) which was also highly positive in DF, while negative in
192 DFSP³⁴.

193 Although Ki-67 is traditionally thought of as a prognostic, rather than diagnostic
194 biomarker, Agarwal et al. identify potential utility of Ki-67 for distinguishing DF and DFSP in a
195 combined scoring system with PHH3¹². PHH3 is expressed in M phase and is therefore useful in
196 determining mitotic counts. The goal of this study was to assess the utility of a combined scoring
197 system incorporating both the Ki67 index and PHH3 mitotic count, where they found that the
198 mean Ki67 proliferation index and mitotic count were significantly higher in DF compared to
199 DFSP¹². Interestingly, this study may highlight that the integration of multiple features or
200 biomarkers can provide more comprehensive information than looking for one “silver bullet”
201 IHC marker to clarify the diagnosis.

202 D2-40 is another emerging marker for which a number of studies suggested utility,
203 however these data were contradictory and require additional validation. A number of studies
204 suggest D2-40 for aiding in the differential diagnosis of DF and DFSP, where D2-40 is positive
205 in DF and negative in DFSP^{14,53}. However, data from Song et al. demonstrated only 33%
206 positivity in DF⁶⁰. Like D2-20, markers such as ERG, CD10, and p75 have some data to indicate
207 utility, but require further investigation due to conflicting data, or low sample numbers. Across
208 all markers, it should be noted that small sample size, differences in antibody clones, staining
209 protocols, and staining evaluation methodology remain a challenge that likely contribute greatly
210 to the observed variability across studies evaluating a given marker.

211

212 **5. Conclusions**

213 In this review, we report the IHC expression in DF and DFSP of traditional diagnostic markers
214 as well as novel markers which may hold diagnostic utility according to the literature from the
215 past 10 years. Of the markers discussed with diagnostic relevance, traditional markers such as
216 CD34, SMA, and FXIIIa were the most common and demonstrated expected expression patterns
217 in DF and DFSP. Additionally, studies investigated novel markers for distinguishing DF and

218 DFSP such as WT1, Cx43, LSP-1, and PHH3/Ki-67. Future studies should seek to continue
219 investigating the expression of these markers and their potential utility for diagnostic application.

220

221 **Data availability**

222 Data supporting the findings of this study are available within the article and/or its
223 supplementary material.

224

225 **REFERENCES**

- 226 1. Abbott JJ, Oliveira AM, Nascimento AG. The Prognostic Significance of Fibrosarcomatous
227 Transformation in Dermatofibrosarcoma Protuberans. *Am J Surg Pathol*. 2006;30(4).
228 https://journals.lww.com/ajsp/fulltext/2006/04000/the_prognostic_significance_of_fibrosarcomatous.2.aspx
229
- 230 2. Reifs CMA, Salido-Vallejo R. Dermatofibrosarcoma protuberans with fibrosarcomatous
231 transformation. *An Bras Dermatol*. 2016;91(5):700-701. doi:10.1590/abd1806-
232 4841.20164886
- 233 3. Abenoza P, Lillemoe T. CD34 and Factor XIII a in the Differential Diagnosis of
234 Dermatofibroma and Dermatofibrosarcoma Protuberans: *Am J Dermatopathol*.
235 1993;15(5):429-434. doi:10.1097/00000372-199310000-00003
- 236 4. Llombart B, Sanmartín O, López-Guerrero JA, et al. Dermatofibrosarcoma protuberans:
237 clinical, pathological, and genetic (*COL1A1-PDGFB*) study with therapeutic implications.
238 *Histopathology*. 2009;54(7):860-872. doi:10.1111/j.1365-2559.2009.03310.x
- 239 5. CERIO R, SPAULL J, JONES EW. Histiocytoma cutis: a tumour of dermal dendrocytes (dermal
240 dendrocytoma). *Br J Dermatol*. 1989;120(2):197-206. doi:10.1111/j.1365-
241 2133.1989.tb07783.x
- 242 6. RAMANI P, BRADLEY NJ, FLETCHER CDM. QBEND/10, a new monoclonal antibody to
243 endothelium: assessment of its diagnostic utility in paraffin sections. *Histopathology*.
244 1990;17(3):237-242. doi:10.1111/j.1365-2559.1990.tb00713.x
- 245 7. Tricco AC, Lillie E, Zarin W, et al. PRISMA Extension for Scoping Reviews (PRISMA-ScR):
246 Checklist and Explanation. *Ann Intern Med*. 2018;169(7):467-473. doi:10.7326/M18-0850
- 247 8. Abdaljaleel MYO, North JP. Sclerosing Dermatofibrosarcoma Protuberans Shows Significant
248 Overlap With Sclerotic Fibroma in Both Routine and Immunohistochemical Analysis: A
249 Potential Diagnostic Pitfall. *Am J Dermatopathol*. 2017;39(2):83-88.
250 doi:10.1097/DAD.0000000000000584

- 251 9. Abdaljaleel M, North JP. Positive MITF and NKI/C3 Expression in Cellular Neurothekeoma
252 and Dermatofibroma. *Appl Immunohistochem Mol Morphol*. 2021;29(6):440-445.
253 doi:10.1097/PAI.0000000000000889
- 254 10. Adem D, Yazici S, Ozsen M, et al. The Ki-67 proliferation index predicts recurrence-free
255 survival in patients with dermatofibrosarcoma protuberans. *Bosn J Basic Med Sci*. Published
256 online October 20, 2020. doi:10.17305/bjbms.2020.5088
- 257 11. Afifi MM, Elnouaem MI, Omar EM, El-Komary I. Oral and Extraoral Intermediate Tumors:
258 Are MMP-9 and Ki-67 Biomarkers Correlated to Their High Recurrence Rates? *Appl*
259 *Immunohistochem Mol Morphol*. 2020;28(3):229-236. doi:10.1097/PAI.0000000000000703
- 260 12. Agarwal A, Gopinath A, Tetzlaff MT, Prieto VG. Phosphohistone-H3 and Ki67: Useful
261 Markers in Differentiating Dermatofibroma From Dermatofibrosarcoma Protuberans and
262 Atypical Fibrohistiocytic Lesions. *Am J Dermatopathol*. 2017;39(7):504-507.
263 doi:10.1097/DAD.0000000000000690
- 264 13. AlOtaibi MN, Basfar AS, Jawhari AM, et al. The Burden of Skin Cancers in Saudi Arabia
265 Through 2011-2022. *Cureus*. Published online September 11, 2023.
266 doi:10.7759/cureus.45052
- 267 14. Aslam M, Khan FW, Chughtai AS, Naeem A, Bashir A, Khan A. Frequency of Expression of
268 D240 in Dermatofibroma – A diagnostic study. *Pak J Med Health Sci*. 2022;16(1):37-39.
269 doi:10.53350/pjmhs2216137
- 270 15. Berklite L, Ranganathan S, John I, Picarsic J, Santoro L, Alaggio R. Fibrous
271 histiocytoma/dermatofibroma in children: the same as adults? *Hum Pathol*. 2020;99:107-
272 115. doi:10.1016/j.humpath.2020.03.012
- 273 16. Berklite L, John I, Ranganathan S, Parafioriti A, Alaggio R. SOX9 Immunohistochemistry in
274 the Distinction of Angiomatoid Fibrous Histiocytoma From Histologic Mimics: Diagnostic
275 Utility and Pitfalls. *Appl Immunohistochem Mol Morphol*. 2020;28(8):635-640.
276 doi:10.1097/PAI.0000000000000809
- 277 17. Brčić I, Godschachner TM, Bergovec M, et al. Broadening the spectrum of NTRK rearranged
278 mesenchymal tumors and usefulness of pan-TRK immunohistochemistry for identification
279 of NTRK fusions. *Mod Pathol*. 2021;34(2):396-407. doi:10.1038/s41379-020-00657-x
- 280 18. Cammareri C, Beltzung F, Michal M, et al. PRAME immunohistochemistry in soft tissue
281 tumors and mimics: a study of 350 cases highlighting its imperfect specificity but potentially
282 useful diagnostic applications. *Virchows Arch*. 2023;483(2):145-156. doi:10.1007/s00428-
283 023-03606-6
- 284 19. Campione E, Di Prete M, Costanza G, et al. Increased Occurrence of Cutaneous Leiomyomas
285 and Dermatofibromas in Patients with Uterine Leiomyomas without Fumarate Hydratase

- 286 Gene Mutations. *Dermatopathology*. 2023;10(3):231-243.
287 doi:10.3390/dermatopathology10030032
- 288 20. Cheah AL, Billings SD, Goldblum JR, Carver P, Tanas MZ, Rubin BP. STAT6 rabbit monoclonal
289 antibody is a robust diagnostic tool for the distinction of solitary fibrous tumour from its
290 mimics. *Pathology (Phila)*. 2014;46(5):389-395. doi:10.1097/PAT.000000000000122
- 291 21. Cleven AHG, Sannaa GAA, Briaire-de Bruijn I, et al. Loss of H3K27 tri-methylation is a
292 diagnostic marker for malignant peripheral nerve sheath tumors and an indicator for an
293 inferior survival. *Mod Pathol*. 2016;29(6):582-590. doi:10.1038/modpathol.2016.45
- 294 22. Dahiya S, Tomar R, Ahuja M, et al. Dermatofibrosarcoma protuberans: Clinicopathological
295 spectrum with emphasis on lymph node metastasis and fibrosarcomatous transformation. *J*
296 *Cancer Res Ther*. 2022;18(9):439. doi:10.4103/jcrt.JCRT_370_20
- 297 23. Dai Z, He Y, Zhang X, et al. Head-and-neck dermatofibrosarcoma protuberans: Survival
298 analysis and Clinically relevant immunohistochemical indicators. *Oral Dis*. 2024;30(3):1040-
299 1051. doi:10.1111/odi.14495
- 300 24. Doyle LA, Mariño-Enriquez A, Fletcher CD, Hornick JL. ALK rearrangement and
301 overexpression in epithelioid fibrous histiocytoma. *Mod Pathol*. 2015;28(7):904-912.
302 doi:10.1038/modpathol.2015.49
- 303 25. Effiom OA, Olurotimi Olojede AC, Akinde OR, Olawuyi AB, Amoo AT, Arotiba GT.
304 Dermatofibrosarcoma protuberans: clinicopathologic presentation in Nigerians. *Pan Afr*
305 *Med J*. 2018;31. doi:10.11604/pamj.2018.31.25.13665
- 306 26. Fernandez-Flores A, Varela-Vazquez A, Mayan MD, Fonseca E. Connexin 43 in
307 Dermatofibroma and Dermatofibrosarcoma Protuberans: Diagnostic, Pathogenic, and
308 Therapeutic Implications. *Am J Dermatopathol*. 2023;45(12):812-815.
309 doi:10.1097/DAD.0000000000002562
- 310 27. Ha SY, Lee SE, Kwon MJ, et al. PDGFB rearrangement in dermatofibrosarcoma protuberans:
311 correlation with clinicopathologic characteristics and clinical implications. *Hum Pathol*.
312 2013;44(7):1300-1309. doi:10.1016/j.humpath.2012.09.021
- 313 28. Han Q, Chen M, Yang J, Du T, Peng H. Dermatofibrosarcoma protuberans of the face: A
314 clinicopathologic and molecular study of 34 cases. *JDDG J Dtsch Dermatol Ges*.
315 2022;20(11):1463-1473. doi:10.1111/ddg.14882
- 316 29. Hengy M, Veenstra J, Perry K, Ozog DM, Friedman BJ. ETS-related Gene (ERG) is
317 Differentially Expressed in Dermatofibroma (Fibrous Histiocytoma) as Compared With
318 Dermatofibrosarcoma Protuberans and Hypertrophic Scars: A Pilot Immunohistochemical
319 Study. *Appl Immunohistochem Mol Morphol*. 2022;30(6):453-458.
320 doi:10.1097/PAI.0000000000001030

- 321 30. Hiraki-Hotokebuchi Y, Yamada Y, Kohashi K, et al. Alteration of PDGFR β -Akt-mTOR pathway
322 signaling in fibrosarcomatous transformation of dermatofibrosarcoma protuberans. *Hum*
323 *Pathol.* 2017;67:60-68. doi:10.1016/j.humpath.2017.07.001
- 324 31. Hung YP, Fletcher CDM, Hornick JL. FOSB is a Useful Diagnostic Marker for Pseudomyogenic
325 Hemangioendothelioma. *Am J Surg Pathol.* 2017;41(5):596-606.
326 doi:10.1097/PAS.0000000000000795
- 327 32. Ishigami T, Hida Y, Matsudate Y, Murao K, Kubo Y. The involvement of fibroblast growth
328 factor receptor signaling pathways in dermatofibroma and dermatofibrosarcoma
329 protuberans. *J Med Invest.* 2013;60(1.2):106-113. doi:10.2152/jmi.60.106
- 330 33. Jahanseir K, Xing D, Greipp PT, et al. PDGFB Rearrangements in Dermatofibrosarcoma
331 Protuberans of the Vulva: A Study of 11 Cases Including Myxoid and Fibrosarcomatous
332 Variants. *Int J Gynecol Pathol.* 2018;37(6):537-546. doi:10.1097/PGP.0000000000000472
- 333 34. Jin SY, Choi JS, Choi YL, Choi YL, Kim DH, Lee SH. Identification of Leukocyte-Specific Protein
334 1-Positive Cells: A Clue to the Cell of Origin and a Marker for the Diagnosis of
335 Dermatofibroma. *Ann Dermatol.* 2015;27(2):157. doi:10.5021/ad.2015.27.2.157
- 336 35. Karanian M, Pérot G, Coindre JM, Chibon F, Pedeutour F, Neuville A. Fluorescence in situ
337 hybridization analysis is a helpful test for the diagnosis of dermatofibrosarcoma
338 protuberans. *Mod Pathol.* 2015;28(2):230-237. doi:10.1038/modpathol.2014.97
- 339 36. Kazakov DV, Kyrpychova L, Martinek P, et al. ALK Gene Fusions in Epithelioid Fibrous
340 Histiocytoma: A Study of 14 Cases, With New Histopathological Findings. *Am J*
341 *Dermatopathol.* 2018;40(11):805-814. doi:10.1097/DAD.0000000000001085
- 342 37. Kazlouskaya V, Malhotra S, Kabigting FD, Lal K, Elston DM. CD99 Expression in
343 Dermatofibrosarcoma Protuberans and Dermatofibroma. *Am J Dermatopathol.*
344 2014;36(5):392-396. doi:10.1097/DAD.0b013e3182a15f3e
- 345 38. Kim JE, Lee JH, Jeong KH, Kim GM, Kang H. Notch Intracellular Domain Expression in Various
346 Skin Fibroproliferative Diseases. *Ann Dermatol.* 2014;26(3):332.
347 doi:10.5021/ad.2014.26.3.332
- 348 39. Kouki N, Ben Rejeb S, Cherif I, et al. Comparative expression profile of CD10 and cyclin D1 in
349 cutaneous histiocytofibroma and dermatofibrosarcoma. *J Immunoassay Immunochem.*
350 2021;42(4):347-358. doi:10.1080/15321819.2020.1868000
- 351 40. Kreicher KL, Honda KS, Kurlander DE, Bordeaux JS. Hormone receptor expression in patients
352 with dermatofibrosarcoma protuberans. *J Am Acad Dermatol.* 2016;75(6):1205-1209.
353 doi:10.1016/j.jaad.2016.07.011
- 354 41. Li FZ, Ye Q, Ran LW, Fang S. Adipophilin expression in skin lesions with clear cell histology. *J*
355 *Clin Pathol.* 2022;75(9):627-631. doi:10.1136/jclinpath-2021-207443

- 356 42. Liu F, Wang H, Wu G, Li C. Clinical and pathological studies of eight cases of lipidized fibrous
357 histiocytoma. *Exp Ther Med*. 2023;25(2):93. doi:10.3892/etm.2023.11792
- 358 43. Lo C hai, Tsang P man, Cheng S ying, Ling C nam, Ho C lam. Myoid differentiation in
359 dermatofibrosarcoma protuberans and its fibrosarcomatous variant: 10 years experience in
360 a tertiary hospital. *Autopsy Case Rep*. 2022;12:e2021368. doi:10.4322/acr.2021.368
- 361 44. Meng T, Shi X, Wu S, Luo Y, Wang X, Long X. Hormone receptors analysis in Chinese patients
362 with dermatofibrosarcoma protuberans. *J Surg Oncol*. 2018;118(1):157-166.
363 doi:10.1002/jso.25117
- 364 45. Moayed-Alaei L, Vargas AC, Adybeik D, Maclean F, Moir D. Analyzing the morphological
365 spectrum of epithelioid fibrous histiocytoma and the immunohistochemical performance of
366 the ALK D5F3 and ALK1 clones. *Hum Pathol*. 2022;120:46-56.
367 doi:10.1016/j.humpath.2021.12.004
- 368 46. Nakamura I, Kariya Y, Okada E, et al. A Novel Chromosomal Translocation Associated With
369 *COL1A2 - PDGFB* Gene Fusion in Dermatofibrosarcoma Protuberans: PDGF Expression as a
370 New Diagnostic Tool. *JAMA Dermatol*. 2015;151(12):1330.
371 doi:10.1001/jamadermatol.2015.2389
- 372 47. Nam KH, Park SW, Yun SK. A clinicohistopathological analysis of cutaneous fibrous
373 histiocytomas of the finger. *Indian J Dermatol*. 2020;65(5):401. doi:10.4103/ijid.IJD_366_18
- 374 48. Pan H, Byers J, Yin H, et al. The utility of TLE1 and BCOR as immunohistochemical.
- 375 49. Park S, Cho S, Kim M, et al. Dermatofibrosarcoma protuberans: A retrospective study of
376 clinicopathologic features and related Akt/mTOR, STAT3, ERK, cyclin D1, and PD-L1
377 expression. *J Am Acad Dermatol*. 2018;79(5):843-852. doi:10.1016/j.jaad.2018.05.016
- 378 50. Piombino E, Broggi G, Barbareschi M, et al. Wilms' Tumor 1 (WT1): A Novel Immunomarker
379 of Dermatofibrosarcoma Protuberans—An Immunohistochemical Study on a Series of 114
380 Cases of Bland-Looking Mesenchymal Spindle Cell Lesions of the Dermis/Subcutaneous
381 Tissues. *Cancers*. 2021;13(2):252. doi:10.3390/cancers13020252
- 382 51. Pukhalskaya T, Smoller BR. TLE1 expression fails to distinguish between synovial sarcoma,
383 atypical fibroxanthoma, and dermatofibrosarcoma protuberans. *J Cutan Pathol*.
384 2020;47(2):135-138. doi:10.1111/cup.13596
- 385 52. Russell-Goldman E, Dong F, Laga A, Hanna J. A Novel Fusion Partner, SP100, Drives Nuclear
386 Dot Localization of ALK in Epithelioid Fibrous Histiocytoma. *Am J Dermatopathol*.
387 2023;45(8):539-543. doi:10.1097/DAD.0000000000002475
- 388 53. Sadullahoglu C, Dere Y, Atasever TR, Oztop MT, Karaaslan O. The role of cd34 and d2-40 in
389 the differentiation of dermatofibroma and dermatofibrosarcoma protuberans. *Turk J*
390 *Pathol*. Published online 2017. doi:10.5146/tjpath.2017.01402

- 391 54. Saeed O, Zhang S, Cheng L, Lin J, Alruwail F, Chen S. STAT6 Expression in Solitary Fibrous
392 Tumor and Histologic Mimics: a Single Institution Experience. *Appl Immunohistochem Mol*
393 *Morphol.* 2020;28(4):311-315. doi:10.1097/PAI.0000000000000745
- 394 55. Sandell RF, Carter JM, Folpe AL. Solitary (juvenile) xanthogranuloma: a comprehensive
395 immunohistochemical study emphasizing recently developed markers of histiocytic lineage.
396 *Hum Pathol.* 2015;46(9):1390-1397. doi:10.1016/j.humpath.2015.05.025
- 397 56. Schechter SA, Bresler SC, Patel RM. Fat necrosis with an associated lymphocytic infiltrate
398 represents a histopathologic clue that distinguishes cellular dermatofibroma from
399 dermatofibrosarcoma protuberans. *J Cutan Pathol.* 2020;47(10):913-916.
400 doi:10.1111/cup.13744
- 401 57. Serra-Guillén C, Llombart B, Nagore E, et al. High immunohistochemical nestin expression is
402 associated with greater depth of infiltration in dermatofibrosarcoma protuberans: a study
403 of 71 cases. *J Cutan Pathol.* 2013;40(10):871-878. doi:10.1111/cup.12203
- 404 58. Shah KK, McHugh JB, Folpe AL, Patel RM. Dermatofibrosarcoma Protuberans of Distal
405 Extremities and Acral Sites: A Clinicopathologic Analysis of 27 Cases. *Am J Surg Pathol.*
406 2018;42(3):413-419. doi:10.1097/PAS.0000000000000998
- 407 59. Smith EH, Lowe L, Harms PW, Fullen DR, Chan MP. Immunohistochemical evaluation of P16
408 expression in cutaneous histiocytic, fibrohistiocytic and undifferentiated lesions. *J Cutan*
409 *Pathol.* 2016;43(8):671-678. doi:10.1111/cup.12730
- 410 60. Song JS, Kim EJ, Park CS, Cho KJ. Dermatofibrosarcoma Protuberans: An Immunomarker
411 Study of 57 Cases That Included Putative Mesenchymal Stem Cell Markers. *Appl*
412 *Immunohistochem Mol Morphol.* 2017;25(8):586-591. doi:10.1097/PAI.0000000000000348
- 413 61. Thangaiah JJ, Westling BE, Roden AC, et al. Loss of dimethylated H3K27 (H3K27me2)
414 expression is not a specific marker of malignant peripheral nerve sheath tumor (MPNST):
415 An immunohistochemical study of 137 cases, with emphasis on MPNST and melanocytic
416 tumors. *Ann Diagn Pathol.* 2022;59:151967. doi:10.1016/j.anndiagpath.2022.151967
- 417 62. Üyetürk Ü. Dermatofibrosarcoma Protuberans: A Rare Malignancy. *Turk J Oncol.* Published
418 online 2017. doi:10.5505/tjo.2017.1635
- 419 63. Vivero M, Doyle LA, Fletcher CDM, Mertens F, Hornick JL. GRIA 2 is a novel diagnostic
420 marker for solitary fibrous tumour identified through gene expression profiling.
421 *Histopathology.* 2014;65(1):71-80. doi:10.1111/his.12377
- 422 64. West KL, Cardona DM, Su Z, Puri PK. Immunohistochemical Markers in Fibrohistiocytic
423 Lesions: Factor XIIIa, CD34, S-100 and p75. *Am J Dermatopathol.* 2014;36(5).

- 424 65. Xiong JX, Cai T, Hu L, et al. Risk factors related to postoperative recurrence of
 425 dermatofibrosarcoma protuberans: A retrospective study and literature review. *World J Clin*
 426 *Cases*. 2021;9(20):5442-5452. doi:10.12998/wjcc.v9.i20.5442
- 427 66. Xu S, Zhao L, Wang J. Atrophic dermatofibrosarcoma protuberans: a clinicopathological
 428 study of 16 cases. *Pathology (Phila)*. 2019;51(6):615-620. doi:10.1016/j.pathol.2019.06.002
- 429 67. Yamada Y, Ichiki T, Susuki Y, et al. Diagnostic utility of ERG immunostaining in
 430 dermatofibroma. *J Clin Pathol*. 2023;76(8):536-540. doi:10.1136/jclinpath-2022-208158
- 431 68. Zhang X, Sun D, Zheng H, et al. Comprehensive analysis of transcriptome characteristics and
 432 identification of TLK2 as a potential biomarker in dermatofibrosarcoma protuberans. *Front*
 433 *Genet*. 2022;13:926282. doi:10.3389/fgene.2022.926282
- 434 69. Zhang Z, Lu Y, Shi C, Chen M, He X, Zhang H. Pediatric dermatofibrosarcoma protuberans: A
 435 clinicopathologic and genetic analysis of 66 cases in the largest institution in Southwest
 436 China. *Front Oncol*. 2023;13:1017154. doi:10.3389/fonc.2023.1017154
- 437 70. Zhou L, Xu H, Zhou J, et al. Nuclear TFE3 expression is a diagnostic marker for Desmoid-type
 438 fibromatosis. *Diagn Pathol*. 2019;14(1):34. doi:10.1186/s13000-019-0814-4
- 439 71. Haycox CL, Odland PB, Olbricht SM, Piepkorn M. dermatofibrosarcoma protuberans with
 440 practical applications for diagnosis and treatment.

441

442 TABLES

443

444 **Table 1.** Immunohistochemical biomarkers applied in DF and their primary indication as
 445 evaluated in the studies reviewed.

Indication	Markers	Utility/Findings
Diagnostic	CD34, FXIIIa, S100, SMA, Desmin, Vimentin	Classical diagnostic markers
	FOSB	Distinguish from pseudomyogenic hemangioendothelioma ³¹
	SOX9	Distinguish from AFH ¹⁶
	TLE1, BCOR	Distinguish from AFH ⁴⁸
	STAT6	Distinguish from SFT ²⁰
	MITF, NKI/C3	Compare to expression in cellular neurothekoma ⁹
	TFE3	Compare expression to desmoid type fibromatosis ⁷⁰ and evaluate histopathologic features ^{36,45}
	ERG ^{29,67} , WT1 ⁵⁰ , p75 ⁶⁴ , D2-40 ^{14,53}	Distinguish from DFSP and its mimics
	CD10 ^{39,60} , CCND1 ³⁹ , LSP1 ³⁴ , CD68 ^{34,42,45,47}	Distinguish from DFSP
	CD99	Distinguish from DFSP and describe expression ^{37,60}
Descriptive	MUC4	Describe features of lipidized fibrous histiocytoma ⁴²
	FGFR1-4, FGF2	Understand expression patterns and role in pathogenesis ³²

	Akt, mTOR, STAT3, ERK, CCND1	Understand expression pattern and assess role in recurrence ⁴⁹
	CD163 ^{45,55} , CD11c, CD31, CD45, lysozyme, and CD4 ⁵⁵	Characterize the immunophenotype of solitary xanthogranuloma in comparison to its differential diagnoses (including BFH)
	NCID ³⁸ , PRAME ¹⁸	Describe expression in various fibroproliferative diseases
	TGFb, TGFRb-1/2, SMAD3, VDR	Describe expression in DF, cutaneous leiomyomas, and uterine leiomyomas ¹⁹
	PanCK ^{42,45} , SOX10, p63, and EMA ⁴⁵ , P16 ^{59,69} , P53 ^{33,41} , CD105, CD133, Oct3/4, CD117, and ALK ⁶⁰ , PDGFRα/β, PDGFα/β ^{46,60} , Nestin ⁴⁶	Describe expression
Prognostic	Ki-67, MMP9	Association with high recurrence rate ¹¹

446
447 Abbreviations: AFH, angiomatoid fibrous histiocytoma; Akt, protein kinase B; ALK, anaplastic lymphoma kinase;
448 BCOR, BCL6 corepressor; BHF, benign fibrous histiocytoma; CCND1, cyclin D1; CD, cluster of differentiation
449 (CD34, CD10, CD68, CD99, CD163, CD11c, CD31, CD45, CD4, CD105, CD133, CD117); D2-40, podoplanin;
450 DF, dermatofibroma; DFSP, dermatofibrosarcoma protuberans; EMA, Epithelial membrane antigen; ERG,
451 erythroblast transformation specific related gene; ERK, extracellular signal-regulated kinase; FXIIIa, factor XIIIa;
452 FGF2, fibroblast growth factor 2; FGFR1-4, fibroblast growth factor receptors 1-4; FOSB, FBJ murine
453 osteosarcoma viral oncogene homolog B; Ki-67, Antigen Kiel 67; LSP1, lymphocyte-specific protein 1; MITF,
454 microphthalmia-associated transcription factor; MMP, matrix metalloproteinase; mTOR, mammalian target of
455 rapamycin; MUC4, mucin 4; NICD, notch intracellular domain; NKI/C3, also known as cluster of differentiation 68
456 (CD68); Oct3/4, octamer-binding transcription factor 3/4; P, protein (p75, p63, p16, p53); PanCK, pan-cytokeratin;
457 PDGFα/β, platelet derived growth factor alpha and beta; PDGFRα/β, platelet derived growth factor receptor alpha
458 and beta; PRAME, Preferentially expressed Antigen in Melanoma; SFT, solitary fibrous tumor; SMA, smooth
459 muscle actin; SMAD3, suppressor of mothers against decapentaplegic homolog 3; SOX, SRY-related HMG box
460 gene (SOX9, SOX10); STAT3, signal transducer and activator of transcription 3; STAT6, signal transducer and
461 activator of transcription 6; TFE3, transcription factor binding to IGHM enhancer 3; TGFb, transforming growth
462 factor beta; TGFRb-1/2, transforming growth factor beta receptor 1 and 2; TLE1, transducin-like enhancer of split 1;
463 VDR, vitamin D receptor; WT1, Wilms tumor gene 1

464
465 **Table 2.** Immunohistochemical markers applied in DFSP and their primary indication as
466 evaluated in the studies reviewed.

Indication	Markers	Utility/Findings
Diagnostic	CD34, FXIIIa, SMA, S100, Desmin, Vimentin	Classical diagnostic markers
	GRIA2 ⁶³ , STAT6 ^{20,54,66}	Distinguish from SFT ²⁰ and describe expression
	H3K27me3, H3K27me2	Distinguish PNST from its mimics ^{21,61}
	TLE1	Distinguish AFX and synovial sarcoma ⁵¹
	EVG	Compare to expression in sclerotic fibroma and perineuroma ⁸
	ERG	Distinguish from its mimics ^{29,67}
	WT1	Distinguish from DFSP and its mimics ⁵⁰
	LSP1 ³⁴ , CD68 ^{37,66} , p75 ⁶⁴ , D2-40 ^{53,60} , CD10 ^{39,41,60} , CCND1 ^{39,49}	Distinguish from DF
Descriptive	Melan-A ^{37,66} , PanCK and HMB45 ⁶⁶	Study features of atrophic DFSP
	ER, PR	Describe role in pathogenesis/tumor growth ^{40,44}
	FGFR1-4, FGF2	Understand expression patterns and role in pathogenesis ³²
	Akt ^{30,49} , mTOR, STAT3, and ERK ⁴⁹ , p-4EBP1, p-S6RP, p-and mTOR ³⁰	Understand expression patterns and role in pathogenesis
	NTRK ¹⁷	Describe expression in soft tissue sarcomas
	P16 ^{59,69}	Describe expression patterns

	BCL-2 ^{23,65,69} , CD99 ^{23,37,60,69} , p63, Myogenin ⁶⁹ , MSA ²³	Describe expression patterns/understand clinicopathologic features
	EMA	Describe expression ^{8,28,69} and assess relevance to fibrosarcomatous transformation ⁴¹
	CD105, CD133, ALK, Oct3/4, and CD117 ⁶⁰ , PDGFR α/β ^{23,30,60} , PDGF α/β ^{23,60} , FAM118B and TLK2 ⁶⁸ , PRAME ¹⁸	Describe expression
Prognostic	Ki-67	Independent predictor of RFS ¹⁰
	EZH2, EGFR, PD-L1, VEGF	Investigation as therapeutic targets ²³
	Nestin ^{46,57}	Association of expression with degree of invasion ⁵⁷

467 Abbreviations: AFX, atypical fibroxanthoma; Akt, protein kinase B; ALK, anaplastic lymphoma kinase; BCL-2, b-
468 cell leukemia/lymphoma 2 protein; CCND1, cyclin D1; CD, cluster of differentiation (CD34, CD68, CD10, CD99,
469 CD105, CD133, CD177); D2-40, podoplanin; DF, dermatofibroma; DFSP, dermatofibrosarcoma protuberans;
470 EGFR, epidermal growth factor receptor; EMA, epithelial membrane antigen; ER, estrogen receptor; ERG,
471 erythroblast transformation specific related gene; ERK, extracellular signal-regulated kinase; EVG, elastin Van
472 Gieson; EZH2, enhancer of zeste homolog 2; FAM118B, family with sequence similarity 118 member B; FGF2,
473 fibroblast growth factor 2; FGFR1-4, fibroblast growth factor receptors 1-4; FXIIIa, factor XIIIa; GRIA2, glutamate
474 ionotropic receptor AMPA type subunit 2; H3K27me2, epigenetic modification to the DNA packaging protein
475 Histone H2; H3K27me3, epigenetic modification to the DNA packaging protein Histone H3; HMB45, human
476 melanoma black 45; Ki-67, Antigen Kiel 67; LSP1, lymphocyte-specific protein 1; Melan-A, melanoma antigen
477 recognized by T cells; MSA, muscle specific actin; mTOR, mammalian target of rapamycin; NTRK, neurotrophic
478 tyrosine receptor kinase; Oct3/4, octamer-binding transcription factor 3/4; P, protein; (p75, p16, p63); p-4EBP1,
479 eukaryotic translation initiation factor 4E-binding protein 1; p-mTOR, phosphorylated mammalian target of
480 rapamycin; p-S6RP, S6 ribosomal protein; PanCK, pan-cytokeratin; PDGF α/β , platelet derived growth factor alpha
481 and beta; PDGFR α/β , platelet derived growth factor receptor alpha and beta; PD-L1, programmed death-ligand 1;
482 PNST, peripheral nerve sheath tumor; PR, progesterone receptor; PRAME, Preferentially expressed Antigen in
483 Melanoma; RFS, recurrence-free survival; SFT, solitary fibrous tumor; SMA, smooth muscle actin; STAT, signal
484 transducer and activator of transcription; STAT6, signal transducer and activator of transcription 6; TLE1, transducin-
485 like enhancer of split 1; TLK2, tousel-like kinase 2; VEGF, vascular endothelial growth factor; WT1, Wilms tumor
486 gene 1.

487
488
489 **Table 3.** General trends of immunohistochemical expression for classical/well described markers
490 for distinguishing DF and DFSP.

Listed markers	DF		DFSP	
	General expression (+/-)	In evaluated studies n/total, (%)	General expression (+/-)	In evaluated studies n/total, (%)
CD34	-	35/226 (15.5)	+	980/1023 (95.8)
FXIIIa	+	163/189 (86.2)	-	28/108 (25.9)
SMA	+	63/183 (34.4)	-	26/370 (7)
S100	-	15/114 (13.1)	-	12/432 (2.8)
ALK	+	71/154 (46.1)	-	0/57 (0)
CD99	+	30/36 (83.3)	-	56/176 (31.8)
CD68	+	25/59 (42.4)	-	5/27 (18.5)
Desmin	-	0/41(0)	-	0/332 (0)
Vimentin	N/A	N/A	+	123/126 (97.6)

491 n/total where n=number of positive samples. Abbreviations: (+), positive for expression; (-),
492 negative for expression; ALK, anaplastic lymphoma kinase; CD, cluster of differentiation

493 (CD34, CD99, CD68); DF, dermatofibroma; DFSP, dermatofibrosarcoma protuberans; FXIIIa,
 494 factor XIIIa; N/A, not available; SMA, smooth muscle actin.

495

496 **Table 4.** General trends of immunohistochemical expression for novel/emerging markers
 497 evaluated in distinguishing DF and DFSP.

Marker	Evidence (n positive/total)	Study
WT1	Negative in DF (0/15), positive in DFSP (54/57)	Piombino et al. (2021) ⁵⁰
Cx43	Positive in DF (16/16), Negative in DFSP (0/13 positive)	Fernandez-flores et al. (2023) ²⁶
LSP-1	Positive in DF (18/20), negative in DFSP (2/20)	Jin et al. (2015) ³⁴
ERG	87/97 DF positive with variable (50-89% cells) positive, 0/64 DFSP positive	Yamada et al. (2023) ⁶⁷
	15/15 DF positive, 6/9 DFSP positive	Hengy et al. (2022) ²⁹
PHH3	DF mean mitotic count 1.8 mm ² , DFSP mean mitotic count 0.5/mm ²	Agarwal et al. (2017) ¹²
Ki-67	Mean proliferative index in DF: 39.2mm ² , DFSP: 12.6 mm ²	Agarwal et al. (2017) ¹²
P75	0/30 DF positive, 17/32 DFSP positive	West et al. (2014) ⁶⁴
D2-40	Positive in DF (49/70)	Aslam et al. (2021) ¹⁴
	Positive in DF (23/30) and negative in DFSP (2/15 positive)	Sadullahoglu 2017 ⁵³
	DF 4/12 positive, DFSP 2/57 positive	Song et al. (2017) ⁶⁰
Oct3/4	0/12 DF, 0/57 DFSP	Song et al. (2017) ⁶⁰
CD10	12/12 DF, 23/57 DFSP	Song et al. (2017) ⁶⁰
	13/15 DF, 15/15 DFSP	Kouki et al. (2021) ³⁹
	12/15 DF, 15/15 DFSP	Kouki et al. (2021) ³⁰
FGF2 and FGFR4	Positive in DF (20/20), variable expressivity in DFSP (4/6 positive)	Ishigami et al. (2013) ³²
FGFR1-3	All cases negative in both DF (0/20) and DFSP (0/6)	Ishigami et al. (2013) ³²
P16	Positive in both DF (18/19) and DFSP (4/5)	Smith et al. (2016) ⁵⁹

498 Abbreviations: CD, cluster of differentiation (CD10); Cx43, connexin 43; D2-40, podoplanin;
 499 DF, dermatofibroma; DFSP, dermatofibrosarcoma protuberans; ERG, erythroblast
 500 transformation specific related gene; FGF2, fibroblast growth factor 2; FGFR1-3, fibroblast
 501 growth factor receptors 1-3; FGFR4, fibroblast growth factor receptor 4; Ki-67, Antigen Kiel 67;
 502 LSP1, lymphocyte-specific protein 1; Oct3/4, octamer-binding transcription factor 3/4; P, protein
 503 (p75, p16);PHH3, phosphohistone H3; WT1, Wilms tumor gene 1.

504

505

506

507 **FIGURE LEGENDS**

508 **Figure 1. PRISMA flow diagram indicating the article selection process.**

509 **Figure 2. Frequency of IHC biomarker use across all studies (n=63).** Bar plot indicating the
510 frequency of IHC biomarkers assessed across all studies. Bars indicate the number of studies
511 which evaluated a given marker.

512

513 **SUPPLEMENTAL MATERIAL**

514 **Table S1.** Study characteristics data extracted from the included studies (n=63).

515 **Table S2.** IHC expression data extracted from the included studies (n=63).

516 **Figure S1. Frequency of IHC biomarker use in studies distinguishing between DF and**
517 **DFSP (n=15).** Bar plot indicating the frequency of IHC biomarkers assessed across studies
518 which aimed to differentiate DF and DFSP. Bars indicate the number of studies which evaluated
519 a given marker.

520

521

522

Figure 1.

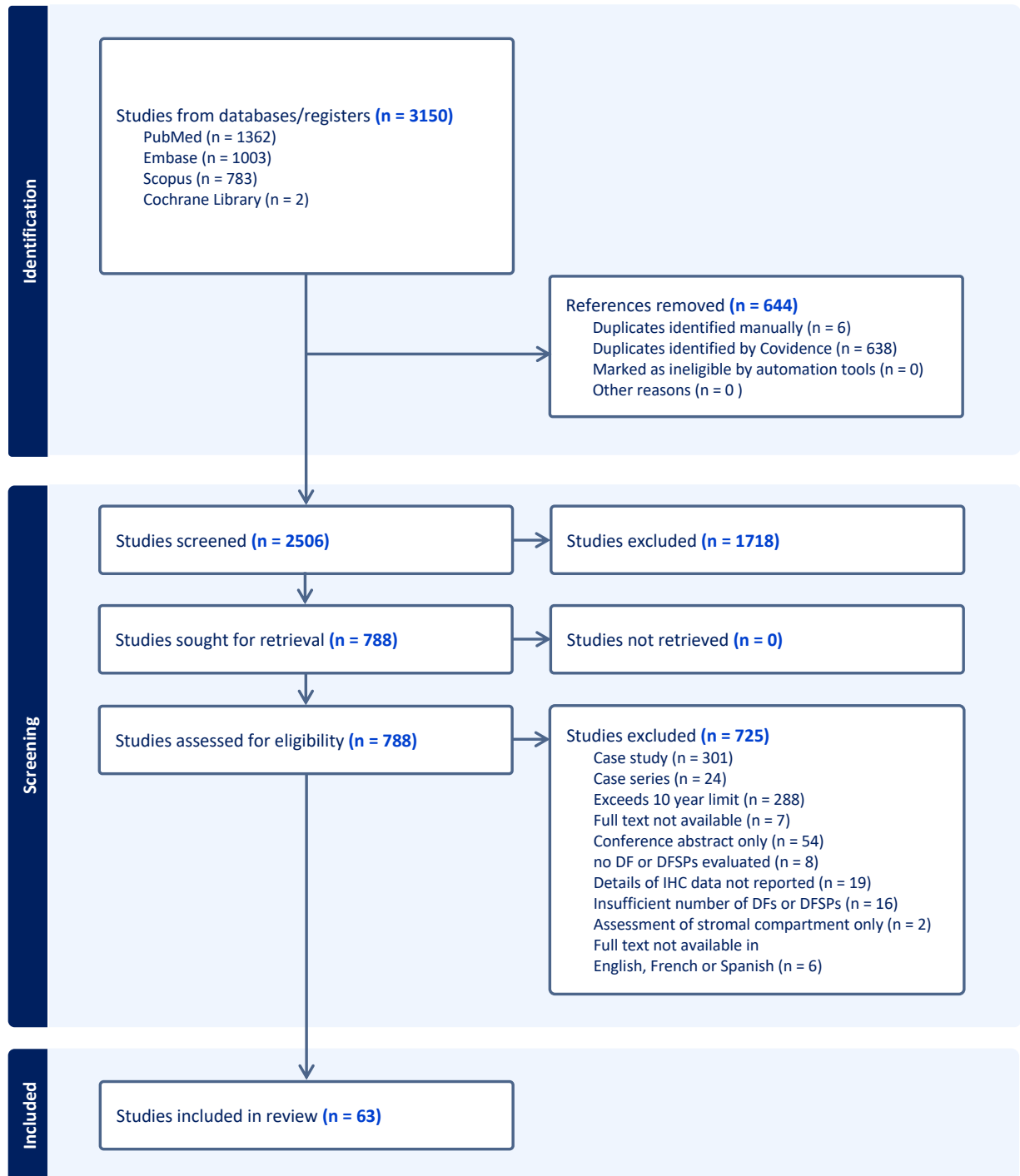


Figure 2.

MARKERS ASSESSED IN ALL STUDIES (n=63)

