

1 **The role of plasmapheresis in snake envenoming: a systematic review**

2 Hari Prasad^{1¶}, Nidhi Kaeley^{2**¶}, Jewel Rani Jose^{3¶}, Ajun U N^{4&}, Takshak Shankar^{5&}, Ajmal Salam^{6&}, Krishna
3 Shukla^{7&}

4 1. Senior Resident, Department of Emergency Medicine, All India Institute of Medical Sciences, New
5 Delhi, India, hariprasad007007007@gmail.com

6 2. Head of Department, Department of Emergency Medicine, All India Institute of Medical Sciences,
7 Rishikesh, India, nidhi.em@aiimsrishikesh.edu.in

8 3. Junior Resident, Department of Emergency Medicine, All India Institute of Medical Sciences, Rishikesh,
9 India, jewka4229@gmail.com

10 4. Senior Research Officer, Department of Psychiatry, National Institute of Mental Health and Neuro
11 Sciences, Bengaluru, India, ajun563@gmail.com

12 5. Senior Resident, Department of Emergency Medicine, All India Institute of Medical Sciences, Rishikesh,
13 India, takshak.shankar@gmx.com

14 6. Senior Resident, Department of Paediatrics, Aster DM Wayanad Institute of Medical Sciences, Wayanad,
15 India, ajmalwims@gmail.com

16 7. DrNB Trainee, Department of Critical Care Medicine, Medanta, The Medicity, Gurgaon, India,
17 krishna.shukla03@gmail.com

18 **Correspondence:** nidhi.em@aiimsrishikesh.edu.in

19

20

21

22

23

24

25

26

27 **Abstract**

28 **Background-** Envenoming from numerous sources, such as snakes, scorpions, and spiders, is a major health issue
29 across the world, resulting in millions of cases and tens of thousands of deaths annually. Venom induced
30 symptoms ranges from systemic reactions like nausea and vomiting to localised pain and swelling. One major risk
31 is the development of venom induced consumption coagulopathy (VICC), which might result in significant
32 consequences. Plasmapheresis is being investigated as a possible therapy for severe envenoming.

33 **Objectives-**We aim to assess the effectiveness and potential advantages of plasmapheresis in snakebite cases,
34 focusing on clinical results. We seek to find if plasmapheresis improves neurological, renal, and hematological
35 dysfunction and impacts secondary outcomes, including patient discharge rates, morbidity, mortality, duration of
36 hospital stay, and the number of plasmapheresis sessions required.

37 **Methods-** Following PRISMA guidelines, we conducted a systematic search of articles published between 1980
38 and July 2023 across multiple databases. MeSH terms related to snakebite and plasmapheresis were applied
39 without publication or language type restrictions. Inclusion criteria considered case reports, cross-sectional
40 studies, or case series featuring plasmapheresis in snakebite management. Inclusions were participants aged 18
41 years or older with confirmed or suspected snakebites, meeting plasmapheresis indications. Exclusions included
42 participants under 18 years, studies reporting only in vitro data, review articles, and redundant reporting. The
43 emphasis was on Emergency Departments or Intensive Care Units.

44 **Results-** In a review of 147 cases (1980 to July 2023), the most common snake was the hump-nosed viper
45 (*Hypnale hypnale*). Renal, neurological, and hematological dysfunctions improved after plasmapheresis. The
46 mean plasmapheresis sessions were 2.1, and the average hospital stay was 13.13 days.

47 **Conclusion-** Once the data has been analyzed, the result emphasizes the clinical importance of plasmapheresis in
48 snakebite envenoming. It helps decision-making when standard therapies are insufficient or ineffective,
49 potentially saving lives.

50 **Keywords-** plasmapheresis, snakebite, snake bite, snakebite envenoming, therapeutic plasma exchange

51

52 **Author Summary**

53 Snakebites pose a significant global health threat, causing numerous deaths and serious injuries annually. While
54 antivenom is the primary treatment, it's not always effective or available. This study explores an alternative
55 treatment called plasmapheresis, a method that filters harmful substances from the blood.

56 We reviewed 147 cases of snake envenoming treated with plasmapheresis between 1980 and 2023. Our findings
57 show that plasmapheresis can improve various complications caused by snake venom, including kidney problems,
58 nerve damage, and blood disorders. On average, patients received about two plasmapheresis treatments and stayed
59 in the hospital for around 13 days.

60 The study suggests that plasmapheresis could be a valuable option when standard treatments aren't working well
61 enough. It might help save lives in severe cases of snake envenoming. While more research is needed, this review
62 provides important insights for doctors treating snakebite victims, especially in areas where snakebites are
63 common and resources are limited.

64 **Background**

65 Envenoming causes significant morbidity and mortality; the most common causes are snakes, scorpions, spiders,
66 bugs, and unidentified bites [1]. According to the World Health Organisation (WHO), there are 2.7 million snake
67 bites globally each year, resulting in 81,000 to 138,000 deaths [2]. Snakebite is classified as a category A
68 Neglected Tropical Disease (NTD) by the WHO [3]. Each year, there are over 81,000 occurrences of snakebite
69 envenoming in India, resulting in 11,000 fatalities [4].

70 Indian Cobra (*Naja Naja*), Russell's Viper (*Daboia russelii*), and Krait (*Bungarus caeruleus*) are among the most
71 harmful and venomous snakes. Examples of local symptoms include painful regional lymphadenopathy, edema,
72 and discomfort at the bite site. Nausea, vomiting, headaches, diaphoresis, stomach discomfort, and diarrhoea are
73 examples of non-specific systemic symptoms. Toxin syndromes such as neurotoxicity, myotoxicity, and VICC
74 can result from systemic envenoming [5]. Some elapid envenomings cause hemostatic and cardiovascular
75 consequences [6].

76 Acute kidney injury (AKI), VICC, and tissue destruction are all caused by metalloproteinases, phospholipase A2,
77 and snake lectins, in hematotoxic venom. The major toxin-mediated coagulopathy brought on by a hemotoxic
78 snakebite is VICC, which is then followed by venom-induced Thrombotic Microangiopathy (TMA) and Diffuse

79 Alveolar Hemorrhage (DAH) [7,8]. Russell's viper (*Daboia russelii*) envenoming causes a specific condition
80 known as Capillary Leak Syndrome (CLS) [9]. Drowsiness, visual abnormalities, and respiratory failure are
81 neurotoxicity signs [6]. Rarely, a snakebite can result in Guillain-Barre Syndrome (GBS) and Insulin Autoimmune
82 Syndrome (IAS), which is treatable with plasmapheresis. For AKI, hemotoxic consequences, CLS, hemodialysis,
83 and antsnake venom are used. But for many, plasmapheresis is a last-ditch option. Plasma exchange is an alternate
84 method for removing venom toxins that are difficult to remove using dialysis or hemoperfusion. Venom toxins
85 can be effectively removed from the blood by plasma exchange but not from other fluid compartments. Plasma
86 exchange may help to reduce venom toxins in the blood compartment and may even cause venom toxins to be
87 redistributed and removed from the extravascular region. Kornalik reported the first instance of plasma exchange
88 being utilized to treat snake bite envenoming in 1990. Rasulov and Berdymuradov reported using plasma
89 exchange in 1994 to treat three of 24 patients who had been bitten by snakes and become envenomed. Zengin et
90 al. found plasmapheresis to be an effective intervention in a retrospective study of 37 snakebite patients with
91 complications not resolving with antivenom administration [10]. Herein, we aim to conduct a systematic review
92 to assess the effectiveness of plasmapheresis in snakebite cases and the situations under which it may be beneficial.

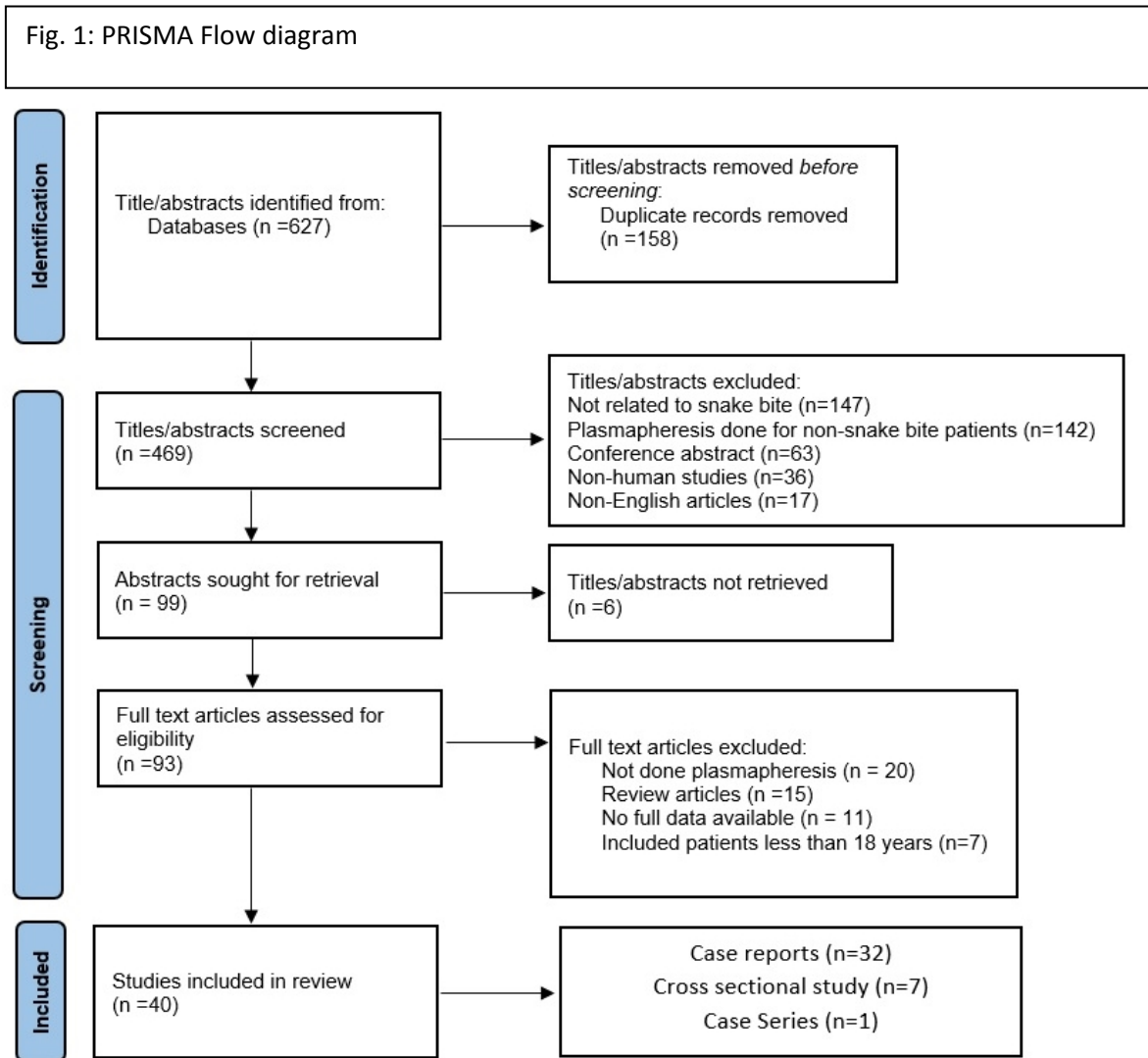
93 **Methods**

94 **Search strategy**

95 PROSPERO (ID: CRD42023459261) was used to register the study protocol. Prior to the start of the systematic
96 review, a protocol was created using PRISMA (Preferred Reporting Items for Systematic Reviews and Meta-
97 Analyses). A comprehensive search approach for articles from 1980 to July 2023 was carried out. PubMed,
98 Embase via Elsevier, MEDLINE via Ovid, The Cochrane Library for Cochrane Reviews, Scopus, Web of Science,
99 and Google Scholar were searched with the MeSH terms 'bite' or 'snakebite' or 'envenomation' or 'snakebite
100 envenoming' and 'plasmapheresis' or 'therapeutic plasma exchange.' Additionally, we contacted the research
101 authors for any missing data, manually checked the reference lists of the included studies, and utilised a database's
102 similar articles function.

103 **Study selection and screening**

104 HP, NK, and JJ independently screened search results for eligibility. For articles eligible after screening, full texts
105 were retrieved by HP, NK, and JJ, which HP, JJ, NK, AU, TS, AS and KS reviewed. HP and JJ screen the citation
106 search. Discrepancies were resolved by consensus. The selection process was done as in Fig. 1 [11].



107

108 **Fig. 1-** PRISMA above shows the flow of patients.

109 **Eligibility Criteria**

110 This review aimed to find, assess, and synthesize all cross-sectional studies, case reports, or case series that used
111 plasmapheresis for snakebite along with conventional Anti Snake Venom (ASV), atropine-neostigmine, calcium
112 gluconate or hemodialysis. Only human cases aged more than 18 years, suspected or confirmed snakebites or
113 those who fulfill indications of plasmapheresis were included in the review. We excluded Human cases under 18
114 years, studies reporting in vitro data only, review articles, or those with complete reporting overlap. The study
115 was set in an Emergency Department or Intensive Care Unit as patients with complications mostly come here.

116

117 **Data extraction**

118 HP and JJ were the authors who extracted the data. Each included study provided the following data regarding
119 study characteristics and outcomes:

120 • Study types: observational studies

121 • The study's methods included: Authors of the study, year, and study design

122 • The intervention(s) of interest: kind, frequency, and comparator(s) used: normal care

123 • Age, gender, and the outcomes listed above were characteristics of the participants' studies.

124 **Assessment of the Risk of Bias**

125 The risk of bias for each research was independently assessed by five review authors (NK, AN, TS, HP, JJ, AS
126 and KS) using the Murad MH, Sultan S, Haffar S, Bazerbachi F. Methodological quality and synthesis of case
127 series and case reports. *BMJ Evid-Based Med.* 2018;23(2): 60–3 [12].

128 **Outcome**

129 The study's primary outcomes were 'improvement in renal dysfunction' defined as patients becoming KDIGO 1
130 at discharge, 'improvement in neurological dysfunction' defined as Guillain Barre Syndrome disability score 0-2
131 at discharge, or 'improvement in hematological dysfunction' described as hemoglobin and platelets returning to
132 age-appropriate normal limits without schistocytes following plasmapheresis done for snakebite. The secondary
133 outcomes were discharge or death, morbidity (KDIGO 2 or3, Guillain Barre Syndrome disability score 3-5, no
134 return to age-appropriate limits for hemoglobin and platelets), hospital stay duration, and number of
135 plasmapheresis. This helps to determine the role of plasmapheresis and its effectiveness in the snakebite.

136 **Analysis**

137 The mean and standard deviation for normal distributions, the median (interquartile range) for non-normal
138 distributions of numerical variables, and percentages and proportions for categorical variables were the ways in
139 which descriptive statistics were stated. The data was analysed using SPSS 23.0.

140 **Results**

141 This systematic review includes 147 patients from 40 studies carried out between 1980 and July 2023. The
 142 population's average age was 49.9 ± 14 years, with 59.9% of patients being male.

143 **Main results:** Regarding the types of snake bites, 77 cases involved unidentified snake species, while the hump-
 144 nosed viper (*Hypnale hypnale*, one of which is *Hypnale zara*) accounted for most known snakebites (42). This
 145 was followed by eight each for Russell's viper (*Daboia russelii*) and saw-scaled viper (five *Echis carinatus*, one
 146 *Echis pyramidum*, one *Echis coloratus*, one *Echis sochureki*), three pit vipers (two *Bothrops asper*, one *Crotalus*
 147 *cerastes*), and other viper species (*Proatheris superciliaris*, *Cerastes cerastes*) accounting for two. Additionally,
 148 there were three krait bites (one *Bungarus caeruleus*, one *Bungarus multicinctus*, one *Bungarus candidus*), one
 149 sea snake bite (*Hydrophis platurus*), one Australian brown snake bite (*Pseudonaja nuchalis*), one taipan bite
 150 (*Oxyuranus scutellatus*), and one Colubridae snake bite (*Notechis scutatus*).

151 A summary table showing study included, type of snake, indication for plasmapheresis and geographical location
 152 of snakebite are shown in Table 1.

153 **Table 1:** Summary Table

Sl.No	Author	Study	Snake	Indication	Geographical Location
1.	Yildirim et al. [13]	Retrospective descriptive study	N/A	VICC	Turkey
2.	Arora et al. [14]	Case report	<i>Daboia russelii</i>	TMA	India
3.	Mohan et al. [15]	Case report	<i>Daboia russelii</i>	TMA	India
4.	Zengin et al. [10]	Retrospective observational study	N/A	VICC	Turkey
5.	Berber et al. [16]	Observational study	N/A	VICC	Turkey

6.	Dineshkumar et al. [17]	Case report	<i>Daboia russelii</i>	TMA	India
7.	Erkurt et al. [18]	Retrospective observational study	N/A	VICC	Turkey
8.	Rathnayaka et al. [19]	Prospective observational study	<i>Hypnale hypnale</i>	TMA	Srilanka
9.	Isbister et al. [20]	prospective observational study	<i>Pseudonaja nuchalis</i>	TMA	Australia
10.	Rahmani et al. [21]	Case series	<i>Echis coloratus</i>	TMA	Israel
11.	Obeidat et al. [22]	Case Report	<i>Echis carinatus</i>	TMA	Jordan
12.	Keyler et al. [23]	Case Report	<i>Proatheris superciliaris</i>	TMA	USA
13.	Kornalik et al. [24]	Case Report	<i>Bothrops asper</i>	VICC	Czechoslovakia.
14.	Valenta et al. [25]	Case Report	<i>Echis pyramidum</i>	TMA	Czech Republic
15.	Sampley et al. [26]	Case Report	N/A	DAH	India
16.	Grace et al. [27]	Case Report	N/A	CLS	India
17.	Hameed et al. [28]	Case Report	<i>Hydrophis platurus</i>	GBS	Pakistan
18.	Cobcroft et al. [29]	Case Report	<i>Oxyuranus scutellatus</i>	TMA	Australia
19.	Chuang et al. [30]	Case Report	<i>Bungarus multicinctus</i>	GBS	Taiwan

20.	Akhilesh Kumar et al. [8]	Case Report	<i>Echis sochureki</i>	DAH	India
21.	Withana et al. [31]	Case Report	<i>Hypnale hypnale</i>	TMA	Srilanka
22.	Mitrakrishnan et al. [32]	Case Report	<i>Hypnale hypnale</i>	TMA	Srilanka
23.	Rathnayaka et al. [33]	Case Series	<i>Daboia russelii</i>	TMA	Srilanka
24.	Srivastava et al. [34]	Case Report	N/A	GBS	India
25.	Reddy et al. [35]	Case Report	<i>Daboia russelii</i>	TMA	India
26.	Cañas et al. [36]	Case Report	<i>Bothrops asper</i>	TMA	Colombia
27.	Rathnayaka et al. [37]	Case report	Hypnale zara	TMA	Srilanka
28.	Godavari et al. [38]	Case Report	N/A	TMA	India
29.	Murthy et al. [39]	Case Report	N/A	TMA	India
30.	Wijewickrama et al. [40]	Prospective observational study	<i>Hypnale hypnale</i>	TMA	Srilanka
31.	Janarthanam et al. [41]	Case Report	<i>Crotalus cerastes</i>	GBS	India
32.	Senthilkumaran et al. [42]	Case Report	<i>Bungarus caeruleus</i>	IAS	India
33.	Priyankara et al. [43]	Case Report	<i>Daboia russelii</i>	TMA	Srilanka
34.	Laothong et al. [44]	Case Series	<i>Bungarus candidus</i>	GBS	Thailand

35.	Herath et al. [45]	case series	<i>Hypnale</i> <i>hypnale</i>	TMA	Srilanka
36.	Bava et al. [46]	Case series	<i>Echis carinatus</i>	DAH, VICC, TMA	India
37.	Elmoqaddem et al. [47]	Case report	<i>Cerastes</i> <i>cerastes</i>	VICC	Morocco
38.	Casamento et al. [48]	Case Series	<i>Notechis</i> <i>scutatus</i>	TMA	Australia

154 CLS, Capillary Leak Syndrome; DAH, Diffuse Alveolar Hemorrhage; GBS, Guillain-Barre Syndrome; IAS,
 155 Insulin Autoimmune Syndrome; TMA, Thrombotic Microangiopathy; USA, United States of America; VICC,
 156 venom-induced consumption coagulopathy

157 Among the indications for plasmapheresis, the majority (51%) was performed for VICC, while 42.2% of cases
 158 were for TMA and 3.4% for GBS. Three cases involved DAH, and one each involved CLS and IAS, all of which
 159 underwent plasmapheresis.

Sl.No	Author	Number of patients *	Age or Range	Sex (Number of Male/Female)	Renal dysfunction present or not. If yes improved or deteriorated following TPE	Neurological dysfunction present or not. If yes improved or deteriorated following TPE	Blood dysfunction present or not. If yes improved or deteriorated following TPE
1.	Yildirim et al. [13]	13	21-75	9/4	-	-	Yes, Improved
2.	Arora et al. [14]	1	44	1/-	Yes, Improved	-	Yes, Improved
3.	Mohan et al. [15]	1	70	-/1	Yes, Improved	-	Yes, Improved

4.	Zengin et al. [10]	33	20-79	19/14	Yes, Improved	-	Yes, Improved
5.	Berber et al. [16]	20	49.55	17/3	Yes, 19 improved 1 Death	-	Yes, 19 improved 1 Death
6.	Dineshkumar et al. [17]	1	56	1/-	Yes/ Not improved-ESRD	-	Yes/ Improved
7.	Erkurt et al. [18]	5	21-80	1/4	Yes, Improved	--	Yes, Improved
8.	Rathnayaka et al. [19]	21	29-70	14/7	Yes/ 16 improved 5 Not improved (1 Death, 4 ESRD)	-	Yes/ 20 improved 1 Not improved-Death
9.	Isbister et al. [20]	1	42	1/-	Yes, Improved	-	Yes, Improved
10.	Rahmani et al. [21]	2	39,70	2/-	Yes, Improved	-	Yes, Improved
11.	Obeidat et al. [22]	1	25	1/-	Yes, Improved	-	Yes, Improved
12.	Keyler et al. [23]	1	27	1/-	Yes, Improved	-	Yes, Improved
13.	Kornalík et al. [24]	1	60	1/-	-	-	Yes, Improved
14.	Valenta et al. [25]	1	41	1/-	Yes, Improved	-	Yes, Improved
15.	Sampley et al. [26] €	1	36	1/-	Yes, Improved	-	Yes, Improved

16.	Grace et al. [27] ξ	1	28	1/-	Yes, Improved	-	Yes, Improved
17.	Hameed et al. [28]	1	21	1/-	-	Yes/ Not improved- Neurodeficit	-
18.	Cobcroft et al. [29]	1	33	1/-	Yes/ Not improved- Death	-	Yes/ Not improved- Death
19.	Chuang et al. [30]	1	36	1/-	-	Yes/ Improved	-
20.	Akhilesh Kumar et al. [8] Ω	1	40	1/-	-	-	Yes, Improved
21.	Withana et al. [31]	1	55	-/1	Yes, Improved	-	Yes, Improved
22.	Mitrakrishnan et al. [32]	1	70	1/-	Yes, Improved	-	Yes, Improved
23.	Rathnayaka et al. [33]	1	66	-/1	Yes, Not Improved- ESRD	-	Yes, Improved
24.	Srivastava et al. [34]	1	40	1/-	-	Yes, Improved	-
25.	Reddy et al. [35]	1	55	-/1	Yes, Improved	-	Yes, Improved
26.	Cañas et al. [36]	1	57	1/-	Yes, Improved	-	Yes, Improved
27.	Rathnayaka et al. [37]	3	55-74	2/1	Yes, Improved	-	Yes, Improved
28.	Godavari et al. [38]	2	30,49	1/1	Yes, Improved	-	Yes, Improved

29.	Murthy et al. [39]	1	51	1/-	Yes, Improved	-	Yes, Improved
30.	Wijewickrama et al. [40]	9	39-59	3/6	Yes, Improved	-	Yes, Improved
31.	Janarthanam et al. [41]	1	29	-/1	-	Yes, Improved	-
32.	Senthilkumaran et al. [42] #	1	54	-/1	-	-	-
33.	Priyankara et al. [43]	1	70	-/1	Yes, Improved	-	Yes, Improved
34.	Laothong et al. [44]	1	35	1/-	-	Yes, Improved \$	-
35.	Herath et al. [45]	7	44-76	3/4	Yes/ Improved Not improved (2 Death, 2 ESRD)	3 - 4	Yes, Improved, 2 Not improved-Death
36.	Bava et al. [46] ¥	3	40-50	2/1	Yes, Improved	2 -	Yes, Improved
37.	Elmoqaddem et al. [47]	1	43	1/-	Yes, Improved	-	-
38.	Casamento et al. [48]	1	55	-/1	Yes, Improved	-	Yes, Improved

160 ESRD End Stage Renal Disease

161 * Number of patients with snakebite as per inclusion criteria of the review

162 #- Patient with Insulin Autoimmune syndrome post snakebite improved following TPE

163 € This patient with DAH post snakebite had concomitant renal and blood dysfunction too all 3 improved following
164 TPE

165 § This patient with CLS post snakebite had concomitant renal and blood dysfunction too all 3 improved following
166 TPE

167 Ω This patient with DAH post snakebite had concomitant blood dysfunction both of which improved following
168 TPE

169 \$ Improved but have persistent autonomic dysfunction

170 ¥ Patient with DAH post snakebite improved following TPE

171

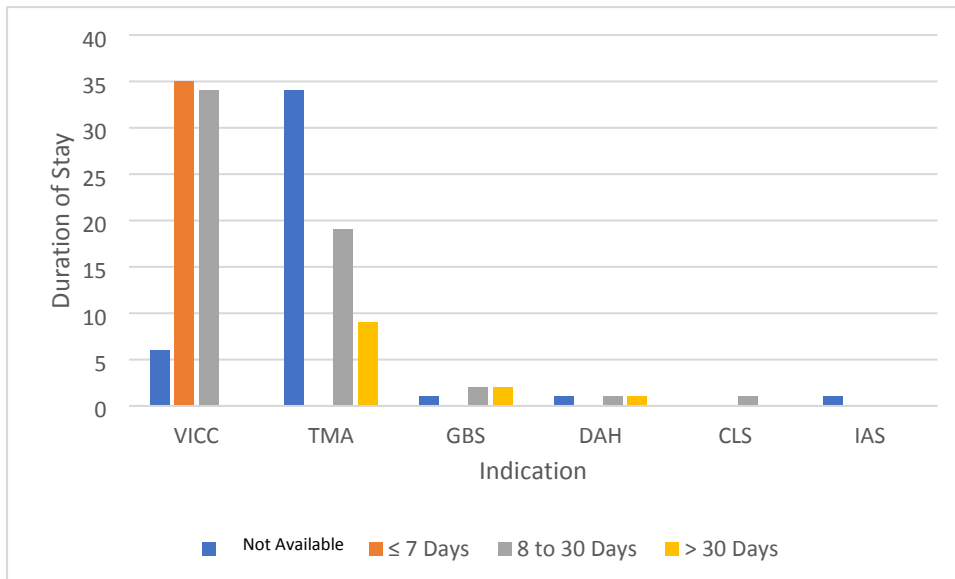
172 Of the 124 patients who developed renal dysfunction, 112 showed improvement after plasmapheresis. Five of the
173 eight patients who developed neurological dysfunction showed improvement after plasmapheresis. Of the 136
174 patients who developed hematological derangements, 124 improved after plasmapheresis. Furthermore, one
175 patient with IAS who developed autonomic dysfunction also improved after plasmapheresis.

176 From the available data, 90.5% of patients were discharged from the hospital, while nine patients succumbed to
177 death. Among the patients, 86.4% did not develop residual clinical effects on discharge (no morbidity), 7.5%
178 developed end-stage renal disease, two developed residual limb weakness, and one developed autoimmune
179 dysfunction. Relation of indication for plasmapheresis and duration of hospital stay is shown in Fig. 2.

180

181 Fig. 2: Mean duration of hospital stay and indications of plasmapheresis

182



183

184 Fig. 2: Bar diagram showing mean duration of hospital stay with plasmapheresis indications

185 CLS, Capillary Leak Syndrome; DAH, Diffuse Alveolar Hemorrhage; GBS, Guillain-Barre Syndrome; IAS,
186 Insulin Autoimmune Syndrome; TMA, Thrombotic Microangiopathy; VICC, venom-induced
187 consumption coagulopathy

188 The duration of hospital stay showed high variability, ranging from 1 to 65 days, with a mean of 13.1 days. The
189 number of plasmapheresis sessions ranged from 1 to 14, with a median of 2 and an interquartile range (IQR) of
190 (1,4).

191 Discussion

192 Snakebites are an occupational danger, with the majority of bites occurring on farms when working barefoot or
193 wandering through the fields at night. The four families of venomous snakes are the Elapidae, Viperidae,
194 Hydrophidae, and Colubridae. Elapid venom's most prevalent clinical effects are neurotoxic, whereas viper venom
195 causes vascular toxicity and nephropathy, and Hydrophiinae or sea snake venom is myotoxic [49].

196 AKI is a common complication of snakebite and a significant cause of death and morbidity. 75% of instances of
197 AKI in this situation are caused by acute tubular necrosis (ATN), while 5–15% of cases are caused by acute
198 interstitial nephritis (AIN) [38]. The prevalence of AKI following Russell's viper (*Daboia russelii*) and *Echis*
199 *carinatus* bites ranges from 13 to 32%. Pathogenesis of AKI in snake envenoming involves hemolysis,
200 rhabdomyolysis, DIC, sepsis, hemodynamic abnormalities, and cell damage caused by the production of
201 proinflammatory cytokines and vasoactive mediators [17,38].

202 Venom induced consumption coagulopathy (VICC)

203 The hemotoxic venom activates coagulation pathways leading to VICC without thrombocytopenia and is
204 characterized by severe bleeding without visible fibrin deposition, microvascular thrombosis, or end-organ failure,
205 which results from snake toxins activating the coagulation pathway. This results in a prolonged prothrombin time,
206 increased fibrinogen consumption, and elevated D-dimer levels, all overlapping with DIC. TMA appears in a
207 subset of individuals with or without VICC whom a snake bite has envenoming. While the coagulopathy in VICC
208 resolves rapidly, the triad of TMA (AKI, thrombocytopenia, and microangiopathic hemolytic anemia) persists for
209 longer. Most cases of TMA following snake envenoming have been documented in Sri Lanka and Australia; very
210 few cases have been reported in India. The proposed mechanism is that venom or its vascular endothelial toxins
211 may function as factors related to VEGF or von Willebrand factor (vWF) activators and cause endothelium
212 damage to initiate TMA. The role of ADAMTS-13, a VWF-cleaving protease, in snake bites requires more
213 investigation [14,17].

214 The symptoms of TMA often begin 1-3 days after the bite and last longer than those of VICC, which typically
215 resolves after 12–24 h of antivenom infusion. According to Bull et al., either the presence of intravascular fibrin
216 or endothelial injury may predispose to fibrin deposition [50]. These data show that TMA may not always be the
217 same as VICC. Certain species, including *B. jararaca*, induce TMA by up-regulating and activating the genes that
218 produce inflammatory mediators such matrix metalloproteinase (MMP)-10, IL-8, VCAM-1, and E-selectin.
219 Jararhagin, a hemorrhagic metalloproteinase discovered from *B. jararaca* venom, may cause a systemic
220 proinflammatory response [51,52].

221 The ecarin enzyme converts prothrombin directly into meizothrombin and is primarily responsible for the
222 pathophysiology of envenoming in members of the *Echis* genus. Disintegrins, including echistatin, ocellatin, and
223 pyramidin, are other venom components that prevent platelet aggregation [53]. Hemorrhaging-like substances
224 exacerbate prothrombotic activation and the production of fibrin deposits and lead to afibrinogenemia [25].

225 TPE for VICC was done in 51.1% of the study's subjects, with 98.6% having their blood dysfunction improved.

226

227 **Thrombotic Micro Angiopathy (TMA)**

228 TMA is a pathological diagnosis and is associated with acute kidney injury (AKI), Microangiopathic Hemolytic
229 Anemia (MAHA) and thrombocytopenia. Thrombotic thrombocytopenic purpura (TTP) and haemolytic uraemic
230 syndrome (HUS) are the prototype diseases associated with TMA. The first is thrombotic thrombocytopenic
231 purpura (TTP), which was discovered in 1925 in a 16-year-old female patient by Eli Moschowitz. The second
232 condition is hemolytic uremic syndrome (HUS), which was discovered by Gasser in 1955 in five newborns who

233 had renal failure, thrombocytopenia, and hemolytic anaemia as a result of a diarrheal sickness [54,55]. Bite-related
234 HUS or HUS-like alterations in Western Australia have been linked to gwadar (*Demansia nuchalis nuchalis*),
235 dugite (*Demansia nuchalis affinis*), and Russell's viper (*Daboia russelii*) bites in India. The difference between
236 HUS and TTP is a little arbitrary because there is much overlap between the two, and it would be preferable to
237 think of them as a continuum of a related disease process [29].

238 TMA is not included in the categories of complement factor dysregulation or ADAMTS 13 deficiency. The
239 primary cause of TMA pathogenesis, according to the study, is endothelial cell damage or dysfunction, which
240 exposes thrombogenic components to coagulation factors and platelets. Endothelial damage occurs as a result of
241 uncontrolled inflammation and/or genetic or acquired abnormalities of complement or hemostasis mediators, as
242 shown in TMA. TPE may be considered as a therapy option for such people if TMA is shown to be the
243 consequence of snake envenoming [15]. TPE for TMA was done in 42.2 % of the study's subjects, with 77.76 %
244 having their renal dysfunction improved and 92.5% have their blood dysfunction improved.

245 **Guillain Barre Syndrome (GBS)**

246 The first instance of GBS associated with a snakebite was reported by Chuang et al. in 1996. Four weeks after
247 being bitten by a *Bungarus multicinctus*, sensorimotor axonal-type polyneuropathy was identified by
248 EMG/NCS. After therapy (plasmapheresis and 500 mg/day of methylprednisolone for five days), the patient's
249 condition improved [30]. In 2010, Srivastava et al. reported that EMG/NCS revealed motor and sensory
250 neuropathy five weeks after the bite, indicating demyelination with subsequent axonal degradation.
251 Plasmapheresis aided the patient's recovery [34]. Neil et al. (2011) described a patient who experienced
252 paraesthesia and quadriparesis 12 days after being bitten by a *Vipera aspis* snake. The researchers discovered
253 molecular similarity between venom proteins and neuronal GM2 gangliosides, hypothesising an immunological
254 explanation rather than direct venom toxicity for this relationship [28,56]. TPE for GBS was performed on
255 3.4% of the study's individuals, with four of them having neurological dysfunction improved and one having
256 neurodeficit. One of those who improved had persisting autonomic dysfunction.

257 **Diffuse Alveolar Hemorrhage (DAH)**

258 DAH is a potentially fatal pulmonary complication in various conditions characterized by hypoxemia caused by
259 alveolar infiltrates, which leads to alveolar hemorrhage and necessitates rapid treatment and lifesaving
260 measures. DAH's causes can be immunological and non-immune. The pathophysiology includes widespread
261 alveolar destruction, alveolar hemorrhage, and antibody-mediated pulmonary capillaritis. Direct venom action

262 and/or an insult mediated by an antibody might account for the delayed DAH by causing widespread alveolar
263 injury. Sampley et al. described DAH in viper envenoming during the first week, with a normal coagulation
264 profile controlled with methylprednisolone and plasmapheresis. The effective use of plasmapheresis and
265 methylprednisolone in DAH on day three following a hump-nosed pit viper (*Hypnale hypnale*) bite, including
266 VICC and thrombotic microangiopathy, was described by Srirangan et al. Therefore, plasma exchange has a
267 limited role in the treatment of snakebite despite evidence supporting its use in thrombotic microangiopathy
268 [8,26]. TPE was performed on three individuals with DAH, two of whom had concurrent blood malfunction and
269 one of whom had concurrent renal impairment. All of which improved after TPE.

270 **Capillary Leak Syndrome (CLS)**

271 Dr. Bayard Clarkson discovered CLS, also known as Clarkson's illness, in 1960. Its defining features are
272 hemoconcentration, hypotension, generalized edema, and hypoalbuminemia without albuminuria [57]. Capillary
273 hyperpermeability and plasma extravasation are the essential mechanisms. CLS can develop as a primary
274 (idiopathic) disorder or a complication of other illnesses. Snake venom contains toxins and enzymes that promote
275 capillary permeability and cause plasma to escape from the intravascular region. The clinical appearance of CLS
276 goes through three stages. First, a prodromal phase of irritation, myalgia, thirst, and syncope. Second, the capillary
277 leakage phase is characterized by intravascular fluid extravasation. Third, complication phase-renal failure is a
278 frequent complication [27]. There are no recognized diagnostic criteria, but with minor revisions, the Thomas and
279 Kumar criteria can be used for diagnosis.

280 Treatment includes theophylline, leukotriene antagonists, terbutaline, plasmapheresis, corticosteroids, and
281 intravenous immunoglobulin (IG), disease-modifying therapy medications. The outlook for CLS is still quite bad
282 because there is no established treatment. We hypothesized that the patient's favorable result may have been
283 influenced by early CLS detection, timely plasmapheresis implementation, and the use of fresh frozen plasma
284 [58]. TPE was done for one patient with CLS post snakebite who had concomitant renal and blood dysfunction
285 too all of which improved following treatment.

286 **Insulin Autoimmune Syndrome (IAS)**

287 In the early 1970s, Hirata and colleagues described Insulin Autoimmune Syndrome (IAS). Postprandial
288 hypoglycemia, increased insulin levels, and detectable insulin antibodies are all indications of IAS. These
289 antibodies, most often IgG, are considered to bind to circulating insulin and inhibit its interaction with its receptor.

290 There have been a few accounts of a snakebite-inducing IAS. Many biomolecules in snake venom have the
291 potential to be antigenic. Common krait's (*Bungarus caeruleus*) venom may contain a compound with structural
292 resemblance to endogenous insulin, leading to the production of antibodies against its epitope, or venoms could
293 include substances that reduce disulfide and cause the production of monomers. The existence of the HLA-
294 DRB1*0406 allele has been linked to the onset of IAS. Dextrose infusions, corticosteroids, somatostatin,
295 diazoxide, azathioprine, rituximab, metformin, dietary changes, and plasmapheresis have all been used to treat
296 IAS. Plasmapheresis rapidly decreased the patient's autoantibody level and reversed their condition. Therefore,
297 once the diagnosis has been made, particularly for individuals with krait (*Bungarus caeruleus*) envenoming, early
298 usage of plasmapheresis will be beneficial [42]. One patient with Insulin Autoimmune syndrome post snakebite
299 was there in study who improved following TPE

300

301 **Plasmapheresis**

302 Plasma exchange is an alternate method for removing venom toxins that are difficult to remove using dialysis or
303 hemoperfusion. Venom toxins can be effectively removed from the blood by plasma exchange but not from other
304 fluid compartments. Plasma exchange may help to reduce venom toxins in the blood compartment and may even
305 cause venom toxins to be redistributed and removed from the extravascular region. Kornalik reported the first
306 instance of plasma exchange being utilized to treat snake bite envenoming in 1990. Rasulov and Berdymuradov
307 reported using plasma exchange in 1994 to treat three of 24 patients who had been bitten by snakes and become
308 envenomed. Zengin et al. found plasmapheresis to be an effective intervention in a retrospective study of 37
309 snakebite patients with complications not resolving with antivenom administration [10].

310 Plasmapheresis has been utilized to treat TMA caused by snake bites in the absence of antivenom. Plasma
311 exchange therapy should be started before a laboratory test can definitively establish the diagnosis because of the
312 substantial mortality risk associated with TTP. This lack of supporting evidence shows that plasma exchange has
313 only a minor role in snakebite envenoming. Therapeutic plasma exchange for snakebite envenoming is classified
314 as Category III, grade 2 C by the American Society for Apheresis (ASFA) (poor recommendation, low-quality or
315 extremely low-quality evidence) [8].

316 According to the ASFA criteria, acquired TTP is a category I indication for TPE (grade 1A evidence). TPE has
317 two advantages: it eliminates autoantibodies against ADAMTS13 and infuses donor plasma with exogenous

318 ADAMTS13 enzyme. The ASFA classified (Shiga like Toxin-Producing E.coli) STEC-HUS as category IV. The
319 argument for using TPE in aHUS is that when allogeneic donor plasma is utilized as the replacement fluid for the
320 exchange; this treatment will eliminate the faulty complement proteins and autoantibodies against complement
321 factor H (CFH). According to ASFA recommendations, TPE is a second-line treatment for patients with additional
322 complement mutations (category II, grade 2C) and a first-line treatment for those who have anti-CFH
323 autoantibodies (category I, grade 2C) [23,59].

324 Other indications for plasmapheresis include Guillain-Barré syndrome, ANCA-associated and Goodpasture
325 glomerulonephritis, chronic demyelinating polyradiculoneuropathy, recurrent focal segmental
326 glomerulosclerosis, hyperviscosity in monoclonal gammopathies, myasthenia gravis, and encephalitis (Category
327 1). Acute encephalomyelitis, cardiac and stem cell transplantation desensitisation, antiphospholipid syndrome,
328 cryoglobulinemia, cardiomyopathy, Hashimoto encephalopathy, Lambert-Eaton syndrome, multiple sclerosis,
329 and myeloma nephropathy (Category 2) are also included. Category 3 indications include acute liver failure,
330 autoimmune hemolytic anaemia, burn shock, newborn lupus, chronic encephalitis, heparin-induced
331 thrombocytopenia, pancreatitis, refractory thrombocytopenia, paraneoplastic syndromes, sepsis, and vasculitis.
332 Systemic amyloidosis, dermatomyositis/polymyositis, and lupus nephritis are all classified under Category 4 [60].

333 Contraindications for therapeutic plasmapheresis include lack of central line access or large bore peripheral lines,
334 hemodynamic instability or septicemia, a known allergy to fresh frozen plasma or replacement colloid/albumin,
335 or heparin; relative contraindications include hypocalcemia and angiotensin-converting enzyme (ACE) inhibitor
336 use within the previous 24 hours [61]. Complications of plasmapheresis are hypocalcemia or hypomagnesemia
337 due to citrate anticoagulation, hypotension, flushing, nausea and vomiting, hypothermia, fluid and electrolyte
338 imbalances, transfusion reactions, thrombocytopenia and hypofibrinogenemia causing bleeding diatheses [62].
339 Plasmapheresis is an effective treatment for a variety of acute and chronic conditions. It may also be used to help
340 prepare for operations and surgeries, as well as to support postoperative recovery and minimise respiration
341 periods. In general, the risks and side effects are minor, with the most prevalent being brief hypotension and
342 associated symptoms [63].

343 However, antivenom should be administered as soon as feasible, and plasma exchange should be considered as a
344 supplemental therapy strategy for patients with severe envenoming, particularly in managing hematologic issues
345 and limb preservation/salvage techniques. We believe that plasma exchange treatment is advantageous because it

346 eliminates toxins and inflammatory mediators. If the envenoming from a snake bite cannot be adequately treated
347 using standard methods, plasma exchange may be explored as part of the treatment [10].

348 So, we propose that plasmapheresis could be used in snakebites in complications such as VICC, TMA, GBS,
349 DAH, CLS, and IAS. Given the rarity of presentation and lack of evidence, plasma exchange could be a lifesaving
350 intervention in some circumstances. The effectiveness of plasma exchange in treating snake bite envenoming
351 should be clarified by conducting extensive randomized controlled trials.

352 **Limitations and strengths**

353 We have included only case series, case reports, and cross-sectional studies as it is challenging to carry out a
354 randomized controlled trial, case-control, or cohort study. The risk of bias was assessed by a nonconventional
355 method using Murad et al. Comparative studies of hemodialysis versus plasmapheresis are required.
356 Plasmapheresis is a costly procedure, and widespread availability is a concern.

357 The study's strength is that it is one of the first to analyze the role of plasmapheresis in snake bite and to list the
358 indications when plasmapheresis may be used in snakebites.

359

360 **Conclusion**

361 Snakebites are serious occupational hazards particularly affecting people in agricultural contexts. Various snake
362 venoms have diverse toxicological profiles, including neurotoxicity, vascular toxicity, nephropathy, and
363 myotoxicity. Acute kidney damage (AKI) is a common and serious complication of snakebite, usually caused by
364 acute tubular necrosis. Hemotoxic venoms can cause coagulopathies, resulting in thrombotic microangiopathy
365 (TMA), which is characterised by acute kidney injury, thrombocytopenia, and microangiopathic hemolytic
366 anaemia. Plasma exchange (plasmapheresis) has emerged as a potential therapeutic option for snakebite
367 complications such as TMA, Guillain-Barré syndrome, diffuse alveolar haemorrhage (DAH), and capillary leak
368 syndrome (CLS). Despite limited evidence, plasmapheresis can be life-saving by removing toxins and
369 inflammatory mediators from the circulation. It is especially useful when conventional therapies are insufficient.
370 Randomised controlled trials are required for establishing the effectiveness of plasmapheresis in snakebite
371 envenoming, however its use as an adjuvant treatment shows promise for improving patient outcomes in severe
372 envenoming.

373 **Acknowledgements**

374 None

375 **Author Contributions**

376 NK had full access to all of the study's data and accepts responsibility for the data's integrity and the correctness

377 of the data analysis. As co-first authors, HP and JRJ contributed equally.

378 Corresponding author: NK

379 Concept and design: HP, NK, JRJ, AU, TS, AS, KS.

380 Acquisition, analysis, or interpretation of data: HP, JRJ, AU.

381 Drafting of the manuscript: HP, NK, JRJ, AS, AU, TS, KS

382 Critical revision of the manuscript for important intellectual content: HP, JRJ, NK, AS, KS, AU, TS

383 Statistical analysis: AU, HP, JRJ.

384 Administrative, technical, or material support: NK.

385 Supervision: HP, JRJ, NK, AS, KS, TS, AU

386 **Funding**

387 None.

388 **Availability of data and materials**

389 The datasets generated during and/or analysed during the current study are available from the corresponding

390 author on reasonable request.

391 **Declarations**

392 Ethics approval and consent to participate

393 Not applicable.

394 **Consent for publication**

395 Not applicable

396 **Competing interests**

397 The authors declare that they have no competing interests.

398 **Author Information**

399 HP, Junior Resident, Department of Emergency Medicine, All India Institute of Medical Sciences, Rishikesh,
400 India, hariprasad007007007@gmail.com

401 NK, Head of Department, Department of Emergency Medicine, All India Institute of Medical Sciences, Rishikesh,
402 India, nidhi.em@aiimsrishikesh.edu.in

403 JRJ, Junior Resident, Department of Emergency Medicine, All India Institute of Medical Sciences, Rishikesh,
404 India, jewka4229@gmail.com

405 AU, Junior Resident, Department of Community and Family Medicine, All India Institute of Medical Sciences,
406 Rishikesh, India, ajun563@gmail.com

407 TS, Senior Resident, Department of Emergency Medicine, All India Institute of Medical Sciences, Rishikesh,
408 India, takshak.shankar@gmx.com

409 AS, Junior Resident, Department of Paediatrics, All India Institute of Medical Sciences, Rishikesh, India,
410 ajmalwims@gmail.com

411 KS, MD, Senior Resident, Department of Emergency Medicine, All India Institute of Medical Sciences,
412 Rishikesh, India, krishna.shukla03@gmail.com

413 **References**

414 1. White J. Bites and stings from venomous animals: a global overview. *Ther Drug Monit.* 2000;22(1):65–8.

415 2. World Health Organization. Snakebite envenoming: a strategy for prevention and control [Internet].
416 Geneva: World Health Organization; 2019 [cited 2023 Aug 18]. 50 p. Available from:
417 <https://apps.who.int/iris/handle/10665/324838>

418 3. Lancet T. Snake-bite envenoming: a priority neglected tropical disease. *The Lancet* [Internet]. 2017 Jul
419 1 [cited 2022 Jul 23];390(10089):2. Available from: [https://www.thelancet.com/journals/lancet/article/PIIS0140-
420 6736\(17\)31751-8/fulltext](https://www.thelancet.com/journals/lancet/article/PIIS0140-6736(17)31751-8/fulltext)

421 4. Kasturiratne A, Wickremasinghe AR, Silva N de, Gunawardena NK, Pathmeswaran A, Premaratna R, et
422 al. The Global Burden of Snakebite: A Literature Analysis and Modelling Based on Regional Estimates of

- 423 Envenoming and Deaths. PLOS Med [Internet]. 2008 Nov 4 [cited 2023 Aug 18];5(11):e218. Available from:
424 <https://journals.plos.org/plosmedicine/article?id=10.1371/journal.pmed.0050218>
- 425 5. Slagboom J, Kool J, Harrison RA, Casewell NR. Haemotoxic snake venoms: their functional activity,
426 impact on snakebite victims and pharmaceutical promise. Br J Haematol [Internet]. 2017 [cited 2023 Aug
427 18];177(6):947–59. Available from: <https://onlinelibrary.wiley.com/doi/abs/10.1111/bjh.14591>
- 428 6. Schrire L, Muller GJ, Pantanowitz L. The diagnosis and treatment of envenomation in South Africa.
429 South African Institute for Medical Research; 1996.
- 430 7. Berling I, Isbister GK. Hematologic effects and complications of snake envenoming. Transfus Med Rev.
431 2015;29(2):82–9.
- 432 8. Kumar A, Gopalakrishnan M, Kuri HR, Bajpayee A, Kothari N, Garg MK. Case Report: Delayed Diffuse
433 Alveolar Hemorrhage in Echis sochureki Envenoming, Jodhpur, India. Am J Trop Med Hyg [Internet]. 2022 Jan
434 31 [cited 2023 Aug 18]; Available from: <https://www.ajtmh.org/view/journals/tpmd/aop/article-10.4269-ajtmh.21-1187/article-10.4269-ajtmh.21-1187.xml>
- 436 9. Krishnadas T, Sasidharan PK. SNAKE BITES IN NORTH KERALA, DEMOGRAPHIC PROFILE
437 AND MEASURES FOR PREVENTION. J Evol Med Dent Sci [Internet]. 2014 Jan 27 [cited 2023 Aug
438 18];3(4):990–9. Available from: <https://go.gale.com/ps/i.do?p=AONE&sw=w&issn=22784748&v=2.1&it=r&id=GALE%7CA646117896&sid=googleScholar&linkaccess=abs>
- 441 10. Zengin S, Yilmaz M, Al B, Yildirim C, Yarbil P, Kilic H, et al. Plasma exchange as a complementary
442 approach to snake bite treatment: an academic emergency department's experiences. Transfus Apher Sci Off J
443 World Apher Assoc Off J Eur Soc Haemapheresis. 2013 Dec;49(3):494–8.
- 444 11. Page MJ, McKenzie JE, Bossuyt PM, Boutron I, Hoffmann TC, Mulrow CD, et al. The PRISMA 2020
445 statement: an updated guideline for reporting systematic reviews. BMJ [Internet]. 2021 Mar 29 [cited 2023 Oct
446 20];372:n71. Available from: <https://www.bmj.com/content/372/bmj.n71>
- 447 12. Murad MH, Sultan S, Haffar S, Bazerbachi F. Methodological quality and synthesis of case series and
448 case reports. BMJ Evid-Based Med. 2018 Apr;23(2):60–3.

- 449 13. Yildirim C, Bayraktaroğlu Z, Gunay N, Bozkurt S, Köse A, Yilmaz M. The use of therapeutic
450 plasmapheresis in the treatment of poisoned and snake bite victims: an academic emergency department's
451 experiences. *J Clin Apheresis*. 2006 Dec;21(4):219–23.
- 452 14. Arora P, Belwal S, Uniyal B, Saxena S. Plasmapheresis in a case of acute kidney injury with severe
453 hemolysis and thrombocytopenia due to hematotoxic (Russell's viper) snake bite. *Saudi J Kidney Dis Transplant*.
454 2020;31(1):276–80.
- 455 15. Mohan G, Guduri PR, Shastry S. Role of therapeutic plasma exchange in snake bite associated
456 thrombotic microangiopathy-A case report with review of literature. *J Clin Apheresis*. 2019 Aug;34(4):507–9.
- 457 16. Berber I, Korkmaz S, Sarici A, Erkurt MA, Kuku I, Kaya E, et al. Therapeutic plasma exchange for
458 envenomation: Is it reasonable? *Transfus Apher Sci*. 2021;60(5):103241.
- 459 17. Dineshkumar T, Dhanapriya J, Sakthirajan R, Thirumalvalavan K, Kurien AA, Balasubramaniyan T, et
460 al. Thrombotic microangiopathy due to Viperidae bite: Two case reports. *Indian J Nephrol*. 2017;27(2):161.
- 461 18. Erkurt MA, Kuku I, Kaya E, Ozgen U, Berber I, Koroglu M, et al. Therapeutic plasma-exchange in
462 hematologic disease: results from a single center in Eastern Anatolia. *Transfus Apher Sci*. 2013;48(3):335–9.
- 463 19. Rathnayaka RN, Ranathunga PAN, Kularatne SAM, Sugathadasa K. Therapeutic plasma exchange for
464 venom-induced thrombotic microangiopathy following hump-nosed pit viper (genus: *Hypnale*) bites: a
465 prospective observational study. *Wilderness Environ Med*. 2022;33(4):386–98.
- 466 20. Isbister GK, Little M, Cull G, McCoubrie D, Lawton P, Szabo F, et al. Thrombotic microangiopathy
467 from Australian brown snake (*Pseudonaja*) envenoming. *Intern Med J*. 2007 Aug;37(8):523–8.
- 468 21. Rahmani TRI, Nasasra T, Fuchs L, Almog Y, Lurie Y, Galante O. Acute thrombotic microangiopathic
469 kidney injury due to *Echis coloratus* envenomation. *Clin Toxicol Phila Pa*. 2020 Apr;58(4):284–6.
- 470 22. Obeidat MB, Al-Swailmeen AM, Al-Sarayreh MM, Rahahleh KM. Thrombotic microangiopathy
471 following Arabian saw-scaled viper (*Echis coloratus*) bite: Case report. *Am J Case Rep*. 2020;21:e922000-1.
- 472 23. Keyler DE. Envenomation by the lowland viper (*Proatheris superciliaris*): severe case profile
473 documentation. *Toxicon*. 2008;52(8):836–41.
- 474 24. Kornalík F, Vorlová Z. Non-specific therapy of a hemorrhagic diathesis after a bite by a young *Bothrops*
475 *asper* (barba amarilla): a case report. *Toxicon Off J Int Soc Toxicology*. 1990;28(12):1497–501.

- 476 25. Valenta J, Stach Z, Kolář M. Envenoming after a snakebite from the Northeast African saw-scaled viper
477 *Echis pyramidum*: prolonged therapy upon failed treatment by antivenom. *Prague Med Rep.* 2011;112(3):226–
478 35.
- 479 26. Sampley S, Sakhuja V, Bhasin D, Singh K, Singh H. Plasmapheresis for pulmonary hemorrhage
480 following viperine snakebite: a case report with review of literature. *Indian J Crit Care Med Peer-Rev Off Publ*
481 *Indian Soc Crit Care Med.* 2020;24(10):986.
- 482 27. Grace M, Jacob KJ, Jayakumar, P. A. Secondary capillary leak syndrome - Plasmapheresis: Is it the
483 answer? | *International Archives of Integrated Medicine | EBSCOhost [Internet].* Vol. 2. 2015 [cited 2024 Jun 30].
484 p. 187. Available from:
485 <https://openurl.ebsco.com/contentitem/gcd:102145212?sid=ebsco:plink:crawler&id=ebsco:gcd:102145212>
- 486 28. Hameed S, Memon M, Khan S. Guillain-Barre Syndrome Following a Snakebite: A Case Report and
487 Review of Literature. *Cureus [Internet].* [cited 2023 Oct 20];11(7):e5278. Available from:
488 <https://www.ncbi.nlm.nih.gov/pmc/articles/PMC6764639/>
- 489 29. Cobcroft RG, Williams A, Cook D, Williams DJ, Masci P. Hemolytic uremic syndrome following taipan
490 envenomation with response to plasmapheresis. *Pathology (Phila) [Internet].* 1997 [cited 2023 Oct 20];29(4):399–
491 402. Available from: <https://linkinghub.elsevier.com/retrieve/pii/S0031302516349893>
- 492 30. Chuang TY, Lin SW, Chan RC. Guillain-Barré syndrome: an unusual complication after snake bite. *Arch*
493 *Phys Med Rehabil.* 1996 Jul;77(7):729–31.
- 494 31. Withana M, Rodrigo C, Gnanathanan A, Gooneratne L. Presumptive thrombotic thrombocytopenic
495 purpura following a hump-nosed viper (*Hypnale hypnale*) bite: a case report. *J Venom Anim Toxins Trop Dis.*
496 2014;20(1):1–6.
- 497 32. Mitrakrishnan JY, Bandula CW, Mitrakrishnan CS, Somaratna K, Jeyalakshmy S. Haemolytic uremic
498 syndrome a hitherto unreported complication of humpnosed viper envenomation. *Indian J Hematol Blood*
499 *Transfus Off J Indian Soc Hematol Blood Transfus.* 2013 Jun;29(2):116–8.
- 500 33. Rathnayaka RN, Ranathunga PAN, Kularatne SA. Thrombotic microangiopathy, hemolytic uremic
501 syndrome, and thrombotic thrombocytopenic purpura following hump-nosed pit viper (Genus: *Hypnale*)
502 envenoming in Sri Lanka. *Wilderness Environ Med.* 2019;30(1):66–78.

- 503 34. Srivastava A, Taly AB, Gupta A, Moin A, Murali T. Guillain-Barré syndrome following snake bite: An
504 unusual complication. *Ann Indian Acad Neurol* [Internet]. 2010 [cited 2023 Oct 20];13(1):67–8. Available from:
505 <https://www.ncbi.nlm.nih.gov/pmc/articles/PMC2859593/>
- 506 35. Reddy SP, Phadnis SA, Kumari P, Sharma N, Sethi J, Pannu AK, et al. Thrombotic microangiopathy in
507 Russel’s viper envenomation. *QJM Int J Med*. 2022;115(7):486–7.
- 508 36. Cañas CA, Vecino MJ, Posso-Osorio I. Atypical Hemolytic Uremic Syndrome in a Patient With
509 Bothrops asper Envenomation. *Wilderness Environ Med* [Internet]. 2022 Mar 1 [cited 2023 Jul 28];33(1):109–
510 15. Available from: <https://www.sciencedirect.com/science/article/pii/S108060322100168X>
- 511 37. Namal Rathnayaka RMMK, Nishanthi Ranathunga PEA, Kularatne SAM. Thrombotic Microangiopathy
512 Following Hypnale zara (Hump-Nosed Pit Viper) Envenoming: The First Known Case Report from Sri Lanka.
513 *Wilderness Environ Med* [Internet]. 2020 Mar 1 [cited 2023 Jul 28];31(1):71–7. Available from:
514 <https://www.sciencedirect.com/science/article/pii/S1080603219301619>
- 515 38. Godavari KSV. Hemolytic Uremic Syndrome-An unusual complication of snake envenomation. *Univ J*
516 *Med Med Spec*. 2016;2(2).
- 517 39. Murthy PR, Ak AK, Karanth S, Kalashetty M. Thrombotic thrombocytopenic purpura in a patient with
518 snake bite. *Indian J Case Rep* [Internet]. 2019 Jun 28 [cited 2024 Jun 30];5(3):277–9. Available from:
519 <https://mansapublishers.com/index.php/ijcr/article/view/1615>
- 520 40. Wijewickrama ES, Gooneratne LV, Gnanathanan A, Gawarammana I, Gunatilake M, Isbister GK.
521 Thrombotic microangiopathy and acute kidney injury following Sri Lankan *Daboia russelii* and *Hypnale* species
522 envenoming. *Clin Toxicol Phila Pa*. 2020 Oct;58(10):997–1003.
- 523 41. Janarthanam MJ. Interesting case of AIDP following snake bite. *Univ J Med Med Spec*. 2016;2(5).
- 524 42. Senthilkumaran S, Miller SW, Williams HF, Thirumalaikolundusubramanian P, Vaiyapuri S, Patel K.
525 Hirata’s disease (insulin autoimmune syndrome) following envenomation by a common krait. *Toxicon Off J Int*
526 *Soc Toxinology*. 2022 Nov;219:106923.
- 527 43. Priyankara S, Rathnasiri V, Mihiran T, Premawansa G, Isbister GK, Silva A. Mild venom-induced
528 consumption coagulopathy associated with thrombotic microangiopathy following a juvenile *Russell’s* viper
529 (*Daboia russelii*) envenoming: A case report. *Toxicon Off J Int Soc Toxinology*. 2022 Jun;212:8–10.

- 530 44. Laothong C, Sitprijia V. Decreased parasympathetic activities in Malayan krait (*Bungarus candidus*)
531 envenoming. *Toxicon Off J Int Soc Toxinology*. 2001 Sep;39(9):1353–7.
- 532 45. Herath N, Wazil A, Kularatne S, Ratnatunga N, Weerakoon K, Badurdeen S, et al. Thrombotic
533 microangiopathy and acute kidney injury in hump-nosed viper (*Hypnale* species) envenoming: A descriptive study
534 in Sri Lanka. *Toxicon* [Internet]. 2012 Jul 1 [cited 2023 Jul 28];60(1):61–5. Available from:
535 <https://www.sciencedirect.com/science/article/pii/S0041010112000876>
- 536 46. Bava D, Kumar PHA, Gupta A, Mandal S, Bajpayee A, Gopalakrishnan M, et al. Redefining the role of
537 therapeutic plasma exchange in complications of *Echis carinatus* sochureki envenomation refractory to anti-snake
538 venom: A case series. *Asian J Transfus Sci*. 2023;17(2):295–300.
- 539 47. Elmoqaddem A, Mrani Alaoui N, Cherrad. M. Hmidi T, Choumi F, Nadour K. Plasma Exchange in a
540 Patient with a Severe Viper Bite. *Saudi J Med Pharm Sci* [Internet]. 2021 Jan 16 [cited 2024 Jun 30];7(1):50–1.
541 Available from: https://saudijournals.com/media/articles/SJMPS_71_50-51.pdf
- 542 48. Casamento AJ, Isbister GK. Thrombotic microangiopathy in two tiger snake envenomations. *Anaesth*
543 *Intensive Care*. 2011;39(6):1124–7.
- 544 49. Chugh KS. Snake-bite-induced acute renal failure in India. *Kidney Int*. 1989 Mar;35(3):891–907.
- 545 50. Bull BS, Rubenberg ML, Dacie JV, Brain MC. Microangiopathic haemolytic anaemia: mechanisms of
546 red-cell fragmentation: in vitro studies. *Br J Haematol*. 1968 Jun;14(6):643–52.
- 547 51. Malaque CMS, Duayer IF, Santoro ML. Acute kidney injury induced by thrombotic microangiopathy in
548 two cases of *Bothrops* envenomation. *Clin Toxicol*. 2019;57(3):213–6.
- 549 52. Bucarechi F, Pimenta MMB, Borrasca-Fernandes CF, Prado CC, Capitani EMD, Hyslop S. Thrombotic
550 microangiopathy following *Bothrops jararaca* snakebite: case report. *Clin Toxicol*. 2019;57(4):294–9.
- 551 53. Okuda D, Nozaki C, Sekiya F, Morita T. Comparative Biochemistry of Disintegrins Isolated from Snake
552 Venom: Consideration of the Taxonomy and Geographical Distribution of Snakes in the Genus *Echis*1. *J Biochem*
553 (Tokyo) [Internet]. 2001 Apr 1 [cited 2023 Oct 20];129(4):615–20. Available from:
554 <https://doi.org/10.1093/oxfordjournals.jbchem.a002898>

- 555 54. Moschcowitz E. An acute febrile pleiochromic anemia with hyaline thrombosis of the terminal arterioles
556 and capillaries: an undescribed disease. *Arch Intern Med* [Internet]. 1925 Jul 1 [cited 2023 Oct 20];36(1):89–93.
557 Available from: <https://doi.org/10.1001/archinte.1925.00120130092009>
- 558 55. Clark WF. Thrombotic Microangiopathy: Current Knowledge and Outcomes With Plasma Exchange.
559 *Semin Dial* [Internet]. 2012 Mar [cited 2023 Oct 20];25(2):214–9. Available from:
560 <https://onlinelibrary.wiley.com/doi/10.1111/j.1525-139X.2011.01035.x>
- 561 56. Neil J, Choumet V, Le Coupanec A, d'Alayer J, Demeret S, Musset L. Guillain-Barre syndrome: first
562 description of a snake envenomation aetiology. *J Neuroimmunol*. 2012 Jan 18;242(1–2):72–7.
- 563 57. Aneja: Idiopathic systemic capillary leak syndrome - Google Scholar [Internet]. [cited 2024 Jun 30].
564 Available from:
565 [https://scholar.google.com/scholar_lookup?journal=UpToDate&title=Idiopathic+systemic+capillary+leak+synd](https://scholar.google.com/scholar_lookup?journal=UpToDate&title=Idiopathic+systemic+capillary+leak+syndrome&author=R+Aneja&author=S+Manaker&author=G+Finlay&)
566 [rome&author=R+Aneja&author=S+Manaker&author=G+Finlay&](https://scholar.google.com/scholar_lookup?journal=UpToDate&title=Idiopathic+systemic+capillary+leak+syndrome&author=R+Aneja&author=S+Manaker&author=G+Finlay&)
- 567 58. Udayabhaskaran V, Arun Thomas ET, Shaji B. Capillary Leak Syndrome Following Snakebite
568 Envenomation. *Indian J Crit Care Med* [Internet]. 2017 Oct;21(10):698–702. Available from: [https://search-](https://search-ebscohost-com.elibraryaiimsrishikesh.remotexs.in/login.aspx?direct=true&db=ccm&AN=125851540&site=ehost-live)
569 [ebscohost-](https://search-ebscohost-com.elibraryaiimsrishikesh.remotexs.in/login.aspx?direct=true&db=ccm&AN=125851540&site=ehost-live)
570 [com.elibraryaiimsrishikesh.remotexs.in/login.aspx?direct=true&db=ccm&AN=125851540&site=ehost-live](https://search-ebscohost-com.elibraryaiimsrishikesh.remotexs.in/login.aspx?direct=true&db=ccm&AN=125851540&site=ehost-live)
- 571 59. Adamski J. Thrombotic microangiopathy and indications for therapeutic plasma exchange. *Hematology*
572 [Internet]. 2014 Dec 5 [cited 2023 Oct 20];2014(1):444–9. Available from:
573 [https://ashpublications.org/hematology/article/2014/1/444/20443/Thrombotic-microangiopathy-and-indications-](https://ashpublications.org/hematology/article/2014/1/444/20443/Thrombotic-microangiopathy-and-indications-for)
574 [for](https://ashpublications.org/hematology/article/2014/1/444/20443/Thrombotic-microangiopathy-and-indications-for)
- 575 60. Schwartz J, Padmanabhan A, Aqui N, Balogun RA, Connelly-Smith L, Delaney M, et al. Guidelines on
576 the Use of Therapeutic Apheresis in Clinical Practice—Evidence-Based Approach from the Writing Committee of
577 the American Society for Apheresis: The Seventh Special Issue. *J Clin Apheresis*. 2016 Jun;31(3):149–62.
- 578 61. Kaplan AA. Therapeutic plasma exchange: core curriculum 2008. *Am J Kidney Dis Off J Natl Kidney*
579 *Found*. 2008 Dec;52(6):1180–96.
- 580 62. Mokrzycki MH, Kaplan AA. Therapeutic plasma exchange: complications and management. *Am J*
581 *Kidney Dis Off J Natl Kidney Found*. 1994 Jun;23(6):817–27.

582 63. Szczepiorkowski ZM, Winters JL, Bandarenko N, Kim HC, Linenberger ML, Marques MB, et al.
583 Guidelines on the use of therapeutic apheresis in clinical practice--evidence-based approach from the Apheresis
584 Applications Committee of the American Society for Apheresis. *J Clin Apheresis*. 2010;25(3):83-177.

585

586

587

588

589