

1 **Pelvic Stability During Total Hip Arthroplasty: A Comparison of Traction and**
2 **Standard Surgical Tables Using Augmented Reality Navigation**

3 **Short title:** Pelvic Stability in Hip Arthroplasty: Comparing Traction vs. Standard Tables
4 with AR Navigation

5

6 Musashi Ima, Tamon Kabata*, Daisuke Inoue, Yu Yanagi, Takahiro Iyobe, Naoya Fujimaru,
7 Satoru Demura

8

9 Department of Orthopedic Surgery, Graduate School of Medical Science, Kanazawa
10 University, 13-1 Takaramachi, Kanazawa, Ishikawa 920-8641, Japan

11

12 ***Corresponding author:** Tamon Kabata, PhD

13 Department of Orthopedic Surgery, Graduate School of Medical Science, Kanazawa
14 University

15 13-1 Takaramachi, Kanazawa, Ishikawa 920-8641, Japan

16 Phone: +81-76-265-2374

17 Fax: +81-76-234-4261

18 Email: tamonkabata@yahoo.co.jp

19 **Abstract**

20 **Background:** Total hip arthroplasty enhances quality of life by improving joint function.

21 However, the success of this procedure heavily relies on precise acetabular cup positioning,
22 which is insufficient using traditional placement guidelines. This insufficiency is evidenced
23 by the persistent occurrence of dislocations, highlighting the critical need for enhanced pelvic
24 alignment accuracy. Standard surgical tables present challenges in maintaining consistent
25 pelvic positioning during the procedure, making it difficult to achieve optimal alignment.

26 **Purpose:** This study aimed to evaluate the effectiveness of a traction surgical table in
27 stabilizing pelvic movements during total hip arthroplasty and compare it with the use of a
28 standard surgical table.

29 **Methods:** This retrospective study assessed 88 total hip arthroplasties performed using the
30 AR-HIP (Zimmer Biomet Japan, Tokyo, Japan) system for real-time pelvic navigation.
31 Procedures were performed using either a standard surgical table (n=48) or a traction surgical
32 table (n=40). Pelvic alignment was monitored at multiple surgical stages, and stability was
33 statistically analyzed to compare the efficacy of the two table types.

34 **Results:** The traction table significantly stabilized anteroposterior pelvic movements across
35 all critical surgical stages ($p < 0.05$), except during anterior capsular release. In contrast,
36 procedures performed on the standard table exhibited less stability in anteroposterior pelvic
37 movements, suggesting the superior performance of the traction table.

38 **Conclusions:** Compared with the standard table, the use of the traction table in total hip
39 arthroplasty effectively controls anteroposterior pelvic movements and improves acetabular
40 cup alignment. However, lateral pelvic stability remains uncontrolled using both table types,
41 indicating a need for further technological advancements in surgical practice to improve the
42 outcomes of total hip arthroplasty.

43

- 44 **Keywords:** Total hip arthroplasty; Pelvic alignment; Traction table; Acetabular cup
- 45 positioning; Augmented reality navigation; AR-HIP system

46 **1. Introduction**

47 Total hip arthroplasty (THA) substantially enhances a patient's quality of life by
48 restoring joint function [1,2]. The success of this procedure depends on various factors, with
49 precise acetabular cup positioning being of paramount importance. Proper placement
50 mitigates the risk of dislocations and reduces polyethylene wear; thus, it plays a crucial role
51 in the long-term success of THA [3]. The "safe zone" proposed by Lewinnek et al in 1978,
52 who recommended an inclination of 30–50° and anteversion of 5–25°, serves as a benchmark
53 for acetabular component orientation [4]. Nevertheless, even placement within this zone is
54 associated with dislocations [5], suggesting that the ideal zone may be narrower [6].

55 The pelvic tilt affects the alignment of the acetabular component. A previous study
56 reported a linear correlation between pelvic angle and cup anteversion, with a 1° change in
57 pelvic tilt altering anteversion by approximately 0.74°, as well as a nonlinear relationship
58 between pelvic tilt and cup inclination, with a 1° change in pelvic angle resulting in an
59 average inclination adjustment of 0.29° [7]. This highlights the importance of understanding
60 pelvic positioning during surgery to anticipate its impact on cup placement.

61 Recently, the anterior approach in the supine position has gained popularity for THA
62 [8]. This approach preserves muscle integrity, facilitates faster functional recovery, and
63 potentially reduces the length of hospital stay [9]. However, both patient factors (e.g., body
64 mass index [BMI], anatomical characteristics) and surgical factors (e.g., incision size, field of
65 view) can impede a surgeon's ability to accurately position the acetabular cup [10], and even
66 experienced surgeons may encounter numerous outliers in freehand supine THA [11].

67 Traditional surgical tables often present challenges in maintaining consistent pelvic
68 positioning during the procedure, which can compromise the accuracy of acetabular cup
69 placement. In contrast, traction tables can more effectively stabilize the pelvis, potentially
70 leading to better surgical outcomes. Furthermore, the AR-HIP system (Zimmer Biomet Japan,

71 Tokyo, Japan) is utilized to prevent acetabular cup misalignment. This portable navigation
72 device enables surgeons to use a smartphone app to align the cup based on recorded
73 landmarks and construct three-dimensional coordinates for precise placement. In this system,
74 the functional pelvic plane (FPP) is defined as a line between the direction of gravity and the
75 anterior superior iliac spine. With the AR-HIP system, surgeons can overlay the FPP onto the
76 actual operative field displayed on a smartphone, allowing for real-time monitoring and
77 adjustment of cup orientation. Pelvic movements can also be observed and assessed
78 throughout the procedure (Figure 1) [12].

79

80 **Figure 1.** (a) Registration photo: Recognition of the anatomical pelvic plane through
81 landmarks such as the bilateral anterior superior iliac spines and the pubic symphysis. The
82 functional pelvic plane is calculated using the built-in gyro sensor of the smartphone.
83 (b) Intraoperatively: The smartphone mounted on the cup handle scans a QR code placed on
84 the pelvis, displaying real-time data on cup alignment and pelvic tilt in both the
85 anteroposterior and lateral directions.

86

87 The current study aimed (1) to observe and quantify pelvic movements at various stages
88 of THA using the AR-HIP system to identify potential shifts in pelvic alignment and (2) to
89 determine the extent of improvement in pelvic alignment when a traction table is used, as
90 compared with conventional surgical tables.

91

92 **2. Materials and methods**

93 **2.1. Patients**

94 This retrospective single-center study initially included 102 hip joints treated for
95 osteoarthritis (OA) at our institution from December 2022 to February 2024. However,

96 patients with inflammatory diseases or severe deformities (Crowe types 3 and 4) and those
97 who underwent revision THA were excluded, resulting in 88 eligible hip joints. Patient
98 records were retrospectively reviewed to collect demographic data (age, sex, and BMI) and
99 other variables (operative time, perioperative and postoperative complications, and length of
100 hospital stay). Complications were defined as intraoperative fractures, postoperative fractures
101 or subsidence, dislocations, wound complications, infections, abscesses, nerve damage, or the
102 need for reoperation. The data were anonymized and stored in a secure electronic database.

103

104 ***2.2. Surgical procedure***

105 All procedures were performed by a single surgeon with 20 years of experience in
106 orthopedic surgery. The anterolateral approach was used, and the implant was selected based
107 on the surgeon's preference without alteration from standard procedures. No randomization
108 or selection of patients was performed. A total of 48 and 40 procedures were performed on a
109 standard operating table from December 2022 to March 2023 and on a traction table
110 (RotexTable®) from September 2023 to March 2024, respectively. Allocation to the standard
111 or traction table was based on the operating room's availability and the surgeon's preference.
112 No specific patient characteristics determined the choice of table, thereby minimizing
113 potential selection bias. The cup was placed to replicate the center of the contralateral
114 femoral head and was internalized until it contacted the teardrop. The stem was positioned to
115 extend the offset corresponding to the internalization of the cup, aligning the global offset
116 with the contralateral side.

117

118 ***2.3. Pelvic alignment measurement using the AR-HIP system***

119 The surgeon used the AR-HIP system, a portable navigation device, through a
120 smartphone app (AR-HIP; Zimmer Biomet, Tokyo, Japan). Specific landmarks were recorded

121 to establish three-dimensional coordinates for precise cup positioning. The FPP was defined
122 as a line between the direction of gravity and the anterior superior iliac spine. This allowed
123 for real-time visualization and adjustment of cup orientation, with pelvic movements
124 monitored and assessed throughout the procedure. The baseline for pelvic alignment was set
125 as the FPP at preoperative registration, with subsequent measurements taken after anterior
126 capsular release, femoral head resection, cup placement, and post-reduction once the
127 retractors were removed.

128 Details on the applied traction force, limb positioning on the traction table, and the
129 specific components of pelvic rotational movement measured were meticulously documented.
130 The study focused on rotations in the sagittal and transverse planes (anteroposterior and
131 lateral directions, respectively), whereas coronal plane (vertical axis) rotations were not
132 evaluated.

133

134 **2.4. Data analysis**

135 Statistical analyses included an independent sample t-test for continuous variables and the
136 chi-square test for categorical variables. Non-parametric tests (Mann–Whitney U test and
137 Fisher's exact test) were conducted as needed. Normality was assessed using the Shapiro–
138 Wilk test. Potential confounding variables such as age, BMI, and preoperative joint function
139 were evaluated and controlled for in the analysis to ensure that they did not significantly
140 affect the results. Statistical significance was set at $p < 0.05$. All tests were two-tailed. Data
141 were analyzed using SPSS version 28 (IBM Corp., Armonk, NY, USA).

142

143 **2.5. Ethical Considerations**

144 This study adhered to the principles of the Declaration of Helsinki. The need for ethics
145 approval was waived by the Medical Ethics Committee of Kanazawa University according to

146 the "Ethical Guidelines for Medical and Health Research Involving Human Subjects"
147 provided by the Ministry of Education, Culture, Sports, Science and Technology (MEXT)
148 and the Ministry of Health, Labour and Welfare (MHLW) in Japan. Written informed consent
149 was obtained from all participants. The data were accessed on 20th February, 2024 for
150 research purposes. The authors did not have access to information that could identify
151 individual participants during or after data collection. Confidentiality and anonymity were
152 ensured, and participants were informed of their right to withdraw at any time.

153

154 **3. Results**

155 **3.1. Patient demographics**

156 The demographic characteristics of the patients are summarized in Table 1. Overall, the
157 standard table group comprised 48 patients, whereas the traction table group consisted of 40
158 patients. The distributions of osteoarthritis and osteonecrosis of the femoral head were similar
159 between the groups, with 40 osteoarthritis cases and 8 osteonecrosis of the femoral head
160 cases in the standard table group and 36 osteoarthritis cases and 4 osteonecrosis of the
161 femoral head cases in the traction table group ($p=0.36$).

162

163 **Table 1.** Demographic data of patients.

Parameter	Standard table	Traction table	<i>p</i> -value
Disease (OA/ONFH)	48 (40/8)	40 (36/4)	0.36
Operative side (R/L)	28/20	21/19	0.55
Age (years)	66.0±8.9	65.2±10.3	0.73
BMI	24.1±4.1	23.5±3.7	0.51
Operative time (min)	152.5±24.3	153±24.6	0.90
Sex (female/male)	34/14	31/9	0.64

164 OA, osteoarthritis; ONFH, osteonecrosis of the femoral head; BMI, body mass index.

165

166 The two groups showed no significant difference with respect to the operative side
167 (right/left), with 28 right hips and 20 left hips in the standard table group and 21 right hips
168 and 19 left hips in the traction table group ($p=0.55$). The average patient age was 66.0 ± 8.9
169 years and 65.2 ± 10.3 years in the standard and traction table groups, respectively ($p=0.73$).
170 BMI was 24.1 ± 4.1 kg/m² and 23.5 ± 3.7 kg/m² in the standard and traction table groups,
171 respectively ($p=0.51$). The average operative time was 152.5 ± 24.3 min and 153 ± 24.6 min in
172 the standard and traction table groups, respectively ($p=0.90$). The sex distribution was also
173 similar, with 34 females and 14 males in the standard table group and 31 females and 9 males
174 in the traction table group ($p=0.64$).

175

176 **3.2. Intraoperative pelvic alignment changes**

177 **3.2.1. Without a traction table**

178 The changes in pelvic alignment in the anteroposterior direction during THA without
179 the use of a traction table are shown in Figure 2. In THA, the pelvis tilted forward by
180 $0.9\pm 1.3^\circ$ on average during anterior capsular release, $3.4\pm 0.8^\circ$ during femoral head resection,
181 $2.3\pm 0.8^\circ$ during cup placement, and $2.0\pm 0.8^\circ$ during reduction. The change averaged $0.9\pm 1.3^\circ$
182 from AR registration to anterior capsular release, $2.52\pm 1.4^\circ$ from anterior capsular release to
183 femoral head resection, $-1.1\pm 0.9^\circ$ from femoral head resection to cup placement, and -
184 $0.3\pm 0.7^\circ$ from cup placement to reduction. The greatest forward tilt occurred between the
185 anterior capsular release and femoral head resection ($p<0.05$).

186

187 **Figure 2.** (a) Pelvic tilt increased anteriorly from registration through each surgical stage,
188 with the most significant change occurring between anterior capsular release and femoral

189 head resection (mean change: $2.52 \pm 1.4^\circ$, $p < 0.05$). (b) Lateral tilt towards the operative side
190 also showed significant variation, particularly after cup placement ($p = 0.029$).

191

192 The changes in lateral pelvic alignment (operative and non-operative sides)
193 intraoperatively are shown in Figure 3. The pelvis tilted laterally towards the operative side
194 by $1.0 \pm 0.8^\circ$ on average during anterior capsular release, $1.9 \pm 1.3^\circ$ during femoral head
195 resection, $2.0 \pm 1.3^\circ$ during cup placement, and $2.8 \pm 0.7^\circ$ during reduction. Throughout the
196 procedure, the pelvis tended to tilt towards the operative side. The change averaged $1.0 \pm 0.8^\circ$
197 from AR registration to anterior capsular release, $0.8 \pm 1.3^\circ$ from anterior capsular release to
198 femoral head resection, $0.4 \pm 1.58^\circ$ from femoral head resection to cup placement, and
199 $0.8 \pm 0.9^\circ$ from cup placement to reduction. In general, the changes in lateral pelvic movement
200 were minimal. However, the variability observed during cup placement and reduction
201 suggests a greater degree of instability in the lateral direction, which could lead to potential
202 malalignment in the absence of adequate control (Figure 2).

203

204 **Figure 3.** (a) The use of a traction table significantly stabilized the anteroposterior pelvic tilt
205 across all stages of surgery ($p = 0.10$). (b) Lateral movements towards the operative side were
206 not significantly controlled ($p = 0.54$) (Figure 2).

207

208 **3.2.2. With a traction table**

209 The changes in pelvic alignment in the anteroposterior direction during THA with the
210 use of a traction table are shown in Figure 3. With the traction table, the pelvis tilted forward
211 by $0.2 \pm 1.1^\circ$ on average during anterior capsular release, $0.8 \pm 1.5^\circ$ during femoral head
212 resection, $0.3 \pm 1.2^\circ$ during cup placement, and $0.6 \pm 0.9^\circ$ during reduction. The change
213 averaged $0.2 \pm 1.1^\circ$ from AR registration to anterior capsular release, $0.5 \pm 1.4^\circ$ from anterior

214 capsular release to femoral head resection, $-0.4\pm 1.4^\circ$ from femoral head resection to cup
215 placement, and $0.2\pm 1.0^\circ$ from cup placement to reduction. The anteroposterior directional
216 changes were not statistically significant, indicating that pelvic movements were more stable
217 intraoperatively with the traction table ($p=0.10$).

218 The changes in lateral pelvic alignment at each stage of THA using a traction table are
219 also depicted in Figure 3. The pelvis tilted towards the operative side by $0.9\pm 1.0^\circ$ on average
220 during anterior capsular release, $1.6\pm 1.1^\circ$ during femoral head resection, $2.0\pm 1.2^\circ$ during cup
221 placement, and $2.3\pm 0.8^\circ$ during reduction. The pelvis consistently tilted towards the operative
222 side throughout the procedure. The change averaged $0.9\pm 1.0^\circ$ from AR registration to
223 anterior capsular release, $0.2\pm 1.5^\circ$ from anterior capsular release to femoral head resection,
224 $0.4\pm 1.5^\circ$ from femoral head resection to cup placement, and $0.4\pm 1.2^\circ$ from cup placement to
225 reduction. No significant difference in the amount of lateral movement was observed,
226 showing a gradual tilt towards the operative side throughout the procedure ($p=0.54$) (Figure
227 3).

228

229 **3.3. Standard table vs traction table**

230 Table 2 presents a comparison of the anteroposterior movements at various surgical
231 stages using the standard and traction tables, whereas Table 3 shows a comparison of the
232 lateral movements (operative and non-operative sides) at various surgical stages using the
233 standard and traction tables. In patients who underwent THA using the standard table
234 compared to those using the traction table, the traction table significantly stabilized the
235 movements in the anteroposterior direction at all surgical stages ($p<0.05$), except during
236 anterior capsular release. When comparing the lateral pelvic movements, the pelvic tilt to the
237 operative or non-operative direction at any surgical stage did not significantly differ between
238 the standard and traction table groups. This result indicated that although the traction table

239 effectively stabilized the anteroposterior pelvic movements, it did not significantly affect the
240 lateral movements during THA.

241

242 **Table 2.** Comparison of anteroposterior movements at various surgical stages using the
243 standard table and traction table.

Surgical stages	Standard table (°)	Traction table (°)	<i>p</i> -value
Anterior capsular release	0.9±1.1	0.2±1.3	0.053
Femoral head resection	3.4±0.8	0.8±1.5	<0.05
Cup placement	2.3±0.8	0.3±1.2	<0.05
Reduction	2.0±0.8	0.6±0.9	<0.05

244

245 **Table 3.** Comparison of lateral movements (operative and non-operative sides) at various
246 surgical stages using the standard table and traction table.

Surgical stages	Standard table (°)	Traction table (°)	<i>p</i> -value
Anterior capsular release	1.0±0.8	0.9±1.0	0.63
Femoral head resection	1.9±1.3	1.6±1.1	0.40
Cup placement	2.0±1.3	2.0±1.2	0.93
Reduction	2.8±0.7	2.3±0.8	0.17

247

248 **4. Discussion**

249 This study demonstrated that using a traction table significantly stabilized
250 anteroposterior pelvic movements during THA, contributing to more precise acetabular cup
251 alignment.

252

253 **4.1. Pelvic tilt and cup alignment in THA**

254 Pelvic tilt has been suggested to influence the alignment of the acetabular component in
255 THA [13]. Intraoperative pelvic alignment varies owing to manipulation during the procedure
256 and patient factors such as BMI [14,15]. An unstable pelvis intraoperatively complicates
257 precise cup placement, leading to potential malalignment, increased risk of dislocations, and
258 premature wear of the implant [3]. Our study highlights the importance of real-time
259 monitoring and stabilization of pelvic movement to ensure accurate cup placement.

260

261 ***4.2. Utilization of the traction table in THA***

262 The use of a traction table in THA allows for controlled femoral rotation and facilitates
263 exposure of the femoral bone [16]. Previous studies have reported high rates of greater
264 trochanteric fractures with the anterior approach without traction tables [17] and suggested
265 the need for additional incisions to expose the acetabulum and femur in > 3,000 cases using
266 the Heuter approach on a standard table [16]. In contrast, when a traction table was used, no
267 additional skin incisions were necessary when positioning the acetabular component [16].
268 Thus, the use of a traction table in THA simplifies the approach to the femur, potentially
269 reduces skin incisions, and minimizes the risk of muscle damage caused by forced traction.

270

271 ***4.3. Effectiveness of the traction table in THA***

272 Our study revealed that the use of the traction table stabilized the anteroposterior pelvic
273 movements intraoperatively. For every degree of anterior pelvic tilt, there is an associated
274 increase of 0.21° and 0.73° in the abduction and anteversion angles of the cup [18].
275 Therefore, stabilizing pelvic motion with a traction table can enhance postoperative cup
276 alignment.

277

278 ***4.4 Consideration of anterior pelvic tilt during osteotomy***

279

280 The anterior pelvic tilt observed during osteotomy is thought to be a phenomenon
281 caused by a combination of multiple factors, including changes in the pelvic support structure
282 and muscle tone, as well as the effects of surgical manipulation and the operating table.
283 Understanding these factors and responding appropriately intraoperatively will enable more
284 accurate acetabular cup placement and contribute to improved surgical outcomes.

285

286 ***4.5. Limitations of the traction table in THA***

287 Our findings also indicated that the traction table did not stabilize lateral pelvic
288 movement during THA. Each degree of lateral tilt towards the operative side increased the
289 abduction and anteversion angles by 0.28° and 0.63° , respectively [18]. Because the traction
290 table does not control lateral motion, there is a risk of significant malalignment in the
291 abduction and anteversion angles of the cup, leading to suboptimal placement.

292

293 ***4.6. Pelvic alignment in THA***

294 Although anteroposterior pelvic alignment can be controlled, lateral movements cannot
295 be stabilized during THA. Improper cup alignment is primarily caused by intraoperative
296 pelvic movement [19]. Therefore, it is crucial to be aware of pelvic movement
297 intraoperatively and take precautions to minimize pelvic tilting.

298 Our study elucidates how the pelvis moves intraoperatively with and without the use of
299 the traction table, and highlights the differences in pelvic dynamics between the two. Portable
300 navigation systems can track pelvic motion in real time. Without such systems, understanding
301 the dynamic changes in pelvic alignment at each surgical stage would enable more accurate
302 cup placement.

303

304 **4.7. Limitations and future research**

305 This study was limited to the use of a specific traction table, and the results for other
306 types of traction tables or surgical approaches remain unknown. The accuracy and limitations
307 of the portable navigation system used to track pelvic movements in real time have not been
308 thoroughly validated. An adequate analysis on how variables such as patients' anatomical
309 characteristics and BMI influence pelvic movements and cup alignment intraoperatively has
310 not been conducted. Although data on short-term surgical outcomes were collected, this study
311 did not include information on long-term outcomes. Thus, the relationship between
312 acetabular cup alignment, long-term functionality, and durability remains unclear. This study
313 utilized a retrospective design; prospective studies or randomized controlled trials are
314 necessary. Future studies should address these limitations and involve a more diverse patient
315 population and a range of surgical approaches. In addition, the development of new
316 technologies and surgical instruments to control pelvic movements more precisely is critical.

318 **4.8. Conclusions**

319 This study examined pelvic motion during THA and the impact on precise acetabular
320 cup alignment. Specifically, it focused on the differences in pelvic movements when using a
321 standard table versus a traction table and how these affected the surgical outcomes. The
322 results confirmed that the use of a traction table clearly controlled the anteroposterior pelvic
323 movements, contributing to accurate acetabular cup alignment. This underscores the
324 importance of pelvic stability intraoperatively, which is essential for the success of THA,
325 particularly for proper acetabular cup placement. However, lateral pelvic movements are not
326 controlled by the traction table, leaving room for further research and technological
327 development.

328

329 **Data Availability Statement**

330 The datasets used and/or analyzed during the current study are available from the
331 corresponding author on reasonable request.

332

333 **Acknowledgements**

334 None.

335

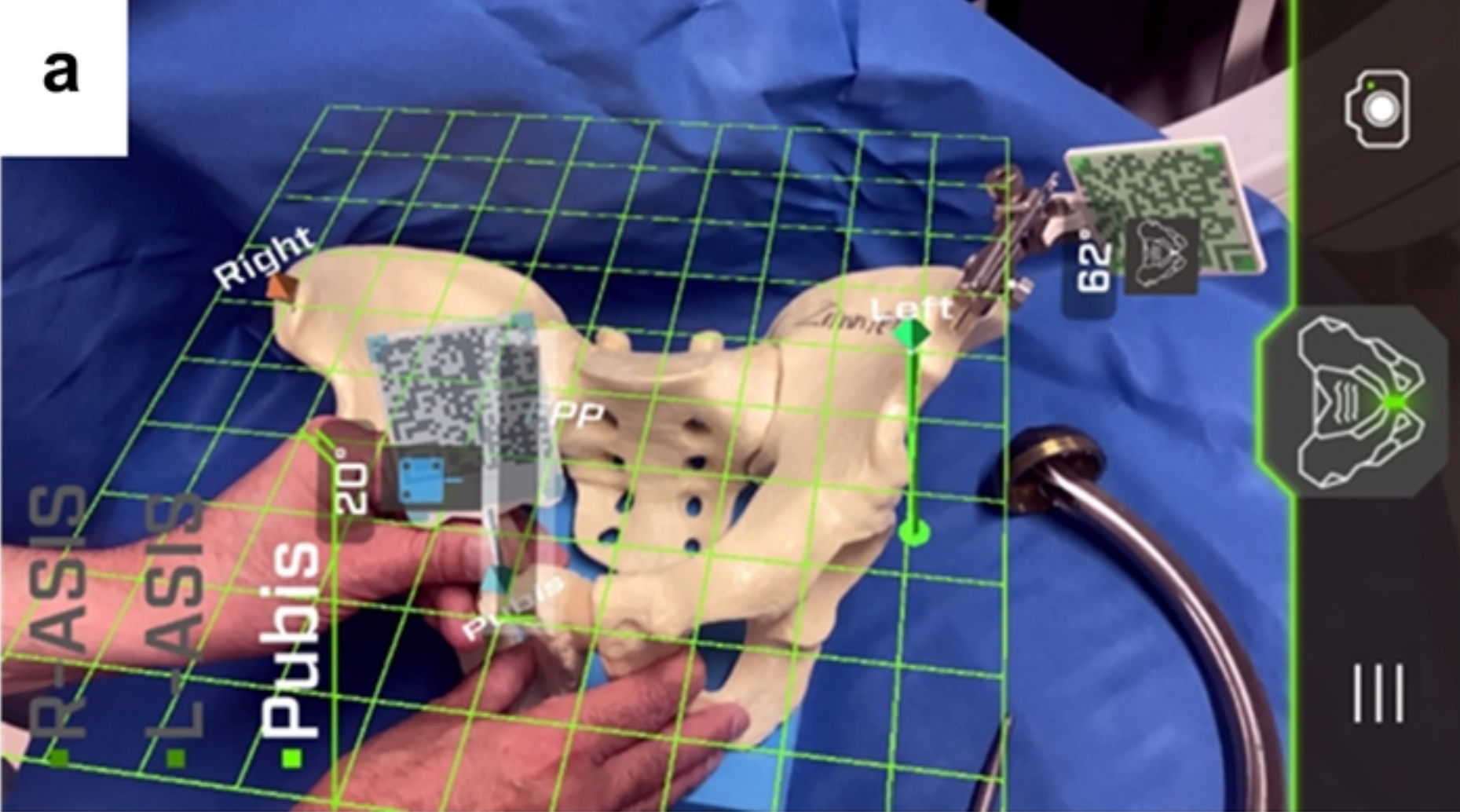
336 **References**

- 337 1. Kumar P, Sen RK, Aggarwal S, Jindal K, Rajnish RK. Assessment and reliability of the
338 World Health Organisation quality of life (WHO QOL-BREF) questionnaire in total hip
339 replacement patients. *J Clin Orthop Trauma*. 2020;11(Suppl 5): S756-S759. doi:
340 [10.1016/j.jcot.2020.07.020](https://doi.org/10.1016/j.jcot.2020.07.020), PubMed PMID: [32837104](https://pubmed.ncbi.nlm.nih.gov/32837104/).
- 341 2. Kolundžić R, Trkulja V, Orlić D. History and factors of survival of total hip
342 arthroplasty. *Med Glas (Zenica)*. 2012;9: 136-142. PubMed PMID: [22634928](https://pubmed.ncbi.nlm.nih.gov/22634928/).
- 343 3. Burger D, Nowakowski AM. Massive Eccentric Wear of the acetabular Cup after
344 polyethylene Liner Abrasion in Hip Arthroplasty may lead to a high risk of Injury
345 during Revision Surgery. *J Orthop Case Rep*. 2021;11: 75-78. doi:
346 [10.13107/jocr.2021.v11.i03.2096](https://doi.org/10.13107/jocr.2021.v11.i03.2096), PubMed PMID: [34239834](https://pubmed.ncbi.nlm.nih.gov/34239834/).
- 347 4. Lewinnek GE, Lewis JL, Tarr R, Compere CL, Zimmerman JR. Dislocations after total
348 hip-replacement arthroplasties. *J Bone Joint Surg Am*. 1978;60: 217-220. doi:
349 [10.2106/00004623-197860020-00014](https://doi.org/10.2106/00004623-197860020-00014), PubMed PMID: [641088](https://pubmed.ncbi.nlm.nih.gov/641088/).
- 350 5. Widmer KH. The impingement-free, prosthesis-specific, and anatomy-adjusted
351 combined target zone for component positioning in THA depends on design and
352 implantation parameters of both components. *Clin Orthop Relat Res*. Karl: Heinz.

- 353 2020;478: 1904-1918. doi: 10.1097/CORR.0000000000001233, PubMed PMID:
354 [32732575](#).
- 355 6. Ohmori T, Kabata T, Kajino Y, Inoue D, Taga T, Yamamoto T, et al. The optimal
356 combined anteversion pattern to achieve a favorable impingement-free angle in total
357 hip arthroplasty. *J Orthop Sci.* 2019;24: 474-481. doi: 10.1016/j.jos.2018.11.008. [Epub
358 2018 December 13]. PubMed PMID: [30554937](#).
- 359 7. Maratt JD, Esposito CI, McLawhorn AS, Jerabek SA, Padgett DE, Mayman DJ. Pelvic
360 tilt in patients undergoing total hip arthroplasty: When does it matter? *J Arthroplasty.*
361 2015;30: 387-391. doi: 10.1016/j.arth.2014.10.014. [Epub 2014 October 23]. PubMed
362 PMID: [25453626](#).
- 363 8. Nairn L, Gyemi L, Gouveia K, Ekhtiari S, Khanna V. The learning curve for the direct
364 anterior total hip arthroplasty: A systematic review. *Int Orthop.* 2021;45: 1971-1982.
365 doi: 10.1007/s00264-021-04986-7. [Epub 2021 February 24]. PubMed PMID:
366 [33629172](#).
- 367 9. Jelsma J, Pijnenburg R, Boons HW, Eggen PJMG, Kleijn LLA, Lacroix H, et al.
368 Limited benefits of the direct anterior approach in primary hip arthroplasty: A
369 prospective single centre cohort study. *J Orthop.* 2017;14: 53-58. doi:
370 [10.1016/j.jor.2016.10.025](#), PubMed PMID: 27822002.
- 371 10. Foissey C, Batailler C, Fary C, Luceri F, Servien E, Lustig S. Transitioning the total hip
372 arthroplasty technique from posterior approach in lateral position to direct anterior
373 approach in supine position-risk factors for acetabular malpositioning and the learning
374 curve. *Int Orthop.* 2020;44: 1669-1676. doi: 10.1007/s00264-020-04583-0. [Epub 2020
375 May 11]. PubMed PMID: [32393990](#).
- 376 11. Maeda Y, Sugano N, Nakamura N, Hamawaki M. The accuracy of a mechanical cup
377 alignment guide in total hip arthroplasty (THA) through direct anterior and posterior

- 378 approaches measured with CT-based navigation. J Arthroplasty. 2015;30: 1561-1564.
379 doi: [10.1016/j.arth.2015.04.011](https://doi.org/10.1016/j.arth.2015.04.011). [Epub 2015 April 11]. PubMed PMID: [25913560](https://pubmed.ncbi.nlm.nih.gov/25913560/).
- 380 12. Ogawa H, Kurosaka K, Sato A, Hirasawa N, Matsubara M, Tsukada S. Does an
381 augmented reality-based portable navigation system improve the accuracy of acetabular
382 component orientation during THA? A randomized controlled trial. Clin Orthop Relat
383 Res. 2020;478: 935-943. doi: [10.1097/CORR.0000000000001083](https://doi.org/10.1097/CORR.0000000000001083), PubMed PMID:
384 [31834164](https://pubmed.ncbi.nlm.nih.gov/31834164/).
- 385 13. Kalteis TA, Handel M, Herbst B, Grifka J, Renkawitz T. In vitro investigation of the
386 influence of pelvic tilt on acetabular cup alignment. J Arthroplasty. 2009;24: 152-157.
387 doi: [10.1016/j.arth.2007.12.014](https://doi.org/10.1016/j.arth.2007.12.014), PubMed PMID: [18977116](https://pubmed.ncbi.nlm.nih.gov/18977116/).
- 388 14. Okamoto M, Kawasaki M, Okura T, Seki T, Imagama S. Effects of body mass index
389 and range of motion on intraoperative change in pelvic tilt during total hip arthroplasty
390 using the direct anterior approach. BMC Musculoskelet Disord. 2021;22: 240. doi:
391 [10.1186/s12891-021-04087-x](https://doi.org/10.1186/s12891-021-04087-x), PubMed PMID: [33653316](https://pubmed.ncbi.nlm.nih.gov/33653316/).
- 392 15. Mouri K, Madachi A, Karita T. Intraoperative pelvic tilt and axial rotation during total
393 hip arthroplasty through the direct anterior approach is affected by the acetabular
394 retractor and cup impactor. Arthroplast Today. 2023;24:101251. Published online Nov
395 6:101251: 101251. doi: [10.1016/j.artd.2023.101251](https://doi.org/10.1016/j.artd.2023.101251), PubMed PMID: [38023653](https://pubmed.ncbi.nlm.nih.gov/38023653/).
- 396 16. Matta JM, Shahrदार C, Ferguson T. Single-incision anterior approach for total hip
397 arthroplasty on an orthopaedic table. Clin Orthop Relat Res. 2005;441: 115-124. doi:
398 [10.1097/01.blo.0000194309.70518.cb](https://doi.org/10.1097/01.blo.0000194309.70518.cb), PubMed PMID: [16330993](https://pubmed.ncbi.nlm.nih.gov/16330993/)() :p 115-124,
399 December 2005. | DOI: [10.1097/01.blo.0000194309.70518.cb](https://doi.org/10.1097/01.blo.0000194309.70518.cb) Matta et al.
- 400 17. De Geest T, Vansintjan P, De Loore G. Direct anterior total hip arthroplasty:
401 Complications and early outcome in a series of 300 cases. Acta Orthop Belg. 2013;79:
402 166-173. PubMed PMID: [23821968](https://pubmed.ncbi.nlm.nih.gov/23821968/).

- 403 18. Asai H, Takegami Y, Seki T, Ishiguro N. Pelvic tilt reduces the accuracy of acetabular
404 component placement when using a portable navigation system: An in vitro study.
405 *Arthroplast Today*. 2021;7: 177-181. doi: 10.1016/j.artd.2020.12.012, PubMed PMID:
406 [33553546](#).
- 407 19. Grammatopoulos G, Pandit HG, da Assunção R, Taylor A, McLardy-Smith P, De Smet
408 KA, et al. Pelvic position and movement during hip replacement. *Bone Joint J*.
409 2014;96–B: 876-883. doi: 10.1302/0301-620X.96B7.32107, PubMed PMID:
410 [24986939](#).
- 411



medRxiv preprint doi: <https://doi.org/10.1101/2024.09.21.24314140>; this version posted September 23, 2024. The copyright holder for this preprint (which was not certified by peer review) is the author/funder, who has granted medRxiv a license to display the preprint in perpetuity. It is made available under a [CC-BY 4.0 International license](https://creativecommons.org/licenses/by/4.0/).

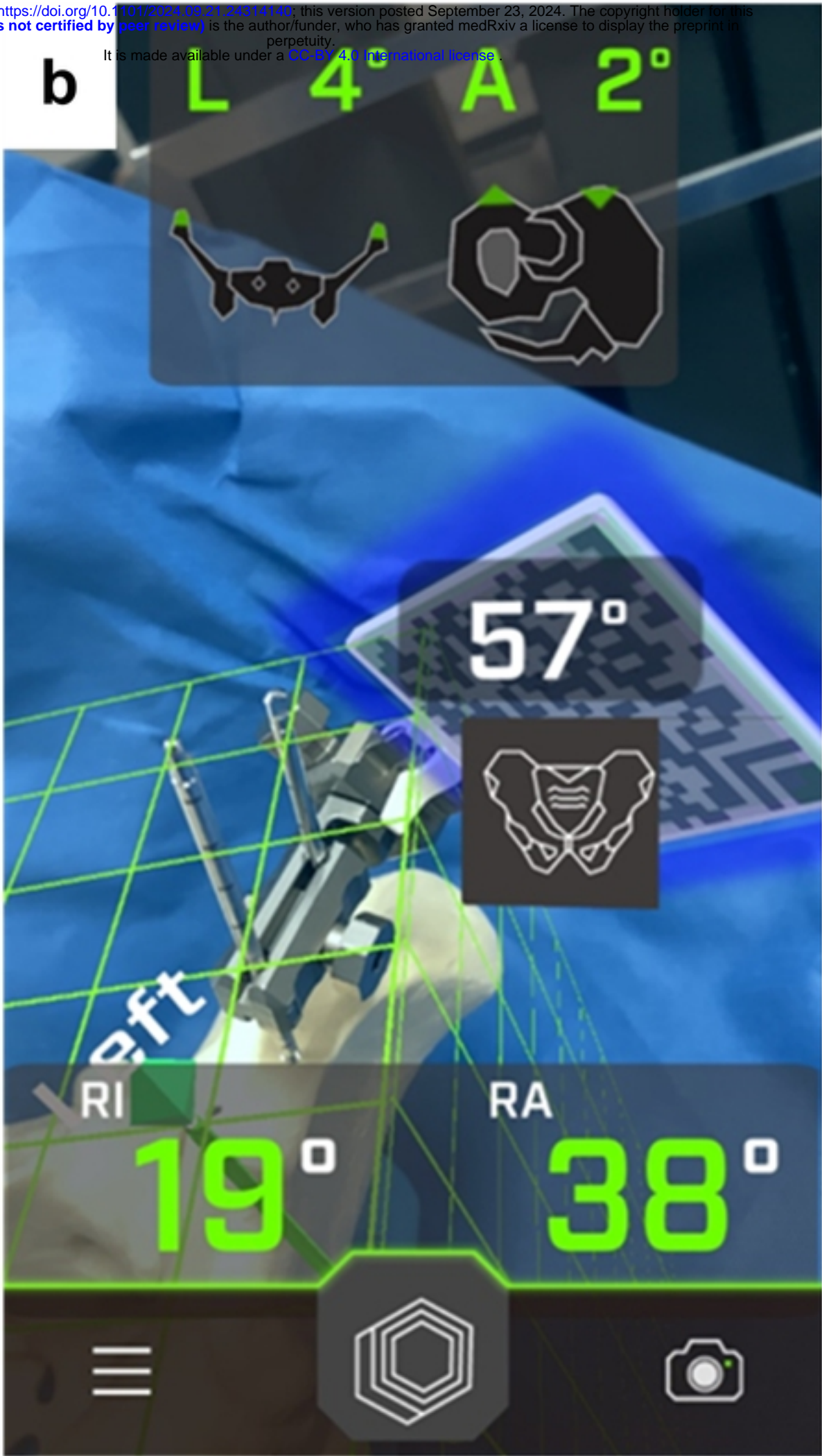
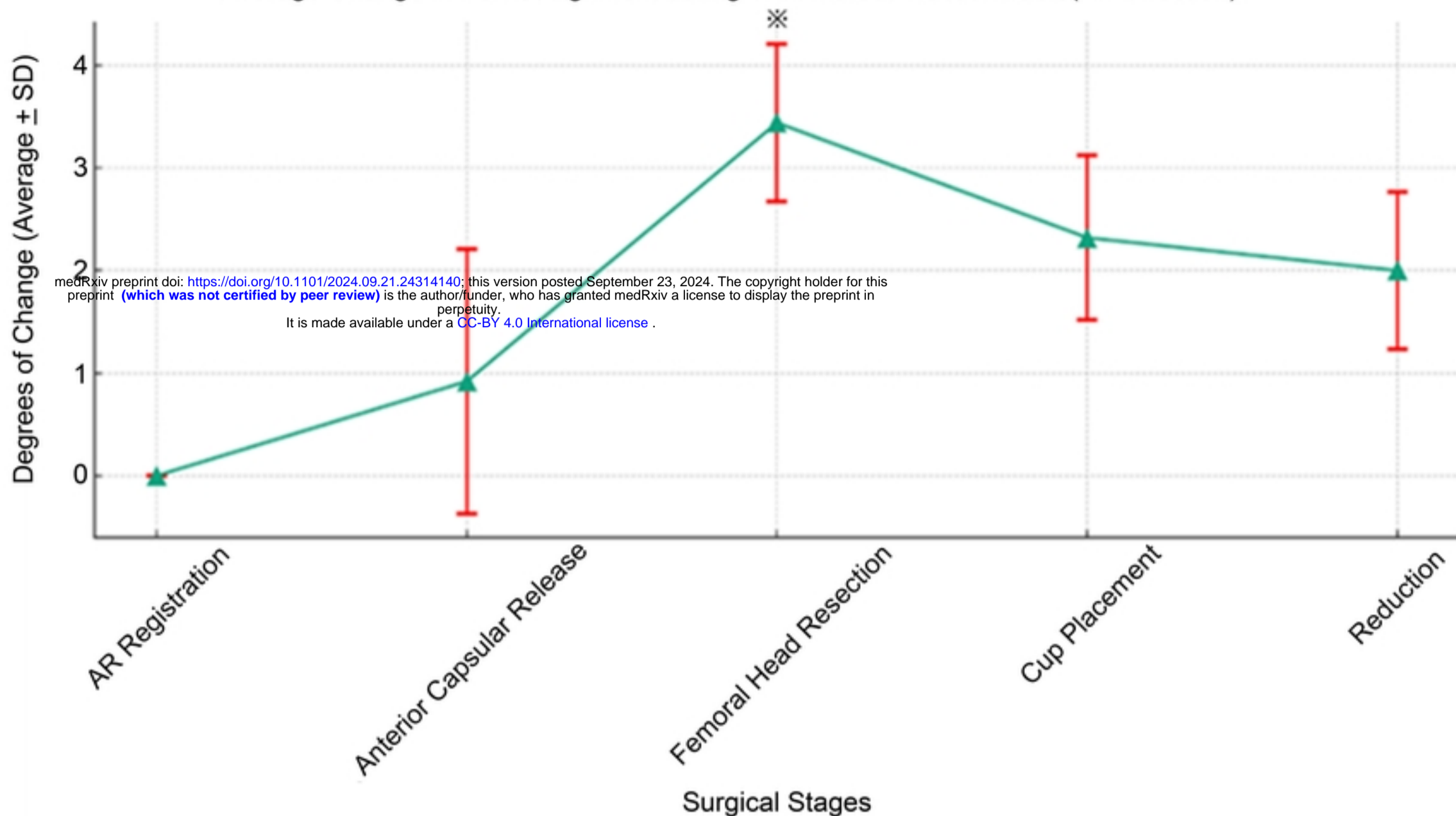


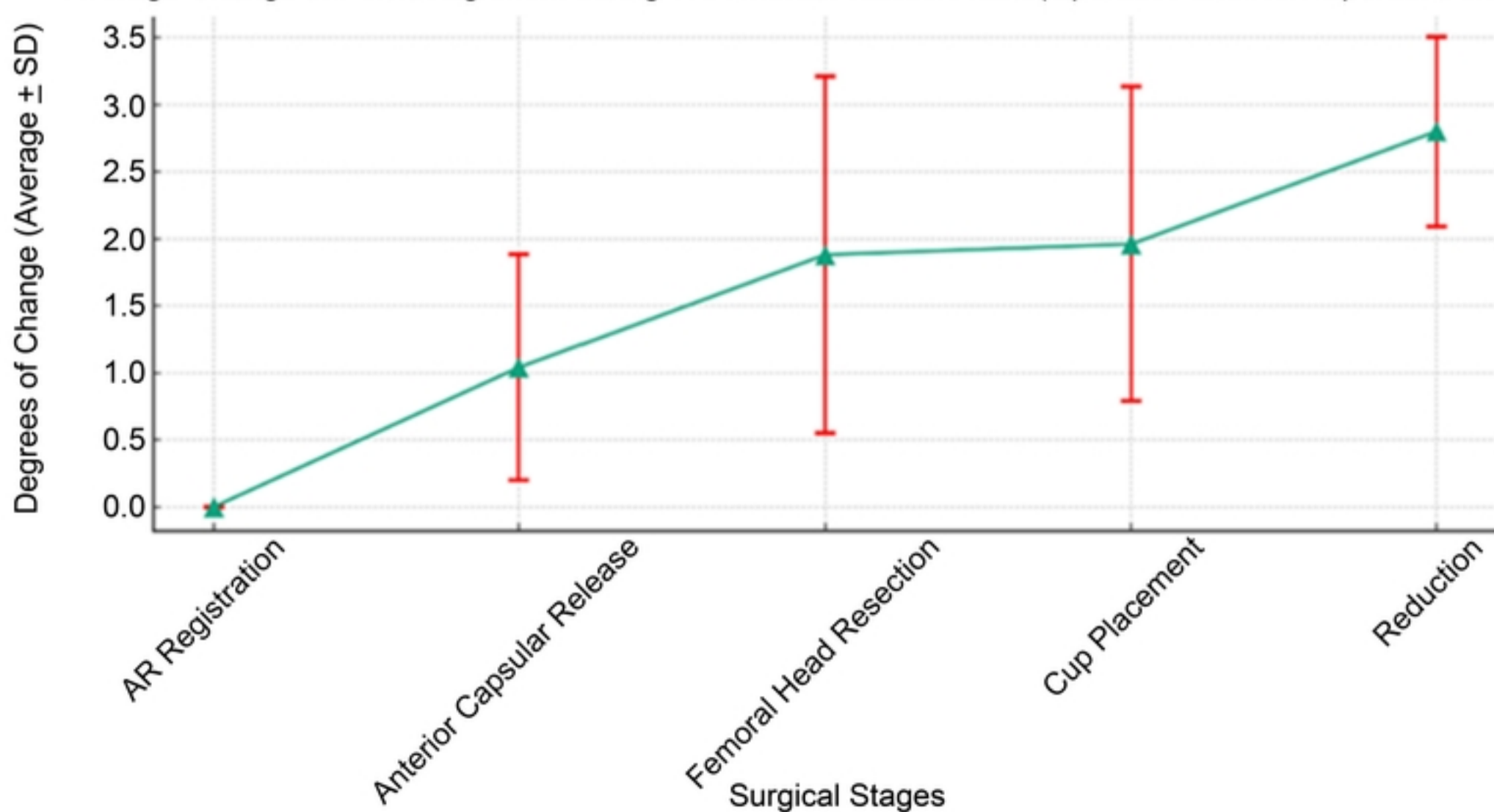
Figure 1

a

Average Change in Pelvic Alignment during THA without Traction Table(AP Direction)

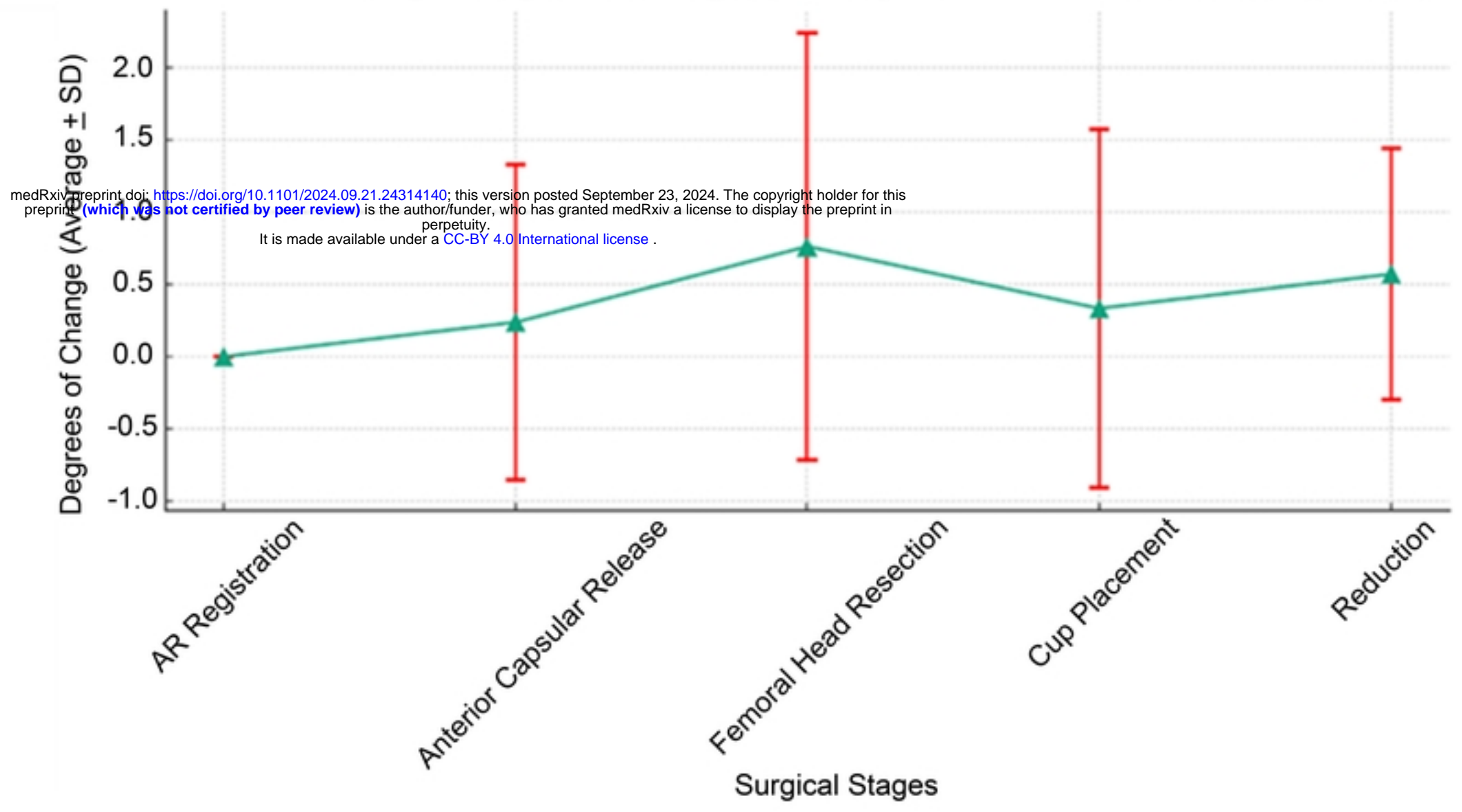
**b**

Average Change in Pelvic Alignment during THA without Traction Table(Operative and Non-Operative side)

**Figure 2**

a

Average Change in Pelvic Alignment during THA without Traction Table(AP Direction)

**b**

Average Change in Pelvic Alignment during THA without Traction Table(Operative and Non-Operative side)

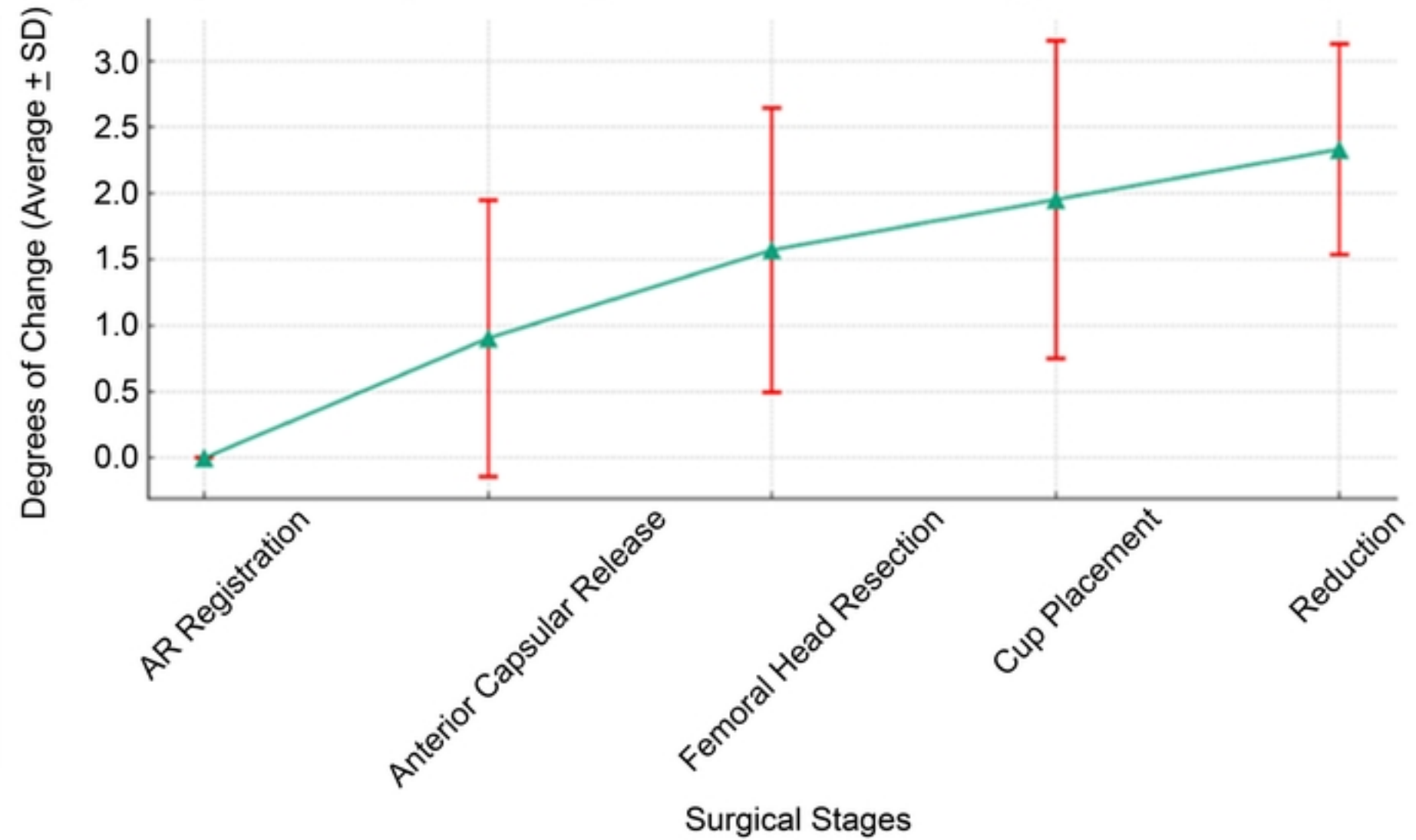


Figure 3