

1 **Developing a virtual Endoscopic Surgery Planning system to optimize surgical outcomes**

2

3 Short title: Virtual Endoscopic Surgery Simulator

4

5 Bradley Hittle¹, B.S, Ahmad Odeh², B.S., Guillermo Maza², M.D., Brenda Shen², M.D., Bradley
6 A Otto², M.D., Don Stredney³, M.S., Gregory J. Wiet^{2,4}, M.D., Kai Zhao^{2*}, PhD.

7

8 ¹The Department of Biomedical Informatics, The Ohio State University Wexner Medical Center,
9 Columbus, OH

10 ²Department of Otolaryngology - Head & Neck Surgery, The Ohio State University, Columbus,
11 OH

12 ³The Interface lab, The Ohio State University, Columbus, OH

13 ⁴Department of Otolaryngology, Nationwide Children's Hospital, Columbus, OH

14

15 *Corresponding author. E-mail: zhao.1949@osu.edu

16

17 **Funding:** NIH-NIDCD R21 DC017530 and R01 DC020302 to KZ

18 **Level of evidence:** Technology development.

19

20 The authors declare no conflict of interests.

21 **Keywords:** functional endoscopic sinus surgery; FESS; olfactory epithelium; olfactory cleft;
22 chronic rhinosinusitis; nasal polyps; hyposmia; anosmia

23

24

25

26 **Abstract**

27 **Objective**

28 Planning and predicting functional outcomes of endoscopic sinus surgeries (e.g., nasal
29 airflow) based solely on visualizing Computerized Tomography (CT) or endoscopy poses a
30 challenge to produce optimal clinical outcomes.

31 **Study design:** Technology development, retrospective case report.

32 **Methods**

33 A virtual surgery planning (VSP) tool is developed that can load any patient's CT data and
34 allow surgeons to remove obstructive tissue using both visual and haptic feedback
35 endoscopically. Pre-calculated airflow resistance, wall shear stress, pressure drop are displayed
36 on the anatomy to identify potential sites of obstruction. After each virtual surgery, changes in
37 nasal airflow can be computed, and the process is reiterated until an optimal result is reached.

38 **Results**

39 As proof-of-concept, a series of isolated or combined procedures were performed on CT
40 of one patient, who had olfactory losses that may involve obstructions blocking the air/odor flow
41 to the olfactory fossa (OF). For this patient, an isolated medial partial middle turbinectomy (PMT)
42 demonstrated the best outcome, better than traditionally performed lateral PMT, while septal
43 body reduction worsened air/odor flow to OF.

44 **Conclusion**

45 This proof of concept case report demonstrates the potential usefulness of VSP in
46 preoperative planning based on objective benchmarks and could be a valuable tool for
47 optimizing future surgical outcomes.

48

49 **Keywords:** functional endoscopic sinus surgery; FESS; olfactory epithelium; olfactory cleft;
50 chronic rhinosinusitis; nasal polyps; hyposmia; anosmia

51

52 **Research Letter**

53 **Introduction**

54 Endoscopic nasal sinus surgery, pioneered by Messerklinger and further advanced by
55 Stammberger and Kennedy¹, has been the procedure of choice for the treatment of nasal
56 obstruction and sinus disease, with an estimated 600,000 surgeries performed in the US every
57 year² alone. Nasal endoscopy provides landmark visualization and navigation for small
58 instruments to operate within the nasal airway and sinuses. However, outcomes of these
59 surgeries are highly variable, from short-term favorable outcomes of 60-90% to long-term
60 outcomes as low as 30%^{3,4}, potentially due to fact that planning and predicting functional
61 outcomes (e.g., airflow) of endoscopic sinus surgeries can be difficult or deceptive based solely
62 on visualizing Computerized Tomography (CT) or endoscopic images.

63 Virtual surgery planning (VSP) has been widely used in many other surgical fields that
64 allows the surgeon to virtually plan the surgery to optimize surgical outcomes. Since previous
65 endoscopic sinus surgery simulators⁵⁻¹⁴ mostly serve as surgical skill-training tools, we thus
66 assembled an interdisciplinary team of engineers, computational scientists, and clinicians to
67 develop an endoscopic sinus VSP system that utilizes state of the art computer graphics and 3D
68 modeling that creates a desktop virtual environment to provide a prospective, preoperative guide
69 that can optimize and improve surgical outcomes.

70
71 **Methods**

72 The prototype comprises three distinct but synergistic components—a volume renderer to
73 provide 3D endoscopic visualization based on patient’s clinical computerized tomography (CT)
74 imaging; a haptic endoscopy tool to navigate and perform the virtual surgery; and the
75 computational fluid dynamic (CFD) system to predict the nasal airflow outcome. The simulator
76 runs on a desktop workstation, using an Intel Xeon E5-1650 v3 processor, 32GB of RAM, and
77 an NVIDIA Quadro P5000 graphics card. The rendering system uses CUDA for Direct Volume
78 Rendering (DVR) and OpenGL version 4.0 for graphics rendering that requires little to no
79 preprocessing of CT data, no manual image segmentation, has fast frame rates and is extremely
80 efficient.

81 A haptic device (PHANTOM, SensAble Technologies, Inc., Woburn, MA) that can apply
82 forces in three degrees of freedoms, provides interaction between virtual endoscopic tools and

83 the 3D CT-based volumetric model during virtual surgery. A virtual camera is attached to the
84 endoscope tool, and the angle and distance of the tool tip can be adjusted, while the camera view
85 is updated as the virtual endoscope navigates the nasal airway. The combination of 3D visual
86 rendering and the haptic feedback allows the surgeon to remove the virtual obstructive tissue
87 similar to in endoscopic surgery.

88 **Results**

89 The developed virtual surgery planning (VSP) tool can load any patient's CT in DICOM
90 format in real-time from various sources, e.g. cone beam CTs or conventional axial spiral CTs,
91 and provide a highly detailed 3D visual display of the nasal sinus airway (see Fig 1 and
92 Supplementary method). The ability to directly load versatile DICOM-format clinical CT images
93 without pre-processing is the key to allow this simulator to be utilized widely in clinical settings.
94 Using a standard mouse input device, the user can orient the patient's face/sinus anatomy in any
95 direction. Pre-calculated airflow resistance, wall shear stress, pressure drop are displayed on the
96 anatomy to identify potential sites of obstruction. In figure 1, a microdebrider was selected as the
97 endoscopic tool, with available tool selections to be expanded in future software versions. The
98 size of the microdebrider can be virtually adjusted. To ease operation, the surgical tool and
99 camera are combined into a single haptic device, so that the surgeon can operate with one hand
100 and toggle between different tools such as the endoscope and the microdebrider using buttons on
101 the haptic device that are easily accessible by the user's index finger. CT image guidance is also
102 supported so that the surgeon can visualize the real-time tool tip location on 3 orthogonal CT
103 slices on the side panels, mimicking the operating room (OR) experience¹⁵. Virtual surgeries can
104 be saved intermittently ("mini save" button) or undone ("restore volume" button) to allow for
105 easy planning with multiple surgical options. By restoring and saving multiple versions of
106 different surgical approaches, different outcomes on a single patient can be compared and the
107 process is reiterated until an optimal result is reached.

108 As proof-of-concept, we performed a series of isolated or combined procedures on one
109 patient, who had nasal valve collapse, septal body hypertrophy, and a middle concha bullosa, and
110 confirmed unilateral olfactory loss only to the left side (PEA threshold: left = 5, right = 9.3,
111 normative range: ≥ 8) that may involve obstructions blocking the air/odor flow to the olfactory
112 fossa (OF). Before virtual surgery, this patient's computed area-averaged PEA absorption flux to
113 OF on the left side was significantly below the normal range (Fig 2e) that was established from

114 22 healthy controls collected from a prior study¹⁶, confirming the likely obstruction-driven
115 olfactory loss, whereas the patient's right pre-surgery olfactory PEA flux was within the normal
116 range. Based on VSP, an isolated medial partial middle turbinectomy (PMT) demonstrated the
117 best outcome, better than traditionally performed lateral PMT, while septal body reduction
118 worsened air/odor flow to OF.

119

120 **Discussion**

121 This proof of concept trial demonstrates the potential usefulness of VSP in preoperative
122 planning based on objective benchmarks and could be a valuable tool for optimizing future
123 surgical outcomes. In contrast to previous systems which emphasize training⁵⁻¹⁴, the current VSP
124 emphasizes on surgical planning. The endoscope environment and haptic feedback only serve as
125 an intuitive interface for experienced surgeons to remove obstructive tissue and plan for surgery
126 in a familiar and more effective way than say on CT scan or using a keyboard and mouse. The
127 integration of an intuitive interface, ability to easily load patient image data, with clinically
128 relevant outcome data (CFD) are significant advancements over previous attempts of sinus
129 surgical planning simulators¹⁷. Such a well-implemented planning tool is likely to have a higher
130 transfer rate to the OR for practicing surgeons and broader clinical impact than those only for
131 surgical training purposes. Finally, the optimized surgical plans can potentially be translated into
132 a CT scan (see Fig 1) and loaded into image guidance systems in ORs to guide the surgeon
133 during surgery, which may complete the full circle of personalized medicine: from planning,
134 optimizing, and to the operating room.

135

136 **Figure Captions**

137

138 **Figure 1. (a) & (b)** Screen shots of nasal sinus VSP simulator with CT image guidance panels,
139 shown with and without microdebrider selection (c) A surgeon operates the sinus surgery
140 simulator. (d-g) Endoscopic view in the simulator at various anatomic landmarks within a
141 patient's nasal cavity. Colors indicate CFD-simulated air pressure during restful breathing (h).

142

143 **Figure 2.** View of (a) septal body volume reduction (SBVR) and (b) nasal valvuloplasty virtual
144 surgeries on patient #1 with unilateral nasal obstruction and olfactory loss (left side). (c) Pre- and

145 post-virtual surgery CTs of various procedures. **Arrows** point to surgical sites. **(d, e)** Simulated
146 **(d)** pre- and **(e)** post-virtual surgery airflow patterns in the left nasal airway. **Arrows** point to
147 most significant air flow pattern changes. Among the various procedures performed, medial
148 middle turbinate reduction and nasal valve expansion were more effective in directing airflow to
149 the olfactory fossa (solid red shaded area). **(e)** Computed area-averaged phenyl ethyl alcohol
150 (PEA: a rosy odor) absorption flux in the olfactory fossa pre- and post- virtual surgeries. An
151 isolated medial aspect partial middle turbinectomy (Medial Mid-Turb) showed the best outcome,
152 and it was better than traditionally performed lateral Mid-Turb, while septal body reduction
153 worsened air/odor flow to OF. Surprisingly, surgery to the nasal valve also leads to good
154 outcome. Before virtual surgery, the left olfactory PEA absorption flux is significantly below
155 that of healthy controls (n=22), confirming the obstruction-related loss.

156
157

158 **Acknowledgements:** We acknowledge Bhakthi Deshpande, Chengyu Li and Zhenxing Wu of
159 the Department of Otolaryngology - Head & Neck Surgery, the Ohio State University, for their
160 assistance in patient testing as well as in CFD simulations.

161

162 **Author contributions:**

163 Conceptualization, Methodology, Project administration, Supervision, Funding
164 acquisition: KZ, GJW, DS

165 Investigation: BH,GM, AO, BS, BAO, DS, GJW, KZ

166 Visualization: GM, BH, AO, BS, KZ

167 Writing – original draft: KZ

168 Writing – review & editing: KZ, AO, GM, BH, GJW

169 **Competing interests:** Authors declare that they have no competing interests.

170 **Data and materials availability:** All data, code, and materials used in the analysis are
171 available to any researcher for purposes of reproducing or extending the analysis via
172 institutional materials transfer agreements (MTAs).

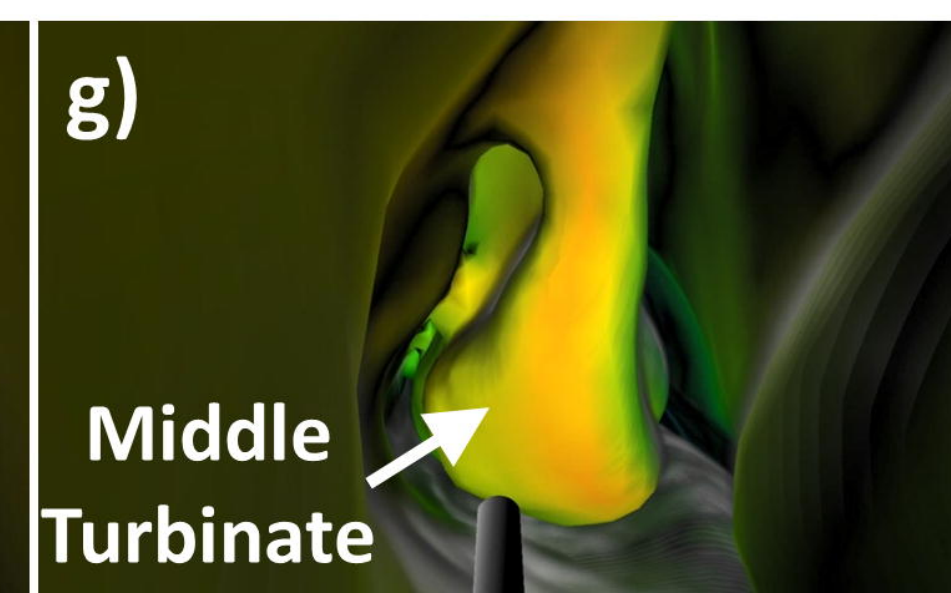
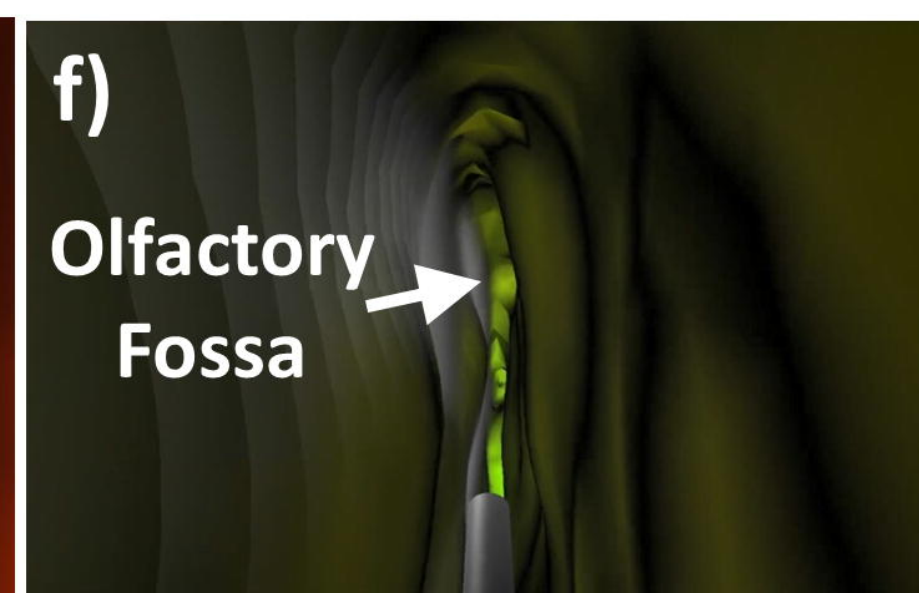
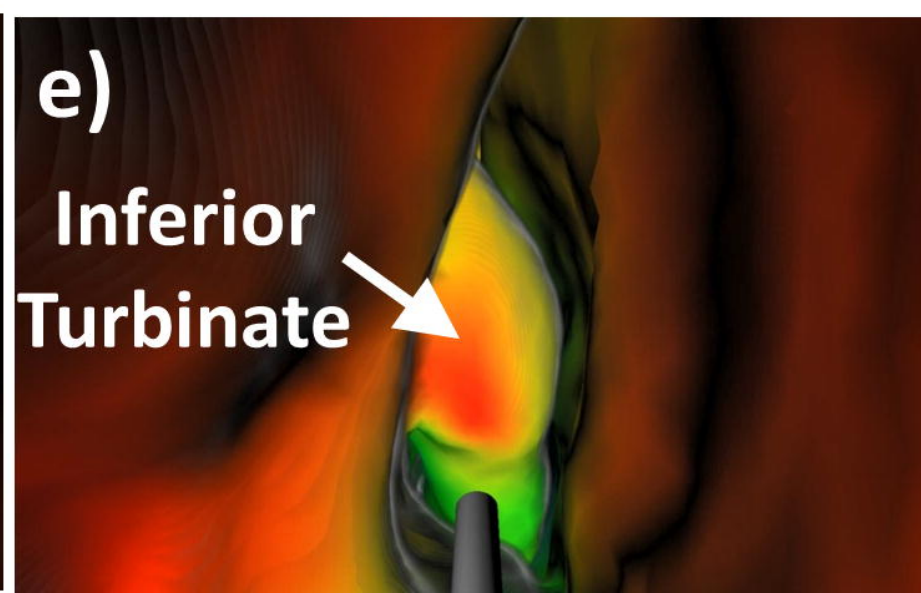
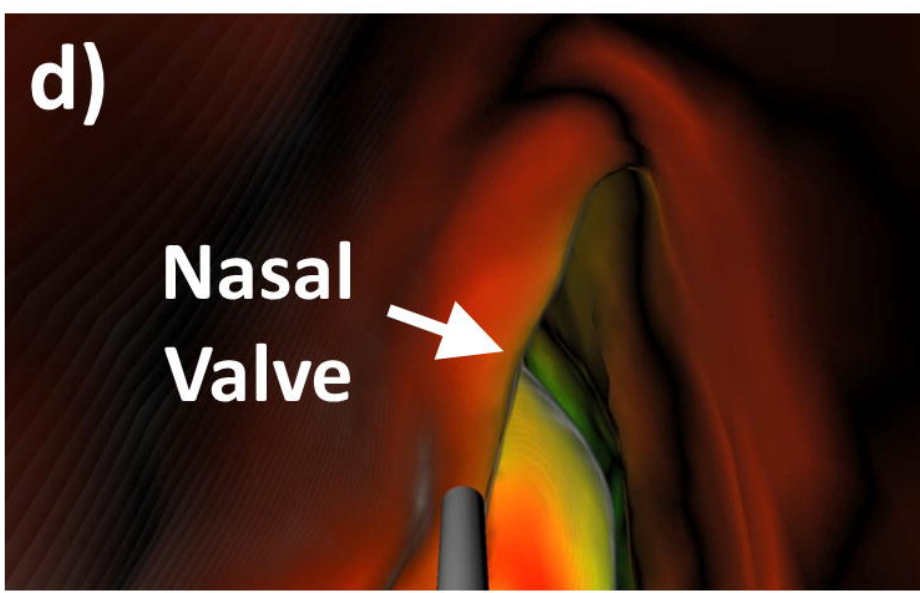
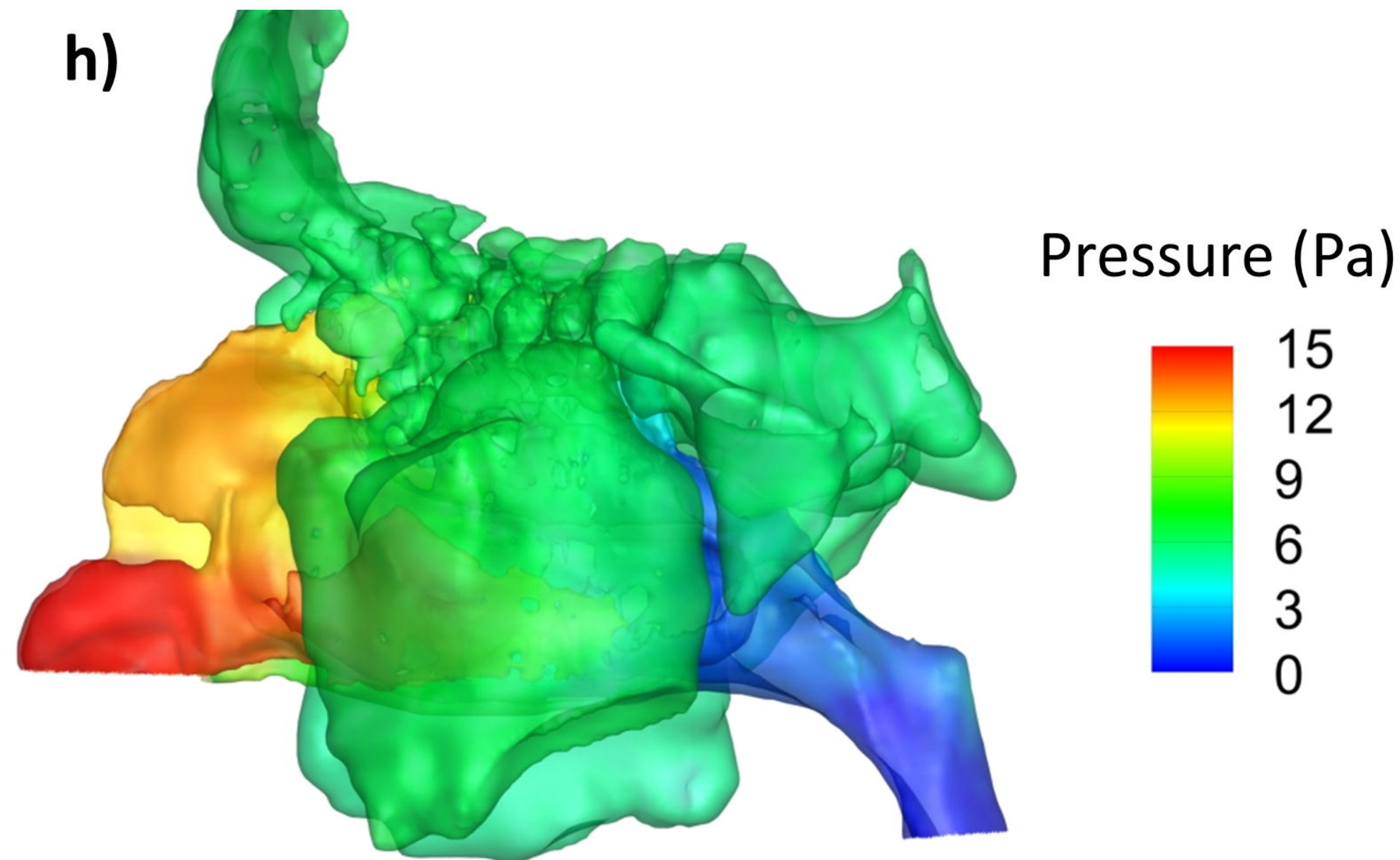
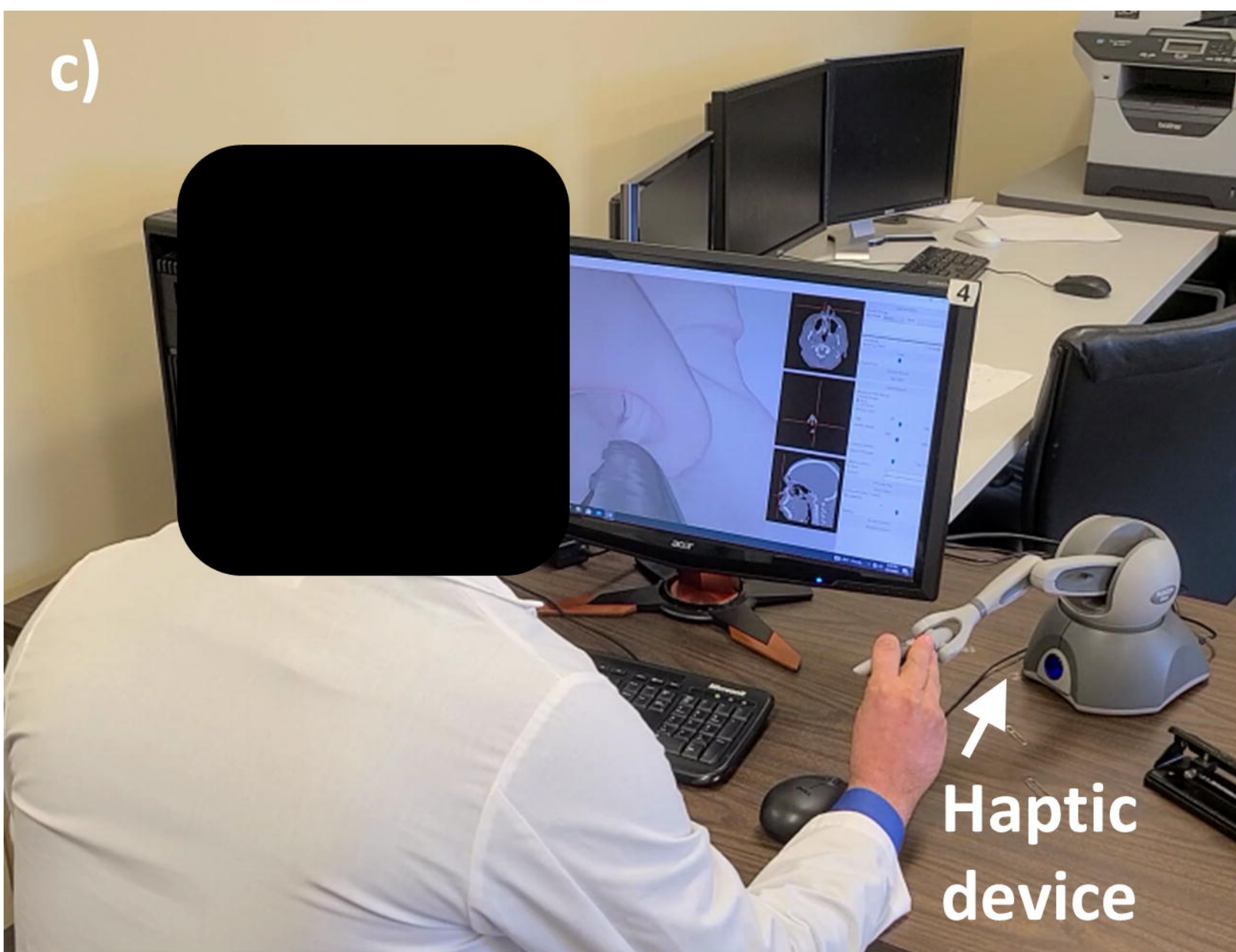
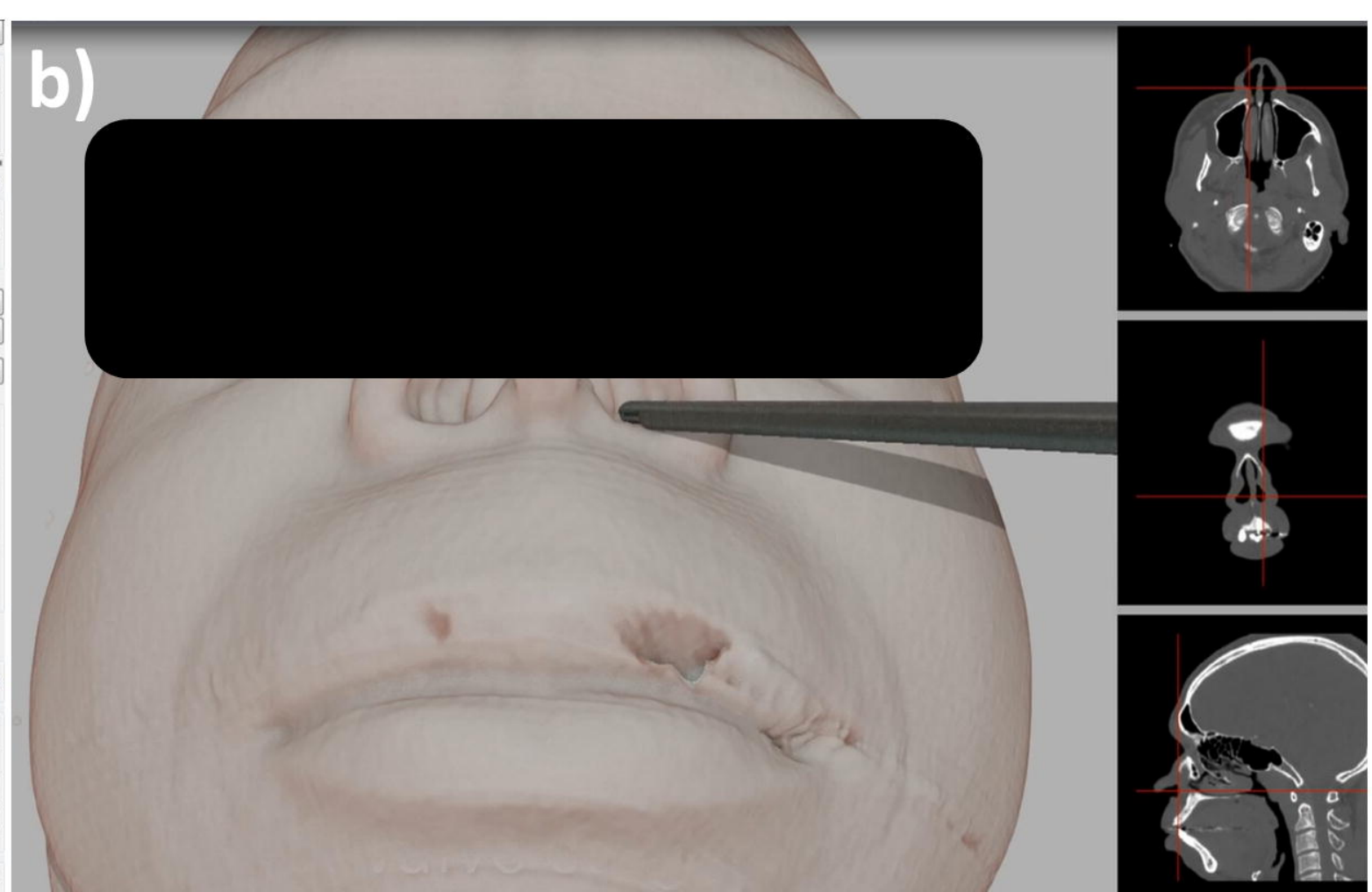
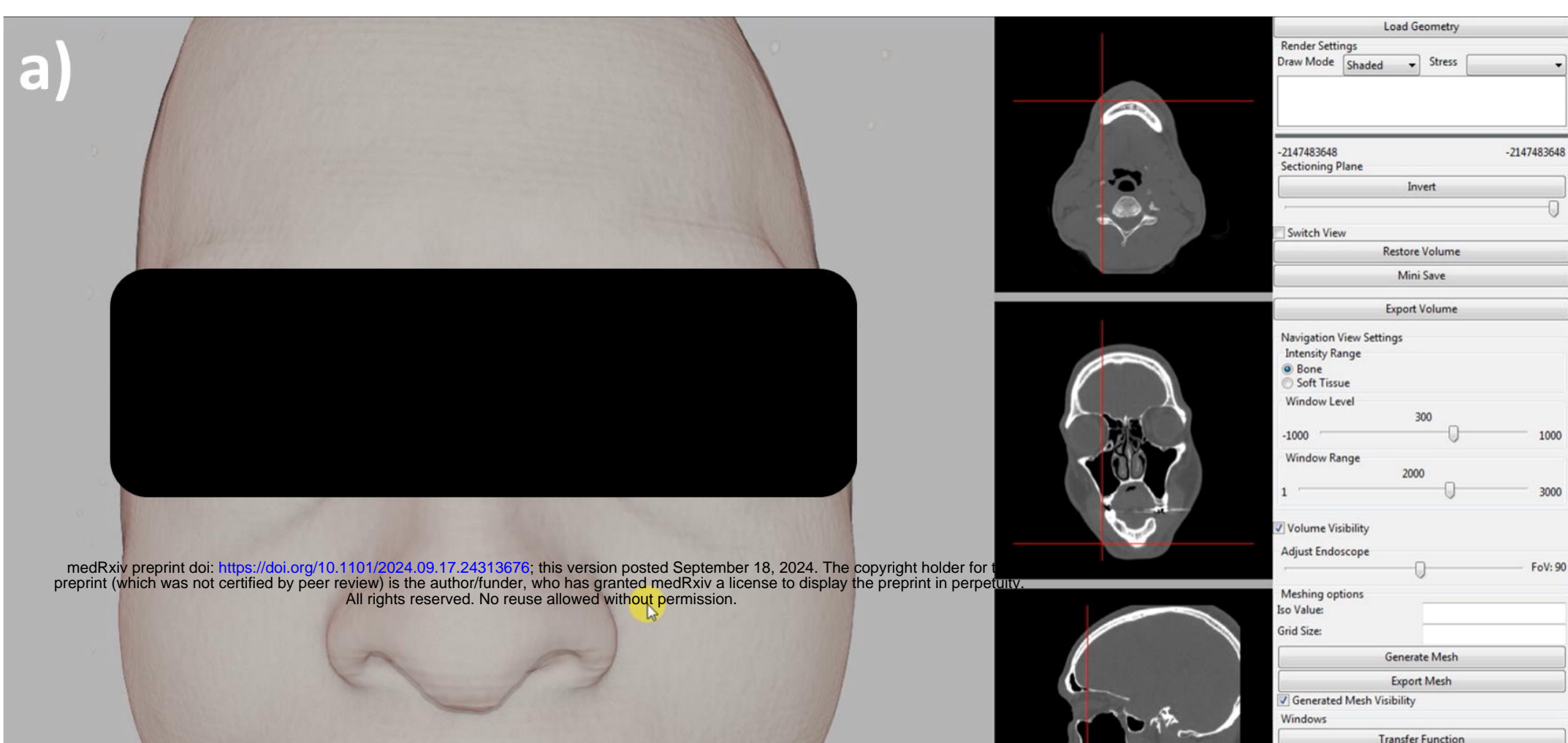
173
174

175

176 References

- 177 1. Kennedy DW, Zinreich SJ, Rosenbaum AE, Johns ME. Functional endoscopic sinus
178 surgery. Theory and diagnostic evaluation. *Arch Otolaryngol Chic Ill* 1960.
179 1985;111(9):576-582. doi:10.1001/archotol.1985.00800110054002
- 180 2. Bhattacharyya N. Ambulatory sinus and nasal surgery in the United States: demographics
181 and perioperative outcomes. *The Laryngoscope*. 2010;120(3):635-638.
182 doi:10.1002/lary.20777
- 183 3. Stewart MG, Smith TL, Weaver EM, et al. Outcomes after nasal septoplasty: results from
184 the Nasal Obstruction Septoplasty Effectiveness (NOSE) study. *Otolaryngol--Head Neck*
185 *Surg Off J Am Acad Otolaryngol-Head Neck Surg*. 2004;130(3):283-290.
186 doi:10.1016/j.otohns.2003.12.004
- 187 4. Ho W kuen, Yuen APW, Tang K chi, Wei WI, Lam PKY. Time course in the relief of nasal
188 blockage after septal and turbinate surgery: a prospective study. *Arch Otolaryngol Head*
189 *Neck Surg*. 2004;130(3):324-328. doi:10.1001/archotol.130.3.324
- 190 5. Edmond CV, Heskamp D, Sluis D, et al. ENT endoscopic surgical training simulator. *Stud*
191 *Health Technol Inform*. 1997;39:518-528.
- 192 6. Rudman DT, Stredney D, Sessanna D, et al. Functional endoscopic sinus surgery training
193 simulator. *The Laryngoscope*. 1998;108(11 Pt 1):1643-1647. doi:10.1097/00005537-
194 199811000-00010
- 195 7. Hilbert M, Müller W, Strutz J. [Development of a surgical simulator for interventions of the
196 paranasal sinuses. Technical principles and initial prototype]. *Laryngorhinootologie*.
197 1998;77(3):153-156. doi:10.1055/s-2007-996951
- 198 8. Nash R, Sykes R, Majithia A, Arora A, Singh A, Khemani S. Objective assessment of
199 learning curves for the Voxel-Man TempoSurg temporal bone surgery computer simulator.
200 *J Laryngol Otol*. 2012;126(7):663-669. doi:10.1017/S0022215112000734
- 201 9. Varshney R, Frenkiel S, Nguyen LHP, et al. The McGill simulator for endoscopic sinus
202 surgery (MSESS): a validation study. *J Otolaryngol - Head Neck Surg J Oto-Rhino-*
203 *Laryngol Chir Cervico-Faciale*. 2014;43(1):40. doi:10.1186/s40463-014-0040-8
- 204 10. Won TB, Hwang P, Lim JH, et al. Early experience with a patient-specific virtual surgical
205 simulation for rehearsal of endoscopic skull-base surgery. *Int Forum Allergy Rhinol*.
206 2018;8(1):54-63. doi:10.1002/alr.22037
- 207 11. Lindquist NR, Leach M, Simpson MC, Antisdell JL. Evaluating Simulator-Based Teaching
208 Methods for Endoscopic Sinus Surgery. *Ear Nose Throat J*. 2019;98(8):490-495.
209 doi:10.1177/0145561319844742

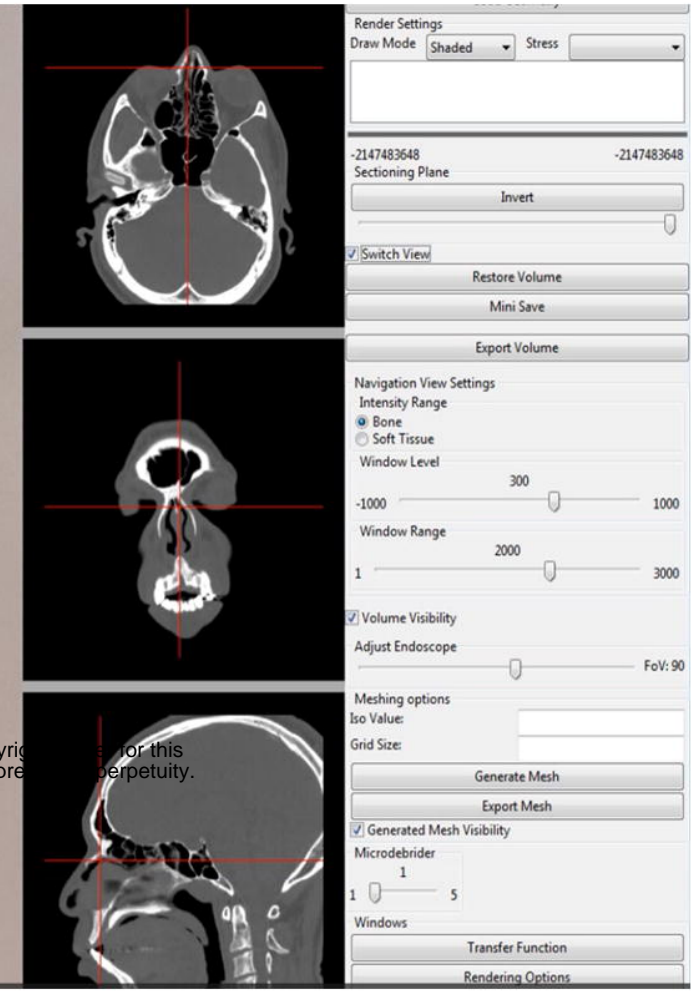
- 210 12. Kim DH, Kim HM, Park JS, Kim SW. Virtual Reality Haptic Simulator for Endoscopic
211 Sinus and Skull Base Surgeries. *J Craniofac Surg*. 2020;31(6):1811-1814.
212 doi:10.1097/SCS.0000000000006395
- 213 13. Richards JP, Done AJ, Barber SR, Jain S, Son YJ, Chang EH. Virtual coach: the next tool
214 in functional endoscopic sinus surgery education. *Int Forum Allergy Rhinol*. 2020;10(1):97-
215 102. doi:10.1002/alr.22452
- 216 14. Carsuzaa F, Fieux M, Legre M, et al. SimLifeÂ®, a new dynamic model for endoscopic
217 sinus and skull base surgery simulation. *Rhinology*. 2023;61(6):574-576.
218 doi:10.4193/Rhin23.230
- 219 15. Fried MP, Morrison PR. Computer-augmented endoscopic sinus surgery. *Otolaryngol Clin*
220 *North Am*. 1998;31(2):331-340. doi:10.1016/s0030-6665(05)70052-9
- 221 16. Li C, Jiang J, Kim K, et al. Nasal Structural and Aerodynamic Features That May Benefit
222 Normal Olfactory Sensitivity. *Chem Senses*. 2018;43(4):229-237.
223 doi:10.1093/chemse/bjy013
- 224 17. Burgos MA, Sevilla García MA, Sanmiguel Rojas E, et al. Virtual surgery for patients with
225 nasal obstruction: Use of computational fluid dynamics (MeComLand®, Digbody® &
226 Noseland®) to document objective flow parameters and optimise surgical results. *Acta*
227 *Otorrinolaringol Esp*. 2018;69(3):125-133. doi:10.1016/j.otorri.2017.05.005
- 228



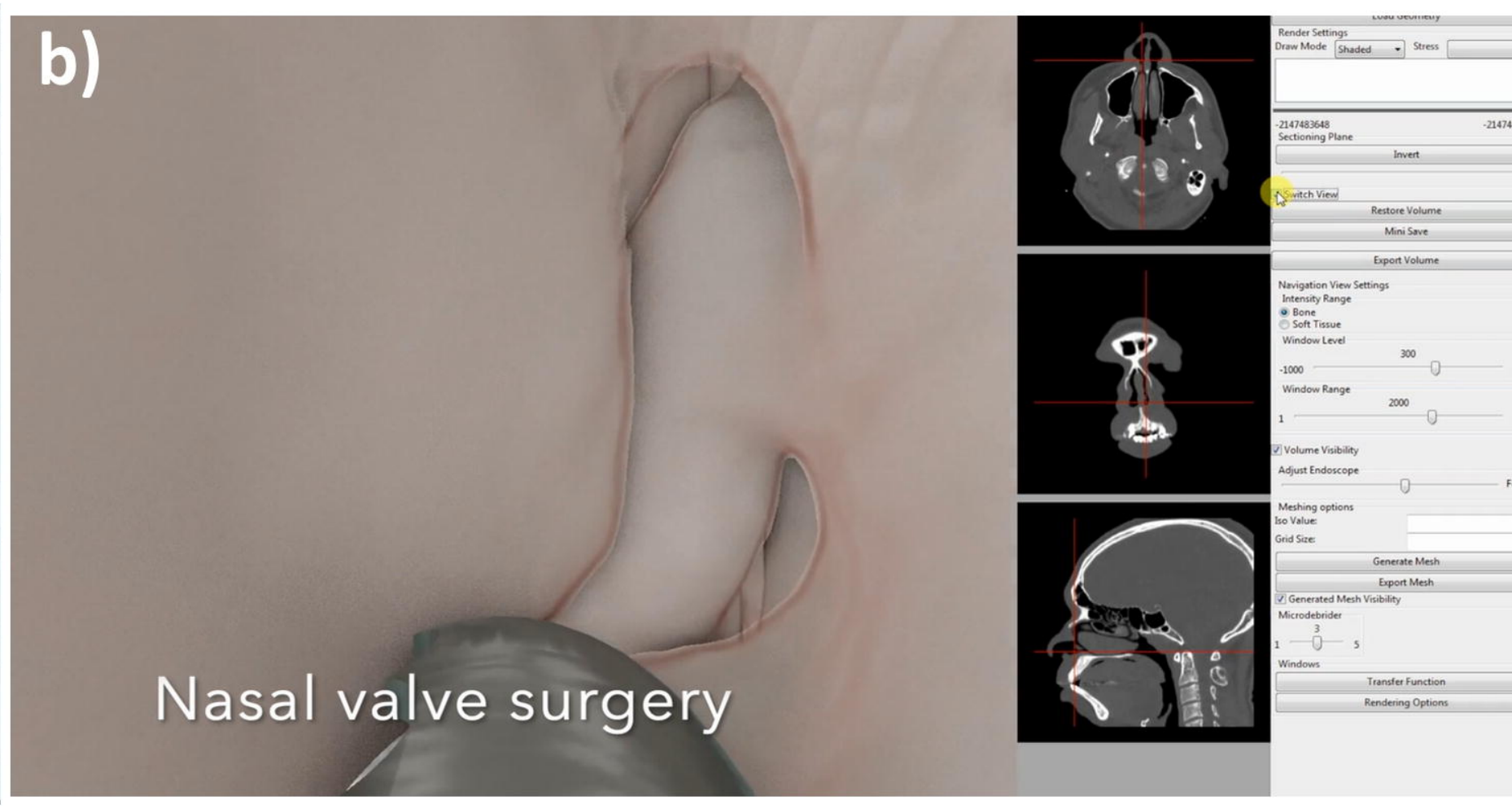
a)

medRxiv preprint doi: <https://doi.org/10.1101/2024.09.17.24313676>; this version posted September 18, 2024. The copyright holder for this preprint (which was not certified by peer review) is the author/funder, who has granted medRxiv a license to display the preprint in perpetuity. All rights reserved. No reuse allowed without permission.

Septal Body Reduction

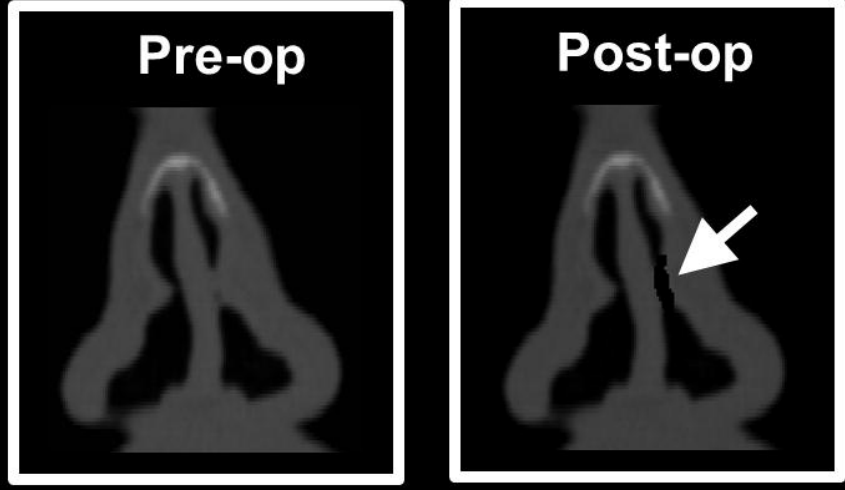


b)

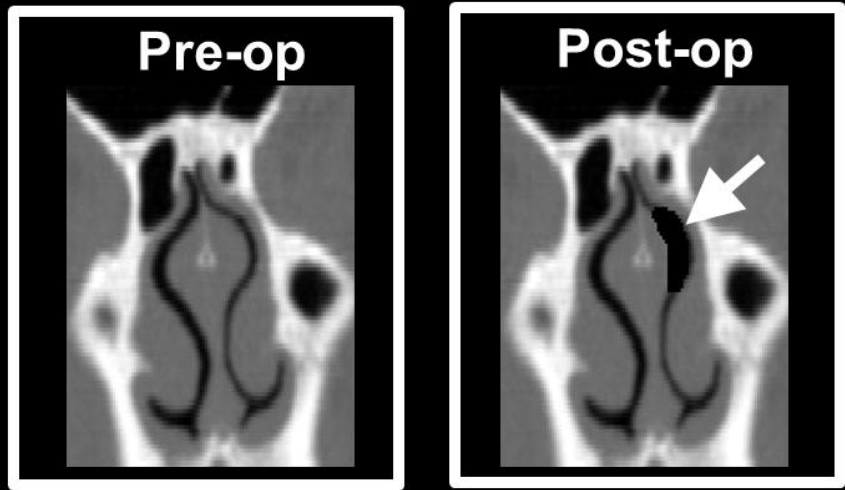


Nasal valve surgery

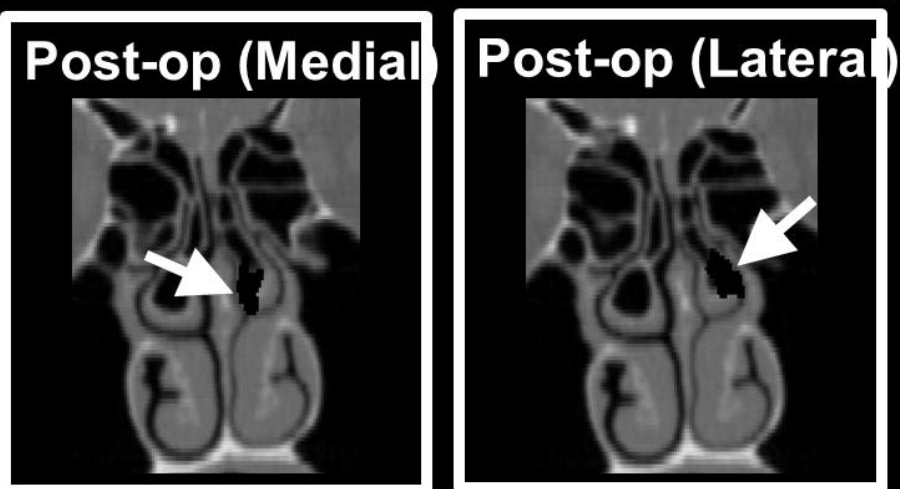
c) Nasal Valve Opening



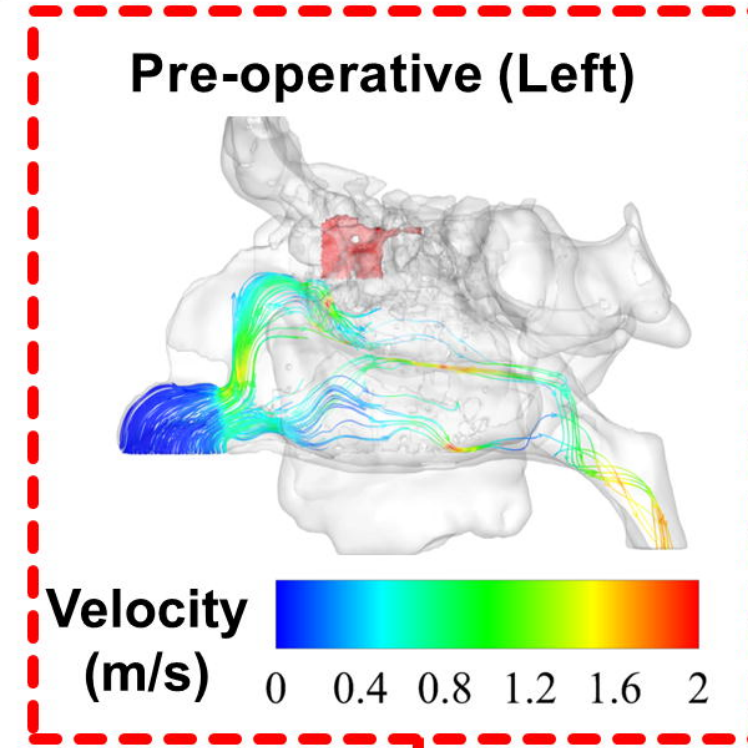
Septal Body Reduction



Partial Middle Turbinectomy

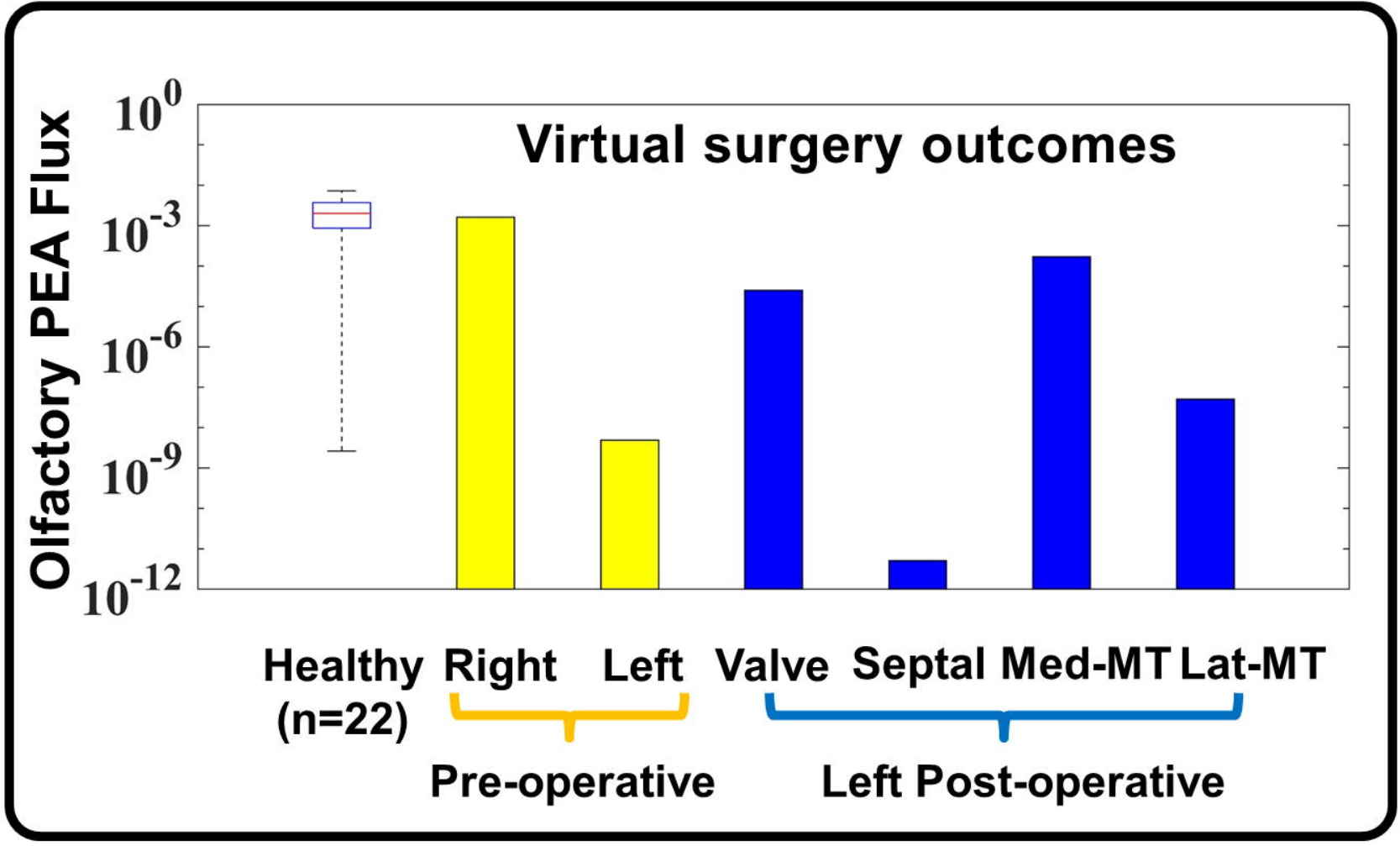


d) Patient 01

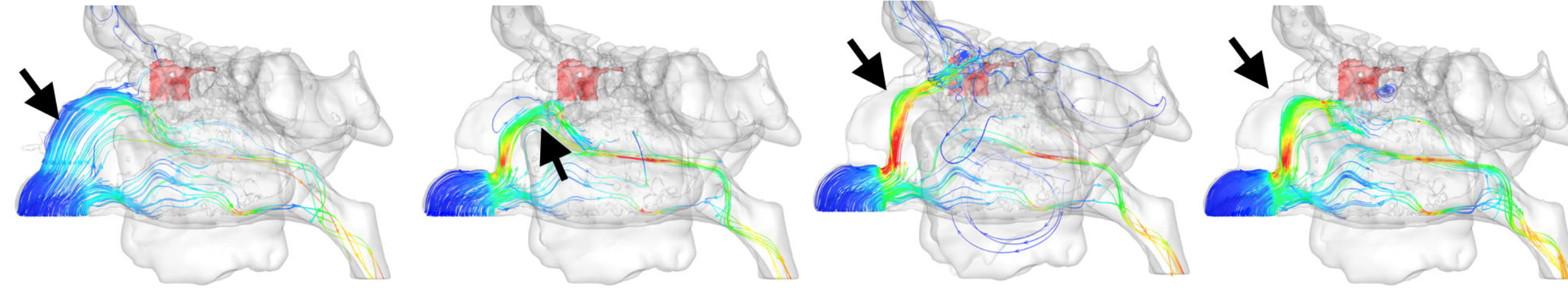


Left Post-operative

f)



e)



Nasal Valve Opening

Septal Body Reduction

Medial Mid-Turb.

Lateral Mid-Turb.