

1

2

3

4 **Outcomes of percutaneous transhepatic gallbladder**
5 **drainage versus percutaneous transhepatic biliary**
6 **drainage for obstructive jaundice**

7

8 **Short title: Usefulness of PTGBD and PTBD in patients with obstructive jaundice.**

9

10

11 Tetsushi Azami^{1*}, Yuichi Takano¹, Naoki Tamai¹, Jun Noda¹, Masataka Yamawaki¹,

12 Fumitaka Niiya¹, Naotaka Maruoka¹, Fumiya Nishimoto¹, Akira Ishihara², Masatsugu

13 Nagahama¹

14

15

16

17 ¹Department of Medicine, Division of Gastroenterology, Showa University Fujigaoka

18 Hospital, Yokohama, Japan

19 ²Department of Gastroenterological Surgery, Hitachi Medical Center, Hitachi, Japan

NOTE: This preprint reports new research that has not been certified by peer review and should not be used to guide clinical practice.

20

21 * Corresponding author

22 E-mail: tetsushiazami@yahoo.co.jp (TA)

23

24 **Author contributions**

25 Conceptualization: Tetsushi Azami.

26 Data curation: Tetsushi Azami.

27 Formal analysis: Tetsushi Azami.

28 Investigation: Tetsushi Azami, Naoki Tamai, Jun Noda, Masataka Yamawaki.

29 Methodology: Tetsushi Azami, Yuichi Takano, Fumitaka Niiya.

30 Project administration: Tetsushi Azami.

31 Supervision: Akira Ishihara, Masatsugu Nagahama.

32 Writing – original draft: Tetsushi Azami, Yuichi Takano.

33 Writing – review & editing: Tetsushi Azami, Yuichi Takano, Fumitaka Niiya, Naotaka

34 Maruoka, Fumiya Nishimoto, Akira Ishihara, Masatsugu Nagahama.

35

36

37 **Abstract**

38 Percutaneous transhepatic gallbladder drainage (PTGBD) is an alternative to
39 percutaneous transhepatic biliary drainage (PTBD) for cases of obstructive jaundice in which
40 the bile duct obstruction is below the confluence of the cystic ducts. The present study aimed
41 to evaluate the usefulness of PTGBD and PTBD in patients with obstructive jaundice. This
42 study enrolled patients who had undergone percutaneous biliary drainage for acute
43 cholangitis and obstructive jaundice at two institutions between January 2017 and March
44 2024. Fifty-five patients were included in this analysis. However, patients with intrahepatic
45 or hilar bile duct stenosis, post choledocholithiasis, complex cholecystitis, total bilirubin
46 levels < 2.0 mg/dL, and uncorrectable bleeding tendency and those who had undergone the
47 procedure and later discontinued without puncture were excluded. The technical success
48 rates, clinical success rates, and complication rates of the procedure were evaluated. The
49 technical success rates were 96.3% (26/27) in the PTGBD group and 82.1% (13/28) in the
50 PTBD group. The clinical success rates were 85.2% (23/27) in the PTGBD group and 67.9%
51 (19/28) in the PTBD group. The complication rates were 11.1% (3/27) in the PTGBD group
52 and 17.9% (5/28) in the PTBD group. Hence, the two groups did not significantly differ in
53 any of the endpoints. The outcomes of PTGBD were comparable to those of PTBD in
54 patients with obstructive jaundice. Hence, PTGBD is a reasonable treatment option for cases
55 of obstructive jaundice in which PTBD is not feasible.

56

57 **Introduction**

58 Bile duct drainage is indicated for all patients with acute cholangitis and obstructive
59 jaundice, except for some mild cases that improve with antimicrobial therapy alone. The
60 Tokyo Guidelines 2018 recommend endoscopic biliary drainage (EBD) as the first-line
61 treatment for bile duct drainage [1]. However, in some cases, EBD cannot be performed due
62 to factors such as the patient's general condition, postoperative reconstructed intestinal tract,
63 and gastrointestinal stenosis. In recent years, endoscopic ultrasound-guided biliary drainage
64 (EUS-BD) has been the salvage procedure of choice for such cases. If EBD and EUS-BD are
65 challenging to perform, percutaneous transhepatic biliary drainage (PTBD) is considered.
66 However, its technical success rate is 63% in patients with nondilated bile ducts and 86% in
67 patients with dilated ducts, which is not sufficient [2].

68 Alternatively, percutaneous transhepatic gallbladder drainage (PTGBD) is a drainage
69 technique for acute cholecystitis. It has a high success rate and can be useful for bile duct
70 drainage if the bile duct obstruction is downstream of the cystic duct. EUS-guided
71 gallbladder drainage has been reported to be useful for EUS-guided hepaticogastrostomy
72 failure in obstructive jaundice [3]. PTGBD can serve as an alternative treatment strategy to
73 PTBD. A case series and a small number of retrospective cohort studies have evaluated the
74 use of PTGBD for cholangitis and obstructive jaundice [4-7]. However, to the best of our

75 knowledge, no studies have compared PTGBD and PTBD. The present study aimed to
76 examine the usefulness of PTGBD and PTBD in patients with obstructive jaundice.

77

78 **Materials and Methods**

79 **Study design and participants**

80 This retrospective study was based on an analysis of data collected from the patients'
81 electronic medical records. Patients who had undergone percutaneous biliary drainage for
82 acute cholangitis and obstructive jaundice at Showa University Fujigaoka Hospital or Hitachi
83 Medical Center between January 1, 2017 and March 31, 2024 were included in this analysis.
84 Patients with intrahepatic or hilar bile duct stenosis, hepaticojejunostomy anastomotic
85 stricture, coexisting cholecystitis, total bilirubin (T.bil) level < 2.0 mg/dL, and uncorrectable
86 bleeding tendency and those who had undergone the procedure and later discontinued
87 without puncture were excluded.

88 The original data were accessed for research purposes on August 16, 2024. The
89 study was conducted according to the Declaration of Helsinki guidelines and was approved
90 by the Showa University Research Ethics Review Board (Approval Number: 2024-106-B).
91 Due to the retrospective nature of the study, the need for informed consent was waived by the
92 IRB.

93

94 **Outcomes**

95 The primary endpoints were technical success rates, clinical success rates, and
96 complication rates. Technical success was defined as catheter placement into the biliary tract.
97 Clinical success was defined as a decrease in T.bil levels to <2.0 mg/dL or a 50% decrease in
98 T.bil levels after 2 weeks. Complications were evaluated based on the Clavien–Dindo
99 classification [8]. The severity of cholangitis was also assessed using the Tokyo Guidelines
100 2018 [1].

101

102 **Procedure details**

103 For percutaneous drainage, PTBD was the first choice, but in cases with poor
104 intrahepatic bile duct dilatation or when bile duct puncture was difficult due to respiratory
105 fluctuations, PTGBD was selected at the surgeon's discretion. PTGBD was performed using a
106 one-step technique (Fig 1). PTBD was performed with either one- or two-step techniques
107 based on the surgeon's discretion (Fig 1). If necessary, analgesics (pentazocine 15 mg) were
108 administered intravenously before puncture.

109 **One-step method**

110 After administering local anesthesia with lidocaine, an 18-G needle (Hanaco
111 Medical, Saitama, Japan) was inserted into the gallbladder or bile duct under
112 ultrasound guidance, and a small amount of bile was aspirated. Next, a 0.035-in guide wire

113 (Radifocus, Terumo, Tokyo, Japan) was placed in the gallbladder or bile duct under
114 fluoroscopy. After a small skin incision was made and dilated with a dilator, a 6–8-Fr pigtail
115 catheter (UreSil, L.C.C., Illinois, the USA) was inserted.

116 **Two-step method**

117 After administering local anesthesia with lidocaine, a 20-G needle was inserted
118 under ultrasound guidance. A small amount of bile was aspirated. Then, cholangiography was
119 conducted (Urografine 60%, Byer AG, Nordrhein-Westfalen, Germany). Next, a 0.018-in
120 guide wire was placed in the bile duct under fluoroscopic guidance. A small skin incision was
121 made, an introducer set was inserted, and all but the sheath was removed. Then, a 0.035-in
122 guide wire was inserted, the sheath was removed, and the bile duct was dilated with a dilator.
123 Finally, a 7-Fr pigtail catheter (CLINY PTCD Kit, Create Medic Co., Yokohama, Japan) was
124 implanted.

125

126 Fig 1. Percutaneous transhepatic gallbladder drainage (PTGBD) and percutaneous
127 transhepatic biliary drainage (PTBD) procedure.

128 (A) 18-G needle was inserted into the gallbladder. Next, a 0.035-in guide wire was placed in
129 the gallbladder. (B) 8-Fr pigtail catheter was inserted. (C) Cholangiography was performed.
130 (D) 18-G needle was inserted into the gallbladder and cholangiography was performed. (E) A
131 0.035-in guide wire was placed in the bile duct. (F) 8-Fr pigtail catheter was inserted.

132

133 **Statistical analysis**

134 The outcomes of the PTGBD and PTBD groups were compared using the Mann–
135 Whitney U test for continuous variables and chi-square test or Fisher’s exact test for nominal
136 variables. A p value of <0.05 was considered statistically significant. R version 4.0.3 (R
137 Foundation for Statistical Computing, Vienna, Austria) was used for data analysis.

138

139 **Results**

140

141 Table 1. Comparison of characteristics between percutaneous transhepatic gallbladder
142 drainage and percutaneous transhepatic biliary drainage.

Characteristics	PTGBD (n=27)	PTBD (n=28)	P-value
age (years), median (range)	76 (53-93)	73 (59-95)	0.34
sex (male), n (%)	20 (74.1)	18 (64.3)	0.684
Charlson Comorbidity Index, median (range)	7 (3-12)	9 (4-11)	0.0599
use of antithrombotic medication, n (%)	5 (18.5)	4 (14.2)	1
baseline T.bil levels (mg/dl), median (range)	4.30 (2.3-22.7)	9.33 (2.0-26.2)	<0.01
severe cholangitis, n (%)	14 (51.9)	5 (17.9)	0.0111
etiology of obstruction			
benign, n (%)	18 (66.7)	5 (17.8)	<0.01
malignant, n (%)	9 (33.3)	23 (82.1)	
bile duct stone	17	5	
chronic pancreatitis	1	0	
pancreatic cancer	4	12	
bile duct cancer	1	6	

ampullary cancer	1	1	
gastric cancer	3	3	
malignant lymphoma	0	1	
reason for ERCP failed or not done, n (%)			<0.01
surgically altered anatomy	13 (48.1)	10 (35.7)	
duodenal invasion	3 (11.1)	5 (17.9)	
failed cannulation	4 (14.8)	13 (46.4)	
respiratory failure or septic shock	7 (25.9)	0	

143 PTGBD: percutaneous transhepatic gallbladder drainage. PTBD: percutaneous transhepatic

144 biliary drainage. ERCP: endoscopic retrograde cholangiopancreatography.

145

146 **Clinical characteristics of the patients**

147 Percutaneous drainage was performed on 79 patients with cholangitis and

148 obstructive jaundice between January 1, 2017, and March 31, 2024. Among them, two

149 presented with hilar bile duct stenosis, seven with hepaticojejunostomy anastomotic stricture,

150 seven with coexisting cholecystitis, and eight with T.bil levels < 2.0 mg/dL were excluded.

151 Hence, 55 patients were finally included in this study.

152 Of 55 patients, 27 and 28 underwent PTGBD and PTBD, respectively. One patient

153 in the PTGBD group and five in the PTBD group experienced technical failure. Technical

154 success was 26 in the PTGBD group and 23 in the PTBD group (21 one-step and 2 two-step

155 procedures) (Fig 2).

156 In terms of technical failures, in one patient, PTGBD was unsuccessful because the

157 dilator could not be inserted due to the lack of gallbladder distension. Surgical treatment was

158 then performed. In five patients in whom PTBD failed, three and two underwent PTGBD and
159 EUS-BD, respectively (Fig 2). Table 1 shows the characteristics of the patients. The PTGBD
160 and PTBD groups did not significantly differ in terms of age, sex, and use of antithrombotic
161 medication. The median Charlson Comorbidity Index (CCI) values were 7 (3–12) in the
162 PTGBD group and 9 (4–11) in the PTBD group. The PTBD group (9.33 [2.0–26.2] mg/dL)
163 had significantly higher baseline T.bil levels than the PTGBD group (4.30 [2.3–22.7] mg/dL).
164 Severe cholangitis was significantly more common in the PTGBD group than in the PTBD
165 group (14 [51.9%] vs 5 [17.9%]). In terms of obstruction etiology, 18 (66.7%) and 9 (33.3%)
166 patients in the PTGBD group presented with benign and malignant diseases, respectively.
167 Moreover, 5 (17.8%) and 23 (82.1%) patients in the PTBD group presented with benign and
168 malignant diseases, respectively. Hence, benign disease was more common in the PTGBD
169 group than in the PTBD group. The most common reasons for failure or absence of
170 endoscopic retrograde cholangiopancreatography (ERCP) were postoperative surgically
171 altered anatomy in the PTGBD group (n = 13 [48.1%]) and failed cannulation in the PTBD
172 group (n = 13 [46.4%]) (Table 1).

173

174 Fig 2. Participant flow chart.

175 PTGBD: percutaneous transhepatic gallbladder drainage. PTBD: percutaneous transhepatic
176 biliary drainage.

177

178 **Outcomes**

179

180 Table 1. Comparison of outcomes between Percutaneous transhepatic gallbladder drainage
181 and percutaneous transhepatic biliary drainage.

	PTGBD (n=27)	
technical success rates, % (n)	96.3 (26)	
clinical success rates, % (n)	85.2 (23)	
complication rates, % (detail)	11.1 (catheter migration: n=2, shock grade II : n=1)	17.9 (catheter migration: n=2, shock grade II : n=1)

182

183 PTGBD: percutaneous transhepatic gallbladder drainage. PTBD: percutaneous transhepatic
184 biliary drainage.

185

186 The technical success rates were 96.3% (26/27) in the PTGBD group and 82.1%
187 (23/28) in the PTBD group. The clinical success rates were 85.2% (23/27) in the PTGBD
188 group and 67.9% (19/28) in the PTBD group. Hence, the two groups did not significantly
189 differ in terms of technical success and clinical success rates. Although not included in the
190 PTBD group, one patient who did not achieve a clinical success to PTGBD achieved a
191 clinical success to PTBD. The complication rates were 11.1% (3/27) in the PTGBD group
192 and 17.9% (5/28) in the PTBD group. Thus, there were no significant differences in terms of
193 the complication rates between the two groups (Table 2).

194

195 **Discussion**

196 Cholecystocentesis, which was first reported by Burckhardt and Muller in 1921, has
197 a long history [9]. Subsequently, Huard and Du-Xuan-Hop et al. successfully performed
198 intrahepatic bile duct puncture in 1937 [10]. The introduction of echo-guided puncture and
199 improvements in treatment tools led to therapeutic application of percutaneous biliary
200 puncture. PTBD was first reported by Glenn et al. in 1962 [11]. PTGBD was first reported by
201 Elyaderani and Gabriele in 1979 [12] and performed by Radder in 1982 in patients with acute
202 cholecystitis [13]. To date, in the Tokyo Guidelines, PTGBD is recommended as the standard
203 drainage method for patients with cholecystitis who are at high risk for surgery, and PTBD is
204 an alternative treatment to EBD in patients with cholangitis [1].

205 In recent years, EUS-BD has been gaining popularity as a biliary drainage technique
206 since the study of Giovannini [14]. Moreover, EUS-GBD has been reported to be useful in
207 treating obstructive jaundice in cases of EUS-guided hepaticogastrostomy failure if the bile
208 duct obstruction was downstream of the confluence of the cystic duct. Furthermore, PTGBD
209 may be useful in obstructive jaundice. A case series and a few retrospective cohort studies
210 have long documented the efficacy of PTGBD for obstructive jaundice [4-7].

211 Li et al. and Park et al. reported that PTGBD resulted in jaundice control in 91% (29
212 / 32) and 100% (20 / 20) of patients with obstructive jaundice. Only 3% (one patient with

213 biliary peritonitis) and 5% (one patient with catheter migration) of patients presented with
214 complications, respectively. And technical success was 100% in both studies. Both studies
215 have revealed that PTGBD is useful in treating obstructive jaundice [4, 5].

216 No reports have compared PTGBD and PTBD. This is the first report comparing the
217 efficacy of PTGBD and PTBD in obstructive jaundice. The technical success, clinical
218 success, and complication rates of PTGBD and PTBD were comparable in this study.
219 PTGBD for obstructive jaundice should be considered as an alternative treatment to PTBD.
220 However, in one case, PTBD improved jaundice in a patient who showed no clinical response
221 to PTGBD. Treatment via the percutaneous drainage route (rendezvous procedure,
222 percutaneous bile duct stenting, and stone removal) is also less difficult with PTBD than with
223 PTGBD. In patients considering treatment via the percutaneous drainage route, PTBD can
224 be a better option because of the ease of subsequent procedures.

225 Although there were no significant differences in terms of outcomes between the
226 two groups, the clinical characteristics of the two groups differed. In terms of disease
227 etiology, benign diseases such as common bile duct stones were more common in the
228 PTGBD group than in the PTBD group. Meanwhile, malignant diseases were more common
229 in the PTBD group than in the PTGBD group. Severe cholangitis was significantly more
230 common in the PTGBD group than in the PTBD group. Severe cholangitis caused by bile
231 duct stones requires a short treatment time due to unstable vital signs. In several cases, it is

232 difficult to obtain patient cooperation and respiratory arrest at the time of puncture.
233 Therefore, PTGBD, which is less difficult to perform, was selected. By contrast, obstructive
234 jaundice caused by malignant diseases is generally more severe than that caused by benign
235 disease. However, it is less likely to be complicated by severe cholangitis. The high degree of
236 bile duct dilatation and the ease of patient cooperation might have been the reasons for
237 selecting PTBD. The PTBD group can have a higher CCI than the PTGBD group because of
238 the higher number of patients with malignant diseases. There were no statistically significant
239 differences. However, it should not be underestimated that the PTGBD group was more
240 likely to have a higher technical success rate and a lower incidence rate of accidents.

241 The greatest advantage of PTGBD is its ease of use and high technical success rate.
242 PTGBD and PTBD should be used interchangeably in different cases. However, in cases
243 where PTBD is challenging to perform, PTGBD should be considered as an alternative
244 treatment.

245 The present study had several limitations. First, it was a retrospective study
246 conducted at two centers, and the number of cases was small. The two groups differed in
247 terms of clinical characteristics, with the PTGBD group having milder jaundice. The type of
248 procedure might have been influenced by the operator's subjective bias. Future studies
249 comparing PTBD and PTGBD under identical conditions should be performed.

250

251 **Conclusions**

252 The outcomes of PTGBD are comparable with those of PTBD in patients with
253 obstructive jaundice. Thus, PTGBD is a reasonable treatment option in cases of obstructive
254 jaundice in which the intrahepatic bile duct dilatation is poor or PTBD is challenging to
255 perform due to the patient's general condition.

256

257 **Acknowledgments**

258 None.

259

260 **References**

- 261 [1] Yokoe M, Hata J, Takada T, Strasberg SM, Asbun HJ, Wakabayashi G, et al. Tokyo
262 Guidelines 2018: diagnostic criteria and severity grading of acute cholecystitis (with videos).
263 J Hepatobiliary Pancreat Sci. 2018;25(1): 41-54.
- 264 [2] Saad WE, Wallace MJ, Wojak JC, Kundu S, Cardella JF. Quality improvement guidelines
265 for percutaneous transhepatic cholangiography, biliary drainage, and percutaneous
266 cholecystostomy. J Vasc Interv Radiol. 2010;21(6): 789-95.
- 267 [3] Imai H, Kitano M, Omoto S, Kadosaka K, Kamata K, Miyata T, et al. EUS-guided
268 gallbladder drainage for rescue treatment of malignant distal biliary obstruction after
269 unsuccessful ERCP. Gastrointest Endosc. 2016;84: 147-151.

- 270 [4] Park JM, Kang CD, Lee M, Park SC, Lee SJ, Jeon YH, et al. Percutaneous
271 cholecystostomy for biliary decompression in patients with cholangitis and pancreatitis. *J Int*
272 *Med Res.* 2018;46(10): 4120-4128.
- 273 [5] Li YL, Wong KH, Chiu KW, Cheng AK, Cheung RK, Yam MK, et al. Percutaneous
274 cholecystostomy for high-risk patients with acute cholangitis. *Medicine (Baltimore).*
275 2018;97(19):e0735.
- 276 [6] Ren Z, Xu Y, Zhu S. Percutaneous transhepatic cholecystostomy for choledocholithiasis
277 with acute cholangitis in high-risk patients. *Hepatogastroenterology.* 2012;59: 329-331.
- 278 [7] Shitrit AB-G, Braverman D. Interval percutaneous cholecystostomy is effective for
279 decompression of the common bile duct in high-risk elderly patients prior to endoscopic
280 retrograde cholangiopancreatography. *Gerontology.* 2008;54: 144-147.
- 281 [8] Dindo D, Demartines N, Clavien PA. Classification of surgical complications: a new
282 proposal with evaluation in a cohort of 6336 patients and results of a survey. *Ann Surg.*
283 2004;240(2): 205-13.
- 284 [9] Burckhardt H, Muller W. Study on the puncture of the gallbladder and their X-ray
285 imaging. *Dtsch Z Chir.* 1921;162: 168-197.
- 286 [10] Huard P, Du-Xuan-Hop. Transhepatic bile duct puncture. *Bull Soc Med Chir*
287 *Indochine.* 1937;15: 1090-1110.

- 288 [11] Glenn F, Evans JA, Mujahed Z, Thorbjarnarson B. Percutaneous transhepatic
289 cholangiography. *Ann Surg.* 1962;156: 451-460.
- 290 [12] Elyaderani M, Gabriele OF. Percutaneous cholecystostomy and cholangiography in
291 patients with obstructive jaundice. *Radiology.* 1979;130: 601-602.
- 292 [13] Radder RW. Percutaneous cholecystostomy. *AJR Am J Roentgenol.* 1982;139: 1240-
293 1241.
- 294 [14] Giovannini M, Moutardier V, Pesenti C, Bories E, Lelong B, Delpero JR. Endoscopic
295 ultrasound-guided bilioduodenal anastomosis: a new technique for biliary drainage.
296 *Endoscopy.* 2001;33: 898-900.
- 297
- 298

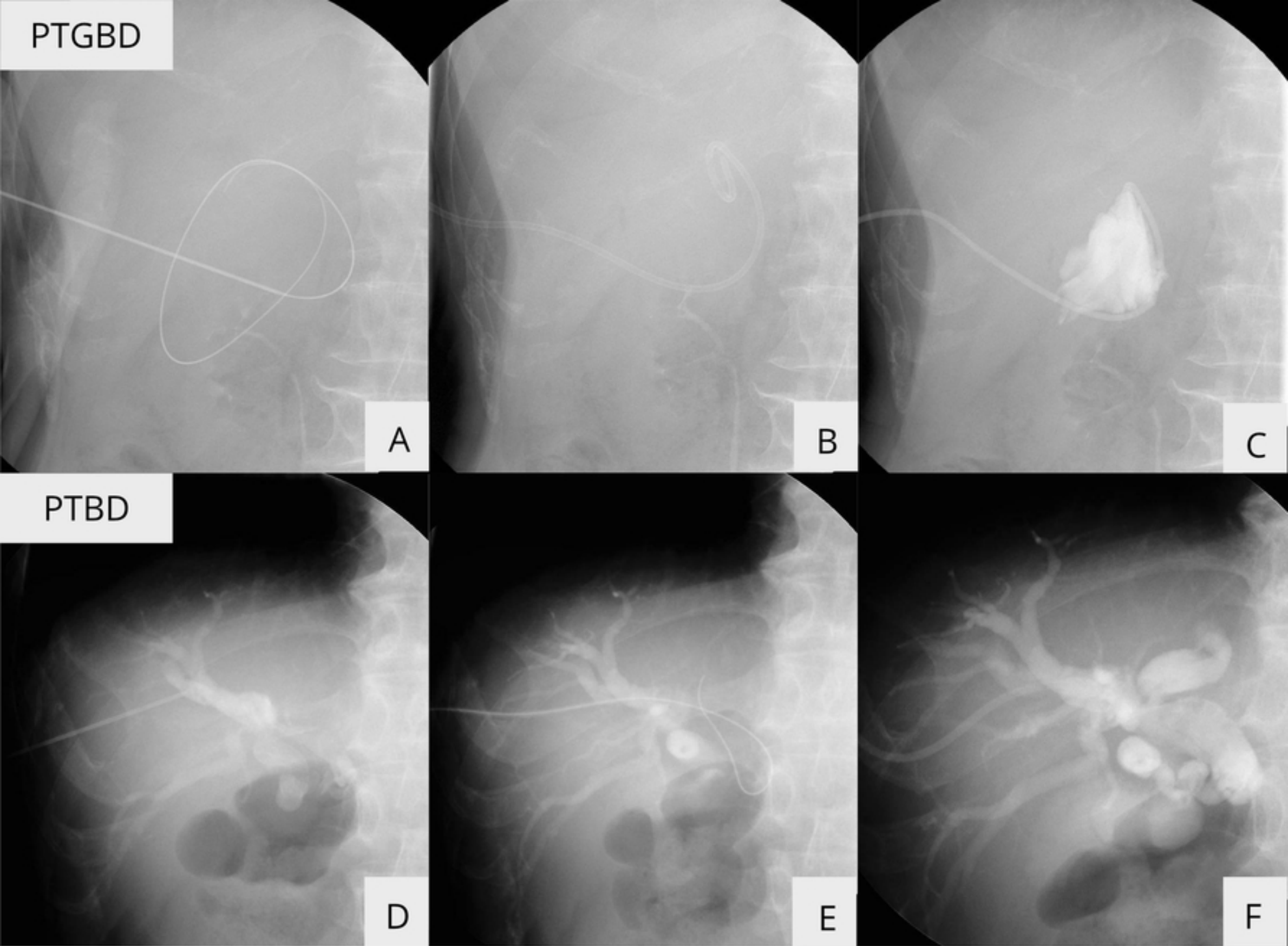


Figure 1

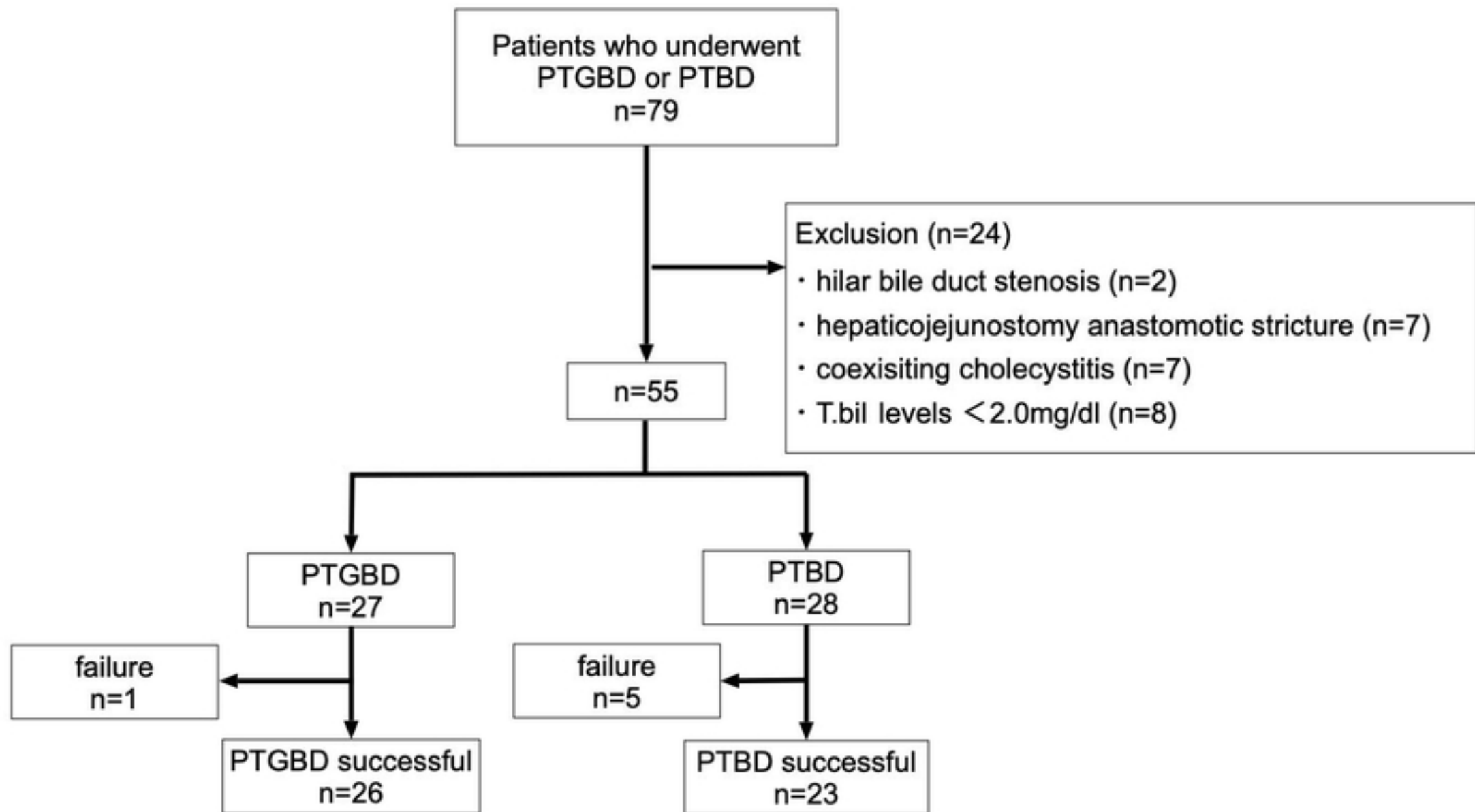


Figure2