

Comprehensive Review of Adverse Effects in Minimally Invasive Cosmetic Procedures:

Insights from a Decade of Clinical Data

Cristina Guadalupe Beltrán Muñoz¹, Elissa Bracamontes Perez², Fernanda Corrales Bay¹,
Aimee Adriana Barajas Nieto², Kate Georgette Rojo Navarro²

1) Unidad Médica de Alta Especialidad Número 2 “Luis Donaldo Colosio” Centro Médico Nacional Noroeste, Obregón, Sonora, México. 2) Hospital General de Los Mochis, Sinaloa, México.

CORRESPONDENCE:

- 1) Cristina Guadalupe Beltrán Muñoz. Unidad Médica de Alta Especialidad Número 2 “Luis Donaldo Colosio” Centro Médico Nacional Noroeste. Prolongación Hidalgo y Huisaguay s/n, Bellavista, Ciudad Obregón, Sonora, México, ZIP code 85130. Phone: +52 644 173 0015. E-mail: crisbeltranm@outlook.com

CONFLICT OF INTERESTS: The authors declare that they have no conflict of interests.

2398 text words; 137 references; 1 figure, 2 tables.

Running headline: Review of the Adverse Effects in Minimally Invasive Cosmetic Procedures Over 10 Years

ABSTRACT (215 WORDS)

Introduction: Minimally invasive cosmetic procedures are medical interventions that do not involve the use of surgical incisions. They are usually based on the administration of biocompatible compounds into subcutaneous or dermal tissue. Although considered low-risk, they can have significant adverse effects such as tissue damage or occlusion of superficial blood vessels. Describing their complications is necessary to ensure the responsible use of these resources. **Objective:** To describe the adverse effects secondary to the use of minimally invasive cosmetic procedures. **Materials and Methods:** Studies describing the adverse effects of minimally invasive cosmetic procedures were searched in PubMed, Scopus, Embase, and Google Scholar from January 2012 to December 2023. **Results:** A total of 98 articles were included. The administration of hyaluronic acid, botulinum toxin, silicone, and autologous fat grafts were the most commonly used procedures. Local symptoms were the most commonly reported reactions (53 studies). Meanwhile, temporary or permanent blindness was reported in 10 studies, immunological alterations in 8, severe pulmonary involvement in 6, neurological damage in 5, arterial occlusion in 3, and 2 studies reported fatalities. **Conclusion:** Minimally invasive cosmetic procedures can cause local complications in the majority of cases, but they can also lead to fatal outcomes, particularly in unprofessional settings. Undergoing these techniques requires a comprehensive professional assessment and close follow-up by licensed personnel.

Key words: Minimally invasive, cosmetic procedures, aesthetic medicine, adverse effects

INTRODUCTION

Currently, there is a significant and growing demand for medical procedures aimed at cosmetic enhancement^{1,2}. This trend is particularly evident in the increasing popularity of minimally invasive procedures, which are favored for their effectiveness, ease of application, and shorter recovery times^{3,4}. These procedures often involve the administration of various substances, such as hyaluronic acid, botulinum toxin, autologous fat grafts, and other cellular products, among others⁵⁻⁸. While these compounds have been proven to be stable, biocompatible⁹, biodegradable and non-toxic^{10,11}, the detailed mechanisms underlying their cellular effects, metabolism, and excretion remain partially understood¹². This uncertainty raises concerns about potential tissue damage, particularly across different skin layers and superficial neurovascular bundles¹³. Despite the widespread use of these procedures, most research has predominantly focused on documenting the adverse effects associated with the most commonly performed interventions¹⁴, or those linked to specific application techniques^{15,16}. Furthermore, the unlicensed practice of cosmetic procedures is alarmingly common, which exacerbates the potential risks these interventions present¹⁷. This leaves a gap in understanding the broader spectrum of risks these procedures may pose. Therefore, we conducted a comprehensive review of the literature with the objective of describing the complications experienced by patients undergoing minimally invasive cosmetic procedures over the past decade. Additionally, we aim to provide a broader perspective on the potential risks associated with these interventions, emphasizing the importance of their responsible use.

METHODS

Using the PICO strategy, we conducted a systematic search in the PubMed, Embase, Scopus and Google Scholar repositories, with the following keywords: “*aesthetic medicine and side effects*” OR “*cosmetic medicine and side effects*” OR “*minimally invasive procedures and iatrogenic*” OR “*filler injection and side effects*” OR “*minimally invasive aesthetic medicine and adverse outcomes*”. Only original articles published between January 2012 and December 2023, written in English or Spanish, and involving human participants undergoing minimally invasive cosmetic procedures (e.g., appearance modification, enhancement of attractiveness, etc.) were included". Systematic reviews and meta-analyses, expert consensus, pre-clinical experimental studies and in-vitro studies were excluded, as well as studies with unavailable content or imprecise information regarding the interventions used. Articles were filtered by title and abstract by five reviewers, and those with relevant information were selected by consensus. Information on the type of procedure, occurrence of adverse events, and other covariates or interest, was collected for all selected articles.

RESULTS

We encountered a total of 238 candidate articles, of which 55 were excluded for containing information unrelated to the aims of this review, 18 for being in a different language, 10 for being duplicates and 57 due to incomplete data, yielding a total of 108 eligible articles. Of the included articles, a total of 33 studies were randomized and 5 were nonrandomized clinical trials, 8 were retrospective cohort studies and 3 were prospective

cohort studies. Additionally, we also included 10 case series, 37 case reports, and 2 "brief reports" (Figure 1, Table 1).

General characteristics of participants

The total sum of the population analyzed in the studies amounted to 10,231 patients. All participants were adults, aged between 18 and 80 years, with the majority being cisgender women in their third to sixth decade of life. Overall, most of the population was healthy and all of them had voluntarily undergone the procedures. Only participants from 17 studies presented with a relevant medical history, including participants with chronic degenerative diseases (9 studies), individuals with facial and/or body malformations (2 studies), with active infections including HIV and COVID-19 (4 studies), transgender participants (1 study), and a patient with a history of autoimmune disease (1 study) (Table 1). Additionally, the race/ethnicity of most participants was White, followed by Korean and Mestizo populations. Only 3 studies evaluated the effects of these interventions on dark-skinned populations (Fitzpatrick classification > IV).

Procedures performed

Most studies focused on the administration of biocompatible substances of various types into superficial anatomical planes of the subjects to model body structures and enhance the attractiveness of the treated area. The most frequently used compound was commercially formulated hyaluronic acid, utilized in more than 40 studies. Additionally, over half of these studies used combinations of this substance with solvents, local anesthetics (mainly lidocaine), oils, or other components. In 3 of these 62 studies, the

origin and composition of the administered hyaluronic acid could not be identified. There was also a noteworthy use of botulinum toxin, administered in 10 studies either as a standalone component or in combination with other substances. Liquid injectable silicone was used in 7 studies. The use of autologous cell products was also prevalent, such as fat grafts (7 studies), platelet-rich plasma (4 studies) or plasma-rich fibrin (1 study). Other substances used less frequently included carbon dioxide, polynucleotide, dextran, phosphatidylcholine, etc.

Intervened areas and responsible health personnel

The most frequently intervened anatomical area was that of the face, chin, and lips (79 studies), particularly in nasolabial folds, cheek areas, and other various sites across the face. This was followed by the gluteal region (16 studies), periorbital, nose and glabella region (8 studies), abdomen (6 studies), and genitalia (2 studies). In most records, the interventions were performed by a specialist physician trained in plastic surgery or another unspecified field. However, there were several instances where the interventions were carried out by unqualified personnel, including uncertified clinics or physicians without a license to perform these procedures. In 3 studies, the intervention was self-administered.

Follow-up of subjects

Excluding case reports and case series studies, the follow-up period for subjects within the studies was highly variable. The follow-up period was less than 6 weeks in 7 studies, between 6 weeks and 6 months in 10 studies, and between 6 to 12 months in 20 studies.

Additionally, 8 studies had a duration of around 2 years, 3 a duration of 2-5 years, and 3 had a follow-up period exceeding 5 years.

Minor and local adverse effects

All studies followed common guidelines for recording adverse effects following cosmetic procedures in humans and were classified in early and late complications. Most of the adverse effects observed were of low severity and appeared immediately or within a few days of the intervention. In the majority of these studies, only minimal discomforts such as periorbital edema, erythema, and localized pain were found. Three studies recorded skin pigmentation alterations with patches of hypo- and hyperpigmentation. In addition to the described discomforts, thirty other studies found cases of swelling, more severe edema, and deformities, with all symptoms disappearing within 48 hours to 7 days. Additionally, eleven studies reported the presence of lumps, nodules, deformities with "unaesthetic" results, infections, cellulitis of varying intensity, and dermal necrosis with prolonged or permanent duration in subjects who underwent these interventions. On the other hand, seven studies reported additional complications such as eyelid ptosis and/or extraocular muscle weakness. Episodes of hematoma and mild hemorrhage were reported in five studies.

Severe adverse effects

The most significant adverse effects were recorded in case report studies, populations with medical history of comorbidities, or studies with over 5 years of follow-up. A total of seven cases reported severe pulmonary involvement due to embolisms that caused acute

respiratory distress syndrome, pulmonary hemorrhage, and/or alveolar hemorrhage. Moreover, eight studies recorded loss of visual acuity, temporary blindness, or permanent unilateral vision loss. Another eight studies presented immunological alterations such as granuloma formation, autoimmune syndromes, and reactivation of a herpes simplex virus infection. Five studies reported severe neurological symptoms, such as ataxia, vertigo, paralysis of the thoracic limbs, facial paralysis, etc., likely due to damage to the cerebellar region, hippocampus, and temporal cortex. Three papers reported notable cases of arterial occlusion; one causing severe necrosis and infection after hyaluronic acid injections on the nose and nasolabial folds, requiring prolonged treatment with antibiotics; the second generating visual loss due to ophthalmic artery obstruction after platelet-rich plasma injections into the face; and the third resulting in unilateral blindness after hyaluronic acid injections in the glabellar area. One case of kidney failure was reported in a participant after undergoing liquid silicone injection in the buttocks and hips. One study reported 4 hospitalizations and 8 deaths in a cohort of 28 patients who underwent filler injections done by unlicensed individuals. Finally, a report on Mexican and Colombian participants documented 64 deaths, 9 of which occurred immediately after lipo injections in the gluteal area. **Table 2** shows the summary of the most common adverse effects found in the population and their approximate incidence per 1000 interventions performed sorted in descending order.

DISCUSSION

In this work, we found various types of adverse effects reported in the medical literature after minimally invasive cosmetic procedures. Although the majority of recorded events

corresponded to mild and localized complications with a rapid resolution, the presence of more severe and sometimes fatal complications pose a significant potential risk and calls for a responsible use of these procedures. The studies that reported the longest-lasting adverse effects were largely retrospective studies and clinical trials with follow-up periods extending beyond six months. This longer duration is critical for identifying late-onset complications that may not appear within the shorter follow-up periods commonly used in many studies. As a result, many of these complications may be underreported in the literature, since the delayed onset of these effects makes it difficult to establish a clear causal relationship between the procedure and the adverse outcomes^{13,15}. This issue is especially significant when considering that short-term patient satisfaction, along with the heavy promotion of these procedures as safe and effective, might lead both patients and healthcare providers to downplay or overlook the potential for long-term adverse effects associated with cosmetic interventions. The focus on immediate results can create a false sense of security, where the benefits seem to outweigh any potential risks, thereby obscuring the true safety profile of these procedures¹⁸.

Another significant finding of this review is that in almost all studies, women represented the predominant population undergoing these procedures. While it is increasingly common for men to undergo aesthetic procedures, previous studies indicate that the perception of artificial enhancement of appearance differs by sex, with men preferring specific and more discrete procedures such as jawline contouring and hair implants¹⁹. Furthermore, a significant number of patients were Asian, particularly of Korean origin. Previous studies indicate the persistence of rigid gender roles in Korean society, which

directly influence female self-esteem and personal well-being²⁰, as well as the expected beauty standards in this population²¹, which likely has a large impact in their use of cosmetic procedures.

The complications described in this review can be grouped into two broad categories: those unrelated to ischemia (pain, erythema, granulomas, infections, etc.), and those secondary to ischemia (arterial occlusion, necrosis, etc.)²². The former were the most prevalent type of complication in the review, including aesthetic alterations such as the formation of nodules and facial asymmetries. The latter can be subdivided into acute or chronic adverse effects. In this review, chronic complications were the most severe, often requiring multidisciplinary and even surgical intervention, as has been previously described for such complications²³. Factors associated with these complications are varied, including healthcare professional expertise²⁴, presence of chronic comorbidities, substance abuse²⁵, anatomical positioning of superficial blood vessels, and the molecular size of injected compounds²⁶. However, most studies were conducted on a healthy population that voluntarily underwent the intervention, so there might be factors or pathological conditions unaccounted for during recruitment that favored the occurrence of long-term complications.

In this review, the most frequently administered substances were hyaluronic acid, botulinum toxin, fat implants, and silicone. Although ultra pure hyaluronic acid is primarily obtained through recombinant DNA technology, contaminants in the stabilizers used in its formulation can generate a delayed immune response that predisposes participants to

fibrosis and granulomas²⁷, as reported in many studies. Interestingly, the commercial formulations described with greater detail were the ones associated with milder adverse effects, a potential explanation is that different hyaluronic acid formulations are designed for specific skin layers²⁸; thus, their correct choice and administration may reduce the risk of complications. Moreover, their incorrect use is particularly dangerous in certain highly vascularized anatomical areas, such as the glabella and the periorcular regions, where small superficial manipulations can trigger emboli formation^{29,30}. On the other hand, injections of botulinum toxin were reported in many studies in which granulomas, cellulitis, and other infections by atypical microorganisms (i.e., mycobacterium), were also present, which is consistent with previous reports^{31,32}. Significant complications were also recorded following the use of silicone, such as implant migration and autoimmune reactions. This can be due to minor contaminations in these implants, in which the presence of microorganisms along with the slow degradation of silicone compounds can favor chronic immune reactions that only become apparent after long follow-up periods³³.

Lastly, most hospital admission and deaths recorded were secondary to severe complications associated with embolism with arterial obstruction and involvement at the pulmonary, cerebral, and retinal levels. These events can occur after administration of any compound, but they were more common following injections of autologous fat implants and some types of hyaluronic acid formulations. Although fat implants undergo comprehensive filtration processes³⁴, migration through the bloodstream remains a significant risk associated with their application³⁵. On the other hand, the higher viscosity and hydrophilicity of hyaluronic acid formulations facilitates its adhesion to vascular walls,

increasing the risk of vascular-related complications³⁶. Although it is believed that negative aspiration before injection may reduce risk, in reality complications can still occur due to a combination of factors such as perivascular injuries or anatomical positioning, which can favor the release of the administered compound into the bloodstream³⁷. In this regard, a thorough knowledge of injection site anatomy and patient history (e.g., presence of chronic conditions and allergies, use of blood thinners), a correct injection technique, and the application of adequate antiseptic procedures with non-irritating substances are more reliable safety measures to prevent undesirable adverse effects³⁸. Additionally, the use of ultrasound in these interventions should be considered as a safer approach, offering enhanced precision and potentially reducing the risk of complications.³⁹

In conclusion, minimally invasive aesthetic procedures, while popular, can result in adverse effects of varying severity. The possibility of unnoticed long-term effects poses an additional concern for both users and healthcare professionals. To minimize risks, it is highly recommended to reduce patient risk factors and enhance procedural accuracy through techniques such as ultrasound guidance. Finally, ensuring that these procedures are exclusively performed by qualified medical personnel is crucial to maintaining patient safety and the overall integrity of the field.

FUNDING: No funding was received.

AVAILABILITY OF DATA AND MATERIALS: The datasets used and/or analyzed during the current study are available from the corresponding author upon reasonable request.

AUTHOR CONTRIBUTIONS: CGBM, EBP, FCB, AABN, and KGRN were jointly involved in selecting and reviewing the resources, as well as in drafting and structuring the manuscript. CGBM was responsible for the conception, integration, and final structuring of the manuscript.

ETHICAL APPROVAL AND CONSENT TO PARTICIPATE: Not applicable. This study only uses non-identifiable patient information.

CONSENT FOR PUBLICATION: Not applicable. The publication of these data does not compromise the anonymity or confidentiality of any patient.

CONFLICT OF INTERESTS: The authors declare that they have no conflict of interests.

TABLES AND FIGURES

Table 1. Summary of Analyzed Resources.

No.	AUTHORS AND REF.	STUDY TYPE	SAMPLE SIZE	POPULATION CHARACTERISTICS	FOLLOW-UP PERIOD	PROCEDURE AND MATERIAL	ANATOMIC REGION	ADVERSE EVENTS
1	Fino et al. ⁴⁰	RCT	65	Participants with chronic comorbidities	>6 months	Hyaluronic acid filler injection.	Face.	Local symptoms.
2	Han et al. ⁴¹	Case report	1	Older age woman	N/A	Hyaluronic acid filler injection.	Vaginal wall.	Acute respiratory distress syndrome with alveolar hemorrhage.
3	Calonge et al. ⁴²	Case report	1	Older age woman	N/A	Carbon dioxide mesotherapy	Both thighs.	Massive subcutaneous emphysema.
4	Curi et al. ⁴³	Case series	2	Older age women	N/A	Hyaluronic acid filler injection.	Lips and cheeks.	Case 1: Local symptoms. Case 2: Systemic inflammatory response syndrome.
5	Martin et al. ⁴⁴	Case report	1	Adult man with untreated schizophrenia	N/A	Self-injections of hyaluronic acid.	Cheeks (malar region).	Periorbital edema with localized depigmentation.
6	Kaminaga kura et al. ⁴⁵	Case report	1	Woman with a controlled chronic disease	N/A	Autologous fat injection.	Upper lip.	Nodules and deformity.
7	Lee et al. ⁴⁶	RCT	20	Korean participants	24 weeks	Filler injections (PMMA and cross-linked dextran in hydroxy-propyl methyl-cellulose).	Nasolabial folds.	Local symptoms.
8	Choi et al. ⁴⁷	RCT	66	Participants with facial asymmetry	24 weeks	Hyaluronic acid filler injection.	Nasolabial folds.	Local symptoms.
9	Choi et al. ⁴⁸	Case series	6	Healthy participants	N/A	Hyaluronic acid filler injection.	Nasolabial folds, nasal tip, nose.	Arterial occlusion, dermal necrosis, cellulitis that required prolonged therapy with antibiotics.
10	Moradi et al. ⁴⁹	RCT	90	Patients with hand deformities	24 weeks	Hyaluronic acid filler injection.	Dorsum of both hands.	Local symptoms.

11	Blanco et al. ⁵⁰	Case report	1	Young woman	N/A	Silicone injection.	Glutes.	Acute respiratory distress syndrome with alveolar hemorrhage.
12	Camuzard et al. ⁵¹	Case report	1	Older age woman	N/A	Liquid silicone injection.	Buttocks and hips.	Glute deformity, dehydration, nausea and vomiting. Acute kidney failure.
13	Roberts & Arthurs ⁵²	Case report	1	Adult man with HIV	N/A	Poly-(L)-Lactic Acid filler injection.	Nasal and periorbital area.	Visual loss due to severe hemorrhage.
14	López et al. ⁵³	RCS	63	Healthy participants	6 months	Hyaluronic acid filler injection.	Face.	Local symptoms.
15	Carella et al. ⁵⁴	Case report	1	Transsexual woman	N/A	Liquid silicone injection.	Buttocks.	Cellulitis, lumps and multiresistant <i>E. coli</i> infection.
16	Apostolou et al. ⁵⁵	Brief report	8	Healthy Black women	N/A	Filler injections with unknown substances ("hydrogel," "botulinum toxin," "silicone," "gel filler", "biogel").	Buttocks.	Severe cellulitis due to <i>Nocardia</i> spp. infection.
17	Downie et al. ⁵⁶	RCT	88	Fitzpatrick > IV participants	24 weeks	Liquid silicone injection.	Nasolabial folds.	Hypo- and hyper-pigmentation.
18	Lee et al. ⁵⁷	RCT	36	Fitzpatrick III-IV participants	2 years	Botulinum Toxin A injection.	Forehead area (sparing supraorbital rim).	Local symptoms.
19	Chang et al. ⁵⁸	Case report	1	Older age woman	N/A	Botulinum Toxin A injection.	Forehead, glabella, and outer corners of the eyes (crow's feet).	Periorbital erythema, edema and pain.
20	Min et al. ⁵⁹	RCT	25	Healthy participants	28 days	Fractional CO2 laser therapy plus platelet rich plasma.	Face.	Localized erythema.
21	Lee et al. ⁶⁰	RCT	34	Healthy participants	1.5 months	Polynucleotide and hyaluronic acid filler injection.	Periorbital area.	Local symptoms.
22	Alaraj et al. ⁶¹	Case report	1	Older age woman	N/A	Botulinum Toxin A injection.	Right eyebrow.	Ptosis, localized pain and facial asymmetry.
23	Alijotas-Rieg et al. ⁶²	Case report	1	Older age woman	N/A	Hyaluronic acid filler injection.	Nasolabial folds, lips, and cheeks	Facial edema, inflammatory nodules.

24	Bohnert et al. ⁶³	RCT	40	Healthy participants	40 weeks	Poly-(L)-Lactic Acid filler injection.	Face.	Localized pain.
25	Zhao et al. ⁶⁴	RCT	160	Healthy participants	2 years	Polycaprolactone injection.	Nasolabial folds.	Pigmentary abnormalities.
26	Nacopoulos & Vesala ⁶⁵	NRCT	23	Healthy participants	4 months	Plasma rich fibrin injection.	Nasolabial folds and oral commissures.	Local symptoms.
27	Jeong et al. ⁶⁶	RCT	58	Healthy participants	12 weeks	Polycaprolactone and polynucleotide filler injection.	Crow's feet.	Local symptoms.
28	Reeds et al. ⁶⁷	RCT	13	Healthy participants	12 months	Phosphatidylcholine and deoxycholate injections	Lower abdomen subcutaneous tissue.	Local symptoms.
29	Beer et al. ⁶⁸	RCT	219	Healthy participants	6 months	Hyaluronic acid filler injection.	Lip and perioral area.	Local symptoms, cephalaea.
30	Bertucci et al. ⁶⁹	RCT	600	Healthy participants	36 weeks	DaxibotulinumtoxinA injection.	Forehead (corrugator/procerus muscles).	Local symptoms.
31	Rzany et al. ⁷⁰	RCT	363	Healthy participants	4 weeks	Deoxycholic acid injection.	Submental fat.	Local symptoms.
32	Jilani et al. ⁷¹	Case report	1	Adult woman	N/A	Liquid silicone injection.	Breasts and buttocks.	Granulomatosis with systemic migration and inflammation.
33	Choi et al. ⁷²	RCT	10	Healthy women	24 weeks	Intradermal radiofrequency plus hyaluronic acid filler injection.	Nasolabial folds.	Local symptoms.
34	Demir et al. ⁷³	Case series	21	Mostly healthy women	58 months	Injection of hydroxyethylmethacrylate particles suspended in hyaluronic acid.	Face (glabella, nasolabial folds, cheeks, lips, perioral area, chin).	Local symptoms. Two cases of abdominal pain and bronchial infection.
35	Siperstein et al. ⁷⁴	RCT	15	Healthy participants	3 months	Hyaluronic acid filler injection.	Cheeks.	Local symptoms.
36	Araco et al. ⁷⁵	RCT	60	Healthy participants	6 months	Polynucleotide plus hyaluronic acid filler injection.	Nasolabial folds.	Local symptoms.
37	Joo et al. ⁷⁶	RCT	60	Healthy participants	3 months	Hyaluronic acid filler injection.	Nasolabial folds.	Local symptoms.

38	Kim et al. ⁷⁷	RCT	24	Healthy participants	12 weeks	Botulinum toxin A.	Cheeks.	Local symptoms.
39	Leonardis & Palange. ⁷⁸	Retrospective study	350	Healthy participants	36 months	Carboxymethylcellulose	Nasolabial folds.	Local symptoms.
40	Lorenc et al. ⁷⁹	NRCT	52	Healthy participants	1 mes	Hyaluronic acid filler injection.	Nasolabial folds.	Local symptoms.
41	Nisi et al. ⁸⁰	RCT	40	Healthy participants	1 mes	Hyaluronic acid plus CO2 injection.	Nasolabial folds.	Local symptoms.
42	Park et al. ⁸¹	Case series	5	Korean participants	12 weeks	PNT filler injection.	Cheeks.	Local symptoms.
43	Shin et al. ⁸²	RCT	20	Korean participants	24 weeks	Dextran filler injection.	Nasolabial folds.	Local symptoms.
44	Hachach-Haram et al. ⁸³	Case report	1	Older age woman	N/A	Self injections of unknown filler (assumed hyaluronic acid).	Nasolabial folds.	Local symptoms.
45	Few et al. ⁸⁴	RCT	235	Healthy participants	2 years	Hyaluronic acid filler injection.	Midface.	Local symptoms.
46	Galadari et al. ⁸⁵	RCT	40	Adult participants	1 year	Polycaprolactone and hyaluronic acid filler injection.	Nasolabial folds.	Local symptoms.
47	Hatcher & Goldman ⁸⁶	Case report	1	Older age woman	N/A	Hyaluronic acid filler injection.	Nasolabial folds.	Local symptoms.
48	Jones et al. ⁸⁷	RCT	282	Healthy participants	24 months	Hyaluronic acid filler injection.	Midface.	Local symptoms.
49	Alsuhaibani & Alfawaz ⁸⁸	Case series	3	Older age woman	N/A	Polyalkylimide filler injection.	Malar area.	Local symptoms.
50	Seok et al. ⁸⁹	Case report	1	Young woman	1 semana	Hyaluronic acid filler injection.	Nasolabial folds.	Local symptoms, dermal necrosis.
51	Chayangsu et al. ⁹⁰	RCS	40	Healthy participants	10 years	Legal and illegal filler injection.	Face, abdomen, hands.	Local symptoms, dermal necrosis, one case of <i>mycobacterium</i> infection.
52	Kerfant et al. ⁹¹	Case report	1	Young woman	N/A	Hypertonic saline injection.	Lower abdomen.	Skin necrosis.
53	Kim et al. ⁹²	Case report	1	Young woman	N/A	Autologous fat injection.	Cheeks.	Dystrophic calcifications, erythematous papules on both cheeks.
54	Maione et al. ⁹³	RCS	1000	Healthy participants	1 mes	Autologous fat injection.	Different body regions.	Local symptoms, infection.

55	Polat & Üstün et al. ⁹⁴	Case report	1	Older age woman	N/A	Phosphatidylcholine mesotherapy injections.	Abdomen and lower limbs.	Infected nodules and cellulitis.
56	Suh et al. ⁹⁵	RCS	31	Healthy participants	2 years	Polydioxanone thread lifting.	Face.	Localized pain and nodules causing facial asymmetry.
57	Berguiga & Galatoire ⁹⁶	RCT	101	Healthy participants	11 months	Hyaluronic acid filler injection.	Tear trough area (nasojugal groove), crow's feet, glabella.	Localized pain and hemorrhage.
58	Wünscher et al. ⁹⁷	Case report	1	Older age woman	N/A	Aquafilling injections (copolyamide with sodium chloride solution).	Gluteal region.	Localized pain, deformity, multiple abscesses.
59	Martínez-López et al. ⁹⁸	Case report	1	Older age woman	N/A	Filler injections (liquid silicone).	Supraorbital region and nasolabial folds.	Subcutaneous nodules.
60	Fabi et al. ⁹⁹	NRCT	2,691	Predominantly White women	28 months	DaxibotulinumtoxinA injection.	Forehead (corrugator/procerus muscles).	Local symptoms and ptosis.
61	Kim et al. ¹⁰⁰	Case report	1	Young woman	N/A	Filler injection.	From the glabella to the nasal tip.	Skin necrosis of the nasal tip.
62	Grippaudo et al. ¹⁰¹	NRCT	26	Participants with a previous filler injection	4 years	Filler injections (collagen, hyaluronic acid, silicone, polyalkylimide/polyacrylamide gel).	Lips.	Localized pain and deformity requiring surgery.
63	Hexsel et al. ¹⁰²	RCT	80	Healthy woman	1 year	Botulinum toxin A.	Forehead.	Localized pain, sensitivity and erythema. Ptosis and hematomas.
64	Szantyr et al. ¹⁰³	Case report	1	Young man with previous anterior cranial fossa and naso-orbital fractures	N/A	Autologous fat injection.	Left supraorbital and right forehead area.	Intense eye pain, phosphenes y acute visual loss.
65	Kim et al. ¹⁰⁴	RCS	1819	Healthy participants	6 years	Botulinum toxin A injection.	Face and neck.	Local symptoms, hemifacial weakness, drooling, and ptosis.

66	Kim et al. ¹⁰⁵	Case report	1	Healthy participants	N/A	Hyaluronic acid filler injection.	Nasal dorsum.	Temporary blindness, ocular muscle weakness, ptosis.
67	Noh et al. ¹⁰⁶	PCS	72	Healthy participants	2 years	Hyaluronic acid filler injection.	Nasolabial folds.	Local symptoms, hematomas and hemorrhage.
68	Roh et al. ¹⁰⁷	RCT	24	Asian participants	4 months	Hyaluronic acid filler injection.	Lower cheeks.	Erythema, bruising.
69	Ibrahim et al. ¹⁰⁸	RCT	68	Healthy participants	3 months	Platelet rich plasma injection or microdermabrasion.	Various anatomical regions (abdomen, groin, arm, thigh, leg, shoulder, back).	Localized pain and hematomas.
70	Mahmood-Faris ¹⁰⁹	RCS	500	Healthy female participants	N/A	Filler injection.	Lips, malar, nasolabial, tear trough, jawline, glabella, nose, temple, or chin.	Ecchymosis, numbness, edema, local pain, and skin necrosis.
71	Singarajah et al. ¹¹⁰	Case report	1	Healthy man	N/A	Self injections of liquid silicone.	Genitalia.	Pulmonary embolism.
72	Essenmacher et al. ¹¹¹	Case report	1	Young woman	N/A	Liquid silicone injections.	Buttocks.	Acute respiratory distress syndrome and hemoptysis.
73	Jang et al. ¹¹²	Case report	1	Young woman	N/A	Hyaluronic acid filler injection.	Forehead and right cheek.	Pulmonary embolism and severe hemorrhage.
74	Shaheen et al. ¹¹³	Case report	1	Young woman	N/A	Filler injection.	Gluteal area.	Pulmonary embolism with cardiac arrest, death.
75	Kim et al. ¹¹⁴	Case report	1	Young woman	N/A	Hyaluronic acid filler injection.	Right eyelid, anterior chamber of the eye.	Temporary blindness (corrected after surgery).
76	Salval et al. ¹¹⁵	Case report	1	Young woman	N/A	Filler injection (assumed to be hyaluronic acid).	Forehead and nasal tip.	Temporary blindness and facial necrosis.
77	Kwon et al. ¹¹⁶	Case report	1	Young woman	N/A	Hyaluronic acid filler injection.	Nasal dorsum.	Eye pain, partial vision loss, and cephalgia during 6 months.
78	Hsieh et al. ¹¹⁷	Case series	2	Adult women (one of them with controlled hepatitis B virus infection)	N/A	Calcium hydroxylapatite injections.	1: Glabellar area. 2: Nasal bridge.	1: Localized pain and temporary blindness. 2: Permanent visual loss.
79	Karam et al. ¹¹⁸	Case series	4	Healthy older age women	N/A	Platelet-rich plasma injection.	Face, hand, neck, forehead, glabellar area,	Visual loss, arterial occlusion, cephalgia,

							nasolabial fold, external canthus of the eye.	edema and dermal necrosis.
80	Madala et al. ¹¹⁹	Case report	1	Young woman	N/A	Platelet-rich plasma injection.	Forehead.	Exophthalmos requiring enucleation, nausea and vomiting, temporary loss of consciousness, permanent visual loss.
81	Wang et al. ¹²⁰	Case report	1	Young woman	N/A	Hyaluronic acid filler injection.	Nose.	Reactivation of Herpes virus infection on the nose.
82	Park et al. ¹²¹	Case series	3	Adult women	N/A	Cryopreserved autologous fat injection.	Forehead.	Lipogranuloma and edema in eyelid and periorbital region.
83	Seok et al. ¹²²	Case series	3	Older age women	N/A	Filler injections (unknown materials).	Forehead, face, dorsum of the hands.	Facial granulomatous reactions presenting as erythematous edema.
84	Seo & Sa ¹²³	Case series	27	Healthy women	4 years	Autologous fat injection.	Face (forehead, cheek, tear trough, glabella, upper eyelid).	Periorbital lipogranulomas.
85	Joseph et al. ¹²⁴	NRCT	42	White women	7 months	Polymethylmethacrylate collagen gel filler injection.	Face.	Hematomas and hypersensitivity reactions on the skin.
86	Li et al. ¹²⁵	PCS	9	Women	3 months	Illegal injections of Botulinum toxin type A.	Face (forehead, ocular area, masseter muscle), leg (gastrocnemius muscle).	Abnormal cerebellar activity, ataxia, hippocampal disturbances.
87	Lee et al. ¹²⁶	Case report	1	Healthy woman	N/A	Hyaluronic acid filler injection.	Glabella.	Stroke causing left eye blindness, motor deficit in pelvic and thoracic limbs, quadriparesis, and prolonged bleeding.
88	Wang et al. ¹²⁷	Case report	1	Young woman	N/A	Autologous fat injection.	Face (temporal and frontal regions).	Arterial embolism, aphasia, neurological disturbances, hemiplegia, and blindness.
89	Davidova et al. ¹²⁸	Case report	1	Older age woman	N/A	Hyaluronic acid filler injection.	Glabella.	Ophthalmic artery occlusion.
90	Mayer et al. ¹²⁹	Brief report	28	Healthy participants	N/A	Filler injections (botulinum toxin, silicone, etc.)	Face, buttocks	Ptosis, scarring, hospital admission, death.

						done by unlicensed individuals.		
91	Cárdenas-Camarena et al. ¹³⁰	RCS	64	Participants from Mexico and Colombia	10 years	Lipoinjection.	Gluteal area.	All subjects died from fat embolism: 9 immediately, 5 after the injection, and the rest after 24 hours.
92	Yoo et al. ¹³¹	Case report	1	Older age woman	N/A	Repeated filler injection.	Face	M. wolinsky soft tissue infection on the right cheek
93	Gan et al. ¹³²	Case report	1	Older age women	NA	Filler injection.	Both temples (temporal scalps).	Alopecia and pain in the right temporal scalp.
94	Jung et al. ¹³³	RCT	88	Moderate to severe age-related midface volume deficit	24 weeks	Filler injection.	Both sides of the face.	Local symptoms (most common: swelling, mass, pain, bruising).
95	Nikolis et al. ¹³⁴	RCT	10	Female participants	28 days	Filler injection.	Both nasolabial folds.	Local symptoms (most common: pain, bumpiness, edema, ecchymosis, erythema).
96	Kamouna et al. ¹³⁵	Case series	6	Young females	N/A	Lip augmentation with vitamins A/E	Lips.	Lipogranulomas (painful swelling with induration of the lips and perioral area).
97	Braccini et al. ¹³⁶	RCT	98	Male and female participants	18 months	Filler injection.	Face.	Local symptoms (most common: pain, erythema, hematoma).
98	Li et al. ¹³⁷	RCT	162	Chinese participants	24 weeks	Hyaluronic acid filler injection.	Nasal dorsum, columella, or anterior nasal spine.	Local symptoms (most common: tenderness, swelling, firmness, redness).

RCT: Randomized Controlled Trial, RCS: Retrospective Cohort Study, PCS: Prospective Cohort Study, NRCT:

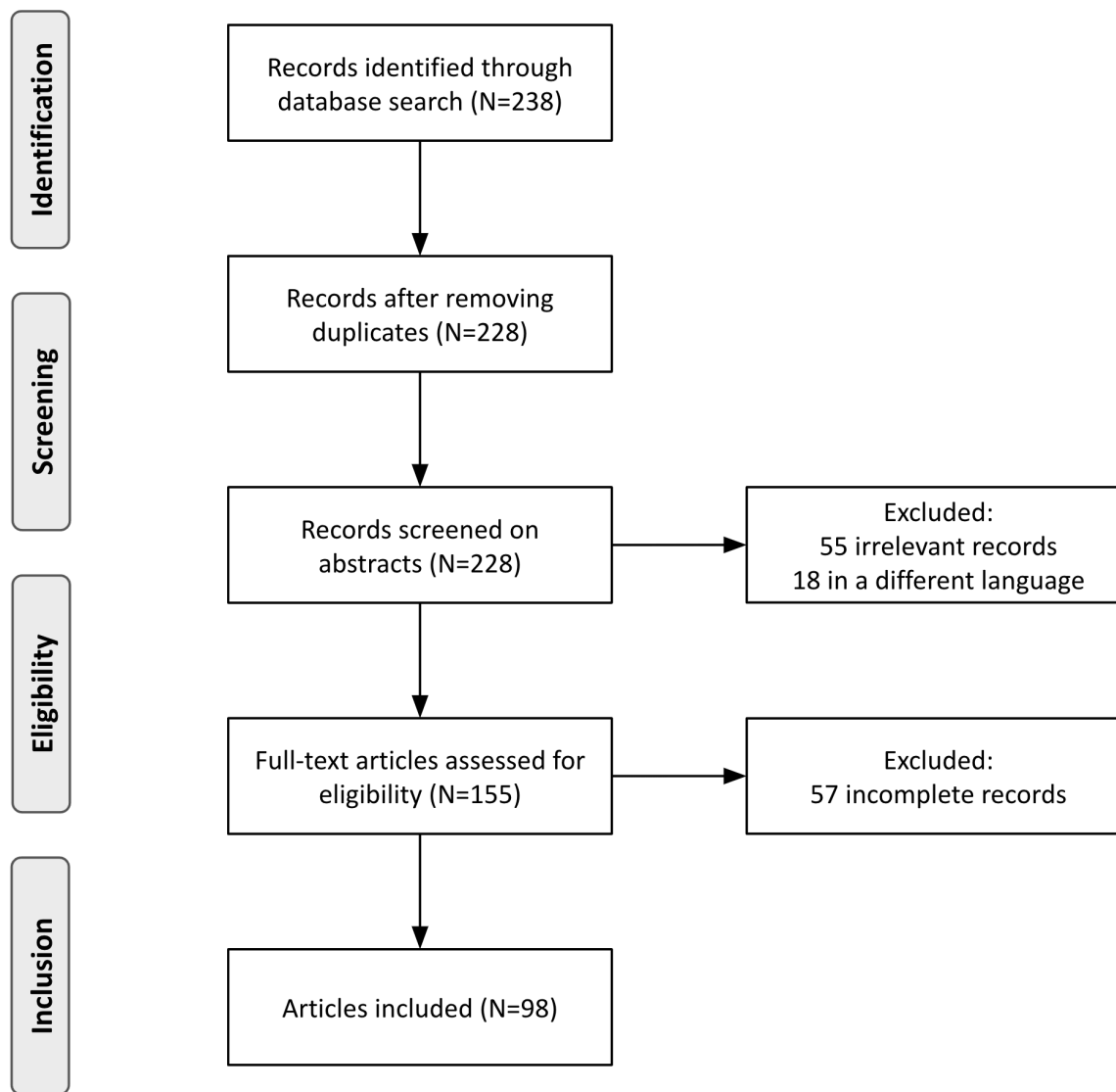
Non-randomized Controlled Trial

Table 2. Incidence of Adverse Events per 1000 Procedures Performed in the Population.

Adverse event	Occurrences per 1000 Procedures
Local complications (pain, erythema, edema, temporary deformity, hypersensitivity)	363.308
Subcutaneous hemorrhage, hematomas	55.127
Asymmetry due to nodules, lumps, or calcifications, with non-aesthetic results	28.443
Pigmentary disturbances	12.022
Fatal fat embolism	7.135
Subocclusion or occlusion of the ophthalmic artery	5.865
Blepharoptosis	5.376
Temporal blindness	3.03
Cellulitis	1.173
Dermal and annex necrosis	0.977
Permanent blindness	0.684
Cerebral infarction	0.489
Acute respiratory distress syndrome	0.489
Pulmonary hemorrhage	0.391
Mycobacterial infection	0.391
Pulmonary embolism	0.293
Severe autoimmune reaction	0.293
Severe bronchial infection	0.195
Reactivation of herpes virus infection	0.098
Livedo Racemosa	0.098
Acute kidney injury	0.098

The adverse effects presented correspond to the total number of interventions performed, without specific distinction of the procedure or technique implemented.

Figure 1. Summary of research strategy



REFERENCES

1. Laughter MR, Anderson JB, Maymone MBC, Kroumpouzou G. Psychology of aesthetics: Beauty, social media, and body dysmorphic disorder. *Clin Dermatol*. 2023;41(1):28–32.
2. Carella F, Degli Esposti L, Adamiano A, Iafisco M. The Use of Calcium Phosphates in Cosmetics, State of the Art and Future Perspectives. *Materials (Basel)*. 2021 Oct 25;14(21):6398.
3. Feng L, Zhai X. Regulation concerns of supply and demand sides for aesthetic medicine from Chinese perspective. *Dev World Bioeth*. 2023 Sep;23(3):277–84.
4. Haut C. [New technologies for noninvasive aesthetic treatments]. *Dermatologie (Heidelb)*. 2023 Oct;74(10):759–64.
5. Moradi A, Watson J. Current Concepts in Filler Injection. *Facial Plast Surg Clin North Am*. 2015 Nov;23(4):489–94.
6. Zeplin PH, Sukhova I, Kranz A, Nürnberger T, Mihalceanu S, Beescho C, et al. Recombinant Silk Hydrogel as a Novel Dermal Filler Component: Preclinical Safety and Efficacy Studies of a New Class of Tissue Fillers. *Aesthet Surg J*. 2020 Aug 14;40(9):NP511–8.
7. Valachová K, Šoltés L. Hyaluronan as a Prominent Biomolecule with Numerous Applications in Medicine. *Int J Mol Sci*. 2021 Jun 30;22(13):7077.
8. Jankovic J. Botulinum toxin: State of the art. *Mov Disord*. 2017 Aug;32(8):1131–8.
9. Amiri R, Khalili M, Iranmanesh B, Ahramiyanpour N, Karvar M, Aflatoonian M. The innovative application of autologous biofillers in aesthetic dermatology. *Ital J Dermatol Venerol*. 2023 Aug;158(4):321–7.
10. Vyas KS, Kaufman J, Munavalli GS, Robertson K, Behfar A, Wyles SP. Exosomes: the latest in regenerative aesthetics. *Regen Med*. 2023 Feb;18(2):181–94.
11. Dorozhkin SV. Calcium Orthophosphates as Bioceramics: State of the Art. *J Funct Biomater*. 2010 Nov 30;1(1):22–107.
12. Sergi R, Bellucci D, Cannillo V. A Review of Bioactive Glass/Natural Polymer Composites: State of the Art. *Materials (Basel)*. 2020 Dec 6;13(23):5560.
13. Rogiers V, Benfenati E, Bernauer U, Bodin L, Carmichael P, Chaudhry Q, et al. The way forward for assessing the human health safety of cosmetics in the EU - Workshop proceedings. *Toxicology*. 2020 Apr 30;436:152421.
14. Urdiales-Gálvez F, Delgado NE, Figueiredo V, Lajo-Plaza JV, Mira M, Moreno A, et al. Treatment of Soft Tissue Filler Complications: Expert Consensus Recommendations. *Aesthetic Plast Surg*. 2018 Apr;42(2):498–510.
15. Colon J, Mirkin S, Hardigan P, Elias MJ, Jacobs RJ. Adverse Events Reported From Hyaluronic Acid Dermal Filler Injections to the Facial Region: A Systematic Review and Meta-Analysis. *Cureus*. 15(4):e38286.
16. Mannino M, Lupi E, Bernardi S, Becelli R, Giovannetti F. Vascular complications with necrotic lesions following filler injections: Literature systematic review. *J Stomatol Oral Maxillofac Surg*. 2023 May 12;101499.
17. Styperek A, Bayers S, Beer M, Beer K. Nonmedical-grade Injections of Permanent Fillers: Medical and Medicolegal Considerations. *J Clin Aesthet Dermatol*. 2013 Apr;6(4):22–9.
18. Cho Chung HI, Kim YA. Perception of cosmetic surgery and associated side effects. *Medicine (Baltimore)*. 2022 Jan 21;101(3):e28641.
19. Rostovtseva VV, Butovskaya ML, Mezentseva AA, Weissing FJ. Effects of sex and sex-related facial traits on trust and trustworthiness: An experimental study. *Front Psychol*. 2023 Jan 5;13:925601.

20. Li J, Liu Y, Song J. The Relationship Between Gender Self-Stereotyping and Life Satisfaction: The Mediation Role of Relational Self-Esteem and Personal Self-Esteem. *Front Psychol.* 2022 Jan 7;12:769459.
21. Kim SY, Seo YS, Baek KY. Face consciousness among South Korean women: a culture-specific extension of objectification theory. *J Couns Psychol.* 2014 Jan;61(1):24–36.
22. Witmanowski H, Błochowiak K. Another face of dermal fillers. *Postepy Dermatol Alergol.* 2020 Oct;37(5):651–9.
23. Ghareeb FM, Hassan MSA, El Nahas MA, Salem MSES. Complicated Facial Fillers: Management Algorithm. *Plast Reconstr Surg Glob Open.* 2022 Jul;10(7):e4445.
24. Galanis C, Sanchez IS, Roostaeian J, Crisera C. Factors influencing patient interest in plastic surgery and the process of selecting a surgeon. *Aesthet Surg J.* 2013 May;33(4):585–90.
25. Schlager JG, Hartmann D, Wallmichrath J, Ruiz San Jose V, Patzer K, French LE, et al. Patient-dependent risk factors for wound infection after skin surgery: A systematic review and meta-analysis. *Int Wound J.* 2022 Nov;19(7):1748–57.
26. Kato JM, Matayoshi S. Visual loss after aesthetic facial filler injection: a literature review on an ophthalmologic issue. *Arq Bras Oftalmol.* 2022;85(3):309–19.
27. López Pérez V. COVID-19 and Dermal Fillers: Should We Really Be Concerned? *Actas Dermosifiliogr.* 2022 Oct;113(9):888–94.
28. Kapoor KM, Saputra DI, Porter CE, Colucci L, Stone C, Brenninkmeijer EEA, et al. Treating Aging Changes of Facial Anatomical Layers with Hyaluronic Acid Fillers. *Clin Cosmet Investig Dermatol.* 2021;14:1105–18.
29. Zein M, Tie-Shue R, Pirakitikulr N, Lee WW. Complications after cosmetic periorcular filler: prevention and management. *Plast Aesthet Res.* 2020;7:44.
30. Wang HC, Yu N, Wang X, Dong R, Long X, Feng X, et al. Cerebral Embolism as a Result of Facial Filler Injections: A Literature Review. *Aesthet Surg J.* 2022 Feb 15;42(3):NP162–75.
31. Machado RA, Oliveira LQ, Martelli-Júnior H, Pires FR, Carvas JB, Rogerio VE, et al. Adverse reactions to the injection of face and neck aesthetic filling materials: a systematic review. *Med Oral Patol Oral Cir Bucal.* 2023 May 1;28(3):e278–84.
32. Wong SSY, Wong SCY, Yuen KY. Infections associated with body modification. *J Formos Med Assoc.* 2012 Dec;111(12):667–81.
33. Trinh LN, McGuigan KC, Gupta A. Delayed Granulomas as a Complication Secondary to Lip Augmentation with Dermal Fillers: A Systematic Review. *Surg J (N Y).* 2022 Jan;8(1):e69–79.
34. Simonacci F, Bertozzi N, Grieco MP, Grignaffini E, Raposio E. Procedure, applications, and outcomes of autologous fat grafting. *Ann Med Surg (Lond).* 2017 Aug;20:49–60.
35. Schiraldi L, Sapino G, Meuli J, Maruccia M, Cherubino M, Raffoul W, et al. Facial Fat Grafting (FFG): Worth the Risk? A Systematic Review of Complications and Critical Appraisal. *J Clin Med.* 2022 Aug 11;11(16):4708.
36. Sun Y, Nie F, Wang G, Li Q, Xie H. An experimental study of the vascular embolism caused by recombinant type III collagen implants and hyaluronic acid. *J Cosmet Dermatol.* 2023 Oct;22(10):2705–13.
37. Goodman GJ, Magnusson MR, Callan P, Roberts S, Hart S, Lin F, et al. Aspiration Before Tissue Filler—An Exercise in Futility and Unsafe Practice. *Aesthet Surg J.* 2021 Jan 29;42(1):89–101.
38. Goodman GJ, Liew S, Callan P, Hart S. Facial aesthetic injections in clinical practice: Pretreatment and posttreatment consensus recommendations to minimise adverse outcomes. *Australas J Dermatol.* 2020 Aug;61(3):217–25.
39. Heydenrych I, De Boule K, Kapoor KM, Bertossi D. The 10-Point Plan 2021: Updated Concepts for Improved Procedural Safety During Facial Filler Treatments. *Clin Cosmet Investig Dermatol.* 2021;14:779–814.

40. Fino P, Toscani M, Grippaudo FR, Giordan N, Scuderi N. Randomized Double-Blind Controlled Study on the Safety and Efficacy of a Novel Injectable Cross-linked Hyaluronic Gel for the Correction of Moderate-to-Severe Nasolabial Wrinkles. *Aesthetic Plast Surg.* 2019 Apr;43(2):470–9.
41. Han SW, Park MJ, Lee SH. Hyaluronic acid-induced diffuse alveolar hemorrhage: unknown complication induced by a well-known injectable agent. *Ann Transl Med.* 2019 Jan;7(1):13.
42. Calonge WM, Lesbros-Pantoflickova D, Hodina M, Elias B. Massive subcutaneous emphysema after carbon dioxide mesotherapy. *Aesthetic Plast Surg.* 2013 Feb;37(1):194–7.
43. Curi MM, Cardoso CL, Curra C, Koga D, Benini MB. Late-onset adverse reactions related to hyaluronic Acid dermal filler for aesthetic soft tissue augmentation. *J Craniofac Surg.* 2015 May;26(3):782–4.
44. Martin DS, Han H, Farley KL. Self Injection of Topical Skin Preparation by Patient Seeking Facial Volume Enhancement: A Case Report. *J Clin Aesthet Dermatol.* 2019 Aug;12(8):51–4.
45. Kaminagakura E, Rosa JA, Carvalho YR, Almeida JD. Undesirable effect of cosmetic lip augmentation with autologous fat tissue. *BMC Res Notes.* 2013 Mar 5;6:79.
46. Lee YB, Song EJ, Kim SS, Kim JW, Yu DS. Safety and efficacy of a novel injectable filler in the treatment of nasolabial folds: polymethylmethacrylate and cross-linked dextran in hydroxypropyl methylcellulose. *J Cosmet Laser Ther.* 2014 Aug;16(4):185–90.
47. Choi WJ, Han SW, Kim JE, Kim HW, Kim MB, Kang H. The Efficacy and Safety of Lidocaine-Containing Hyaluronic Acid Dermal Filler for Treatment of Nasolabial Folds: A Multicenter, Randomized Clinical Study. *Aesthetic Plast Surg.* 2015 Dec;39(6):953–62.
48. Choi SY, Shin SH, Seok J, Yoo KH, Kim BJ. Management strategies for vascular complications in hyaluronic acid filler injections: A case series analysis. *J Cosmet Dermatol.* 2023 Dec;22(12):3261–7.
49. Moradi A, Allen S, Bank D, Marmur E, Fagien S, Glaser DA, et al. A Prospective, Multicenter, Randomized, Evaluator-Blinded, Split-Hand Study to Evaluate the Effectiveness and Safety of Large-Gel-Particle Hyaluronic Acid with Lidocaine for the Correction of Volume Deficits in the Dorsal Hand. *Plast Reconstr Surg.* 2019 Oct;144(4):586e–96e.
50. Blanco J, Gaines S, Arshad J, Sheele JM. Silicone pneumonitis, diffuse alveolar hemorrhage and acute respiratory distress syndrome from gluteal silicone injections. *Am J Emerg Med.* 2018 Dec;36(12):2340.e3-2340.e4.
51. Camuzard O, Dumas P, Foissac R, Fernandez J, David S, Balaguer T, et al. Severe granulomatous reaction associated with hypercalcemia occurring after silicone soft tissue augmentation of the buttocks: a case report. *Aesthetic Plast Surg.* 2014 Feb;38(1):95–9.
52. Roberts SAI, Arthurs BP. Severe visual loss and orbital infarction following periorbital aesthetic poly-(L)-lactic acid (PLLA) injection. *Ophthalmic Plast Reconstr Surg.* 2012;28(3):e68-70.
53. López PV, García PT, López-Pitalúa JA, Pinto H. Side effects after hyaluronic acid facial injection in adults during COVID-19 pandemic. *J Cosmet Dermatol.* 2023 Jun;22(6):1714–9.
54. Carella S, Romanzi A, Ciotti M, Onesti MG. Skin ulcer: a long-term complication after massive liquid silicone oil infiltration. *Aesthetic Plast Surg.* 2013 Dec;37(6):1220–4.
55. Apostolou A, Bolcen SJ, Dave V, Jani N, Lasker BA, Tan CG, et al. *Nocardia cyriacigeorgica* infections attributable to unlicensed cosmetic procedures--an emerging public health problem? *Clin Infect Dis.* 2012 Jul;55(2):251–3.
56. Downie JB, Grimes PE, Callender VD. A multicenter study of the safety and effectiveness of hyaluronic acid with a cohesive polydensified matrix for treatment of nasolabial folds in subjects with Fitzpatrick skin types IV, V, and VI. *Plast Reconstr Surg.* 2013 Oct;132(4 Suppl 2):41S-47S.

57. Lee SH, Min HJ, Kim YW, Cheon YW. The Efficacy and Safety of Early Postoperative Botulinum Toxin A Injection for Facial Scars. *Aesthetic Plast Surg*. 2018 Apr;42(2):530–7.
58. Chang YS, Chang CC, Shen JH, Chen YT, Chan KKW. Nonallergic Eyelid Edema After Botulinum Toxin Type A Injection: Case Report and Review of Literature. *Medicine (Baltimore)*. 2015 Sep;94(38):e1610.
59. Min S, Yoon JY, Park SY, Moon J, Kwon HH, Suh DH. Combination of platelet rich plasma in fractional carbon dioxide laser treatment increased clinical efficacy of for acne scar by enhancement of collagen production and modulation of laser-induced inflammation. *Lasers Surg Med*. 2018 Apr;50(4):302–10.
60. Lee YJ, Kim HT, Lee YJ, Paik SH, Moon YS, Lee WJ, et al. Comparison of the effects of polynucleotide and hyaluronic acid fillers on periocular rejuvenation: a randomized, double-blind, split-face trial. *J Dermatolog Treat*. 2022 Feb;33(1):254–60.
61. Alaraj AM, Oystreck DT, Bosley TM. Variable ptosis after botulinum toxin type a injection with positive ice test mimicking ocular myasthenia gravis. *J Neuroophthalmol*. 2013 Jun;33(2):169–71.
62. Alijotas-Reig J, Fernández-Figueras MT, Puig L. Pseudocystic encapsulation: a late noninflammatory complication of hyaluronic acid filler injections. *Dermatol Surg*. 2013 Nov;39(11):1726–8.
63. Bohnert K, Dorizas A, Lorenc P, Sadick NS. Randomized, Controlled, Multicentered, Double-Blind Investigation of Injectable Poly-L-Lactic Acid for Improving Skin Quality. *Dermatol Surg*. 2019 May;45(5):718–24.
64. Zhao H, Ren R, Bao S, Qian W, Ma X, Wang R, et al. Efficacy and Safety of Polycaprolactone in Treating Nasolabial Folds: A Prospective, Multicenter, and Randomized Controlled Trial. *Facial Plast Surg*. 2023 Jun;39(3):300–6.
65. Nacopoulos C, Vesala AM. Lower facial regeneration with a combination of platelet-rich fibrin liquid matrices based on the low speed centrifugation concept-Cleopatra technique. *J Cosmet Dermatol*. 2020 Jan;19(1):185–9.
66. Jeong GJ, Ahn GR, Park SJ, Hong JY, Kim BJ. A randomized, patient/evaluator-blinded, split-face study to compare the efficacy and safety of polycaprolactone and polynucleotide fillers in the correction of crow's feet: The latest biostimulatory dermal filler for crow's feet. *J Cosmet Dermatol*. 2020 Jul;19(7):1593–9.
67. Reeds DN, Mohammed BS, Klein S, Boswell CB, Young VL. Metabolic and structural effects of phosphatidylcholine and deoxycholate injections on subcutaneous fat: a randomized, controlled trial. *Aesthet Surg J*. 2013 Mar;33(3):400–8.
68. Beer K, Glogau RG, Dover JS, Shamban A, Handiwala L, Olin JT, et al. A randomized, evaluator-blinded, controlled study of effectiveness and safety of small particle hyaluronic acid plus lidocaine for lip augmentation and perioral rhytides. *Dermatol Surg*. 2015 Apr;41 Suppl 1:S127-136.
69. Bertucci V, Solish N, Kaufman-Janette J, Yoelin S, Shamban A, Schlessinger J, et al. DaxibotulinumtoxinA for Injection has a prolonged duration of response in the treatment of glabellar lines: Pooled data from two multicenter, randomized, double-blind, placebo-controlled, phase 3 studies (SAKURA 1 and SAKURA 2). *J Am Acad Dermatol*. 2020 Apr;82(4):838–45.
70. Rzany B, Griffiths T, Walker P, Lippert S, McDiarmid J, Havlickova B. Reduction of unwanted submental fat with ATX-101 (deoxycholic acid), an adipocytolytic injectable treatment: results from a phase III, randomized, placebo-controlled study. *Br J Dermatol*. 2014 Feb;170(2):445–53.
71. Jilani N, Shabbir J, Nemytova E. Liquid Silicone-Induced Extensive and Debilitating

- Granulomatosis Responding to Hydroxychloroquine. *Case Rep Rheumatol*. 2019;2019:8173790.
72. Choi SY, Lee YH, Kim H, Koh HJ, Park SY, Park WS, et al. A combination trial of intradermal radiofrequency and hyaluronic acid filler for the treatment of nasolabial fold wrinkles: a pilot study. *J Cosmet Laser Ther*. 2014 Jan;16(1):37–42.
 73. Demir E, Perez-Bouza A, Pallua N. Adverse late reactions after cosmetic implantation of hydroxyethylmethacrylate particles suspended in hyaluronic acid: clinics and complication management. *Aesthetic Plast Surg*. 2013 Jun;37(3):576–86.
 74. Siperstein R, Nestor E, Meran S, Grunebaum L. A split-face, blind, randomized placebo-controlled clinical trial investigating the efficacy and safety of hyaluronic acid filler for the correction of atrophic facial scars. *J Cosmet Dermatol*. 2022 Sep;21(9):3768–78.
 75. Araco A, Araco F, Raichi M. Clinical efficacy and safety of polynucleotides highly purified technology (PN-HPT®) and cross-linked hyaluronic acid for moderate to severe nasolabial folds: A prospective, randomized, exploratory study. *J Cosmet Dermatol*. 2023 Jan;22(1):146–55.
 76. Joo HJ, Woo YJ, Kim JE, Kim BJ, Kang H. A Randomized Clinical Trial to Evaluate the Efficacy and Safety of Lidocaine-Containing Monophasic Hyaluronic Acid Filler for Nasolabial Folds. *Plast Reconstr Surg*. 2016 Mar;137(3):799–808.
 77. Kim MJ, Kim JH, Cheon HI, Hur MS, Han SH, Lee YW, et al. Assessment of Skin Physiology Change and Safety After Intradermal Injections With Botulinum Toxin: A Randomized, Double-Blind, Placebo-Controlled, Split-Face Pilot Study in Rosacea Patients With Facial Erythema. *Dermatol Surg*. 2019 Sep;45(9):1155–62.
 78. Leonardis M, Palange A. New-generation filler based on cross-linked carboxymethylcellulose: study of 350 patients with 3-year follow-up. *Clin Interv Aging*. 2015;10:147–55.
 79. Lorenc ZP, Bruce S, Werschler WP. Safety and efficacy of a continuous-flow, injection-assisted device in delivery of dermal fillers. *Aesthet Surg J*. 2013 Jul;33(5):705–12.
 80. Nisi G, Cuomo R, Brandi C, Grimaldi L, Sisti A, D’Aniello C. Carbon dioxide therapy and hyaluronic acid for cosmetic correction of the nasolabial folds. *J Cosmet Dermatol*. 2016 Jun;15(2):169–75.
 81. Park KY, Seok J, Rho NK, Kim BJ, Kim MN. Long-chain polynucleotide filler for skin rejuvenation: efficacy and complications in five patients. *Dermatol Ther*. 2016;29(1):37–40.
 82. Shin SJ, Her Y, Yu DS, Kim CW, Kim SS. Twenty-four-week multicenter, evaluator-blinded clinical study of the efficacy and safety of a dextran filler in the treatment of nasolabial folds. *Dermatol Surg*. 2014 Jun;40(6):652–7.
 83. Hachach-Haram N, Gregori M, Kirkpatrick N, Young R, Collier J. Complications of facial fillers: resource implications for NHS hospitals. *BMJ Case Rep*. 2013 Jan 28;2013:bcr2012007141, bcr-2012–007141.
 84. Few J, Cox SE, Paradkar-Mitragotri D, Murphy DK. A Multicenter, Single-Blind Randomized, Controlled Study of a Volumizing Hyaluronic Acid Filler for Midface Volume Deficit: Patient-Reported Outcomes at 2 Years. *Aesthet Surg J*. 2015 Jul;35(5):589–99.
 85. Galadari H, van Abel D, Al Nuami K, Al Faresi F, Galadari I. A randomized, prospective, blinded, split-face, single-center study comparing polycaprolactone to hyaluronic acid for treatment of nasolabial folds. *J Cosmet Dermatol*. 2015 Mar;14(1):27–32.
 86. Hatcher JL, Goldman ND. Recognition and treatment of non-infectious hyaluronic acid reactions. *J Dermatolog Treat*. 2014 Dec;25(6):513–5.
 87. Jones D, Murphy DK. Volumizing hyaluronic acid filler for midface volume deficit: 2-year results from a pivotal single-blind randomized controlled study. *Dermatol Surg*. 2013 Nov;39(11):1602–12.

88. Alsuhaibani AH, Alfawaz N. Lower eyelid swelling as a late complication of Bio-Alcamid filler into the malar area. *Saudi J Ophthalmol*. 2011 Jan;25(1):75–9.
89. Seok J, Choi SY, Park KY, Jang JH, Bae JH, Kim BJ, et al. Depressed scar after filler injection successfully treated with pneumatic needleless injector and radiofrequency device. *Dermatol Ther*. 2016;29(1):45–7.
90. Chayangsu O, Wanitphakdeedecha R, Pattanaprichakul P, Hidajat IJ, Evangelista KER, Manuskitti W. Legal vs. illegal injectable fillers: The adverse effects comparison study. *J Cosmet Dermatol*. 2020 Jul;19(7):1580–6.
91. Kerfant N, Philandrianos C, Alliez A, Casanova D. Inadvertent subcutaneous injection of hypertonic saline solution during lipofilling. *Aesthetic Plast Surg*. 2013 Aug;37(4):709–10.
92. Kim DH, Jang HW, Kim HJ, Son SW. Dystrophic calcifications after autologous fat injection on face. *J Cosmet Laser Ther*. 2014 Jun;16(3):138–40.
93. Maione L, Vinci V, Klinger M, Klinger FM, Caviggioli F. Autologous fat graft by needle: analysis of complications after 1000 patients. *Ann Plast Surg*. 2015 Mar;74(3):277–80.
94. Polat M, Üstün H. A case of mesotherapy-induced panniculitis. *Cutan Ocul Toxicol*. 2016;35(2):163–4.
95. Suh DH, Jang HW, Lee SJ, Lee WS, Ryu HJ. Outcomes of polydioxanone knotless thread lifting for facial rejuvenation. *Dermatol Surg*. 2015 Jun;41(6):720–5.
96. Berguiga M, Galatoire O. Tear trough rejuvenation: A safety evaluation of the treatment by a semi-cross-linked hyaluronic acid filler. *Orbit*. 2017 Feb;36(1):22–6.
97. Wünscher SV, Cambiaso-Daniel J, Gualdi A, Rapp T. Long-term Complications of Gluteal Augmentation Using Aquafilling Filler: A Case Report. *Indian J Plast Surg*. 2023 Jun;56(3):267–9.
98. Martinez-Lopez A, Pérez-Lopez I, Sánchez-Cano D, Ruiz-Villaverde R. Nódulos subcutáneos faciales de 3 meses de evolución. *Dermatol Online J*. 2017 Feb 15;23(2):13030/qt53p393n2.
99. Fabi SG, Cohen JL, Green LJ, Dhawan S, Kontis TC, Baumann L, et al. DaxibotulinumtoxinA for Injection for the Treatment of Glabellar Lines: Efficacy Results From SAKURA 3, a Large, Open-Label, Phase 3 Safety Study. *Dermatol Surg*. 2021 Jan 1;47(1):48–54.
100. Kim SK, Kim JH, Hwang K. Skin Necrosis of the Nose After Injection of Ribose Cross-Linked Porcine Atelocollagen. *J Craniofac Surg*. 2015 Oct;26(7):2211–2.
101. Grippaudo FR, Di Girolamo M, Mattei M, Pucci E, Grippaudo C. Diagnosis and management of dermal filler complications in the perioral region. *J Cosmet Laser Ther*. 2014 Oct;16(5):246–52.
102. Hexsel D, Soirefmann M, Porto MD, Siega C, Schilling-Souza J, Rodrigues TC. Fields of muscular and anhidrotic effects of 2 botulinum toxin-A commercial preparations: a prospective, double-blind, randomized, multicenter study. *Dermatol Surg*. 2015 Jan;41 Suppl 1:S110-118.
103. Szantyr A, Orski M, Marchewka I, Szuta M, Orska M, Zapala J. Ocular Complications Following Autologous Fat Injections into Facial Area: Case Report of a Recovery from Visual Loss After Ophthalmic Artery Occlusion and a Review of the Literature. *Aesthetic Plast Surg*. 2017 Jun;41(3):580–4.
104. Kim BW, Park GH, Yun WJ, Rho NK, Jang KA, Won CH, et al. Adverse events associated with botulinum toxin injection: a multidepartment, retrospective study of 5310 treatments administered to 1819 patients. *J Dermatolog Treat*. 2014 Aug;25(4):331–6.
105. Kim SN, Byun DS, Park JH, Han SW, Baik JS, Kim JY, et al. Panophthalmoplegia and vision loss after cosmetic nasal dorsum injection. *J Clin Neurosci*. 2014 Apr;21(4):678–80.
106. Noh TK, Moon HR, Yu JS, Chang SE, Moon IJ, Choi SY, et al. Effects of highly concentrated hyaluronic acid filler on nasolabial fold correction: A 24-month extension study. *J Dermatolog*

- Treat. 2016 Nov;27(6):510–4.
107. Roh NK, Kim MJ, Lee YW, Choe YB, Ahn KJ. A Split-Face Study of the Effects of a Stabilized Hyaluronic Acid-Based Gel of Nonanimal Origin for Facial Skin Rejuvenation Using a Stamp-Type Multineedle Injector: A Randomized Clinical Trial. *Plast Reconstr Surg*. 2016 Mar;137(3):809–16.
 108. Ibrahim ZAES, El-Tatawy RA, El-Samongy MA, Ali DAM. Comparison between the efficacy and safety of platelet-rich plasma vs. microdermabrasion in the treatment of striae distensae: clinical and histopathological study. *J Cosmet Dermatol*. 2015 Dec;14(4):336–46.
 109. Mahmood Faris BJ. The Use of Facial Fillers in Clinical Practice: The Level of Patient Satisfaction and an Overview of Common Clinical Complications. *Actas Dermosifiliogr*. 2024 May;115(5):458–65.
 110. Singarajah A, Wang A, Sayegh J, Vilke GM, Quenzer FC. “Botched”: A Case Report of Silicone Embolism Syndrome After Penile and Scrotal Injection. *Clin Pract Cases Emerg Med*. 2020 Nov;4(4):595–8.
 111. Essenmacher AC, Astani SA. Respiratory Disease following Illicit Injection of Silicone: A Case Report. *Case Rep Med*. 2013;2013:743842.
 112. Jang JG, Hong KS, Choi EY. A case of nonthrombotic pulmonary embolism after facial injection of hyaluronic Acid in an illegal cosmetic procedure. *Tuberc Respir Dis (Seoul)*. 2014 Aug;77(2):90–3.
 113. Shaheen S, Al-Habbaa A, Riad MS, Mandour AS, Elzeny MA, Alnady K. Fatal pulmonary embolism following injectable gluteal filler usage: a case report. *Egypt Heart J*. 2023 Oct 10;75(1):83.
 114. Kim DY, Eom JS, Kim JY. Temporary blindness after an anterior chamber cosmetic filler injection. *Aesthetic Plast Surg*. 2015 Jun;39(3):428–30.
 115. Salval A, Ciancio F, Margara A, Bonomi S. Impending Facial Skin Necrosis and Ocular Involvement After Dermal Filler Injection: A Case Report. *Aesthetic Plast Surg*. 2017 Oct;41(5):1198–201.
 116. Kwon SG, Hong JW, Roh TS, Kim YS, Rah DK, Kim SS. Ischemic oculomotor nerve palsy and skin necrosis caused by vascular embolization after hyaluronic acid filler injection: a case report. *Ann Plast Surg*. 2013 Oct;71(4):333–4.
 117. Hsieh YH, Lin CW, Huang JS, Yeh PT. Severe ocular complications following facial calcium hydroxylapatite injections: Two case reports. *Taiwan J Ophthalmol*. 2015;5(1):36–9.
 118. Karam EZ, Gan A, Muci Mendoza R, Martinez E, Perez E. Visual Loss after Platelet-rich Plasma Injection into the Face. *Neuroophthalmology*. 2020;44(6):371–8.
 119. Madala S, Bao YK, Lee JH, Gluckstein J, Chang J, Zhang-Nunes S. Phthisical eye and orbital ischemia after cosmetic platelet-rich plasma injection to the forehead. *Am J Ophthalmol Case Rep*. 2024 Jun;34:101968.
 120. Wang C, Sun T, Yu N, Wang X. Herpes reactivation after the injection of hyaluronic acid dermal filler: A case report and review of literature. *Medicine (Baltimore)*. 2020 Jun 12;99(24):e20394.
 121. Ryeung Park Y, Choi JA, Yoon La T. Periorbital lipogranuloma after cryopreserved autologous fat injection at forehead: unexpected complication of a popular cosmetic procedure. *Can J Ophthalmol*. 2013 Dec;48(6):e166-168.
 122. Seok J, Hong JY, Park KY, Kim BJ, Seo SJ, Kim MN, et al. Delayed immunologic complications due to injectable fillers by unlicensed practitioners: our experiences and a review of the literature. *Dermatol Ther*. 2016;29(1):41–4.
 123. Seo JW, Sa HS. Periorbital Lipogranuloma Following Facial Autologous Fat Injections: Non-surgical Treatment. *Aesthetic Plast Surg*. 2015 Dec;39(6):946–52.

124. Joseph JH, Shamban A, Eaton L, Lehman A, Cohen S, Spencer J, et al. Polymethylmethacrylate Collagen Gel-Injectable Dermal Filler for Full Face Atrophic Acne Scar Correction. *Dermatol Surg.* 2019 Dec;45(12):1558–66.
125. Li GF, Ban S, Wang M, Zhang J, Lu H, Shi YH, et al. Brain functional changes in patients with botulism after illegal cosmetic injections of botulinum toxin: A resting-state fMRI study. *PLoS One.* 2018;13(11):e0207448.
126. Lee JS, Kim JY, Woo SJ. Unilateral Blindness With Bilateral Brain Infarction After Cosmetic Facial Filler Injection. *J Neuroophthalmol.* 2021 Dec 1;41(4):e566–71.
127. Wang DW, Yin YM, Yao YM. Internal and external carotid artery embolism following facial injection of autologous fat. *Aesthet Surg J.* 2014 Nov;34(8):NP83-87.
128. Davidova P, Müller M, Wenner Y, König C, Kenikstul N, Kohnen T. Ophthalmic artery occlusion after glabellar hyaluronic acid filler injection. *Am J Ophthalmol Case Rep.* 2022 Jun;26:101407.
129. Mayer JE, Goldberg DJ. Injuries Attributable to Cosmetic Procedures Performed by Unlicensed Individuals in the United States. *J Clin Aesthet Dermatol.* 2015 Oct;8(10):35–7.
130. Cárdenas-Camarena L, Bayter JE, Aguirre-Serrano H, Cuenca-Pardo J. Deaths Caused by Gluteal Lipoinjection: What Are We Doing Wrong? *Plast Reconstr Surg.* 2015 Jul;136(1):58–66.
131. Yoo SJ, Lee KH, Jung SN, Heo ST. Facial skin and soft tissue infection caused by *Mycobacterium wolinskyi* associated with cosmetic procedures. *BMC Infect Dis.* 2013 Oct 16;13:479.
132. Gan SD, Itkin A, Wolpowitz D. Hyaluronic acid-induced alopecia: a novel complication. *Dermatol Surg.* 2013 Nov;39(11):1724–5.
133. Jung JM, Lee WS, Kim HT, Moon YS, Paik SH, Lee WJ, et al. A Multi-center, randomized, double blinded, comparative study of two hyaluronic acid fillers for temporary restoration of mid-face volume in Asians. *J Cosmet Dermatol.* 2020 Jul;19(7):1619–26.
134. Nikolis A, Enright KM, Öhrlund Å, Winlöf P, Cotofana S. A randomized, split-face, double-blind, comparative study of the safety and efficacy of small- and large-particle hyaluronic acid fillers for the treatment of nasolabial folds. *J Cosmet Dermatol.* 2021 May;20(5):1450–8.
135. Kamouna B, Kazandjieva J, Balabanova M, Dourmishev L, Negentsova Z, Etugov D, et al. Oil-soluble vitamins: illegal use for lip augmentation. *Facial Plast Surg.* 2014 Dec;30(6):635–43.
136. Braccini F, Fanian F, Garcia P, Delmar H, Loreto F, Benadiba L, et al. Comparative clinical study for the efficacy and safety of two different hyaluronic acid-based fillers with Tri-Hyal versus Vycross technology: A long-term prospective randomized clinical trial. *J Cosmet Dermatol.* 2023 Feb;22(2):473–85.
137. Li D, Sun J, Zhang Y, Wang X, Yang S, Harvey C, et al. VYC-20L is Safe and Effective for Improving Volume and Aesthetic Appearance of the Nose in Chinese Adults. *Clin Cosmet Investig Dermatol.* 2022;15:1195–204.

Identification

Records identified through
database search (N=238)

Screening

Records after removing
duplicates (N=228)

Eligibility

Records screened on
abstracts (N=228)

Excluded:
55 irrelevant records
18 in a different language

Inclusion

Full-text articles assessed for
eligibility (N=155)

Excluded:
57 incomplete records

Articles included (N=98)

