

Toscana Virus Infection Clinical Characterization

Nazli Ayhan^{1,2*}, Carole Eldin^{1,3}, Remi Charrel^{1,3,4}

¹Unité des Virus Émergents (UVE: Aix-Marseille Univ, Università di Corsica, IRD 190, Inserm 1207, IRBA), France.

²Centre National de Référence des Arbovirus, Inserm-IRBA, Marseille, France.

³Laboratoire des Infections Virales Aigues et Tropicales, Pole des Maladies Infectieuses, AP-HM Hopitaux Universitaires de Marseille, France

⁴ Le Service de Prévention du Risque Infectieux (LESPRI), CLIN AP-HM Hôpitaux Universitaires de Marseille, France

*Corresponding Author : Unité des Virus Émergents (UVE) Méditerranée Infection, 19-21, Bd. Jean Moulin 13005 Marseille, Tel: +33(0)4 13 73 21 51, nazli.ayhan@univ-amu.fr

Abstract

Background: Toscana virus (TOSV) is a sandfly-borne phlebovirus causing central nervous system (CNS) infection in Mediterranean countries, during summer season. However, clinical aspects of the disease caused by this virus are poorly known by clinicians, so that its prevalence is probably underestimated due to a lack of diagnosis.

Study design: We gathered data from all available case series and retrospective studies identifying TOSV as the causative viral agent. The informations of age, sex, clinical characteristics, laboratory findings, imaging results and clinical outcomes of TOSV infection were recorded and analyzed.

Results: In our review a total of 95 articles including TOSV infections resulting in a total of 1,381 cases were analyzed. Our findings indicate, TOSV affects individuals across various age groups, with a median age of 44.45 years. A notable disparity in infection rates between genders, with men being significantly

NOTE: likely to present symptoms due to TOSV than women, with a sex ratio of 2.0 (p<0.001). The

27 clinical presentation of TOSV infection encompasses a range of symptoms, including fever, headache,
28 retro-orbital pain, neurological and muscular manifestations with less common reports of cutaneous
29 and gastrointestinal symptoms. To date, six fatalities have been attributed to TOSV infections, with a
30 median age of 76 years.

31 Diagnostic evaluation of TOSV infections often involves the analysis of cerebrospinal fluid, where
32 findings may include an elevated white blood cell count.

33 **Conclusions:** These findings underscore the diverse clinical manifestations of TOSV infections and
34 highlight the importance of considering this pathogen in the differential diagnosis of patients
35 presenting with acute febrile illness, especially in endemic regions. TOSV represents an emerging
36 infectious threat that warrants inclusion in the diagnostic protocols for patients presenting with CNS,
37 particularly within the Mediterranean basin or for those with recent travel history to endemic regions
38 during warmer months when sandflies are actively circulating.

39

40

41 Introduction

42 Toscana virus (TOSV) is classified within the *Phlebovirus toscanaense* species of the *Phenuiviridae*
43 family within the *Bunyavirales* order. TOSV is recognized as a significant human pathogen prevalent in
44 the Mediterranean region (1). Recent studies, including Medlock et al. (2) have documented a
45 concerning increase in the population density of blood-feeding insects, along with their dissemination
46 into territories previously considered free of sand flies. This expansion of the sand fly habitats
47 substantially increases the risk of TOSV exposure among human population. Cases of TOSV infection
48 have been reported in various Mediterranean countries such as; Italy, Spain, Portugal, France, Türkiye,
49 Croatia, Greece, Algeria, Tunisia (3). Seroprevalence studies in both human and non-human
50 vertebrates have revealed significant infection rates, with high prevalence reported in Italy (19.8%) (4),
51 Türkiye (17.8%) (5), Greece (21%) (6), North Africa (22%-41%) (7); and the Balkans (37.5%) (8)
52 indicating the widespread presence of TOSV across the Mediterranean basin. A recent retrospective
53 study in Germany by Dersch et al. (2021) identified cases of TOSV-neuroinvasive disease in patients
54 with meningoencephalitis with no recent travel history to endemic areas, suggesting a broader
55 geographical spread than previously thought (9). TOSV is listed in the first three viral agents causing
56 neurological infection at least in Italy, Spain and France together with enteroviruses and herpesviruses
57 during warm season (10). However, the rare inclusion of TOSV in the diagnostic algorithm of nervous
58 system infections (CNS) infections results in an important underestimation of the incidence (3).

59 The objective of our study was to review the available data about clinical characteristics of TOSV
60 infections to raise the awareness of physicians about this emerging pathogen.

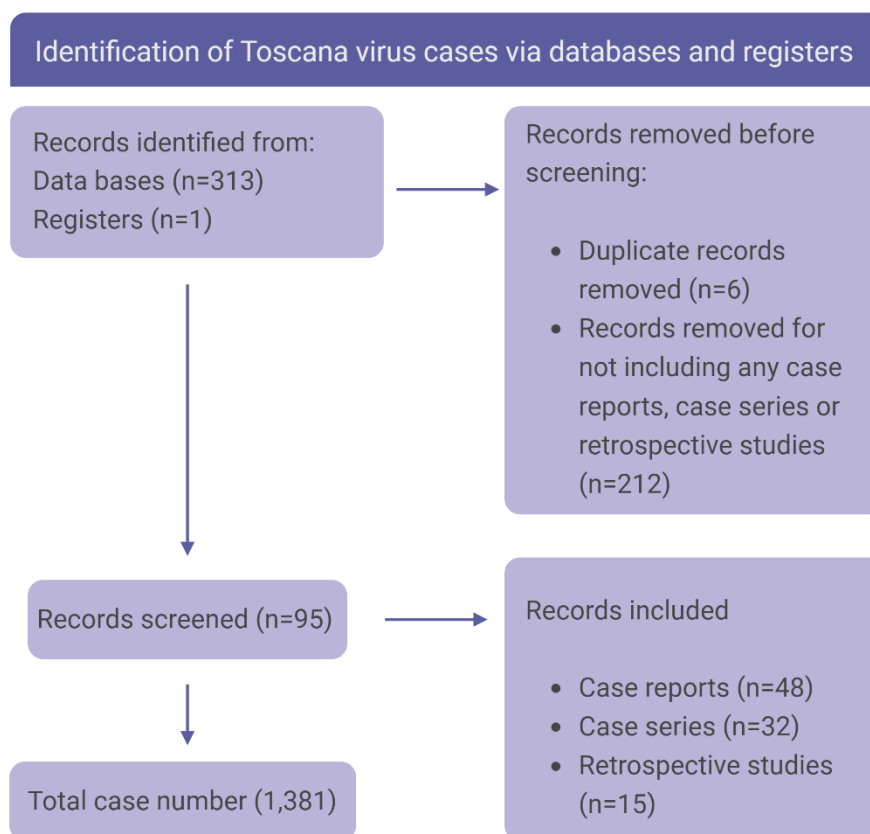
61

62

63 Material and Method

64 Study design

65 Relevant entries in global Web-based resources that comprise Scopus (<http://www.scopus.com/>),
66 Web of Science (<https://isiknowledge.com>), and PubMed (<https://pubmed.ncbi.nlm.nih.gov>), Google
67 scholar (<https://scholar.google.com.tr/>) were searched. Database investigations were performed
68 using the keywords “bunyavirus”, “phlebovirus,” “Toscana virus”, “TOSV”, “Toscana virus case
69 report”, “nervous system infection”. Reports unrelated to TOSV infection were omitted, as well as
70 conference reports with recurring data in publications. The references cited in each report were
71 examined for further publications, which were included in the analysis (Figure1).



72

73

Figure2. Toscana virus local and imported case distribution map.

74 Statistical Analysis

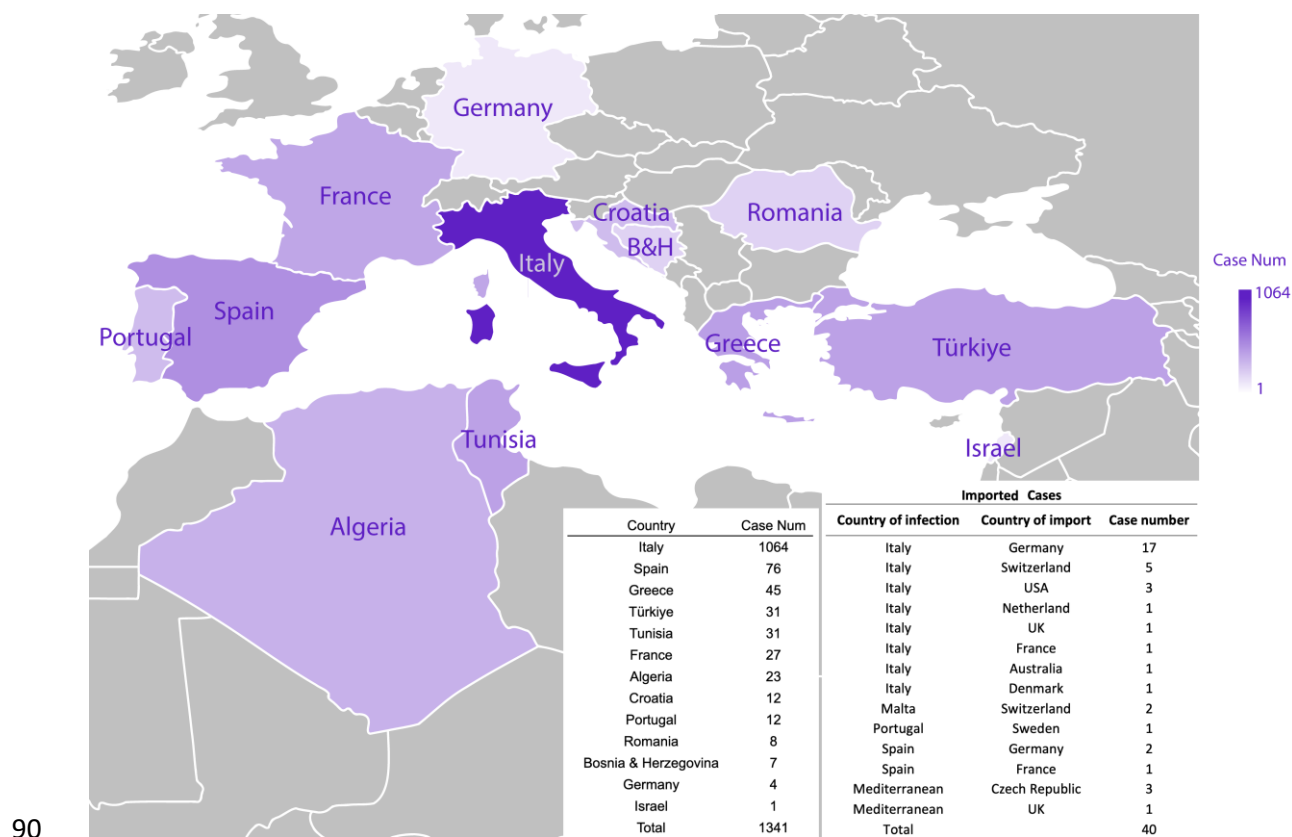
75 All variables (described in Table 1) were screened using a logistic regression univariate analysis to check
76 for statistically significant associations of demographic characters with TOSV in SPSS version 24.

77 Results

78 Demographic and geographic characteristics

79 We conducted an inventory of 95 articles including 48 case reports, 32 case series and 15 retrospective
80 studies, documenting a total of 1,381 cases of TOSV infection cases between 1985 and 2023. Age and
81 sex demographics were obtained for 762 and 1,115 patients respectively (Table 1). Significantly more
82 male patients were reported with TOSV infection compared to female patients (744 males to 371
83 females; $p < 0.001$).

84 TOSV infections were recorded in 12 countries: with the majority of cases originating from Italy
85 ($n=1064$), followed by Spain ($n=76$), Greece ($n=45$), Türkiye and Tunisia each with ($n=31$), France
86 ($n=27$), Algeria ($n=23$), and lesser numbers from Croatia ($n=12$), Portugal ($n=12$), Romania ($n=8$),
87 Bosnia & Herzegovina ($n=7$), Germany ($n=4$) and Israel ($n=1$). A total of 40 travelers returning from
88 Mediterranean countries were reported, of which 30 had visited Italy, including both mainland and
89 islands (Figure2).



90

91 **Figure2.** Toscana virus local and imported case distribution map.

92 TOSV infections were reported across a wide range of age groups, with the youngest patient being
 93 between 0-5 year old (11) and the oldest between 90-95 year old (12); the median age of patients was
 94 44.4 years. The disease manifested in 82 pediatric patients under 15 years of age, as documented in
 95 nine studies (11–19). Notably, the prevalence of TOSV infection in children was significantly lower, at
 96 5.9%.

97 **Clinical characteristics**

98 *Typical manifestations*

99 Retro-orbital pain was the most common symptom (156/163, 95.7%). Then headache was observed in
 100 93.2% of cases (566/607) sometimes reported as the “worst headache of their life”. Fever was
 101 described in 91.9% (678/738) of cases with an abrupt onset and temperature ranging from 38°C to
 102 39.5°C. Neck rigidity was reported in 88.2% (473/536). Other non-specific signs such as

103 nausea/vomiting, muscle weakness, asthenia and fatigue were described in almost 80% of cases (Table
104 1).

105 **Table 1.** Demographic characteristics and non-specific clinical signs.

	Number of cases	Total	%
Age, median [range]	44.45	762	
Sex (male/female)	744/371	1115	
Signs			
Fever	678	738	91.9
Headache	566	607	93.2
Nausea/Vomiting	340	431	78.9
Neck rigidity	473	536	88.2
Muscle weakness / Asthenia / Fatigue	34	43	79.1
Retro-orbital pain	156	163	95.7

106 *Neurological manifestations*

107 Of the 644 documented cases, 519 patients (representing 80.6%) presented with meningitis or aseptic
108 meningitis, while 111 patients presented with either pure encephalitis or meningo-encephalitis (Table
109 2); myelitis was very rarely reported. Until recently, a total of 49 cases were recorded as
110 meningitis/meningo-encephalitis. More recently, Mellace et al. (2022) identified 331 cases featuring
111 neurological symptoms; however, the distinction between meningitis and
112 encephalitis/meningoencephalitis was not clearly defined.. As a consequence, although central
113 manifestations are not unusual, pure meningitis is the most prominent neurological manifestation of
114 TOSV infections.

115

116 **Table 2. TOSV neurological manifestations.**

Clinical Presentations	Number of cases	Total	
		analysed cases	%
Meningitis /Aseptic Meningitis	519	644	80.6
Encephalitis	77	241	32.0
Meningoencephalitis	34	221	15.4
Meningitis/Aseptic Meningitis or Meningoencephalitis	49		
Myelitis	2		
Total	684+331* = 1015	1382	73.44

117 * However recent article include 331 patients with meningitis, meningoencephalitis, encephalitis and polineuropatia didn't
 118 included the number count due to lack of information for each clinical presentation but included in total count (19).

119 Three cases of hydrocephalus were documented in young patients (range between 15-25 year-old); in
 120 all cases, hydrocephalus was observed as a complication following viral meningoencephalitis (20,21).

121 Specific neurological manifestations were categorized based on their involvement of either the central
 122 or peripheral nervous system, as detailed in Table 3.

123 **Table 3. TOSV neurological signs and symptoms.**

Neurological Manifestations:
signs and symptoms denoting a central nervous system involvement
abnormal behavior, agitation, anhedonia irritability, aphasia, ataxia, blurred vision, cerebral atrophy, confusion, depression, double vision, dysmetria, epilepsy, facial paresis, focal neurological deficit, hallucinations, hemiparesis/paresis, hydrocephalus, hypotonia, impaired consciousness, insomnia, nystagmus, obtundation, occipital/ischemic stroke, paresis, paresthesia, phonophobia, photophobia, kernig's sign, seizure, sleepiness, stumbling and dysmetria, tetra paresis, tonic-clonic seizure, tremor

signs and symptoms denoting a peripheral nervous system involvement

brachial plexitis, Guillain Barré like syndrome, hyperaesthesia, limited atrophy, motor and sensory neuropathy, peripheral polyneuropathy,
--

124

125 Out of 712 patient, 569 exhibited at least one neurological signs or symptoms listed in Table3. Among
126 central neurological manifestations, Kernig's sign was the most prevalent, observed in 135 cases,
127 followed by decreased consciousness and photophobia (n=41), facial or leg hemiparesis /paresis (n=17)
128 and confusion (n=16). Speech impairment was reported in eight patients(22–28) while six patients
129 experienced hearing impairment, characterized by bilateral deafness that persisted beyond the acute
130 phase and 6 patients reported hearing impairment (29–32). Additionally, changes in personality, sexual
131 and social disinhibition, aggressiveness, and other abnormal behaviors were also documented (33,34)
132 (Table2). The presence of symptoms signing a peripheral neuropathy was observed in 14 cases of which
133 10 presented with Guillain-Barre like syndrome (35–37).

134 *Ocular manifestations*

135 Retro-orbital pain or pressure were very frequently observed, documented in 156 out of 163 cases. In
136 contrast, conjunctivitis was reported only in a single case (38) (Table4).

137 *Gastro-intestinal manifestations*

138 Gastro-intestinal manifestations consisting of gastroenteritis, abdominal pain, dysphagia or diarrhea
139 were reported rarely (16/43). (20,37,39–41) (Table4).

140 *Cutaneous manifestations*

141 Dermatological symptoms including petechiae, rash, exanthema, and febrile erythema were reported
142 in 15 out of 38 cases. Rash was the most frequently observed symptom, noted in 11 cases
143 (20,29,39,41–45) (46) (Table4).

144 *Muscular manifestations*

145 The musculoskeletal symptoms observed included cramps, myalgia/arthralgia, myositis/fasciitis, and
146 muscle stiffness. Among the 51 patients who exhibited these symptoms, all presented with myalgia
147 and/or arthralgia (12,18,22,35,38,44,45,47–53) (Table4).

148 **Table 4. Number of TOSV cases with muscular, ocular, gastro-intestinal, cutaneous and**
149 **neurological manifestations.**

	Number of cases	Total	%
Muscular Manifestations	51	211	24,2
Myalgia / Arthralgia	51	211	24,2
Ocular Manifestations	157	164	95,7
Retroorbital pain or pressure	156	163	95,7
Gastro-intestinal Manifestations	16	43	37,2
Gastroenteritis	7	16	43,8
Cutaneous Manifestations	15	38	39,5
Rash	11	32	34,4
Neurological Manifestations	569	712	79,9
Central Nervous System Manifestations	560	683	82
Peripheral Nervous System Manifestations	14	26	53,8

150

151 *Testicular manifestations*

152 Testicular manifestations, including epididymo-orchitis, testicular pain, and swelling, were reported in
153 five patients (20,39,41,54,55) (Table 5). These symptoms were significantly more frequent (p-value
154 <0.001) among younger patients, with a median age of 27 years (range 16-44) (Table 5). Recently, TOSV
155 RNA was detected in the seminal fluid of a patient in the age range of 20-25 year old until day 59 after
156 infection without any testicular manifestations (28).

157 **Table 5. TOSV infection cases with testicular manifestations.**

Characteristic / References	Age range / Age median [range] (n)	Fever	Headache	Neck rigidity / pain	Nausea / vomiting
Echevarria et al. 2003	25-29	NR*	NR*	NR*	NR*
Baldelli et al. 2004	15-19	1	1	1	1
Zanelli et al. 2013	25-29	1	1	-	-
Tschumi et al. 2019	20-24	1	1	-	-
Mascitti et al. 2020	40-44	1	1	-	-
	27 [16-44] (5)	4	4	1	1

158 * , NR, not reported

159 *Severe cases and Mortality*

160 Although TOSV infections are frequently associated with severe clinical manifestations, the vast
 161 majority of patients recover completely. Nonetheless, six fatal cases have been reported across two
 162 studies: the first fatality occurred in Italy (31); and five subsequent fatalities were reported in Romania
 163 (31,49). The overall the mortality rate is 0.43% with deceased patients having a median age of 76 years-
 164 old (range 70-91). Age was found to have a statistically significant impact on mortality (p -value <0.001).
 165 In addition, five out of six fatal cases had comorbidities such as hypertension and diabetes (Table6).

166 There were nine cases of severe TOSV infections leading to coma (20,31,49,56). Seven of these were
 167 elder patients with median age of 79, six of whom had comorbidities such as diabetes and hypertension
 168 and two patients were two siblings with the age range between 15 to 20, previously mentioned as
 169 having developed hydrocephalus following infection.

170

171

172

173

174 **Table6. TOSV infection lethal cases.**

Reference	Nb of case	Sex	Age Range	Country	Comorbidities	Period	In-hospital length of stay (days)
Bartels et al. 2012	1	male	70-74	Italy	-	-	14
Popescu et al. 2021	1	male	90-94	Romania	Hypertension, congestive heart failure, ischemic heart disease, stroke sequelae	June	10
	1	female	65-69	Romania	Hypertension, diabetes mellitus, obesity, NonHodgkin lymphoma	August	4
	1	male	75-79	Romania	Diabetes mellitus type II, Ischemic heart disease	August	19
	1	male	70-74	Romania	Diabetes mellitus type II, Ischemic heart disease, Atrial fibrillation, Congestive heart failure, Diabetic polyneuropathy and arteriopathy	August	4
	1	female	85-89	Romania	Hypertension, Stroke sequelae, Chronic renal failure	August	6

175

176

177 *Laboratory characteristics*

178 Cerebrospinal fluid (CSF) analysis showed elevated white blood cell (WBC) levels in 22 cases.

179 Lymphocytic predominance ratio was high in 82% of the patients (47 out of 57) (>50%). CSF samples

180 showed high protein levels in 102 patients. Mildly elevated glucose levels have been showed in 179
181 patients (Table 7).

182 **Table 7. TOSV laboratory characteristics.**

Laboratory Findings	Mean (n) [range]	Normal range/percentage
CSF protein level (mg/dL)	56.34 (77) [11-757]	15-45
CSF WBC (cells/mm3)	432.50 (22) [6-3500]	0-5
CSF Lymphocytes ratio (%)	73.40% (57) [18%-100%]	50%
CSF Glucose (mg/dL)	63.21 (60) [29-132]	>40

183

184 *Electro-physiology analysis*

185 The electroencephalogram (EEG) showed abnormal results in 43 patients (11,23,31,56–62) with non-
186 specific abnormalities, occasional spikes and slow waves (58).

187 *Imaging and Radiological findings and electrocardiogram tests*

188 When available, magnetic resonance imaging (MRI) results showed diffuse encephalopathy, diffuse
189 atrophy abnormalities, diffuse bilateral asymmetric myositis or scattered punctuate T2-hyperintense
190 non-enhancing white matter lesions in 11 patients (21,27,45,53,63). Cerebral atrophy and/or occipital
191 stroke sequelae were detected in 2 patients with computerized tomography (CT) scan (49).

192 Few patients were examined by with electrocardiogram (ECG) and chest X-ray. Chest X-ray
193 demonstrated an opacity in the right middle lobe of the lung of one patient (29). No abnormalities
194 were recorded with ECG after TOSV infection (Table8).

195

196

197

198

199

200 **Table8. TOSV electro-physiology analysis and radiology findings.**

Electro-physiology analysis and radiology findings	Number of abnormal cases	Total
EEG	43	82
MRI	11	30
CT	3	30
Chest X-ray	1	8
ECG	0	3

201

202 Discussion

203 Infections caused by TOSV exhibit a high diversity of clinical manifestations, none of them being neither
204 pathognomonic nor highly specific. It is crucial to provide a comprehensive analysis of the observed
205 signs in order to improve the clinical orientation for physicians seeing both residents and visitors in the
206 Mediterranean regions during the warm season when TOSV can be transmitted by sand flies (Figure1).
207 Unlike other neuroinvasive viruses such as herpes viruses and enteroviruses, TOSV infections occur
208 exclusively during the period of activity of phlebotomine sand flies, typically from March to November
209 in the Mediterranean, with slight variations depending on local climate conditions (64).
210 From 1985 to 2023, a total of 1,381 cases were reported from 12 different countries of which the
211 majority (1,064 cases, 77%) occurred in Italy. The annual incidence rate of cases fluctuates considerably
212 in relation with complex biology of vectors, hosts and environmental factors. TOSV infections have
213 been documented across a broad age spectrum (median age 44.45 years, ranging from 0 to 95 years
214 old); however, age itself is not indicative of etiology, though most cases occur between 20 and 60 years
215 old. Using data collected in travelers returning to their homeland, the median incubation period was

216 calculated at 12 days (10-14 days) for the neuroinvasive forms (65). Whether the same incubation
217 period applies for milder cases remains unexplored.

218 TOSV symptomatic infections are observed twice as frequently in males as in females. The reasons for
219 this gender disparity in symptomatology could be related to differences in immune response, viral
220 susceptibility, or possibly due to variations in exposure factors and the prevalence of high-risk
221 behaviors. However, similar seroprevalence rates between males and females suggest that behavioral
222 factors alone may not explain this difference (66). Interestingly, the same tendency is also observed
223 for WNV infections (67).

224 Both length of hospitalization and symptoms duration vary significantly based on the severity of the
225 case. The longest hospitalization was 60 days (68) and the longest symptoms duration was 28 days
226 (52,69). The lethality rate of TOSV infections is 0.43% which is lower than other neuroinvasive
227 arboviruses such as WNV, Japanese encephalitis virus (JEV) or tick-borne encephalitis virus (TBEV). All
228 the fatal cases were older than 60 year-old; five of the six fatal cases had comorbidities such as
229 hypertension and/or diabetes mellitus.

230 Severe neuroinvasive forms, characterized by encephalitis or meningo-encephalitis, are reported in
231 15.8 to 32.0% of neurological cases, the latter representing almost 80% of 712 studied cases. Since
232 TOSV cases reported in the literature are the most severe ones, neuroinvasive forms are certainly
233 overrepresented. Common forms are frequent although they are likely to remain either undetected or
234 unpublished (70); those forms are associated with unspecific clinical manifestations such as fever,
235 headache, nausea, vomiting, retro-orbital pain and muscle weakness.

236 Severe long-lasting or permanent neurological sequelae such as consciousness impairment,
237 hydrocephalus, ischemic stroke and aphasia (20,49,68,71,72) were described. In contrast with other
238 arboviruses, severe neurological forms are not more frequent in the elderly (19). However, the lower
239 incidence rate of TOSV infections in the pediatric group (5.9%) can either be explained by a lower
240 exposure and/or by a reporting bias, or by biological factors such as immune response and/or viral
241 susceptibility.

242

243 Among system specific manifestations, CNS signs are the most frequently observed with 79.9% of cases
244 followed by ocular and muscular manifestations. Peripheral neurological manifestations, gastro-
245 intestinal and cutaneous manifestations were reported rarely. Additionally, a unique case involved a
246 patient with gastrointestinal manifestations who was also co-infected with West Nile virus (37).
247 Although testicular manifestations are noteworthy, they have been documented in only five patients.
248 To date, aside from the Zika virus (ZIKV), no other arbovirus has been identified as a causative agent
249 for testicular manifestations. Recently, the presence and persistence of TOSV RNA in seminal fluid has
250 been demonstrated without evidence for sexual transmission (28).

251 In most of cases presenting with clinical picture justifying CSF collection, CSF was clear and colorless.
252 The CSF formula showed elevated WBC levels in 22 patients and lymphocytic meningitis in 58 patients.
253 Mildly elevated protein and glucose levels were described in 102 patients and 179 patients
254 respectively. Hypoglycorachia was never reported. CSF parameters were available only for a subset of
255 the reviewed cases.

256 Electro-physiology analysis and radiology findings showed abnormalities in EEG or in MRI for 56 cases
257 (4%). CT scan and chest X-ray were performed occasionally and abnormalities were rarely recorded.
258 No abnormalities were recorded for ECG which was performed only for three patients (58,73,74)

259 In almost all cases, the recovery is complete without persisting functional sequelae. However, there
260 are a few documented cases where individuals have experienced complicated forms of meningitis
261 and/or encephalitis with lingering effects attributed to TOSV. These effects include impaired cognitive
262 functions and altered social and sexual behaviors (60,68) Other neuroinvasive arboviruses, such as
263 WNV, JEV or TBEV, cause long-lasting or permanent sequelae (75).

264 Finally, most TOSV infections remain undiagnosed, as TOSV is not included in the list of pathogens to
265 be screened in patients presenting with febrile illness and/or neurological manifestations in areas
266 where the virus is endemic. The only exception is Italy where it is recommended to include TOSV in the

267 panel of viruses to be tested during summertime for suspect cases. This is likely why most cases are
268 reported in Italy besides the fact that TOSV has been discovered in Italy and that physicians are much
269 more aware of its existence than in other at risk countries. This oversight is highlighted by numerous
270 retrospective studies, which suggest that many cases of TOSV infection are classified as "infections due
271 to unknown pathogenic agents" due to the absence of specific laboratory screening for TOSV
272 (35,51,76,77). Nevertheless, most TOSV cases exhibit nonspecific signs or symptoms with short
273 duration in non-severe cases.

274 Together, the combination of lack of awareness of physician with absence of recommendations to
275 screen suspect cases using specific laboratory tests has and continue to greatly contribute to the
276 underestimation of TOSV cases despite its public health importance.

277

278

279 [Acknowledgement](#)

280

281 This study was funded by European Commission grant 101057690 and UKRI grants 10038150 and
282 10039289, and is catalogued by the CLIMOS Scientific Committee as CLIMOS number XXXX* ([http://](http://www.climos-project.eu)
283 www.climos-project.eu). The contents of this publication are the sole responsibility of the authors and
284 do not necessarily reflect the views of the European Commission, the Health, and Digital Executive
285 Agency, or UKRI. Neither the European Union nor granting authority nor UKRI can be held responsible.
286 The funders had no role in study design, data collection and analysis, decision to publish, or preparation
287 of the manuscript. For the purposes of Open Access, the authors have applied a CC BY [option: CC BY-
288 ND] public copyright license to any Author Accepted Manuscript version arising from this submission.

289 CLIMOS forms part of the Climate Change and Health Cluster comprising six Horizon Europe projects:
290 BlueAdapt, CATALYSE, CLIMOS, HIGH Horizons, IDAlert, and TRIGGER.

291 *The number will be added after publication.

292

293 References

- 294 1. Charrel RN, Bichaud L, de Lamballerie X. Emergence of Toscana virus in the mediterranean
295 area. *World J Virol* . 2012;1(5):135–41. DOI: <https://doi.org/10.5501/wjv.v1.i5.135>
- 296 2. Medlock JM, Hansford KM, Van Bortel W, Zeller H, Alten B. A summary of the evidence for the
297 change in European distribution of phlebotomine sand flies (Diptera: Psychodidae) of public
298 health importance. *J Vector Ecol*. 2014;72–7. DOI: [https://doi.org/10.1111/j.1948-](https://doi.org/10.1111/j.1948-7134.2014.12072.x)
299 [7134.2014.12072.x](https://doi.org/10.1111/j.1948-7134.2014.12072.x)
- 300 3. Ayhan N, Charrel RN. An update on Toscana virus distribution, genetics, medical and
301 diagnostic aspects. *Clin Microbiol Infect*. 2020;26(8). DOI:
302 <https://doi.org/10.1016/j.cmi.2019.12.015>
- 303 4. Terrosi C, Olivieri R, Bianco C, Cellesi C, Cusi MG. Age-dependent seroprevalence of Toscana
304 virus in central Italy and correlation with the clinical profile. *Clin Vaccine Immunol*.
305 2009;16(8):1251–2. DOI: <https://doi.org/10.1128/CVI.00376-08>
- 306 5. Ergunay K, Aydogan S, Ilhami Ozcebe O, Cilek EE, Hacıoglu S, Karakaya J, et al. Toscana Virus
307 (TOSV) exposure is confirmed in blood donors from Central, North and South/Southeast
308 Anatolia, Turkey. *Zoonoses Public Health* . 2012;59(2):148–54. DOI:
309 <https://doi.org/10.1111/j.1863-2378.2011.01436.x>
- 310 6. Anagnostou V, Papa A. Seroprevalence of Toscana virus among residents of Aegean Sea
311 islands, Greece. *Travel Med Infect Dis* . 2013;11(2):98–102. DOI:
312 <https://doi.org/10.1016/j.tmaid.2012.11.006>
- 313 7. Alkan C, Allal-Ikhlef AB, Alwassouf S, Baklouti A, Piorkowski G, de Lamballerie X, et al. Virus
314 isolation, genetic characterization and seroprevalence of Toscana virus in Algeria. *Clin*
315 *Microbiol Infect* . 2015;21(11):1040.e1-1040.e1. DOI:
316 <https://doi.org/10.1016/j.cmi.2015.07.012>
- 317 8. Punda-Polic V, Jeroncic A, Mohar B, Kraljevic KS. Prevalence of Toscana virus antibodies in
318 residents of Croatia. *Clin Microbiol Infect*. 2012;18(6):200–3. DOI:

- 319 <https://doi.org/10.1111/j.1469-0691.2012.03840.x>
- 320 9. Dersch R, Sophocleous A, Cadar D, Emmerich P, Schmidt-Chanasit J, Rauer S. Toscana virus
321 encephalitis in Southwest Germany: a retrospective study. *BMC Neurol* . 2021;21(1):1–5. DOI:
322 <https://doi.org/10.1186/s12883-021-02528-7>
- 323 10. Gori Savellini G, Gandolfo C, Cusi MG. Epidemiology of Toscana virus in South Tuscany over
324 the years 2011-2019. *J Clin Virol*. 2020;128:104452. DOI:
325 <https://doi.org/10.1016/j.jcv.2020.104452>
- 326 11. Braitto A, Ciufolini MG, Pippi L, Corbisiero R, Fiorentini C, Gistri A, et al. Phlebotomus-
327 transmitted toscana virus infections of the central nervous system: a seven-year experience in
328 Tuscany. *Scand J Infect Dis* . 1998;30(5):505–8. DOI:
329 <https://doi.org/10.1080/00365549850161539>
- 330 12. Papa A, Kontana A, Tsergouli K. Phlebovirus infections in Greece. *J Med Virol* .
331 2015;87(7):1072–6. DOI: <https://doi.org/10.1002/jmv.24163>
- 332 13. Mendoza-Montero J, Gamez-Rueda M-I, Navarro-Mari J-M, de la Rosa-Fraile M, Oyonarte-
333 Gomez S. Infections Due to Sandfly Fever Virus Serotype Toscana in Spain. *Clin Infect Dis* .
334 1998;27(3):434–6. DOI: <https://doi.org/10.1086/514684>
- 335 14. Braitto A, Corbisiero R, Corradini S, Fiorentini C, Ciufolini MG. Toscana virus infections of the
336 central nervous system in children: A report of 14 cases. *J Pediatr* . 1998;132(1):144–8. DOI:
337 [https://doi.org/10.1016/S0022-3476\(98\)70500-1](https://doi.org/10.1016/S0022-3476(98)70500-1)
- 338 15. Santos L, Simões J, Costa R, Martins S, Lecour H. Toscana virus meningitis in Portugal, 2002-
339 2005. *Euro Surveill* . 2007;12(6):E3-4. DOI: <https://doi.org/10.2807/esm.12.06.00715-en>
- 340 16. Anagnostou V, Pardalos G, Athanasiou-Metaxa M, Papa A. Novel phlebovirus in febrile child,
341 Greece. *Emerg Infect Dis* . 2011;17(5):940–1. DOI: <https://doi.org/10.3201/eid1705.101958>
- 342 17. Punda-Polić V, Mohar B, Duh D, Bradarić N, Korva M, Fajs L, et al. Evidence of an
343 autochthonous Toscana virus strain in Croatia. *J Clin Virol* . 2012;55(1):4–7. DOI:
344 <https://doi.org/10.1016/j.jcv.2012.06.006>

- 345 18. Dupouey J, Bichaud L, Ninove L, Zandotti C, Thirion-Perrier L, de Lamballerie X, et al. Toscana
346 virus infections: A case series from France. *J Infect* . 2014;68(3):290–5. DOI:
347 <https://doi.org/10.1016/j.jinf.2013.11.006>
- 348 19. Mellace F, Del Manso M, Oradini-Alacreu A, Ceccarelli E, Mateo-Urdiales A, Petrone D, et al.
349 Meningiti, meningo-encefaliti ed encefaliti da virus Toscana in Italia, 2016-2021. Punta
350 dell'iceberg di una arbovirosi endemica poco conosciuta. *Boll Epidemiol Naz* . 2024;3(2):10–9.
- 351 20. Baldelli F, Grazia Ciufolini M, Francisci D, Marchi A, Venturi G, Fiorentini C, et al. Unusual
352 Presentation of Life-Threatening Toscana Virus Meningoencephalitis. *Clin Infect Dis* .
353 2004;38(4):515–20. DOI: <https://doi.org/10.1086/381201>
- 354 21. Oechtering J, Petzold GC. Acute hydrocephalus due to impaired CSF resorption in Toscana
355 virus meningoencephalitis. *Neurology* . 2012;79(8):829–31. DOI:
356 <https://doi.org/10.1212/WNL.0b013e3182661f1>
- 357 22. Calisher CH, Weinberg AN, Muth DJ, Lazuick JS. Toscana virus infection in United States citizen
358 returning from Italy. *Lancet (London, England)* . 1987;1(8525):165–6. DOI:
359 23. Epelboin L, Hausfater P, Schuffenecker I, Riou B, Zeller H, Bricaire F, et al. Meningoencephalitis
360 Due to Toscana Virus in a French Traveler Returning From Central Italy. *J Travel Med* .
361 2008;15(5):361–3. DOI: <https://doi.org/10.1111/j.1708-8305.2008.00221.x>
- 362 24. Sanbonmatsu-Gómez S, Pérez-Ruiz M, Collao X, Sánchez-Seco MP, Morillas-Márquez F, de la
363 Rosa-Fraile M, et al. Toscana virus in Spain. *Emerg Infect Dis* . 2005;11(11):1701–7. DOI:
364 <https://doi.org/10.3201/eid1111.050851>
- 365 25. Kay MK, Gibney KB, Riedo FX, Kosoy OL, Lanciotti RS, Lambert AJ. Toscana virus infection in
366 American traveler returning from Sicily, 2009. *Emerg Infect Dis* . 2010;16(9):1498–500. DOI:
367 <https://doi.org/10.3201/eid1609.100505>
- 368 26. Greco F, Mauro MV, Tenuta R, Apuzzo G, Giraldi C. A new case of meningitis due to Toscana
369 virus . Vol. 35, *NEW MICROBIOLOGICA*. 2012; 1:35(1):99.
- 370 27. Suardi LR, Di Lauria N, Pozzi M, Rogasi PG, Barilaro A, Azzolini F, et al. Acute cerebellar ataxia:

- 371 a rare Toscana Virus (TOSV) meningoencephalitis complication. 2019;130(3):276–8. DOI:
372 <https://doi.org/10.1080/00207454.2019.1673748>
- 373 28. Matusali G, D’Abramo A, Terrosi C, Carletti F, Colavita F, Vairo F, et al. Infectious Toscana Virus
374 in Seminal Fluid of Young Man Returning from Elba Island, Italy. *Emerg Infect Dis* .
375 2022;28(4):865. DOI: <https://doi.org/10.3201/eid2804.211920>
- 376 29. Howell BA, Azar MM, Landry ML, Shaw AC. Toscana virus encephalitis in a traveler returning
377 to the United States. *J Clin Microbiol* . 2015;53(4):1445–7. DOI: [https://doi.org/](https://doi.org/10.1128/JCM.03498-14)
378 [10.1128/JCM.03498-14](https://doi.org/10.1128/JCM.03498-14)
- 379 30. Ocal M, Orsten S, Inkaya AC, Yetim E, Acar NP, Alp S, et al. Ongoing Activity of Toscana Virus
380 Genotype A and West Nile Virus Lineage 1 Strains in Turkey: A Clinical and Field Survey.
381 *Zoonoses Public Health* . 2014;61(7):480–91. DOI: <https://doi.org/10.1111/zph.12096>
- 382 31. Bartels S, Boni L, Kretzschmar HA, Heckmann JG. Lethal encephalitis caused by the Toscana
383 virus in an elderly patient. *J Neurol* . 2012;259(1):175–7. DOI:
384 <https://doi.org/10.1007/s00415-011-6121-y>
- 385 32. Martínez-García FA, Moreno-Docón A, Segovia-Hernández M, Fernández-Barreiro A.
386 [Deafness as a sequela of Toscana virus meningitis]. *Med Clin (Barc)* . 2008;130(16):639. DOI:
387 <https://doi.org/10.1157/13120347>
- 388 33. Osborne JC, Khatamzas E, Misbahuddin A, Hart R, Sivaramakrishnan A, Breen DP. Toscana
389 virus encephalitis following a holiday in Sicily. *Pract Neurol* . 2016;16(2):139–41. DOI:
390 <https://doi.org/10.1136/practneurol-2015-001265>
- 391 34. Serata D, Rapinesi C, Del Casale A, Simonetti A, Mazzarini L, Ambrosi E, et al. Personality
392 Changes After Toscana Virus (TOSV) Encephalitis in a 49-Year-Old Man: A Case Report. *Int J*
393 *Neurosci* . 2011;121(3):165–9. DOI: <https://doi.org/10.3109/00207454.2010.537412>
- 394 35. Ocal M, Orsten S, Inkaya AC, Yetim E, Acar NP, Alp S, et al. Ongoing Activity of Toscana Virus
395 Genotype A and West Nile Virus Lineage 1 Strains in Turkey: A Clinical and Field Survey.
396 *Zoonoses Public Health* . 2014;61(7):480–91. DOI: <https://doi.org/10.1111/zph.12096>

- 397 36. Rota E, Morelli N, Immovilli P, De Mitri P, Guidetti D. Guillain-Barré-like axonal
398 polyneuropathy associated with Toscana virus infection: A case report. *Medicine (Baltimore)* .
399 2017;96(38):e8081. DOI: <https://doi.org/10.1097/MD.0000000000008081>
- 400 37. Okar SV, Bekircan-Kurt CE, Hacıoğlu S, Erdem-Özdamar S, Özkul A, Ergünay K. Toscana virus
401 associated with Guillain–Barré syndrome: a case–control study. *Acta Neurol Belgica* 2020
402 1213 . 2020;121(3):661–8. DOI: <https://doi.org/10.1007/s13760-020-01279-5>
- 403 38. Tappe D, Schmidt-Chanasit J, Günther S, Ries A, Ziegler U, Müller A, et al. Acute Toscana virus
404 infection mimicked by Yersinia-induced reactive arthritis syndrome after journey to Spain. *J*
405 *Clin Virol*. 2010;47(1):104–5.
- 406 39. Echevarría J-M, de Ory F, Guisasola M-E, Sánchez-Seco M-P, Tenorio A, Lozano Á, et al. Acute
407 meningitis due to Toscana virus infection among patients from both the Spanish
408 Mediterranean region and the region of Madrid. *J Clin Virol* . 2003;26(1):79–84. DOI:
409 [https://doi.org/10.1016/S1386-6532\(02\)00041-0](https://doi.org/10.1016/S1386-6532(02)00041-0)
- 410 40. Anagnostou V, Pardalos G, Athanasiou-Metaxa M, Papa A. Novel phlebovirus in febrile child,
411 Greece. *Emerg Infect Dis* . 2011;17(5):940–1. DOI: <https://doi.org/10.3201/eid1705.101958>
- 412 41. Zanelli G, Bianco C, Cusi MG. Testicular involvement during Toscana virus infection: an
413 unusual manifestation? *Infection* . 2013;41(3):735–6. DOI: [https://doi.org/10.1007/s15010-](https://doi.org/10.1007/s15010-012-0368-9)
414 [012-0368-9](https://doi.org/10.1007/s15010-012-0368-9)
- 415 42. Schultze D, Korte W, Rafeiner P, Niedrig M. First report of sandfly fever virus infection
416 imported from Malta into Switzerland, October 2011. *Euro Surveill* . 201;17(27). DOI:
417 <https://doi.org/10.2807/ese.17.27.20209-en>
- 418 43. Arden KE, Heney C, Shaban B, Nimmo GR, Nissen MD, Sloots TP, et al. Detection of Toscana
419 virus from an adult traveler returning to Australia with encephalitis. *J Med Virol* .
420 2017;89(10):1861–4. DOI: <https://doi.org/10.1002/jmv.24839>
- 421 44. Dominati A, Sap L, Vora S. [Fever in a returning traveler from Tuscany]. *Rev Med Suisse* .
422 2018;14(592):294–6.

- 423 45. Vilibic-Cavlek T, Zidovec-Lepej S, Ledina D, Knezevic S, Savic V, Tabain I, et al. Clinical,
424 Virological, and Immunological Findings in Patients with Toscana Neuroinvasive Disease in
425 Croatia: Report of Three Cases. *Trop Med Infect Dis* 2020, Vol 5, Page 144 . 2020;5(3):144.
426 DOI: <https://doi.org/10.3390/tropicalmed5030144>
- 427 46. Gámbaro F, Pérez AB, Prot M, Agöera E, Baidaliuk A, Sánchez-Seco MP, et al. Untargeted
428 metagenomic sequencing identifies Toscana virus in patients with idiopathic meningitis,
429 southern Spain, 2015 to 2019. *Eurosurveillance*. 2023;28(45):2200913. DOI:
430 <https://doi.org/10.2807/1560-7917.ES.2023.28.45.2200913>
- 431 47. Nicoletti L, Renzi A, Caciolli S, Nicoletti L, Bartolozzi D, Balducci M, et al. Central Nervous
432 System Involvement during Infection by Phlebovirus Toscana of Residents in Natural Foci in
433 Central Italy (1977–1988). *Am J Trop Med Hyg* . 1991;45(4):429–34. DOI:
434 <https://doi.org/10.4269/ajtmh.1991.45.429>
- 435 48. Pauli C, Schwarz TF, Meyer CG, Jager G. [Neurological symptoms after an infection by the
436 sandfly fever virus]. *Dtsch Med Wochenschr* . 1995;120(43):1468–72. DOI:
437 <https://doi.org/10.1055/s-2008-1055501>
- 438 49. Mosnier E, Charrel R, Vidal B, Ninove L, Schleinitz N, Harlé JR, et al. Toscana virus myositis and
439 fasciitis. *Med Mal Infect* . 2013;43(5):208–10. DOI:
440 <https://doi.org/10.1016/j.medmal.2013.04.002>
- 441 50. Erdem H, Ergunay K, Yilmaz A, Naz H, Akata F, Inan AS, et al. Emergence and co-infections of
442 West Nile virus and Toscana virus in Eastern Thrace, Turkey. *Clin Microbiol Infect* .
443 2014;20(4):319–25. DOI: <https://doi.org/10.1111/1469-0691.12310>
- 444 51. Schirmer L, Wölfel S, Georgi E, Ploner M, Bauer B, Hemmer B. Extensive Recruitment of
445 Plasma Blasts to the Cerebrospinal Fluid in Toscana Virus Encephalitis. *Open Forum Infect Dis* .
446 2015;2(3):ofv124. DOI: <https://doi.org/10.1093/ofid/ofv124>
- 447 52. Popescu CP, Cotar AI, Dinu S, Zaharia M, Tardei G, Ceausu E, et al. Emergence of Toscana
448 Virus, Romania, 2017–2018. *Emerg Infect Dis* . 2021;27(5):1482. DOI: <https://doi.org/>

- 449 10.3201/eid2705.204598
- 450 53. Quattrone F, Mazzetti P, Aquino F, Sani S, Carneglia L, Pistello M, et al. Two clusters of
451 Toscana virus meningo-encephalitis in Livorno Province and Elba Island, July-September 2018.
452 *Ann Ig* . 2020;32(6):674–81. DOI: <https://doi.org/10.7416/ai.2020.2387>
- 453 54. Tschumi F, Schmutz S, Kufner V, Heider M, Pigny F, Schreiner B, et al. Meningitis and
454 epididymitis caused by Toscana virus infection imported to Switzerland diagnosed by
455 metagenomic sequencing: A case report. *BMC Infect Dis*. 2019;19(1). DOI:
456 <https://doi.org/10.1186/s12879-019-4231-9>
- 457 55. Mascitti H, Calin R, Dinh A, Makhoulfi S, Davido B. Testicular pain associated with clear fluid
458 meningitis: How many cases of Toscana virus are we missing? *Int J Infect Dis*. 2020;1:93:198–
459 200. DOI: <https://doi.org/10.1016/j.ijid.2020.02.008>
- 460 56. Kuhn J, Bewermeyer H, Hartmann-Klosterkoetter U, Emmerich P, Schilling S, Valassina M.
461 Toscana virus causing severe meningoencephalitis in an elderly traveller. *J Neurol Neurosurg
462 Psychiatry* . 2005;76(11):1605–6. DOI: <https://doi.org/10.1136/jnnp.2004.060863>
- 463 57. Braitto A, Corbisiero R, Corradini S, Marchi B, Sancasciani N, Fiorentini C, et al. Evidence of
464 Toscana virus infections without central nervous system involvement: A serological study. *Eur
465 J Epidemiol* . 1997;13(7):761–4. DOI: <https://doi.org/10.1023/A:1007422103992>
- 466 58. Dionisio D, Valassina M, Ciufolini MG, Vivarelli A, Esperti F, Cusi MG, et al. Encephalitis
467 without Meningitis Due to Sandfly Fever Virus Serotype Toscana. *Clin Infect Dis* .
468 2001;32(8):1241–3. DOI: <https://doi.org/10.1086/319759>
- 469 59. Gabriel M, Resch C, Günther S, Schmidt-Chanasit J. Toscana virus infection imported from Elba
470 into Switzerland. *Emerg Infect Dis* . 2010;16(6):1034–6. DOI: [https://doi.org/
471 10.3201/eid1606.091763](https://doi.org/10.3201/eid1606.091763)
- 472 60. Serata D, Rapinesi C, Del Casale A, Simonetti A, Mazzarini L, Ambrosi E, et al. Personality
473 Changes After Toscana Virus (TOSV) Encephalitis in a 49-Year-Old Man: A Case Report. *Int J
474 Neurosci* . 2011;121(3):165–9. DOI: <https://doi.org/10.3109/00207454.2010.537412>

- 475 61. Nicuolo G Di, Pagliano P, Battisti S, Starace M, Mininni V, Attanasio V, et al. Toscana Virus
476 Central Nervous System Infections in Southern Italy. *J Clin Microbiol* . 2005;43(12):6186–8.
477 DOI: <https://doi.org/10.1128/JCM.43.12.6186-6188.2005>
- 478 62. Doudier B, Ninove L, Million M, de Lamballerie X, Charrel RN, Brouqui P. Unusual Toscana
479 virus encephalitis in southern France. *Med Mal Infect* . 2011;1(41):50–1. DOI: [https://doi.org/](https://doi.org/10.1016/j.medmal.2010.09.006)
480 [10.1016/j.medmal.2010.09.006](https://doi.org/10.1016/j.medmal.2010.09.006)
- 481 63. Marlinge M, Crespy L, Zandotti C, Piorkowski G, Kaphan E, Charrel RN, et al. A febrile
482 meningoencephalitis with transient central facial paralysis due to Toscana virus infection,
483 south-eastern France, 2014. *Eurosurveillance*. 2014; 4;19(48):20974. DOI:
484 <https://doi.org/10.2807/1560-7917.ES2014.19.48.20974>
- 485 64. Jaijakul S, Arias CA, Hossain M, Arduino RC, Wootton SH, Hasbun R. Toscana
486 meningoencephalitis: A comparison to other viral central nervous system infections. *J Clin*
487 *Virol* . 2012;55(3):204–8. DOI: <https://doi.org/10.1016/j.jcv.2012.07.007>
- 488 65. Laroche L, Jourdain F, Ayhan N, Bañuls AL, Charrel R, Prudhomme J. Incubation Period for
489 Neuroinvasive Toscana Virus Infections. *Emerg Infect Dis* . 2021;27(12):3147. DOI:
490 <https://doi.org/10.3201/eid2712.203172>
- 491 66. Masse S, Ayhan N, Capai L, Bosseur F, de Lamballerie X, Charrel R, et al. Circulation of Toscana
492 Virus in a Sample Population of Corsica, France. *Viruses*. 2019;11(9):817. DOI:
493 <https://doi.org/10.3390/v11090817>
- 494 67. McDonald E, Mathis S, Martin SW, Erin Staples J, Fischer M, Lindsey NP. Surveillance for West
495 Nile Virus Disease — United States, 2009–2018. *MMWR Surveill Summ*. 2021;70(1):1–15. DOI:
496 <http://dx.doi.org/10.15585/mmwr.ss7001a1>
- 497 68. Sanbonmatsu-Gámez S, Pérez-Ruiz M, Palop-Borrás B, Navarro-Marí JM. Unusual
498 manifestation of toscana virus infection, Spain. *Emerg Infect Dis* . 2009;15(2):347–8. DOI:
499 <https://doi.org/10.3201/eid1502.081001>
- 500 69. Schwarz TF, Jager G, Gilch S, Pauli C. Serosurvey and laboratory diagnosis of imported sandfly

- 501 fever virus, serotype Toscana, infection in Germany. *Epidemiol Infect* . 1995;114:501–10. DOI:
502 <https://doi.org/10.1017/S0950268800052213>
- 503 70. Hemmersbach-Miller M, Parola P, Charrel RN, Paul Durand J, Brouqui P. Sandfly fever due to
504 Toscana virus: an emerging infection in southern France. *Eur J Intern Med*. 2004 1;15(5):316–
505 7. DOI: <https://doi.org/10.1016/j.ejim.2004.05.006>
- 506 71. Kuhn J, Bewermeyer H, Hartmann-Klosterkoetter U, Emmerich P, Schilling S, Valassina M.
507 Toscana virus causing severe meningoencephalitis in an elderly traveller. *J Neurol Neurosurg*
508 *Psychiatry* . 2005;76(11):1605–6. DOI: <https://doi.org/10.1136/jnnp.2004.060863>
- 509 72. Oechtering J, Petzold GC. Acute hydrocephalus due to impaired CSF resorption in Toscana
510 virus meningoencephalitis. *Neurology* . 2012;79(8):829–31. DOI:
511 <https://doi.org/10.1212/WNL.0b013e3182661f1a>
- 512 73. Epelboin L, Hausfater P, Schuffenecker I, Riou B, Zeller H, Bricaire F, et al. Meningoencephalitis
513 Due to Toscana Virus in a French Traveler Returning From Central Italy. *J Travel Med* .
514 2008;15(5):361–3. DOI: <https://doi.org/10.1111/j.1708-8305.2008.00221.x>
- 515 74. Zanelli G, Bianco C, Cusi MG. Testicular involvement during Toscana virus infection: an
516 unusual manifestation? *Infection* . 2013;41(3):735–6. DOI: [https://doi.org/10.1007/s15010-](https://doi.org/10.1007/s15010-012-0368-9)
517 [012-0368-9](https://doi.org/10.1007/s15010-012-0368-9)
- 518 75. Kvam KA, Stahl JP, Chow FC, Soldatos A, Tattevin P, Sejvar J, et al. Outcome and Sequelae of
519 Infectious Encephalitis. *J Clin Neurol* . 2024;20(1):23. DOI: [https://doi.org/10.3988/jcn.](https://doi.org/10.3988/jcn.2023.0240)
520 [2023.0240](https://doi.org/10.3988/jcn.2023.0240)
- 521 76. Francisci D, Papili R, Camanni G, Morosi S, Ferracchiato N, Valente M, et al. Evidence of
522 Toscana virus circulation in Umbria: First report. *Eur J Epidemiol*. 2003;18(5):457–9. DOI:
523 <https://doi.org/10.1023/A:1024295710118>
- 524 77. Vocale C, Bartoletti M, Rossini G, Macini P, Pascucci MG, Mori F, et al. Toscana Virus Infections
525 in Northern Italy: Laboratory and Clinical Evaluation. *Vector-Borne Zoonotic Dis* .
526 2012;12(6):526–9. DOI: <https://doi.org/10.1089/vbz.2011.0781>

