

Efficacy and Safety of Middle Meningeal Artery Embolization for Patients with Chronic Subdural Hematoma: A Systematic Review and Meta-Analysis

Kabir N¹, Owais B¹, Trifan G¹, Testai FD¹

¹ Department of Neurology and Rehabilitation, University of Illinois College of Medicine at Chicago, Chicago, IL

Corresponding author:

Kabir, Nabihah, MD

Department of Neurology and Rehabilitation

University of Illinois College of Medicine at Chicago

Chicago, IL, 60612

Email: nabihah@uic.edu

Keywords: chronic subdural hemorrhage, middle meningeal artery embolization, recurrent hematoma, best medical management

1 **Background:** Chronic subdural hematoma (CSDH) is characterized by the collection of blood
2 beneath the dura mater. Traditional treatments involve surgical drainage of the hematoma, but
3 recurrence rates can be high. A highly vascularized neo-membrane irrigated by the middle
4 meningeal artery (MMA) may be involved in CSDH re-accumulation.

5 **Objective:** We conducted a systematic review and meta-analysis of studies that compared the
6 efficacy and safety of MMA embolization to conventional treatment alone for CSDH.

7 **Material and Methods:** A systematic search of PubMed, Embase Ovid, and ClinicalTrials.gov
8 identified observational and randomized clinical studies comparing MMA embolization to
9 conventional treatment for chronic subdural hematoma. The efficacy outcomes were hematoma
10 recurrence and good functional outcome (as defined by a modified Rankin Scale score (mRS) of
11 0-2). Safety outcomes were the rate of major complication and mortality. Heterogeneity among
12 studies were evaluated using the I^2 statistic. Analyses were conducted using Cochrane Review
13 Manager software, with risk ratios (RR) and 95% confidence intervals (95% CI) presented for
14 key outcomes. Absolute risk reduction (ARR, 95% CI) 1000 patients were also calculated using
15 GRADEpro software.

16 **Results:** The analysis included data from 13 studies (4 RCTs and 9 observational studies) with
17 a total number of 2960 patients (35.3% in the MMA group and 64.7% in the conventional
18 treatment group). Compared to conventional treatment, MMA embolization decreased risk of
19 hematoma recurrence by 60% (13 studies, RR=0.40, 95% CI 0.25-0.63; $I^2=50\%$), for an
20 absolute effect of 119 fewer events/1000 patients (95% CI 70-149), with similar risk of major
21 complications (9 studies, RR=0.82, 95% CI=0.54-1.25) and mortality risk (13 studies, RR=0.90,
22 95% CI=0.54-1.51). In subgroup analyses by study type, pooled results from RCTs showed
23 similar direction effects as those from observational studies for both efficacy and safety
24 outcomes.

25 **Conclusion:** MMA embolization in CSDH management is a safe and effective approach for
26 CSDH.

27 **Introduction**

28
29 Chronic subdural hematoma (CSDH) refers to the accumulation of blood, blood-degradation
30 products, of fluid between the dura mater and the arachnoid. CSDH affects preponderantly the
31 elderly and has an estimated incidence of 1.7 to 20.6 per 100,000 persons per year.¹ However,
32 based on the increase in global life expectancy and the trends obtained in observational studies,
33 it is projected that the incidence of this condition will continue to rise². The traditional
34 management of CSDH, which includes surgical drainage, is associated with periprocedural
35 complications and recurrence rates that range from 3% to 30%³. Historically, it was considered
36 that CSDH was the consequence of venous oozing secondary to traumatic injury of the bridging
37 veins. However, cumulative evidence indicates that, although trauma, even if mild, may
38 constitute an initial insult, the pathogenesis of CSDH involves the development of a layer of
39 connective tissue cells that leads to the formation of a new membrane⁴. This membrane is
40 enriched in pro-inflammatory and pro-angiogenic mediators, such as tissue-plasminogen
41 activators, matrix-metalloproteinases, and vascular endothelial growth factor. These mediators
42 contribute to the development of leaky vessels that result in repeated microbleeds and the
43 exudation of fluid. This phenomenon further enhances inflammation and results in a vicious
44 cycle that perpetuates CSDH and contributes to its recurrence.

45 Since the vascular supply to this new membrane derives from the middle meningeal artery
46 (MMA), it has been proposed that the embolization of the MMA may reduce the risk of
47 hematoma growth and recurrence. Since the MMA is a branch of the external carotid artery, it
48 was considered that this procedure would not significantly increase the risk of cerebrovascular
49 complications. Data supporting the benefit and safety of endovascular embolization of the MMA
50 as an adjunct to surgical drainage originates from non-randomized retrospective studies and
51 registries. In a meta-analysis including non-randomized studies, MMA embolization had lower
52 rates of CSDH recurrence and need for surgical rescue with comparable rates of in-hospital

53 complications⁵. The results of three randomized clinical trials (RCTs) assessing the benefits and
54 risks of MMA embolization as an adjunct therapy for patients with CSDH were recently
55 reported⁶⁷⁸⁹⁻¹¹. Here we present the results of a meta-analysis where we assessed the efficacy
56 and safety of MMA for the treatment of patients with CSDH.

57

58 **Material and Methods**

59 Our study follows the Preferred Reporting Items for Systematic Reviews and Meta-Analyses
60 (PRISMA) statement guidelines¹². This protocol is registered in PROSPERO, trial number
61 IDCRD42024515860. Data is available from the corresponding author upon reasonable request.
62 No informed consent was required from the human subjects given the nature of the analysis.

63

64 **Eligibility Criteria and Outcomes**

65 This study included randomized controlled clinical trials and observational studies that
66 compared the efficacy and safety of MMA embolization plus standard of care (conservative or
67 surgical treatment) to standard of care alone for patients with CSDH. Studies that only reported
68 outcomes for MMA embolization without separately reporting the outcomes for conventional
69 management only, case reports, and non-peer-reviewed studies were excluded. The primary
70 efficacy outcome was the risk of hematoma recurrence, and the safety outcome was mortality
71 risk. In a secondary analysis, we investigated the risk of good functional outcomes defined as
72 modified Rankin Scale Score (mRS) of 0-2 at follow-up and the frequency of major
73 complications. **Supplemental Table 1** depicts the definitions used in each trial. Given the wildly
74 variable definitions for the safety endpoints used in the RCTs (**Supplementary Table 2**), we
75 only report here the rates of safety points from each RCT, while presenting the pooled results of
76 safety outcomes of the observational studies.

77 **Information Sources and Search Methods**

78 We queried PubMed, Embase Ovid, and ClinicalTrials.gov from inception to February 2024. The
79 search algorithm is shown in **Appendix 1**. The results were screened for inclusion criteria by 2
80 of the authors (GT and FDT). Disagreements were resolved using the other two authors (NK
81 and BO). Information on trial design, sample size, mean age, sex, laterality of the hematoma
82 (unilateral vs bilateral), etiology, baseline CSDH volume or thickness, and mean follow-up time,
83 along with the safety and efficacy outcomes were collected.

84 **Statistical Analyses and Bias Assessment**

85 Two of the authors (GT and FDT) independently determined the risk of bias in RCTs using the
86 RoB2 (Revised Cochrane Risk of Bias) tool¹³; the risk of bias in nonrandomized studies was
87 assessed using the intervention (ROBINS-I) tool¹⁴. Publication bias was investigated by visual
88 inspection of funnel plots for asymmetry for each reported outcome. Heterogeneity between
89 studies was quantified using I^2 statistic, and as recommended by the American Heart
90 Association¹⁵, using the following cut-offs: 0–40%: might not be important; 30–60%: may
91 represent moderate heterogeneity; 50–90%: may represent substantial heterogeneity; and 75–
92 100%: considerable heterogeneity. To further investigate heterogeneity, subgroup analysis by
93 study design was performed.

94 Analyses were done using Cochrane Review Manager (v 5.4)¹⁶. Descriptive characteristics of
95 the included studies were recorded. Event rates for each efficacy and safety outcome of interest
96 were compared between MMA embolization plus conventional treatment and conventional
97 management alone. Results are presented as risk ratios along with their corresponding 95%
98 confidence intervals (CI), using random-effects Mantel-Haenszel method. The absolute number
99 of events per 1000 patients (absolute risk reduction, 95% CI) was calculated using the
100 GRADEpro software¹⁷.

101

102

103

104 **Results**

105 **Study Selection and Characteristics**

106 The search yielded a total of 3,978 records. Of these, 13 studies with 2,960 patients (35.3% in
107 the MMA group and 64.7% in the conventional treatment group) were included in the final
108 analysis (**Figure 1**). There were 9 observational studies and 4 RCTs. Three of the RCTs were
109 recently presented at the 2024 International Stroke Conference⁶⁷⁸⁹⁻¹¹. Baseline characteristics
110 of the included studies are presented in **Table 1**. In the MMA group, mean (SD) age was 72.4±
111 4.6 years, 73.3% were males, and mean SDH thickness was 18± 4.6. Comparatively, in the
112 MMA group mean age was 70.6± 5.4 years, 70% were males, and the mean SDH thickness
113 was 18.5± 4.7 mm. Mean follow-up time between groups was similar among groups (3.2
114 months). The risk of bias across all studies, and for each included study is shown in
115 **Supplementary Figure 1**. Visual inspection of the funnel plots revealed symmetry for the main
116 outcomes (**Supplementary Figure 2**).

117 **Efficacy outcomes**

118 **Figure 2** depicts the risk of hematoma recurrence between adjunct MMA embolization and
119 conventional management alone for all studies. There was an absolute effect of 119 fewer
120 events per 1,000 patients (95% CI 70-149) and an overall risk reduction of 60% in favor of
121 adjunct MMA embolization compared with conventional treatment alone (13 studies, RR=0.40,
122 95% CI 0.25-0.63) with moderate heterogeneity ($I^2=50\%$). When analyzing by study design,
123 data from RCTs showed a risk reduction of hematoma recurrence with adjunct MMA
124 embolization of 52% (4 studies, RR=0.48, 95% CI=0.34-0.67), with low heterogeneity ($I^2=15\%$)
125 and an absolute effect of 86 fewer hematoma recurrences per 1,000 participants (95% CI 54-
126 109) (**Figure 2**). In comparison, observational studies showed a 74% risk reduction for
127 hematoma recurrence in favor of adjunct MMA (RR=0.26, 95% CI= 0.10-0.66) with substantial

128 heterogeneity ($I^2=64\%$) and an absolute effect of 167 fewer recurrences per 1,000 participants
129 (95% CI 63-203) (**Figure 2**).

130 Rates for good functional outcomes were available for 4 studies only (1 RCT and 3
131 observational studies). Overall risk for good functional outcome was similar between groups
132 (RR=1.02, 95% CI=0.98 -1.06) with no heterogeneity ($I^2=0\%$) (**Figure 2**).

133 **Safety outcomes**

134 **Figure 3** depicts the risk of major complications and mortality rates. Overall, the pooled risk of
135 major complications for all observational studies was 29% lower in the MMA group compared
136 with conventional treatment alone (9 studies, RR=0.82, 95% CI 0.54-1.25) with no heterogeneity
137 ($I^2=0\%$). The safety endpoint rates reported in each RCT varied between 5% to 16% for the
138 MMA group, compared to 4% to 22% in the conventional treatment group. Mortality rates were
139 similar as well for both groups (13 studies, RR=0.90, 95% CI=0.54 -1.51) with no heterogeneity
140 ($I^2=0\%$). When analyzed by study design, mortality rates were comparable for RCTs (RR=0.82,
141 95% CI 0.28-2.34; $I^2=45\%$) and observational studies (RR=0.87, 95% CI=0.42-1.81, $I^2=0\%$)
142 (**Figure 3**).

143

144 **Discussion**

145 The results of our meta-analysis show that MMA embolization added to conventional treatment
146 is superior to conventional treatment alone for the treatment of CSDH. Previous meta-analyses
147 that included data from retrospective cohorts have shown that MMA embolization is associated
148 with lower rates of hematoma recurrence and fewer complications¹⁵. However, the lack of data
149 from RCTs confounded the interpretation of these results. Limitations like retrospective data and
150 lack of separate reporting for conventional treatment hampered their generalizability⁵. This
151 updated meta-analysis addresses these issues by including recent RCTs and observational
152 studies with direct comparisons between MMA embolization with adjunct standard care and
153 standard care alone. In our study, which included the results from three new RCTs⁶⁷⁸, we

154 observed a 60% reduction in overall hematoma recurrence risk in favor of MMA embolization
155 plus conventional treatment compared to conventional treatment alone, for an absolute risk
156 reduction of 86 fewer hematoma recurrences per 1000 participants. In the subgroup analysis by
157 study design, the rate of hematoma recurrence reduction in favor of MMA was higher in
158 observational studies than in RCTs (74% vs. 52%). These differences could be explained, at
159 least in part, by methodologic factors, including patient selection, publication bias, and study
160 design. Also, several studies reported outcomes obtained in small cohorts which can increase
161 the type II error. Furthermore, the wide confidence intervals and moderate heterogeneity
162 observed in observational studies suggest elevated variability in the reported outcomes and
163 raise concerns about the precision of the calculated point estimates. In comparison, the analysis
164 using data from RCTs produced estimates with narrower confidence intervals and low
165 heterogeneity. Thus, the inclusion of adequately powered RCTs allows for a more accurate
166 estimation of the effect of MMA embolization on CSDH outcomes. This finding strengthens the
167 evidence for the efficacy of MMA embolization in chronic subdural hematoma.

168
169 The surgical interventions used for the treatment of CSDH, like burr-hole evacuation, are
170 considered safe. However, the rate of perioperative complications and mortality observed in
171 CSDH cohorts varies from 0% to 32%. These complications are not always caused by the
172 surgical procedure itself but are secondary to other factors such as preexisting active medical
173 conditions and frailty^{18,19}. MMA embolization, which is typically done endovascularly, is well
174 tolerated and is also considered safe. The MMA contributes minimally to cerebral blood flow,
175 and collateral circulation can effectively compensate for the blocked MMA, minimizing the risk of
176 cerebrovascular complications. Additionally, embolization is performed via the external carotid
177 artery, further reducing the risk of ischemic stroke²⁰. The overall incidence of complications in
178 cohorts treated with MMA embolization is less than 4%²¹. The safety of MMA embolization is
179 also supported by the results of previous meta-analyses which reported similar complication

180 rates for adjunct MMA embolization and conventional treatment groups.^{5 22} In our study, there
181 were no significant differences in the safety endpoint or mortality for the pooled results,
182 indicating that MMA embolization plus conventional treatment provides a safe alternative to
183 conventional management alone for CSDH. Future studies should assess the long-term
184 durability of the MMA effect and whether this approach allows the use of anticoagulation in
185 patients who require such treatment. Similar to previous studies, we observed that MMA
186 embolization as an adjunct treatment does not improve functional outcomes compared to
187 conventional management alone²². However, it should be noted that most of the studies
188 included in this analysis ascertained functional outcomes using the mRS. This scale is widely
189 used in stroke research. However, the sensitivity of this tool to detect differences in disability in
190 the particular case of SDH, where the neurologic deficits may be subtle, has not been well
191 described.

192

193 **Limitations**

194 Our meta-analysis has several limitations. First, the conventional treatment was not
195 standardized among studies; thus, there are intrinsic variations among the studies that we are
196 not able to account for. Second, there is variability in the definitions of efficacy and safety
197 outcomes among studies. Third, the majority of the studies included in our analysis had an
198 observational retrospective design with the consequent risk of selection bias²³. In addition, many
199 of them were performed in small cohorts and did not include power calculations. However, in
200 subgroup analysis, we observed that the results reported in observational studies are
201 comparable to those obtained in adequately powered RCTs. Fourth, we reported our results as
202 RRs and absolute effects. Because the absolute risk for control varies between trials, these
203 estimates should be interpreted with caution. However, our meta-analysis is the largest study
204 comparing the efficacy and safety of MMA as adjunct therapy to standard treatment alone for
205 patients with CSDH. In addition, we included the results of three large RCTs which, combined,

206 accounted for almost 75% of the final sample size and allowed us to calculate point estimates
207 with low heterogeneity.

208

209

210 **Conclusion**

211 MMA embolization as an adjunct treatment significantly decreases the recurrence of CSDH
212 without increasing the risk of morbidity or mortality when compared to conventional treatment
213 alone. Several studies are currently underway to compare the efficacy and safety of MMA
214 embolization as a standalone treatment for CSDH.

215

Table 1. Baseline Characteristics ⁵

Study, year	Design	Sample size		Lost to follow up/Exited, n(%)		Mean mm ±SD or median (IQR) age		Male, N(%)		Traumatic SDH, n(%)		Bilateral SDH, n(%)		Median (IQR)vol/thickness of baseline SDH in mm		Mean follow-up time (months)	
		MMA Treatment	Conventional	MMA treatment	Conventional	MMA Treatment	Conventional	MMA Treatment	Conventional	MMA Treatment	Conventional	MMA Treatment	Conventional	MMA Treatment	Conventional	MMA Treatment	Conventional
EMBOLISE, 2024	RCT	197	203	30 (15)	23 (11)	72.98±11.01 or [74.7]	70.99±11.28 or [72.5]	72.60%	73.40%	NR	NR	21.30%	18.20%	21.6±6.3	21.4±6.2	3	3
MAGIC-MT, 2024	RCT	360	362	NR	NR	68.5 (60-74)	70 (61-75)	81.10%	84%	178 (49.4)	201 (55.5)	NR	NR	22.8 (18.6-27.1)	22.4(18.5-26.8)	3	3
STEM, 2024	RCT	149	161	NR	NR	74.2 ± 9.8	74.2±10.3	67.2	74.5	NR	NR	NR	NR	NR	NR	3	3
Onyinzio et al, 2021	OR	50	82	28 (56%)	31 (37%)	79.2	77.4±10.3	42 (84%)	53 (65%)	NR	NR	NR	NR	21	23.5±4.7	3	3
Marulanda et al, 2021	OR	25	25	0	0	75 (70-87)	82(67-88)	14 (56)	16 (64)	10 (40)	7 (28)	0 (0)	0(0)	19(14-23.4)	18.1 (10.9-26.1)	2	3
Catapano et al, 2021	OR	35	196	NR	NR	68±12	71±13	25 (71%)	139 (71%)	23 (66%)	144 (73%)	6 (17%)	86 (43%)	15±3.9	15.3	3-4	3-4
Carpenter et al, 2021	OR	23	185	1 (4%)	5 (2%)	61±6.2	70.2±12.6	18 (82%)	123 (67%)	NR	NR	4 (17%)	46 (25%)	18±6	18±5	3-4	3-4
Shotar et al, 2020	OR	89	174	6 (6%)	12 (6%)	74±13	77±12	68 (76%)	123 (71%)	NR	NR	15 (17%)	36 (21%)	NR	NR	3	3
Ng et al, 2019	RCT	21	25	1 (5)	2 (8)	77.4±10.9	74.7±13.9	10 (53)	13 (59)	12 (63)	15 (68)	3 (16)	3 (14)	6.4±5.7	6.8±5.3	3	3
Ban et al, 2018	OP	72	469	0	0	69.3±10.4	67.4±13.16	48 (67%)	347 (74%)	45 (62%)	272 (58%)	19 (26%)	107 (23%)	19.6±5.00	20.3±6.47	3-6	3-6
Matsumoto et al, 2018	OR	4	10	0	0	NR	NR	NR	NR	NR	NR	NR	NR	NR	NR	3	3
Kim et al, 2017	OR	20	23	0	0	73.65±7.14	65.65±6.91	14 (70.0)	16(69.6)	8	17	6	1	18.9±7.58	21.01±6.21	3	3
Lam et al, 2023	RCT	16	19	0	3	64.2	72.4	12	11	13	16	9	4	21.1	20.9	3	3

RCT-randomized control trial; OR-observational retrospective study; OP-observational prospective trial; NR=not reported

Figure 1. PRISMA Flow Diagram

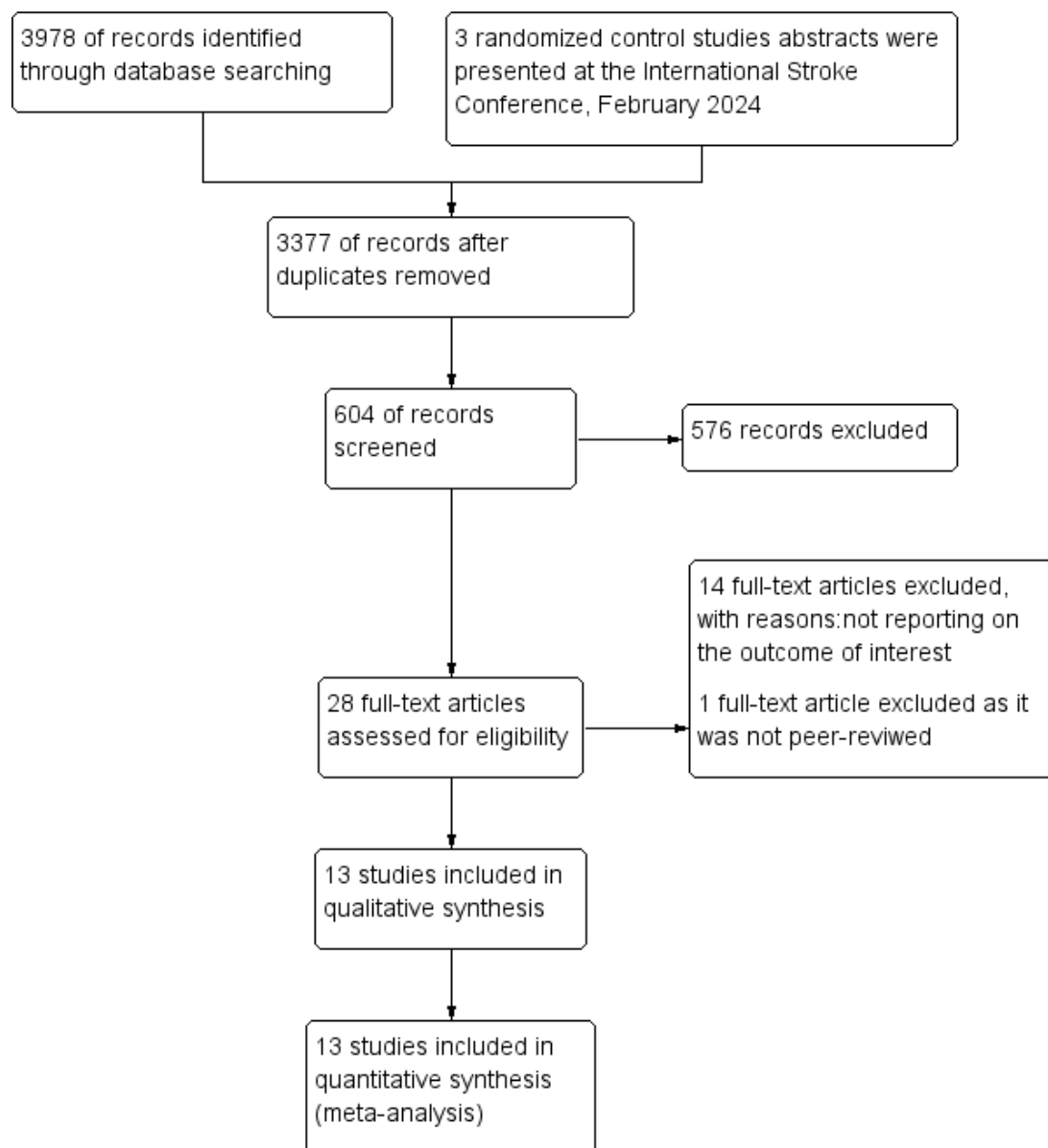
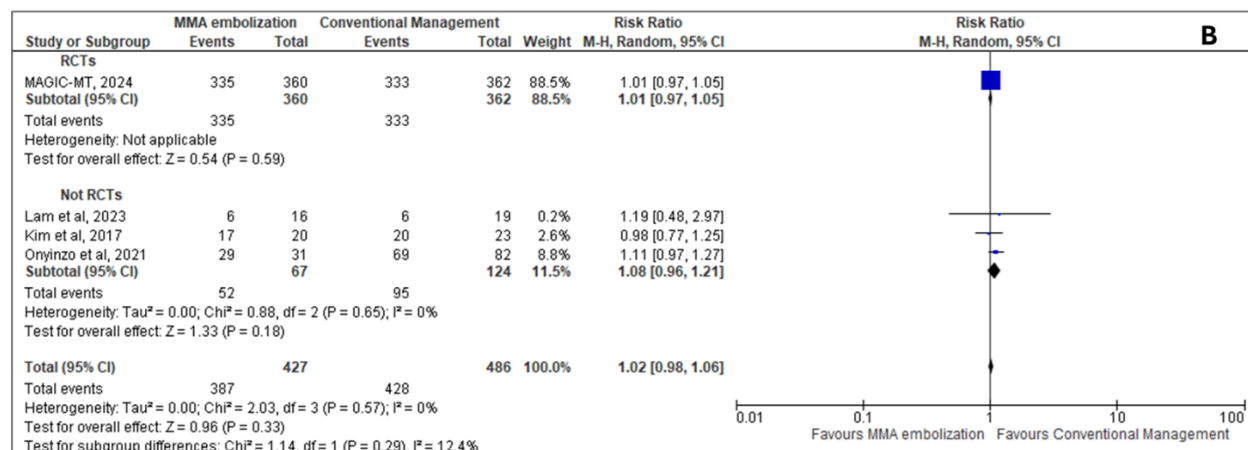
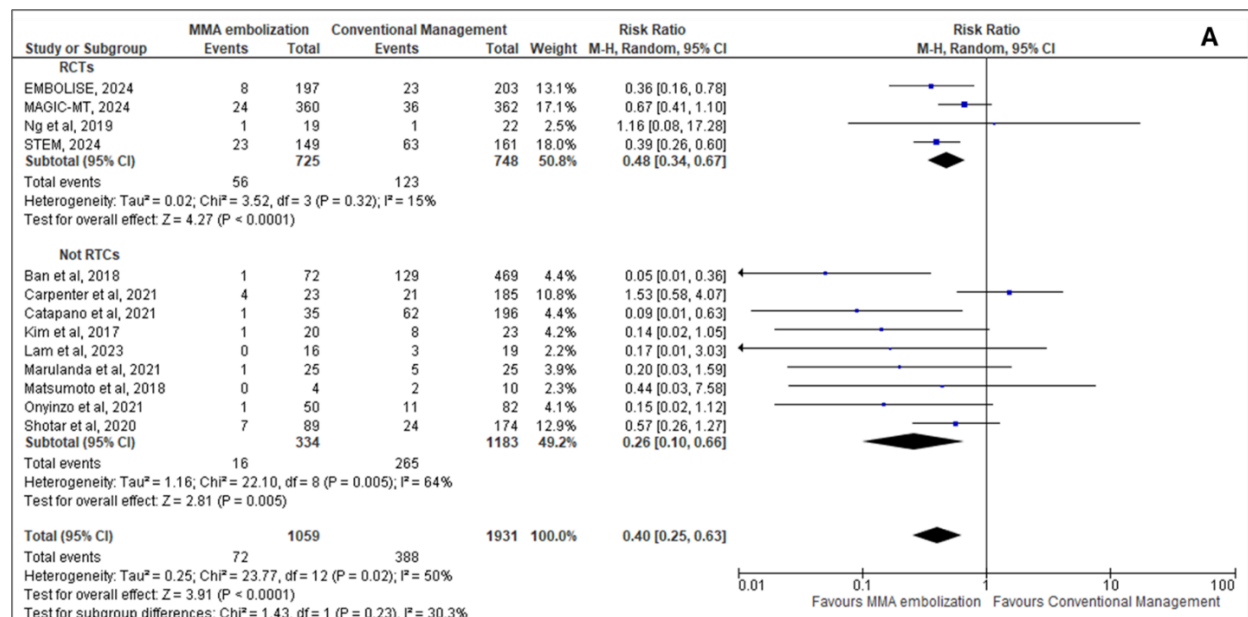
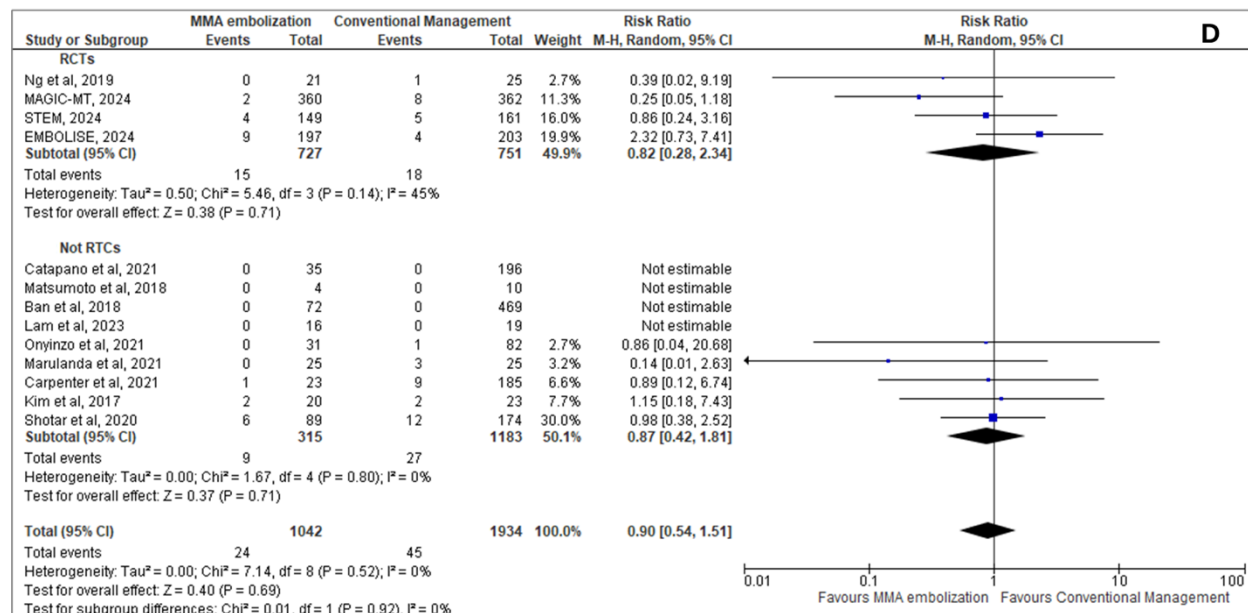
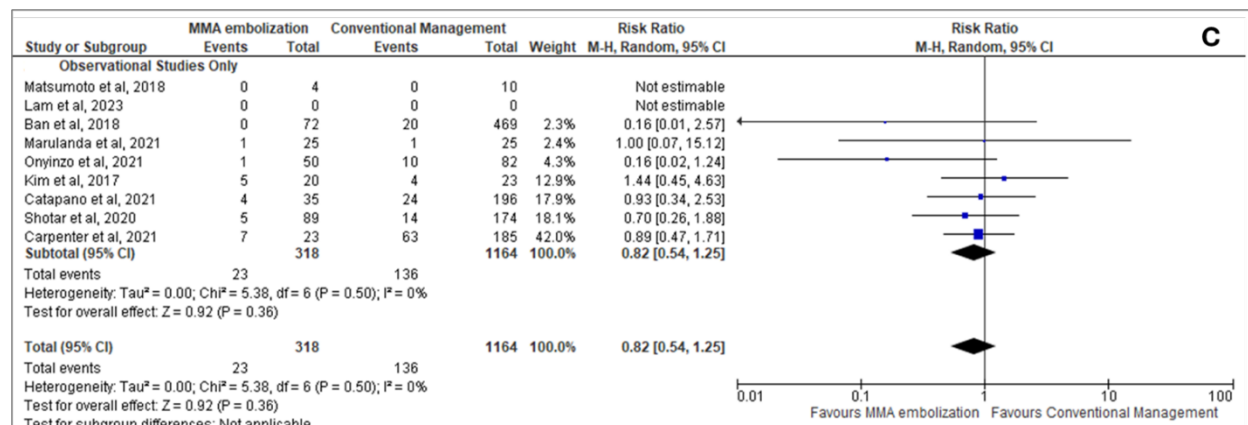


Figure 2. Efficacy outcome with and without MMA embolization.



Risk ratio for hematoma recurrence (A), and good functional outcome (mRS ≤ 2) (B) for patients receiving adjunct MMA embolization to conventional management vs conventional management only. M-H indicates the Mantel-Haenszel method; RCT: Randomized control trial.

Figure 3. Safety Outcomes with and without MMA embolization



Risk ratio for safety endpoints (C), as reported in each trial, and mortality (D) for patients receiving adjunct MMA embolization to conventional management vs conventional management only. M-H indicates Mantel-Haenszel method.

References

1. Feghali J, Yang W, Huang J. Updates in Chronic Subdural Hematoma: Epidemiology, Etiology, Pathogenesis, Treatment, and Outcome. *World Neurosurgery*. 2020;141:339-345. doi:10.1016/j.wneu.2020.06.140
2. Rauhala M, Helén P, Huhtala H, et al. Chronic subdural hematoma—incidence, complications, and financial impact. *Acta Neurochir*. 2020;162(9):2033-2043. doi:10.1007/s00701-020-04398-3
3. Balser D, Farooq S, Mehmood T, Reyes M, Samadani U. Actual and projected incidence rates for chronic subdural hematomas in United States Veterans Administration and civilian populations. *JNS*. 2015;123(5):1209-1215. doi:10.3171/2014.9.JNS141550
4. Ducruet AF, Grobelny BT, Zacharia BE, et al. The surgical management of chronic subdural hematoma. *Neurosurg Rev*. 2012;35(2):155-169. doi:10.1007/s10143-011-0349-y
5. Ironside N, Nguyen C, Do Q, et al. Middle meningeal artery embolization for chronic subdural hematoma: a systematic review and meta-analysis. *J NeuroIntervent Surg*. 2021;13(10):951-957. doi:10.1136/neurintsurg-2021-017352
6. Davies J, Knopman J. Embolization of the Middle Meningeal Artery With ONYX™ Liquid Embolic System for Subacute and Chronic Subdural Hematoma (EMBOLISE). ClinicalTrials.gov. Published June 24, 2024. <https://clinicaltrials.gov/study/NCT04402632?tab=history&a=9#study-details-card>
7. Mao Y. Managing Non-acute Subdural Hematoma Using Liquid Materials : a Chinese Randomized Trial of MMA Treatment (MAGIC-MT). ClinicalTrials.gov. Published April 30, 2024. <https://clinicaltrials.gov/study/NCT04700345>
8. Fiorella D, Arthur A. The SQUID Trial for the Embolization of the Middle Meningeal Artery for Treatment of Chronic Subdural Hematoma (STEM) (STEM). ClinicalTrials.gov. Published August 16, 2023. <https://clinicaltrials.gov/study/NCT04410146>
9. Davies J, Knopman J. Embolise Study - Interim Results from the Surgery Cohort. In: ; 2024. <https://www.abstractsonline.com/pp8/#!/10942/presentation/3767>
10. Mao Y. Managing non-Acute SDH using liquid materials: a chinese randomized trial of MMA Treatment (MAGIC-MT). In: ; 2024. <https://www.abstractsonline.com/pp8/#!/10942/presentation/3768>
11. Fiorella D, Arthur A. Squid Trial for the Embolization of the Middle Meningeal Artery for Treatment of Chronic Subdural Hematoma - Stem Trial. In: ; 2024. <https://www.abstractsonline.com/pp8/#!/10942/presentation/3770>
12. Liberati A, Altman DG, Tetzlaff J, et al. The PRISMA statement for reporting systematic reviews and meta-analyses of studies that evaluate health care interventions: explanation and elaboration. *Journal of Clinical Epidemiology*. 2009;62(10):e1-e34. doi:10.1016/j.jclinepi.2009.06.006

13. Sterne JAC, Savović J, Page MJ, et al. RoB 2: a revised tool for assessing risk of bias in randomised trials. *BMJ*. Published online August 28, 2019;14898. doi:10.1136/bmj.14898
14. Sterne JA, Hernán MA, Reeves BC, et al. ROBINS-I: a tool for assessing risk of bias in non-randomised studies of interventions. *BMJ*. Published online October 12, 2016;i4919. doi:10.1136/bmj.i4919
15. Rao G, Lopez-Jimenez F, Boyd J, et al. Methodological Standards for Meta-Analyses and Qualitative Systematic Reviews of Cardiac Prevention and Treatment Studies: A Scientific Statement From the American Heart Association. *Circulation*. 2017;136(10). doi:10.1161/CIR.0000000000000523
16. Review Manager (RevMan) [Computer program]. Version 5.4. The Cochrane Collaboration, 2020. [n.d].
17. GRADEpro software. Accessed February 28, 2024. https://gdt.gradepro.org/app/#projects/p_6a2cde5c-d39f-5fc9-8c87-1b9daae8942b_5d34fc4a-0465-46ba-a73b-820cdd349f02/evidence-syntheses/9dea65cc-bd3e-493d-9136-0057bbe093e1/quality-of-evidence
18. Koliaş AG, Chari A, Santarius T, Hutchinson PJ. Chronic subdural haematoma: modern management and emerging therapies. *Nat Rev Neurol*. 2014;10(10):570-578. doi:10.1038/nrneurol.2014.163
19. Atefi N, Alcock S, Silvaggio JA, Shankar J. Clinical Outcome and Recurrence Risk of Chronic Subdural Hematoma After Surgical Drainage. *Cureus*. 2023;15(2):e35525. doi:10.7759/cureus.35525
20. Désir LL, D'Amico R, Link T, et al. Middle Meningeal Artery Embolization and the Treatment of a Chronic Subdural Hematoma. *Cureus*. Published online October 18, 2021. doi:10.7759/cureus.18868
21. Gerstl J, Shafi M, Badikol S, et al. E-049 Complications of middle meningeal artery embolization – a systematic review. In: *SNIS 20th Annual Meeting Electronic Poster Abstracts*. BMJ Publishing Group Ltd.; 2023:A105.1-A105. doi:10.1136/jnis-2023-SNIS.149
22. Sattari SA, Yang W, Shahbandi A, et al. Middle Meningeal Artery Embolization Versus Conventional Management for Patients With Chronic Subdural Hematoma: A Systematic Review and Meta-Analysis. *Neurosurgery*. 2023;92(6):1142-1154. doi:10.1227/neu.0000000000002365
23. Lu H, Cole SR, Howe CJ, Westreich D. Toward a Clearer Definition of Selection Bias When Estimating Causal Effects. *Epidemiology*. 2022;33(5):699-706. doi:10.1097/EDE.0000000000001516

Supplemental Data:

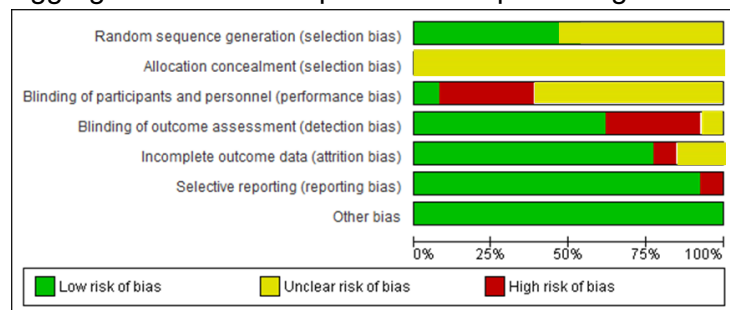
Supplementary Figure 1: Risk of bias across and between studies.

Risk of bias summary for each individual study. Authors' judgments about each risk of bias item for each included study.

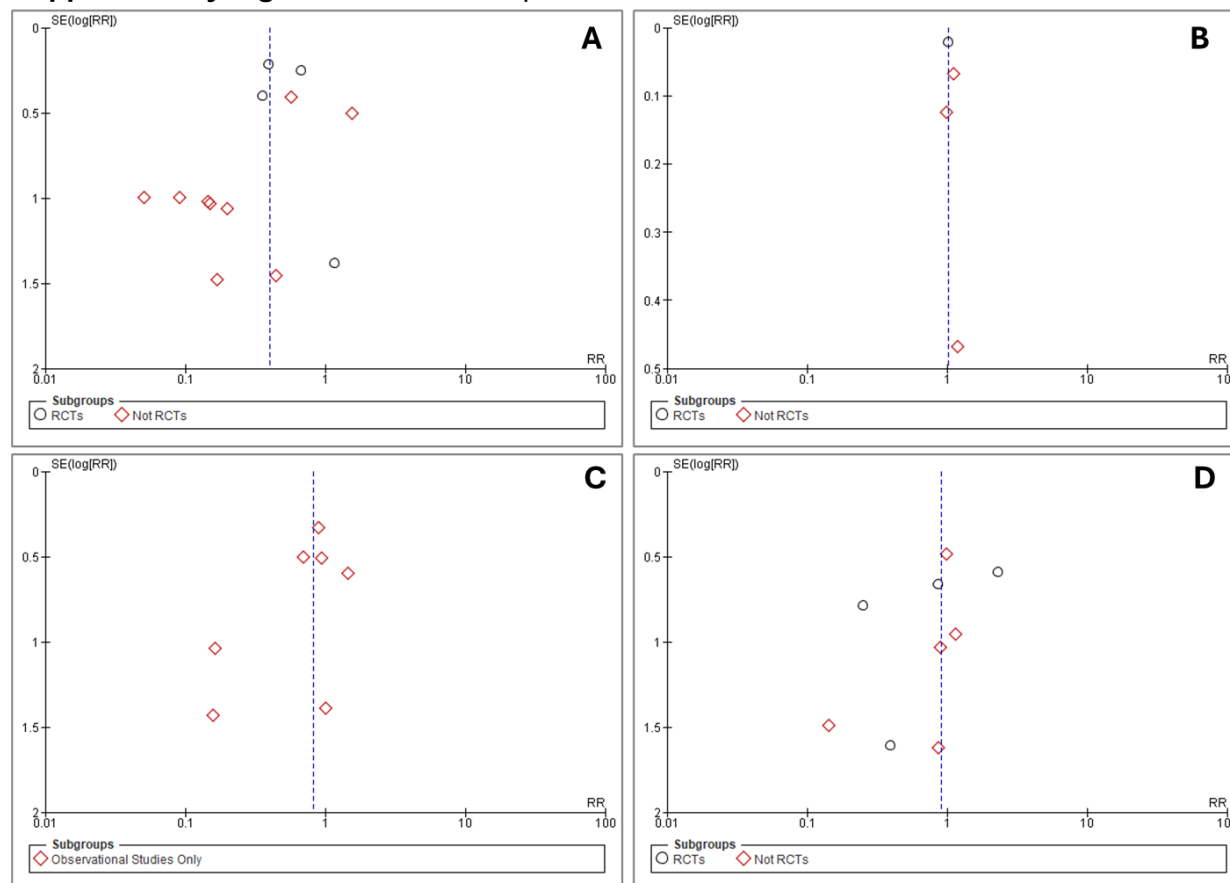
	Random sequence generation (selection bias)	Allocation concealment (selection bias)	Blinding of participants and personnel (performance bias)	Blinding of outcome assessment (detection bias)	Incomplete outcome data (attrition bias)	Selective reporting (reporting bias)	Other bias
Ban et al, 2018	?	?	?	+	+	+	+
Carpenter et al, 2021	?	?	?	+	+	+	+
Catapano et al, 2021	+	?	?	+	+	+	+
EMBOLISE, 2024	+	?	-	-	+	+	+
Kim et al, 2017	?	?	?	+	+	+	+
Lam et al, 2023	+	?	+	?	-	-	+
MAGIC-MT, 2024	+	?	-	-	?	+	+
Marulanda et al, 2021	+	?	?	+	+	+	+
Matsumoto et al, 2018	?	?	?	+	+	+	+
Ng et al, 2019	+	?	-	-	+	+	+
Onyinzo et al, 2021	?	?	?	+	+	+	+
Shotar et al, 2020	?	?	?	+	+	+	+
STEM, 2024	+	?	-	-	?	+	+

Key: + : Low risk; ? : Unclear Risk; - : High Risk

Aggregated risk of bias presented as percentages across all included studies.



Supplementary Figure 2: Risk of bias plots



Funnel plots for risk of bias by study type. Funnel plots obtained for all the studies included in the meta-analysis for hematoma recurrence (**panel A**), rates of reported good functional outcome (mRS <2) (**panel B**), risk of safety endpoints (**panel C**) and mortality risk (**panel D**).

Supplemental Table 1. Hematoma Recurrence as defined in each study

Study	Hematoma Recurrence
EMBOLISE, 2024	hematoma recurrence/progression requiring surgical drainage
MAGIC-MT, 2024	hematoma maximum thickness exceeding 10 mm at 90 days or the patient receiving re-operation within 90 days in patients who underwent burr-hole drainage
STEM, 2024	Residual or re-accumulation of the SDH (≥ 10 mm) on 180-day scan from intervention
Onyinzo et al, 2021	CT findings in the follow-up period residual CSDH > 10mm
Marulanda et al, 2021	Recurrence was defined as reaccumulating hematoma or continuous growth discovered on follow-up imaging with or without a new acute/subacute component
Catapano et al, 2021	residual cSDH or reaccumulation > 10 mm
Carpenter et al, 2021	re-accumulation of hematoma with symptoms requiring reoperation
Shotar et al, 2020	reoperation to treat a recurrent CSDH previously treated by burr-hole craniostomy
Ng et al, 2019	any radiologically persistent subdural collection with persistent or new symptoms attributable to CSDH
Ban et al, 2018	incomplete hematoma resolution (remaining or reaccumulated hematoma with thickness > 10 mm)
Matsumoto et al, 2018	residual hematoma thickness of more than 50% or the absence of size reduction
Kim et al, 2017	increase in the hematoma density and width
Salih et al, 2023	SDH expansion after intervention or appearance of new acute components that warranted intervention or continuous close clinical and radiographic follow-up
Lam et al, 2023	radiologically persistent or new cSDH with persistent or new symptoms secondary to the mass effect of the cSDH

Supplemental Table 2 . Safety End Points as defined in each study

Study	Safety End Points
EMBOLISE, 2024	Neurologic*, Brain abscess Cerebellar/cerebral hemorrhage Cerebral infarction Dementia Encephalopathy Extradural hematoma Gait disturbance Headache Neurological decompensation Neurological symptom Pneumocephalus Procedural complication Seizure/status epilepticus SOH Subdural Wound infection Non-Neurologic* Anemia Asthenia Atrial fibrillation Cardiac arrest Dysphagia Hepatic encephalopathy Hypotension Malnutrition Neuropathy (peripheral) Pneumonia Respiratory failure
MAGIC-MT, 2024	Symptomatic intracranial hemorrhage Surgery-related intracranial hemorrhage Surgery-related neurological deficits Surgery-related central nervous system infection Surgery-related arterial dissection, vascular wall injury and vascular reperforation Surgery-related ischemia Retroperitoneal/wrist hematoma Neuropathy at the puncture site Contrast allergy or contrast encephalopathy
STEM, 2024	Major disabling stroke, an increase in the NIHSS of 4 points or more from baseline that persists for 24 or more hours from the time of the event (major stroke), and results in a mRS of 3 or greater at 90 days from the event (disabling stroke)
Onyinzo et al, 2021	hematoma re-accumulation, acute re-bleeding, CSF fistula
Marulanda et al, 2021	Complications not defined/described after matching
Catapano et al, 2021	Overall Complications not defined
Carpenter et al, 2021	Seizure, pneumonia, urinary tract infections, acute kidney injury, stroke, DVT/PE, sepsis
Shotar et al, 2020	Epilepsy, empyema
Ng et al, 2019	surgical reoperation
Ban et al, 2018	Treatment related complication, Cerebral infarction
	Treatment related complication, acute epidural or subdural hematoma
	Treatment related complication, Surgical infection
	Treatment related complication, intracerebral hemorrhage
Matsumoto et al, 2018	surgical complications
Kim et al, 2017	surgical complications: intracranial bleeding, wound hematomas, post operative hemorrhage medical complications: seizure, angina pectoris, urinary tract infection, pneumonia and delirium
Salih et al, 2023	NR
Lam et al, 2023	Infection, new neurological deficits, seizures, pseudoaneurysms, retroperitoneal hemorrhage, allergic reactions to contrast or medications, stroke, intracerebral, hemorrhage, carotid dissection, deep vein thrombosis, pulmonary embolism, myocardial infarction

Appendix 1

Embase

Search Algorithm

.....
No. Query Results

#5. (('subdural hematoma'/exp OR 'subdural hematoma') AND middle AND meningeal AND artery AND embolization OR chronic) AND subdural AND hemorrhage OR hematoma) AND recurrence AND embolization

#4. (('subdural hematoma'/exp OR 'subdural hematoma') AND middle AND meningeal AND artery AND embolization OR chronic) AND subdural AND hemorrhage OR hematoma) AND recurrence AND embolization

#3. (('subdural hematoma'/exp OR 'subdural hematoma') AND middle AND meningeal AND artery AND embolization OR chronic) AND subdural AND hemorrhage

#2. (('subdural hematoma'/exp OR 'subdural hematoma') AND middle AND meningeal AND artery AND embolization OR chronic) AND subdural AND hemorrhage OR hematoma) AND recurrence

#1. 'subdural hematoma'/exp OR 'subdural hematoma'

.....
Results 601

601

1,653

9,574

24,688

Pubmed search algorithm

Search number Query Sort By Filters Search Details Results

4 (((((Middle Meningeal Artery Embolization) AND (chronic subdural hematoma)) AND (outcomes)) AND (surgery)) OR (burr hole)) AND (recurrence) (((("middle"[All Fields] OR "middles"[All Fields]) AND ("meningeal arteries"[MeSH Terms] OR ("meningeal"[All Fields] AND "arteries"[All Fields]) OR "meningeal arteries"[All Fields] OR ("meningeal"[All Fields] AND "artery"[All Fields]) OR "meningeal artery"[All Fields]) AND ("embol"[All Fields] OR "embolics"[All Fields] OR "embolisations"[All Fields] OR "embolise"[All Fields] OR "embolised"[All Fields] OR "embolising"[All Fields] OR "embolism"[MeSH Terms] OR "embolism"[All Fields] OR "embolic"[All Fields] OR "embolisms"[All Fields] OR "embolization, therapeutic"[MeSH Terms] OR ("embolization"[All Fields] AND "therapeutic"[All Fields]) OR "therapeutic embolization"[All Fields] OR "embolisation"[All Fields] OR "embolization"[All Fields] OR "embolizations"[All Fields] OR "embolize"[All Fields] OR "embolized"[All Fields] OR "embolizes"[All Fields] OR "embolizing"[All Fields]) AND ("chronic subdural haematoma"[All Fields] OR "hematoma, subdural, chronic"[MeSH Terms] OR ("hematoma"[All Fields] AND "subdural"[All Fields] AND "chronic"[All Fields]) OR "chronic subdural hematoma"[All Fields] OR ("chronic"[All Fields] AND "subdural"[All Fields] AND "hematoma"[All Fields])) AND ("outcome"[All Fields] OR "outcomes"[All Fields]) AND ("surgery"[MeSH Subheading] OR "surgery"[All Fields] OR "surgical procedures, operative"[MeSH Terms] OR ("surgical"[All Fields] AND "procedures"[All Fields] AND "operative"[All Fields]) OR "operative surgical procedures"[All Fields] OR "general surgery"[MeSH Terms] OR ("general"[All Fields] AND "surgery"[All Fields]) OR "general surgery"[All Fields] OR "surgery s"[All Fields] OR "surgerys"[All Fields] OR "surgeries"[All Fields])) OR ("trephining"[MeSH Terms] OR "trephining"[All Fields] OR ("burr"[All Fields] AND "hole"[All Fields]) OR "burr hole"[All Fields])) AND ("recurrence"[All Fields] OR "recurrence"[MeSH Terms] OR "recurrence"[All Fields] OR

"recurrences"[All Fields] OR "recurrencies"[All Fields] OR "recurrency"[All Fields] OR
"recurrent"[All Fields] OR "recurrently"[All Fields] OR "recurrents"[All Fields]) 710
3 (((Middle Meningeal Artery Embolization) AND (chronic subdural hematoma)) AND
(outcomes)) AND (surgery)) OR (burr hole) (("middle"[All Fields] OR "middles"[All Fields]) AND
("meningeal arteries"[MeSH Terms] OR ("meningeal"[All Fields] AND "arteries"[All Fields]) OR
"meningeal arteries"[All Fields] OR ("meningeal"[All Fields] AND "artery"[All Fields]) OR
"meningeal artery"[All Fields]) AND ("embol"[All Fields] OR "embolics"[All Fields] OR
"embolisations"[All Fields] OR "embolise"[All Fields] OR "embolised"[All Fields] OR
"embolising"[All Fields] OR "embolism"[MeSH Terms] OR "embolism"[All Fields] OR
"embolic"[All Fields] OR "embolisms"[All Fields] OR "embolization, therapeutic"[MeSH Terms]
OR ("embolization"[All Fields] AND "therapeutic"[All Fields]) OR "therapeutic embolization"[All
Fields] OR "embolisation"[All Fields] OR "embolization"[All Fields] OR "embolizations"[All Fields]
OR "embolize"[All Fields] OR "embolized"[All Fields] OR "embolizes"[All Fields] OR
"embolizing"[All Fields]) AND ("chronic subdural haematoma"[All Fields] OR "hematoma,
subdural, chronic"[MeSH Terms] OR ("hematoma"[All Fields] AND "subdural"[All Fields] AND
"chronic"[All Fields]) OR "chronic subdural hematoma"[All Fields] OR ("chronic"[All Fields] AND
"subdural"[All Fields] AND "hematoma"[All Fields])) AND ("outcome"[All Fields] OR
"outcomes"[All Fields]) AND ("surgery"[MeSH Subheading] OR "surgery"[All Fields] OR
"surgical procedures, operative"[MeSH Terms] OR ("surgical"[All Fields] AND "procedures"[All
Fields] AND "operative"[All Fields]) OR "operative surgical procedures"[All Fields] OR "general
surgery"[MeSH Terms] OR ("general"[All Fields] AND "surgery"[All Fields]) OR "general
surgery"[All Fields] OR "surgery s"[All Fields] OR "surgerys"[All Fields] OR "surgeries"[All
Fields])) OR ("trephining"[MeSH Terms] OR "trephining"[All Fields] OR ("burr"[All Fields] AND
"hole"[All Fields]) OR "burr hole"[All Fields]) 3,978
2 (hematoma, subdural, chronic (MeSH)' OR 'chronic' OR 'subdural hematoma' AND
'meningeal arteries (MeSH)' OR 'middle meningeal artery' AND 'embolization, therapeutic'

(MeSH) OR 'embolization' AND 'recurrence') OR (embolization and recurrence)
((((((((("hematoma, subdural, chronic"[MeSH Terms] OR ("hematoma"[All Fields] AND
"subdural"[All Fields] AND "chronic"[All Fields]) OR "chronic subdural hematoma"[All Fields] OR
"hematoma subdural chronic"[All Fields]) AND ("medical subject headings"[MeSH Terms] OR
("medical"[All Fields] AND "subject"[All Fields] AND "headings"[All Fields]) OR "medical subject
headings"[All Fields] OR "mesh"[All Fields])) OR ("chronic"[All Fields] OR "chronical"[All Fields]
OR "chronically"[All Fields] OR "chronicities"[All Fields] OR "chronicity"[All Fields] OR
"chronicization"[All Fields] OR "chronics"[All Fields]) OR ("subdural haematoma"[All Fields] OR
"hematoma, subdural"[MeSH Terms] OR ("hematoma"[All Fields] AND "subdural"[All Fields])
OR "subdural hematoma"[All Fields] OR ("subdural"[All Fields] AND "hematoma"[All Fields])))
AND ("meningeal arteries"[MeSH Terms] OR ("meningeal"[All Fields] AND "arteries"[All Fields])
OR "meningeal arteries"[All Fields])) AND ("medical subject headings"[MeSH Terms] OR
("medical"[All Fields] AND "subject"[All Fields] AND "headings"[All Fields]) OR "medical subject
headings"[All Fields] OR "mesh"[All Fields])) OR (("middle"[All
Fields] OR "middles"[All Fields]) AND ("meningeal arteries"[MeSH Terms] OR ("meningeal"[All
Fields] AND "arteries"[All Fields]) OR "meningeal arteries"[All Fields] OR ("meningeal"[All Fields]
AND "artery"[All Fields]) OR "meningeal artery"[All Fields])) AND ("embolization,
therapeutic"[MeSH Terms] OR ("embolization"[All Fields] AND "therapeutic"[All Fields]) OR
"therapeutic embolization"[All Fields] OR "embolization therapeutic"[All Fields])) AND ("medical
subject headings"[MeSH Terms] OR ("medical"[All Fields] AND "subject"[All Fields] AND
"headings"[All Fields]) OR "medical subject headings"[All Fields] OR "mesh"[All Fields])) OR
("embol"[All Fields] OR "embolics"[All Fields] OR "embolisations"[All Fields] OR "embolise"[All
Fields] OR "embolised"[All Fields] OR "embolising"[All Fields] OR "embolism"[MeSH Terms] OR
"embolism"[All Fields] OR "embolic"[All Fields] OR "embolisms"[All Fields] OR "embolization,
therapeutic"[MeSH Terms] OR ("embolization"[All Fields] AND "therapeutic"[All Fields]) OR
"therapeutic embolization"[All Fields] OR "embolisation"[All Fields] OR "embolization"[All Fields]

OR "embolizations"[All Fields] OR "embolize"[All Fields] OR "embolized"[All Fields] OR "embolizes"[All Fields] OR "embolizing"[All Fields])) AND ("recurrence"[All Fields] OR "recurrence"[MeSH Terms] OR "recurrence"[All Fields] OR "recurrences"[All Fields] OR "recurrencies"[All Fields] OR "recurrency"[All Fields] OR "recurrent"[All Fields] OR "recurrently"[All Fields] OR "recurrents"[All Fields])) OR (("embol"[All Fields] OR "embolics"[All Fields] OR "embolisations"[All Fields] OR "embolise"[All Fields] OR "embolised"[All Fields] OR "embolising"[All Fields] OR "embolism"[MeSH Terms] OR "embolism"[All Fields] OR "embolic"[All Fields] OR "embolisms"[All Fields] OR "embolization, therapeutic"[MeSH Terms] OR ("embolization"[All Fields] AND "therapeutic"[All Fields]) OR "therapeutic embolization"[All Fields] OR "embolisation"[All Fields] OR "embolization"[All Fields] OR "embolizations"[All Fields] OR "embolize"[All Fields] OR "embolized"[All Fields] OR "embolizes"[All Fields] OR "embolizing"[All Fields]) AND ("recurrence"[All Fields] OR "recurrence"[MeSH Terms] OR "recurrence"[All Fields] OR "recurrences"[All Fields] OR "recurrencies"[All Fields] OR "recurrency"[All Fields] OR "recurrent"[All Fields] OR "recurrently"[All Fields] OR "recurrents"[All Fields])) 19,903

1 (hematoma, subdural, chronic (MeSH)' OR 'chronic' OR 'subdural hematoma' AND 'meningeal arteries (MeSH)' OR 'middle meningeal artery' AND 'embolization, therapeutic' (MeSH) OR 'embolization' AND 'recurrence') OR (conventional management) (((((((("hematoma, subdural, chronic"[MeSH Terms] OR ("hematoma"[All Fields] AND "subdural"[All Fields] AND "chronic"[All Fields]) OR "chronic subdural hematoma"[All Fields] OR "hematoma subdural chronic"[All Fields]) AND ("medical subject headings"[MeSH Terms] OR ("medical"[All Fields] AND "subject"[All Fields] AND "headings"[All Fields]) OR "medical subject headings"[All Fields] OR "mesh"[All Fields])) OR ("chronic"[All Fields] OR "chronical"[All Fields] OR "chronically"[All Fields] OR "chronicities"[All Fields] OR "chronicity"[All Fields] OR "chronicization"[All Fields] OR "chronics"[All Fields]) OR ("subdural haematoma"[All Fields] OR "hematoma, subdural"[MeSH Terms] OR ("hematoma"[All Fields] AND "subdural"[All Fields]) OR "subdural hematoma"[All

Fields] OR ("subdural"[All Fields] AND "hematoma"[All Fields])) AND ("meningeal arteries"[MeSH Terms] OR ("meningeal"[All Fields] AND "arteries"[All Fields]) OR "meningeal arteries"[All Fields])) AND ("medical subject headings"[MeSH Terms] OR ("medical"[All Fields] AND "subject"[All Fields] AND "headings"[All Fields]) OR "medical subject headings"[All Fields] OR "mesh"[All Fields])) OR (("middle"[All Fields] OR "middles"[All Fields]) AND ("meningeal arteries"[MeSH Terms] OR ("meningeal"[All Fields] AND "arteries"[All Fields]) OR "meningeal arteries"[All Fields] OR ("meningeal"[All Fields] AND "artery"[All Fields]) OR "meningeal artery"[All Fields])) AND ("embolization, therapeutic"[MeSH Terms] OR ("embolization"[All Fields] AND "therapeutic"[All Fields]) OR "therapeutic embolization"[All Fields] OR "embolization therapeutic"[All Fields])) AND ("medical subject headings"[MeSH Terms] OR ("medical"[All Fields] AND "subject"[All Fields] AND "headings"[All Fields]) OR "medical subject headings"[All Fields] OR "mesh"[All Fields])) OR ("embol"[All Fields] OR "embolics"[All Fields] OR "embolisations"[All Fields] OR "embolise"[All Fields] OR "embolised"[All Fields] OR "embolising"[All Fields] OR "embolism"[MeSH Terms] OR "embolism"[All Fields] OR "embolic"[All Fields] OR "embolisms"[All Fields] OR "embolization, therapeutic"[MeSH Terms] OR ("embolization"[All Fields] AND "therapeutic"[All Fields]) OR "therapeutic embolization"[All Fields] OR "embolisation"[All Fields] OR "embolization"[All Fields] OR "embolizations"[All Fields] OR "embolize"[All Fields] OR "embolized"[All Fields] OR "embolizes"[All Fields] OR "embolizing"[All Fields])) AND ("recurrence"[All Fields] OR "recurrence"[MeSH Terms] OR "recurrence"[All Fields] OR "recurrences"[All Fields] OR "recurrencies"[All Fields] OR "recurrency"[All Fields] OR "recurrent"[All Fields] OR "recurrently"[All Fields] OR "recurrents"[All Fields])) OR (("conventional"[All Fields] OR "conventionals"[All Fields]) AND ("manage"[All Fields] OR "managed"[All Fields] OR "management s"[All Fields] OR "managements"[All Fields] OR "manager"[All Fields] OR "manager s"[All Fields] OR "managers"[All Fields] OR "manages"[All Fields] OR "managing"[All Fields] OR "managment"[All Fields] OR "organization and administration"[MeSH Terms] OR

("organization"[All Fields] AND "administration"[All Fields]) OR "organization and administration"[All Fields] OR "management"[All Fields] OR "disease management"[MeSH Terms] OR ("disease"[All Fields] AND "management"[All Fields]) OR "disease management"[All Fields])) 91,460

ClinicalTrials.gov

NCT Number

Interventions

NCT04410146

for Treatment of Chronic Subdural Hematoma (STEM)

<https://clinicaltrials.gov/study/NCT04410146> ACTIVE_NOT_RECRUITING Subdural Hematoma,

Chronic DEVICE: SQUID Embolization|DEVICE: SQUID Embolization and Surgical

Evacuation|PROCEDURE: Surgical Evacuation|OTHER: Other: Medical Management Balt USA

INTERVENTIONAL

Study Title Study URL Study Status Conditions

Sponsor Collaborators Study Type

The SQUID Trial for the Embolization of the Middle Meningeal Artery

NCT03307395 Middle Meningeal Artery Embolization for Treatment of Chronic Subdural

Hematoma <https://clinicaltrials.gov/study/NCT03307395> COMPLETED Chronic Subdural

Hematoma PROCEDURE: Middel Meningeal Artery Embolization Weill Medical College of

Cornell University INTERVENTIONAL

NCT04500795 Prospective Study on the Use of Middle Meningeal Artery Embolization for

Chronic Subdural Haematoma <https://clinicaltrials.gov/study/NCT04500795> WITHDRAWN

Chronic Subdural Hematoma|Subdural Hematoma PROCEDURE: Middle meningeal artery

embolization Chinese University of Hong Kong

INTERVENTIONAL

NCT04270955 Dartmouth Middle Meningeal Embolization Trial (DaMMET)

<https://clinicaltrials.gov/study/NCT04270955> COMPLETED Chronic Subdural

Hematoma|Subdural Hematoma PROCEDURE: Embolization of the Middle Meningeal

Artery|PROCEDURE: Standard of care including possible surgical evacuation of subdural

hematoma Dartmouth-Hitchcock Medical Center

INTERVENTIONAL

NCT04511572 Embolization of Middle Meningeal Artery in Chronic Subdural Hematoma

<https://clinicaltrials.gov/study/NCT04511572> RECRUITING Chronic Subdural Hematomas

PROCEDURE: embolization of the middle meningeal artery Academisch Medisch Centrum -

Universiteit van Amsterdam (AMC-UvA) INTERVENTIONAL NCT04574843 Middle Meningeal

Artery Embolization With Liquid Embolic Agent for Treatment of Chronic Subdural Hematoma

<https://clinicaltrials.gov/study/NCT04574843> RECRUITING Chronic Subdural Hematoma

PROCEDURE: Embolization of MMA Mashhad University of Medical Sciences

INTERVENTIONAL

NCT05374681 Efficacy of a Minimally Invasive Therapy Adjuvant to the Standards of Care by

Cyanoacrylate Embolization <https://clinicaltrials.gov/study/NCT05374681> RECRUITING Chronic

Subdural Hematoma OTHER: Medical treatment|OTHER: Surgical treatment|OTHER:

embolization of the MMA University Hospital, Brest

INTERVENTIONAL

NCT04742920 The Onyx[®] Trial For The Embolization Of The Middle Meningeal Artery For

Chronic Subdural Hematoma (OTEMACS) <https://clinicaltrials.gov/study/NCT04742920>

RECRUITING Hematoma, Subdural, Chronic|Brain Diseases|Central Nervous System

Diseases|Wounds and Injuries

DEVICE: Middle Meningeal Artery Embolization|PROCEDURE: Standard Management

University Hospital, Montpellier INTERVENTIONAL

NCT04095819 Middle Meningeal Artery (MMA) Embolization Compared to Traditional Surgical

Strategies to Treat Chronic Subdural Hematomas (cSDH)

<https://clinicaltrials.gov/study/NCT04095819> UNKNOWN Chronic Subdural Hematoma

PROCEDURE: Middle Meningeal Artery procedure|PROCEDURE: Traditional Surgery

Atlantic Health System INTERVENTIONAL

NCT06274580 Endovascular vs Conservative Treatment in Patients With Chronic Subdural

Hematomas and Mild Symptoms <https://clinicaltrials.gov/study/NCT06274580>

NOT_YET_RECRUITING Subdural Hematoma, Chronic DEVICE: embolization of the middle meningeal artery Ospedale Policlinico San Martino

INTERVENTIONAL

NCT04816591 Middle Meningeal Artery Embolization for the Treatment of Subdural

Hematomas With TRUFILLÂ® n-BCA <https://clinicaltrials.gov/study/NCT04816591>

RECRUITING Chronic Subdural Hematoma DEVICE: Experimental: Interventional Cohort:

Treatment Arm|OTHER: Active Comparator: Interventional Cohort: Control Arm|DEVICE:

Experimental: Observational Cohort: Treatment Arm|OTHER: Active Comparator: Observational

Cohort: Control Arm Cerenovus, Part of DePuy Synthes Products, Inc. INTERVENTIONAL

NCT04065113 Middle Meningeal Artery Embolization for Chronic Subdural Hematoma

<https://clinicaltrials.gov/study/NCT04065113> RECRUITING Chronic Subdural Hematoma

PROCEDURE: Middle Meningeal Artery Embolization with polyvinyl alcohol particles

(PVA)|PROCEDURE: Drainage of Subdural Hematoma Washington University School of

Medicine INTERVENTIONAL

NCT05327933 Preventing Recurrences of Chronic Subdural Hematoma in Adult Patients by

Middle Meningeal Artery Embolization <https://clinicaltrials.gov/study/NCT05327933>

RECRUITING Hematoma, Subdural, Chronic PROCEDURE: Surgery plus endovascular MMA

embolization|PROCEDURE: Surgery

alone Unfallkrankenhaus Berlin INTERVENTIONAL

NCT06163547 Middle Meningeal Artery Embolization for Chronic Subdural Hematomas

(STORMM) <https://clinicaltrials.gov/study/NCT06163547> NOT_YET_RECRUITING

Chronic Subdural Hematomas|Cerebral Compression Due to Injury RADIATION: MMA

embolization University Hospital, Geneva INTERVENTIONAL

NCT04372147 Embolization of the Middle Meningeal Artery for the Prevention of

Chronic Subdural Hematoma Recurrence in High Risk Patients (EMPROTECT)

<https://clinicaltrials.gov/study/NCT04372147> UNKNOWN Chronic Subdural Hematoma|at

Risk of Post-operative Recurrence|Burr-hole Surgery PROCEDURE: MMA embolization

Assistance Publique - Hôpitaux de Paris INTERVENTIONAL