



32 **KEY POINTS:**

33 **Question:** Can a deep learning algorithm applied to echocardiography videos  
34 effectively identify chronic liver diseases including cirrhosis and steatotic liver disease  
35 (SLD)?

36

37 **Findings:** This retrospective observational cohort study utilized 1,596,640  
38 echocardiography videos from 66,922 studies of 24,276 patients. The deep learning  
39 model with a computer vision pipeline (EchoNet-Liver) demonstrated strong  
40 performance to detect cirrhosis and SLD. External validation at a geographically distinct  
41 site demonstrated similar discriminative ability.

42

43 **Meaning:** The application of EchoNet-Liver to echocardiography could aid  
44 opportunistic screening of chronic liver diseases, providing a unique cost-effective  
45 angle to improve patient management.

46

47

48

49 **Abbreviations:**

50 AI : Artificial intelligence

51 AUROC: Area under receiver operating characteristic

52 AUPRC: Area Under precision recall curve

53 CLD: chronic liver disease

54 CVD: cardiovascular disease

55 LVEF: Left ventricular ejection fraction

56 PR: Precision-recall

57 SLD: steatotic liver disease

58 PPV: positive predictive value

59 NPV: negative predictive value

60 MRI: magnetic resonance imaging

61 MRS: magnetic resonance spectroscopy

62 PDFF: proton density fat fraction

63

64 **ABSTRACT**

65 **Importance:** Chronic liver disease affects more than 1.5 billion adults worldwide,  
66 however the majority of cases are asymptomatic and undiagnosed. Echocardiography is  
67 broadly performed and visualizes the liver; but this information is not leveraged.

68 **Objective:** To develop and evaluate a deep learning algorithm on echocardiography  
69 videos to enable opportunistic screening for chronic liver disease.

70 **Design:** Retrospective observational cohorts

71 **Setting:** Two large urban academic medical centers

72 **Participants:** Adult patients who received echocardiography and abdominal imaging  
73 (either abdominal ultrasound or abdominal magnetic resonance imaging) with  $\leq 30$  days  
74 between tests, between July 4, 2012, to June 4, 2022.

75 **Exposure:** Deep learning model predictions from a deep-learning computer vision  
76 pipeline that identifies subcostal view echocardiogram videos and detects the presence  
77 of cirrhosis or steatotic liver disease (SLD).

78 **Main Outcome and Measures:** Clinical diagnosis by paired abdominal ultrasound or  
79 magnetic resonance imaging (MRI).

80 **Results:** A total of 1,596,640 echocardiogram videos (66,922 studies from 24,276  
81 patients) from Cedars-Sinai Medical Center (CSMC) were used to develop  
82 EchoNet-Liver, an automated pipeline that identifies high quality subcostal images from  
83 echocardiogram studies and detects the presence of cirrhosis or SLD. In the held-out  
84 CSMC test cohort, EchoNet-Liver was able to detect the presence of cirrhosis with an  
85 AUC of 0.837 (0.789 - 0.880) and SLD with an AUC of 0.799 (0.758 - 0.837). In a  
86 separate test cohort with paired abdominal MRIs, cirrhosis was detected with an AUC  
87 of 0.704 (0.689-0.718) and SLD was detected with an AUC of 0.726 (0.659-0.790). In  
88 an external test cohort of 106 patients (n = 5,280 videos), the model detected cirrhosis  
89 with an AUC of 0.830 (0.738 - 0.909) and SLD with an AUC of 0.768 (0.652 – 0.875).

90 **Conclusions and Relevance:** Deep learning assessment of clinical echocardiography  
91 enables opportunistic screening of SLD and cirrhosis. Application of this algorithm may  
92 identify patients who may benefit from further diagnostic testing and treatment for  
93 chronic liver disease.

94 **Introduction**

95           Chronic liver disease (CLD) affects an estimated 1.5 billion people worldwide  
96 and 100 million in the United States and can result in malignancy, end-stage liver  
97 disease, or mortality<sup>1</sup>. The prevalence of chronic liver disease is sharply increasing<sup>2,3</sup>,  
98 particularly related to steatotic liver disease (SLD) as a result of increased burden of  
99 obesity and metabolic disease, however the vast majority of patients are undiagnosed<sup>4,5</sup>.  
100 This issue affects many individuals with known cardiovascular disease as well as  
101 individuals with even severe end-stage liver disease, such as cirrhosis, which is  
102 frequently missed in the earlier stages of fibrosis<sup>4</sup>.

103           Multiple approaches are available for screening and diagnosis of chronic liver  
104 disease, including serological risk scores, qualitative and quantitative ultrasound and  
105 magnetic resonance imaging (MRI), and invasive biopsy<sup>6,7</sup>. However, accuracy,  
106 availability, and cost all limit the sufficiency of these pathways to address  
107 underdiagnosis. Echocardiography, or ultrasound of the heart and associated structures,  
108 is a first-line diagnostic ultrasound test, and is frequently performed across the spectrum  
109 of patients with metabolic and cardiovascular diseases<sup>8</sup>. Included within a standard  
110 echocardiographic examination are subcostal views which visualize the inferior vena  
111 cava and provide clear visualization of hepatic tissue quality as well as liver contour.  
112 The full clinical utility of these images for identification of hepatic disease is  
113 underutilized as cardiologists are not trained in the assessment of liver pathologies by  
114 ultrasound.

115           Artificial intelligence (AI) can identify diseases and characteristics that may  
116 not be readily observable by the human eye<sup>9-13</sup>, predict disease progression<sup>14</sup>,  
117 mortality<sup>15</sup>, and improve measurement accuracy of cardiac parameters<sup>16-19</sup>. Our study  
118 aims to develop and validate an AI computer vision approach to leverage  
119 echocardiographic images and videos to detect CLD. We hypothesize that a  
120 deep-learning pipeline can identify high-quality subcostal view videos and detect SLD  
121 and cirrhosis in a high-throughput fashion. We trained and evaluated the model  
122 performance in internal and external validations across multiple cohorts. AI-based  
123 analysis of hepatic tissue visible within standard subcostal echocardiography videos

124 may provide opportunistic screening of chronic liver disease from standard  
125 echocardiography without additional costs.  
126

127 **Methods**

128 **Cohort Selection**

129 We included adult patients over 18 years who received an echocardiogram at  
130 Cedars-Sinai Medical Center (CSMC) within 30 days of abdominal ultrasound and no  
131 history of liver transplant between July 2012 and June 2022. Clinical diagnoses from  
132 the abdominal ultrasound report including normal liver, steatotic liver, and cirrhotic  
133 liver, were paired with the echocardiogram images as labels for training and validation.  
134 In addition, we created an independent test cohort of patients with echocardiography  
135 and a matched abdominal MRI for cross-modal validation. Studies from patients  
136 included within any test cohort (ultrasound or MRI) were excluded from training cohort  
137 (**Supplementary Tables 1 - 4**). A cohort of patients from Stanford Healthcare (SHC)  
138 who had echocardiography and abdominal ultrasound within 30 days were included as  
139 external validation. An overall flowchart for model development and evaluation is  
140 provided in **Figure 1**. Approval for this study was obtained from the Cedars-Sinai  
141 Medical Center and Stanford Healthcare Institutional Review Boards, and the  
142 requirement for informed consent was waived for retrospective data analysis without  
143 patient contact.

144

145 **Disease Definitions**

146

147 Echocardiography studies were matched to the closest abdominal ultrasound  
148 study within 30 days. CLD labels were derived from the abdominal ultrasound reports  
149 and categorized studies into normal, cirrhosis, or SLD based on text describing the liver  
150 parenchyma. If an echocardiography study had greater than one abdominal ultrasound  
151 within 30 days, labels were taken from the radiologist confirmed clinical report closest  
152 in time. Controls were identified when the report specified the liver parenchyma was  
153 normal. In the abdominal MRI group, diagnosis labels for cirrhosis was taken from the  
154 clinical MRI report; for SLD, we focused on the subset of cases where magnetic  
155 resonance imaging-derived proton density fat fraction (MRI-PDFF) or magnetic  
156 resonance spectroscopy (MRS) fat signal was measured, with larger than 5.0% being  
157 diagnostic of SLD<sup>25</sup>.

158

### 159 **View Selection and Image Processing**

160 A standard echocardiogram study often contains 50-100 videos, of which  
161 typically only 1-2 videos per study capture the liver in sufficient quality for assessment  
162 of the liver echotexture and contour. Echocardiography videos were initially obtained as  
163 Digital Imaging and Communications in Medicine (DICOM) files and underwent  
164 de-identification and processing into AVI videos. We developed a pipeline of two deep  
165 learning models for view classification (identification of the subcostal view videos) and  
166 quality control (excluding videos with severe motion artifact and low image quality).  
167 Two video-based convolutional neural networks (R2+1D)<sup>23</sup> were used with standardized  
168  $112 \times 112$  pixel videos for input. A dataset of 11,778 manually curated videos of 4,991  
169 patients was used model training, classified by both view type and image quality  
170 (representative ground truth images in **Supplemental Figure 1**). To evaluate the  
171 performance of view selection and quality checking, we randomly selected 100 CSMC  
172 echocardiogram studies (n = 2,315 videos) and two cardiologists manually identified  
173 high quality subcostal and low-quality subcostal view videos for comparison with  
174 model output.

175

### 176 **Chronic Liver Disease Detection**

177 For the training and evaluation of the liver disease detection models, we  
178 utilized an image-based model (DenseNet<sup>26</sup>), to focus on hepatic tissue texture for the  
179 prediction of cirrhosis and SLD. Given the focus on texture, the input data were still  
180 frame images from high quality subcostal echocardiogram videos at native resolution  
181 ( $480 \times 640$  pixels). We trained the model to minimize binary cross-entropy loss using an  
182 AdamW optimizer with an initial learning rate of  $1 \times 10^{-5}$  at a batch size of 40 for 100  
183 epochs. A variety of hyperparameters and architectures were compared prior to  
184 development of the final EchoNet-Liver model (**Supplemental Table 5**). All model  
185 training and evaluation were conducted using Python 3.8, PyTorch 2.2, and torchvision  
186 0.17.

187

### 188 **Statistical analysis**

189 Model performance was determined by measuring the area under the receiver  
190 operating curve (AUC) on held out test cohorts. Area under the precision-recall curves

191 (AUPRC), sensitivity, specificity, positive predictive value, and negative predictive  
192 value were similarly reported at the Youden index. All 95% confidence intervals were  
193 calculated with 10,000 bootstrapping samples. Data analysis was performed using both  
194 Python (version 3.8.0) and R (version 4.2.2) programming languages. This study was  
195 carried out following the TRIPOD-AI guideline (**Supplemental Material 1**)<sup>27</sup>. Saliency  
196 maps were generated to identify the areas of interest for the classifier across all test  
197 datasets. Each saliency map was produced using Grad-CAM<sup>28</sup>, which captures the  
198 gradient information directed into the final convolutional layer of the trained deep  
199 learning model. We input the final layer of the fourth DenseBlock for this approach.

200

#### 201 **Code and Data Availability**

202 Code is available at <https://github.com/echonet/liver/> and training data is  
203 available with submission of a research protocol and approval by CSMC and SHC  
204 IRBs.

205



## 206 **RESULTS**

### 207 **Patient characteristics**

208 Using a total of 1,596,640 videos from 66,922 CSMC echocardiography  
209 studies of 24,276 patients were identified and split 8:1:1 by patient into training,  
210 validation, and held-out test cohorts. The patient cohorts exhibited a variety of  
211 comorbidities consistent with patients that receive both echocardiography and  
212 abdominal ultrasound studies with prevalent hypertension (28.8%), hyperlipidemia  
213 (20.1%), diabetes (19.3%), hepatitis B (1.2%) and hepatitis C (3.7%) (**Table 1**). The  
214 average BMI was  $26.5 \pm 6.2$ , and 5.3% of the patients regularly consumed alcohol. The  
215 median duration between the echocardiography and abdominal ultrasound examinations  
216 was 0 days (interquartile range, -4 to +3 days). In this cohort, there were 371 (8.8%)  
217 cirrhosis and 645 (14.0%) SLD cases based on abdominal ultrasound reports.

218 We identified an additional test population of 6,959 echocardiogram videos  
219 from 4,145 studies across 2,335 CSMC patients who underwent abdominal MRI for  
220 cirrhosis and MRI with PDFF/MRS for SLD, and echocardiography within 365 days.  
221 The patients in this additional test cohort were not included in training and validation  
222 cohort of disease detection models. In the SHC cohort for EchoNet-Liver evaluation, we  
223 identified 66 studies of individual patients who have a total of 130 high-quality  
224 subcostal videos. Of all patients, 10 and 11 patients were diagnosed with cirrhosis and  
225 SLD respectively based on abdominal ultrasound. Patient characteristics are presented  
226 in **Table 1**. Patient characteristics in each model development (i.e., view-classifier  
227 model, quality-control model, cirrhosis detection model and SLD detection model) were  
228 demonstrated in **Supplemental Tables 1-4**.

229

230

### 231 **View Classifier and Quality Control Performance Across Two Institutions**

232 A total 11,419 subcostal view videos were used for training a subcostal view  
233 classifier model, with all other videos labeled as non-subcostal controls. On an  
234 independent test set of 100 CSMC studies (n = 2,315 videos), the view classifier model  
235 identified 186 out of 196 subcostal view videos with an AUC of 0.991 (0.984 – 0.997).  
236 The sensitivity was 0.949 (0.910-0.974) and specificity was 0.999 (0.998-1.00). In the  
237 SHC population, the subcostal view classifier identified 149 out of 228 subcostal videos

238 from a total of 5,280 total videos with an AUC of 0.965 (0.956 - 0.974). The sensitivity  
239 was 0.654 (0.591 – 0.716) and specificity was 0.993 (0.991 – 0.995). In comparison of  
240 image quality by two cardiologists, the quality-control model demonstrated an AUC of  
241 0.855 (0.800-0.905) in CSMC and an AUC of 0.785 (0.722-0.843) in SHC.

242

### 243 **Disease Detection Performance Across Two Institutions**

244 In the held-out CSMC test ultrasound dataset, the EchoNet-Liver detected  
245 chronic liver disease with an AUC of 0.837 (95% CI 0.789 - 0.880) for cirrhosis and  
246 0.799 (0.758 - 0.837) for SLD (**Figure 2**). For cirrhosis, the AUPRC was 0.309 (0.206 –  
247 0.417), PPV was 0.238 (0.180 - 0.299), and NPV was 0.976 (0.965 - 0.986). For SLD,  
248 the AUPRC was 0.408 (0.325 – 0.491), the PPV was 0.275 (0.232 - 0.319) and the NPV  
249 was 0.951 (0.935 - 0.966). In the CSMC test cohort, the algorithm showed a sensitivity  
250 of 0.696 (0.582 - 0.803) and a specificity of 0.847 (0.824 - 0.868) for detecting of  
251 cirrhosis and sensitivity of 0.741 (0.669 - 0.812) and specificity of 0.720 (0.692 - 0.747)  
252 for detecting SLD. In the SHC cohort, EchoNet-Liver detected cirrhosis and SLD with  
253 an AUC of 0.830 (0.738 - 0.909) and 0.768 (0.652 – 0.875) respectively. For cirrhosis,  
254 the AUPRC was 0.500 (0.278 – 0.708), PPV was 0.334 (0.203 - 0.471), and NPV was  
255 0.952 (0.901 - 0.989). For SLD, the AUPRC was 0.518 (0.299 – 0.705), the PPV was  
256 0.370 (0.219 - 0.528) and the NPV was 0.924 (0.864 - 0.976). In the SHC test cohort,  
257 EchoNet-Liver demonstrated a sensitivity of 0.802 (0.611 - 0.957) and a specificity of  
258 0.709 (0.623 - 0.789) for detecting of cirrhosis and sensitivity of 0.667 (0.450 - 0.867)  
259 and specificity of 0.781 (0.701 - 0.855) for detecting SLD. Evaluation metrics are  
260 summarized in **Table 2**.

261

### 262 **Comparison with Diagnosis by Magnetic Resonance Imaging**

263 In order to evaluate the performance of EchoNet-Liver across multiple  
264 diagnostic pathways, the algorithm was evaluated in a cohort of patients that both  
265 received echocardiography and abdominal MRI at CSMC. In the MRI paired cohort,  
266 EchoNet-Liver detected the presence of cirrhosis with an AUC of 0.704 (95% CI  
267 0.689–0.718) (**Figure 2-A**), and a AUPRC of 0.493 (95% CI 0.468–0.518)  
268 (**Supplementary Figure 2-A**). When evaluated in the MRS/PDFF steatosis cohort, the  
269 model detected the presence of SLD with an AUC of 0.726 (95% CI 0.659–0.790)

270 **(Figure 2-B)** and an AUPRC of 0.626 (95%CI 0.519–0.731) (**Supplementary Figure**  
271 **2-B**)

272

### 273 **Model Explainability**

274 We generated saliency maps for representative echocardiography images from  
275 the two test datasets (CSMC held-out dataset and SHC external dataset shown in **Figure**  
276 **3**). For both cirrhosis and SLD, EchoNet-Liver highlighted the liver of the subcostal  
277 echocardiographic images as regions of interest, with a diffuse activation throughout the  
278 hepatic parenchyma.

279

## 280 **Discussion**

281           In this study, we demonstrated strong performance of a deep learning pipeline  
282 (EchoNet-Liver) for detecting cirrhosis and SLD from clinical echocardiography images.  
283 The discriminative ability of the model was confirmed in a geographically distinct  
284 external health-care system cohort as well as in a cohort of patients with paired  
285 abdominal MRI imaging. Across diverse populations and disease definitions, deep  
286 learning-enhanced echocardiography enabled high-throughput automated detection of  
287 chronic liver disease, which could enable opportunistic screening for asymptomatic  
288 liver disease.

289           Chronic liver disease often remains undiagnosed due to the asymptomatic  
290 nature of early disease. Despite the significant prevalence and morbidity, routine  
291 screening is not recommended given the high cost of imaging and lack of evidence of its  
292 cost-effectiveness<sup>23</sup>. Opportunistic screening from echocardiogram images can identify  
293 a high-risk population of patients with concurrent cardiovascular risk and liver disease  
294 in a cost-effective manner. By harnessing pre-existing imaging indicated for other  
295 diagnostic reason, our AI-enhanced workflow can increase the potential utility of  
296 imaging examinations<sup>29</sup>. By incorporating view classification, quality control, and  
297 disease detection in one pipeline, automation with AI can enable high-throughput  
298 evaluation of this non-invasive and common cardiovascular diagnostic test.

299           There are several limitations in the present study to consider. This study is a  
300 retrospective study conducted at two tertiary care centers for patients who have  
301 undergone both abdominal ultrasound and echocardiography, which may result in  
302 selection bias. The spectrum of age, gender, race, and comorbidities in the study dataset  
303 may not represent the general population and may bias towards patients with more  
304 comorbidity, necessitating further external validation. Comparison between disparate  
305 imaging modalities such as ultrasound and MRI will have inherent limitations due to  
306 different modality-specific accuracy. However, in totality this study suggests that the  
307 clinical utility of high throughput disease screening using AI is promising, particularly  
308 for early disease, and enhances the utility of pre-existing imaging data<sup>11,12,30</sup>. Further  
309 studies are warranted to establish the optimal clinical workflow for opportunistic liver  
310 disease screening among CVD patients and downstream treatment. By improving

311 diagnosis of subclinical CLD, we may be able to limit or reverse disease progression  
312 <sup>20-22</sup> and improve patient care by triaging patients toward appropriate clinical and  
313 diagnostic management<sup>23,24</sup>.

314 In conclusion, we found that EchoNet-Liver, a deep learning pipeline using  
315 echocardiography to detect the presence of SLD and cirrhosis, had strong performance  
316 in multiple populations and disease definitions. The findings were consistent across two  
317 institutions and with comparison to abdominal magnetic resonance imaging. Deep  
318 learning applied to echocardiography may offer an opportunity for opportunistic and  
319 cost-effective screening for chronic liver disease.

320

321

## 322 **Disclosures**

323 YS reports support from the KAKENHI (Japan Society for the Promotion of Science:  
324 24K10526), oversea research grant from SUNRISElab, Japan Heart Foundation and  
325 Ogawa Foundation and honoraria for lectures from m3.com inc. DO reports support  
326 from the National Institute of Health (NIH; NHLBI R00HL157421 and R01HL173526)  
327 and Alexion, and consulting or honoraria for lectures from EchoIQ, Ultromics, Pfizer,  
328 InVision, the Korean Society of Echocardiography, and the Japanese Society of  
329 Echocardiography. ACK reports consulting fees from InVision and support from the  
330 American Heart Association (AHA; 23CDA1053659) and National Institutes of Health  
331 (NIH; UL1TR001881).

332

333

## 334 **Author contributions**

335 Concept and design: YS, DO, AK

336 Code and programming: YS, MV, JR

337 Acquisition, analysis, or interpretation of data: YS, DO, AK, FA

338 Drafting and Critical revision of the manuscript: YS, DO, AK, HT, SC JC

339 Statistical analysis: YS, DO, AK

340 Obtained funding: AK, DO, SC

341 Supervision: AK, DO, SC

342



344 **Tables**345 **Table 1:** Patient characteristics of the study cohort

Characteristic	CSMC cohort, N = 24,276	CSMC Ultrasound Test cohort N = 1,486	CSMC MRI Test cohort, N = 2,335	SHC External Validation cohort, N = 106
Number of studies	66,922	6,996	6,751	106
Number of video files	1,596,640	163,736	164,579	5,388
Age, mean (SD)	65.1 (17.1)	63.0 (17.3)	62.7 (14.6)	59.3 (16.8)
BMI, mean (SD)	27.1 (6.6)	26.9 (6.6)	26.9 (6.2)	27.0 (7.9)
Gender, female	11,892 (49.1%)	666 (44.9%)	1,200 (51.4%)	48 (45.3%)
Race/Ethnicity				
White	16,347 (67.3%)	972 (65.4%)	1,572 (67.3%)	49 (46.2%)
Black	3,962 (16.3%)	279 (18.8%)	335 (14.3%)	2 (1.9%)
Asian	1,699 (7.0%)	95 (6.4%)	184 (7.9%)	21 (19.8%)
Other	2,268 (9.3%)	140 (9.4%)	244 (10.5%)	34 (32.0%)
Hypertension	6,989 (28.8%)	454 (30.6%)	549 (23.5%)	72 (67.9%)
Dyslipidemia	4,879 (20.1%)	328 (22.1%)	367 (15.7%)	45 (42.5%)
Diabetes	4,675 (19.3%)	310 (20.9%)	449 (19.2%)	43 (40.6%)
Stroke	1,626 (6.7%)	113 (7.6%)	107 (4.6%)	7 (6.6%)
Atrial Fibrillation	802 (3.3%)	71 (4.8%)	42 (1.8%)	36 (34.0%)
Heart Failure	2,964 (12.2%)	276 (18.6%)	105 (4.5%)	47 (44.3%)
Coronary Artery Disease	4,517 (18.6%)	342 (23.0%)	259 (11.1%)	29 (27.4%)

LVEF, mean (SD)	58.1 (14.9)	56.5 (16.5)	63.0 (10.1)	55.4 (13.8)
Active Smoking	1,208 (5.0%)	100 (6.7%)	101 (4.3%)	4 (3.8%)
HBV	284 (1.2%)	15 (1.0%)	72 (3.1%)	9 (8.5%)
HCV	908 (3.7%)	53 (3.6%)	201 (8.6%)	9 (8.5%)
Alcohol	1,243 (5.1%)	92 (6.2%)	211 (9.0%)	26 (24.5%)

346

347 LVEF: Left Ventricular Ejection Fraction; BMI: Body Mass Index; SD: Standard Deviation; SLD: Steatotic liver disease,

348 HBV: hepatitis B, HCV: hepatitis C

349

350



351 **Table 2:** Prediction of liver disease by deep learning analysis of echocardiography using labels from abdominal ultrasound held-out test  
 352 population.

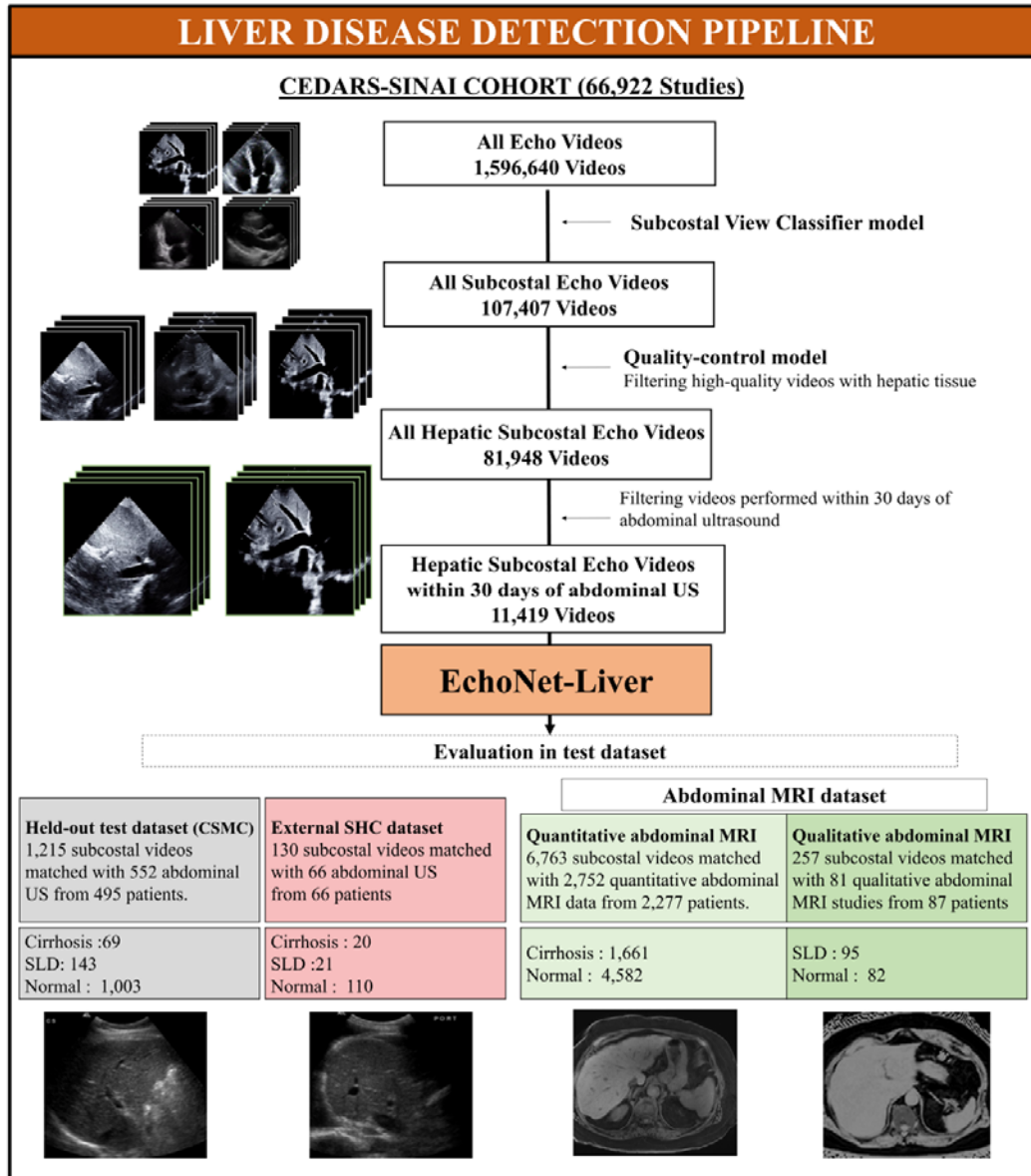
	AUROC	AUPRC	Sensitivity	Specificity	PPV	NPV
<u>(a) CSMC held-out test cohort</u>						
Cirrhosis	0.837 (0.789 - 0.880)	0.309 (0.206 – 0.417)	0.696 (0.582 - 0.803)	0.847 (0.824 - 0.868)	0.238 (0.180 - 0.299)	0.976 (0.965 - 0.986)
SLD	0.799 (0.758 - 0.837)	0.408 (0.325 – 0.491)	0.741 (0.669 - 0.812)	0.720 (0.692 - 0.747)	0.275 (0.232 - 0.319)	0.951 (0.935 - 0.966)
<u>(b) SHC external validation test cohort</u>						
Cirrhosis	0.830 (0.738 - 0.909)	0.500 (0.278 – 0.708)	0.802 (0.611 - 0.957)	0.709 (0.623 - 0.789)	0.334 (0.203 - 0.471)	0.952 (0.901 - 0.989)
SLD	0.768 (0.652 - 0.875)	0.518 (0.299 – 0.705)	0.667 (0.450 - 0.867)	0.781 (0.701 - 0.855)	0.370 (0.219 - 0.528)	0.924 (0.864 - 0.976)

353 PPV: positive predictive value. NPV: positive predictive value. AUROC: Area under receiver operating characteristic. SLD: Steatotic  
 354 liver disease.

355

356 **Figures**

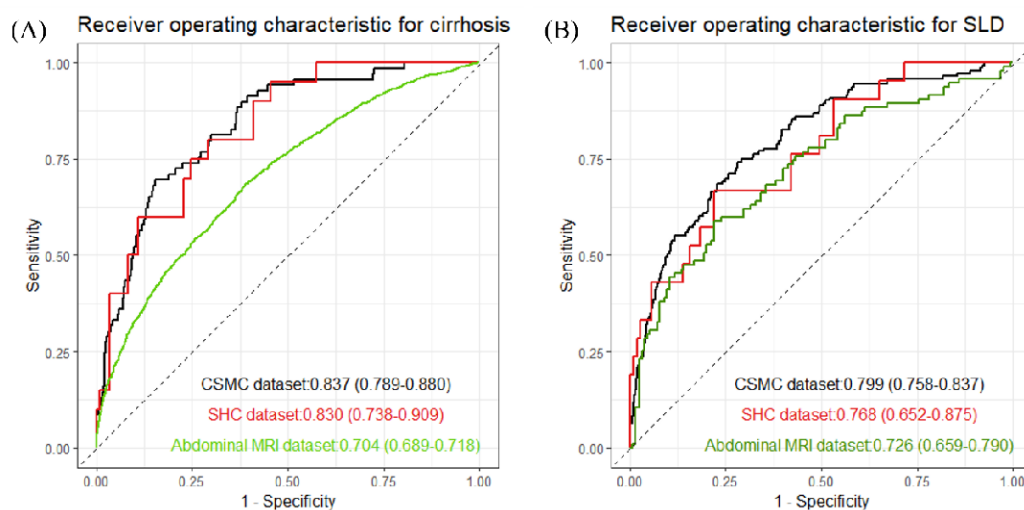
357 **Figure 1: Overview of the study pipeline**



358

359 More than 2M echocardiogram videos were used to train EchoNet-Liver, an automated  
 360 pipeline for deep learning view classification, image quality assessment, and detection  
 361 of chronic liver disease. Evaluation of EchoNet-Liver was performed 3 held-out test  
 362 cohorts, including patients with paired echocardiograms and abdominal ultrasounds  
 363 (CSMC), abdominal MRI (CSMC), and an ultrasound external test dataset (SHC). SLD:  
 364 steatotic liver disease, MRI: magnetic resonance imaging.

365 **Figure 2. Model Performance of Echo-Net-Liver**



366

367 Performance of a deep learning model using high-quality subcostal echocardiography  
368 videos for cirrhosis (A) and SLD (B). Model was evaluated in an internal CSMC  
369 held-out test dataset (black), external SHC abdominal ultrasound dataset (red) and  
370 abdominal MRI test dataset (green).

371 US: ultrasound, MRI: Magnetic resonance imaging, SLD: Steatotic liver disease

372

373

374

375

376

377

378

379

380

381

382

383

384

385

386



395 **Reference**

396

- 397 1. Moon AM, Singal AG, Tapper EB. Contemporary Epidemiology of Chronic Liver  
398 Disease and Cirrhosis. *Clin Gastroenterol Hepatol*. 2020;18(12):2650-2666.
- 399 2. Tian H, Zhang K, Hui Z, et al. Global burden of non-alcoholic fatty liver disease in  
400 204 countries and territories from 1990 to 2019. *Clin Res Hepatol Gastroenterol*.  
401 2023;47(1):102068.
- 402 3. GBD 2017 Cirrhosis Collaborators. The global, regional, and national burden of  
403 cirrhosis by cause in 195 countries and territories, 1990-2017: a systematic analysis  
404 for the Global Burden of Disease Study 2017. *Lancet Gastroenterol Hepatol*.  
405 2020;5(3):245-266.
- 406 4. Bajaj JS, Silvey SG, Rogal S, et al. Undiagnosed Cirrhosis and Hepatic  
407 Encephalopathy in a National Cohort of Veterans With Dementia. *JAMA Netw Open*.  
408 2024;7(1):e2353965-e2353965.
- 409 5. Castera L, Laouenan C, Vallet-Pichard A, et al. High Prevalence of NASH and  
410 Advanced Fibrosis in Type 2 Diabetes: A Prospective Study of 330 Outpatients  
411 Undergoing Liver Biopsies for Elevated ALT, Using a Low Threshold. *Diabetes*  
412 *Care*. 2023;46(7):1354-1362.
- 413 6. Sterling RK, Patel K, Duarte-Rojo A, et al. AASLD Practice Guideline on  
414 blood-based non-invasive liver disease assessments of hepatic fibrosis and steatosis.  
415 *Hepatology*. Published online March 15, 2024.  
416 doi:10.1097/HEP.0000000000000845
- 417 7. Rinella ME, Neuschwander-Tetri BA, Siddiqui MS, et al. AASLD Practice  
418 Guidance on the clinical assessment and management of nonalcoholic fatty liver  
419 disease. *Hepatology*. 2023;77(5):1797-1835.
- 420 8. Virnig BA, Shippee ND, O'Donnell B, Zeglin J, Parashuram S. *Trends in the Use of*  
421 *Echocardiography, 2007 to 2011*. Agency for Healthcare Research and Quality  
422 (US); 2014.
- 423 9. Yuan N, Duffy G, Dhruva SS, et al. Deep Learning of Electrocardiograms in Sinus  
424 Rhythm From US Veterans to Predict Atrial Fibrillation. *JAMA Cardiol*. Published  
425 online October 18, 2023. doi:10.1001/jamacardio.2023.3701

- 426 10. Hughes JW, Yuan N, He B, et al. Deep learning evaluation of biomarkers from  
427 echocardiogram videos. *EBioMedicine*. 2021;73:103613.
- 428 11. Duffy G, Cheng PP, Yuan N, et al. High-Throughput Precision Phenotyping of Left  
429 Ventricular Hypertrophy With Cardiovascular Deep Learning. *JAMA Cardiol*.  
430 2022;7(4):386-395.
- 431 12. Vrudhula A, Duffy G, Vukadinovic M, Liang D, Cheng S, Ouyang D. High  
432 throughput deep learning detection of mitral regurgitation. *bioRxiv*. Published  
433 online February 12, 2024. doi:10.1101/2024.02.08.24302547
- 434 13. Goto S, Mahara K, Beussink-Nelson L, et al. Artificial intelligence-enabled fully  
435 automated detection of cardiac amyloidosis using electrocardiograms and  
436 echocardiograms. *Nat Commun*. 2021;12(1):2726.
- 437 14. Oikonomou EK, Holste G, Yuan N, et al. A Multimodal Video-Based AI Biomarker  
438 for Aortic Stenosis Development and Progression. *JAMA Cardiol*. Published online  
439 April 6, 2024. doi:10.1001/jamacardio.2024.0595
- 440 15. Lau Emily S., Di Achille Paolo, Kopparapu Kavya, et al. Deep Learning-Enabled  
441 Assessment of Left Heart Structure and Function Predicts Cardiovascular  
442 Outcomes. *J Am Coll Cardiol*. 2023;82(20):1936-1948.
- 443 16. Ouyang D, He B, Ghorbani A, et al. Video-based AI for beat-to-beat assessment of  
444 cardiac function. *Nature*. 2020;580(7802):252-256.
- 445 17. Kwan AC, Chang EW, Jain I, et al. Deep Learning-Derived Myocardial Strain.  
446 *JACC Cardiovasc Imaging*. Published online March 12, 2024.  
447 doi:10.1016/j.jcmg.2024.01.011
- 448 18. Tromp J, Seekings PJ, Hung CL, et al. Automated interpretation of systolic and  
449 diastolic function on the echocardiogram: a multicohort study. *The Lancet Digital  
450 Health*. 2022;4(1):e46-e54.
- 451 19. He B, Kwan AC, Cho JH, et al. Blinded, randomized trial of sonographer versus AI  
452 cardiac function assessment. *Nature*. 2023;616(7957):520-524.
- 453 20. Harrison Stephen A., Bedossa Pierre, Guy Cynthia D., et al. A Phase 3, Randomized,  
454 Controlled Trial of Resmetirom in NASH with Liver Fibrosis. *N Engl J Med*.  
455 2024;390(6):497-509.

- 456 21. Newsome Philip N., Buchholtz Kristine, Cusi Kenneth, et al. A Placebo-Controlled  
457 Trial of Subcutaneous Semaglutide in Nonalcoholic Steatohepatitis. *N Engl J Med.*  
458 2021;384(12):1113-1124.
- 459 22. Sanyal AJ, Bedossa P, Fraessdorf M, et al. A phase 2 randomized trial of  
460 survodutide in MASH and fibrosis. *N Engl J Med.* Published online June 7, 2024.  
461 doi:10.1056/NEJMoa2401755
- 462 23. Leung PB, Davis AM, Kumar S. Diagnosis and Management of Nonalcoholic Fatty  
463 Liver Disease. *JAMA.* 2023;330(17):1687-1688.
- 464 24. Tapper EB, Parikh ND. Diagnosis and Management of Cirrhosis and Its  
465 Complications: A Review. *JAMA.* 2023;329(18):1589-1602.
- 466 25. Caussy C, Alqiraish MH, Nguyen P, et al. Optimal threshold of controlled  
467 attenuation parameter with MRI-PDFF as the gold standard for the detection of  
468 hepatic steatosis. *Hepatology.* 2018;67(4):1348-1359.
- 469 26. Huang G, Liu Z, Weinberger KQ. Densely connected convolutional networks. *Proc*  
470 *IEEE Comput Soc Conf Comput Vis Pattern Recognit.* Published online August 25,  
471 2016:2261-2269.
- 472 27. Collins GS, Moons KGM, Dhiman P, et al. TRIPOD+AI statement: updated  
473 guidance for reporting clinical prediction models that use regression or machine  
474 learning methods. *BMJ.* 2024;385. doi:10.1136/bmj-2023-078378
- 475 28. Selvaraju RR, Cogswell M, Das A, Vedantam R, Parikh D, Batra D. Grad-CAM:  
476 Visual Explanations from Deep Networks via Gradient-Based Localization. In:  
477 *2017 IEEE International Conference on Computer Vision (ICCV).* IEEE;  
478 2017:618-626.
- 479 29. Pickhardt PJ. Value-added Opportunistic CT Screening: State of the Art. *Radiology.*  
480 2022;303(3):E41.
- 481 30. Sandhu AT, Rodriguez F, Ngo S, et al. Incidental Coronary Artery Calcium:  
482 Opportunistic Screening of Previous Nongated Chest Computed Tomography Scans  
483 to Improve Statin Rates (NOTIFY-1 Project). *Circulation.* 2023;147(9):703-714.