

REVIEW ARTICLE

Geographic patterns of the number of root canals in permanent molars. A Systematic Review

Authors

Alain Manuel Chaple Gil, ^{1,2*} <https://orcid.org/0000-0002-8571-4429>

Email: alain.chaple@uautonoma.cl

Meylin Santiesteban Velázquez, ¹ <https://orcid.org/0009-0008-5935-9313>

Email: santiestebanm00@gmail.com

Kelvin Ian Afrashtehfar, ^{3,4} <https://orcid.org/0000-0002-6053-8967>

Email: kelvin.afrashtehfar@unibe.ch

¹Universidad de Ciencias Médicas de La Habana. Facultad de Ciencias Médicas “Victoria de Girón”. La Habana, Cuba

²Universidad Autónoma de Chile. Facultad de Ciencias de la Salud. Temuco, Chile.

³ Department of Reconstructive Dentistry and Gerodontology. School of Dental Medicine. University of Bern. Berne, Canton of Bern, Switzerland.

⁴Clinical Sciences Department, College of Dentistry, Ajman University. Ajman City, UAE.

*Corresponding Author: alain.chaple@uautonoma.cl

Universidad de Ciencias Médicas de La Habana: Calle 146 No. 2504 e/ 25 y 31, Cubanacán. Playa. La Habana, Cuba.

Universidad Autónoma de Chile: Av. Alemania 1090. Temuco, Chile. 45 289 5000

Conflict of interest: The authors declare that they have no conflicts of interest.

Funding: This research was developed using the researchers' own resources and did not receive institutional funding.

AUTHORSHIP CONTRIBUTION

Concepts: Alain Manuel Chaple Gil.

Data curation: Alain Manuel Chaple Gil, Meylin Santiesteban Velázquez.

Analysis: Alain Manuel Chaple Gil, Meylin Santiesteban Velázquez, Kelvin Ian Afrashtehfar.

Research: Alain Manuel Chaple Gil, Meylin Santiesteban Velázquez, Kelvin Ian Afrashtehfar.

Methodology: Alain Manuel Chaple Gil

Software: Alain Manuel Chaple Gil

Supervision: Alain Manuel Chaple Gil

Validation: Alain Manuel Chaple Gil, Kelvin Ian Afrashtehfar.

Display: Alain Manuel Chaple Gil, Meylin Santiesteban Velázquez, Kelvin Ian Afrashtehfar

Writing - original draft: Alain Manuel Chaple Gil, Meylin Santiesteban Velázquez, Kelvin Ian Afrashtehfar

Drafting - revision and editing: Alain Manuel Chaple Gil, Meylin Santiesteban Velázquez, Kelvin Ian Afrashtehfar.

Geographic patterns of the number of root canals in permanent molars. A Systematic Review

ABSTRACT

Introduction: The variability in the distribution and number of root canals in human permanent molars makes endodontic therapy difficult if the prevalence of these patterns is not well known.

Objective: To synthesize scientific evidence on geographical variations in the number of root canals in permanent molars.

Methods: A study conducted at the University of Medical Sciences of Havana analyzed the number of root canals in permanent molars. We searched for primary studies published in English, Spanish, or Portuguese that reported the number of canals in each tooth. We excluded clinical case studies, editorials, and studies that did not provide specific information on duct anatomy. A sensitivity analysis was performed to assess the impact of the methodological quality of the studies in the two groups. The findings were synthesized by grouping the studies by geographical region and describing the prevalence of different root canal configurations.

Results: Data on permanent molars were collected from 93 studies that contributed 60402 molars studied. In Africa, the first and second upper molars commonly have three root canals (45.62% and 41.31%, respectively), similar to the first and second lower molars (59.79% and 67.55%, respectively). In America, the upper first molar most frequently has four root canals (56.66%). In Asia, it is more common to find that all molar groups have three canals (51.09%–65.58%), except for the lower thirds, which may have two or three canals (42.88% and 57.12%). In Europe, all molars are frequently present with three canals, except for the lower third. In Oceania, the first upper molars commonly have six root canals (65%).

Conclusion: Significant variations in the number of root canals in permanent molars according to geographic region were observed. Distinct patterns were observed in the Americas, Asia, Africa, Europe, and Oceania, with varying prevalences of different root canal configurations.

Keywords: Demography; Geographic Information Systems; Tooth Root; Root Canals; Anatomy.

INTRODUCTION

The controversy regarding the morphology of the roots and root canals of teeth poses significant challenges for endodontic practice, as a comprehensive judgment of this branch of dental science is required to obtain successful treatment results. Therefore, several classification systems have been described to accurately characterize root and root canal configurations^(1, 2, 3); however, this is not sufficient. So much so that Studies that have used advanced imaging techniques, such as micro-computed tomography (micro-CT) and cone beam computed tomography (CBCT), have revealed the complexities of root canal anatomy, highlighting the limitations of the existing classification systems^(4, 5). In addition, investigations into the morphology of the root and canal of the third molars have revealed new canal configurations not previously described, emphasizing the unpredictable nature of tooth anatomy and the need for further research in this field.^(4, 5)

The number of root canals in permanent molars varies depending on the type of tooth and the individual anatomy. Research indicates that maxillary and mandibular molar primaries can have a wide range of root and channel configurations, with the most common being three canals and three roots in maxillary first molars.⁽⁷⁾ and two separate roots with two distinct mesial canals and a distal canal for the first mandibular ⁽⁸⁾ Other studies conclude that a significant proportion of the first permanent maxillary molars have three roots and four canals, with a high prevalence of a second mesiobuccal canal (MB2)^(9, 10, 11) That's why understanding these variations is vitally important to achieving successful endodontic treatments.

Most universities advocate that their curricula have an internationalization that provides knowledge about their graduates' ways of acting to be able to perform in any context that they have to live in their professional lives.^(12, 13) That is why the present research pays tribute to this globalization of knowledge in the dental guild, since a dentist graduated in America could practice his profession in patients from the Middle East and know the frequency of the number of root canals that the molars will have to whichtheye will perform endodonticsatn that latitude of the planet.

The variability in the distribution and number of root canals in human permanent molars makes endodontic therapy difficult if the prevalence of these patterns is not well known. For this reason, making available to the dental community a vision of how these patterns behave by geographical area would contribute to the dental sciences.

As a result of the previous approaches, the problem to be dealt with in this research is outlined in the scientific question: Are there significant differences in the morphology and configuration of root canals of permanent molars between different geographic populations?

To answer this question, the objective of this research was to synthesize the available scientific evidence on the geographical variations in the internal anatomy of the root canals of permanent molars in terms of their number, establishing significant patterns, and differences between different populations.

METHODS

A systematic review study was conducted from April to July 2024 at the University of Medical Sciences of Havana, where this project was approved by the Scientist Committee. The PRISMA guide was used for the execution of the research, and the databases used for the retrieval of the reports were PubMed, Scopus, and Web of Science (WOS).

Inclusion criteria

Primary research studies were included (originals, investigations, research papers or clinical trials) These had to show reports of anatomical aspects related to the number of root canals of the permanent molars. Articles in English, Spanish, and Portuguese were also included. Articles that did not specifically report the number of canals per permanent molar but could be determined by inference were also included.

Exclusion Criteria

Articles on clinical cases, opinion articles, editorials, reviews, or others that differed from those described in the inclusion criteria were excluded. Studies that deal with the subject studied primary or deciduous teeth, studies that do not report anatomical information on the number of root canals, and other articles written in languages other than English, Spanish, or Portuguese.

In addition, were excluded articles that were not available in full text and that did not show at least in the abstract relevant results for the extraction of data necessary in the research.

Search for studies

The formulations used in PubMed was: ((Pulp Canal*[Title]) OR (Root Canal*[Title]) OR (dental canal*[Title]) OR (canal*[Title])) AND ((anatomy [Title]) OR (morphology [Title])), and with the

same keywords, it was used in the databases consulted, adjusting them to the characteristics of each one.

Alternatively, the Research Rabbit website (<https://researchrabbitapp.com/home>) was used to retrieve articles that were not the result of the searches but were relevant to the study. The phrase used was 'root canal morphology of human molars.'

Procedures

Calibration was performed among the authors to evaluate the selected articles. The degree of coincidence of the evaluations made by the reviewers was determined using *Orwin's* method in 1994, and a kappa statistic was performed to measure the agreement among the reviewers who would make simple decisions about inclusion/exclusion. Kappa values between 0.40 and 0.59 were considered to reflect acceptable agreement, 0.60 to 0.74 to be an adequate agreement, and 0.75 or more to reflect excellent agreement.

The records obtained from the databases were processed into a document from the bibliographic manager EndNote, through which export files were managed for the screening process on the Rayyan® site (<https://rayyan.ai/>). Using this tool, duplicates and other records that did not match the primary inclusion/exclusion criteria were eliminated, and the researchers blindly determined which articles were suitable for inclusion and which were not. In case of discrepancy or doubt, a 3rd author was in charge of deriving the inclusion results.

Data Extraction

From the included reports, data such as the author and year of publication, design of the study, age of the study population, geographic location of the study, number of molars analyzed, dental group (1st, 2nd, and 3rd upper and/or lower permanent molars), and number of molar groups with one, two, three, four, five, six, or more root canals were obtained.

Sensitivity analysis was performed to assess the impact of the methodological quality of the studies on the results, which were divided into two groups: 1) high-quality group, which included studies that used high-resolution imaging techniques (CT or CBCT) to evaluate root anatomy; and 2) low-quality group, which included studies that relied on conventional radiographs or less accurate assessment methods.

Data analysis

This systematic review focuses on the quantitative synthesis of the results of primary studies not to estimate a particular effect, but to generalize about the number of root canals in

permanent molars globally. As the main objective was to provide a summary estimate of the outcome, it was not necessary to conduct a detailed risk of bias analysis (ROB) of each individual study. Despite not including a formal ROB, the following steps were taken to ensure the quality of the included evidence: rigorous study selection, critical evaluation of the studies, analysis of heterogeneity, and sensitivity of analysis.

A narrative synthesis of the findings was made, grouping the studies by geographic regions and describing the reported prevalence of different root canal configurations (number of canals) in maxillary and mandibular molars for each population.

Global and regional heat maps, plots, and tables were generated, showing the geographic distribution of the prevalence of different root canal configurations in maxillary and mandibular molars. This allows the spatial patterns to be clearly visualized.

For the sensitivity analysis of the studies, we performed descriptive statistics separately for each group and compared the results to assess the impact of the methodological quality.

RStudio® 2024.04.1 Build 748 was used for data processing. The data frames and RStudio codes used for the processing of information are available at the following link according to the principles of open science (<https://doi.org/10.17632/xvgf59n75k.1>):

All the results were grouped into tables, maps, and graphs showing relative and absolute frequencies for a better understanding of the patterns of the number of canals for each molar group in each geographical region.

RESULTS

Calibration of the authors who reviewed the articles included in the study was excellent in all cases.

The search yielded 2917 articles distributed among PubMed (1086), Scopus (1240), and WOS (559). Only 32 articles were obtained from the Research Rabbit. (Figure 1)

After eliminating duplicates and decanting articles that did not meet the inclusion criteria, 272 reports were obtained that could be evaluated for eligibility. Of the 149 articles, the number of root canals per tooth could not be defined, 8 were not available in full text, 18 were not related to the research, and 4 were articles of other modalities reflected in the exclusion criteria (Figure 1). At the end of the screening, 93 reports were obtained that were included in this study and are listed in Table 1.

These articles yielded information on 95 sample records of molars from countries in which the number of canals per tooth could be determined. This was due to the fact that the studies of Martins et al⁽¹⁴⁾ and Peiris et al⁽¹⁵⁾ studied two populations from different countries.

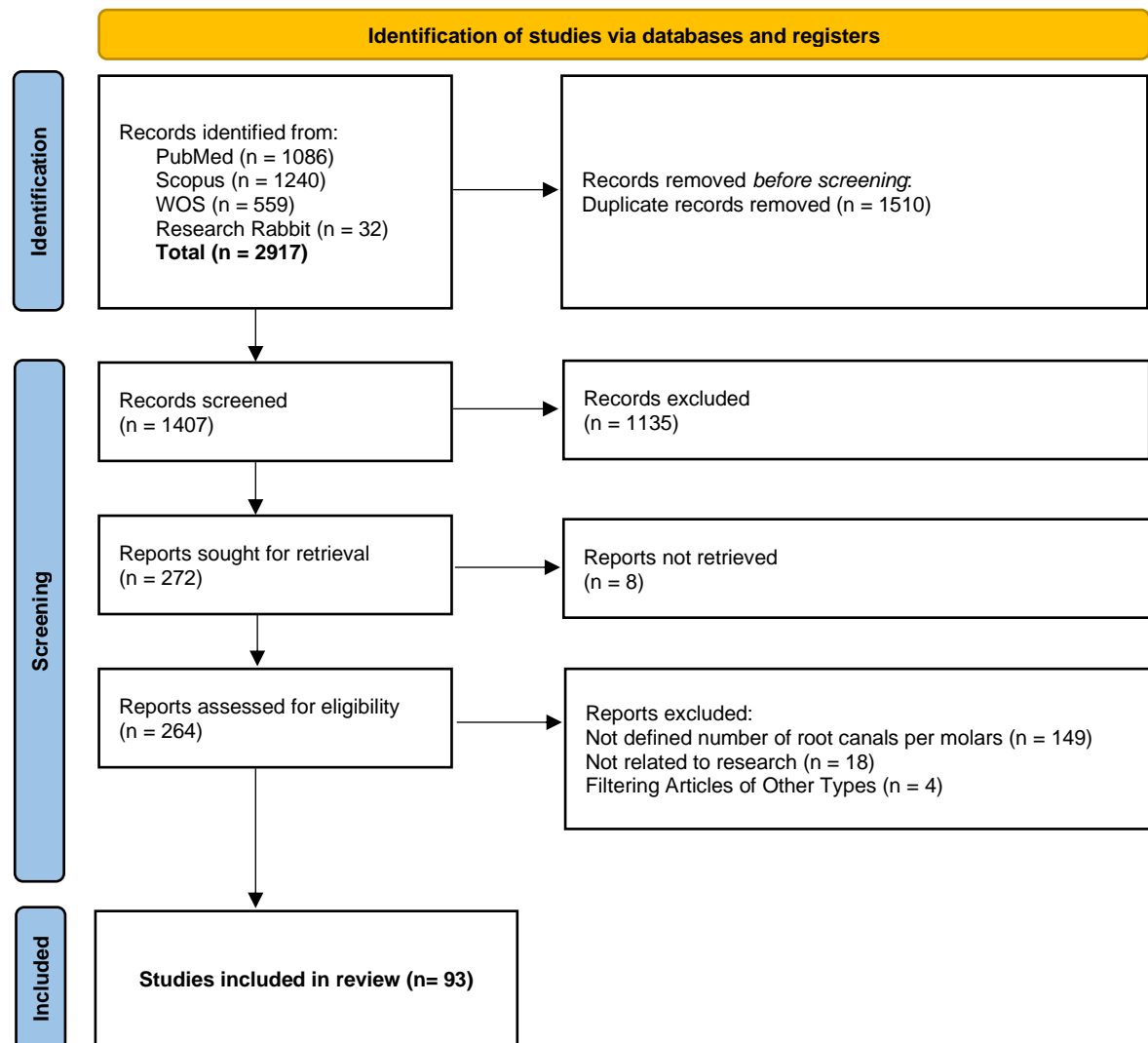


Figure 1. PRISMA flow diagram to select reports to include in the systematic review

Only one study was written in Spanish, while the rest were published in English. The Journal of Endodontics was the most frequent journal (19.35%), where reports were published, and there were no significant frequencies of authors. (Table 1)

Sensitivity analysis of the studies was not necessary because only 10.75% of the studies belonged to the group with low measurement quality.

Table 1. Distribution of the articles included in the study according to relevant data for their identification

#	1st Author	Title	Year	Journal	URL
1	Rosaline ⁽¹⁶⁾ , H.	Analysis of root and canal morphologies of maxillary second molars in a South Indian population using cone-beam computed tomography: A retrospective study	2021	Endodontology	https://doi.org/10.4103/endo.endo_93_21
2	Aydin ⁽¹⁷⁾ , H.	Analysis of root and canal morphology of fused and separate rooted maxillary molar teeth in Turkish population	2021	Niger J Clin Pract	https://doi.org/10.4103/njcp.njcp_316_20
3	Kim ⁽¹⁸⁾ , Y.	Morphology of maxillary first and second molars analyzed by cone-beam computed tomography in a Korean population: variations in the number of roots and canals and the incidence of fusion	2012	J Endod	https://doi.org/10.1016/j.joen.2012.04.025
4	Rahman ⁽¹⁹⁾ , N. A	Analysis of root and canal morphology of maxillary first and second molars among malay ethnic in the Malaysian population with the aid of cone-beam computed tomography: A retrospective study	2020	Eur J Gen Dent	https://www.thieme-connect.com/products/ejournals/pdf/10.4103/ejgd.ejgd_167_19.pdf
5	Algarni ⁽²⁰⁾ , Y. A.	Analysis of root canal anatomy and variation in morphology of maxillary first molar using various methods: An in vitro study	2019	World Journal of Dentistry	https://doi.org/10.5005/jp-journals-10015-1644
6	Mantovani ⁽²¹⁾ , V. D. O.	Analysis of the mandibular molars root canals morphology. Study by computed tomography	2022	Braz Dent J	https://doi.org/10.1590/0103-6440202205105
7	Tian ⁽²²⁾ , X. M.	Analysis of the Root and Canal Morphologies in Maxillary First and Second Molars in a Chinese Population Using Cone-beam Computed Tomography	2016	J Endod	https://doi.org/10.1016/j.joen.2016.01.017
8	Stropko ⁽²³⁾ , J. J.	Canal morphology of maxillary molars: clinical observations of canal configurations	1999	J Endod	https://doi.org/10.1016/s0099-2399(99)80276-3
9	Donyavi ⁽²⁴⁾ , Z.	Assessment of root canal morphology of maxillary and mandibular second molars in the Iranian population using CBCT	2019	Dent Med Probl	https://doi.org/10.17219/dmp/101783
10	Wang ⁽²⁵⁾ , M.	Assessment of the coronal root canal morphology of permanent maxillary first molars using digital 3D-reconstruction technology based on micro-computed tomography data	2023	J Dent Sci	https://doi.org/10.1016/j.jds.2022.08.011
11	Mirza ⁽²⁶⁾ , M. B.	CBCT based study to analyze and classify root canal morphology of maxillary molars – A retrospective study	2022	European Review for Medical and Pharmacological Sciences	https://doi.org/10.26355/eurrev_202209_29753
12	Krishnamurthy ⁽²⁷⁾ , N. H.	A CBCT Study to Evaluate the Root and Canal Morphology of Permanent Maxillary First Molars in Children	2022	Int J Clin Pediatr Dent	https://doi.org/10.5005/jp-journals-10005-2441
13	Moazzy ⁽²⁸⁾ , I.	Comprehensive evaluation of root and root canal morphology of mandibular second molars in a Saudi subpopulation evaluated by cone-beam computed tomography	2022	BMC Oral Health	https://doi.org/10.1186/s12903-022-02305-z
14	Al Shehadat ⁽²⁹⁾ , S.	Cone Beam Computed Tomography Analysis of Root and Root Canal Morphology of First Permanent Lower Molars in a Middle East Subpopulation	2019	J Int Soc Prev Community Dent	https://doi.org/10.4103/jispcd.JISPCD_41_19

15	Madfa ⁽³⁰⁾ , A. A.	Cone beam computed tomography analysis of the root and canal morphology of the maxillary second molars in a Hail province of the Saudi population	2023	Heliyon	https://doi.org/10.1016/j.heliyon.2023.e19477
16	Kalender ⁽³¹⁾ , A.	Cone beam computed tomography evaluation of maxillary molar root canal morphology in a Turkish Cypriot population	2016	Biotechnology & Biotechnological Equipment	https://doi.org/10.1080/13102818.2015.1092885
17	Celikten ⁽³²⁾ , B.	Cone beam CT evaluation of mandibular molar root canal morphology in a Turkish Cypriot population	2016	Clin Oral Investig	https://doi.org/10.1007/s00784-016-1742-2
18	Pérez-Heredia ⁽³³⁾ , M.	Cone-beam Computed Tomographic Study of Root Anatomy and Canal Configuration of Molars in a Spanish Population	2017	J Endod	https://doi.org/10.1016/j.joen.2017.03.026
19	Al-Sheeb ⁽³⁴⁾ , F.	Cone-beam computed tomographic study of root morphology, canal configuration, and bilateral symmetry of mandibular first and second molars in a Qatari population	2022	Saudi Endodontic Journal	https://doi.org/10.4103/sej.sej_176_21
20	Deng ⁽³⁵⁾ , P. U.	Cone-beam computed tomography analysis on root and canal morphology of mandibular first permanent molar among multiracial population in East Coast Malaysian population	2018	Eur J Dent	https://doi.org/10.4103/ejd.ejd_82_18
21	Zheng ⁽³⁶⁾ , Q. H.	A Cone-Beam Computed Tomography Study of Maxillary First Permanent Molar Root and Canal Morphology in a Chinese Population	2010	J Endod	https://doi.org/10.1016/j.joen.2010.06.018
22	Popovic ⁽³⁷⁾ , M.	Cone-beam computed tomography study of tooth root and canal morphology of permanent molars in a Serbian population	2020	Vojnosanitetski Pregled	https://doi.org/10.2298/vsp180322100p
23	Fu ⁽³⁸⁾ , Y.	Coronal root canal morphology of permanent two-rooted mandibular first molars with novel 3D measurements	2020	Int Endod J	https://doi.org/10.1111/iej.13220
24	Rios ⁽³⁹⁾ , P.	Description of the Morphology of the Root Canal System of the Maxillary First Molar Using Cone-Beam Computed Tomography in a Chilean Population	2023	International Journal of Morphology	https://doi.org/10.4067/S0717-95022023000200477
25	Martins ⁽¹⁴⁾ , J. N. R.	Differences on the Root and Root Canal Morphologies between Asian and White Ethnic Groups Analyzed by Cone-beam Computed Tomography	2018	J Endod	https://doi.org/10.1016/j.joen.2018.04.001
26	Razumova ⁽⁴⁰⁾ , S.	Evaluation of Anatomy and Root Canal Morphology of the Maxillary First Molar Using the Cone-Beam Computed Tomography among Residents of the Moscow Region	2018	Contemp Clin Dent	https://doi.org/10.4103/ccd.ccd_127_18
27	Namdar ⁽⁴¹⁾ , P.	Evaluation of Root and Canal Morphology of Maxillary First and Second Molars by Cone Beam Computed Tomography in a Northern Iranian Population	2023	Journal of Research in Dental and Maxillofacial Sciences	https://doi.org/10.52547/jrdms.8.4.265
28	Wang ⁽⁴²⁾ , H.	Evaluation of root and canal morphology of maxillary molars in a southern chinese subpopulation: A cone-beam computed tomographic study	2017	International Journal of Clinical and Experimental Medicine	https://e-century.us/files/ijcem/10/4/ijcem0045172.pdf

29	Guo ⁽⁴³⁾ , J.	Evaluation of root and canal morphology of maxillary permanent first molars in a North American population by cone-beam computed tomography	2014	J Endod	https://doi.org/10.1016/j.joen.2014.02.002
30	Al Mheiri ⁽⁴⁴⁾ , E.	Evaluation of root and canal morphology of maxillary permanent first molars in an Emirati population; a cone-beam computed tomography study	2020	BMC Oral Health	https://doi.org/10.1186/s12903-020-01269-2
31	Ahmed ⁽⁴⁵⁾ , G.	Evaluation of Root and Canal Morphology of Maxillary Permanent Molars in an Egyptian Population by Cone-beam Computed Tomography	2017	J Endod	https://doi.org/10.1016/j.joen.2017.02.014
32	Alrahabi ⁽⁴⁶⁾ , M.	Evaluation of root canal morphology of maxillary molars using cone beam computed tomography	2015	Pak J Med Sci	https://doi.org/10.12669/pjms.312.6753
33	Reuben ⁽⁴⁷⁾ , J.	The evaluation of root canal morphology of the mandibular first molar in an Indian population using spiral computed tomography scan: an in vitro study	2008	J Endod	https://doi.org/10.1016/j.joen.2007.11.018
34	Dibaji ⁽⁴⁸⁾ , F.	Evaluation of the relationship between buccolingual width of mesiobuccal root and root canal morphology of maxillary first molars by cone-beam computed tomography	2022	Dent Res J (Isfahan)	https://doi.org/10.4103/1735-3327.336690
35	Wang ⁽⁴⁹⁾ , Y.	Evaluation of the root and canal morphology of mandibular first permanent molars in a western Chinese population by cone-beam computed tomography	2010	J Endod	https://doi.org/10.1016/j.joen.2010.08.016
36	Nikoloudaki ⁽⁵⁰⁾ , G. E.	Evaluation of the Root and Canal Morphology of Maxillary Permanent Molars and the Incidence of the Second Mesiobuccal Root Canal in Greek Population Using Cone-beam Computed Tomography	2015	Open Dent J	https://doi.org/10.2174/1874210601509010267
37	Caputo ⁽⁵¹⁾ , B. V.	Evaluation of the Root Canal Morphology of Molars by Using Cone-beam Computed Tomography in a Brazilian Population: Part I	2016	J Endod	https://doi.org/10.1016/j.joen.2016.07.026
38	Pawar ⁽⁵²⁾ , A.	An In-Vivo cone-beam computed tomography analysis of root and canal morphology of maxillary first permanent molars in an Indian population	2021	Indian J Dent Res	https://doi.org/10.4103/ijdr.IJDR_782_19
39	Monsarrat ⁽⁵³⁾ , P.	Interrelationships in the Variability of Root Canal Anatomy among the Permanent Teeth: A Full-Mouth Approach by Cone-Beam CT	2016	PLoS One	https://doi.org/10.1371/journal.pone.0165329
40	McGuigan ⁽⁵⁴⁾ , M. B.	An investigation into dose optimisation for imaging root canal anatomy using cone beam CT	2020	Dentomaxillofac Radiol	https://doi.org/10.1259/dmfr.20200072
41	Matsunaga ⁽⁵⁵⁾ , S.	Japanese Maxillary First Molar Root Canal Morphology: An Ultrastructural Study Using Micro-Computed Tomography	2022	Journal of Hard Tissue Biology	https://doi.org/10.2485/jhtb.31.109
42	Ren ⁽⁵⁶⁾ , H. Y.	Maxillary molar root and canal morphology of Neolithic and modern Chinese	2021	Arch Oral Biol	https://doi.org/10.1016/j.archoralbio.2021.105272
43	Zhang ⁽⁵⁷⁾ , T.	Maxillary Molar Root Canal Morphology Using Cone-Beam Computed Tomography: An Epidemiological Study from Shandong Province, China	2023	International Journal of Morphology	https://doi.org/10.4067/S0717-95022023000300775

44	Lee ⁽⁵⁸⁾ , J. H.	Mesiobuccal root canal anatomy of Korean maxillary first and second molars by cone-beam computed tomography	2011	Oral Surg Oral Med Oral Pathol Oral Radiol Endod	https://doi.org/10.1016/j.tripleo.2010.11.026
45	Verma ⁽⁵⁹⁾ , P.	A Micro CT study of the mesiobuccal root canal morphology of the maxillary first molar tooth	2011	Int Endod J	https://doi.org/10.1111/j.1365-2591.2010.01800.x
46	Tomaszewska ⁽⁶⁾ , I. M.	A micro-computed tomographic (micro-CT) analysis of the root canal morphology of maxillary third molar teeth	2018	Ann Anat	https://doi.org/10.1016/j.aanat.2017.09.003
47	Filpo-Perez ⁽⁶⁰⁾ , C.	Micro-computed tomographic analysis of the root canal morphology of the distal root of mandibular first molar	2015	J Endod	https://doi.org/10.1016/j.joen.2014.09.024
48	Asijavičienė ⁽⁶¹⁾ , U.	Microcomputed tomography evaluation of the root canals morphology of the mandibular first molars	2020	Stomatologija	Not Available
49	Kim ⁽⁶²⁾ , S. Y.	Morphology of mandibular first molars analyzed by cone-beam computed tomography in a Korean population: variations in the number of roots and canals	2013	J Endod	https://doi.org/10.1016/j.joen.2013.08.015
50	Lyra ⁽⁶³⁾ , C. M.	Morphology of mesiobuccal root canals of maxillary first molars: A comparison of CBCT scanning and cross-sectioning	2015	Braz Dent J	https://doi.org/10.1590/0103-644020130096
51	Shetty ⁽¹⁰⁾ , A.	Occurrence and Morphology of MB2 Canals in Maxillary First Molars in an Indian Subpopulation: A Cone Beam Computed Tomography Study	2022	Journal of Health and Allied Sciences Un	https://doi.org/10.1055/s-0041-1736268
52	Kenawi ⁽⁶⁴⁾ , L. M. M.	Radiographic Investigation of Root Canal Morphology of Permanent Mandibular Molars in Makkah Population (Saudi Arabia) Using Cone-Beam Computed Tomography	2022	Int J Dent	https://doi.org/10.1155/2022/1535752
53	Mohara ⁽⁶⁵⁾ , N. T.	Root Anatomy and Canal Configuration of Maxillary Molars in a Brazilian Subpopulation: A 125- μ m Cone-Beam Computed Tomographic Study	2019	Eur J Dent	https://doi.org/10.1055/s-0039-1688736
54	Xia ⁽⁶⁶⁾ , Y.	Root Anatomy and Root Canal Morphology of Maxillary Second Permanent Molars in a Chongqing Population: A Cone-Beam Computed Tomography Study	2020	Med Sci Monit	https://doi.org/10.12659/msm.922794
55	Atram ⁽⁶⁷⁾ , J.	Root and canal anatomy of mandibular first molar teeth of an Indian population	2020	Endodontology	https://doi.org/10.4103/endo.endo_71_19
56	Peiris ⁽¹⁵⁾ , R.	Root and canal morphology of human permanent teeth in a Sri Lankan and Japanese population	2008	Anthropological Science	https://doi.org/10.1537/ase.070723
57	Rwonyonyi ⁽⁶⁸⁾ , C. M.	Root and canal morphology of mandibular first and second permanent molar teeth in a Ugandan population	2009	Odontology	https://doi.org/10.1007/s10266-009-0100-0
58	Senan ⁽⁶⁹⁾ , E.	Root and Canal Morphology of Mandibular Second Molars in a Yemeni Population: A Cone-beam Computed Tomography	2021	Eur Endod J	https://doi.org/10.14744/eej.2020.94695
59	Shehabeldin Mohamed ⁽⁷⁰⁾ , S.	Root and canal morphology of mandibular second molars in an Egyptian subpopulation: a cone-beam computed tomography study	2023	BMC Oral Health	https://doi.org/10.1186/s12903-023-02939-7

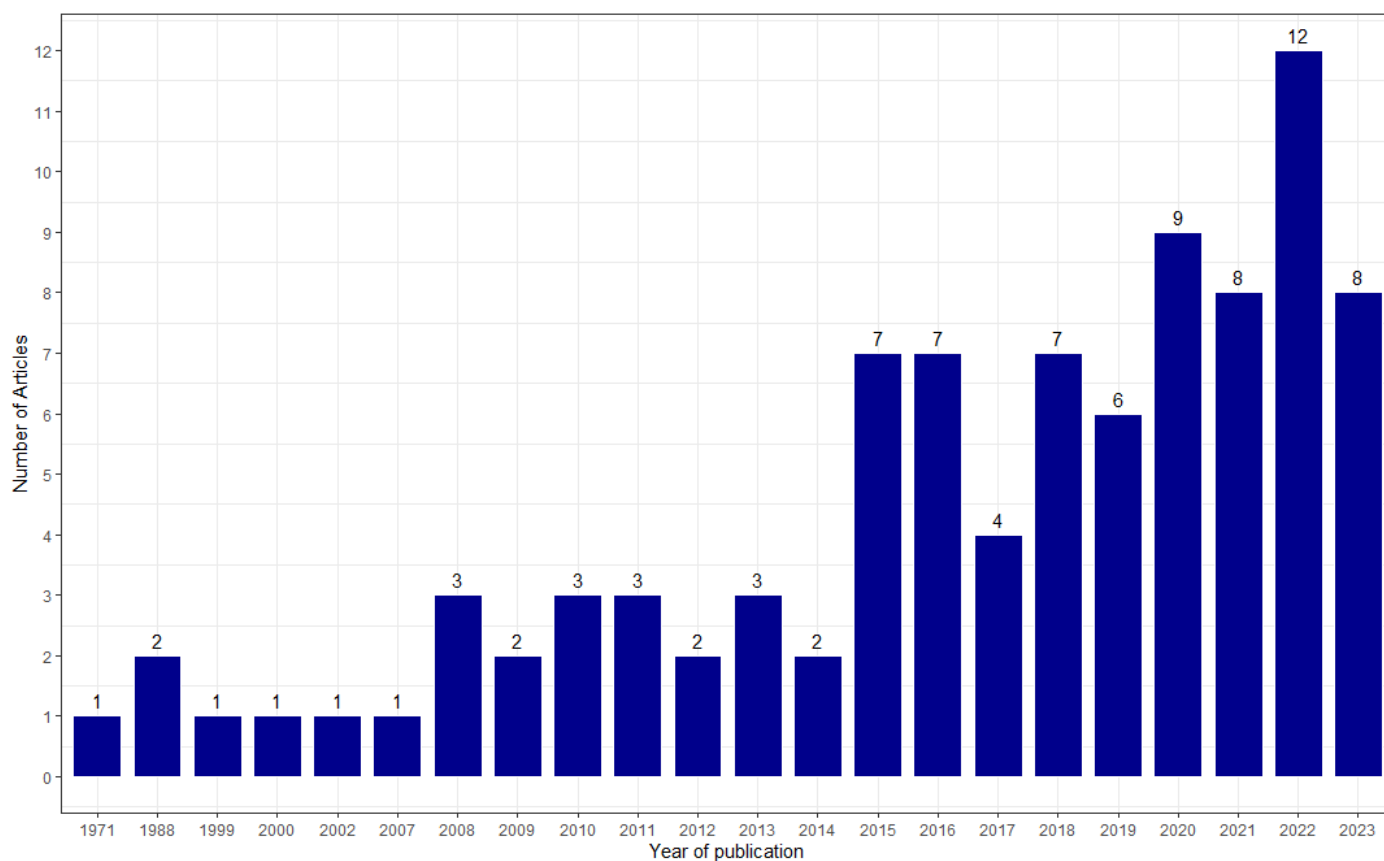
60	Prasanna, Neelakantan ⁽⁷¹⁾ , P.	Root and canal morphology of mandibular second molars in an Indian population	2010	J Endod	https://doi.org/10.1016/j.joen.2010.04.001
61	Ahmed ⁽⁷²⁾ , H. A.	Root and canal morphology of permanent mandibular molars in a Sudanese population	2007	Int Endod J	https://doi.org/10.1111/j.1365-2591.2007.1283.x
62	Gulabivala ⁽⁷³⁾ , K.	Root and canal morphology of Thai mandibular molars	2002	Int Endod J	https://doi.org/10.1046/j.1365-2591.2002.00452.x
63	Al-Qudah ⁽⁴⁾ , A. A.	Root and canal morphology of third molar teeth	2023	Sci Rep	https://doi.org/10.1038/s41598-023-34134-7
64	Mashyakhly ⁽⁷⁴⁾ , M.	Root and Root Canal Morphology Differences Between Genders: A Comprehensive in-vivo CBCT Study in a Saudi Population	2019	Acta Stomatol Croat	https://doi.org/10.15644/asc53/3/5
65	Qi ⁽⁷⁵⁾ , G.	Root and root canal morphology of mandibular second permanent molars in the Gansu province population: A CBCT study	2022	Australian Endodontic Journal	https://doi.org/10.1111/aei.12692
66	Ahmad ⁽⁷⁶⁾ , I.	Root and root canal morphology of third molars in a Jordanian subpopulation	2016	Saudi Endodontic Journal	https://doi.org/10.4103/1658-5984.189350
67	Demirtaş ⁽⁷⁷⁾ , Ö.	Root canal anatomy of maxillary first molars in a Turkish population using cone-beam computed tomography	2023	Journal of Dental Materials and Techniques	https://doi.org/10.22038/JDMT.2023.70840.1557
68	Pawar ⁽⁷⁸⁾ , A. M.	Root canal morphology and variations in mandibular second molar teeth of an Indian population: an in vivo cone-beam computed tomography analysis	2017	Clin Oral Investig	https://doi.org/10.1007/s00784-017-2082-6
69	Gomez ⁽⁷⁹⁾ , F.	Root canal morphology and variations in mandibular second molars: an in vivo cone-beam computed tomography analysis	2021	BMC Oral Health	https://doi.org/10.1186/s12903-021-01787-7
70	Ceperuelo ⁽⁸⁰⁾ , D.	Root canal morphology of Chalcolithic and early bronze age human populations of El Mirador Cave (Sierra de Atapuerca, Spain)	2014	Anat Rec (Hoboken)	https://doi.org/10.1002/ar.22958
71	Shahi ⁽⁸¹⁾ , S.	Root canal morphology of human mandibular first permanent molars in an Iranian population	2008	J Dent Res Dent Clin Dent Prospects	https://doi.org/10.5681/joddd.2008.004
72	Sidow ⁽⁸²⁾ , S. J.	Root canal morphology of human maxillary and mandibular third molars	2000	J Endod	https://doi.org/10.1097/00004770-200011000-00011
73	Chourasia ⁽⁸³⁾ , H. R.	Root canal morphology of mandibular first permanent molars in an Indian population	2012	Int J Dent	https://doi.org/10.1155/2012/745152
74	Sana ⁽⁸⁴⁾ , U.	Root Canal Morphology of Mandibular First Permanent Molars in Pakistani Sub-population - An in vitro study	2021	Pakistan Journal of Medical & Health Sciences	https://doi.org/10.53350/pjmhs211561314
75	Naseri ⁽⁸⁵⁾ , M.	Root Canal Morphology of Maxillary Second Molars according to Age and Gender in a Selected Iranian Population: A Cone-Beam Computed Tomography Evaluation	2018	Iran Endod J	https://doi.org/10.22037/iej.v13i3.19278

76	Alamri ⁽⁸⁶⁾ , H. M.	Root canal morphology of maxillary second molars in a Saudi sub-population: A cone beam computed tomography study	2020	Saudi Dent J	https://doi.org/10.1016/j.sdentj.2019.09.003
77	Habiba Suleiman ⁽⁸⁷⁾ , M.	Root canal morphology of native Tanzanian permanent mandibular molar teeth	2018	The Pan African medical journal	https://doi.org/10.11604/pamj.2018.31.24.14416
78	Weng ⁽⁸⁸⁾ , X. L.	Root canal morphology of permanent maxillary teeth in the Han nationality in Chinese Guanzhong area: a new modified root canal staining technique	2009	J Endod	https://doi.org/10.1016/j.joen.2009.02.010
79	Pan ⁽⁸⁹⁾ , J. Y. Y.	Root canal morphology of permanent teeth in a Malaysian subpopulation using cone-beam computed tomography	2019	BMC Oral Health	https://doi.org/10.1186/s12903-019-0710-z
80	Singh ⁽⁹⁰⁾ , S.	Root canal morphology of South Asian Indian maxillary molar teeth	2015	Eur J Dent	https://doi.org/10.4103/1305-7456.149662
81	Skidmore ⁽⁹¹⁾ , A. E.	Root canal morphology of the human mandibular first molar	1971	Oral Surg Oral Med Oral Pathol	https://doi.org/10.1016/0030-4220(71)90304-5
82	Walker ⁽⁹²⁾ , R. T.	Root form and canal anatomy of mandibular first molars in a southern Chinese population	1988	Endod Dent Traumatol	https://doi.org/10.1111/j.1600-9657.1988.tb00287.x
83	Walker ⁽⁹³⁾ , R. T.	Root form and canal anatomy of mandibular second molars in a southern Chinese population	1988	J Endod	https://doi.org/10.1016/s0099-2399(88)80192-4
84	Abarca ⁽⁹⁴⁾ , J.	Root morphology of mandibular molars: a cone-beam computed tomography study	2015	Folia Morphologica	https://doi.org/10.5603/fm.a2019.0084
85	Estrela ⁽⁹⁵⁾ , C.	Study of Root Canal Anatomy in Human Permanent Teeth in A Subpopulation of Brazil's Center Region Using Cone-Beam Computed Tomography - Part 1	2015	Braz Dent J	https://doi.org/10.1590/0103-6440201302448
86	Mathew ⁽⁹⁶⁾ , T.	Study of the morphology of MB2 canals in maxillary first molars using CBCT	2018	Indian Journal of Public Health Research and Development	https://doi.org/10.5958/0976-5506.2018.00495.3
87	Naseri ⁽⁹⁶⁾ , M.	Survey of Anatomy and Root Canal Morphology of Maxillary First Molars Regarding Age and Gender in an Iranian Population Using Cone-Beam Computed Tomography	2016	Iran Endod J	https://www.ncbi.nlm.nih.gov/pmc/articles/PMC5069906/pdf/iej-11-298.pdf
88	Plotino ⁽⁹⁷⁾ , G.	Symmetry of root and root canal morphology of maxillary and mandibular molars in a white population: a cone-beam computed tomography study in vivo	2013	J Endod	https://doi.org/10.1016/j.joen.2013.09.012
89	Fu ⁽⁹⁸⁾ , Y. J.	Three-dimensional analysis of coronal root canal morphology of 136 permanent mandibular first molars by micro-computed tomography	2022	J Dent Sci	https://doi.org/10.1016/j.jds.2021.07.021
90	Demirbuga ⁽⁹⁹⁾ , S.	Use of cone-beam computed tomography to evaluate root and canal morphology of mandibular first and second molars in Turkish individuals	2013	Med Oral Patol Oral Cir Bucal	https://doi.org/10.4317/medoral.18473
91	Zhang ⁽¹⁰⁰⁾ , R.	Use of cone-beam computed tomography to evaluate root and canal morphology of mandibular molars in Chinese individuals	2011	Int Endod J	https://doi.org/10.1111/j.1365-2591.2011.01904.x

92	Khattak ⁽¹⁰¹⁾ , I.	Use Of Tooth Clearing Technique To Determine Root And Canal Morphology Of Permanent Mandibular Third Molars In Population Of Peshawar: An In Vitro Cross-Sectional Study	2021	Khyber Medical University Journal	https://doi.org/10.35845/kmuj.2021.21653
93	Yang ⁽¹⁰²⁾ , L.	Variations of root and canal morphology of mandibular second molars in Chinese individuals: a cone-beam computed tomography study	2022	BMC Oral Health	https://doi.org/10.1186/s12903-022-02299-8

Source: Developed by authors from data

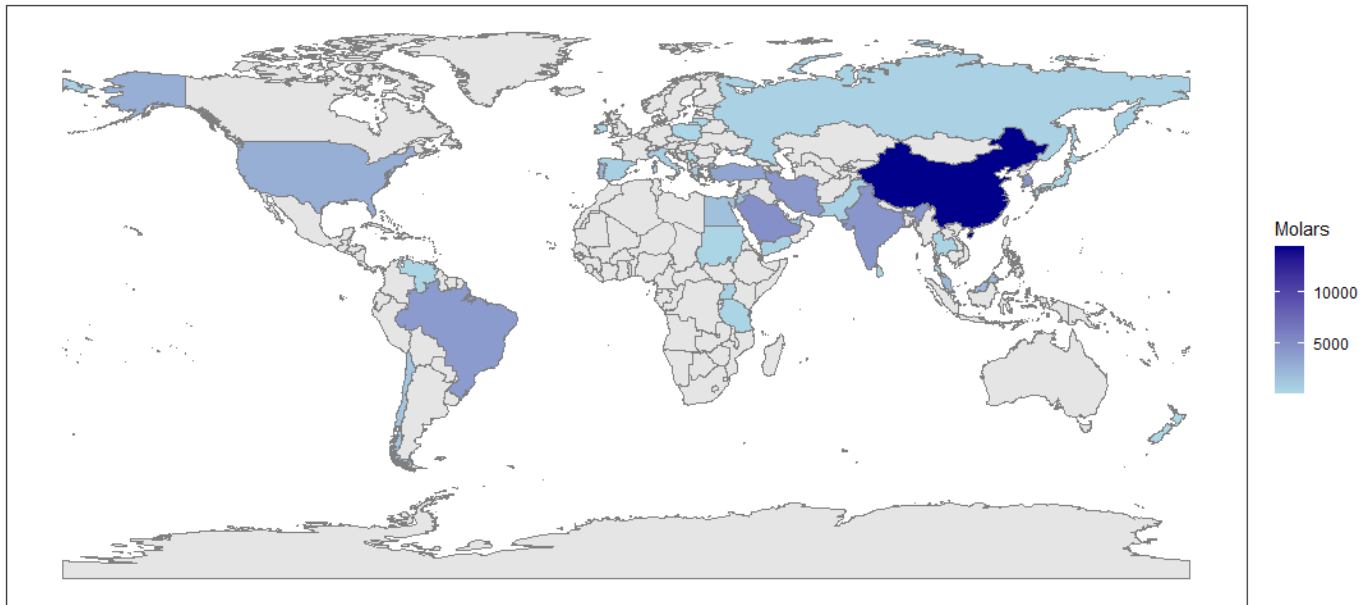
Articles from 1971 to 2023 were included, with 2022 being the year with the highest number of articles published (12 articles), followed by 2020 (9 articles), 2021, and 2023 with 8 articles each. (Table1 & Figure 2)



Source: Developed by authors from data

Figure 2. Distribution of number of articles published per year.

Data were extracted from 60402 molars from all dental groups (Figure 3). China had the highest number of molars, representing 23.88% of the total. This was followed by Saudi Arabia, South Korea, India, and Iran, with 7.94%, 7.37%, 7.21%, and 7.03%, respectively. According to the data extracted, Ireland had the lowest number of molars contributed, with three molars, followed by Poland with 0.13%, Lithuania 0.10%, and New Zealand with 0.03% (Table 2).



Source: Developed by authors from data

Figure 3. Distribution of number of molars assessed in studies according to different countries.

Table 2. Distribution of molars by arch and countries involved.

Countries (ISO2)	Total of Molars		1 st Upper Molar		2 nd Upper Molar		3 th Upper Molar		1 st Lower Molar		2 nd Lower Molar		3 th Lower Molar	
	#	%	#	%	#	%	#	%	#	%	#	%	#	%
AE	1329	2,20	522	2,60	0	-	0	-	807	7,64	0	-	0	-
BR	4053	6,71	1143	5,70	1038	6,01	0	-	1157	10,95	715	6,98	0	-
CL	1221	2,02	199	0,99	0	-	0	-	510	4,83	512	5,00	0	-
CN	14423	23,88	6054	30,21	5180	30,01	43	4,02	1203	11,39	1943	18,96	0	-
CY	1616	2,68	373	1,86	438	2,54	0	-	384	3,64	421	4,11	0	-
EG	1565	2,59	605	3,02	610	3,53	0	-	0	-	350	3,42	0	-
ES	580	0,96	155	0,77	150	0,87	0	-	138	1,31	137	1,34	0	-
FR	589	0,98	149	0,74	167	0,97	0	-	130	1,23	143	1,40	0	-
GR	812	1,34	410	2,05	402	2,33	0	-	0	-	0	-	0	-
HK	200	0,33	100	0,50	100	0,58	0	-	0	-	0	-	0	-
IE	3	0,00	3	0,01	0	-	0	-		-	0	-	0	-
IN	4352	7,21	1692	8,44	600	3,48	100	9,35	761	7,21	1199	11,70	0	-
IR	4246	7,03	836	4,17	2339	13,55	0	-	209	1,98	862	8,41	0	-
IT	596	0,99	161	0,80	157	0,91	0	-	117	1,11	161	1,57	0	-
JO	1390	2,30	0	-	0	-	681	63,64	0	-	0	-	709	58,16
JP	153	0,25	100	0,50	53	0,31	0	-	0	-	0	-	0	-
KR	4452	7,37	1271	6,34	1242	7,19	0	-	1939	18,36	0	-	0	-
LK	213	0,35	0	-	213	1,23	0	-	0	-	0	-	0	-
LT	62	0,10	0	-	0	-	0	-	62	0,59	0	-	0	-
MY	2015	3,34	824	4,11	890	5,16	0	-	301	2,85	0	-	0	-
NZ	20	0,03	20	0,10	0	-	0	-	0	-	0	-	0	-
PK	393	0,65	0	-	0	-	0	-	200	1,89	0	-	193	15,83
PL	78	0,13	0	-	0	-	78	7,29	0	-	0	-	0	-
PT	2242	3,71	714	3,56	589	3,41	0	-	463	4,38	476	4,65	0	-

QA	450	0,75	0	-	0	-	0	-	195	1,85	255	2,49	0	-
RS	138	0,23	138	0,69	0	-	0	-	0	-	0	-	0	-
RU	410	0,68	410	2,05	0	-	0	-	0	-	0	-	0	-
SA	4793	7,94	1447	7,22	1781	10,32	0	-	575	5,44	990	9,66	0	-
SD	200	0,33	0	-	0	-	0	-	100	0,95	100	0,98	0	-
TH	351	0,58	0	-	0	-	0	-	118	1,12	60	0,59	173	14,19
TR	3391	5,61	940	4,69	703	4,07	0	-	823	7,79	925	9,03	0	-
TZ	231	0,38	0	-	0	-	0	-	146	1,38	85	0,83	0	-
UG	447	0,74	0	-	0	-	0	-	224	2,12	223	2,18	0	-
US	2698	4,47	1775	8,86	611	3,54	168	15,70	0	-	0	-	144	11,81
VE	190	0,31	0	-	0	-	0	-	0	-	190	1,85	0	-
YE	500	0,83	0	-	0	-	0	-	0	-	500	4,88	0	-
Total	60402	100,00	20041	33,18	17263	28,58	1070	1,77	10562	17,49	10247	16,96	1219	2,02

AE (United Arab Emirates) BR (Brazil) CL (Chile) CN (China) CY (Cyprus) EG (Egypt) ES (Spain) FR (France) GR (Greece) HK (Hong Kong) IE (Ireland) IN (India) IR (Iran) IT (Italy) JO (Jordan) JP (Japan) KR (South Korea) LK (Sri Lanka) LT (Lithuania) MY (Malaysia) NZ (New Zealand) PK (Pakistan) PL (Poland) PT (Portugal) QA (Qatar) RS (Serbia) RU (Russia) SA (Saudi Arabia) SD (Sudan) TH (Thailand) TR (Turkey) TZ (Tanzania, United Republic of) UG (Uganda) US (United States of America) VE (Venezuela) YE (Yemen)

Source: Developed by authors from data

The most represented dental group of molars was the upper first molars with 33.18% of the total, and the ones with the lowest reported by countries were the upper third molars (1.77 %) and lower molars (2.02 %) (Table 2 and Figure 4).

Among the upper first molars, China was the country with the most reported molars (30.21 %) and Ireland (0.01 %), being the only dental group present in the data extracted from the studies included in the research (Table 2 and Figure 4).

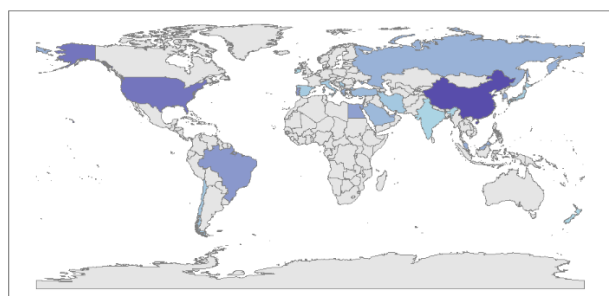
In relation to the upper second molars (28.58%), China contributed 30.01% of the total collected in the studies, and Japan (0.31%) had the lowest amount. (Table 2 & Figure 4)

For the upper third molars, the only countries that contributed data in the included studies were Jordan (63.64%), the United States (15.70%), India (9.35%), Poland (7.29%), and China (4.02%). (Table 2 & Figure 4)

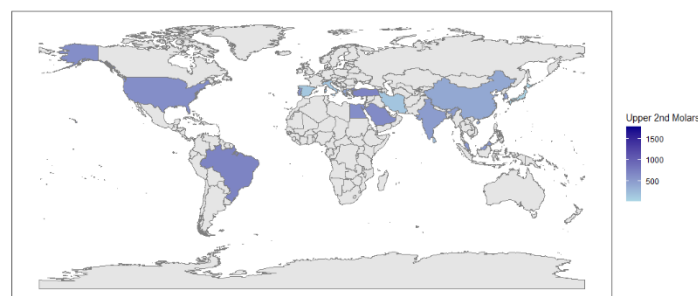
The lower first molar had 17.49% of the total data analyzed in the studies included in this research. South Korea had the highest number of lower first molars (18.36 %), followed by Lithuania (0.59 %). (Table 2 & Figure 4)

The lower second molar accounted for 16.96% of the total number of patients included. The countries with the most molars in this dental group were China (18.96 %) and Thailand (0.59 %). (Table 2 & Figure 4)

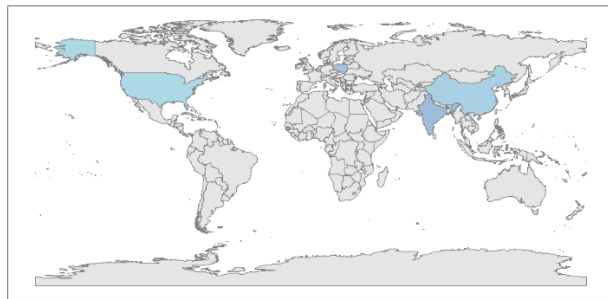
In the upper third molar, the only countries that contributed data in the studies included in the research were Jordan (58.16%), Pakistan (15.83%), Thailand (14.19%) and the United States (11.81%). (Table 2 & Figure 4)



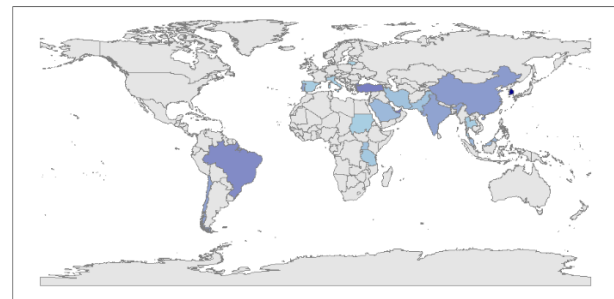
a)



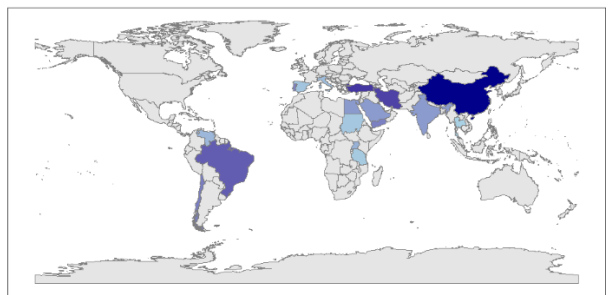
b)



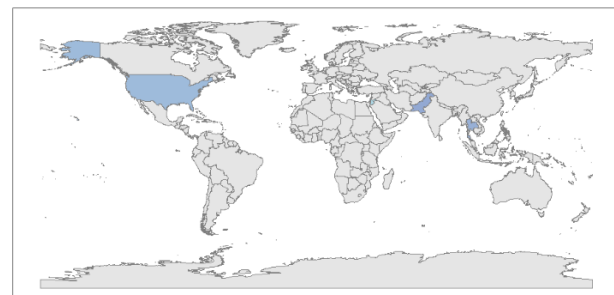
c)



d)



e)



f)

Source: Developed by authors from data

Figure 4. Distribution by country of the different molar groups studied. a) upper 1st molar, b) upper 2nd molars, c) upper 3th molars, d) lower 1st molars, e) lower 2nd molars and f) lower 3th molars.

According to the data obtained in the studies in relation to the number of root canals in permanent molars, it is evident that in the African continent, it is common to find the first and second upper molars with three root canals with values of 45.62% and 41.31%, respectively. The same occurred in the first and second lower molars, with values of 59.79% for the first and 67.55% for the second. According to the information from the studies included in the research, there were no reports of treatment of the upper and lower third molars on this continent. (Table 3)

In America, there are many upper first molars with four root canals, representing 56.66% of the total molars in this dental group. The remaining dental groups had three root canals, with values of 53.12% for the second upper molar, 60.12% for the third upper molar, 60.11% for the first lower molar, 67.55% for the second lower molar, and 57.64% for the third lower molar. (Table 3)

On the Asian continent, all the dental groups included in the study had three root canals, with values of 54.69% for the first upper molar, 58.24% for the second upper molar, 51.09% for the upper third molar, 62.45% for the lower first molar, and 65.58% for the lower second molar. In the case of lower third molars, there was a predominance of three root canals, although there was a very similar percentage of lower third molars with two root canals, representing 42.88% of the total. (Table 3)

On the European continent, all dental groups were represented by permanent molars with three root canals, with the exception of the lower third molars, for which there are no reports on the number of root canals in this dental group for this continent. The values were 61.82%, 55.22 %, 53.85 %, 81.21 %, and 56.38% for the first, second, third, first, and second molars, respectively. (Table 3)

In Oceania, according to the data extracted from the studies included in the research, only reports indicate that it is more common to find upper first molars with six root canals, with a value of 65% of the total. (Table 3)

Table 3. Distribution of the number of root canals for each molar group in relation to the continents.

	1st Upper Molar													
	Total of Molars		1 Canal		2 Canals		3 Canals		4 Canals		5 Canals		6 Canal	
	#	%	#	%	#	%	#	%	#	%	#	%	#	%
Africa	605	3,02	0	-	0	-	276	45,62	175	28,93	154	25,45	0	-
Americas	3117	15,55	0	-	21	0,67	1314	42,16	1766	56,66	16	0,51	0	-
Asia	14159	70,65	3	0,02	124	0,88	7743	54,69	6182	43,66	97	0,69	10	0,07
Europe	2140	10,68	16	0,75	41	1,92	1323	61,82	732	34,21	28	1,31	0	-
Oceania	20	0,10	0	-	0	-	3	15,00	4	20,00	0	-	13	65,00
Sub- Total	20041	33,18*	19	0,09	186	0,93	10659	53,19	8859	44,20	295	1,47	23	0,11
	2nd Upper Molar													
Africa	610	3,53	0	-	0	-	252	41,31	133	21,80	225	36,89	0	-
Americas	1649	9,55	8	0,49	60	3,64	876	53,12	703	42,63	2	0,12	0	-
Asia	13539	78,43	148	1,09	2494	18,42	7885	58,24	2970	21,94	42	0,31	0	-
Europe	1465	8,49	21	1,43	355	24,23	809	55,22	268	18,29	12	0,82	0	-

Oceania	0	-	0	-	0	-	0	-	0	-	0	-	0	-
Sub- Total	17263	28,58*	177	1,03	2909	16,85	9822	56,90	4074	23,60	281	1,63	0	-
3th Upper Molar														
Africa	0	-	0	-	0	-	0	-	0	-	0	-	0	-
Americas	168	15,70	4	2,38	10	5,95	101	60,12	46	27,38	6	3,57	1	0,60
Asia	824	77,01	74	8,98	112	13,59	421	51,09	203	24,64	14	1,70	0	-
Europe	78	7,29	18	23,08	12	15,38	42	53,85	6	7,69	0	-	0	-
Oceania	0	-	0	-	0	-	0	-	0	-	0	-	0	-
Sub- Total	1070	1,77*	96	8,97	134	12,52	564	52,71	255	23,83	20	1,87	1	0,09
1st Lower Molar														
Africa	470	4,45	0	-	94	20,00	281	59,79	92	19,57	3	0,64	0	-
Americas	1667	15,78	0	-	118	7,08	1002	60,11	526	31,55	18	1,08	3	0,18
Asia	7515	71,15	6	0,08	518	6,89	4693	62,45	2223	29,58	72	0,96	3	0,04
Europe	910	8,62	0	-	68	7,47	739	81,21	103	11,32	0	-	0	-
Oceania	0	-	0	-	0	-	0	-	0	-	0	-	0	-
Sub- Total	10562	17,49*	6	0,06	798	7,56	6715	63,58	2944	27,87	93	0,88	6	0,06
2nd Lower Molar														
Africa	758	7,40	11	1,45	147	19,39	512	67,55	78	10,29	10	1,32	0	-
Americas	1417	13,83	10	0,71	301	21,24	1049	74,03	57	4,02	0	-	0	-
Asia	7155	69,83	309	4,32	1833	25,62	4692	65,58	316	4,42	5	0,07	0	-
Europe	917	8,95	9	0,98	366	39,91	517	56,38	24	2,62	1	0,11	0	-
Oceania	0	-	0	-	0	-	0	-	0	-	0	-	0	-
Sub- Total	10247	16,96*	339	3,31	2647	25,83	6770	66,07	475	4,64	16	0,16	0	-
3th Lower Molar														
Africa	0	-	0	-	0	-	0	-	0	-	0	-	0	-
Americas	144	11,81	5	3,47	25	17,36	83	57,64	25	17,36	5	3,47	1	0,69
Asia	1075	88,19	36	3,35	461	42,88	474	44,09	103	9,58	1	0,09	0	-
Europe	0	-	0	-	0	-	0	-	0	-	0	-	0	-
Oceania	0	-	0	-	0	-	0	-	0	-	0	-	0	-
Sub- Total	1219	2,02*	41	3,36	486	39,87	557	45,69	128	10,50	6	0,49	1	0,08
Total	60402	100	678	1,12	7160	11,85	35087	58,09	16735	27,71	711	1,18	31	0,05

*These percentages are derived from the total molars at the end of the table (n=60402). The remaining percentages were at the rate of the subtotal for each dental group.

Font: Developed by authors from data

DISCUSSION

Study sensitivity analysis is a procedure that helps researchers gauge the effectiveness of the results and guide readers on the accuracy of the information collected. In a study by *Franka Marušić et al.*⁽¹⁰³⁾ they report that only 52% of the articles reported on quality thresholds for sensitivity analysis. In contrast, *Ho et al.*⁽¹⁰⁴⁾ reported that only 0.9% of the articles evaluated had high methodological quality. These findings emphasize the importance of conducting rigorous evaluations of the quality of systematic review reports to ensure the reliability of the extracted

data. In our study, a small group of included articles received a low sensitivity and accuracy evaluation, corresponding to articles published at a time when high-fidelity imaging equipment such as tomographs did not yet exist. Thus, the present research has guaranteed that the findings of the included studies provide reliable results.

Ethnicity reveals significant anatomical variations in the teeth, as evidenced by the findings of several investigations. There is relevant variability in the number of root and root canal configurations dating from different historical periods, suggesting that genetics influences morphological diversity ([Z, 105](#)). In addition, odontometric analyses have shown that East and Southeast Asians share dental similarities with sub-Saharan Africans, which places them at the center of a wide range of dental characteristics ([106](#)). On the other hand, research on African-American populations has shown the impact of mixing, derivation, and localized gene flow on dental morphology, which demonstrates the complex relationship of sociohistorical factors when studying anatomical characteristics ([107](#)). All these studies highlight the intricate correspondence between ethnic origins and dental anatomical variations and shed light on the diverse patterns observed in different population groups around the world ([Z, 108](#)). This background derives the complexity of establishing anatomical patterns by considering populations of different continents, although a general view is helpful in visualizing an overview of these times.

Latin Americans show intermediate frequencies of dental features compared to those of Native Americans, Europeans and Africans ([109](#)). This is due to the mass exodus from the European and African continents centuries ago, which evidently had a direct impact on the anatomical characteristics of today's inhabitants. In the present study, the American population had divergent characteristics with the European and African populations ([110](#)) in terms of the maxillary first molar, but homogeneous samples were not recovered from these last two continents, as in the case of the Asian continent. The rest of the molar groups had similar typologies, although the study by *Delgado et al* ([109](#)) shows that dental characteristics provide a low predictive power of individual genetic ancestry. These findings underscore the importance of taking ethnicity into account when assessing anatomical variations in the permanent molar canals.

Naseri et al. ([111](#)) analyzed studies from Iran and stated that although most maxillary first molars have three roots, the studies included in this research demonstrated a high frequency of two or more ducts in the mesiobuccal root. In the current study, the results concurred in a similar manner, and although the first maxillary molars with three canals prevailed, the second highest prevalence found in the studies was that of molars with four root canals. These results indicate

that the variability between three and four canals in clinical practice can be frequently found according to geographical context or globally. This was demonstrated by a systematic review by Barbhai et al.⁽¹¹²⁾, who found that 68.2% of the first maxillary molars had a second mesiobuccal canal.

A systematic review by *Valencia de Pablo et al.*⁽¹¹³⁾ attempted to analyze the published literature related to root anatomy and configuration of the root canal system of the mandibular permanent first molar. In relation to the number of canals in this dental group, they determined that of 18 studies that included 4745 teeth, 61.3% had three canals, 35.7% 4 canals and about 1% had five canals. These results are almost identical to those obtained in the present study, and it is worth noting that they included reports with the same geographical diversity as this study.

Valencia de Pablo et al.⁽¹¹³⁾ suggest that the number of roots of the mandibular first molar is directly related to the ethnicity of the population studied. The presence of a third root is more common in the Native American, Eskimos, and Chinese populations, suggesting a genetic component.

Another systematic review by *AL-Rammahi et al.*⁽¹¹⁴⁾ observed the presence of a medial mesial canal in some studies, with a variable prevalence, which implies that the alterations of the normal anatomy of the mandibular first molar conform more to an anatomical pattern of three canals, as classically expressed in the academic literature. In addition, in distal roots, the study found a conduit that corresponded to the most common configuration. These results coincide with the prevalence of mandibular first molars in the three canals in the present study, although it is essential to take into account the anatomical variability of this molar group to obtain successful endodontic treatment.

Although the research by *Mashyakhy et al.*⁽¹¹⁵⁾ was exclusive to studies that included mandibular teeth from Saudi Arabian populations, it was found that the first mandibular molars had three and four canals with a higher prevalence (58.7% and 40.6%, respectively). In the present study, the results were convergent with those of *Mashyakhy et al.*⁽¹¹⁵⁾ even when these characteristics were specified in the continent to which that nation belongs.

In the study by *Joshi et al.*⁽¹¹⁶⁾, the mandibular second molars had three roots. In their systematic review, most mesial roots had two canals (70.4%) and most distal roots had a single canal (77%). *Mashyakhy et al.*⁽¹¹⁵⁾ found similar results in their systematic review research exclusively for population studies in Saudi Arabia. The present research had similar global and individual results for each continent on the prevalence of mandibular second molars with three canals, although

in all the studies that studied this molar group there were cases of teeth that had two canals with a not so low prevalence. This fact warns that the anatomy of the root canals in the second molars of the mandible is variable and complex.

Limited research on the root and root canal morphology of third molars faces important implications for dental practice and the understanding of craniofacial morphology. Studies have shown that third molars have an unpredictable anatomy, with new canal configurations that had not been previously described in the literature, which highlights the need for further research⁽⁴⁾ In addition, craniofacial morphology has been related to the impaction of the third molars⁽¹¹⁷⁾ and their agenesis⁽¹¹⁸⁾ which exposes the importance of taking into account other facial parameters in treatment decisions.

The study by *Morita et al*⁽¹¹⁹⁾ encourages understanding the metameric variation in human molars through a detailed morphological analysis that can provide information on the evolution and development of teeth. Perhaps applied to this dental group it can allow a better understanding of its dental morphology and its evolutionary implications.

The findings of this study suggest that the internal anatomy of permanent molars, particularly the number of root canals, presents significant variations globally. These variations have important implications in clinical practice, as they can influence endodontic treatment planning, the likelihood of treatment success, and the management of complications. More research is needed to understand the causes of these variations and develop more precise treatment strategies for different populations.

Among the limitations of the present study is the fact that although all continents were representative and the sample was large enough to generalize the results, there was no homogeneity in the distribution due to lack of studies in many of the continents. Such was the case in America, specifically North America, Africa and Europe. Despite this, it was possible to visualize a pattern in the number of canals for each molar group studied and to delimit them to the geographical regions in question.

The future directions for this controversial topic in the dental profession aim to systematize in the compilation of new inclusive studies for a subsequent analysis of the anatomical behavior of the root canals of posterior teeth and to the need to carry out studies to make a sketch of what would be interesting from the point of view of the clinical view focused in the presence of number of root canals have those teeth when the clinician performs approaches for endodontic treatments.

CONCLUSIONS

The study evaluated geographic variation in the internal anatomy of the root canals of permanent molars and found a wide variability in the number of root canals according to geographic region. The results reveal distinct patterns in the Americas, Asia, Africa, Europe, and Oceania, with varying prevalences of different root canal configurations on each continent.

It was observed that, in Africa, the upper and lower first and second molars most frequently have three root canals. In America, the first upper molars stand out for having four root canals. In Asia, most molars have three root canals, except for the lower third molars, where a similar proportion of two and three root canals is observed. In Europe, the upper and lower molars, except for the lower third, show a predominance of three root canals. Finally, in Oceania, the first upper molars are characterized by having six root canals with a higher frequency.

REFERENCES

1. Ahmed HMA, Musale PK, El Shahawy OI, Dummer PMH. Application of a new system for classifying tooth, root and canal morphology in the primary dentition. *International Endodontic Journal*. 2020;53(1):27-35. <https://doi.org/10.1111/iej.13199>
2. Ahmed HMA, Ibrahim N, Mohamad NS, Nambiar P, Muhammad RF, Yusoff M, et al. Application of a new system for classifying root and canal anatomy in studies involving micro-computed tomography and cone beam computed tomography: Explanation and elaboration. *International Endodontic Journal*. 2021;54(7):1056-82. <https://doi.org/10.1111/iej.13486>
3. Ahmed HMA, Versiani MA, De-Deus G, Dummer PMH. A new system for classifying root and root canal morphology. *International Endodontic Journal*. 2017;50(8):761-70. <https://doi.org/10.1111/iej.12685>
4. Al-Qudah AA, Bani Younis HAB, Awawdeh LA, Daud A. Root and canal morphology of third molar teeth. *Sci Rep*. 2023;13(1):6901. doi:10.1038/s41598-023-34134-7

5. Ahmed HMA. Anatomical challenges, electronic working length determination and current developments in root canal preparation of primary molar teeth. *International Endodontic Journal*. 2013;46(11):1011-22. <https://doi.org/10.1111/iej.12134>
6. Tomaszewska IM, Leszczyński B, Wróbel A, Gładysz T, Duncan HF. A micro-computed tomographic (micro-CT) analysis of the root canal morphology of maxillary third molar teeth. *Ann Anat*. 2018;215(83-92). doi:10.1016/j.aanat.2017.09.003
7. Przesmycka A, Tomczyk J, Zalewska M, Regulski P. Root and root canal diversity in human permanent maxillary first premolars and first molars in inhabitants from the ancient Middle Euphrates Valley (Syria). *International Journal of Osteoarchaeology*. 2023;33(1):16-25. doi: <https://doi.org/10.1002/oa.3170>
8. Martos J, Jardim Silva L, Lourenço Morel L, Hisse Gomes G, Gomes e Silva Leonardo N. Primeiro molar inferior permanente com radix entomolaris: relato de caso de uma ocorrência incomum. Relato de Caso. *Endodontics*. 2023;13(2):10320. <https://doi.org/10.14436/2358-2545.13.2.200-216.oar>
9. Mathew T, Shetty A, Hegde MN, Babu B, Shetty KS. Study of the morphology of MB2 canals in maxillary first molars using CBCT. *Indian Journal of Public Health Research and Development*. 2018;9(5):359-62. doi:10.5958/0976-5506.2018.00495.3
10. Shetty A, Bhat R, Babu B, Hegde MN, Shetty C, Shetty P, et al. Occurrence and Morphology of MB2 Canals in Maxillary First Molars in an Indian Subpopulation: A Cone Beam Computed Tomography Study. *Journal of Health and Allied Sciences Nu*. 2022;12(2):101-5. doi:10.1055/s-0041-1736268
11. Betancourt P, Fuentes R, Aracena Rojas S, Cantín M, Navarro Cáceres P. Prevalencia del segundo canal en la raíz mesiovestibular de los primeros molares maxilares mediante tomografía computarizada de haz de cono. *Avances en Odontoestomatología*. 2013;29(31-6).

12. Al-Jumeily D, Balchin A, Bishop L, Ferrebe A, Simkhada P. Internationalisation: cui bono? Innovations in Practice. 2018;12(1):17-20. <https://doi.org/10.24377/LJMU.iip.vol12iss1article208>
13. Fragouli E. Internationalizing the Curriculum. IJHEM. 2020;06(02):18-30. <https://doi.org/10.24052/IJHEM/V06N02/ART-2>
14. Martins JNR, Gu Y, Marques D, Francisco H, Caramês J. Differences on the Root and Root Canal Morphologies between Asian and White Ethnic Groups Analyzed by Cone-beam Computed Tomography. Journal of Endodontics. 2018;44(7):1096-104. doi:10.1016/j.joen.2018.04.001
15. Peiris R. Root and canal morphology of human permanent teeth in a Sri Lankan and Japanese population. Anthropological Science. 2008;116(2):123-33. doi:10.1537/ase.070723
16. Rosaline H, Kanagasabai A, Shaji A, Bose S, Saeralaathan S, Ganesh A. Analysis of root and canal morphologies of maxillary second molars in a South Indian population using cone-beam computed tomography: A retrospective study. Endodontology. 2021;33(3):133-8. doi:10.4103/endo.endo_93_21
17. Aydin H. Analysis of root and canal morphology of fused and separate rooted maxillary molar teeth in Turkish population. Niger J Clin Pract. 2021;24(3):435-42. doi:10.4103/njcp.njcp_316_20
18. Kim Y, Lee SJ, Woo J. Morphology of maxillary first and second molars analyzed by cone-beam computed tomography in a Korean population: variations in the number of roots and canals and the incidence of fusion. J Endod. 2012;38(8):1063-8. doi:10.1016/j.joen.2012.04.025
19. Rahman NA, Halim MS, Khamis MF, Ghani HA. Analysis of root and canal morphology of maxillary first and second molars among Malay ethnic in the Malaysian population with the aid of cone-beam computed tomography: A retrospective study. European Journal of General Dentistry. 2020;9(2):84-9. doi:10.4103/ejgd.ejgd_167_19

20. Algarni YA. Analysis of root canal anatomy and variation in morphology of maxillary first molar using various methods: An in vitro study. *World Journal of Dentistry*. 2019;10(4):291-4. doi:10.5005/jp-journals-10015-1644
21. Mantovani VDO, Gabriel AEDS, Silva RG, Savioli RN, Sousa-Neto MD, Cruz-Fiiho AM. Analysis of the mandibular molars root canals morphology. Study by computed tomography. *Brazilian Dental Journal*. 2022;33(5):1-8. doi:10.1590/0103-6440202205105
22. Tian XM, Yang XW, Qian L, Wei B, Gong Y. Analysis of the Root and Canal Morphologies in Maxillary First and Second Molars in a Chinese Population Using Cone-beam Computed Tomography. *Journal of Endodontics*. 2016;42(5):696-701. doi:10.1016/j.joen.2016.01.017
23. Stropko JJ. Canal morphology of maxillary molars: clinical observations of canal configurations. *J Endod*. 1999;25(6):446-50. doi:10.1016/s0099-2399(99)80276-3
24. Donyavi Z, Shokri A, Khoshbin E, Khalili M, Faradmal J. Assessment of root canal morphology of maxillary and mandibular second molars in the Iranian population using CBCT. *Dent Med Probl*. 2019;56(1):45-51. doi:10.17219/dmp/101783
25. Wang M, Gao Y, Deng Q, Gao Y, Song D, Huang D. Assessment of the coronal root canal morphology of permanent maxillary first molars using digital 3D-reconstruction technology based on micro-computed tomography data. *J Dent Sci*. 2023;18(2):586-93. doi:10.1016/j.jds.2022.08.011
26. Mirza MB, Gufran K, Alhabib O, Alafraa O, Alzahrn F, Abuelqomsan MAS, et al. CBCT based study to analyze and classify root canal morphology of maxillary molars – A retrospective study. *European Review for Medical and Pharmacological Sciences*. 2022;26(18):6550-60. doi:10.26355/eurrev_202209_29753
27. Krishnamurthy NH, Athira P, Umapathy T, Balaji P, Jose S. A CBCT Study to Evaluate the Root and Canal Morphology of Permanent Maxillary First Molars in Children. *Int J Clin Pediatr Dent*. 2022;15(5):509-13. doi:10.5005/jp-journals-10005-2441

28. Moazzy IA, Moazzy IA, Saad MAZ, Saad MA-Z, Abdulmjeed SE, Abdulmjeed SE, et al. Comprehensive evaluation of root and root canal morphology of mandibular second molars in a Saudi subpopulation evaluated by cone-beam computed tomography. BMC Oral Health. 2022;doi:10.1186/s12903-022-02305-z
29. Al Shehadat S, Waheb S, Al Bayatti SW, Kheder W, Khalaf K, Murray CA. Cone Beam Computed Tomography Analysis of Root and Root Canal Morphology of First Permanent Lower Molars in a Middle East Subpopulation. J Int Soc Prev Community Dent. 2019;9(5):458-63. doi:10.4103/jispcd.JISPCD_41_19
30. Madfa AA, Almansour MI, Al-Zubaidi SM, Alghurayes AH, Al DSD, Alzoori FI, et al. Cone beam computed tomography analysis of the root and canal morphology of the maxillary second molars in a Hail province of the Saudi population. Heliyon. 2023;9(9):e19477. doi:10.1016/j.heliyon.2023.e19477
31. Kalender A, Celikten B, Tufenkci P, Aksoy U, Basmaci F, Kelahmet U, et al. Cone beam computed tomography evaluation of maxillary molar root canal morphology in a Turkish Cypriot population. Biotechnology & Biotechnological Equipment. 2016;30(1):145-50. doi:10.1080/13102818.2015.1092885
32. Celikten B, Tufenkci P, Aksoy U, Kalender A, Kermeoglu F, Dabaj P, et al. Cone beam CT evaluation of mandibular molar root canal morphology in a Turkish Cypriot population. Clin Oral Investig. 2016;20(8):2221-6. doi:10.1007/s00784-016-1742-2
33. Pérez-Heredía M, Ferrer-Luque CM, Bravo M, Castelo-Baz P, Ruíz-Piñón M, Baca P. Cone-beam Computed Tomographic Study of Root Anatomy and Canal Configuration of Molars in a Spanish Population. J Endod. 2017;43(9):1511-6. doi:10.1016/j.joen.2017.03.026
34. Al-Sheeb F, Diab H, Al Obaid M, Diab A, Lari M, Mahmoud N. Cone-beam computed tomographic study of root morphology, canal configuration, and bilateral symmetry of mandibular first and second molars in a Qatari population. Saudi Endodontic Journal. 2022;12(2):186-94. doi:10.4103/sej.sej_176_21

35. Deng PU, Halim MS, Masudi SM, Al-Shehadat S, Ahmad B. Cone-beam computed tomography analysis on root and canal morphology of mandibular first permanent molar among multiracial population in East Coast Malaysian population. *Eur J Dent.* 2018;12(3):410-6. doi:10.4103/ejd.ejd_82_18
36. Zheng QH, Wang Y, Zhou XD, Wang QA, Zheng GN, Huang DM. A Cone-Beam Computed Tomography Study of Maxillary First Permanent Molar Root and Canal Morphology in a Chinese Population. *Journal of Endodontics.* 2010;36(9):1480-4. doi:10.1016/j.joen.2010.06.018
37. Popovic M, Zivanovic S, Vucicevic T, Grujovic M, Papic M. Cone-beam computed tomography study of tooth root and canal morphology of permanent molars in a Serbian population. *Vojnosanitetski Pregled.* 2020;77(5):470-8. doi:10.2298/vsp180322100p
38. Fu Y, Deng Q, Xie Z, Sun J, Song D, Gao Y, et al. Coronal root canal morphology of permanent two-rooted mandibular first molars with novel 3D measurements. *Int Endod J.* 2020;53(2):167-75. doi:10.1111/iej.13220
39. Rios P, Arriagada C, Rosas C, Aracena D. Description of the Morphology of the Root Canal System of the Maxillary First Molar Using Cone-Beam Computed Tomography in a Chilean Population. *International Journal of Morphology.* 2023;41(2):477-81. doi:10.4067/S0717-95022023000200477
40. Razumova S, Brago A, Khaskhanova L, Barakat H, Howijieh A. Evaluation of Anatomy and Root Canal Morphology of the Maxillary First Molar Using the Cone-Beam Computed Tomography among Residents of the Moscow Region. *Contemp Clin Dent.* 2018;9(S133-s6). doi:10.4103/ccd.ccd_127_18
41. Namdar P, Molania T, Hoshyari N, Lotfizadeh A, Alimohammadi M, Khojastehfar M, et al. Evaluation of Root and Canal Morphology of Maxillary First and Second Molars by Cone Beam Computed Tomography in a Northern Iranian Population. *Journal of Research in Dental and Maxillofacial Sciences.* 2023;8(4):265-73. doi:10.52547/jrdms.8.4.265

42. Wang H, Ci BW, Yu HY, Qin W, Yan YX, Wu BL, et al. Evaluation of root and canal morphology of maxillary molars in a southern chinese subpopulation: A cone-beam computed tomographic study. *International Journal of Clinical and Experimental Medicine*. 2017;10(4):7030-9. doi:
43. Guo J, Vahidnia A, Sedghizadeh P, Enciso R. Evaluation of root and canal morphology of maxillary permanent first molars in a North American population by cone-beam computed tomography. *J Endod*. 2014;40(5):635-9. doi:10.1016/j.joen.2014.02.002
44. Al Mheiri E, Chaudhry J, Abdo S, El Abed R, Khamis AH, Jamal M. Evaluation of root and canal morphology of maxillary permanent first molars in an Emirati population; a cone-beam computed tomography study. *BMC Oral Health*. 2020;20(1):274. doi:10.1186/s12903-020-01269-2
45. Ahmed G, Ahmed Mostafa G, Muhammad N, Mohamed Mokhtar N, Amr Ahmed B, Amr B, et al. Evaluation of Root and Canal Morphology of Maxillary Permanent Molars in an Egyptian Population by Cone-beam Computed Tomography. *Journal of Endodontics*. 2017;doi:10.1016/j.joen.2017.02.014
46. Alrahabi M, Sohail Zafar M. Evaluation of root canal morphology of maxillary molars using cone beam computed tomography. *Pak J Med Sci*. 2015;31(2):426-30. doi:10.12669/pjms.312.6753
47. Reuben J, Velmurugan N, Kandaswamy D. The evaluation of root canal morphology of the mandibular first molar in an Indian population using spiral computed tomography scan: an in vitro study. *J Endod*. 2008;34(2):212-5. doi:10.1016/j.joen.2007.11.018
48. Dibaji F, Shariati R, Moghaddamzade B, Mohammadian F, Sooratgar A, Kharazifard M. Evaluation of the relationship between buccolingual width of mesiobuccal root and root canal morphology of maxillary first molars by cone-beam computed tomography. *Dent Res J (Isfahan)*. 2022;19(5). doi:10.4103/1735-3327.336690

49. Wang Y, Zheng QH, Zhou XD, Tang L, Wang Q, Zheng GN, et al. Evaluation of the root and canal morphology of mandibular first permanent molars in a western Chinese population by cone-beam computed tomography. *J Endod.* 2010;36(11):1786-9. doi:10.1016/j.joen.2010.08.016
50. Nikoloudaki GE, Kontogiannis TG, Kerezoudis NP. Evaluation of the Root and Canal Morphology of Maxillary Permanent Molars and the Incidence of the Second Mesio Buccal Root Canal in Greek Population Using Cone-beam Computed Tomography. *Open Dent J.* 2015;9(267-72). doi:10.2174/1874210601509010267
51. Caputo BV, Noro Filho GA, de Andrade Salgado DM, Moura-Netto C, Giovani EM, Costa C. Evaluation of the Root Canal Morphology of Molars by Using Cone-beam Computed Tomography in a Brazilian Population: Part I. *J Endod.* 2016;42(11):1604-7. doi:10.1016/j.joen.2016.07.026
52. Pawar A, Thakur B, Machado R, Kwak SW, Kim HC. An In-Vivo cone-beam computed tomography analysis of root and canal morphology of maxillary first permanent molars in an Indian population. *Indian J Dent Res.* 2021;32(1):104-9. doi:10.4103/ijdr.IJDR_782_19
53. Monsarrat P, Arcaute B, Peters OA, Maury E, Telmon N, Georgelin-Gurgel M, et al. Interrelationships in the Variability of Root Canal Anatomy among the Permanent Teeth: A Full-Mouth Approach by Cone-Beam CT. *PLoS One.* 2016;11(10):e0165329. doi:10.1371/journal.pone.0165329
54. McGuigan MB, Theodorakou C, Duncan HF, Davies J, Sengupta A, Horner K. An investigation into dose optimisation for imaging root canal anatomy using cone beam CT. *Dentomaxillofac Radiol.* 2020;49(7):20200072. doi:10.1259/dmfr.20200072
55. Matsunaga S, Yamada M, Kasahara N, Noguchi T, Morita S, Kitamura K, et al. Japanese Maxillary First Molar Root Canal Morphology: An Ultrastructural Study Using Micro-Computed Tomography. *Journal of Hard Tissue Biology.* 2022;31(2):109-14. doi:10.2485/jhtb.31.109

56. Ren HY, Kum KY, Zhao YS, Yoo YJ, Jeong JS, Perinpanayagam H, et al. Maxillary molar root and canal morphology of Neolithic and modern Chinese. *Arch Oral Biol.* 2021;131(105272). doi:10.1016/j.archoralbio.2021.105272
57. Zhang T, Zhao M, Hu Y. Maxillary Molar Root Canal Morphology Using Cone-Beam Computed Tomography: An Epidemiological Study from Shandong Province, China. *International Journal of Morphology.* 2023;41(3):775-84. doi:10.4067/S0717-95022023000300775
58. Lee JH, Kim KD, Lee JK, Park W, Jeong JS, Lee Y, et al. Mesio Buccal root canal anatomy of Korean maxillary first and second molars by cone-beam computed tomography. *Oral Surg Oral Med Oral Pathol Oral Radiol Endod.* 2011;111(6):785-91. doi:10.1016/j.tripleo.2010.11.026
59. Verma P, Love RM. A Micro CT study of the mesio buccal root canal morphology of the maxillary first molar tooth. *Int Endod J.* 2011;44(3):210-7. doi:10.1111/j.1365-2591.2010.01800.x
60. Filpo-Perez C, Bramante CM, Villas-Boas MH, Húngaro Duarte MA, Versiani MA, Ordinola-Zapata R. Micro-computed tomographic analysis of the root canal morphology of the distal root of mandibular first molar. *J Endod.* 2015;41(2):231-6. doi:10.1016/j.joen.2014.09.024
61. Asijavičienė U, Drukteinis S, Suduiko A. Microcomputed tomography evaluation of the root canals morphology of the mandibular first molars. *Stomatologija.* 2020;22(3):75-9. doi:
62. Kim SY, Kim BS, Woo J, Kim Y. Morphology of mandibular first molars analyzed by cone-beam computed tomography in a Korean population: variations in the number of roots and canals. *J Endod.* 2013;39(12):1516-21. doi:10.1016/j.joen.2013.08.015
63. Lyra CM, delai D, Pereira KCR, Pereira GM, Júnior BP, Oliveira CAP. Morphology of mesio buccal root canals of maxillary first molars: A comparison of CBCT scanning and cross-sectioning. *Brazilian Dental Journal.* 2015;26(5):525-9. doi:10.1590/0103-644020130096
64. Kenawi LMM, Althobaiti RF, Filimban DM, Alotaiby SDA, Alharbi MA, Kassar WM. Radiographic Investigation of Root Canal Morphology of Permanent Mandibular Molars in

Makkah Population (Saudi Arabia) Using Cone-Beam Computed Tomography. *Int J Dent.* 2022;2022(1535752). doi:10.1155/2022/1535752

65. Mohara NT, Coelho MS, de Queiroz NV, Borreau MLS, Nishioka MM, de Jesus Soares A, et al. Root Anatomy and Canal Configuration of Maxillary Molars in a Brazilian Subpopulation: A 125- μ m Cone-Beam Computed Tomographic Study. *Eur J Dent.* 2019;13(1):82-7. doi:10.1055/s-0039-1688736

66. Xia Y, Qiao X, Huang YJ, Li YH, Zhou Z. Root Anatomy and Root Canal Morphology of Maxillary Second Permanent Molars in a Chongqing Population: A Cone-Beam Computed Tomography Study. *Med Sci Monit.* 2020;26(e922794). doi:10.12659/msm.922794

67. Atram J, Banga K, Gupta P, Pawar A. Root and canal anatomy of mandibular first molar teeth of an Indian population. *Endodontology.* 2020;32(1):3-7. doi:10.4103/endo.endo_71_19

68. Rwenyonyi CM, Kutesa A, Muwazi LM, Buwembo W. Root and canal morphology of mandibular first and second permanent molar teeth in a Ugandan population. *Odontology.* 2009;97(2):92-6. doi:10.1007/s10266-009-0100-0

69. Senan E, Alhadainy H, Madfa AA. Root and Canal Morphology of Mandibular Second Molars in a Yemeni Population: A Cone-beam Computed Tomography. *Eur Endod J.* 2021;6(1):72-81. doi:10.14744/ej.2020.94695

70. Shehabeldin Mohamed S, Mohammed abou El S, Shaimaa Mohamed Abu el S, Nawar Naguib N. Root and canal morphology of mandibular second molars in an Egyptian subpopulation: a cone-beam computed tomography study. *BMC oral health.* 2023;doi:10.1186/s12903-023-02939-7

71. Prasanna N, Chandana S, Chandana S, Subbarao CV, Mithun R, et al. Root and canal morphology of mandibular second molars in an Indian population. *Journal of Endodontics.* 2010;doi:10.1016/j.joen.2010.04.001

72. Ahmed HA, Abu-bakr NH, Yahia NA, Ibrahim YE. Root and canal morphology of permanent mandibular molars in a Sudanese population. *Int Endod J.* 2007;40(10):766-71. doi:10.1111/j.1365-2591.2007.1283.x
73. Gulabivala K, Opananon A, Ng YL, Alavi A. Root and canal morphology of Thai mandibular molars. *Int Endod J.* 2002;35(1):56-62. doi:10.1046/j.1365-2591.2002.00452.x
74. Mashyakhy M, Gambarini G. Root and Root Canal Morphology Differences Between Genders: A Comprehensive in-vivo CBCT Study in a Saudi Population. *Acta Stomatol Croat.* 2019;53(3):213-46. doi:10.15644/asc53/3/5
75. Qi G, Qi G, Qinxiu W, Qinxiu W, Yaling Y, Yongjian Y, et al. Root and root canal morphology of mandibular second permanent molars in the Gansu province population: A <sc>CBCT</sc> study. *Australian Endodontic Journal.* 2022;doi:10.1111/aej.12692
76. Ahmad I, Azzeh M, Zwiri A, Abu Haija MA, Diab M. Root and root canal morphology of third molars in a Jordanian subpopulation. *Saudi Endodontic Journal.* 2016;6(3):113-21. doi:10.4103/1658-5984.189350
77. Demirtaş Ö, Duman ŞB. Root canal anatomy of maxillary first molars in a Turkish population using cone-beam computed tomography. *Journal of Dental Materials and Techniques.* 2023;12(4):168-74. doi:10.22038/JDMT.2023.70840.1557
78. Pawar AM, Pawar M, Kfir A, Singh S, Salve P, Thakur B, et al. Root canal morphology and variations in mandibular second molar teeth of an Indian population: an in vivo cone-beam computed tomography analysis. *Clin Oral Investig.* 2017;21(9):2801-9. doi:10.1007/s00784-017-2082-6
79. Gomez F, Brea G, Gomez-Sosa JF. Root canal morphology and variations in mandibular second molars: an in vivo cone-beam computed tomography analysis. *BMC Oral Health.* 2021;21(1):424. doi:10.1186/s12903-021-01787-7

80. Ceperuelo D, Lozano M, Duran-Sindreu F, Mercadé M. Root canal morphology of Chalcolithic and early bronze age human populations of El Mirador Cave (Sierra de Atapuerca, Spain). *Anat Rec (Hoboken)*. 2014;297(12):2342-8. doi:10.1002/ar.22958
81. Shahi S, Yavari HR, Rahimi S, Torkamani R. Root canal morphology of human mandibular first permanent molars in an Iranian population. *J Dent Res Dent Clin Dent Prospects*. 2008;2(1):20-3. doi:10.5681/joddd.2008.004
82. Sidow SJ, West LA, Liewehr FR, Loushine RJ. Root canal morphology of human maxillary and mandibular third molars. *J Endod*. 2000;26(11):675-8. doi:10.1097/00004770-200011000-00011
83. Chourasia HR, Meshram GK, Warhadpande M, Dakshindas D. Root canal morphology of mandibular first permanent molars in an Indian population. *Int J Dent*. 2012;2012(745152). doi:10.1155/2012/745152
84. Sana U, Niazi IU, Din RS, Rasheed M, Haider I, Yousaf O. Root Canal Morphology of Mandibular First Permanent Molars in Pakistani Sub-population - An in vitro study. *Pakistan Journal of Medical & Health Sciences*. 2021;15(6):1314-6. doi:10.53350/pjmhs211561314
85. Naseri M, Ali Mozayeni M, Safi Y, Heidarnia M, Akbarzadeh Baghban A, Norouzi N. Root Canal Morphology of Maxillary Second Molars according to Age and Gender in a Selected Iranian Population: A Cone-Beam Computed Tomography Evaluation. *Iran Endod J*. 2018;13(3):373-80. doi:10.22037/iej.v13i3.19278
86. Alamri HM, Mirza MB, Riyahi AM, Alharbi F, Aljarbou F. Root canal morphology of maxillary second molars in a Saudi sub-population: A cone beam computed tomography study. *Saudi Dent J*. 2020;32(5):250-4. doi:10.1016/j.sdentj.2019.09.003
87. Habiba Suleiman M, Habiba Suleiman M, Irene Kida M, Irene Kida M, Irene KM. Root canal morphology of native Tanzanian permanent mandibular molar teeth. *The Pan African medical journal*. 2018;doi:10.11604/pamj.2018.31.24.14416

88. Weng XL, Yu SB, Zhao SL, Wang HG, Mu T, Tang RY, et al. Root canal morphology of permanent maxillary teeth in the Han nationality in Chinese Guanzhong area: a new modified root canal staining technique. *J Endod*. 2009;35(5):651-6. doi:10.1016/j.joen.2009.02.010
89. Pan JYY, Parolia A, Chuah SR, Bhatia S, Mutalik S, Pau A. Root canal morphology of permanent teeth in a Malaysian subpopulation using cone-beam computed tomography. *BMC Oral Health*. 2019;19(1):14. doi:10.1186/s12903-019-0710-z
90. Singh S, Pawar M. Root canal morphology of South Asian Indian maxillary molar teeth. *Eur J Dent*. 2015;9(1):133-44. doi:10.4103/1305-7456.149662
91. Skidmore AE, Bjorndal AM. Root canal morphology of the human mandibular first molar. *Oral Surg Oral Med Oral Pathol*. 1971;32(5):778-84. doi:10.1016/0030-4220(71)90304-5
92. Walker RT. Root form and canal anatomy of mandibular first molars in a southern Chinese population. *Endod Dent Traumatol*. 1988;4(1):19-22. doi:10.1111/j.1600-9657.1988.tb00287.x
93. Walker RT. Root form and canal anatomy of mandibular second molars in a southern Chinese population. *J Endod*. 1988;14(7):325-9. doi:10.1016/s0099-2399(88)80192-4
94. Jaime A, Jaime A, Durán MRC, Duran M, Diana Yecedth P, Parra D, et al. Root morphology of mandibular molars: a cone-beam computed tomography study. *Folia Morphologica*. 2015;doi:10.5603/fm.a2019.0084
95. Estrela C, Bueno MR, Couto GS, Rabelo LE, Alencar AH, Silva RG, et al. Study of Root Canal Anatomy in Human Permanent Teeth in A Subpopulation of Brazil's Center Region Using Cone-Beam Computed Tomography - Part 1. *Braz Dent J*. 2015;26(5):530-6. doi:10.1590/0103-6440201302448
96. Naseri M, Safi Y, Akbarzadeh Baghban A, Khayat A, Eftekhari L. Survey of Anatomy and Root Canal Morphology of Maxillary First Molars Regarding Age and Gender in an Iranian

Population Using Cone-Beam Computed Tomography. Iran Endod J. 2016;11(4):298-303.
doi:10.22037/iej.2016.8

97. Plotino G, Tocci L, Grande NM, Testarelli L, Messineo D, Ciotti M, et al. Symmetry of root and root canal morphology of maxillary and mandibular molars in a white population: a cone-beam computed tomography study in vivo. J Endod. 2013;39(12):1545-8.
doi:10.1016/j.joen.2013.09.012

98. Fu YJ, Gao Y, Gao YX, Tan XL, Zhang L, Huang DM. Three-dimensional analysis of coronal root canal morphology of 136 permanent mandibular first molars by micro-computed tomography. Journal of Dental Sciences. 2022;17(1):482-9. doi:10.1016/j.jds.2021.07.021

99. Demirbuga S, Sekerci AE, Dinçer AN, Cayabatmaz M, Zorba YO. Use of cone-beam computed tomography to evaluate root and canal morphology of mandibular first and second molars in Turkish individuals. Med Oral Patol Oral Cir Bucal. 2013;18(4):e737-44.
doi:10.4317/medoral.18473

100. Zhang R, Wang H, Tian YY, Yu X, Hu T, Dummer PMH. Use of cone-beam computed tomography to evaluate root and canal morphology of mandibular molars in Chinese individuals. International Endodontic Journal. 2011;44(11):990-9. doi:10.1111/j.1365-2591.2011.01904.x

101. Khattak I, Khattak MA, Khattak YJ, Arbab S, Rashid M, Shah SA. USE OF TOOTH CLEARING TECHNIQUE TO DETERMINE ROOT AND CANAL MORPHOLOGY OF PERMANENT MANDIBULAR THIRD MOLARS IN POPULATION OF PESHAWAR: AN IN VITRO CROSS-SECTIONAL STUDY. Khyber Medical University Journal. 2021;13(4):216-21. doi:10.35845/kmuj.2021.21653

102. Yang L, Han J, Wang Q, Wang Z, Yu X, Du Y. Variations of root and canal morphology of mandibular second molars in Chinese individuals: a cone-beam computed tomography study. BMC Oral Health. 2022;22(1):274. doi:10.1186/s12903-022-02299-8

103. Marušić MF, Fidahić M, Cepuha CM, Farçaş LG, Tseke A, Puljak L. Methodological tools and sensitivity analysis for assessing quality or risk of bias used in systematic reviews published

in the high-impact anesthesiology journals. BMC Medical Research Methodology. 2020;20(1):121. <https://doi.org/10.1186/s12874-020-00966-4>

104. Ho L, Ke FYT, Wong CHL, Wu IXY, Cheung AKL, Mao C, et al. Low methodological quality of systematic reviews on acupuncture: a cross-sectional study. BMC Medical Research Methodology. 2021;21(1):237. <https://doi.org/10.1186/s12874-021-01437-0>

105. Wong BKJ, Leichter JW, Chandler NP, Cullinan MP, Holborow DW. Radiographic Study of Ethnic Variation in Alveolar Bone Height Among New Zealand Dental Students. Journal of Periodontology. 2007;78(6):1070-4. <https://doi.org/10.1902/jop.2007.060366>

106. Hanihara T, Ishida H. Metric dental variation of major human populations. American Journal of Physical Anthropology. 2005;128(2):287-98. <https://doi.org/10.1002/ajpa.20080>

107. Gross JM, Edgar HJH. Geographic and temporal diversity in dental morphology reflects a history of admixture, isolation, and drift in African Americans. American Journal of Physical Anthropology. 2021;175(2):497-505. <https://doi.org/10.1002/ajpa.24258>

108. Hanihara T. Morphological variation of major human populations based on nonmetric dental traits. American Journal of Physical Anthropology. 2008;136(2):169-82. <https://doi.org/10.1002/ajpa.20792>

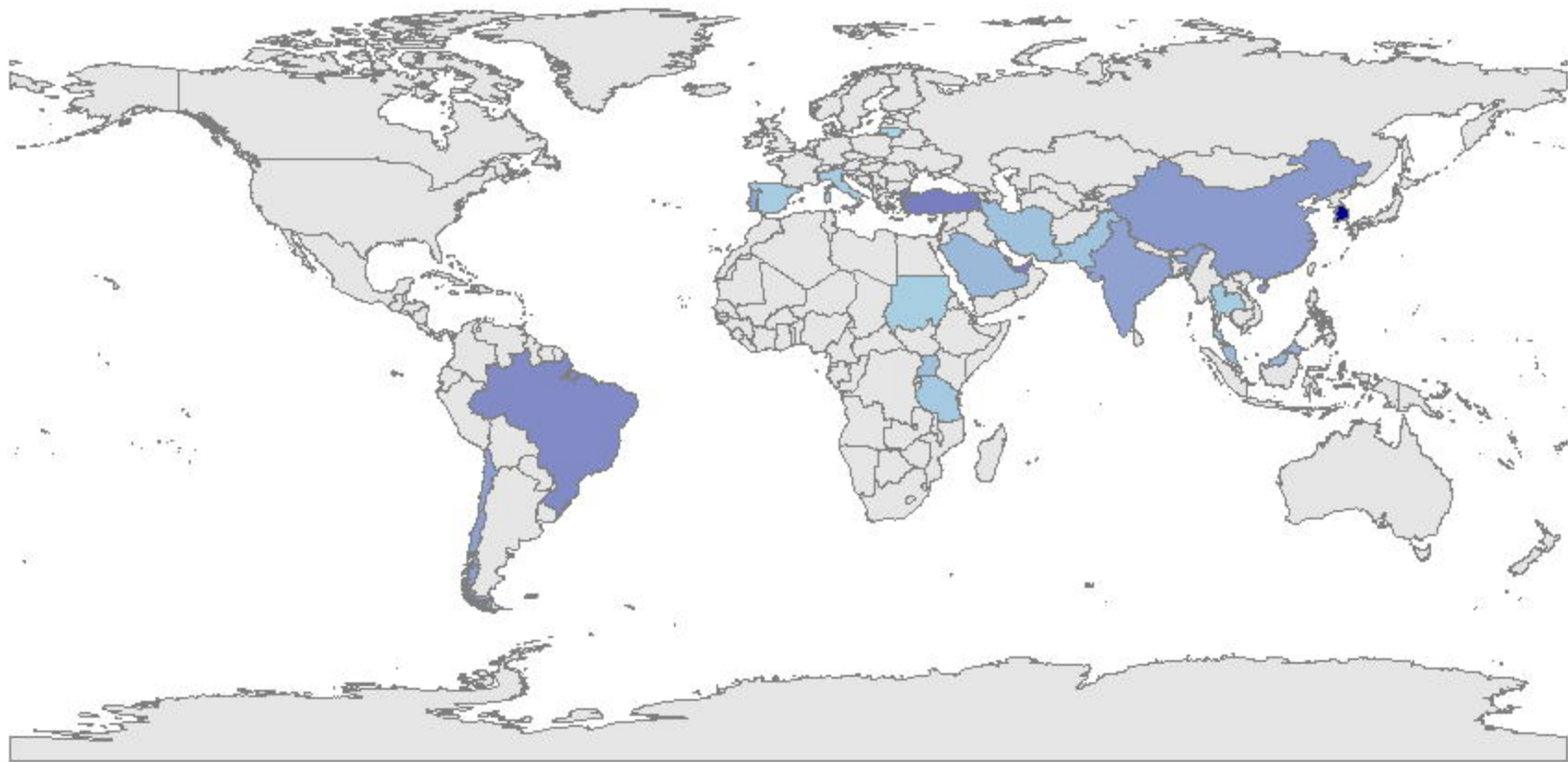
109. Delgado M, Ramírez LM, Adhikari K, Fuentes-Guajardo M, Zanolli C, Gonzalez-José R, et al. Variation in dental morphology and inference of continental ancestry in admixed Latin Americans. American Journal of Physical Anthropology. 2019;168(3):438-47. <https://doi.org/10.1002/ajpa.23756>

110. Sperber, Moreau. Study of the number of roots and canals in Senegalese first permanent mandibular molars. International Endodontic Journal. 1998;31(2):117-22. <https://doi.org/10.1046/j.1365-2591.1998.00126.x>


111. Naseri M, Kharazifard MJ, Hosseinpour S. Canal Configuration of Mesio Buccal Roots in Permanent Maxillary First Molars in Iranian Population: A Systematic Review. *J Dent (Tehran)*. 2016;13(6):438-47.
112. Barbhai S, Shetty R, Joshi P, Mehta V, Mathur A, Sharma T, et al. Evaluation of Root Anatomy and Canal Configuration of Human Permanent Maxillary First Molar Using Cone-Beam Computed Tomography: A Systematic Review. *Int J Environ Res Public Health*. 2022;19(16):10.3390/ijerph191610160
113. de Pablo ÓV, Estevez R, Péix Sánchez M, Heilborn C, Cohenca N. Root Anatomy and Canal Configuration of the Permanent Mandibular First Molar: A Systematic Review. *Journal of Endodontics*. 2010;36(12):1919-31. <https://doi.org/10.1016/j.joen.2010.08.055>
114. Al-Rammahi HM, Chai WL, Nabhan MS, Ahmed HMA. Root and canal anatomy of mandibular first molars using micro-computed tomography: a systematic review. *BMC Oral Health*. 2023;23(1):339. 10.1186/s12903-023-03036-5
115. Mashyakhly M, AlTuwaijri N, Alessa R, Alazzam N, Alotaibi B, Almutairi R, et al. Anatomical Evaluation of Root and Root Canal Morphology of Permanent Mandibular Dentition among the Saudi Arabian Population: A Systematic Review. *Biomed Res Int*. 2022;2022(2400314). 10.1155/2022/2400314
116. Joshi PS, Shetty R, Sarode GS, Mehta V, Chakraborty D. Root anatomy and canal configuration of human permanent mandibular second molar: A systematic review. *J Conserv Dent*. 2021;24(4):298-306. 10.4103/jcd.jcd_642_20
117. Kindler S, Ittermann T, Bülow R, Holtfreter B, Klausenitz C, Metelmann P, et al. Does craniofacial morphology affect third molars impaction? Results from a population-based study in northeastern Germany. *PLoS One*. 2019;14(11):e0225444. 10.1371/journal.pone.0225444
118. Huang Y, Yan Y, Cao J, Xie B, Xiao X, Luo M, et al. Observations on association between third molar agenesis and craniofacial morphology. *Journal of Orofacial Orthopedics / Fortschritte der Kieferorthopädie*. 2017;78(6):504-10. 10.1007/s00056-017-0109-x

119. Morita W, Morimoto N, Ohshima H. Exploring metameric variation in human molars: a morphological study using morphometric mapping. *Journal of Anatomy*. 2016;229(3):343-55.

<https://doi.org/10.1111/joa.12482>




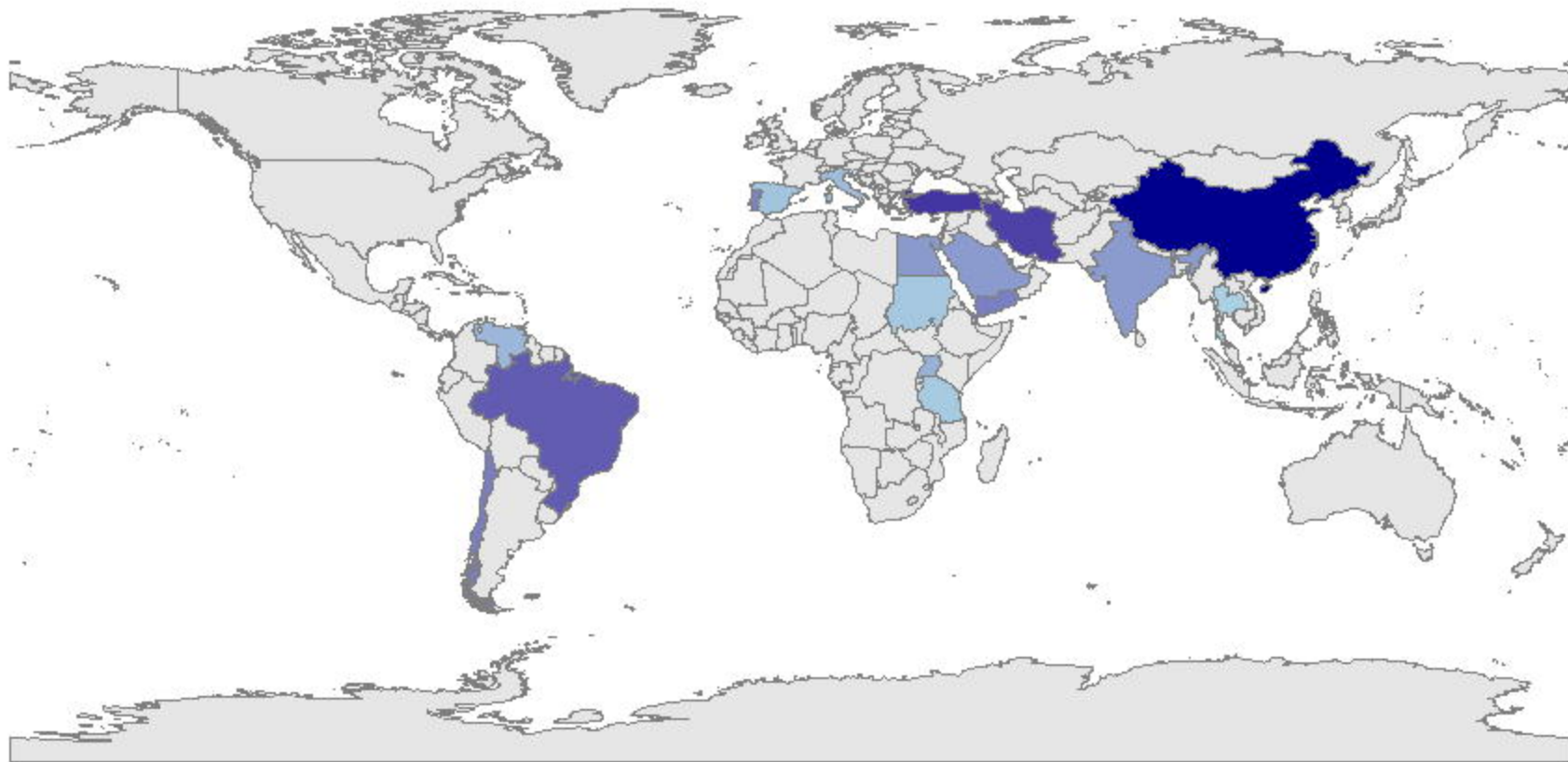
Lower 1st Molars

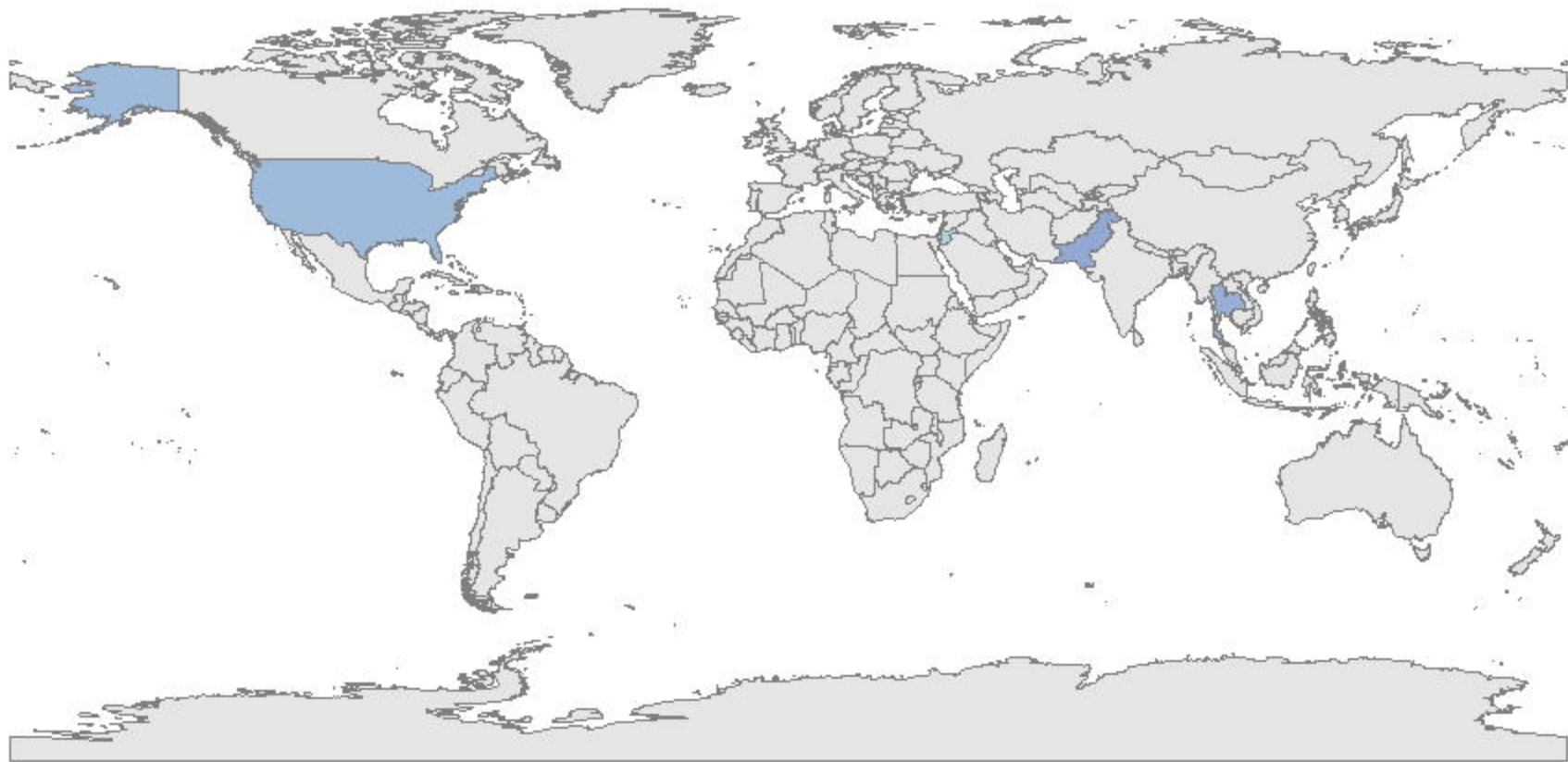


1500

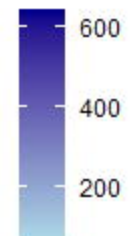
1000

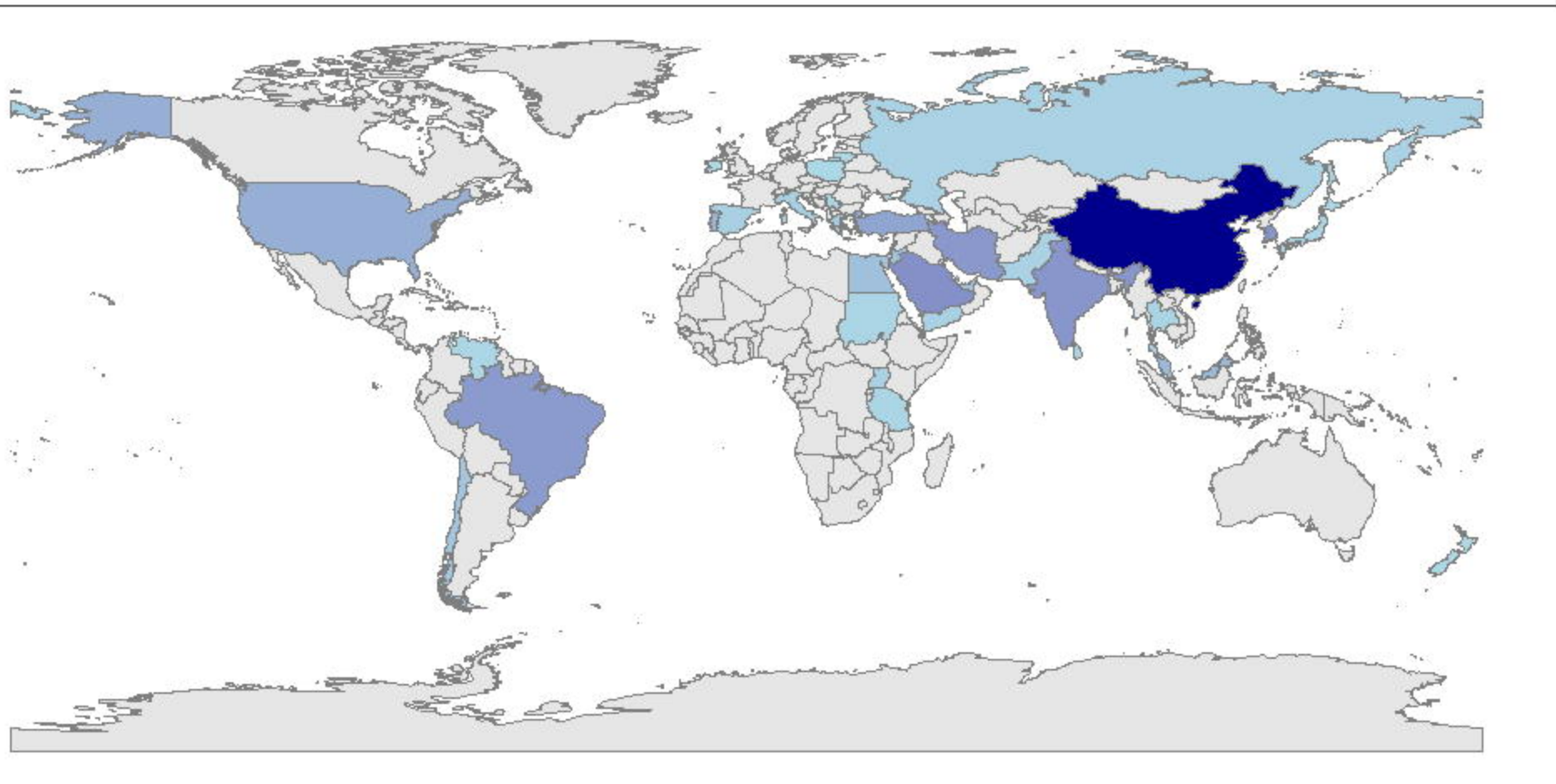
500

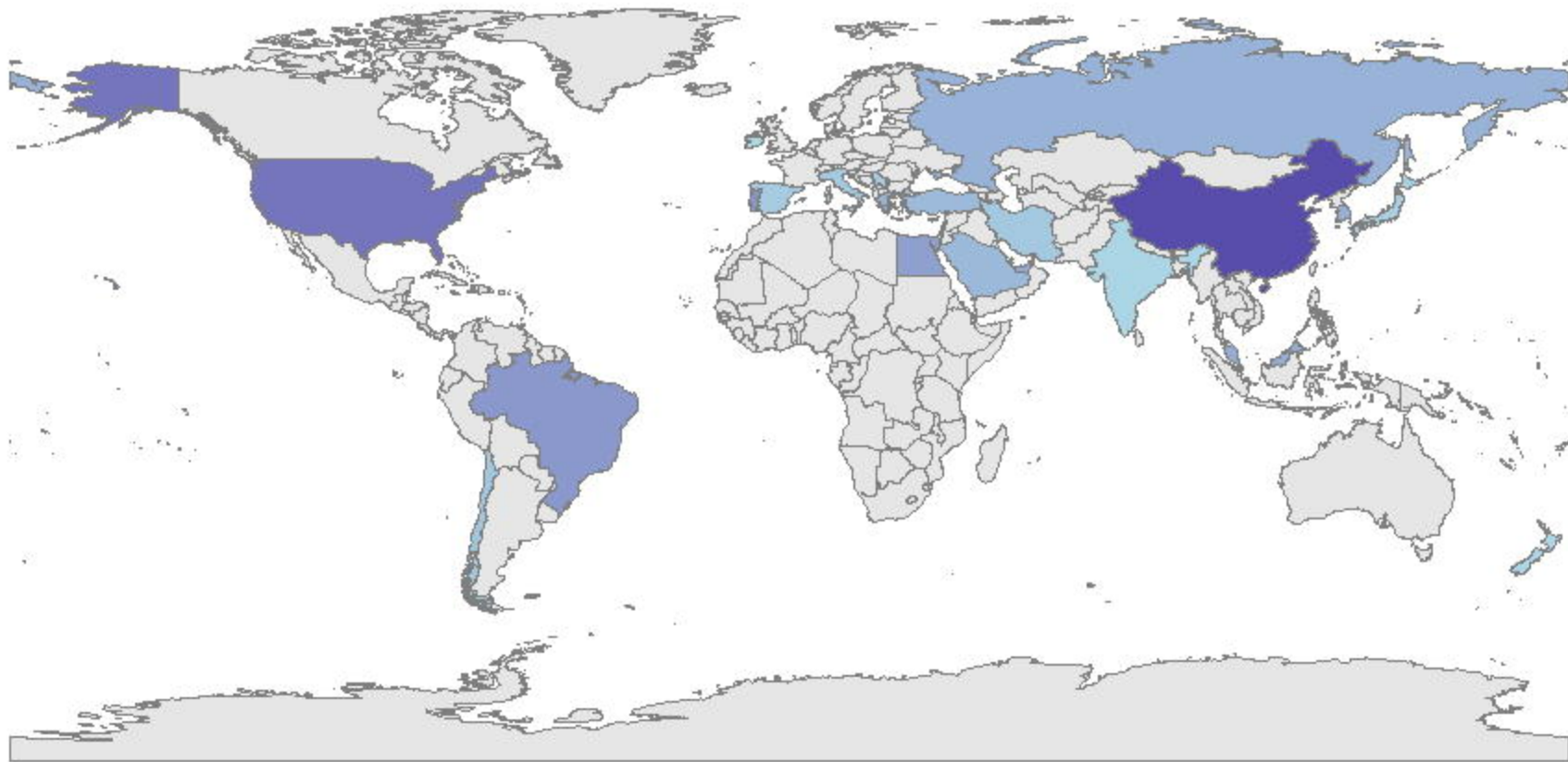




Lower 3th Molars







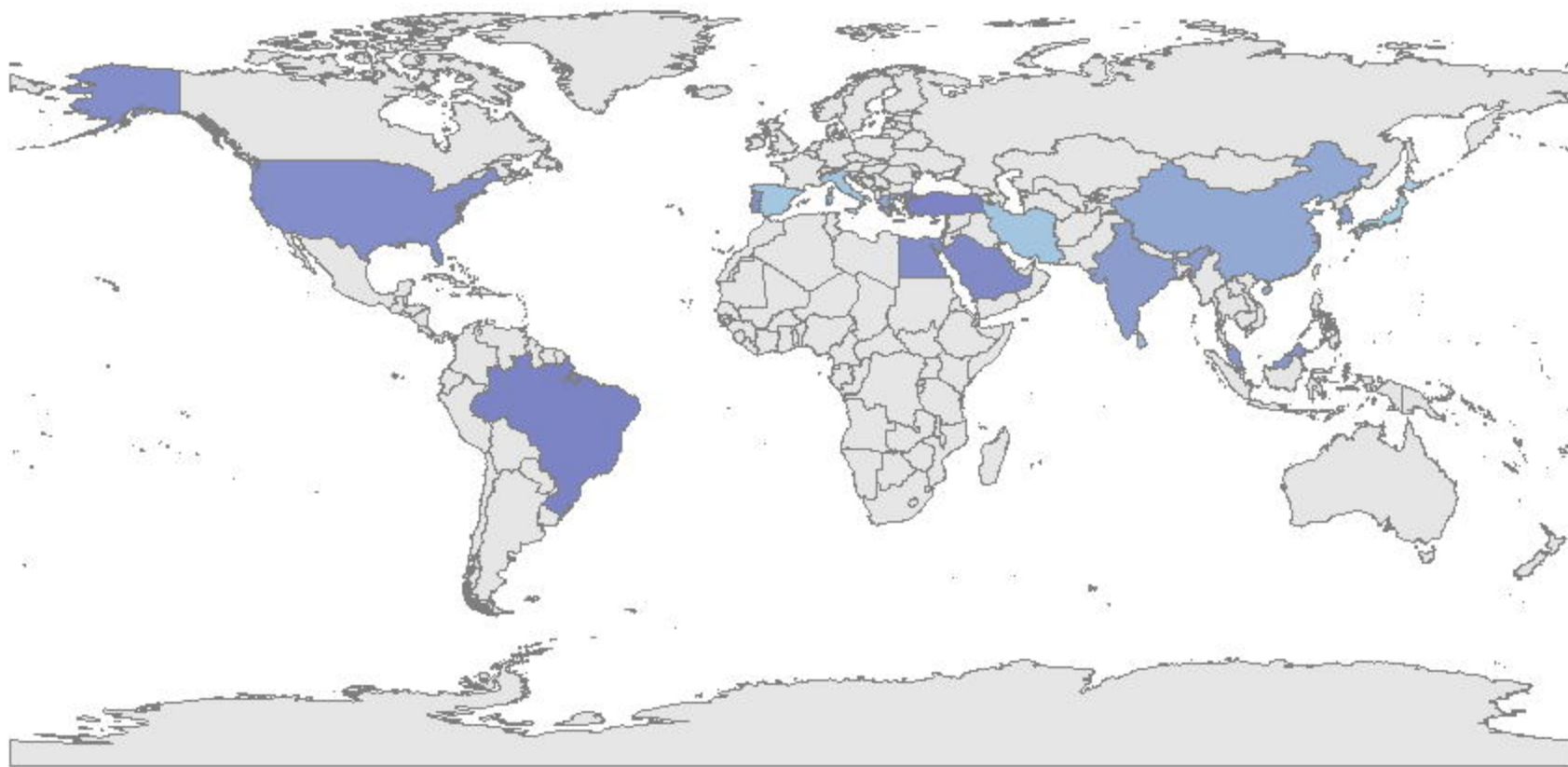
Upper 1st Molars

2000

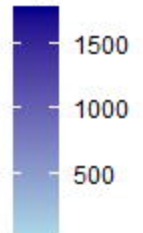
1500

1000

500



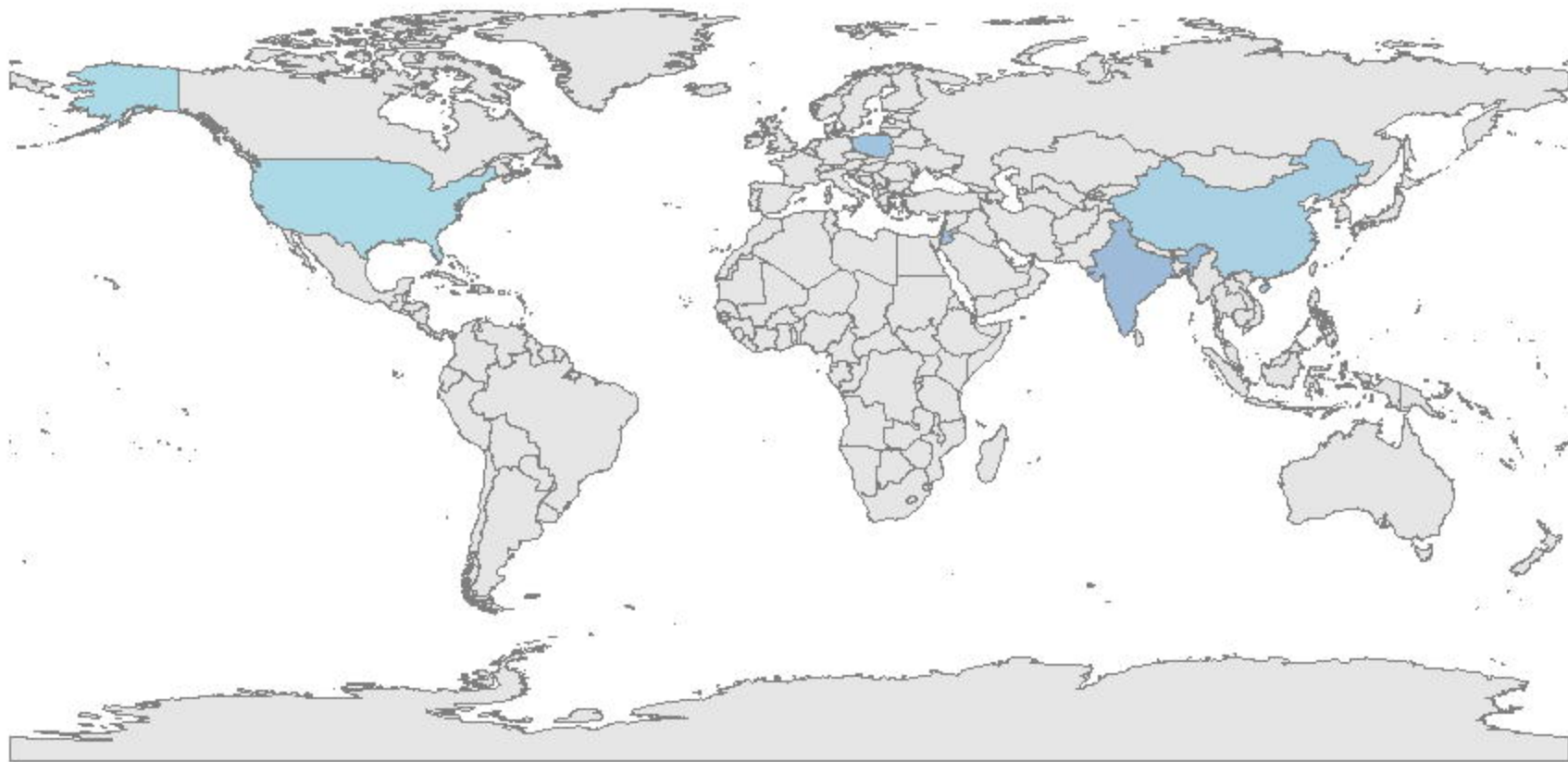
Upper 2nd Molars



1500

1000

500



Upper 3th Molars

