

1 **Original Article**

2

3 *Title page*

4 **Bubbles help in troubles: contrast-enhanced ultrasound (CEUS) as predictor of**
5 **recurrence for TIA/stroke in low-grade internal carotid artery stenosis.**

6 *Francesca D’Auria*^{1*} *Danilo Flavio Santo*^{2*}

7

8 *Authors equally contributed.

9

10 ¹Università degli Studi di Salerno, Cardiovascular Outpatients Clinic, Salerno, Italy.

11 ²Santagostino Medical Center, Cardiovascular Outpatient Clinic, Milano, Italy.

12

13 **Keywords:** CEUS, TIA, stroke, carotid stenosis, ultrasound, Doppler, echography.

14

15

16

17

18

19

20

21

22

23

24

25

26

27

28

29

30 **Correspondence to:** Francesca D’Auria, MD PhD MBA - Cardiovascular Surgeon - Azienda
31 Ospedaliera Universitaria OO.RR. San Giovanni di Dio e Ruggi d’Aragona, Cardiovascular Surgery
32 Department, Via San Leonardo n. 1, 84131 Salerno, Italy. Mobile (+39) 333.724.6468 – email:
33 f.dauria@hotmail.com.

NOTE: This preprint reports new research that has not been certified by peer review and should not be used to guide clinical practice.

34 ***Abstract***

35

36 ***Introduction***

37 Contrast-enhanced ultrasound (CEUS) allows to visualize atherosclerotic plaque neo-vessels which
38 are the hallmark of carotid plaque instability.

39 ***Aim***

40 Aim of our prospective study was to check the correlation between carotid CEUS analysis and the
41 recurrence of TIA/stroke in patients with a previous recent TIA/stroke and neurological impairment
42 congruent with the vascular stenosis.

43 ***Materials and Methods***

44 From November 2021 to May 2023, 62 consecutive patients (mean age 73.8 +/- 12.2, female 51)
45 with a TIA/stroke in the previous 30 days, underwent carotid ultrasound and carotid CEUS in
46 outpatients setting after 10 days from the acute event. Inclusion criteria was one atherosclerotic
47 plaque inside the internal carotid artery, congruent with symptoms, which was causing a stenosis
48 less than 50% (low-grade stenosis). Carotid plaque neovascularization scoring method was: score 0:
49 no visible microbubbles within the plaque (A); score 1: minimal microbubbles confined to
50 periadventitial (B); and score 2: microbubbles present throughout the plaque core (C). During the
51 six-month follow-up, we checked TIA/stroke recurrences. A multivariable logistic regression
52 analysis was performed.

53 ***Results***

54 In our series, 22% of patients have CEUS score 0, 35% CEUS score 1, and 43% CEUS score 2. At
55 six-month follow-up we found 21% TIA/stroke recurrences in CEUS score 2, despite of the
56 ongoing best medical therapy as per guidelines. In Cox regression analysis, CEUS-detected
57 neovascularization was independently associated with TIA/stroke recurrence (hazard ratio, 5.37;
58 95% confidence interval, 1.36–2.31).

59 ***Conclusions***

60 Plaque neovascularization, detected by CEUS, is an independent predictor of TIA/stroke recurrence
61 at six-month follow-up in patients with carotid atherosclerosis despite of low-grade stenosis.

62

63

64

65

66 Abstract word count: 250.

67 **Introduction**

68 International guidelines for carotid artery atherosclerosis surgical and/or endovascular treatment are
69 clear and strictly related to patients' symptoms, the grade of vascular stenosis, and the measured
70 velocity¹⁻². In case of not significant stenosis caused by soft plaque which may determine
71 TIA/stroke and its recurrence due to embolism, surgeons are keen to remove it³. This prudential
72 orientation may cause an overtreatment of patients. In regards of this perceived feeling of surgical
73 overdo and aiming to move towards increasingly precise medicine, we started a prospective
74 observational trial with the purpose to identify possible diagnostic strategy to better orient surgical
75 decision making in this grey zone. To meet our commitment, reducing not only surgical
76 overtreatment but also patients X-ray exposure, we find that Carotid Contrast-Enhanced Ultrasound
77 (CEUS) may be the methods to adopt in our research program and we try to elaborate an image-
78 based surgical decision score system. In fact, CEUS is an imaging technique that involves the use of
79 contrast agents (e.g. saline solution bubble or sulphur hexafluoride solution) to enhance the
80 visualization of blood flow within the carotid arteries using ultrasound technology. During a carotid
81 CEUS procedure, the contrast agent is injected into the bloodstream. It highlights the blood vessels
82 and improves the clarity of the ultrasound images. This allows to more accurately evaluate the
83 structure and function of the carotid arteries, aiding in the diagnosis and management of conditions
84 such as carotid artery disease and stroke risk assessment⁴⁻⁵.

85

86 **Material and Methods**

87 Aim of our prospective study was to check the correlation between carotid CEUS analysis and the
88 recurrence of TIA/stroke in patients with a previous recent TIA/stroke and neurological impairment
89 congruent with the vascular stenosis. From November 2021 to February 2023, 62 consecutive
90 patients (mean age 73.8 +/- 12.2, female 51) with a TIA/stroke in the previous 30 days, underwent
91 carotid ultrasound and carotid CEUS using intravenous 3 ml sulphur hexafluoride solution
92 (SonoVue[®]) in outpatients setting after 10 days from the acute event. The demography of the
93 population is summarized in Table 1. Inclusion criteria was one atherosclerotic plaque inside the
94 internal carotid artery, congruent with symptoms, which was causing a stenosis less than 50% (low-
95 grade stenosis), while exclusions criteria were history of cerebral vascular diseases; history of
96 neurological disease; presence of infections, malignant tumours, cardiopulmonary dysfunction,
97 hepatic dysfunction, kidney failure (any degree), respiratory failure; hyperechoic or uniformly
98 hyperechoic plaque. We arbitrary established a carotid plaque neovascularization scoring method as
99 it is presented in Figure 1. The score 0 means no visible microbubbles within the plaque (A); score

100 1 is when minimal microbubbles are confined to peri adventitial (B); and score 2 consists in
101 microbubbles which are present throughout the plaque core (C). During the six-month we checked
102 TIA/stroke recurrences. No one patient was lost at follow-up. A multivariable logistic regression
103 analysis for ischemic stroke and recurrent TIA was performed checking correlation between
104 TIA/stroke recurrence and gender, age, hypertension, hyperlipidaemia, diabetes (any type), chronic
105 obstructive lung disease (COPD), smoke status (active or previous), obesity, stress, atrial
106 fibrillation, plaque velocity (peak systolic velocity), internal carotid kinking, CEUS score 0, CEUS
107 score 1, and CEUS score 2. Internal ethical committee approved the study and produced a specific
108 informed consent form for patients. These study compliances with ethical standards; each patient
109 signed the specific informed consent (in accordance with the Declaration of Helsinki) to be enrolled
110 in this research and authorized to publish the data in anonymous mode for search purpose only. An
111 additional informed consent for personal data collection, treatment, post processing analysis, and
112 publishing purposes was collected and signed by each patient as per institutional internal ethical
113 committee. No sponsor or external fund were used to conduct this independent search. Statistical
114 analysis was performed using SPSS Statistics 17.0 software. Frequency and percentages (%) were
115 used for categorical variables, whereas mean \pm SD were employed for continuous variables.
116 Continuous variables were compared between three groups using the independent t test. Proportions
117 were compared using the chi-square test. To determine the association between variables and
118 ischemic stroke or recurrent TIA after TIA, a multivariate logistic regression analysis was
119 performed. Receiver operation curve (ROC) was generated to examine the efficacy of the resulting
120 model. The level of significance was set at P value < 0.05.

121

122 **Results**

123 In our series, 22% of patients have a CEUS score 0; 35% of patients have a CEUS score 1; and 43%
124 of patients have a CEUS score 2. At six-month follow-up we found 21% TIA/stroke recurrences in
125 CEUS score 2, despite of the ongoing best medical therapy as per guidelines.

126 The multivariable logistic regression analysis for ischemic stroke and recurrent TIA, shows that
127 CEUS-detected neovascularization was independently associated with TIA/stroke recurrence
128 (hazard ratio, 5.37; 95% confidence interval, 1.36–2.31), while no other considered factors appeared
129 to be significant as predictors of recurrence TIA/stroke, as it is reported in Table 2.

130 The ROC of the multivariate logistic regression analysis model for CEUS 2 score is showed in
131 Figure 2.

132

133 *Discussion*

134 Carotid CEUS is often used as a non-invasive alternative to other imaging techniques such as
135 computed tomography angiography (CTA) and/or magnetic resonance angiography (MRA) for
136 evaluating extra-cranial carotid artery disease⁶. It offers advantages such as real-time imaging, lack
137 of ionizing radiation, and the ability to assess blood flow dynamics. Carotid plaque instability refers
138 to a condition where the atherosclerotic plaque becomes particularly prone to rupture or erosion.
139 When plaque becomes unstable, it can lead to the formation of blood clots (thrombosis) or
140 embolism. These clots or particles can then travel to smaller blood vessels in the brain, leading to
141 blockages and potentially causing a stroke or transient ischemic attack (TIA)³. Several factors
142 contribute to carotid plaque instability, including the composition of the plaque because plaque that
143 contains a large amount of soft, lipid-rich material is more prone to rupture than stable, calcified
144 plaque. Other factors for instability are the plaque size and shape; in fact, large, irregularly shaped
145 plaques are more likely to be unstable compared to smaller, smoother plaques. Underlying medical
146 conditions like hypertension, diabetes, hyperlipidaemia, and smoking can contribute to plaque
147 instability by promoting inflammation and atherosclerosis; finally, hemodynamic factors, due to
148 turbulent blood flow, can increase stress on the plaque, potentially leading to its rupture⁷. All these
149 factors entered in our propensity score and Cox regression analysis, as reported in Table 2, but only
150 CEUS-detected neovascularization was independently associated with TIA/stroke recurrence
151 (hazard ratio, 5.37; 95% confidence interval, 1.36–2.31). Identifying carotid plaque instability is
152 important because it indicates an increased risk of stroke or other cardiovascular events. Imaging
153 techniques such as ultrasound, MRA or CTA can help assess plaque stability by evaluating plaque
154 composition, size, and characteristics⁸. Management of carotid plaque instability typically involves
155 aggressive risk factor modification, including lifestyle changes (such as diet, exercise, and smoking
156 cessation) and medications such as statins, single (or double antiplatelet agents), and/or
157 anticoagulants to stabilize the plaque and reduce the risk of thrombosis and/or embolism. In some
158 cases, surgical intervention, such as carotid endarterectomy or carotid artery stenting, may be
159 considered to remove or stabilize the unstable plaque and restore proper blood flow. Atherosclerotic
160 plaque vascularization, also known as neovascularization, refers to the formation of new blood
161 vessels within or around an atherosclerotic plaque. This process occurs in response to the
162 inadequate blood supply to the growing plaque and the hypoxic conditions within it.
163 Neovascularization is the body's attempt to supply oxygen and nutrients to the hypoxic areas within
164 or around the plaque. However, the newly formed blood vessels are often fragile and leaky, leading
165 to increased inflammation and plaque instability. Neovascularization is commonly observed in

166 advanced atherosclerosis and is associated with vulnerable plaques that have a higher risk of rupture
167 and causing cardiovascular events such as heart attack or stroke. Detecting neovascularization
168 within atherosclerotic plaques can be challenging but can be achieved through advanced imaging
169 techniques such as contrast-enhanced ultrasound, MRA or CTA⁹. These imaging examinations are
170 expensive and time consuming. In case of CTA, it exposes patients to X ray, on the other side,
171 MRA identifying neovascularization within plaques may help in risk assessment and guiding
172 treatment decisions in individuals with advanced atherosclerosis but it is not adoptable for each
173 patient (e.g. claustrophobia, intra-corporeal metal splinters, intra-corporeal device not MR
174 compatible). Transient ischemic attack (TIA) can occur in individuals with low-grade carotid artery
175 stenosis, although the risk is generally lower compared to cases of more severe stenosis. In low-
176 grade carotid artery stenosis, the narrowing of the artery is typically less than 50%¹⁰. It is essential
177 to recognize that even low-grade stenosis can contribute to TIA under certain circumstances, first of
178 all plaque vulnerability¹¹. In our study, presence of minimal microbubbles which are confined to
179 peri adventitial zone and microbubbles throughout the plaque core are predictive risk factors for
180 TIA/stroke. The absence of microbubble was not related to TIA/stroke recurrence and the best
181 medical therapy (statin, antihypertensive drugs, and single antiplatelet) was enough efficient to
182 prevent further neurological episode overtime¹².

183

184 ***Conclusions***

185 Plaque neovascularization, detected by CEUS, is an independent predictor of TIA/stroke recurrence
186 at six-month follow-up in patients with carotid atherosclerosis despite of low-grade stenosis. This
187 finding may guide in the decision between medical therapy and surgical/interventional treatment in
188 the decision making and management of low-grade carotid artery stenosis which is symptomatic for
189 single episode of TIA/stroke. These preliminary data need to be confirmed by large sample of
190 patients and a more longer follow-up period.

191

192 ***References***

- 193 1. Naylor AR, Ricco JB, de Borst GJ, Debus S, de Haro J, Halliday A, Hamilton G, Kakisis J,
194 Kakkos S, Lepidi S, Markus HS, McCabe DJ, Roy J, Sillesen H, van den Berg JC, Vermassen
195 F, Esvs Guidelines Committee, Kolh P, Chakfe N, Hinchliffe RJ, Koncar I, Lindholt JS, Vega
196 de Ceniga M, Verzini F, Esvs Guideline Reviewers, Archie J, Bellmunt S, Chaudhuri A,
197 Koelemay M, Lindahl AK, Padberg F, Venermo M. Editor's Choice - Management of
198 Atherosclerotic Carotid and Vertebral Artery Disease: 2017 Clinical Practice Guidelines of the

- 199 European Society for Vascular Surgery (ESVS). *Eur J Vasc Endovasc Surg*. 2018 Jan;55(1):3-
200 81. doi: 10.1016/j.ejvs.2017.06.021. Epub 2017 Aug 26.
- 201 2. Zeebregts CJ, Paraskevas KI. The New 2023 European Society for Vascular Surgery (ESVS)
202 Carotid Guidelines - The European Perspective. *Eur J Vasc Endovasc Surg*. 2023 Jan;65(1):3-4.
203 doi: 10.1016/j.ejvs.2022.04.033. Epub 2022 May 6. PMID: 35533843
- 204 3. Bonati LH, Kakkos S, Berkefeld J, de Borst GJ, Bulbulia R, Halliday A, van Herzelee I, Koncar
205 I, McCabe DJ, Lal A, Ricco JB, Ringleb P, Taylor-Rowan M, Eckstein HH. European Stroke
206 Organisation guideline on endarterectomy and stenting for carotid artery stenosis. *Eur Stroke J*.
207 2021 Jun;6(2):I-XLVII. doi: 10.1177/23969873211012121. Epub 2021 May 11. PMID:
208 34414302
- 209 4. Brinjikji W, Huston J 3rd, Rabinstein AA, Kim GM, Lerman A, Lanzino G. *J Neurosurg*.
210 Contemporary carotid imaging: from degree of stenosis to plaque vulnerability. 2016
211 Jan;124(1):27-42. doi: 10.3171/2015.1.JNS142452. Epub 2015 Jul 31. PMID: 26230478
212 Review.
- 213 5. Li Z, Xu X, Ren L, Shao Y, Luo S, Chen S, Guan X. Prospective Study About the Relationship
214 Between CEUS of Carotid Intraplaque Neovascularization and Ischemic Stroke in TIA Patients.
215 *Front Pharmacol*. 2019 Jun 21;10:672. doi: 10.3389/fphar.2019.00672. eCollection 2019.
216 PMID: 31281254.
- 217 6. Zhu C, Li Z, Ju Y, Zhao X. Detection of Carotid Webs by CT Angiography, High-Resolution
218 MRI, and Ultrasound. *J Neuroimaging*. 2021 Jan;31(1):71-75. doi: 10.1111/jon.12784. Epub
219 2020 Sep 28. PMID: 32986890.
- 220 7. Ignatyev IM, Gafurov MR, Krivosheeva NV. Criteria for Carotid Atherosclerotic Plaque
221 Instability. *Ann Vasc Surg*. 2021 Apr;72:340-349. doi: 10.1016/j.avsg.2020.08.145. Epub 2020
222 Sep 11. PMID: 32927044.
- 223 8. Rotzinger DC, Qanadli SD, Fahrni G. Imaging the Vulnerable Carotid Plaque with CT: Caveats
224 to Consider. Comment on Wang et al. Identification Markers of Carotid Vulnerable Plaques: An
225 Update. *Biomolecules* 2022, 12, 1192. *Biomolecules*. 2023 Feb 20;13(2):397. doi:
226 10.3390/biom13020397. PMID: 36830766.
- 227 9. Huang R, Abdelmoneim SS, Ball CA, Nhola LF, Farrell AM, Feinstein S, Mulvagh SL.
228 Detection of Carotid Atherosclerotic Plaque Neovascularization Using Contrast Enhanced
229 Ultrasound: A Systematic Review and Meta-Analysis of Diagnostic Accuracy Studies. *J Am
230 Soc Echocardiogr*. 2016 Jun;29(6):491-502. doi: 10.1016/j.echo.2016.02.012. Epub 2016 Mar
231 30. PMID: 27038513 Review.

- 232 10. Li F, Gu SY, Zhang LN, Chen J, Yao MH, Wu TT, Ma J, Jia CX, Wu R. Carotid plaque score
233 and ischemic stroke risk stratification through a combination of B-mode and contrast-enhanced
234 ultrasound in patients with low and intermediate carotid stenosis. *Front Cardiovasc Med*. 2023
235 Dec 18;10:1209855. doi: 10.3389/fcvm.2023.1209855. eCollection 2023. PMID: 38179504.
- 236 11. Rerkasem A, Orrapin S, Howard DP, Rerkasem K. Carotid endarterectomy for symptomatic
237 carotid stenosis. *Cochrane Database Syst Rev*. 2020 Sep 12;9(9):CD001081. doi:
238 10.1002/14651858.CD001081.pub4. PMID: 32918282
- 239 12. Magnoni M, Ammirati E, Moroni F, Norata GD, Camici PG. Impact of Cardiovascular Risk
240 Factors and Pharmacologic Treatments on Carotid Intraplaque Neovascularization Detected by
241 Contrast-Enhanced Ultrasound. *J Am Soc Echocardiogr*. 2019 Jan;32(1):113-120.e6. doi:
242 10.1016/j.echo.2018.09.001. Epub 2018 Oct 16. PMID: 30340893.

243

244

245

246

247

248

249

250

251

252

253

254

255

256

257

258

259

260

261

262

263

264 Main text word count: 2110.

265 **Tables**

<i>Variable</i>	<i>N (%) / Mean ± SD</i>	<i>Variable</i>	<i>N (%) / Mean ± SD</i>
Female	51 (82)	Antiplatelet therapy	60 (97)
Male	11 (18)	Antihypertensive therapy	62 (97)
Age	73.8 +/- 12.2	Statin	58 (94)
Hypertension	60 (97)	New Oral Anticoagulant	22 (35)
Hyperlipidaemia	58 (94)	Atrial fibrillation	8 (13)
Diabetes (any type)	24 (39)	Coronary artery disease	2 (3)
COPD	21 (34)	Peripheral artery disease	14 (23)
Active smoker	41 (66)	Internal carotid artery stenosis (%)	52 +/- 10
Previous smoker	21 (34)	Peak systolic velocity (cm/s)	162 +/- 104
Stress	32 (52)	End diastolic velocity (cm/s)	62 +/- 12

266 Table 1. Patients' demography.

<i>Variable</i>	<i>P value</i>	<i>Hazard Ratio</i>	<i>Confidence Interval 95%</i>
Female	0.21	0.07	0.67 – 0.87
Male	0.11	0.04	0.57 – 0.98
Age	0.89	0.02	0.76 – 0.89
Hypertension	0.98	0.32	0.57 – 0.98
Hyperlipidaemia	0.92	1.2	0.26 – 0.29
Diabetes (any type)	0.76	1.8	0.76 – 0.89
COPD	0.09	0.5	0.06 – 0.89
Active smoker	0.78	0.7	0.23 – 9.87
Previous smoker	0.43	0.3	0.57 - 12.48
Obesity	0.08	1.3	0.05 - 11.28
Stress	0.68	0.2	0.26 – 0.98

Atrial fibrillation	0.89	1.8	0.76 – 0.89
Peak systolic velocity	0.25	1.98	0.22 – 0.34
Vessel kinking	0.82	1.72	0.52 - 9.48
CEUS score 0	0.23	1.02	0.21 – 1.28
CEUS score 1	0.08	1.32	1.28-1.98
CEUS score 2	0.002	5.37	1.36–2.31

267 Table 2. Multivariable logistic regression analysis for ischemic stroke/TIA recurrence.

268

269

270

271

272

273

274

275

276

277

278

279

280

281

282

283

284

285

286

287

288

289

290

291

292

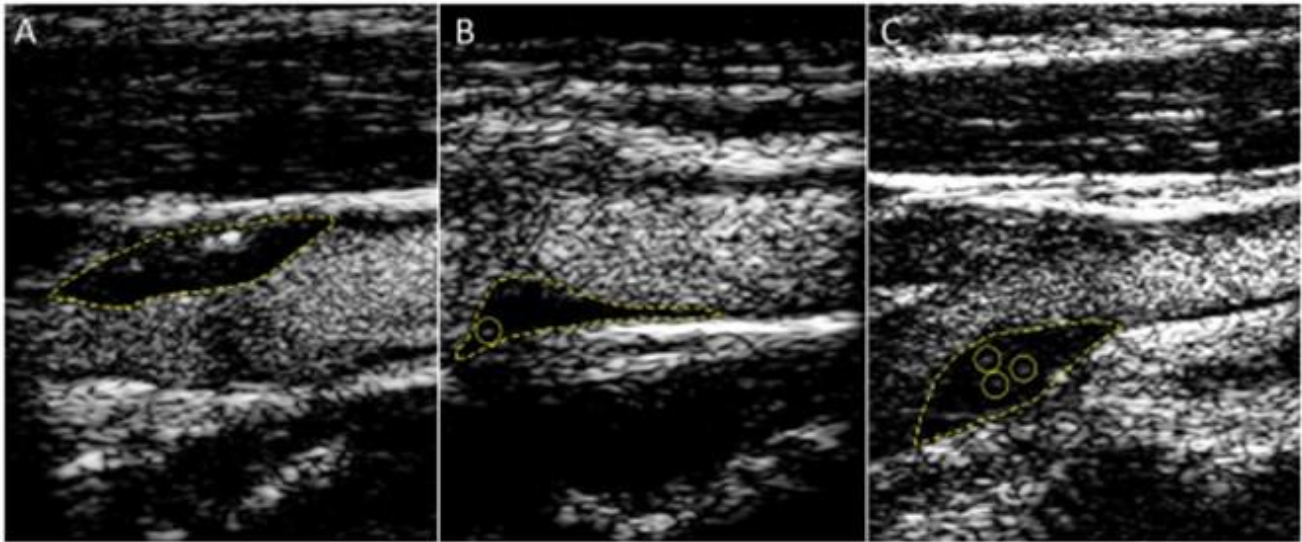
293

294 **Figure legend**

295 Figure 1. Carotid plaque neovascularization scoring: score 0: no visible microbubbles within the
296 plaque (A); score 1: minimal microbubbles confined to periadventitial (B); and score 2:
297 microbubbles present throughout the plaque core (C).

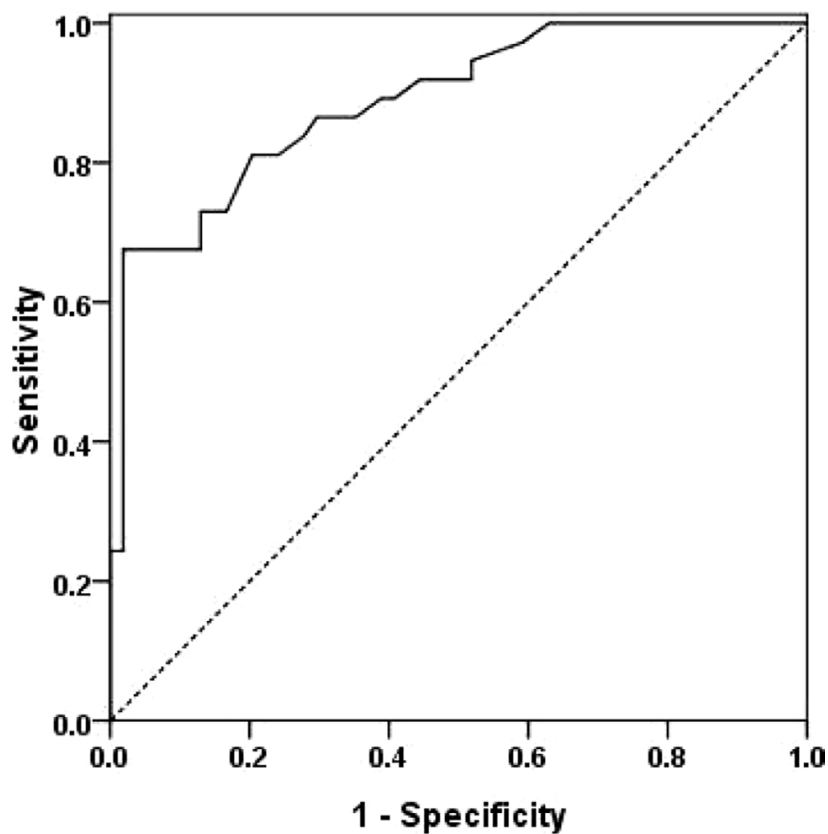
298 Figure 2. Receiver operation curve (ROC) of the multivariate logistic regression analysis model
299 (CEUS 1, CEUS 2 score).

300



301

302 Figure 1. Carotid plaque neovascularization scoring: score 0: no visible microbubbles within the
303 plaque (A); score 1: minimal microbubbles confined to periadventitial (B); and score 2:
304 microbubbles present throughout the plaque core (C).



305

306 Figure 2. Receiver operation curve (ROC) of the multivariate logistic regression analysis model for
307 CEUS2 score.

308

309 *Financial support and sponsorship*

310 None

311

312 *Conflicts of interest*

313 None

