

1 **Differential inclusion of *NEB* exons 143 and 144 provides insight into *NEB*-related**
2 **myopathy variant interpretation and disease manifestation**

3
4 Sarah Silverstein^{1,2,3}, Rotem Orbach^{1#}, Safoora Syeda^{1#}, A Reghan Foley¹, Svetlana
5 Gorokhova^{4,5}, Katherine G. Meilleur^{1,6}, Meganne E. Leach^{1,7}, Prech Uapinyoying^{1,8}, Katherine R
6 Chao⁹, Sandra Donkervoort¹, Carsten G. Bönnemann^{1*}

7
8 **Abstract (250 words)**

9 Biallelic pathogenic variants in the gene encoding nebulin (*NEB*) are a known cause of
10 congenital myopathy. We present two individuals with congenital myopathy and compound
11 heterozygous variants (NM_001271208.2: c.2079C>A; p.(Cys693Ter) and c.21522+3A>G) in
12 *NEB*. Transcriptomic sequencing on patient muscle revealed that the extended splice variant
13 c.21522+3A>G causes exon 144 skipping. Nebulin isoforms containing exon 144 are known to
14 be mutually exclusive with isoforms containing exon 143, and these isoforms are differentially
15 expressed during development and in adult skeletal muscles. Patients MRIs were compared to
16 the known pattern of relative abundance of these two isoforms in muscle. We propose that the

¹ Neuromuscular and Neurogenetic Disorders of Childhood Section, National Institute of Neurological Disorders and Stroke, National Institutes of Health, Bethesda, Maryland 20892, USA

² Rutgers New Jersey School of Medicine, 185 S Orange Ave Newark NJ 07103 USA

³ Undiagnosed Diseases Program, National Human Genome Research Institute, National Institute of Health, Bethesda, Maryland 20892, USA

⁴ Aix Marseille Univ, INSERM, MMG, U 1251, Marseille, France

⁵ Department of Medical Genetics, Timone Children's Hospital, APHM, Marseille, France

⁶ Biogen, Boston MA

⁷ Division of Neurology, Oregon Health and Science University, 3181 SW Sam Jackson Park Rd, Portland, OR

⁸ Research Center for Genetic Medicine, Children's National Research Institute, Children's National Medical Center, Washington DC 20010

⁹ Broad Institute of MIT and Harvard, 415 Main St. Cambridge MA 02142

These authors contributed equally to this work

* Corresponding author: carsten.bonnemann@nih.gov

17 pattern of muscle involvement in these patients better fits the distribution of exon 144-containing
18 isoforms in muscle than with previously published MRI findings in *NEB*-related disease due to
19 other variants. To our knowledge this is the first report hypothesizing disease pathogenesis
20 through the alteration of isoform distributions in muscle.

21

22 **Introduction**

23 Nemaline myopathies are a clinically heterogenous group of skeletal muscle diseases
24 ranging from severe congenital-onset disease to milder childhood-onset disease. Biallelic
25 pathogenic variants in *NEB* (OMIM 161650), a gene encoding nebulin, are a known cause for
26 nemaline myopathy (OMIM 256030), belonging to a histologically defined subgroup of
27 congenital myopathies (Lehtokari et al., 2014). Nebulin is a giant protein (600-900 kDa) that is
28 an important part of the sarcomeric thin filament and is involved in muscle contraction,
29 sarcomere maintenance and homeostasis, although the precise mechanisms of its various
30 functions are still under investigation (Yuen & Ottenheijm, 2020). Nemaline myopathy usually
31 presents congenitally with axial and proximal muscle weakness, prominent facial and bulbar
32 weakness, and respiratory muscle weakness (Lehtokari et al., 2014). Milder phenotypes of
33 nemaline myopathy with onset during childhood or adulthood presenting with distal muscle
34 weakness have also been reported (Lehtokari et al., 2014; Sewry et al., 2019; Wallgren-
35 Pettersson & Laing, 2000). Pathogenic *NEB* variants are a major cause of nemaline myopathy,
36 however, given *NEB*'s 183 exon expanse, and the complexity of its resulting isoforms, the
37 identification of variants is challenging, and the functional impact of *NEB* variants is difficult to
38 interpret.

39 Alternative splicing creates diversity of function from an otherwise limited number of
40 genes. Differential splicing programs are well-established within skeletal muscle for various
41 developmental states and between type I and type II myofibers; perturbations to these alternative
42 isoform programs are known to drive muscle disease (Nakka et al., 2018, Trapnell et al., 2010,
43 Matyushenko et al., 2020; Nikonova et al., 2020; Robaszkiewicz et al., 2020). Moreover,
44 alternative splicing characteristics between mature muscles that are not associated with fiber type
45 composition or development have recently been explored for titin encoding gene (*TTN*), although
46 disruptions in the relative abundance of these isoforms have not yet been linked to disease
47 (Freiburg et al., 2000; Nikonova et al., 2020; Savarese et al., 2018). .

48 *NEB* (NM_001271208.2) is a complex transcriptional unit and is known to include
49 alternatively spliced exons (143 and 144) that are mutually exclusive. Exon 143 is thought to be
50 prominently expressed in the fetal period, while exon 144 is shown to be expressed with
51 increasing age in both mice and humans (Donner et al., 2004, 2006; Laitila et al., 2012; Lam et
52 al., 2018; Uapinyoying et al., 2020). While certain adult muscles ultimately express an equal
53 ratio of both exons (e.g., vastus intermedius and medialis) others express higher amounts of exon
54 143 compared to exon 144 (e.g. tibialis anterior), and some adult muscles exclusively express
55 exon 144 (e.g. gastrocnemius, rectus femoris) (Laitila et al., 2012). As such, a role for the
56 specific isoforms in myogenesis and fiber typing is postulated (Lehtokari et al., 2014), however
57 the impact on disease mechanism and disease manifestation in humans has not yet been
58 explored.

59 RNA sequencing has emerged as a promising tool for understanding the impact of
60 specific variants on transcription and splice regulation, thus aiding in assessing pathogenicity.
61 Here we report detailed phenotypic data on two siblings affected with congenital onset muscle

62 weakness in whom we identified compound heterozygous pathogenic variants in *NEB*
63 (NM_001271208.2: c.2079C>A; p.(Cys693Ter) and c.21522+3A>G). Aberrant splicing of the
64 *NEB* intronic variant was confirmed by muscle RNA sequencing. We also explore how the
65 differential expression of *NEB* isoforms may be linked to muscle function in normal and diseased
66 muscle. Further, we propose that differential isoform expression across muscle groups may
67 explain disease-specific patterns of muscle involvement in skeletal muscle disease.

68

69 **Subjects and Methods:**

70 *Patient recruitment and sample collection*

71 Patients were referred by their neurologist or geneticist. Written informed consent and
72 age-appropriate assent for study procedures were obtained by a qualified investigator (protocol
73 12-N-0095 approved by the National Institute of Neurological Disorders and Stroke, National
74 Institutes of Health Institutional Review Board (IRB)). Medical history was obtained and clinical
75 evaluations, including muscle magnetic resonance imaging (MRI) and muscle biopsy, were
76 performed as part of the standard diagnostic evaluation. Blood samples for research-based testing
77 were obtained using standard procedures.

78

79 *Genetic testing*

80 Quartet exome sequencing was performed on DNA isolated from whole blood. Exome
81 sequencing and data processing were performed by the Genomics Platform at the Broad Institute
82 of MIT and Harvard with an Illumina exome capture (38 Mb target) and sequenced (150 bp
83 paired reads) to cover >90% of targets at 20x and a mean target coverage of >100x. Exome
84 sequencing data was processed through a pipeline based on Picard and mapping done using the

85 BWA aligner to the human genome build 38. Variants were called using Genome Analysis
86 Toolkit (GATK, HaplotypeCaller package version 3.4).

87

88 Human whole transcriptome sequencing was performed by the GenomicsPlatform at the
89 Broad Institute of MIT and Harvard on RNA isolated from patient 1 muscle (biopsy taken in
90 early childhood from biceps muscle). The transcriptome product combines poly(A)-selection of
91 mRNA transcripts with a strand-specific cDNA library preparation, with a mean insert size of
92 550 bp. Libraries were sequenced on the HiSeq 2500 platform to a minimum depth of 50 million
93 reads. ERCC RNA controls were included for all samples, allowing additional control of
94 variability between samples. Raw sequencing data was aligned using the GTEX pipeline version
95 10 (<https://github.com/broadinstitute/gtex-pipeline/tree/master/rnaseq>).

96 Confirmation of variants discovered in patients and segregation testing in the parents and
97 unaffected sibling was performed by Sanger sequencing.

98

99 *Splice Variant Analysis*

100 Patient 1 BAM file was analyzed using the Integrative Genomics Viewer (IGV)
101 (Thorvaldsdottir et al., 2013). Considering the known variability of exon 143 versus 144
102 inclusions depending on age and muscle biopsy site, we carefully searched for appropriate
103 controls for Patient 1. Unfortunately, controls matching both age and biopsy site were
104 unavailable. We could not use the GTEx muscle samples as controls, as the youngest sample in
105 GTEx is an 18-year-old (yo) individual (with most of the samples 65+), and the muscle samples
106 were from the gastrocnemius muscle or designated as from “below the patella.” Thus, controls
107 were selected from our own disease cohort excluding any sample with known *NEB*-related

108 disease. The only available RNA-seq samples from biceps tissue were from adults. All RNA-seq
109 samples in our cohort with biopsies taken at early childhood are from the quadriceps muscle. We
110 therefore selected two age-matched control samples and two controls matching the biopsy site.
111 Sashimi plots were generated with ggsashimi (Garrido-Martín et al., 2018).

112

113 *Transcript Usage*

114 The MANE select and MANE plus Clinical transcripts for *NEB* are NM_001164508.2
115 and NM_001164507.2, respectively. Although the MANE select transcript is used to report *NEB*
116 variants in ClinVar and gnomAD, we utilized the alternative transcript NM_001271208.2 in this
117 study. The MANE select and MANE plus Clinical transcripts each contains only one of the two
118 mutually exclusive exons 143 and 144 and are thus both labeled as “exon 143” in their respective
119 transcripts. To preserve clarity as we discuss both exons, we use the non-biological
120 NM_001271208.2 transcript, which contains both exons 143 and 144.

121

122 *Muscle MRI imaging and relative exon expression analysis*

123 Muscle MRI was performed using conventional T1-weighted spin echo and short tau
124 inversion recovery (STIR) of the lower extremities. Multiple sequences including axial STIR and
125 T1 images were obtained at 3 Tesla without vascular contrast administration.

126 T1 axial images of proximal and distal lower extremities were reviewed in detail to note
127 pattern of muscle involvement and fibroadipose transformation (Lamminen, 2014; Ortolan et al.,
128 2015) to include a qualitative Modified Mercuri Scoring (MMS) of the thigh and lower legs as
129 previously done by Perry and his colleagues (MMS: 0= Normal appearance; 1= Early fat
130 infiltration, scattered areas of T1 high signal; 2= Numerous discrete areas of T1 high signal with

131 beginning confluence <30% of the volume; 3= Fat infiltration 30–60% of volume; 4= Fat
132 infiltration >60% of the volume; 5= End stage, no residual muscle tissue (Perry et al., 2023). P1
133 MMS and P2 MMS (calculated on his muscle MRI from teenage years) were averaged per
134 muscle to reflect detailed exon 144 skipping genotype pattern. MRI of age-matched Control *NEB*
135 patients (ie *NEB* patients with variants other than *NEB* c.21522+3A>G) were selected from *NEB*
136 patients reported by Perry et al 2023, and mean MMS was calculated from reported scores
137 (supplemental table 3) (Perry et al., 2023).

138 Current literature was reviewed to identify the reported relative expression of exon 143
139 and 144 across lower limb muscles in adult humans and mice (Supplemental Table 2). The
140 collected data was subsequently binned into four qualitative categories per muscle: 1) Exon 144
141 only, 2) Exon 144 was expressed more than Exon 143, 3) Exon 143 was expressed equally with
142 Exon 144 and 4) majority Exon 143. Where human data conflicted with mouse data, human data
143 was used to make Figure D6. If no human data was available and a conflict found between
144 mouse datasets, the more quantitative dataset from Uapinyoying et al 2020 was used to make
145 Figure D6. The muscle MRI grading for each muscle was then compared to the relative
146 expression of exons 143 and 144.

147 **Results**

148 *Clinical Presentation.*

149 Patient (P1) is a young adult male of American and Asian ancestry. He was born to non-
150 consanguineous parents at 42 weeks gestational age via Cesarean section. Pregnancy was
151 complicated by decreased fetal movements. Early gross motor milestones were attained on time,
152 achieving independent ambulation at the upper limit of normal. Early walking gait was described
153 as wide-based, waddling and with inward rotation of the knees. During childhood he was noted

154 to have facial weakness, while fine motor, language and cognitive development were normal. On
155 physical exam at age in early childhood, he had a high-arched, narrow palate, facial weakness,
156 atrophic gluteal muscles, proximal more than distal muscle weakness and a positive Gowers’
157 maneuver. Gait was described as wide-based and waddling with exaggerated effort to perform
158 knee extension. Additionally, he was noted to have hyperlaxity in joints of the hands and
159 contractures of the Achilles tendons. Creatine Kinase (CK) levels were reportedly normal
160 throughout childhood. Electromyography studies were consistent with non-irritable myopathy. A
161 muscle biopsy performed in early childhood showed non-specific myopathic changes without
162 nemaline rods on histology (Figure A). Electron microscopy was not available. Echocardiogram
163 and pulmonary function studies were within normal limits. Serial examinations in late childhood
164 and teenage years demonstrated slightly improved muscle strength throughout (Table 1, available
165 on request). At examination as a young adult, the patient reports worsening muscle weakness and
166 stamina along with weight gain, difficulty chewing, frequent falls, myopia, hypertension, and
167 borderline conductive hearing loss secondary to multiple episodes of otitis media. The
168 hypertension and worsening muscle weakness may be the result of significant weight gain.

169 Patient (P2) is a teenage male. Pregnancy was complicated by decreased fetal movement
170 in one of the twins. He was born at 38 weeks gestational age via C-section due to transverse
171 positioning. There were no concerns at birth, and early milestones were normal. At early
172 childhood, P2’s parents noted that he had difficulty climbing stairs. On physical examination in
173 childhood, he had a transverse smile, atrophic gluteal muscles, proximal muscle weakness and an
174 exaggerated Trendelenburg gait with arm pumping. He had a negative Gowers’ maneuver
175 (Figure A). CK levels were normal. Examination at age late childhood showed slightly improved
176 muscle strength. Electromyography studies performed revealed findings suggestive of a non-

177 irritable myopathy. As a teenager, P2 reported a regular regimen of weight training and stable to
178 improved strength, although noted recent difficulty with chewing tough foods. Echocardiogram
179 and pulmonary function testing have been normal (Table 1, available on request).

180

181 *Exome Sequencing identified biallelic variants in NEB.*

182 Quartet exome sequencing (ES) was performed, which identified compound
183 heterozygous variants in *NEB* (NM_001271208.2) in both individuals. The maternally inherited
184 variant (c.2079C>A; p.Cys693Ter) results in an early stop codon in exon 22 and is predicted to
185 induce nonsense mediated decay. This variant is reported in 3 individuals in gnomAD exomes
186 v4.0.0 with a Grpmax filtering allele frequency (European, non-Finnish) of 0.000002280%
187 (Karczewski et al., 2022; Whiffin et al., 2017). The paternally inherited variant (c.21522+3A>G;
188 rs148950085) is adjacent to exon 144. The c.21522+3A>G variant has conflicting interpretations
189 of pathogenicity in ClinVar based on 6 submissions, 4 pathogenic and two Uncertain
190 Significance (Variant ID 430110) and is predicted to result in donor loss via in-silico tools
191 (CADD prediction v1.6 24 (Rentzsch et al., 2021); spliceAI 0.71, (Jaganathan et al., 2019)). This
192 variant has also been reported as pathogenic in several recently published cohorts when in trans
193 with a missense or truncating *NEB* variant, but never in homozygosity (Supplemental Table 1,
194 available on request) (Lee et al., 2017; Wang et al., 2020; Wen et al., 2020). This variant has a
195 Grpmax filtering allele frequency (East Asian) of 0.001567% in gnomAD exomes and genomes
196 v4.0.0 and one homozygote is reported. The presence of one homozygote in gnomAD does not
197 exclude pathogenicity for two reasons. Firstly, the age of this individual is unknown and biallelic
198 *NEB* variants have been reported to cause disease late in life, and secondly, hypomorphic splice
199 variants are reported to cause disease only in trans with a pathogenic variant but not when found

200 in a homozygous state (Zernant et al., 2017). P1 and P2 report paternal Asian ancestry, and it has
201 been suggested that c.21522+3A>G originates from a common Asian ancestor (Lee et al., 2017;
202 Wang et al., 2020; Wen et al., 2020). While the highest population frequency for this variant is
203 found in East Asians, it is also reported in the gnomAD exomes and genomes v4.0.0 database in
204 the South Asian population with a frequency of 0.0002624 (22/ 22766 alleles) to the exclusion of
205 any additional populations (Karczewski et al., 2022; Whiffin et al., 2017). In summary, this
206 suggests that P1 and P2 share compound heterozygous variants which cause nemaline myopathy,
207 one variant which is only reported in East and South Asian populations and the mechanism for
208 disease remains unclear. No other candidate variants were identified by exome sequencing.

209

210 *RNA sequencing confirms NEB c.21522+3A>G causes impaired splicing.*

211 To evaluate the effect of the biallelic *NEB* variants identified in ES, whole transcriptomic
212 sequencing on P1 muscle was performed. At the location of the c.2079C>A; p.Cys693Ter
213 variant, DNA sequencing shows a balanced (50:50) heterozygous C>A variant while the RNA
214 sequencing shows allelic imbalance in favor of the wild-type allele (83% G to 17% T,
215 Supplemental Figure 1), suggestive of nonsense mediated decay of the maternal allele transcript
216 with the c.2079C>A; p.Cys693Ter variant. Additionally, exon coverage throughout the *NEB*
217 gene seems to be reduced compared to control RNA-seq samples, although this cannot be
218 assessed with certainty without quantification and normalization for library size. At the location
219 of the intronic c.21522+3A>G variant, almost complete exclusion of exon 144 is seen in the
220 patient sample compared to age-matched controls (Figure B and Supplemental Figure 3).
221 Although no age- and biopsy-matched samples are available for comparison, RNA-seq data from
222 adult biceps similarly shows that exon 144 is excluded in P1 compared with controls

223 (Supplemental Figure 2). As no relative expression data is reported for biceps (Donner et al.,
224 2004, 2006; Laitila et al., 2012; Lam et al., 2018; Uapinyoying et al., 2020), it is possible that in
225 biceps exon 144 is not included normally. In addition, a developmental difference cannot be
226 excluded as our patient was early childhood at the time of biopsy, whereas the controls were
227 adults. However, there is one report of an 18-year-old female patient with a different base pair
228 change (A>C instead of A>G) at the same site as our variant, causing cryptic donor activation
229 leading to exon 144 extension (Cummings et al., 2017). This was assessed in RNA-seq data
230 obtained from either vastus lateralis or biceps muscle (Cummings et al., 2017). Notably, we
231 observe six novel isoform reads containing exon 144 extension due to the same cryptic donor
232 activation as reported in the A>C variant in our patient sample but not in controls (Supplemental
233 Figure 2 and 3). While the region between exons 142-145 contain multiple splice junctions, the
234 exon 144 exclusion and six reads supporting cryptic donor activation are the only differences in
235 the patient sample compared with controls (Supplemental Figure 2 and 3). Irrespective if the
236 c.21522+3A>G variant causes intron retention or cryptic donor activation with exon extension,
237 we expect that the variant in P1 causes complete loss of the exon 144 containing protein isoform
238 due to a PTC after 7 amino acids, leaving only the exon 143 isoform available for translation
239 (Figure C).

240

241 *Muscle MRI imaging have a distinct pattern of involvement.*

242 Muscle MRI of P1 (as a teenager) and P2 (as a teenager) reveals striking proximal
243 involvement of the vasti muscles, adductor magnus, biceps femoris and semimembranosus
244 (mMMS: 2.5-5) (Figure D, Supplemental Table 3). In contrast, age-matched control NEB
245 patients are relatively spared for the same muscle groups (mMMS: 0.75-1.0) (Perry et al., 2023).

246 The rectus femoris, semitendinosus, sartorius, gracilis and adductor longus are relatively spared
247 for both our patients and controls (mMMS P1/P2: 0-2; mMMS control: 0.5-0.75) (Figure D,
248 Supplemental Table 3) (Perry et al., 2023). However, it is worth noting that P1 rectus femoris
249 muscle was extensively replaced by fibroadipose tissue and rated as MMS 4, while P2 rectus
250 femoris muscle was spared and rated as 0 (Supplemental Table 3).

251 Distally, P1 and P2 have striking involvement of the soleus and lateral gastrocnemius
252 muscles (mMMS: 4-4.25), with sparing of the anterior compartment (mMMS: 0).

253 Comparatively, control NEB patients presented with mild involvement of the soleus and lateral
254 gastrocnemius (mMMS: 1.25-2) and the anterior compartment (mMMS: 1.5) (Perry et al., 2023).

255 The medial gastrocnemius and tibialis posterior show mild involvement for both our patients and
256 control(s?) (mMMS P1/P2: 1.5-2.0; mMMS control: 0.75-1.0) (Figure D, supplemental table 3)
257 (Perry et al., 2023).

258

259 **Discussion**

260

261 Rare congenital myopathies and dystrophies frequently pose diagnostic challenges
262 considering that several important disease-causing genes expressed in skeletal muscle are
263 exceedingly long and have complex splicing patterns. Here we present two affected individuals
264 each carrying a c.21522+3A>G variant near the mutually exclusive exon 144 of *NEB*
265 (NM_001271208.2) in trans with a truncating *NEB* variant. A literature review on mutually
266 exclusive exons 143 and 144 suggests that once adulthood is reached, the relative abundance of
267 these two isoforms vary amongst muscles. Many of these muscles exhibit a shift from
268 predominant exon 143 expression early in development to exon 144 with age, although most
269 muscles express a mixture of both isoforms (Figure D6, Supplemental Table 2) (Donner et al.,

270 2004, 2006; Laitila et al., 2012; Lam et al., 2018; Uapinyoying et al., 2020). However, relative
271 abundance was analyzed mostly via qPCR data in mouse tissue, with only a small amount of
272 human muscle contributing, and excepting one study provided no correlation between mRNA
273 abundance and protein levels (Donner et al., 2004, 2006; Laitila et al., 2012; Lam et al., 2018;
274 Uapinyoying et al., 2020). More work to systematically establish the precise distributions in
275 human muscle and elucidate the functional roles needs to be done to aid interpretation of variant
276 pathogenicity in these mutually exclusive exons.

277 The c.21522+3A>G splice variant found in our patients has recently been reported in
278 patients with nemaline myopathy (Lee et al., 2017; Wang et al., 2020; Wen et al., 2020).
279 Previously, RT-PCR performed on patient muscle cDNA to interpret the functional impact of the
280 c.21522+3A>G variant suggested the generation of a splice isoform that excluded both exons
281 143 and 144, splicing exon 142 directly to exon 145 (Wang et al., 2020). With RNA sequencing,
282 however, a more complex story emerges as both patient and controls show a few reads splicing
283 exons 142 to 145, suggesting that this is a rare but normal isoform (Supplemental Figure 2 and
284 3). This is corroborated in GTEx muscle samples (Supplemental Figure 4). Instead, we observe
285 loss of exon 144 and 6 unique reads mapping to a cryptic donor site, suggestive of exon 144
286 extension leading to nonsense mediated decay (Figure B and supplemental figures 2 and 3).
287 While we cannot be certain of the precise splice isoform generated due to low read depth at the
288 cryptic donor site in our patient sample, we can be confident that the variant causes loss of exon
289 144 isoforms when in trans with a nonsense variant (Figure C: Splicing Diagram). Utilizing
290 transcriptomic sequencing for analysis of this complex splice region provided insight into
291 pathogenesis unobtainable through methods like RT-PCR.

292 Considering the developmental roles of exons 143 and 144 reported in the literature,
293 transcriptomic sequencing can be difficult to interpret in this complex region of *NEB*, and choice
294 of control is especially important (Donner et al., 2004, 2006; Lam et al., 2018). This is illustrated
295 by a variant in a 3-year-old male with congenital myopathy at the +4 site published by
296 Cummings et al., 2017, where RNA sequencing derived from biceps muscle demonstrated
297 switching to exon 143-containing transcripts. However, as one control sample similarly showed
298 this isoform switching, the authors concluded that this is not a pathogenic variant. Examination
299 of supplemental data reveals that this control sample is from a 1-year-old female with unknown
300 biopsy origin and may thus not be sufficient evidence to exclude pathogenicity of the extended
301 splice variant (Cummings et al., 2017). Although the unbiased approach of RNA sequencing can
302 better detect complex splice events, these alternatively spliced isoforms prove difficult to assess
303 considering the variability by age and muscle type in healthy tissue.

304 Our patients presented with a pattern of muscle involvement atypical to the primarily
305 distal involvement reported for *NEB* nemaline myopathy (Figure D) (Jungbluth et al., 2004;
306 Perry et al., 2023; Scoto et al., 2013). Notably, there is one report of a 54-year-old woman with
307 biallelic variants in *NEB* and primarily proximal muscle involvement (Wunderlich et al., 2018).
308 Since exon 144-containing isoforms are lost in our patients, we thought to examine if the MRI
309 pattern of involvement follow the distribution of exon 144. When comparing our patient muscle
310 MRI to the established literature on the adult relative distribution of exons 143/144 isoforms
311 (Figure D6, Supplemental Table 2, Supplemental Table 3), muscles that are known to contain
312 higher or equal exon 143 expression (sartorius, gracilis, semitendinosus, tibialis anterior and
313 extensor digitorum longus) were shown to be relatively spared while muscles with higher
314 amounts of exon 144 (vastus lateralis, vastus medialis, lateral gastrocnemius and soleus) were

315 more affected (Figure D). Notably, the rectus femoris, biceps femoris, adductors longus/magnus
316 and medial gastrocnemius did not fit with the distribution of exon 144 (Figure D). Intriguingly,
317 the rectus femoris was significantly involved in P1 (MMS=4) while uninvolved in P2 (MMS=0),
318 suggesting that exon 144 expression cannot completely explain P1's MRI (Supplemental Table
319 3). Additionally, the long head of the biceps femoris was strikingly involved in our patients
320 (mMMS=4.5), while the short head was uninvolved (mMMS=0), but no data was available
321 regarding which part of the biceps femoris was surveyed in relative abundance studies (Figure D,
322 Supplemental table 3). The adductor magnus is described as containing both isoforms in the
323 literature, with no specific relative abundance for comparison (Figure D6, Supplemental Table
324 3). The semimembranosus is described as having less 144 than the adductor longus, but no
325 relative expression data is available and thus may well have more 144 than 143, which would fit
326 with the involvement seen in our patients. The overall impression is that the patient MRI findings
327 fit with the known pattern of exon 144 distribution more than with what had been published in
328 the literature. However, one recent published report of childhood onset nemaline myopathy due
329 to a nonsense variant in trans with the c.21522+3A>G variant provides MRI imaging taken in
330 adulthood refuting our analysis (Wen et al., 2020). This patient is reported to have muscle
331 involvement typical of nemaline myopathy, including involvement in the tibialis anterior,
332 although muscle grading is not provided for comparison and the images are insufficient (Wen et
333 al., 2020). Although a functional improvement in strength was noted for P2, the MRI data
334 showed mild progression of fibroadipose replacement of affected muscles, which may be due to
335 the increased reliance these muscles have on exon 144 as adulthood is reached (Figure D2-3).
336 Additional MRI imaging taken at several timepoints from patients with variants impacting exon

337 144 *NEB* splicing are needed to establish whether perhaps there may be a variant-specific pattern
338 of muscle involvement on MRI.

339 Understanding the unique roles these mutually exclusive exons play in the sarcomere
340 may be important both to understand muscle development and to identify therapeutic approaches
341 in *NEB*-related myopathy. Considering that the *NEB* gene contains other notable alternatively
342 spliced regions (exons 63-66, 82-105, and 166-177), insight into the function of exons 143 and
343 144 may inform investigations into these other regions (Donner et al., 2004). Besides their
344 different relative abundance, the mutually exclusive isoforms that contain exon 143 or 144 differ
345 in charge and hydrophobicity, and exon 144 contains a predicted protein kinase C
346 phosphorylation site (Donner et al., 2004). A step towards gaining insight into the roles of these
347 isoforms may be through uncovering a genotype-phenotype correlation. With the heterogeneity
348 of disease clinical presentation, no genotype-phenotype relationship is currently established for
349 pathogenic variants in *NEB* (Amburgey et al., 2021; Sewry et al., 2019). To date, patients
350 described with the c.21522+3A>G splice variant have been categorized with congenital-onset or
351 mild-onset disease, but none with severe disease (Supplemental Table 1, available on request)
352 (Lee et al., 2017; Wang et al., 2020). Furthermore, a patient with a homozygous deep intronic
353 variant in intron 144 leading to complete loss of exon 144 was reported with a phenotype of
354 congenital-onset nemaline myopathy and proximal more than distal weakness (Laflamme et al.,
355 2021). Given the adult role of exon 144, it is possible that untampered expression of
356 developmentally necessary exon 143 helps maintain the sarcomere and prevents severe disease.
357 Although a consensus exists for the diametric roles of these isoforms (supplemental Table 2),
358 one study challenges this binary understanding (Donner et al., 2006; Lam et al., 2018). When
359 probed in cell culture as opposed to muscle tissue, exon 144 is expressed exclusively in

360 myoblasts, switching to exon 143 expression upon differentiation into early myotubes (Lam et
361 al., 2018). Further work to understand the full pattern of expression will be important to properly
362 understand the function of these exons.

363 Finally, *NEB*-related myopathy is typically a form of nemaline myopathy (Table 1,
364 available on request), so the absence of the hallmark finding of nemaline rods in the muscle
365 biopsy in our patients is noteworthy (Figure A), since all reported patients with the
366 c.21522+3A>G variant were found to have nemaline rods on biopsy (Lee et al., 2017; Wang et
367 al., 2020; Wen et al., 2020). In nemaline myopathies in general, the presence and percentage of
368 rods in a patient biopsy can be variable and, although diagnostically helpful, may not correlate
369 with disease severity (Sewry et al., 2019; Wang et al., 2020). Furthermore, given the differential
370 muscle involvement evident on imaging, it is conceivable that nemaline rods could indeed be
371 found in another muscle. Thus, the absence of nemaline rod pathology in our patients does not
372 rule out the diagnosis, but highlights the importance of still considering *NEB*-related myopathy
373 in the compatible clinical context, while taking into consideration the many complexities of the
374 *NEB* gene as evident on genomic and transcriptional analysis (Wallgren-Pettersson et al., 2007).

375

376 *Future Directions*

377 Additional patients and research are needed, especially to assess how lack of exon 144-
378 containing transcripts affects muscle function and patterns of involvement. Further work to
379 validate the relative abundance of these isoforms in humans and their functional or regulatory
380 impact will better aid our understanding of muscle development and disease pathogenesis.
381 Finally, while to our knowledge this is the first report of disease pathogenesis through the
382 alteration of isoform distribution, we speculate that more examples of splice active variants

383 skewing alternative splicing may be found, establishing this as a pathogenic mechanism for
384 neuromuscular disease.

385

386 **Supplemental Information**

387 Supplemental Information includes three tables and four figures

388

389 **Declaration of interests**

390 The authors have no conflicts of interest to declare

391

392 **Acknowledgement**

393 We would like to thank the families for their participation. The work in C.G. Bönnemann's
394 laboratory is supported by intramural funds from the NIH National Institute of Neurological
395 Disorders. Sequencing and analysis were provided by the Broad Institute of MIT and Harvard
396 Center for Mendelian Genomics (Broad CMG) and was funded by the National Human Genome
397 Research Institute, the National Eye Institute, the National Heart, Lung and Blood Institute and
398 grant UM1HG008900 to Daniel MacArthur and Heidi Rehm. This study makes use of data
399 shared through the seqr platform with funding provided by National Institutes of Health grants
400 R01HG009141 and UM1HG008900.

401

402 The Genotype-Tissue Expression (GTEx) Project was supported by the Common Fund of the
403 Office of the Director of the National Institutes of Health, and by NCI, NHGRI, NHLBI, NIDA,
404 NIMH, and NINDS. The data used for the analyses described in this manuscript were obtained
405 from dbGaP accession number phs000424.v8.p2 on 09/25/2023.

406

407 This research was made possible through the NIH Medical Research Scholars Program, a public-
408 private partnership supported jointly by the NIH and contributions to the Foundation for the NIH
409 from the Doris Duke Charitable Foundation, Genentech, the American Association for Dental
410 Research, the Colgate-Palmolive Company, and other private donors.

411

412 **Web Resources**

413 <http://www.omim.org/>

414 <https://gnomad.broadinstitute.org/>

415 <https://www.ncbi.nlm.nih.gov/clinvar/>

416 <https://www.ncbi.nlm.nih.gov/snp/>

417 <https://muscleviz.github.io> (Wittenbach et al., 2019)

418

419 **Data and Code Availability**

420

421 **References**

- 422 Amburgey, K., Acker, M., Saeed, S., Amin, R., Beggs, A. H., Bönnemann, C. G., Brudno, M.,
423 Constantinescu, A., Dastgir, J., Diallo, M., Genetti, C. A., Glueck, M., Hewson, S., Hum,
424 C., Jain, M. S., Lawlor, M. W., Meyer, O. H., Nelson, L., Sultanum, N., ... Dowling, J. J.
425 (2021). A Cross-Sectional Study of Nemaline Myopathy. *Neurology*, *96*(10), e1425–e1436.
426 <https://doi.org/10.1212/WNL.0000000000011458>
- 427 Cummings, B. B., Marshall, J. L., Tukiainen, T., Lek, M., Donkervoort, S., Foley, A. R., Bolduc,
428 V., Waddell, L. B., Sandaradura, S. A., O’Grady, G. L., Estrella, E., Reddy, H. M., Zhao,
429 F., Weisburd, B., Karczewski, K. J., O’Donnell-Luria, A. H., Birnbaum, D., Sarkozy, A.,
430 Hu, Y., ... MacArthur, D. G. (2017). Improving genetic diagnosis in Mendelian disease
431 with transcriptome sequencing. *Science Translational Medicine*, *9*(386).
432 <https://doi.org/10.1126/scitranslmed.aal5209>
- 433 Donner, K., Nowak, K. J., Aro, M., Pelin, K., & Wallgren-Pettersson, C. (2006). Developmental
434 and muscle-type-specific expression of mouse nebulin exons 127 and 128. *Genomics*, *88*(4),
435 489–495. <https://doi.org/10.1016/J.YGENO.2006.06.008>

- 436 Donner, K., Sandbacka, M., Lehtokari, V. L., Wallgren-Pettersson, C., & Pelin, K. (2004).
437 Complete genomic structure of the human nebulin gene and identification of alternatively
438 spliced transcripts. *European Journal of Human Genetics* 2004 12:9, 12(9), 744–751.
439 <https://doi.org/10.1038/sj.ejhg.5201242>
- 440 Freiburg, A., Trombitas, K., Hell, W., Cazorla, O., Fougereousse, F., Centner, T., Kolmerer, B.,
441 Witt, C., Beckmann, J. S., Gregorio, C. C., Granzier, H., & Labeit, S. (2000). Series of
442 exon-skipping events in the elastic spring region of titin as the structural basis for
443 myofibrillar elastic diversity. *Circulation Research*, 86(11), 1114–1121.
444 <https://doi.org/10.1161/01.RES.86.11.1114>
- 445 Garrido-Martín, D., Palumbo, E., Guigó, R., & Breschi, A. (2018). ggsashimi: Sashimi plot
446 revised for browser- and annotation-independent splicing visualization. *PLOS*
447 *Computational Biology*, 14(8), e1006360.
448 <https://doi.org/10.1371/JOURNAL.PCBI.1006360>
- 449 Jaganathan, K., Kyriazopoulou Panagiotopoulou, S., McRae, J. F., Darbandi, S. F., Knowles, D.,
450 Li, Y. I., Kosmicki, J. A., Arbelaez, J., Cui, W., Schwartz, G. B., Chow, E. D., Kanterakis,
451 E., Gao, H., Kia, A., Batzoglou, S., Sanders, S. J., & Farh, K. K. H. (2019). Predicting
452 Splicing from Primary Sequence with Deep Learning. *Cell*, 176(3), 535-548.e24.
453 <https://doi.org/10.1016/J.CELL.2018.12.015>
- 454 Jungbluth, H., Sewry, C. A., Counsell, S., Allsop, J., Chattopadhyay, A., Mercuri, E., North, K.,
455 Laing, N., Bydder, G., Pelin, K., Wallgren-Pettersson, C., & Muntoni, F. (2004). Magnetic
456 resonance imaging of muscle in nemaline myopathy. *Neuromuscular Disorders* □: NMD,
457 14(12), 779–784. <https://doi.org/10.1016/J.NMD.2004.08.005>
- 458 Karczewski, K. J., Solomonson, M., Chao, K. R., Goodrich, J. K., Tiao, G., Lu, W., Riley-Gillis,
459 B. M., Tsai, E. A., Kim, H. I., Zheng, X., Rahimov, F., Esmaeeli, S., Grundstad, A. J.,
460 Reppell, M., Waring, J., Jacob, H., Sexton, D., Bronson, P. G., Chen, X., ... Neale, B. M.
461 (2022). Systematic single-variant and gene-based association testing of thousands of
462 phenotypes in 426,370 UK Biobank exomes. *MedRxiv*, 2021.06.19.21259117.
463 <https://doi.org/10.1101/2021.06.19.21259117>
- 464 Laflamme, N., Lace, B., Thonta Setty, S., Rioux, N., Labrie, Y., Droit, A., Chrestian, N., &
465 Rivest, S. (2021). A Homozygous Deep Intronic Mutation Alters the Splicing of Nebulin
466 Gene in a Patient With Nemaline Myopathy. *Frontiers in Neurology*, 12.
467 <https://doi.org/10.3389/FNEUR.2021.660113>
- 468 Laitila, J., Hanif, M., Paetau, A., Hujanen, S., Keto, J., Somervuo, P., Huovinen, S., Udd, B.,
469 Wallgren-Pettersson, C., Auvinen, P., Hackman, P., & Pelin, K. (2012). Expression of
470 multiple nebulin isoforms in human skeletal muscle and brain. *Muscle & Nerve*, 46(5), 730–
471 737. <https://doi.org/10.1002/MUS.23380>
- 472 Lam, L. T., Holt, I., Laitila, J., Hanif, M., Pelin, K., Wallgren-Pettersson, C., Sewry, C. A., &
473 Morris, G. E. (2018). Two alternatively-spliced human nebulin isoforms with either exon
474 143 or exon 144 and their developmental regulation. *Scientific Reports*, 8(1).
475 <https://doi.org/10.1038/S41598-018-33281-6>
- 476 Lamminen, A. E. (2014). Magnetic resonance imaging of primary skeletal muscle diseases:
477 patterns of distribution and severity of involvement. [Http://Dx.Doi.Org/10.1259/0007-1285-](http://Dx.Doi.Org/10.1259/0007-1285-63-756-946)
478 [63-756-946](https://doi.org/10.1259/0007-1285-63-756-946), 63(756), 946–950. <https://doi.org/10.1259/0007-1285-63-756-946>
- 479 Lee, J. M., Lim, J. G., Shin, J. H., Park, Y. E., & Kim, D. S. (2017). Clinical and genetic
480 diversity of nemaline myopathy from a single neuromuscular center in Korea. *Journal of the*
481 *Neurological Sciences*, 383, 61–68. <https://doi.org/10.1016/J.JNS.2017.10.020>

- 482 Lehtokari, V.-L., Kiiski, K., Sandaradura, S. A., Laporte, J., Repo, P., Frey, J. A., Donner, K.,
483 Marttila, M., Saunders, C., Barth, P. G., den Dunnen, J. T., Beggs, A. H., Clarke, N. F.,
484 North, K. N., Laing, N. G., Romero, N. B., Winder, T. L., Pelin, K., & Wallgren-Pettersson,
485 C. (2014). Mutation update: the spectra of nebulin variants and associated myopathies.
486 *Human Mutation*, *35*(12), 1418–1426. <https://doi.org/10.1002/humu.22693>
- 487 Nakka, K., Ghigna, C., Gabellini, D., & Dilworth, F. J. (2018). Diversification of the muscle
488 proteome through alternative splicing. *Skeletal Muscle* *2018* *8:1*, 8(1), 1–18.
489 <https://doi.org/10.1186/S13395-018-0152-3>
- 490 Nikonova, E., Kao, S. Y., & Spletter, M. L. (2020). Contributions of alternative splicing to
491 muscle type development and function. *Seminars in Cell & Developmental Biology*, *104*,
492 65–80. <https://doi.org/10.1016/J.SEMCDB.2020.02.003>
- 493 Ortolan, P., Zanato, R., Coran, A., Beltrame, V., & Stramare, R. (2015). Role of Radiologic
494 Imaging in Genetic and Acquired Neuromuscular Disorders. *European Journal of*
495 *Translational Myology*, *25*(2), 121. <https://doi.org/10.4081/EJTM.2015.5014>
- 496 Perry, L., Stimpson, G., Singh, L., Morrow, J. M., Shah, S., Baranello, G., Muntoni, F., &
497 Sarkozy, A. (2023). Muscle magnetic resonance imaging involvement patterns in nemaline
498 myopathies. *Annals of Clinical and Translational Neurology*, *10*(7), 1219–1229.
499 <https://doi.org/10.1002/ACN3.51816>
- 500 Rentzsch, P., Schubach, M., Shendure, J., & Kircher, M. (2021). CADD-Splice—improving
501 genome-wide variant effect prediction using deep learning-derived splice scores. *Genome*
502 *Medicine*, *13*(1), 1–12. <https://doi.org/10.1186/S13073-021-00835-9/FIGURES/4>
- 503 Savarese, M., Jonson, P. H., Huovinen, S., Paulin, L., Auvinen, P., Udd, B., & Hackman, P.
504 (2018). The complexity of titin splicing pattern in human adult skeletal muscles. *Skeletal*
505 *Muscle*, *8*(1). <https://doi.org/10.1186/S13395-018-0156-Z>
- 506 Scoto, M., Cullup, T., Cirak, S., Yau, S., Manzur, A. Y., Feng, L., Jacques, T. S., Anderson, G.,
507 Abbs, S., Sewry, C., Jungbluth, H., & Muntoni, F. (2013). Nebulin (NEB) mutations in a
508 childhood onset distal myopathy with rods and cores uncovered by next generation
509 sequencing. *European Journal of Human Genetics* □: *EJHG*, *21*(11), 1249–1252.
510 <https://doi.org/10.1038/EJHG.2013.31>
- 511 Sewry, C. A., Laitila, J. M., & Wallgren-Pettersson, C. (2019). Nemaline myopathies: a current
512 view. *Journal of Muscle Research and Cell Motility*, *40*(2), 111–126.
513 <https://doi.org/10.1007/S10974-019-09519-9>
- 514 Thorvaldsdottir, H., Robinson, J. T., & Mesirov, J. P. (2013). Integrative Genomics Viewer
515 (IGV): high-performance genomics data visualization and exploration. *Briefings in*
516 *Bioinformatics*, *14*(2), 178–192. <https://doi.org/10.1093/bib/bbs017>
- 517 Trapnell, C., Williams, B. A., Pertea, G., Mortazavi, A., Kwan, G., Van Baren, M. J., Salzberg,
518 S. L., Wold, B. J., & Pachter, L. (2010). Transcript assembly and abundance estimation
519 from RNA-Seq reveals thousands of new transcripts and switching among isoforms. *Nature*
520 *Biotechnology*, *28*(5), 511. <https://doi.org/10.1038/NBT.1621>
- 521 Uapinyoying, P., Goecks, J., Knoblac, S. M., Panchapakesan, K., Bonneman, C. G., Partridge, T.
522 A., Jaiswa, J. K., & Hoffma, E. P. (2020). A long-read RNA-seq approach to identify novel
523 transcripts of very large genes. *Genome Research*, *30*(6), 885–897.
524 <https://doi.org/10.1101/GR.259903.119>
- 525 Wallgren-Pettersson, C., & Laing, N. G. (2000). Report of the 70th ENMC International
526 Workshop: nemaline myopathy, 11-13 June 1999, Naarden, The Netherlands.

- 527 *Neuromuscular Disorders*: *NMD*, 10(4–5), 299–306. <https://doi.org/10.1016/S0960->
528 8966(99)00129-7
- 529 Wang, Q., Hu, Z., Chang, X., Yu, M., Xie, Z., Lv, H., Zhang, W., Xiong, H., Yuan, Y., & Wang,
530 Z. (2020). Mutational and clinical spectrum in a cohort of Chinese patients with hereditary
531 nemaline myopathy. *Clinical Genetics*, 97(6), 878–889. <https://doi.org/10.1111/CGE.13745>
- 532 Wen, Q., Chang, X., & Guo, J. (2020). A childhood-onset nemaline myopathy caused by novel
533 heterozygote variants in the nebulin gene with literature review. *Acta Neurologica Belgica*,
534 120(6), 1351–1360. <https://doi.org/10.1007/S13760-019-01230-3>
- 535 Whiffin, N., Minikel, E., Walsh, R., O'Donnell-Luria, A. H., Karczewski, K., Ing, A. Y., Barton,
536 P. J. R., Funke, B., Cook, S. A., Macarthur, D., & Ware, J. S. (2017). Using high-resolution
537 variant frequencies to empower clinical genome interpretation. *Genetics in Medicine* 2017
538 19:10, 19(10), 1151–1158. <https://doi.org/10.1038/gim.2017.26>
- 539 Wittenbach, J. D., Cocanougher, B. T., Yun, P., Foley, A. R., & Bönnemann, C. G. (2019).
540 MuscleViz: Free Open-Source Software for Muscle Weakness Visualization. *Journal of*
541 *Neuromuscular Diseases*, 6(2), 263–266. <https://doi.org/10.3233/JND-190385>
- 542 Wunderlich, G., Brunn, A., Daimagüler, H. S., Bozoglu, T., Fink, G. R., Lehmann, H. C., Weis,
543 J., & Cirak, S. (2018). Long term history of a congenital core-rod myopathy with compound
544 heterozygous mutations in the Nebulin gene. *Acta Myologica*, 37(2), 121.
545 </pmc/articles/PMC6060425/>
- 546 Yuen, M., & Ottenheijm, C. A. C. (2020). Nebulin: big protein with big responsibilities. *Journal*
547 *of Muscle Research and Cell Motility*, 41(1), 103–124. <https://doi.org/10.1007/S10974-019->
548 09565-3
- 549 Zernant, J., Lee, W., Collison, F. T., Fishman, G. A., Sergeev, Y. V., Schuerch, K., Sparrow, J.
550 R., Tsang, S. H., & Allikmets, R. (2017). Frequent hypomorphic alleles account for a
551 significant fraction of ABCA4 disease and distinguish it from age-related macular
552 degeneration. *Journal of Medical Genetics*, 54(6), 404–412.
553 <https://doi.org/10.1136/JMEDGENET-2017-104540>
554

555 **Figure Legends**

556 **Figure A:** Patient Phenotype and Pedigree A) facial weakness, ankle contractures, narrow palate,
557 and body habitus in P1 (left) and P2 (right). B) strength grading for both P1 and P2 at two
558 timepoints, diagram created by MuscleViz (<https://muscleviz.github.io/>). C) pedigree and
559 segregation of NEB variants in our patient family. D) histology from P1, H&E (left) Gomori
560 Trichrome (middle) and NADH (right), no nemaline rods noted. EM images were unavailable for
561 analysis.

562

563 **Figure B:** RNA sequencing of NEB exons 143 and 144 in patient P1 and controls. The age
564 control group is the aggregate of two age matched control samples from quadriceps. Reported as
565 median junction reads. The biceps control group is an aggregate of three adult patients with
566 biceps biopsies, aggregate by median junction. The patient biopsy has very few junction reads to
567 exon 144 compared with both controls. Junctions with less than 10 reads were removed for
568 clarity. All junctions and individual control samples can be viewed in supplemental figures 2 and
569 3.

570
571 **Figure C:** NEB (NM_001271208.2) gene models illustrating the different splicing patterns
572 involving the mutually exclusive exons 143 and 144 in control individuals and patients. The
573 patient variant affects splicing leading to generation of an aberrant exon 144 containing isoform
574 with a premature stop codon resulting in nonsense mediated decay.

575
576 **Figure D:** Muscle MRI T1 and relative expression of exons 143 and 144. 1A) Significantly
577 increased T1 signaling, indicating severe, almost complete, replacement of muscle with
578 fibroadipose tissue in the vasti, rectus femoris (RF), long head of biceps femoris (BF), adductors
579 (Ad) with relative sparing of semitendinosus (ST), Sartorius (Sr) and Gracilis (Gr) and milder
580 involvement of the semimembranosus (SM). 1B) In the lower leg there is fibroadipose
581 replacement of lateral gastrocnemius (LG) and soleus (So) (right>left) with relative sparing of
582 anterior compartment muscles. 2A) Increased T1 signaling consistent with fibroadipose
583 replacement in a patchy distribution in the vastus lateralis (VL), vastus intermedius (VI),
584 semimembranosus (SM) and long head of biceps femoris (BF) muscles (left>right) in the upper
585 leg 2B) and patchy fibroadipose replacement of the lateral gastrocnemius (LG) and soleus (So)

586 muscles in the lower leg. 3A) Symmetric patchy fibroadipose replacement of VL and VI with
587 relative sparing of vastus medialis (VM). In the posterior thigh, there is selective and more
588 prominent involvement of SM and long head of BF, slightly more significant on the left
589 compared to the right. RF, Sr, Gr, short head of BF, and ST are selectively spared and appear
590 hypertrophied. 3B) Fibroadipose replacement of LG, So, and tibialis posterior (TP) with sparing
591 of the anterior lower leg muscles and medial gastrocnemius (MG). 4) mean Modified Mercuri
592 Scores reported for age matched *NEB* patients (supplemental table 3) (Perry et al, 2023) 5) mean
593 Modified Mercuri Scores reported for P1 and P2 (supplemental table 3) 6) Approximate
594 depiction of relative expression of exons 143 and 144 as reported in the literature (Donner et
595 al., 2004, 2006; Laitila et al., 2012; Lam et al., 2018; Uapinyoying et al., 2020).

596

597 **Supplemental Figure 1:** A) Reads aligned to Exon 22 in DNA show heterozygous SNP
598 c.2079C>A; p.(Cys693Ter) present in 50% of reads. B) The variant c.2079C>A; p.(Cys693Ter)
599 is present only in 11 out of 64 reads in RNAseq of P1, consistent with nonsense mediated decay
600 prediction for this truncating variant

601

602 **Supplemental Figure 2:** analysis of all isoforms (no junction reads removed) existing in patient
603 and controls between exons 142-145. The only difference between patient and controls is the
604 lack of exon 144 inclusion. Note the 6 splice junction reads in patient starting in intron 144 and
605 ending at exon 145. Patient in purple and three biceps controls in green, all adult (30-50yrs)
606 biceps have a higher read count of exon 144 compared with 143 in adult biceps

607

608 **Supplemental Figure 3:** Patient compared with two age and sex matched controls, but not
609 biopsied from the same muscle group. Both exons 143 and 144 are expressed almost equally in
610 control samples, while the patient sample expresses exon 144 only. Again, Note the 6 splice
611 junction reads in patient starting in intron 144 and ending at exon 145, which are not seen in
612 controls.

613
614 **Supplemental Figure 4:** five randomly selected GTEX muscle samples biopsied from “below
615 the patella” or “gastrocnemius” all show multiple rare isoforms, including isoforms splicing exon
616 142 directly to exon 145. Notably, there is no isoform that matches the six reads demonstrating
617 intron 144 extension in our patient. There is variability in exon 143 expression between
618 individual samples, although the lack of precise biopsy knowledge makes drawing conclusions
619 regarding the relative abundance of 143 and 144 from GTEX data difficult.

620

621

Figure A

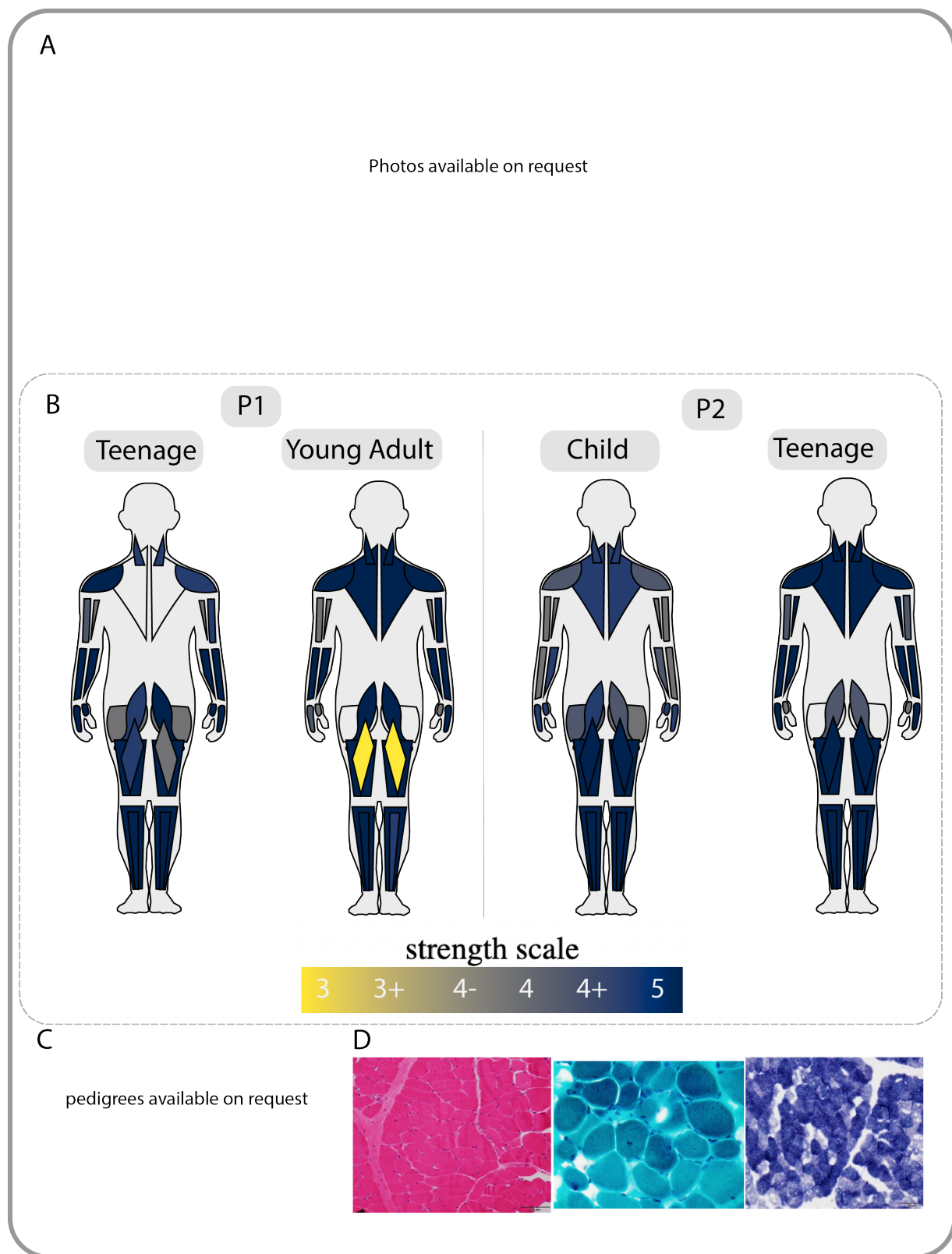


Figure B

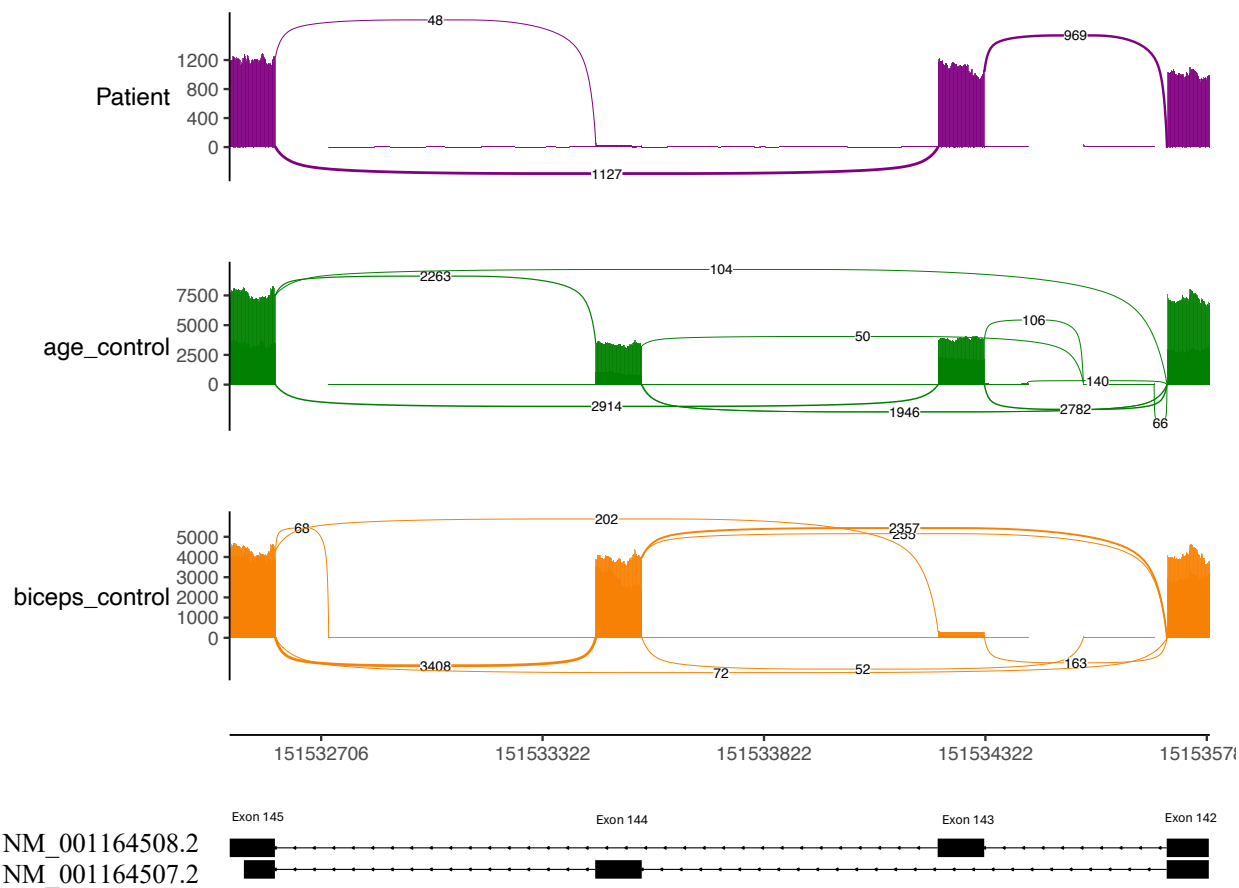
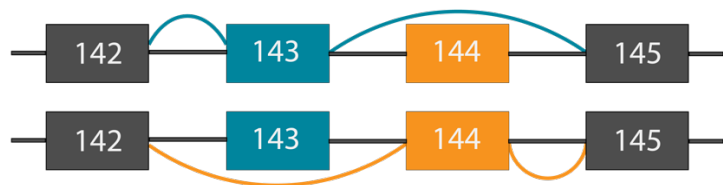


Figure C

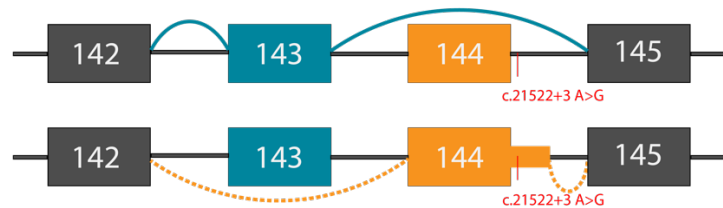Wild Type Gene Model



Wild Type Isoforms



Patient Gene Model



Patient Isoforms




Figure D

