

1 **Full title:** Specific pelvic shape in patients with developmental dysplasia of the hip on 3D
2 morphometric homologous model analysis

3

4 **Short title:** 3D homologous analysis for the pelvises with DDH.

5

6 Yui Sasaki¹, Daisuke Suzuki^{2*}, Ryo Tokita³, Hiroyuki Takashima⁴, Hirofumi Matsumura⁵,

7 Satoshi Nagoya⁶

8

9 1. Division of Rehabilitation, Hitsujigaoka Hospital, Sapporo, Japan

10 2. Department of Health Sciences, Hokkaido Chitose Collage of Rehabilitation, Chitose, Japan

11 3. Department of Rehabilitation, Sapporo Medical University Hospital, Sapporo, Japan

12 4. Division of Biomedical Science and Engineering, Faculty of Health Sciences, Hokkaido
13 University, Sapporo, Japan

14 5. Department of Physical Anthropology, School of Health Science, Sapporo Medical University,
15 Sapporo, Japan

16 6. Division of Orthopaedic Surgery, Sapporo Kojinkai Memorial Hospital, Sapporo, Japan

17

18 *Corresponding author

19 d-suzuki@chitose-reha.ac.jp: (DS)

20

NOTE: This preprint reports new research that has not been certified by peer review and should not be used to guide clinical practice.

21 **Abstract**

22 **Purpose:** To clarify the morphological factors of the pelvis in patients with developmental
23 dysplasia of the hip (DDH), three-dimensional (3D) pelvic morphology was analyzed using a
24 template-fitting technique.

25 **Methods:** Three-dimensional pelvic data of 50 patients with DDH (DDH group) and 3D pelvic
26 data of 50 patients without obvious pelvic deformity (Normal group) were used. All patients were
27 female. A template model was created by averaging the normal pelvises into a symmetrical and
28 isotropic mesh. Next, 100 homologous models were generated by fitting the pelvic data of each
29 group of patients to the template model. Principal component analysis was performed on the
30 coordinates of each vertex (15,235 vertices) of the pelvic homologous model. In addition, a
31 receiver-operating characteristic (ROC) curve was calculated from the sensitivity of DDH
32 positivity for each principal component, and principal components for which the area under the
33 curve was significantly large were extracted ($p < 0.05$). Finally, which components of the pelvic
34 morphology frequently seen in DDH patients are related to these extracted principal
35 components was evaluated.

36 **Results:** The first, third, and sixth principal components showed significantly larger areas under
37 the ROC curves. The morphology indicated by the first principal component was associated with
38 a decrease in coxal inclination in both the coronal and horizontal planes. The third principal
39 component was related to the sacral inclination in the sagittal plane. The sixth principal
40 component was associated with narrowing of the superior part of the pelvis.

41 **Conclusion:** The most important factor in the difference between normal and DDH pelvises
42 was the change in the coxal angle in both the coronal and horizontal planes. That is, in the
43 anterior and superior views, the normal pelvis is a triangle, whereas in DDH, it was more like a
44 quadrilateral.

45

46 **Keywords:** morphology of the pelvis, homology model, developmental dysplasia of the hip,
47 coxal inclination, principal component analysis

48

49 **Introduction**

50 Developmental dysplasia of the hip (DDH) refers to a condition in which the acetabulum that
51 covers the femoral head is hypoplastic, and it is defined as a center-edge (CE) angle of less
52 than 20 degrees [1]. DDH is more common in women and is considered a cause of hip
53 osteoarthritis, which has a prevalence of approximately 3.5% in Japanese women [2]. In fact,
54 approximately 80% of Japanese women with osteoarthritis of the hip have DDH, and many of
55 them develop the osteoarthritis at an early age [3]. DDH also causes pain and instability in the
56 hip joint, which can be problematic in daily life. Many patients with DDH also have low back pain
57 [4-7].

58 With the development of diagnostic imaging technology, the location of acetabular defects in
59 patients with DDH is not uniform and can be divided into three types: total defect,
60 anterosuperior defect, and posterosuperior defect [8, 9]. Approximately 18% have been shown

61 to have insufficient posterior and posterosuperior coverage of the acetabulum [10].

62 Furthermore, the acetabular notch in patients with posterosuperior defects has been shown to

63 be located more anteriorly than in healthy subjects [11]. In other words, the pelvis of DDH

64 patients does not have a fixed area of dysplasia, but the location of the dysplasia differs

65 depending on the patient. Furthermore, DDH is known to cause not only dysplasia of the

66 acetabulum, but also deformity of the entire pelvis. For example, it has been reported that the

67 pelvis is tilted more forward than in healthy individuals, both superior and inferior iliac wing

68 angles are larger [12], the width of the pelvic outlet is wider [13], and the iliac wings are curved

69 inwardly [14]. However, at present, evaluation of pelvic morphology in DDH patients is limited to

70 local measurements, and morphological analysis of the entire pelvis has not been performed.

71 In recent years, advances in computer processing power and algorithms have made it possible

72 to analyze entire 3D image data. Of such analysis methods, template fitting is attracting

73 attention [15]. In this study, template fitting was used to perform a homologous model analysis

74 of the pelvis. The homologous model analysis is a method that comprehensively measures how

75 much and in what direction the model changes. This made it possible to extract the

76 characteristic shape of the pelvis of DDH patients.

77

78 **Methods**

79 **Subjects**

80 Three-dimensional pelvic data of 50 patients with DDH (DDH group) and 3D pelvic data of 50

81 patients without obvious pelvic deformity (Normal group) were used with computed tomography
82 (CT Aquilion CX Edition, Toshiba Medical Systems, Otawara, Japan; tube voltage 120 kV; slice
83 thickness 0.5 mm). The inclusion criteria were female patients who visited Sapporo Medical
84 University Hospital between April 2013 and October 2022 for both the DDH and Normal groups,
85 had no indication of opt-out, had no history of hip or spine surgery, and were under 55 years of
86 age. The DDH group consisted of patients who underwent rotational acetabular osteotomy
87 (RAO) at Sapporo Medical University. They were all Tönnis grade 0 or 1. The Normal group
88 consisted of patients with no obvious pelvic deformity and a center-edge angle of 25 degrees or
89 more. The mean age was 39.4 years (range 21-51 years) in the DDH group and 39.0 years
90 (range 21-52 years) in the Normal group.

91 In conducting this study, the normal group were used anonymized CT DICOM data. the DDH
92 group were used CT DICOM data anonymized to prevent identification by authors other than
93 the attending physician (SN). Furthermore, since we used patient data obtained during regular
94 medical treatment, the Ethics Committee of our institution has approved that an opt-out format
95 is acceptable without requiring informed consent from individual patients. This study was
96 approved by the institutional review board of Sapporo Medical University Hospital (approval
97 number: 322-205).

98

99 **Template Fitting**

100 Although a 3D model consists of a polygon mesh, there are basically no homologous vertices

101 between a template model and an arbitrary 3D model, and the number of vertices is not
102 identical, so it is impossible to compare them as they are. Therefore, homologous modeling by
103 template fitting was used to make arbitrary 3D models comparable.

104 In template fitting, first, homologous points such as protrusions, and ridges, etc. are registered
105 as landmarks in both the reference model (template model) and the 3D models to be analyzed.
106 Next, a homologous model is created by transforming and superimposing the template model
107 into the 3D model to be analyzed, based on the landmarks as a reference. The created
108 homologous model can be assumed to show overall homology with the template model (Fig 1).
109 Therefore, by creating homologous models of all the pelvises to be analyzed, it is possible to
110 comprehensively evaluate in which direction and degree each vertex changes among the
111 homologous modeled pelvises.

112 The 3D pelvis model was reconstructed using 3D imaging software (Mimics ver. 23.0,
113 Materialize, Leuven, Belgium) from a series of CT images and output by converting to STL
114 format. Since a shape with holes cannot create a homologous model, the anterior and posterior
115 sacral foramina and vertebral foramina were closed using 3D modeling software (3matic ver.
116 15.0, Materialize). After these preparations, 10 randomly selected pelvises were synthesized,
117 mirrored to form them bilaterally symmetrically, and isotropically remeshed to create the
118 template model. This resulted in the creation of a template model with 15,235 vertices. This
119 template model was placed in the anterior pelvic plane [16, 17]. Next, 58 points consisting of the
120 anterior superior iliac spine and symphysis pubis, etc. were defined as landmarks (Fig 2).

121 The pelvises to be analyzed were placed in the anterior pelvic coordinate system after filling
122 the holes in the same way as the template model. Next, template fitting was performed using
123 the landmarks as a reference to create a homologous model. The homologous model created
124 using this template fitting had the same topology and number of data points as the template
125 model (Fig 2).

126 The homologous model was created using HBM-Rugle software (Medic Engineering, Kyoto,
127 Japan, <http://www.rugle.co.jp/>). The main parts of this software were originally developed at the
128 Digital Human Research Center of the National Institute of Advanced Industrial Science and
129 Technology [18]. The robustness of the fitting accuracy of this software has been verified in
130 several studies [19-26].

131 In the actual template fitting using HBM-Rugle, the pelvis model to be analyzed was
132 superimposed on the template model using the ICP method [27] with 58 landmarks as reference
133 points. Next, the template model was fitted to the pelvis model to be analyzed using non-rigid
134 mesh deformation to generate a homologous model. The average distance between the planes
135 of the generated homologous model and the original pelvis model was 0.632 ± 0.124 mm.

136

137 **Data analyses**

138 The size of all homologous pelvis models was normalized to minimize the sum of squared
139 distances between each vertex of the template model and each vertex of the homologous
140 model. Principal component analysis was then performed on the three-dimensional coordinates

141 of the vertices that made up each model (HBM-Rugle).

142 Of the principal components obtained, receiver-operating characteristic (ROC) curve analysis

143 was performed to evaluate the characteristics found in pelvises with DDH [28]. The ROC curves

144 were determined by setting the DDH group to 1 and the Normal group to 0 for the principal

145 component score of each pelvic model. The area under the curve (AUC) of the ROC curve was

146 determined, and then the significance of the AUC was evaluated using the χ^2 test (null

147 hypothesis = 0.5). The significance level was set at 5%. The ROC analysis was performed using

148 Bell Curve for Excel (version 3.21, SSRI, Tokyo, Japan). Next, virtual pelvic morphology that

149 would occur when the principal component score was changed by ± 3 standard deviations (SD)

150 was outputted, and how each principal component affected the pelvic morphology was

151 evaluated (HBM-Rugle). In addition, to evaluate the meaning of each principal component, a

152 scatter plot of each measurement value of the pelvis (sharp angle, iliac wing angle, sacral slope,

153 ischiopubic angle, pelvic inclination) when the pelvis is placed in the functional pelvic coordinate

154 system was created [29] (Fig 3).

155

156 **Results**

157 Principal component analysis was performed using the 3D coordinates of the vertices of the

158 homologous pelvic model. When calculating up to the 20th principal component, the cumulative

159 contribution rate exceeded 80%. ROC curve analysis was performed on these principal

160 components with the DDH group as positive. The principal components with significant AUCs

161 were the first ($p<0.001$), third ($p<0.05$), and sixth principal components ($p<0.01$) (Table 1, Fig 4).

162 Fig 5 shows histograms of the principal component scores (PC1, PC3, and PC6) that were

163 significantly different, separately for the Normal group and the DDH group.

164 The virtual morphologies when these principal component scores were changed by $\pm 3SD$ are

165 shown in Figs 6-8. The morphology indicated by the first principal component was associated

166 with a decrease in coxal inclination in both coronal and horizontal planes. In addition, it was

167 associated with both an increased Sharp angle and an increased ischiopubic angle. The third

168 principal component was related to posterior translation of the sacrum in the sagittal plane and

169 a decrease in the sacral slope. The sixth principal component was associated with narrowing of

170 the superior part of the pelvis.

171 Scatter plots between the PCs and the pelvic measurements were created, and it was found

172 that PC1 had some strong correlations with each measurement except for the sacral slope, but

173 strong correlations were not obtained for PC3 and PC6. Nevertheless, PC3 had a weak

174 correlation with the Sharp angle, and PC6 had weak correlations with the iliac wing angle,

175 sacral slope, and ischiopubic angle (Fig 9, Table 2).

176

177 **Discussion**

178 In this study, 100 homologous models were created by template fitting from both 50 DDH

179 patients and 50 normal control patients. Morphological analysis for these homologous models

180 was performed to extract the characteristics of the pelvis of DDH patients. The pelvic

181 morphology of DDH patients was found to be different from the Normal group in terms of not
182 only acetabular dysplasia, but also the inclination of the coxa and the sacrum. Although
183 morphological analysis using a homologous model assumes that all vertices comprising the
184 pelvis are homologous, it is an objective method that uses all morphological information. This
185 method has recently been used to evaluate foot form, cranial morphology, facial aging changes,
186 and pelvis sex determination, and it is attracting attention as a new comparison method for 3D
187 models [15, 19, 21, 24].

188 DDH is a frequent hip disorder in Japan, and it has been reported that 80% of patients
189 diagnosed with osteoarthritis of the hip joint have DDH [3]. It is also known that DDH occurs
190 more frequently in women. DDH is a multifactorial disease, and in addition to genetic factors, it
191 has been suggested that the pressure on the hip joint applied during pregnancy, such as breech
192 position, oligohydramnios, and overweight, is significant [30-32].

193
194 Although some differences in the morphology of the pelvis between healthy subjects and
195 patients with DDH have been previously reported, comprehensive changes in the pelvic
196 morphology have not been studied [12]. In the present study, it was possible to evaluate the
197 characteristics of DDH in the overall morphology of the pelvis by creating a homologous model
198 of the pelvis. On principal component analysis and ROC analysis using three-dimensional
199 coordinates as an element, the AUCs of the ROC curves based on each principal component
200 score of the first, third, and sixth principal components were significant.

201 The first principal component was associated with a decrease in inclination of the coxa in both
202 coronal and horizontal planes (Fig 6). Although these have been reported previously [10, 14],
203 they were evaluated separately, such as changes in the angle of the iliac wings and increases
204 in the ischiopubic angle (Fig 9) [12]. However, the present results suggest that these differences
205 stem from a single factor. The scatter plots showed that the first principal component also had a
206 strong negative correlation with the Sharp angle (Fig 9) [33]. That is, as the coronal inclination
207 of the coxa decreases, the acetabulum inclines, and in addition, coverage of the femoral head
208 decreases.

209 The third principal component appeared to be related to sacral slope (Fig 7). This effect was
210 weak in the coronal plane and strong in the sagittal plane. In addition, in the horizontal plane,
211 the sacrum was located posteriorly. However, the scatter plots of the PC3 score and sacral
212 slope/pelvic inclination showed that these measurements had little correlation (Fig 9). It is
213 possible that the alignment of all pelvises to the anterior pelvic plane at the time of analysis
214 masked the relationship between sacral tilt and pelvic tilt at the original pelvic position. On the
215 other hand, PC3 showed a weak correlation with the Sharp angle.

216 Reports that young patients in the early stages of DDH have a strong sacral slope [34, 35] are
217 like the characteristics seen in the third principal component. In addition, an increase in sacral
218 slope is closely related to an increase in lumbar lordosis. It is thought that patients with large
219 lumbar lordosis are more likely to develop low back pain caused by the posterior part of the
220 vertebrae [36, 37], and it has been reported that patients with DDH often have low back pain

221 [38]. Thus, the third principal component suggests that it might be related to not only sacral
222 slope, but also the development of low back pain.

223 The sixth principal component was related to the size of the superior part of pelvis composed
224 of the iliac wings and sacrum (Fig 8). The superior part of the pelvis widens in the Normal
225 group, whereas it hardly widens in the DDH group. Unlike the third principal component, this
226 principal component has strong effects on the coronal plane. Patients with DDH are known to
227 have medial orientation of the iliac wings and anterior inferior iliac spine [14, 39], which is like
228 changes in the sixth principal component. Further, the upper surface of the vertebral body of the
229 first sacral vertebra also tilts anteriorly, suggesting changes in sacral slope. In fact, the scatter
230 plots between PC6 and pelvic measurements showed a weak correlation with iliac wing angle
231 and sacral slope (Fig 9).

232 The analysis of the present study suggested that the pelvis of DDH has a significant influence
233 not only on acetabular dysplasia, but also on the shape of the acetabulum and sacrum. As
234 shown in the first and sixth principal components, the iliac wings are narrow in the coronal and
235 horizontal planes in the pelvis of DDH. This indicates that the course of the gluteus medius
236 muscle was different from that of the Normal group. It is known that patients with DDH have
237 weak abductor strength [40, 41], but this is likely due to differences in the course of the gluteus
238 medius muscle. In recent years, some researchers reported that gluteus medius muscle
239 weakness is significantly associated with low back pain [42, 43]. This suggests that patients with
240 DDH should also consider gluteus medius training [44, 45] and lower back pain care.

241 Furthermore, a large sacral slope in DDH patients means a large lumbar lordosis. A large
242 lumbar lordosis is also closely related to low back pain [46]. Therefore, this study showed
243 morphometrically that pelvic shape may be associated with gluteus medius muscle weakness
244 and low back pain in patients with DDH.

245 In summary, the characteristics of the pelvis of DDH patients were identified by comparing the
246 pelvises of 50 patients with DDH and of 50 patients with no obvious deformity using a
247 homologous model. The most important factor in the difference between normal and DDH
248 pelvises was the change in the coxal angle in both the coronal and horizontal planes. That is, in
249 the anterior and superior views, the normal pelvis is a triangle, whereas the DDH was more like
250 a quadrilateral. The pelvic characteristics of DDH patients shown in this study, i.e., changes in
251 the morphology of the iliac wing and sacrum etc., may affect the muscles and lumbar spine to
252 which they are attached and articulated, and treatment that recognizes them should be
253 considered.

254

255 **Study limitations**

256 In this study, pelvic morphological change was evaluated in patients with DDH using
257 homologous model analysis, but there were the following problems.

- 258 1. Since the pelvic model was simplified, the detailed shape could not be measured.
- 259 2. When creating a homologous model, since a perforated (torus-shaped) structure was not
260 allowed, the vertebral foramen and anterior sacral foramen were blocked, resulting in some

261 parts that differed slightly from the actual shape.

262 3. Pelvic inclination could not be evaluated because all pelvises were aligned in the anterior

263 pelvic plane.

264

265 **Acknowledgments**

266 Dr. Toda Hajime (Sapporo Medical University, Department of Health Sciences) created a

267 conceptual diagram of the homology model in Figure 1. Mr. Toyohisa Tanijiri (Medic

268 Engineering, Kyoto, Japan) developed the software (HBM-Rugle) necessary for homologous

269 model analysis and added several functions according to our requests. He also provided me

270 with the knowledge and information necessary for analysis.

271 This study was supported by JSPS KAKENHI (Grant Number 21K11269).

272

References

1. Wiberg G. Studies on dysplastic acetabula and congenital subluxation of the hip joint with special reference to the complication of osteoarthritis. Stockholm: Exp., Norstedt Stockholm; 1939.
2. Inoue K, Wicart P, Kawasaki T, Huang J, Ushiyama T, Hukuda S, et al. Prevalence of hip osteoarthritis and acetabular dysplasia in french and japanese adults. *Rheumatology* (Oxford, England). 2000;39(7):745-8. Epub 2000/07/26. doi: 10.1093/rheumatology/39.7.745. PubMed PMID: 10908693.
3. Jingushi S, Ohfuji S, Sofue M, Hirota Y, Itoman M, Matsumoto T, et al. Multiinstitutional epidemiological study regarding osteoarthritis of the hip in Japan. *Journal of orthopaedic science : official journal of the Japanese Orthopaedic Association*. 2010;15(5):626-31. doi: 10.1007/s00776-010-1507-8. PubMed PMID: 20953923.
4. Offierski CM, MacNab I. Hip-spine syndrome. *Spine*. 1983;8(3):316-21. Epub 1983/04/01. doi: 10.1097/00007632-198304000-00014. PubMed PMID: 6623198.
5. Yoshimoto H, Sato S, Masuda T, Kanno T, Shundo M, Hyakumachi T, et al. Spinopelvic alignment in patients with osteoarthrosis of the hip: a radiographic comparison to patients with low back pain. *Spine*. 2005;30(14):1650-7. Epub 2005/07/19. doi: 10.1097/01.brs.0000169446.69758.fa. PubMed PMID: 16025036.
6. Jia CQ, Wu YJ, Cao SQ, Hu FQ, Zheng ZR, Xu C, et al. Mid-term low back pain improvement after total hip arthroplasty in 306 patients with developmental dysplasia of

- 293 the hip. *Journal of orthopaedic surgery and research*. 2023;18(1):212. Epub 2023/03/19.
- 294 doi: 10.1186/s13018-023-03701-z. PubMed PMID: 36932447; PubMed Central PMCID:
- 295 PMCPMC10022041.
- 296 7. Dezateux C, Rosendahl K. Developmental dysplasia of the hip. *Lancet (London, England)*.
- 297 2007;369(9572):1541-52. Epub 2007/05/08. doi: 10.1016/s0140-6736(07)60710-7.
- 298 PubMed PMID: 17482986.
- 299 8. Nepple JJ, Wells J, Ross JR, Bedi A, Schoenecker PL, Clohisy JC. Three Patterns of
- 300 Acetabular Deficiency Are Common in Young Adult Patients With Acetabular Dysplasia.
- 301 *Clin Orthop Relat Res*. 2016. doi: 10.1007/s11999-016-5150-3. PubMed PMID: 27830486.
- 302 9. Wilkin GP, Ibrahim MM, Smit KM, Beaulé PE. A Contemporary Definition of Hip Dysplasia
- 303 and Structural Instability: Toward a Comprehensive Classification for Acetabular
- 304 Dysplasia. *J Arthroplasty*. 2017;32(9s):S20-s7. Epub 2017/04/09. doi:
- 305 10.1016/j.arth.2017.02.067. PubMed PMID: 28389135.
- 306 10. Fujii M, Nakashima Y, Yamamoto T, Mawatari T, Motomura G, Matsushita A, et al.
- 307 Acetabular retroversion in developmental dysplasia of the hip. *J Bone Joint Surg Am*.
- 308 2010;92(4):895-903. doi: 10.2106/JBJS.I.00046. PubMed PMID: 20360513.
- 309 11. Fujii M, Nakashima Y, Sato T, Akiyama M, Iwamoto Y. Acetabular tilt correlates with
- 310 acetabular version and coverage in hip dysplasia. *Clin Orthop Relat Res*.
- 311 2012;470(10):2827-35. doi: 10.1007/s11999-012-2370-z. PubMed PMID: 22544668;
- 312 PubMed Central PMCID: PMCPMC3441999.

- 313 12. Fujii M, Nakashima Y, Sato T, Akiyama M, Iwamoto Y. Pelvic deformity influences
314 acetabular version and coverage in hip dysplasia. Clin Orthop Relat Res.
315 2011;469(6):1735-42. doi: 10.1007/s11999-010-1746-1. PubMed PMID: 21203874;
316 PubMed Central PMCID: PMC3094603.
- 317 13. Kojima S, Kobayashi S, Saito N, Nawata M, Horiuchi H, Takaoka K. Morphological
318 characteristics of the bony birth canal in patients with developmental dysplasia of the hip
319 (DDH): investigation by three-dimensional CT. Journal of orthopaedic science : official
320 journal of the Japanese Orthopaedic Association. 2001;6(3):217-22. Epub 2001/08/03. doi:
321 10.1007/s007760100037. PubMed PMID: 11484113.
- 322 14. Sako N, Kaku N, Tagomori H, Tsumura H. Is the Iliac Wing Curved Inward in Patients with
323 Developmental Dysplasia of the Hip? Clin Orthop Surg. 2021;13(4):461-7. Epub
324 2021/12/07. doi: 10.4055/cios20230. PubMed PMID: 34868494; PubMed Central PMCID:
325 PMCPMC8609215.
- 326 15. Matsumura H, Tanijiri T, Kouchi M, Hanihara T, Friess M, Moiseyev V, et al. Global
327 patterns of the cranial form of modern human populations described by analysis of a 3D
328 surface homologous model. Sci Rep. 2022;12(1):13826. doi: 10.1038/s41598-022-15883-
329 3. PubMed PMID: 35970916; PubMed Central PMCID: PMCPMC9378707.
- 330 16. McKibbin B. Anatomical factors in the stability of the hip joint in the newborn. J Bone Joint
331 Surg Br. 1970;52(1):148-59. Epub 1970/02/01. PubMed PMID: 5436200.
- 332 17. Suzuki D, Nagoya S, Takashima H, Tateda K, Yamashita T. Three-dimensional orientation

- 333 of the acetabulum. *Clinical anatomy* (New York, NY). 2017;30(6):753-60. doi:
334 10.1002/ca.22945. PubMed PMID: 28631289.
- 335 18. Loop C. *Smooth Subdivision Surfaces Based on Triangles*. 1987.
- 336 19. Mochimaru M, Kouchi M, Dohi M. Analysis of 3-D human foot forms using the Free Form
337 Deformation method and its application in grading shoe lasts. *Ergonomics*.
338 2000;43(9):1301-13. Epub 2000/10/03. doi: 10.1080/001401300421752. PubMed PMID:
339 11014753.
- 340 20. Meunier P, Shu C, Xi P, editors. *Revealing the internal structure of human variability for
341 design purposes*2009.
- 342 21. Imaizumi K, Taniguchi K, Ogawa Y, Matsuzaki K, Nagata T, Mochimaru M, et al. Three-
343 dimensional analyses of aging-induced alterations in facial shape: a longitudinal study of
344 171 Japanese males. *International journal of legal medicine*. 2015;129(2):385-93. Epub
345 2014/11/10. doi: 10.1007/s00414-014-1114-x. PubMed PMID: 25381651.
- 346 22. Inoue K, Nakano H, Sumida T, Yamada T, Otawa N, Fukuda N, et al. A novel
347 measurement method for the morphology of the mandibular ramus using homologous
348 modelling. *Dento maxillo facial radiology*. 2015;44(8):20150062. Epub 2015/07/07. doi:
349 10.1259/dmfr.20150062. PubMed PMID: 26143939; PubMed Central PMCID:
350 PMC4628420.
- 351 23. Kato A, Kouchi M, Mochimaru M, Isomura A, Ohno N. A Geometric Morphometric Analysis
352 of the Crown Form of the Maxillary Central Incisor in Humans. *Dental Anthropology*

- 353 Journal. 2018.
- 354 24. Fukuta M, Kato C, Biwasaka H, Usui A, Horita T, Kanno S, et al. Sex estimation of the
355 pelvis by deep learning of two-dimensional depth images generated from homologous
356 models of three-dimensional computed tomography images. *Forensic Science
357 International: Reports*. 2020;2:100129. doi: <https://doi.org/10.1016/j.fsir.2020.100129>.
- 358 25. Kuwahara K, Hikosaka M, Takamatsu A, Miyazaki O, Nosaka S, Ogawa R, et al. Average
359 Models and 3-dimensional Growth Patterns of the Healthy Infant Cranium. *Plastic and
360 reconstructive surgery Global open*. 2020;8(8):e3032. Epub 2020/09/29. doi:
361 10.1097/gox.0000000000003032. PubMed PMID: 32983787; PubMed Central PMCID:
362 PMC7489617.
- 363 26. Goto L, Lee W, Huysmans T, Molenbroek JFM, Goossens RHM. The Variation in 3D Face
364 Shapes of Dutch Children for Mask Design. *Applied Sciences*. 2021;11(15):6843. PubMed
365 PMID: doi:10.3390/app11156843.
- 366 27. Besl PJ, McKay ND. A method for registration of 3-D shapes. *IEEE Transactions on
367 Pattern Analysis and Machine Intelligence*. 1992;14(2):239-56. doi: 10.1109/34.121791.
- 368 28. Zou KH, O'Malley AJ, Mauri L. Receiver-operating characteristic analysis for evaluating
369 diagnostic tests and predictive models. *Circulation*. 2007;115(5):654-7. Epub 2007/02/07.
370 doi: 10.1161/circulationaha.105.594929. PubMed PMID: 17283280.
- 371 29. Tamura S, Miki H, Tsuda K, Takao M, Hattori A, Suzuki N, et al. Hip range of motion
372 during daily activities in patients with posterior pelvic tilt from supine to standing position. *J*

- 373 Orthop Res. 2015;33(4):542-7. doi: 10.1002/jor.22799. PubMed PMID: 25492855.
- 374 30. Hinderaker T, Daltveit AK, Irgens LM, Udén A, Reikerås O. The impact of intra-uterine
375 factors on neonatal hip instability. An analysis of 1,059,479 children in Norway. Acta
376 orthopaedica Scandinavica. 1994;65(3):239-42. Epub 1994/06/01. doi:
377 10.3109/17453679408995446. PubMed PMID: 8042471.
- 378 31. Suzuki S, Yamamuro T. Correlation of fetal posture and congenital dislocation of the hip.
379 Acta orthopaedica Scandinavica. 1986;57(1):81-4. Epub 1986/02/01. doi:
380 10.3109/17453678608993223. PubMed PMID: 3962640.
- 381 32. De Pellegrin M, Moharamzadeh D. Developmental dysplasia of the hip in twins: the
382 importance of mechanical factors in the etiology of DDH. Journal of pediatric orthopedics.
383 2010;30(8):774-8. Epub 2010/11/26. doi: 10.1097/BPO.0b013e3181fc35c0. PubMed
384 PMID: 21102200.
- 385 33. Nakamura S, Ninomiya S, Nakamura T. Primary osteoarthritis of the hip joint in Japan. Clin
386 Orthop Relat Res. 1989;(241):190-6. Epub 1989/04/01. PubMed PMID: 2924462.
- 387 34. Okuda T, Fujita T, Kaneuji A, Miaki K, Yasuda Y, Matsumoto T. Stage-specific sagittal
388 spinopelvic alignment changes in osteoarthritis of the hip secondary to developmental hip
389 dysplasia. Spine. 2007;32(26):E816-9. Epub 2007/12/20. doi:
390 10.1097/BRS.0b013e31815ce695. PubMed PMID: 18091476.
- 391 35. During J, Goudfrooij H, Keessen W, Beeker TW, Crowe A. Toward standards for posture.
392 Postural characteristics of the lower back system in normal and pathologic conditions.

- 393 Spine. 1985;10(1):83-7. Epub 1985/01/01. PubMed PMID: 3157224.
- 394 36. Adams MA, Hutton WC. The effect of posture on the role of the apophysial joints in
395 resisting intervertebral compressive forces. J Bone Joint Surg Br. 1980;62(3):358-62. Epub
396 1980/08/01. doi: 10.1302/0301-620x.62b3.6447702. PubMed PMID: 6447702.
- 397 37. Norton BJ, Sahrman SA, Van Dillen LR. Differences in measurements of lumbar
398 curvature related to gender and low back pain. The Journal of orthopaedic and sports
399 physical therapy. 2004;34(9):524-34. Epub 2004/10/21. doi: 10.2519/jospt.2004.34.9.524.
400 PubMed PMID: 15493520.
- 401 38. Provan JL, Moreau P, MacNab I. Pitfalls in the diagnosis of leg pain. Canadian Medical
402 Association journal. 1979;121(2):167-71. Epub 1979/07/21. PubMed PMID: 229951;
403 PubMed Central PMCID: PMCPMC1704280.
- 404 39. Shoji T, Yasunaga Y, Yamasaki T, Izumi S, Adachi N, Ochi M. Anterior Inferior Iliac Spine
405 Bone Morphology in Hip Dysplasia and Its Effect on Hip Range of Motion in Total Hip
406 Arthroplasty. J Arthroplasty. 2016;31(9):2058-63. Epub 2016/03/26. doi:
407 10.1016/j.arth.2016.02.018. PubMed PMID: 27012430.
- 408 40. Jacobsen JS, Hölmich P, Thorborg K, Bolvig L, Jakobsen SS, Søballe K, et al. Muscle-
409 tendon-related pain in 100 patients with hip dysplasia: prevalence and associations with
410 self-reported hip disability and muscle strength. Journal of hip preservation surgery.
411 2018;5(1):39-46. Epub 2018/02/10. doi: 10.1093/jhps/hnx041. PubMed PMID: 29423249;
412 PubMed Central PMCID: PMCPMC5798082.

- 413 41. Hardcastle P, Nade S. The significance of the Trendelenburg test. *J Bone Joint Surg Br.*
414 1985;67(5):741-6. Epub 1985/11/01. doi: 10.1302/0301-620x.67b5.4055873. PubMed
415 PMID: 4055873.
- 416 42. Penney T, Ploughman M, Austin MW, Behm DG, Byrne JM. Determining the activation of
417 gluteus medius and the validity of the single leg stance test in chronic, nonspecific low
418 back pain. *Archives of physical medicine and rehabilitation.* 2014;95(10):1969-76. Epub
419 2014/07/06. doi: 10.1016/j.apmr.2014.06.009. PubMed PMID: 24992020.
- 420 43. Sadler S, Cassidy S, Peterson B, Spink M, Chuter V. Gluteus medius muscle function in
421 people with and without low back pain: a systematic review. *BMC Musculoskelet Disord.*
422 2019;20(1):463. doi: 10.1186/s12891-019-2833-4. PubMed PMID: 31638962; PubMed
423 Central PMCID: PMCPMC6805550.
- 424 44. Brosseau L, Wells GA, Pugh AG, Smith CA, Rahman P, Álvarez Gallardo IC, et al. Ottawa
425 Panel evidence-based clinical practice guidelines for therapeutic exercise in the
426 management of hip osteoarthritis. *Clinical rehabilitation.* 2016;30(10):935-46. Epub
427 2015/09/25. doi: 10.1177/0269215515606198. PubMed PMID: 26400851.
- 428 45. Marshall PW, Patel H, Callaghan JP. Gluteus medius strength, endurance, and co-
429 activation in the development of low back pain during prolonged standing. *Hum Mov Sci.*
430 2011;30(1):63-73. doi: 10.1016/j.humov.2010.08.017. PubMed PMID: 21227522.
- 431 46. Sorensen CJ, Norton BJ, Callaghan JP, Hwang CT, Van Dillen LR. Is lumbar lordosis
432 related to low back pain development during prolonged standing? *Manual therapy.*

433 2015;20(4):553-7. Epub 2015/02/01. doi: 10.1016/j.math.2015.01.001. PubMed PMID:

434 25637464; PubMed Central PMCID: PMC4469524.

435

437 **Tables**

438

439 Table 1. List of principal components up to the 6th order.

principal component	contributing ratio (%)	accumulative contributing ratio (%)	AUC	p value of χ^2 test (null hypothesis: AUC=0.5)
1	16.785	16.785	0.8692	< 0.001**
2	12.497	29.282	0.5904	0.1170
3	9.471	38.753	0.6152	0.0418*
4	5.485	44.239	0.5284	0.6265
5	4.356	48.595	0.5440	0.4531
6	4.142	52.737	0.6532	0.0058**

440

* indicates $p < 0.05$, ** indicates $p < 0.01$

441

442 Table 2. Correlation coefficients between the PCs and the pelvic measurements.

Measurements	PC1	PC3	PC6
Sharp angle	0.7795	0.2619	0.1685
Iliac wing angle	0.7463	0.1783	0.3095
Sacral slope	0.2711	0.0616	0.3959
Pelvic inclination	0.7469	0.0424	0.1520
Ischiopubic angle	0.4802	0.0045	0.2735

443

444

445 **Figure captions**

446 **Figure 1.** Creation of a homologous model by template fitting. If the models to be analyzed (A,
447 B) have different shapes and numbers of vertices, they cannot be compared. Therefore, the
448 template model is transformed and superimposed based on landmarks into the models to be
449 analyzed. The created model is called a homologous model, and it can be assumed that all
450 vertices are homologous to the template model. Comparisons can be made by converting all
451 models to be analyzed into homologous models (C, D).

452
453 **Figure 2.** Homologous modeling of the actual pelvis. A homologous model with corresponding
454 vertices is created from a template consisting of 15,235 vertices.

455
456 **Figure 3.** The pelvic angles measured in this study.

457
458 **Figure 4.** The ROC curve of DDH for 1st-20th principal components. The 1st, 3rd, and 6th
459 principal components are shown in red.

460
461 **Figure 5.** Histograms of principal component scores (PC1, PC3, and PC6).

462
463 **Figure 6.** The virtual morphologies when the first principal component (PC1) is changed from -
464 3SD to +3SD.

465

466 **Figure 7.** The virtual morphologies when PC3 is changed from -3SD to +3SD.

467

468 **Figure 8.** The virtual morphologies when PC6 is changed from -3SD to +3SD.

469

470 **Figure 9.** Scatter plots between the PC1, PC3, and PC6 and the pelvic measurements. Blue

471 dots: the Normal group, Red dots: the DDH group.

472

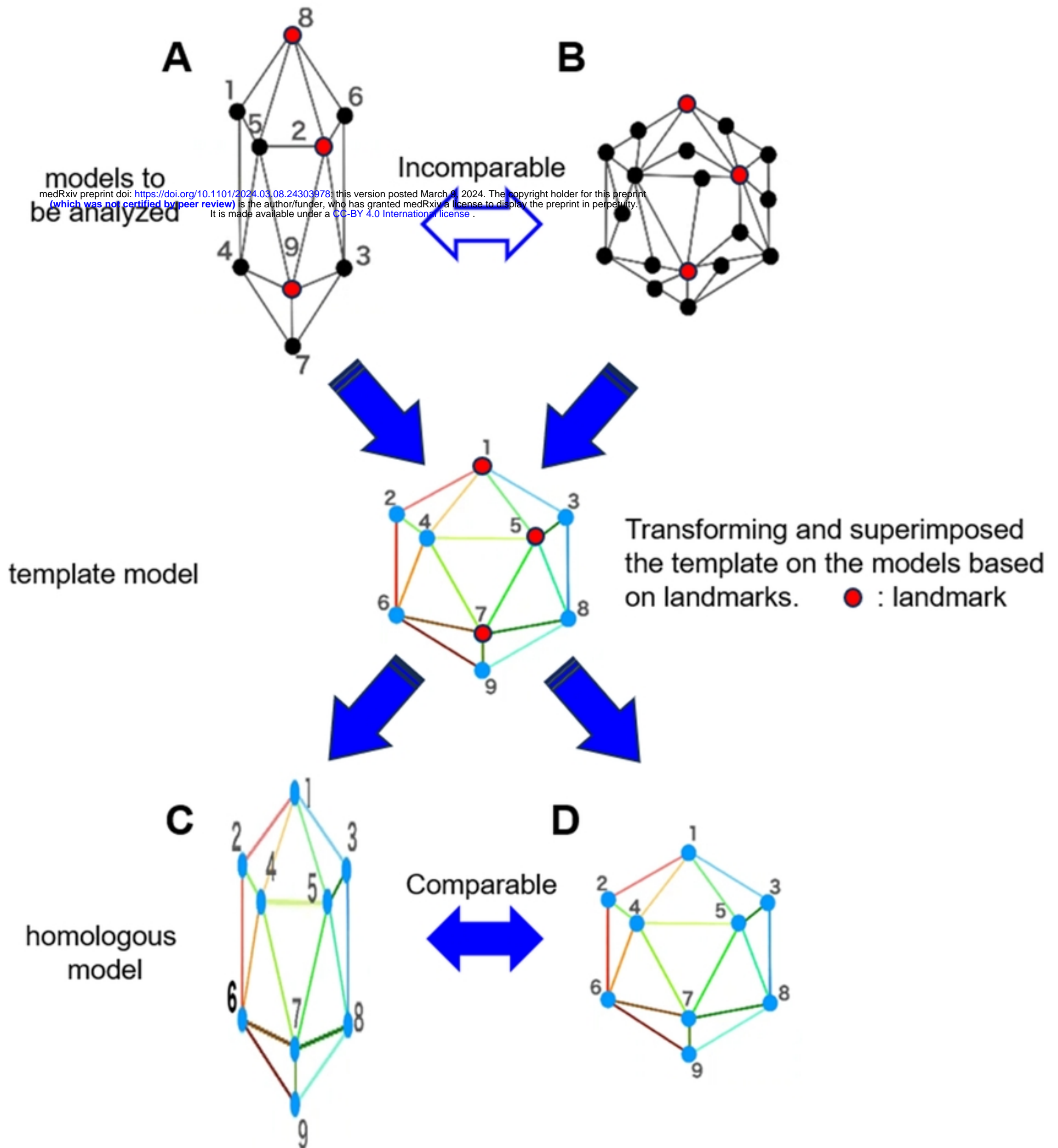


Figure 1

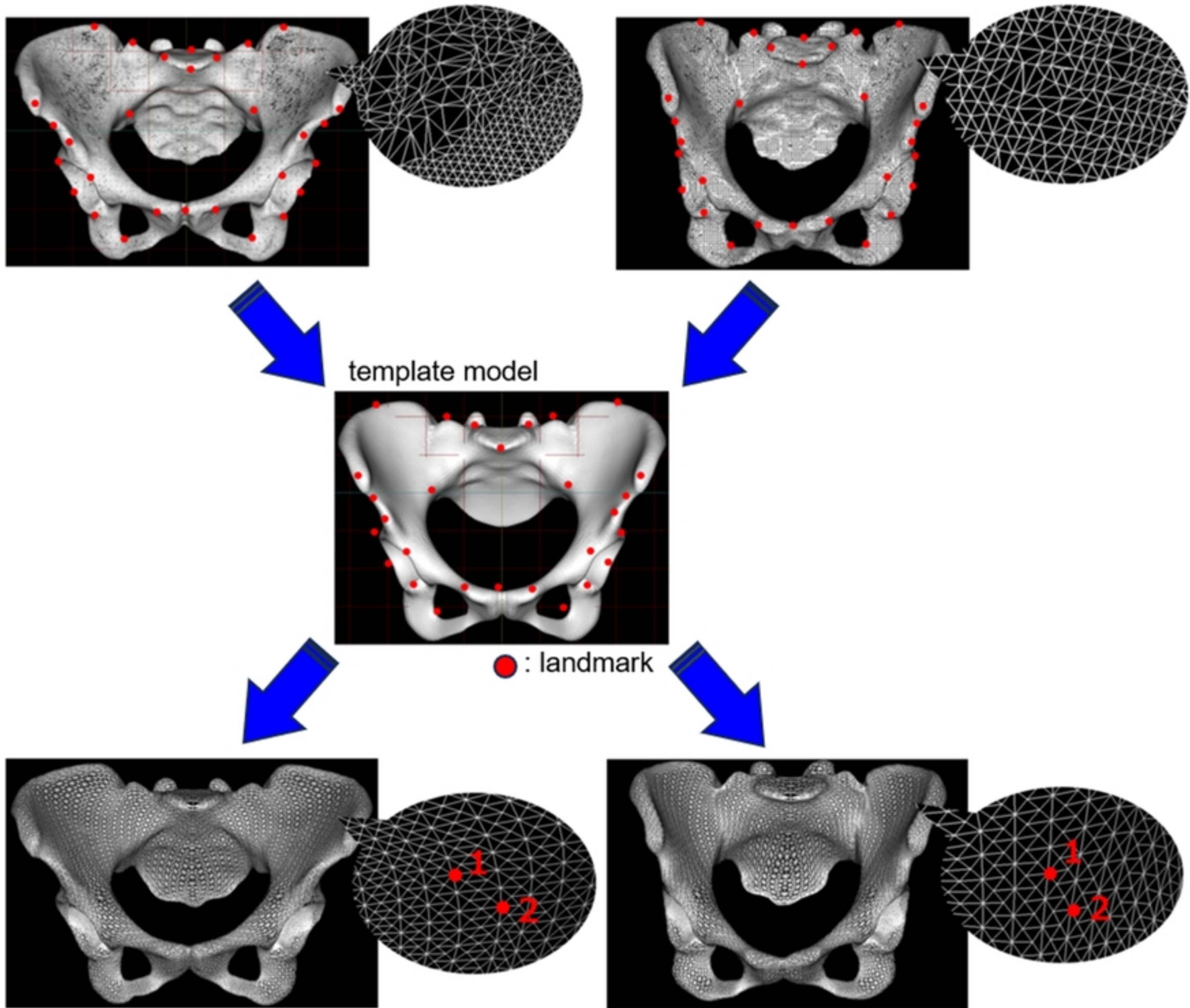
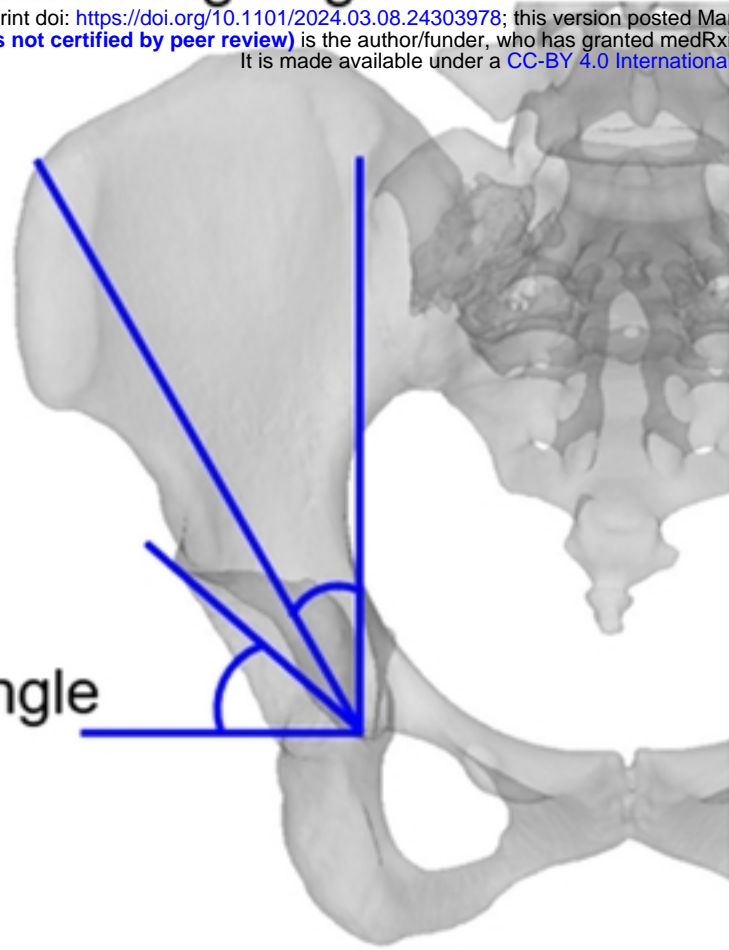


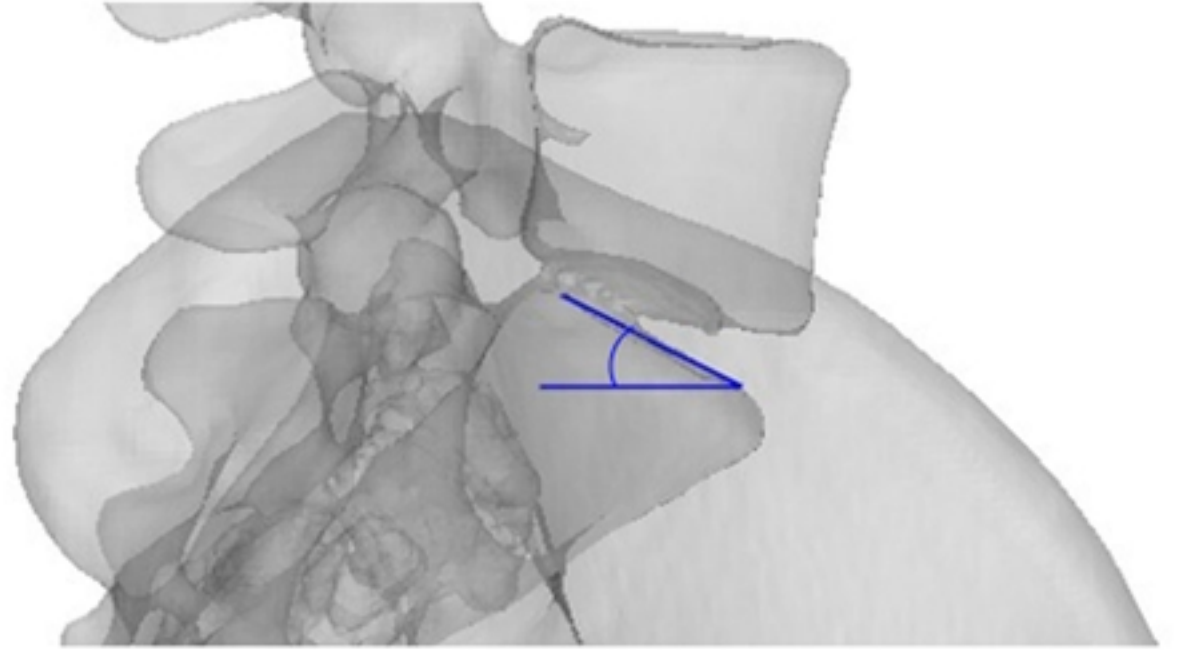
Figure 2

iliac wing angle

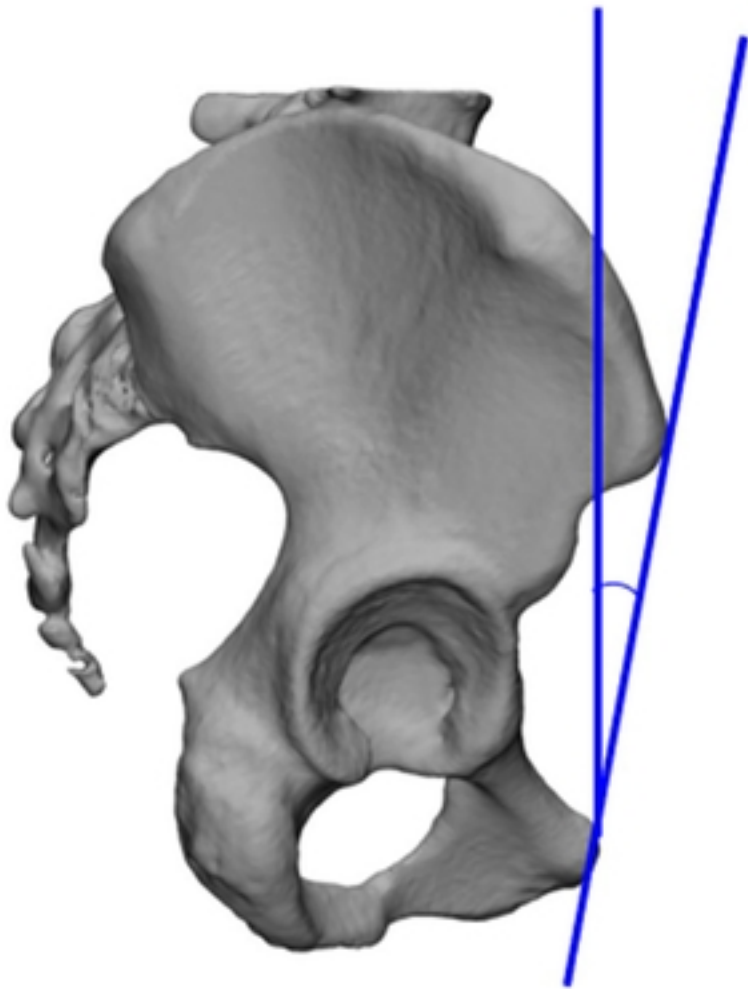
medRxiv preprint doi: <https://doi.org/10.1101/2024.03.08.24303978>; this version posted March 9, 2024. The copyright holder for this preprint (which was not certified by peer review) is the author/funder, who has granted medRxiv a license to display the preprint in perpetuity. It is made available under a [CC-BY 4.0 International license](https://creativecommons.org/licenses/by/4.0/).



sacral slope



pelvic inclination



ischiopubic angle

ischial spine

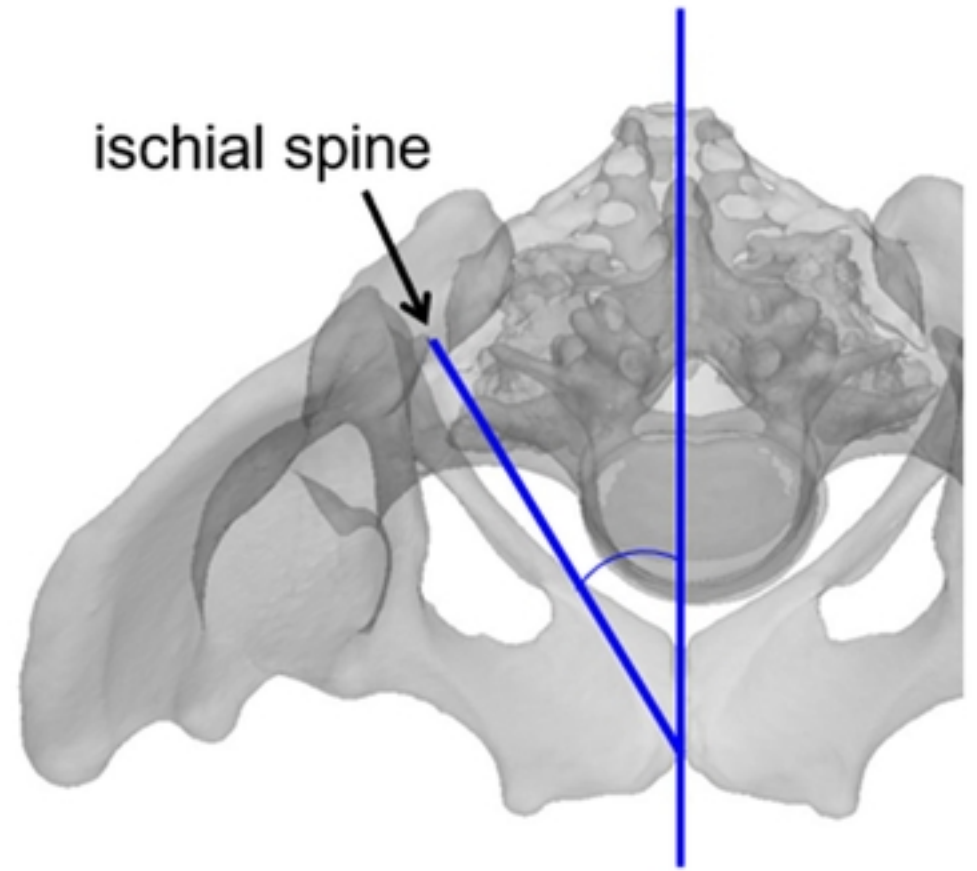


Figure 3

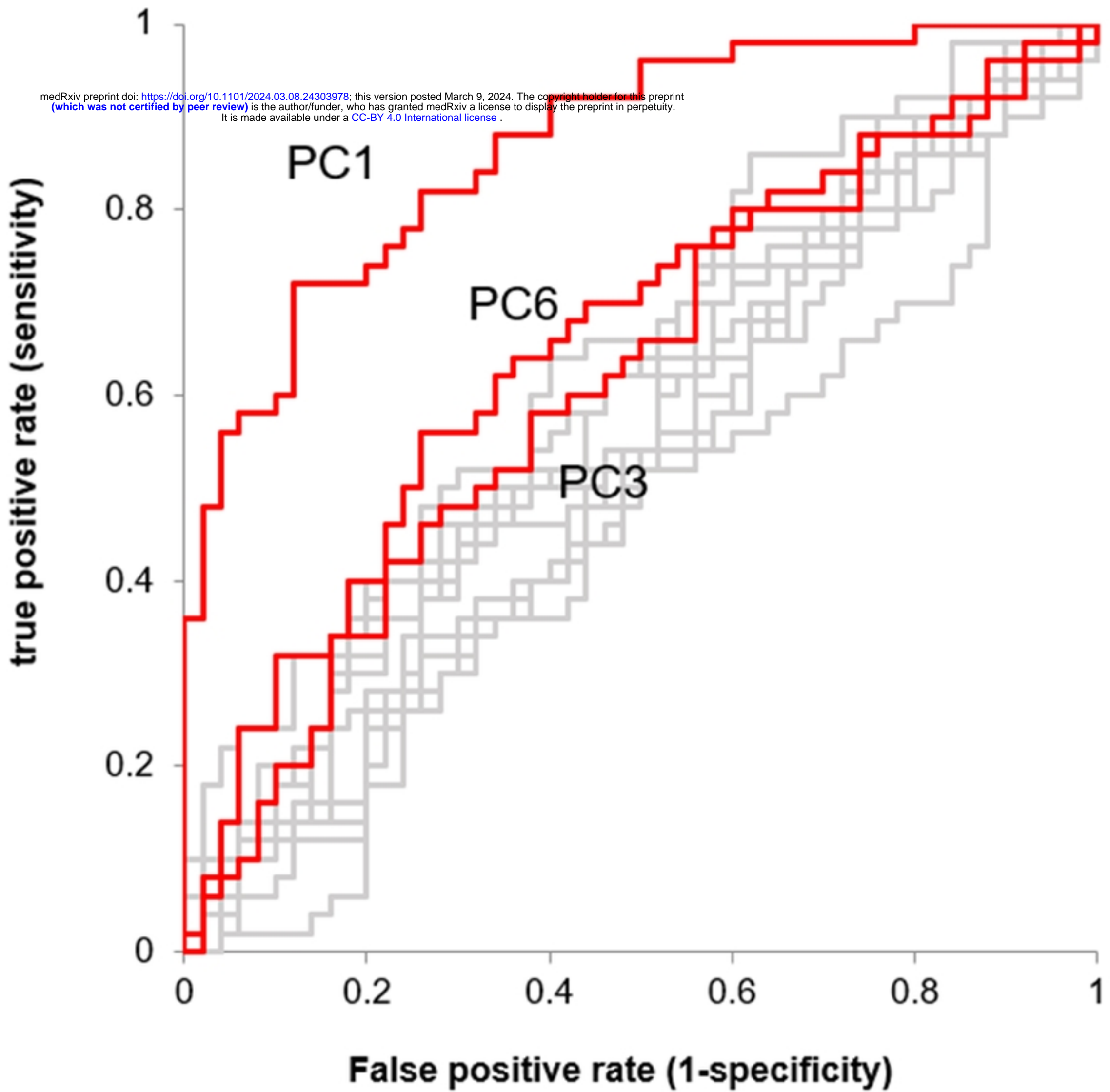


Figure 4

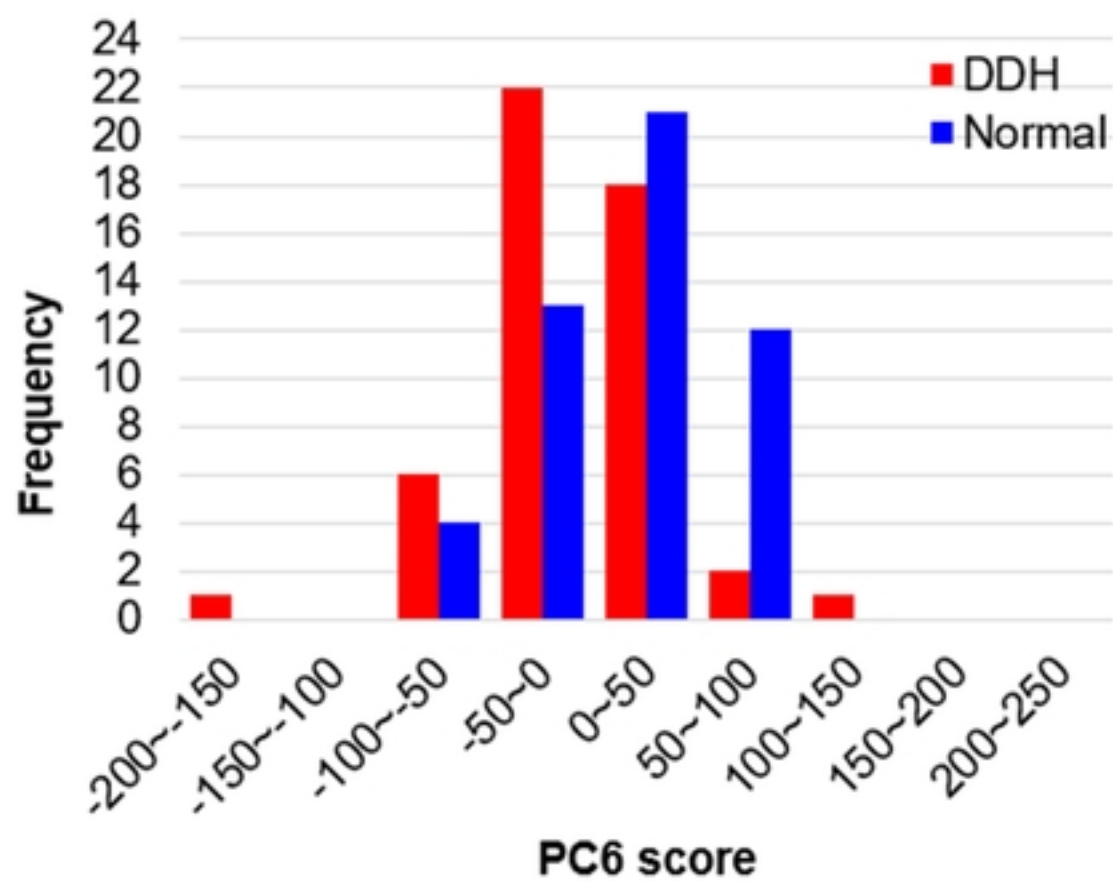
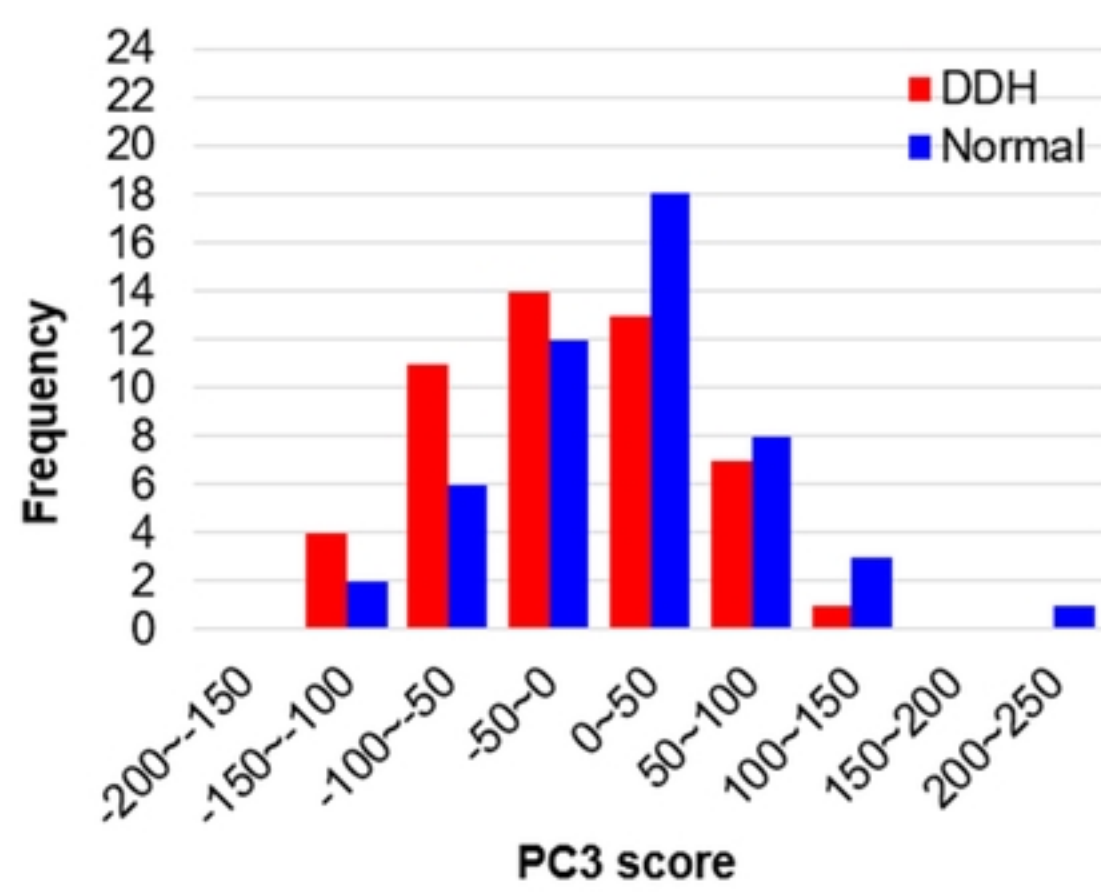
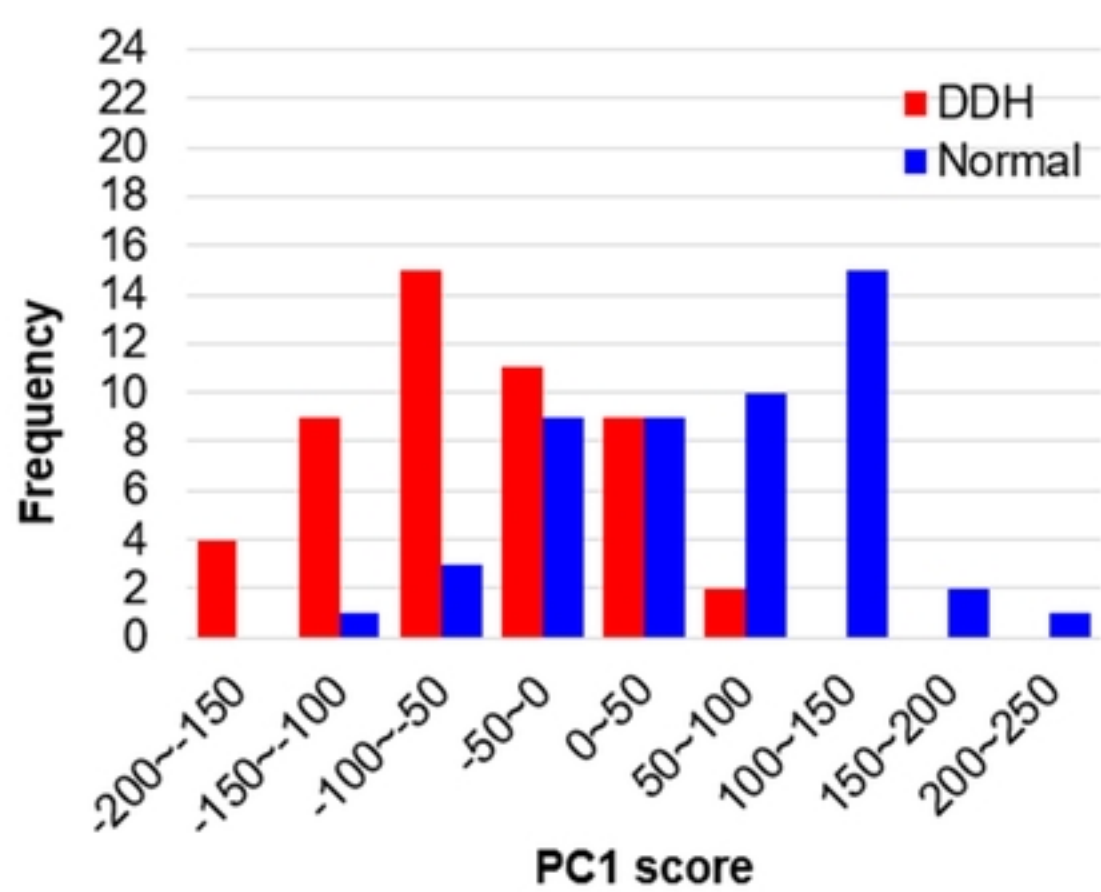
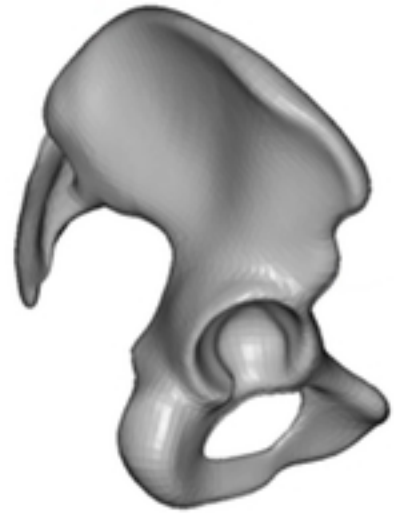
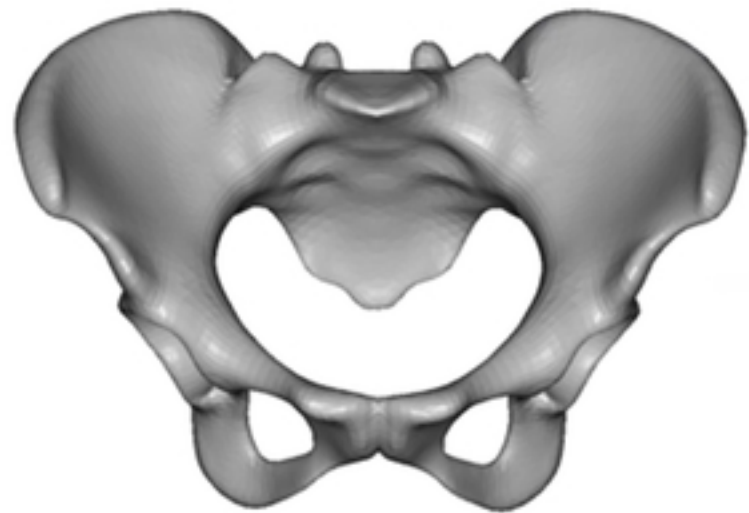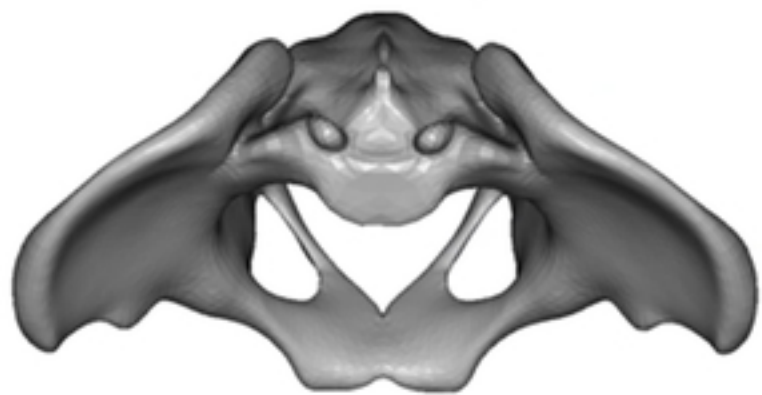


Figure 5

Normal



DDH

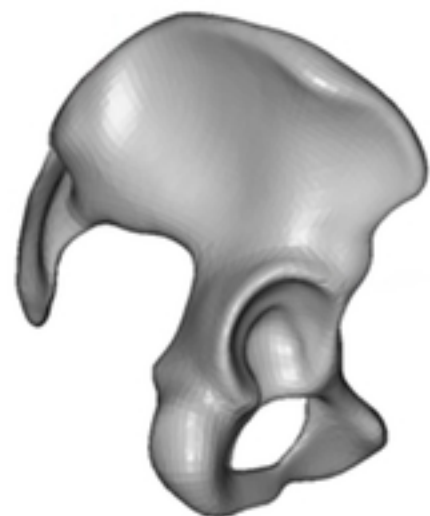
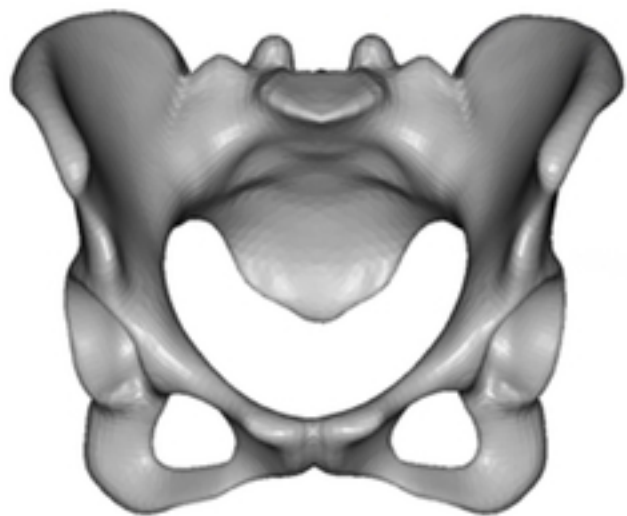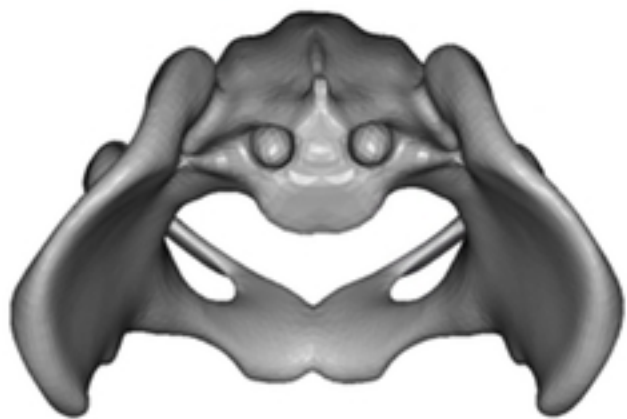
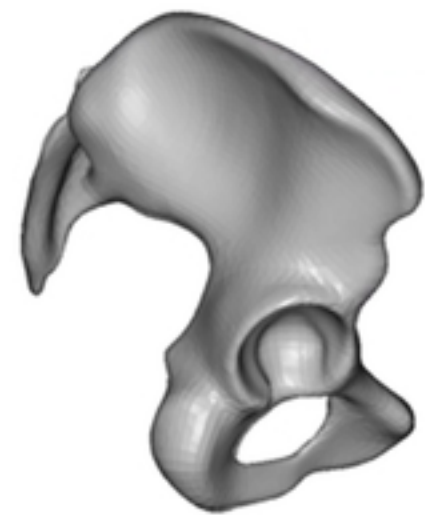
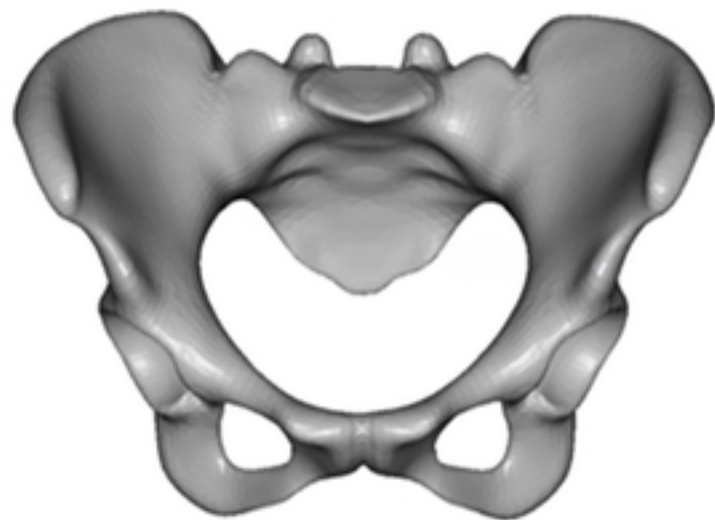
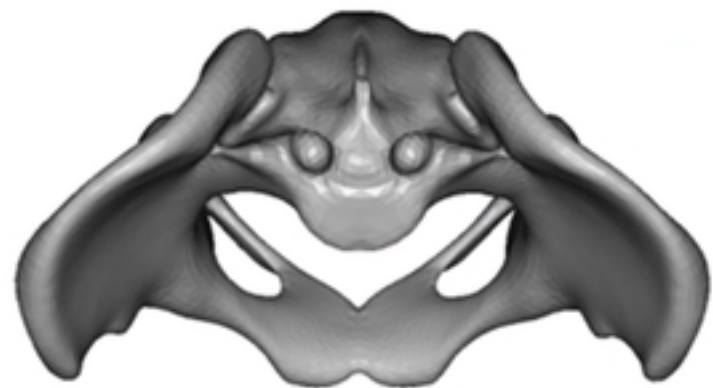


Figure 6

Normal



DDH

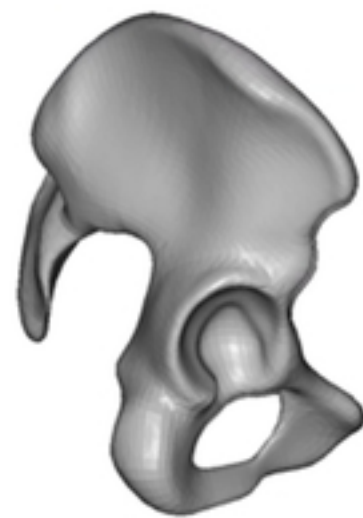
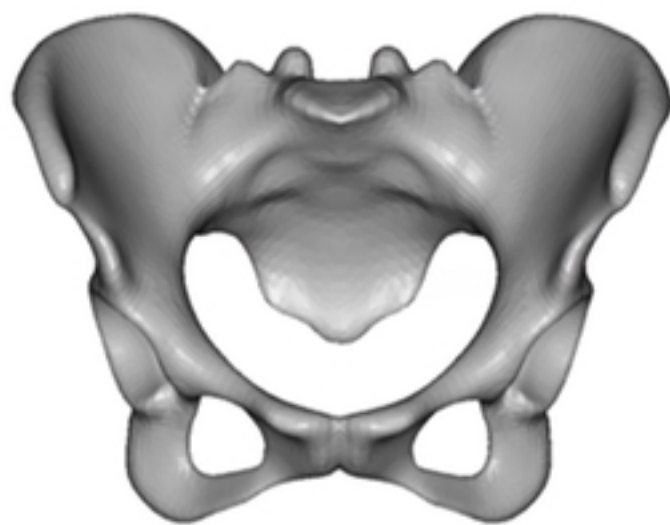
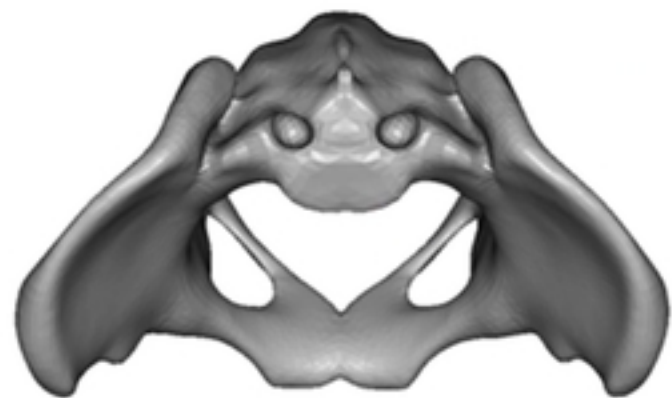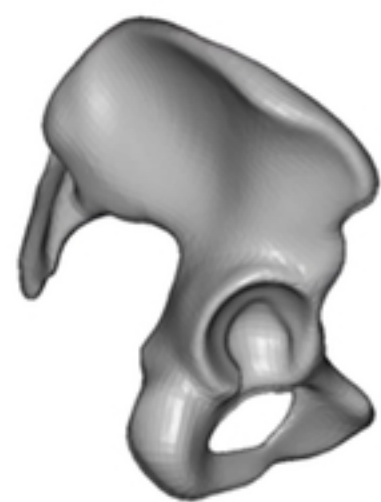
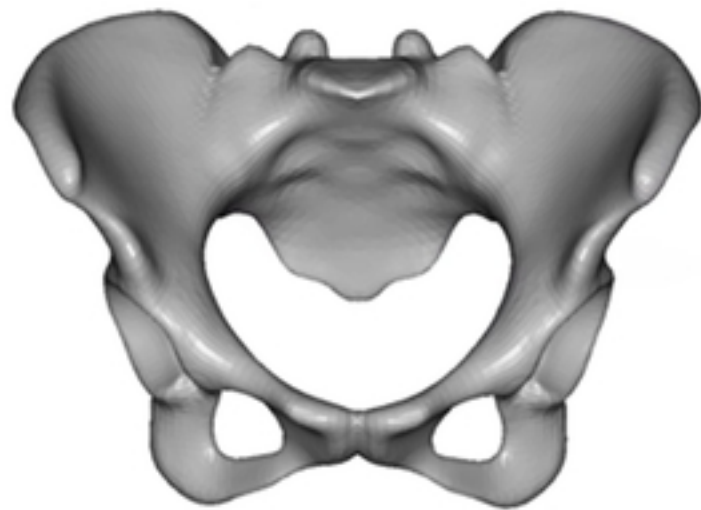
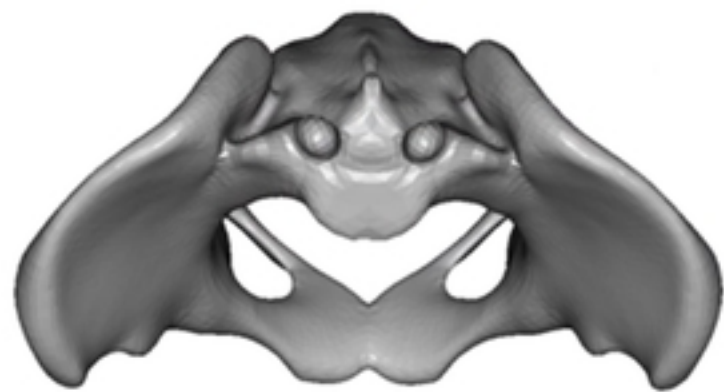


Figure 7

Normal



DDH

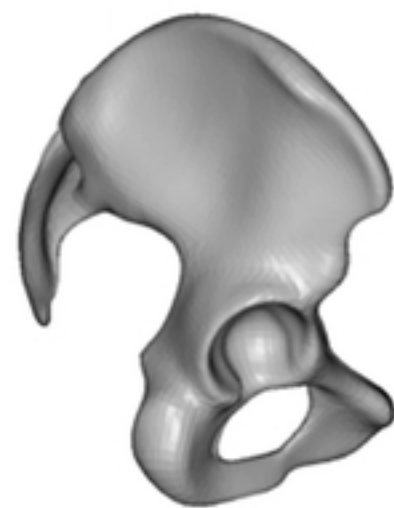
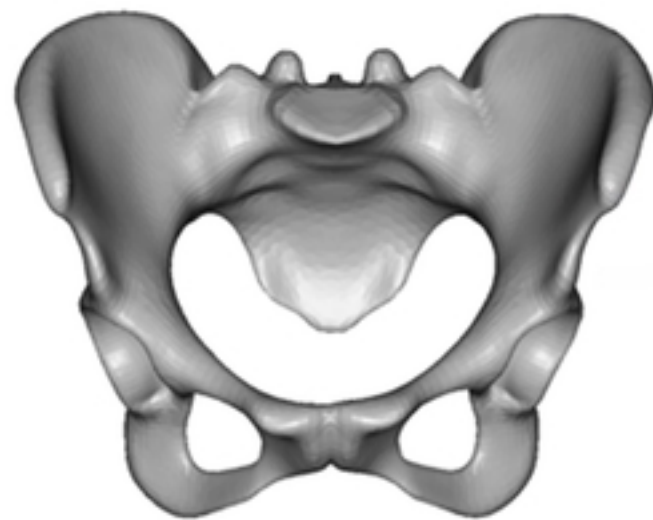
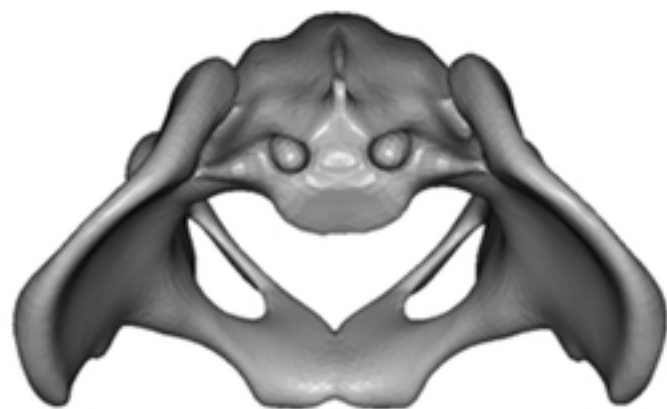
Figure 8

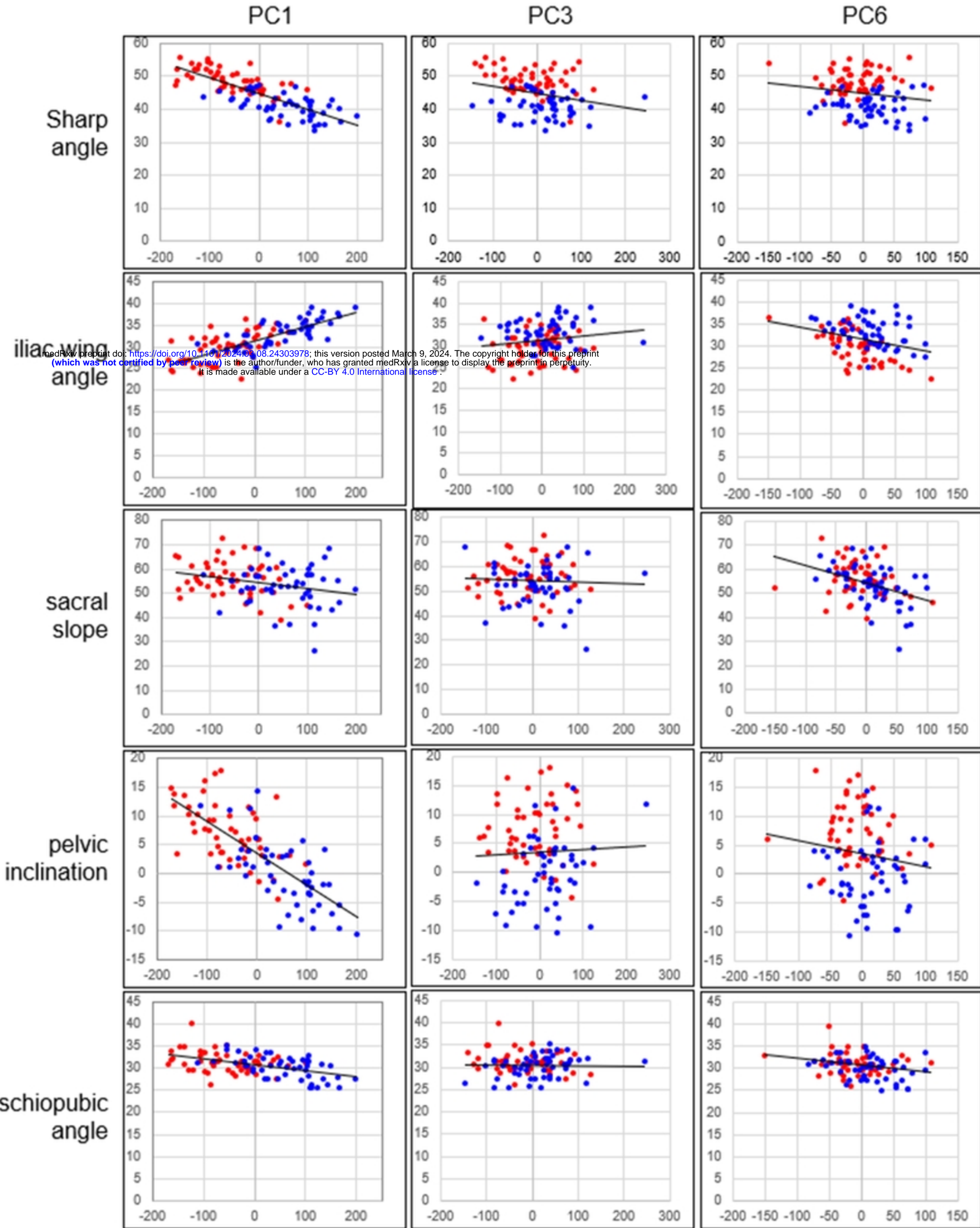


Figure 9