

1 **Routine Intracoronary Imaging-guided Left Main Coronary Intervention**

2

3 Yoshinobu Murasato¹, MD, PhD, Hitoshi Nakashima², MD, PhD, Hiroshi Sugino³, MD, PhD,

4 Masaya Arikawa⁴, MD, PhD, Fumiaki Mori⁵, MD, PhD, Yasunori Ueda⁶, MD, PhD, Keisuke

5 Matsumura⁷, MD, PhD, Mitsuru Abe⁸, MD, PhD, Tomomi Koizumi⁹, MD, PhD, Mitsuhiro

6 Shimomura¹⁰, MD, PhD, Kazuteru Fujimoto¹¹, MD, PhD, Takahiro Saeki¹², MD, PhD, Shogo

7 Imagawa¹³, MD, PhD, Takashi Takenaka¹⁴, MD, PhD, Yukiko Morita¹⁵, MD, PhD, Katsuro

8 Kashima¹⁶, MD, PhD, Akira Takami¹⁷, MD, PhD, Yujiro Ono¹⁸, MD, PhD, Atsuki Fukae¹⁹,

9 MD, PhD, and Hisako Yoshida²⁰, PhD on behalf of LM-JANHO investigators

10

11 ¹Department of Cardiology, National Hospital Organization Kyushu Medical Center,

12 Fukuoka, Japan

13 ²Department of Cardiology, National Hospital Organization Kagoshima Medical Center,

14 Kagoshima, Japan

15 ³Department of Cardiology, National Hospital Organization Kure Medical Center, Kure,

16 Japan

17 ⁴Department of Cardiology, National Hospital Organization Oita Medical Center, Oita, Japan

18 ⁵Department of Cardiology, National Hospital Organization Yokohama Medical Center,

19 Yokohama, Japan

NOTE: This preprint reports new research that has not been certified by peer review and should not be used to guide clinical practice.

1 ⁶Cardiovascular Division, National Hospital Organization Osaka National Hospital, Osaka,

2 Japan

3 ⁷Department of Cardiology, National Hospital Organization Saitama Hospital, Wako, Japan

4 ⁸Department of Cardiology, National Hospital Organization Kyoto Medical Center, Kyoto,

5 Japan

6 ⁹Department of Cardiology, National Hospital Organization Mito Medical Center, Mito,

7 Japan

8 ¹⁰Department of Cardiology, National Hospital Organization Ureshino Medical Center,

9 Ureshino, Japan

10 ¹¹Department of Cardiology, National Hospital Organization Kumamoto Medical Center,

11 Kumamoto, Japan

12 ¹²Department of Cardiology, National Hospital Organization Kanazawa Medical Center,

13 Kanazawa, Japan

14 ¹³Department of Cardiology, National Hospital Organization Hakodate Hospital, Hakodate,

15 Japan

16 ¹⁴Department of Cardiology, National Hospital Organization Hokkaido Medical Center,

17 Sapporo, Japan

18 ¹⁵Department of Cardiology, National Hospital Organization Sagamihara Hospital,

19 Sagamihara, Japan

1 ¹⁶Department of Cardiology, National Hospital Organization Ibusuki Medical Center, Ibusuki,

2 Japan

3 ¹⁷Department of Cardiology, National Hospital Organization Chiba Medical Center, Chiba,

4 Japan

5 ¹⁸Department of Cardiology, National Hospital Organization Higashi Hiroshima Medical

6 Center, Higashi Hiroshima, Japan

7 ¹⁹Department of Cardiology, National Hospital Organization Nagasaki Medical Center,

8 Omura, Japan

9 ²⁰Department of Medical Statistics, Osaka Metropolitan University, Osaka, Japan

10

11 *Corresponding author:

12 Yoshinobu Murasato, MD, PhD

13 Department of Cardiology, National Hospital Organization Kyushu Medical Center

14 1-8-1, Jigyohama, Chuo, Fukuoka 810-8563, Japan

15 Tel: +81-92-852-0700, Fax: +81-92-847-8802, E-mail: y.murasato@gmail.com

16

17 **Short title:** Imaging-guided Left Main Coronary Intervention

18

19 **Total words:** 7951 words

1 **Abstract**

2 **Background:** Left main (LM) percutaneous coronary intervention (PCI) with routine
3 intracoronary imaging guidance is recommended; however, its real-world effectiveness
4 remains unclear. This study aimed to investigate the outcomes in a Japanese National
5 Hospital Organization cohort in which routine imaging guidance was adopted.

6 **Methods:** Of the 806 consecutive patients undergoing drug-eluting stent implantation for de
7 novo unprotected LM lesions across 19 hospitals, 743 were analyzed after excluding 63
8 owing to criteria mismatch or incomplete follow-up. The primary endpoint was 1-year major
9 adverse cardiovascular and cerebrovascular events (MACCE), comprising all-cause death,
10 cerebrovascular disorder, clinical-driven revascularization, and myocardial infarction.

11 **Results:** The cohort exhibited increased prevalences of diabetes mellitus, prior myocardial
12 infarction, and prior revascularization. Acute coronary syndrome was present in 31.2% of the
13 patients, with 39.3% classified as Canadian Cardiovascular Society functional angina (CCS)
14 class \geq III. LM bifurcation lesions were observed in 78.0% of the patients, with two-stent
15 implantation in 8.8% of the patients. MACCE occurred in 17.5% of the patients, with target
16 lesion revascularization and cardiac death rates of 2.0% and 3.4%, respectively. Independent
17 risk factors for MACCE included CCS class \geq III (hazard ratio [HR], 2.07), mechanical
18 cardiac support device use (HR, 2.17), two-stent implantation (HR, 2.49), 10% increase in
19 left ventricular ejection fraction (HR, 0.72), and radial access (HR, 0.62).

1 **Conclusion:** Routine imaging-guided LM-PCI is associated with a lower incidence of target
2 lesion revascularization and cardiac death. However, severe left ventricular dysfunction and
3 multiple-vessel involvement are associated with higher mortality and revascularization risks,
4 requiring comprehensive management beyond imaging-guided PCI.

5

6 **Keywords:** Left main coronary artery, Percutaneous coronary intervention, Intracoronary
7 imaging

8

1 **Non-standard Abbreviations and Acronyms**

2 CABG: coronary artery bypass graft

3 CCS: Canadian Cardiovascular Society functional angina classification

4 CI: confidence interval

5 DES: drug-eluting stent

6 HR: hazard ratio

7 IVUS: intravascular ultrasound

8 KBI: kissing balloon inflation

9 LAD: left anterior descending artery

10 LCX: left circumflex artery

11 LM: left main

12 LM-JANHO: left main coronary intervention in a cohort of Japanese National Hospital

13 Organization

14 MACCE: major adverse cardiovascular and cerebrovascular events

15 MV: main vessel

16 OFDI: optical frequency dependent imaging

17 OCT: optical coherence tomography

18 OR: odds ratio

19 PCI: percutaneous coronary intervention

- 1 POT: proximal optimal technique
- 2 SB: side branch
- 3 SYNTAX: Synergy between Percutaneous Coronary Intervention with Taxus and Cardiac
- 4 Surgery
- 5 TLR: target lesion revascularization
- 6 TVR: target vessel revascularization
- 7
- 8

1 **Clinical Perspective**

2 **What is new?**

3 ● This study clarifies the clinical outcomes of left main coronary intervention guided by
4 routine intracoronary imaging, revealing a low frequency of target lesion
5 revascularization and cardiac death.

6 ● Despite the favorable local efficacy of imaging guidance, patients with severe left
7 ventricular dysfunction and multiple-vessel involvement still face elevated risks of
8 mortality and revascularization.

9

10 **What are the clinical implications?**

11 ● Intracoronary imaging guidance in the left main coronary artery is crucial for optimizing
12 intervention treatments and enhancing local efficacy at the treated sites.

13 ● Despite these improvements, the high mortality rate associated with serious myocardial
14 damage from left main coronary artery obstruction underscores the importance of careful
15 consideration in such cases.

16 ● Coronary artery disease involving the left main and multiple vessels carries an elevated
17 risk of additional revascularizations beyond the target lesion, emphasizing the need for
18 comprehensive management strategies.

19

1 **Introduction**

2 Intracoronary imaging guidance is recommended for complex percutaneous coronary
3 intervention (PCI) to reduce mortality and target lesion revascularization¹⁻⁸. It is also
4 recommended for left main (LM) PCI^{9, 10}, which has a large perfusion territory and is
5 associated with a higher risk of hemodynamic collapse or fatal events. Imaging guidance is
6 associated with sufficient stent expansion with less malapposition owing to optimal device
7 selection and swift detection of stent failure or deformation^{11, 12}. Additionally,
8 imaging-guided bifurcation intervention is useful for the prediction of side branch (SB)
9 compromise¹¹ and prevention of unnecessary aggressive SB treatments, such as two-stent
10 deployment or oversized SB dilation, leading to overtreatment regardless of uncertain
11 angiographic findings in the bifurcation¹³.

12 A meta-analysis of 11 randomized control trials comparing LM-PCI and coronary artery
13 bypass graft (CABG), including 11,518 patients, demonstrated similar rates of all-cause
14 mortality when the Synergy between Percutaneous Coronary Intervention with Taxus and
15 Cardiac Surgery (SYNTAX) score was <32 ¹⁴. Therefore, the guidelines have been changed so
16 that LM-PCI is ranked in class I treatment, similar to CABG, when the SYNTAX score is
17 <22 , which indicates that anatomical lesion complexity is low⁹.

18 Intravascular imaging guidance has become more popular in Japan than in other countries
19 because of reimbursement of intracoronary imaging devices through social insurance.

1 Intracoronary imaging guidance was used in 95% of all PCIs in the nationwide survey in
2 2014¹⁵. In the Japanese Circulation Society 2018 Guidelines on Revascularization of Stable
3 Coronary Artery Disease, intravascular ultrasound (IVUS) guidance is strongly recommended
4 as class I in LM-PCI, and optical coherence tomography (OCT)/optical frequency-dependent
5 imaging (OFDI) guidance is also recommended as class IIa in bifurcation PCI¹⁰. However,
6 most of the evidences are derived from small-scale randomized trials comparing imaging
7 guidance and angio-guidance or propensity-match comparison in large-scale registries, in
8 which more complex lesions are selected according to the cases treated under imaging
9 guidance³. Therefore, the efficacy of routine intracoronary imaging for LM-PCI in daily
10 practice has not yet been clarified. We aimed to investigate the clinical outcomes of LM-PCI
11 in a large cohort of the Japanese National Hospital Organization (LM-JANHO) group, where
12 intracoronary imaging guidance is routinely used.

13

14 **Methods**

15 *Study population and design*

16 The LM-JANHO is a multicenter, retrospective, observational registry study. In total, 806
17 consecutive patients who underwent LM-PCI with a drug-eluting stent (DES) between
18 January 2016 and December 2020 were retrospectively enrolled from 19 institutes in the
19 Japanese National Hospital Organization group.

1 The inclusion criteria were as follows: (1) de novo LM lesions including significant stenosis
2 in the LM ($\geq 50\%$) and/or daughter branches ($\geq 75\%$) within a distance of 5 mm from the
3 carina, which were treated with DES implantation in LM or crossover from LM to daughter
4 branches; (2) suitable lesion for DES implantation in the LM; (3) patient age >20 years; and
5 (4) tolerability of dual antiplatelet therapy for >6 months. The exclusion criteria were as
6 follows: (1) in-stent restenosis lesions; (2) chronic total occlusion in the LM or adjusting
7 branches; (3) the left anterior descending artery (LAD) and/or left circumflex artery (LCX)
8 protected by prior CABG; (4) female with possible or definite pregnancy; (5) unsuitable
9 candidate as judged by the responsible doctor, and (6) refusal to provide personal information
10 for the study after receiving study information, in accordance with the opt-out system.

11 After the exclusion of 38 patients (inclusion criteria unmet in 26, lost to follow-up in 11,
12 physician's decision in one) and 25 patients with any deficit of 1-year follow-up data, the data
13 of 743 patients were analyzed (Figure 1). The study protocol was approved by the
14 Institutional Review Board of the Japanese National Hospital Organization and each
15 attending hospital. This study was conducted using an opt-out system and was disclosed to
16 the patients and requirement for informed consent was waived. The study protocol was
17 developed in accordance with the Declaration of Helsinki and registered in the University
18 Hospital Medical Information Network (ID: UMIN 000037332) prior to the initiation of
19 enrollment.

1 ***Percutaneous coronary intervention protocol***

2 All patients were treated with sufficient periprocedural heparin and dual antiplatelet therapy
3 with aspirin (100 mg) and either clopidogrel (50–75 mg) or prasugrel (3.75 mg), which was
4 continued for at least 6 months. In cases with deficits in PCI initiation, the procedure was
5 performed after administering the loading dose (aspirin 200 mg, clopidogrel 300 mg, and
6 prasugrel 20 mg). Imaging was strongly recommended before PCI to assess the lesion and
7 select the optimal therapeutic device and after the PCI procedure for its optimization. The use
8 of IVUS or OCT/OFDI was at the operator’s discretion. If any stent failure (stent
9 malapposition >400 µm, insufficient stent expansion [<80%] compared with the mean value
10 of proximal and distal references, and stent deformation) or serious dissection in the SB or
11 stent proximal and/or distal edges was observed on imaging, prompt additional treatment was
12 performed. The proximal optimal technique (POT), using a short balloon according to the
13 LM vessel size, was recommended; however, its use relied on the operator’s discretion after
14 the imaging assessment for LM stent expansion. After LM crossover stenting to the LAD or
15 LCX, opposite branch ostial dilation and the choice of method (kissing balloon inflation
16 [KBI] or opposite branch dilation alone) were also dependent on the operator’s discretion.

17 ***Data collection***

18 Patient background, lesion characteristics, on-site visual assessment of coronary angiography,
19 PCI procedure, medical treatment, and clinical outcome at 1-year follow-up were registered

1 from each hospital to the REDCap system, a web-based application designed for streamlined
2 data collection and management, in Osaka Metropolitan University Hospital center for
3 clinical research and innovation.

4 In this study, acute coronary syndrome included acute myocardial infarction accompanied by
5 elevated cardiac biomarker levels with or without ST elevation on electrocardiography and
6 unstable angina, defined as new-onset or increased-severity angina within 1 month, resting
7 angina, and postinfarction angina without elevated cardiac biomarker levels. Stable angina
8 was defined as stable symptoms during high exertion, with no chest pain at rest in the past
9 month. Silent myocardial ischemia was defined as the objective evidence of myocardial
10 ischemia without evident chest symptoms. Cardiogenic shock was defined as a sustained
11 episode of systolic blood pressure <80 mmHg and cardiac index <1.8 L/min·m², determined
12 to be secondary to cardiac dysfunction, and/or the requirement of a parenteral inotropic or
13 vasopressor agent or mechanical support to maintain blood pressure and cardiac index within
14 24 h before PCI. Pulmonary edema was defined as symptoms of heart failure within 24 h
15 before PCI, including dyspnea on mild activity, orthopnea, body fluid retention, moist rales,
16 and neck vein distention, which were equivalent to Congestive Heart Failure in the New York
17 Heart Association functional classification class IV. Cardiac death was defined as death due
18 to cardiac diseases, including heart failure, fatal arrhythmia, and sudden death. Vascular death
19 was defined as death due to a vascular disease, except for coronary artery disease, such as

1 diseases of the cerebrovascular artery, aorta, and peripheral and pulmonary arteries. Target
2 lesion revascularization (TLR) was defined as any revascularization by PCI or CABG in the
3 treated LM and adjusting proximal LAD and LCX within 5 mm from the branch ostium.
4 Target vessel revascularization (TVR) was defined as revascularization of the LM, LAD, or
5 LCX. Clinically driven revascularization included TVR and non-TVR. Stent thrombosis
6 included definite and probable stent thrombosis as defined by the Academic Research
7 Consortium. Cerebrovascular disorders included stroke with any new-onset neurological
8 deficit due to the occlusion of the cerebrovascular artery and cerebrovascular hemorrhage,
9 except for traumatic hemorrhage. Successful PCI was defined as the achievement of
10 Thrombolysis in Myocardial Infarction flow grade III with residual stenosis of $\leq 25\%$ in the
11 target lesion¹⁶.

12 ***Endpoint***

13 Major adverse cardiovascular and cerebrovascular events (MACCE) were defined as
14 composite endpoints of the following at 1-year follow-up: all-cause death, cerebrovascular
15 disorder, any clinically driven revascularization, and myocardial infarction.

16 ***Statistical analyses***

17 Continuous variables are expressed as mean \pm standard deviation. Categorical variables are
18 presented as percentages. Cox proportional hazard models were constructed to evaluate the
19 association between each patient background, lesion characteristics, PCI procedures, and

1 MACCE. Hazard ratios (HRs) and 95% confidence intervals (CIs) were calculated. The rates
2 of MACCE incidence between patient background, lesion characteristics, PCI procedures
3 were compared by estimating cumulative incidence functions against the days from PCI. All
4 reported p-values were determined by two-sided analysis, and p-values <0.05 were
5 considered significant. Analyses were performed using the R software (version 4.2.2) (R
6 Foundation for Statistical Computing, Vienna, Austria).

7

8 **Results**

9 **Baseline patient characteristics**

10 Baseline patient characteristics are summarized in Table 1. Increased prevalence rates of male
11 sex (78.7%), dyslipidemia (71.0%), diabetes mellitus (49.3%), prior myocardial infarction
12 (25.2%), and prior PCI or CABG (43.6%) were observed. The mean left ventricular ejection
13 fraction was $56\pm 15\%$. Acute coronary syndrome was observed in 31.2% of the patients, and a
14 severe hemodynamic collapse state (cardiogenic shock, cardiopulmonary arrest, and
15 pulmonary edema) was observed in 2.4–6.1% of the patients. Canadian Cardiovascular
16 Society (CCS) class ≥ 3 was observed in 39.3% of the patients.

17 **Lesion background**

18 The backgrounds of the lesions are shown in Table 1. LM bifurcation was observed in 78.0%
19 of the patients, and the most prevalent Medina classification was 1-1-0 lesion (30.1%) and

1 true bifurcation lesion, which included significant stenosis in both the main vessel (MV) and
2 SB, accounted for 34.7%. Angiographically nonsignificant LM lesions (Medina 0-x-x) were
3 included in 30.9% of the patients because of the identification of LM atherosclerotic plaques
4 on intracoronary imaging.

5 **PCI procedures**

6 The PCI procedures are presented in Table 2. Radial access was frequently used in 70.1% of
7 the patients, and most patients were treated with 6- and 7-Fr guiding systems (51.9% and
8 41.8%, respectively). Imaging guidance was routinely performed (97.7%), and IVUS and
9 OCT/OFDI were performed in 86.5% and 12.2% of the patients, respectively. A
10 current-generation DES was implanted in all patients, except for one in which a bare metal
11 stent was used according to the physician's discretion. Two-stent deployment in the LM
12 bifurcation was performed in 8.8% of the patients, and elective procedure was performed in
13 only 14 patients (1.9% of the entire cohort). The stenting technique was performed in the
14 sequence of culottes, T-stenting, and crush stenting. The POT was performed in 53.1% of the
15 patients treated with one-stent deployment. KBI or SB dilation alone was performed in 75.0%
16 of the patients. A mechanical cardiac support device was used in 16.4% of the patients
17 (intra-aortic balloon pumping, 15.8%; extracorporeal membrane oxygenation, 2.7%).
18 Modification of calcified lesions was performed using rotational or orbital atherectomy
19 (9.2%) and a scoring balloon (19.7%). MV stent size was 3.5–4.0 mm in 63.0% and 3.0–3.5

1 mm in 30.8% of the patients, and SB stent size was 3.0–3.5 mm in 41.0% and 2.5–3.0 mm in
2 34.9% of the patients. The PCI success rate was 98.6%.

3 **Adverse events at 1-year follow-up**

4 Adverse events at the 1-year follow-up are shown in Table 3. The rates of all-cause death,
5 cerebrovascular disorders, clinically driven revascularization, and myocardial infarction were
6 8.9%, 1.2%, 8.2%, and 1.9%, respectively. MACCE, which were a composite of these events,
7 were observed in 17.5% of the patients. TLR and cardiac death occurred in 2.0% and 3.4% of
8 the patients, respectively. The cumulative curve of MACCE showed a gradual increase
9 (Figure 2a), whereas that of all-cause death peaked within 30 days and plateaued at 1 year
10 (Figure 3a).

11 **Risk in major adverse cardiovascular and cerebrovascular events**

12 Multivariate analysis of the risk of MACCE is shown in Table 4. Independent factors that
13 elevated the risk included CCS \geq class III (HR, 2.07; 95% CI, 1.39–3.07; $p < 0.001$),
14 mechanical cardiac support device use (HR, 2.17; 95% CI, 1.43–3.30; $p < 0.001$), and
15 two-stent implantation (HR, 2.49; 95% CI, 1.48–4.18; $p < 0.001$). Factors that reduced the risk
16 were left ventricular ejection fraction -10% increase (HR, 0.72; 95% CI, 0.52–0.99; $p = 0.041$)
17 and radial access (HR, 0.62; 95% CI, 0.42–0.91; $p = 0.015$). The cumulative curve of MACCE
18 showed higher rates of mechanical cardiac support device use (Figure 2b), CCS classes III
19 and IV (c), two-stent implantation (d), and nonradial access (e). The cumulative curve of

1 all-cause death showed higher rates of mechanical cardiac support device use (Figure 3b),
2 CCS class IV (c), and nonradial access (e), which peaked within 30 days.

3

4 **Discussion**

5 In the LM-JANHO study on routine imaging-guided unprotected LM-PCI, including acute
6 coronary syndrome, 17.5% of the patients experienced composite endpoints (comprising
7 all-cause death, cerebrovascular disorder, any clinically driven revascularization, and
8 myocardial infarction) at the 1-year follow-up. Notably, the study reported a low incidence of
9 TLR (2.0%) and cardiac death (3.4%). Risk factors for the composite endpoints included
10 CCS class \geq III, use of a mechanical cardiac support device, and two-stent implantation, while
11 a 10% increase in left ventricular ejection fraction and radial access were associated with a
12 reduced risk.

13

14 *Effect of routine imaging guidance in LM-PCI*

15 Imaging guidance in LM-PCI demonstrated a lower incidence of composite endpoints of
16 all-cause death, restenosis, or definite stent thrombosis (HR, 0.65; 95% CI, 0.50–0.84) and
17 all-cause death alone (HR, 0.62; 95% CI, 0.47–0.82) in 2468 patients of the Swedish
18 Coronary Angiography and Angioplasty Registry, in which IVUS guidance was used in
19 25.2% of the patients². In 11,264 unprotected LM-PCI procedures performed in England and

1 Wales, analysis of 5056 pairs of imaging- and angio-guided PCIs after propensity matching
2 showed that the imaging-guided PCI presented a lower incidence of 12-month mortality than
3 the angio-guided PCI (odds ratio [OR], 0.660; 95% CI, 0.57–0.77)⁷. A meta-analysis of
4 comparison between IVUS guidance (2096 patients) and angio-guidance (1984 patients) in
5 LM-PCI also exhibited a lower incidence of all-cause death (OR, 0.46; 95% CI, 0.30–0.71),
6 cardiac death (OR, 0.47; 95% CI, 0.29–0.77), and composite endpoints, including stent
7 thrombosis, myocardial infarction, cardiac death, and all-cause death (OR, 0.42; 95% CI,
8 0.26–0.67)³. However, imaging guidance was employed for complex lesions in these studies,
9 and the efficacy of routine imaging in every LM-PCI has not been elucidated.

10 The present study included cases with acute myocardial infarction and cardiogenic shock that
11 were excluded in the other previous studies of the imaging-guided LM-PCI^{3, 5-7, 17}. Therefore,
12 all-cause death (8.9% vs. 2.5–9.0%) and cardiac death at 1 year (3.4% vs. 0.8–2.4%) were
13 observed more frequently in the present study than in previous studies. However, there was a
14 similar incidence rate of TVR (4.6% vs. 4.2–6.7%) and lower incidence rates of TLR (2.0%
15 vs. 2.7–7.7%), stent thrombosis (0.3% vs. 0.5–1.7%), and myocardial infarction (1.9% vs.
16 1.5–11.2%), indicating that optimal PCI was induced by imaging guidance in survivors after
17 acute coronary events. The following factors contribute to the efficacy of routine imaging
18 guidance in LM-PCI: first, the optimal device selection in terms of size and length was based
19 on pre-PCI imaging, which decreased additional stenting due to overdilation or inappropriate

1 positioning of the balloon or stent in the plaque-rich area. Information concerning plaque
2 morphology, thrombus burden, and intracoronary calcification severity was also useful for
3 appropriate preparation before stenting. Second, some atherosclerotic plaques were identified
4 by intracoronary imaging in the angiographically insignificant LM lesions, which increased
5 LM crossover stenting in the Medina (0-x-x) lesions. In this study, this type of lesion was
6 observed in 30.9% of the patients, whereas in previous studies with limited use of imaging, it
7 was observed in 0–21.5% of the patients¹⁸⁻²¹. Third, more appropriate PCI optimization for
8 sufficient stent expansion, less stent malapposition or deformation, and navigation of optimal
9 SB guidewire crossings were promoted. Accurate assessment of SB dissection or stenosis
10 after balloon dilation on intracoronary imaging resulted in a decrease in two-stent deployment
11 in this study (8.8%). Elective two-stent deployment was performed in only 1.9% of the
12 patients, and fewer escalations from provisional stenting (6.9%) were noted. Thus, local
13 effectiveness of imaging-guided PCI on LM lesion was prominent in less TLR (2.0%) and
14 cardiac death (3.4%) in this study compared with the prior Japanese registry study (AOI
15 registry) (TLR: 9.1% [bifurcation]/11.0% [non-bifurcation], cardiac death: 6.6%/5.0%¹⁹) or
16 randomized studies comparing provisional and elective two stenting with the limited use of
17 imaging guidance and exclusion of acute myocardial infarction and cardiogenic shock (EBC
18 MAIN, TLR: 6.1% [provisional stent]/9.3% [two stents]²¹; DK Crush V, TLR: 10.7%/5.0%,
19 cardiac death: 1.3%/2.1%²⁰).

1

2 ***Risk of MACCE***

3 CCS class \geq III and mechanical cardiac support device use were directly related to the severe
4 hemodynamic collapse state, which might result in cardiac death in acute phase. As nonradial
5 access was adopted more frequently in an unstable hemodynamic state with weak pulsation
6 of the radial artery, it was also associated with the risk of cardiac death. In fact, the group
7 with these factors had elevated mortality within 30 days and reached a plateau at 1 year
8 (Figure 3). Even with technical improvements in LM-PCI under imaging guidance, the initial
9 myocardial damage induced by LM ischemia cannot be effectively relieved.

10 Lower left ventricular ejection fraction was identified as an independent risk factor for
11 MACCE. This was a result of LM ACS that led to severe left ventricular damage or ischemic
12 cardiomyopathy that had already presented with multiple-vessel diseases, including LM
13 lesions. A lower left ventricular ejection fraction was associated with heart failure recurrence,
14 fatal arrhythmic events, and more frequent coronary revascularization.

15 Two-stent deployment was also an independent risk factor for MACCE. Higher risk^{18, 19, 22, 23}
16 of two-stent deployment was demonstrated in previous studies in which first-generation DES
17 were mainly used. However, similar^{21, 23} or superior clinical outcomes^{20, 24} compared with
18 provisional stenting have been reported in recent studies that used current-generation DES. In
19 the present study, two-stent deployment was used in a limited manner for more complex

1 lesions (8.8%). More than 20% of the cases that would have been treated with elective
2 two-stent deployment in other studies with limited use of intracoronary imaging were treated
3 with provisional stenting in this study. However, true bifurcation lesions were not identified
4 as risk factors for MACCE, and some SB lesions were left with dissection or incomplete full
5 vessel dilation. Angiographically hazy images after pre-dilation in the SB were likely to
6 promote more elective two-stent deployment or escalation to provisional two stenting in other
7 studies. Escalation to provisional two stenting was observed in 22–47% of the patients owing
8 to suboptimal findings in the SB, which were mainly assessed by angiographical diameter
9 stenosis²⁵ and have been revealed to be overestimated with physiologically insignificant
10 stenosis in 30% of the patients²⁶. Although definite imaging criteria were not established in
11 this study, individual operators decided to perform additional SB stenting more strictly
12 according to imaging findings, such as intimal flap, which threatens vessel occlusion,
13 progression of hematoma, and insufficient lumen dilation with concrete plaque remaining.
14 Although suboptimal angiographic findings remained in some true bifurcation lesions, they
15 were not associated with worse clinical outcomes in imaging-guided LM-PCI. As most
16 two-stent deployments were adopted in cases with suboptimal SB balloon dilation or multiple
17 vessel involvement, diffuse lesions, hard calcification, rich plaque burden, and stent landing
18 in the distal plaque were likely to be present, requiring more vessel revascularization.
19 Therefore, comprehensive management strategies that consider plaque debulking, aggressive

1 medical therapy, and switching to CABG after lesion assessment using intracoronary imaging
2 are required.

3

4 ***Contemporary PCI techniques***

5 ***Radial access:*** In the present study, radial access was used in 70.1% of the patients using a 6-
6 or 7-Fr guiding catheter. Radial access was first approached in elective cases, and the
7 introduction of a slender system with a thinner outer sheath by 1 Fr than the conventional
8 system allowed for increased use of a 7-Fr guiding catheter, which enabled complex PCI
9 procedures to be performed with greater ease. Radial access is associated with less bleeding
10 (OR, 0.43; 95% CI, 0.27–0.69; p=0.0004) and lower in-hospital mortality rate (OR, 0.49;
11 95% CI, 0.31–0.79; p=0.004) in a meta-analysis of LM-PCI including 17,258 patients²⁷.

12 ***POT:*** In the present study, POT was performed in 53.1% of the patients, which was not as in
13 randomized trials^{8, 20, 21}, but more frequent than in other registry studies^{6, 19, 28}. The POT
14 provides sufficient stent expansion and less stent malapposition in the proximal MV, and
15 re-POT is recommended after SB dilation to correct stent deformation²⁸⁻³⁰. In the present
16 study, the more frequent KBI (62%) might have resulted in sufficient stent expansion with
17 less malapposition in the LM, and confirmation by imaging led to a lower performance of
18 POT or re-POT. However, it is crucial to determine the optimal size of the balloon for the
19 POT according to the LM vessel size in the pre-PCI imaging and to confirm sufficient stent

1 expansion in the LM, including the polygon confluence without any significant stent
2 malapposition in the post-PCI imaging³¹.

3 ***Optimal SB wiring:*** In imaging-guided bifurcation PCI, confirmation of the optimal SB
4 wiring before SB dilation is recommended¹¹. Even in two-dimensional IVUS imaging, the
5 optimal SB guidewire position can be identified as the most distal site at the carina between
6 the struts located at the center of the carinal site of the SB. Three-dimensional reconstruction
7 of OCT/OFDI images provides a clear image of the SB guidewire recrossing point and the
8 configuration of the SB jailing strut pattern^{32, 33}. Three-dimensional OCT/OFDI guidance
9 enhances optimal SB wiring to the distal cell at the SB ostium (from 50–66% to 90%) and
10 reduces incomplete stent apposition after subsequent KBI^{32, 34}. In the present study,
11 OCT/OFDI guidance was infrequent (12.2%); however, confirmation of the SB wiring
12 position was routinely performed under IVUS guidance.

13 ***SB dilation under the imaging guidance:*** Any SB dilation was performed more frequently
14 (75%) in the present study than in other registry studies^{26, 28, 35, 36}. The LCX ostial area is
15 larger than that of other SBs in non-LM bifurcations and is covered with more jailing struts³².
16 The success rate of optimal SB wiring was lower in LM bifurcation than in non-LM
17 bifurcation under angio-guidance (55% vs. 75%), and more incomplete strut apposition was
18 observed in LM bifurcation³². Incomplete removal of jailing struts in the LCX ostium due to
19 suboptimal SB wiring or inappropriate balloon dilation leads to clustering of jailing struts at

1 the rim of the LCX ostium, which may be associated with thrombus attachment or restenotic
2 reaction³⁷⁻³⁹. More suboptimal SB wiring and subsequent SB dilation than expected would
3 have occurred in previous studies due to the limited use of imaging. The efficacy of KBI in
4 angiographic SB restenosis and the reduction of subclinical thrombus attachment to the
5 jailing struts was confirmed in a study of imaging-guided bifurcation PCI^{32, 40}. Although
6 leaving the LCX without any dilation after LM-LAD crossover stenting has a sufficiently
7 higher survival rate from cardiac events in cases with high FFR values in the jailed LCX³⁵,
8 there are reports of non-fenestration-related restenosis due to intimal coverage of the jailing
9 struts at the LCX ostium and very late stent thrombosis on the jailing struts in an autopsy
10 study of sudden cardiac death of patients after LM-PCI³⁹. In the e-Ultimaster bifurcation
11 substudy, which demonstrated the efficacy of the POT but not that of KBI, the least and most
12 prevalent target lesion failures were found in cases with both POT and KBI performed and
13 those without either of them, which indicates that leaving the SB untouched without any
14 optimization in the proximal MV or SB is associated with worse clinical outcomes²⁸.
15 Imaging-guided optimal SB treatment and POT are crucial to reduce procedure-related
16 events.

17 ***Mechanical cardiac supporting device:*** In the present study, intra-aortic balloon pumping
18 was used in 15.8% of the patients, and extracorporeal membrane oxygenation was used in
19 2.7% of the patients. As Impella had not been introduced in Japan at the start of the study

1 period and had limited use for cardiogenic shock in licensed institutes, there were no cases
2 with Impella support in this study. As the inefficacy of intra-aortic balloon pumping or
3 extracorporeal membrane oxygenation on long-term survival has been reported^{41, 42} a higher
4 rate of cardiac death in patients using a mechanical cardiac support device was demonstrated
5 in this study. Improvement of the survival rate after LM-related ACS has been reported in
6 Impella support due to early unloading of the left ventricle, prevention of its remodeling, and
7 subsequent multiple organ failure⁴³. Improvement in mortality is expected using Impella
8 support; however, further studies are warranted to investigate its efficacy in LM-related ACS
9 in East Asian races, which have shown a higher bleeding risk than Caucasian races⁴⁴.

10 *Study limitations*

11 The present study has the following limitations. 1) The study did not adopt a randomized trial
12 design, with 97.7% of cases treated under imaging guidance. Consequently, the study design
13 does not facilitate a direct assessment of the efficacy of imaging guidance in comparison with
14 angio-guidance. Instead, efficacy was established by comparing the results with those from
15 previous reports. 2) Given that consecutive cases of LM-PCI were enrolled, this study
16 included cases of acute myocardial infarction or cardiogenic shock, which were excluded in
17 previous studies. This may have led to an increase in clinical events, particularly in terms of
18 mortality. 3) Because this was a retrospective study, there were no standardized criteria for
19 optimal PCI results in intracoronary imaging among the participating institutes, except for the

1 general recommendations of a stent expansion index >80%, minimal stent malapposition, and
2 confirmation of the SB wiring site. 4) The enrollment of LM-PCI or CABG in LM-related
3 diseases varied among the participating institutes, and the expertise and skills of operators
4 performing LM-PCI also differed. These variations may have influenced the study outcomes.

5

6 **Acknowledgements**

7 None.

8

9 **Sources of Funding**

10 The LM-JANHO study is supported by a Grant-in-Aid for Clinical Research from the
11 National Hospital Organization in Japan.

12

13 **Disclosures**

14 Y. Murasato has received research grant from Orbus Neich and lecturer fees from Abbott
15 Medical, Medtronic, Terumo, and Kaneka. Y. Ueda has received research grant from Abbott
16 Medical, Daiichi-Sankyo, Teijin, Japan Lifeline, Orbus Neich, Janssen, Otsuka, Ono, Eli Lilly,
17 Amgen, Novo Nordisk, and Novartis, and lecture fees from Abbott Medical, Kowa, Bayer,
18 Daiichi-Sankyo, Nipro, Takeda, AstraZeneca, Japan Lifeline, Novartis, Ono, Boehringer
19 Ingelheim, PDR Pharma, Kaneka Medix, Mochida, Otsuka, and Amgen.

1 **References**

- 2 1. Buccheri S, Franchina G, Romano S, Puglisi S, Venuti G, D'Arrigo P, Francaviglia B,
3 Scalia M, Condorelli A, Barbanti M, et al. Clinical Outcomes Following Intravascular
4 Imaging-Guided Versus Coronary Angiography-Guided Percutaneous Coronary Intervention
5 With Stent Implantation: A Systematic Review and Bayesian Network Meta-Analysis of 31
6 Studies and 17,882 Patients. *JACC Cardiovasc Interv.* 2017;10:2488-2498.
- 7 2. Andell P, Karlsson S, Mohammad MA, Gotberg M, James S, Jensen J, Frobert O,
8 Angeras O, Nilsson J, Omerovic E, et al. Intravascular Ultrasound Guidance Is Associated
9 With Better Outcome in Patients Undergoing Unprotected Left Main Coronary Artery
10 Stenting Compared With Angiography Guidance Alone. *Circ Cardiovasc Interv.*
11 2017;10:e004813.
- 12 3. Zhang Q, Wang B, Han Y, Sun S, Lv R, Wei S. Short- and Long-Term Prognosis of
13 Intravascular Ultrasound-Versus Angiography-Guided Percutaneous Coronary Intervention: A
14 Meta-Analysis Involving 24,783 Patients. *J Interv Cardiol.* 2021;2021:6082581.
- 15 4. Lee JM, Choi KH, Song YB, Lee JY, Lee SJ, Lee SY, Kim SM, Yun KH, Cho JY,
16 Kim CJ, et al. Intravascular Imaging-Guided or Angiography-Guided Complex PCI. *N Engl J*
17 *Med.* 2023;388:1668-1679.
- 18 5. de la Torre Hernandez JM, Garcia Camarero T, Baz Alonso JA, Gomez-Hospital JA,
19 Veiga Fernandez G, Lee Hwang DH, Sainz Laso F, Sanchez-Recalde A, Perez de Prado A,

- 1 Lozano Martinez-Luengas I, et al. Outcomes of Predefined Optimisation Criteria for
2 Intravascular Ultrasound Guidance of Left Main Stenting. *EuroIntervention*.
3 2020;16:210-217.
- 4 6. Cortese B, Piraino D, Gentile D, Onea HL, Lazar L. Intravascular Imaging for Left
5 Main Stem Assessment: An Update on the Most Recent Clinical Data. *Catheter Cardiovasc*
6 *Interv*. 2022;100:1220-1228.
- 7 7. Kinnaird T, Johnson T, Anderson R, Gallagher S, Sirker A, Ludman P, de Belder M,
8 Copt S, Oldroyd K, Banning A, et al. Intravascular Imaging and 12-Month Mortality After
9 Unprotected Left Main Stem PCI: An Analysis From the British Cardiovascular Intervention
10 Society Database. *JACC Cardiovasc Interv*. 2020;13:346-357.
- 11 8. Holm NR, Andreasen LN, Neghabat O, Laanmets P, Kumsars I, Bennett J, Olsen NT,
12 Odenstedt J, Hoffmann P, Dens J, et al. OCT or Angiography Guidance for PCI in Complex
13 Bifurcation Lesions. *N Engl J Med*. 2023;389:1477-1487.
- 14 9. Neumann FJ, Sousa-Uva M, Ahlsson A, Alfonso F, Banning AP, Benedetto U, Byrne
15 RA, Collet JP, Falk V, Head SJ, et al. 2018 ESC/EACTS Guidelines on Myocardial
16 Revascularization. *Eur Heart J*. 2019;40:87-165.
- 17 10. Nakamura M, Yaku H, Ako J, Arai H, Asai T, Chikamori T, Daida H, Doi K, Fukui T,
18 Ito T, et al. JCS/JSCVS 2018 Guideline on Revascularization of Stable Coronary Artery
19 Disease. *Circ J*. 2022;86:477-588.

- 1 11. Takagi K, Nagoshi R, Kim BK, Kim W, Kinoshita Y, Shite J, Hikichi Y, Song YB,
2 Nam CW, Koo BK, et al. Efficacy of Coronary Imaging on Bifurcation Intervention.
3 *Cardiovasc Interv Ther.* 2021;36:54-66.
- 4 12. Raber L, Mintz GS, Koskinas KC, Johnson TW, Holm NR, Onuma Y, Radu MD,
5 Joner M, Yu B, Jia H, et al. Clinical Use of Intracoronary Imaging. Part 1: Guidance and
6 Optimization of Coronary Interventions. An Expert Consensus Document of the European
7 Association of Percutaneous Cardiovascular Interventions. *Eur Heart J.* 2018;39:3281-3300.
- 8 13. Murasato Y, Kinoshita Y, Yamawaki M, Okamura T, Nagoshi R, Watanabe Y, Suzuki
9 N, Mori T, Shinke T, Shite J, et al. Impact of Medina Classification on Clinical Outcomes of
10 Imaging-guided Coronary Bifurcation Stenting. *Int J Cardiol Heart Vasc.* 2023;49:101311.
- 11 14. Windecker S, Neumann FJ, Juni P, Sousa-Uva M, Falk V. Considerations for the
12 Choice Between Coronary Artery Bypass Grafting and Percutaneous Coronary Intervention
13 as Revascularization Strategies in Major Categories of Patients with Stable Multivessel
14 Coronary Artery Disease: An Accompanying Article of the Task force of the 2018
15 ESC/EACTS Guidelines on Myocardial Revascularization. *Eur Heart J.* 2019;40:204-212.
- 16 15. Kameyama T, Ino Y, Kubo T, Akasaka T. Advances in Coronary Artery Imaging (in
17 Japanese). *J Jpn Coron Assoc.* 2016;22:39-44.
- 18 16. Sawano M, Yamaji K, Kohsaka S, Inohara T, Numasawa Y, Ando H, Iida O, Shinke
19 T, Ishii H, Amano T. Contemporary Use and Trends in Percutaneous Coronary Intervention in

- 1 Japan: An Outline of the J-PCI Registry. *Cardiovasc Interv Ther.* 2020;35:218-226.
- 2 17. Maznyczka A, Arunothayaraj S, Egred M, Banning A, Brunel P, Ferenc M, Hovasse
3 T, Wlodarczak A, Pan M, Schmitz T, et al. Bifurcation Left Main Stenting With or Without
4 Intracoronary Imaging: Outcomes from the EBC MAIN Trial. *Catheter Cardiovasc Interv.*
5 2023;102:415-429.
- 6 18. Toyofuku M, Kimura T, Morimoto T, Hayashi Y, Shiode N, Nishikawa H, Nakao K,
7 Shirota K, Kawai K, Hiasa Y, et al. Comparison of 5-year Outcomes in Patients With and
8 Without Unprotected Left Main Coronary Artery Disease After Treatment With
9 Sirolimus-eluting Stents: Insights from the j-Cypher Registry. *JACC Cardiovasc Interv.*
10 2013;6:654-663.
- 11 19. Ohya M, Kadota K, Toyofuku M, Morimoto T, Higami H, Fuku Y, Yamaji K,
12 Muranishi H, Yamaji Y, Nishida K, et al. Long-Term Outcomes After Stent Implantation for
13 Left Main Coronary Artery (from the Multicenter Assessing Optimal Percutaneous Coronary
14 Intervention for Left Main Coronary Artery Stenting Registry). *Am J Cardiol.*
15 2017;119:355-364.
- 16 20. Chen SL, Zhang JJ, Han Y, Kan J, Chen L, Qiu C, Jiang T, Tao L, Zeng H, Li L, et al.
17 Double Kissing Crush Versus Provisional Stenting for Left Main Distal Bifurcation Lesions:
18 DKCRUSH-V Randomized Trial. *J Am Coll Cardiol.* 2017;70:2605-2617.
- 19 21. Hildick-Smith D, Egred M, Banning A, Brunel P, Ferenc M, Hovasse T, Wlodarczak

- 1 A, Pan M, Schmitz T, Silvestri M, et al. The European Bifurcation Club Left Main Coronary
2 Stent Study: A Randomized Comparison of Stepwise Provisional vs. Systematic Dual
3 Stenting Strategies (EBC MAIN). *Eur Heart J.* 2021;42:3829-3839.
- 4 22. Behan MW, Holm NR, de Belder AJ, Cockburn J, Erglis A, Curzen NP, Niemela M,
5 Oldroyd KG, Kervinen K, Kumsars I, et al. Coronary Bifurcation Lesions Treated with
6 Simple or Complex Stenting: 5-year Survival from Patient-level Pooled Analysis of the
7 Nordic Bifurcation Study and the British Bifurcation Coronary Study. *Eur Heart J.*
8 2016;37:1923-1928.
- 9 23. Lee JM, Hahn JY, Kang J, Park KW, Chun WJ, Rha SW, Yu CW, Jeong JO, Jeong
10 MH, Yoon JH, et al. Differential Prognostic Effect Between First- and Second-Generation
11 Drug-Eluting Stents in Coronary Bifurcation Lesions: Patient-Level Analysis of the Korean
12 Bifurcation Pooled Cohorts. *JACC Cardiovasc Interv.* 2015;8:1318-1331.
- 13 24. Zhang JJ, Ye F, Xu K, Kan J, Tao L, Santoso T, Munawar M, Tresukosol D, Li L,
14 Sheiban I, et al. Multicentre, randomized comparison of two-stent and provisional stenting
15 techniques in patients with complex coronary bifurcation lesions: the DEFINITION II trial.
16 *Eur Heart J.* 2020;41:2523-2536.
- 17 25. Paradies V, Banning A, Cao D, Chieffo A, Daemen J, Diletti R, Hildick-Smith D,
18 Kandzari DE, Kirtane AJ, Mehran R, et al. Provisional Strategy for Left Main Stem
19 Bifurcation Disease: A State-of-the-Art Review of Technique and Outcomes. *JACC*

- 1 *Cardiovasc Interv.* 2023;16:743-758.
- 2 26. Lee HS, Kim U, Yang S, Murasato Y, Louvard Y, Song YB, Kubo T, Johnson TW,
3 Hong SJ, Omori H, et al. Physiological Approach for Coronary Artery Bifurcation Disease:
4 Position Statement by Korean, Japanese, and European Bifurcation Clubs. *JACC Cardiovasc*
5 *Interv.* 2022;15:1297-1309.
- 6 27. Goel S, Pasam RT, Raheja H, Gotesman J, Gidwani U, Ahuja KR, Reed G, Puri R,
7 Khatri JK, Kapadia SR. Left Main Percutaneous Coronary Intervention-Radial Versus
8 Femoral Access: A Systematic Analysis. *Catheter Cardiovasc Interv.* 2020;95:E201-E213.
- 9 28. Chevalier B, Mamas MA, Hovasse T, Rashid M, Gomez-Hospital JA, Pan M,
10 Witkowski A, Crowley J, Aminian A, McDonald J, et al. Clinical Outcomes of the Proximal
11 Optimisation Technique (POT) in Bifurcation Stenting. *EuroIntervention.*
12 2021;17:e910-e918.
- 13 29. Albiero R, Burzotta F, Lassen JF, Lefevre T, Banning AP, Chatzizisis YS, Johnson
14 TW, Ferenc M, Pan M, Daremont O, et al. Treatment of Coronary Bifurcation Lesions, Part I:
15 Implanting the First Stent in the Provisional Pathway. The 16th Expert Consensus Document
16 of the European Bifurcation Club. *EuroIntervention.* 2022;18:e362-e376.
- 17 30. Lassen JF, Albiero R, Johnson TW, Burzotta F, Lefevre T, Iles TL, Pan M, Banning
18 AP, Chatzizisis YS, Ferenc M, et al. Treatment of Coronary Bifurcation Lesions, part II:
19 Implanting Two Stents. The 16th Expert Consensus Document of the European Bifurcation

- 1 Club. *EuroIntervention*. 2022;18:457-470.
- 2 31. Murasato Y, Mori T, Okamura T, Nagoshi R, Fujimura T, Yamawaki M, Ono S,
3 Serikawa T, Nakao F, Shite J, et al. Efficacy of the Proximal Optimization Technique on
4 Crossover Stenting in Coronary Bifurcation Lesions in the 3D-OCT Bifurcation Registry. *Int*
5 *J Cardiovasc Imaging*. 2019;35:981-990.
- 6 32. Okamura T, Nagoshi R, Fujimura T, Murasato Y, Yamawaki M, Ono S, Serikawa T,
7 Hikichi Y, Norita H, Nakao F, et al. Impact of Guidewire Recrossing Point into Stent Jailed
8 Side Branch for Optimal Kissing Balloon Dilatation: Core Lab 3D Optical Coherence
9 Tomography Analysis. *EuroIntervention*. 2018;13:e1785-e1793.
- 10 33. Onuma Y, Katagiri Y, Burzotta F, Holm NR, Amabile N, Okamura T, Mintz GS,
11 Darremont O, Lassen JF, Lefevre T, et al. Joint Consensus on the Use of OCT in Coronary
12 Bifurcation Lesions by the European and Japanese Bifurcation Clubs. *EuroIntervention*.
13 2019;14:e1568-e1577.
- 14 34. Onuma Y, Kogame N, Sotomi Y, Miyazaki Y, Asano T, Takahashi K, Kawashima H,
15 Ono M, Katagiri Y, Kyono H, et al. A Randomized Trial Evaluating Online 3-Dimensional
16 Optical Frequency Domain Imaging-Guided Percutaneous Coronary Intervention in
17 Bifurcation Lesions. *Circ Cardiovasc Interv*. 2020;13:e009183.
- 18 35. Lee CH, Nam CW, Cho YK, Yoon HJ, Kim KB, Gwon HC, Kim HS, Chun WJ, Han
19 SH, Rha SW, et al. 5-Year Outcome of Simple Crossover Stenting in Coronary Bifurcation

- 1 Lesions Compared With Side Branch Opening. *JACC Asia*. 2021;1:53-64.
- 2 36. Tarantini G, Fovino LN, Varbella F, Trabattoni D, Caramanno G, Trani C, De Cesare
3 N, Esposito G, Montorfano M, Musto C, et al. A Large, Prospective, Multicentre Study of
4 Left Main PCI Using a Latest-Generation Zotarolimus-eluting Stent: the ROLEX study.
5 *EuroIntervention*. 2023;18:e1108-e1119.
- 6 37. Foin N, Torii R, Alegria E, Sen S, Petraco R, Nijjer S, Ghione M, Davies JE, Di
7 Mario C. Location of Side Branch Access Critically Affects Results in Bifurcation Stenting:
8 Insights from Bench Modeling and Computational Flow Simulation. *Int J Cardiol*.
9 2013;168:3623-3628.
- 10 38. Takahashi H, Otake H, Shinke T, Murasato Y, Kinoshita Y, Yamawaki M, Takeda Y,
11 Fujii K, Yamada SI, Shimada Y, et al. Impact of Final Kissing Balloon Inflation on Vessel
12 Healing Following Drug-eluting Stent Implantation: Insight from the Optical Coherence
13 Tomography Sub-study of the J-REVERSE Trial. *J Cardiol*. 2016;68:504-511.
- 14 39. Burzotta F, Lassen JF, Lefevre T, Banning AP, Chatzizisis YS, Johnson TW, Ferenc
15 M, Rathore S, Albiero R, Pan M, et al. Percutaneous Coronary Intervention for Bifurcation
16 Coronary Lesions: The 15(th) Consensus Document from the European Bifurcation Club.
17 *EuroIntervention*. 2021;16:1307-1317.
- 18 40. Murasato Y, Kinoshita Y, Yamawaki M, Shinke T, Otake H, Takeda Y, Fujii K,
19 Yamada S, Shimada Y, Yamashita T, et al. Efficacy of Kissing Balloon Inflation after

- 1 Provisional Stenting in Bifurcation Lesions Guided by Intravascular Ultrasound: Short and
2 Midterm Results of the J-REVERSE Registry. *EuroIntervention*. 2016;11:e1237-e1248.
- 3 41. Thiele H, Zeymer U, Thelemann N, Neumann FJ, Hausleiter J, Abdel-Wahab M,
4 Meyer-Saraei R, Fuernau G, Eitel I, Hambrecht R, et al. Intraaortic Balloon Pump in
5 Cardiogenic Shock Complicating Acute Myocardial Infarction: Long-Term 6-Year Outcome
6 of the Randomized IABP-SHOCK II Trial. *Circulation*. 2019;139:395-403.
- 7 42. Thiele H, Zeymer U, Akin I, Behnes M, Rassaf T, Mahabadi AA, Lehmann R, Eitel I,
8 Graf T, Seidler T, et al. Extracorporeal Life Support in Infarct-Related Cardiogenic Shock. *N*
9 *Engl J Med* 2023;389:1286-1297.
- 10 43. Basir MB, Kapur NK, Patel K, Salam MA, Schreiber T, Kaki A, Hanson I, Almany S,
11 Timmis S, Dixon S, et al. Improved Outcomes Associated with the use of Shock Protocols:
12 Updates from the National Cardiogenic Shock Initiative. *Catheter Cardiovasc Interv*.
13 2019;93:1173-1183.
- 14 44. Numasawa Y, Sawano M, Fukuoka R, Ejiri K, Kuno T, Shoji S, Kohsaka S.
15 Antithrombotic Strategy for Patients with Acute Coronary Syndrome: A Perspective from
16 East Asia. *J Clin Med*. 2020;9:1963.
17

1 **Figure legends**

2 **Figure 1.** Study flow of the extraction of the analyzed patients.

3 **Figure 2.** Cumulative curve of major adverse cardiovascular and cerebrovascular events. (a)

4 Entire group. (b) The groups using or not using a mechanical cardiac support device (MCS).

5 (c) Canadian Cardiovascular Society functional angina classification. (d) The groups treated

6 with a single stent, two stents, and left main shaft stenting alone. (e) The groups of radial and

7 nonradial access. (f) The groups of true bifurcation lesion, non-true bifurcation lesion, and

8 non-bifurcation lesion.

9 **Figure 3.** Cumulative curve of all-cause mortality. (a) Entire group. (b) The groups using or

10 not using a mechanical cardiac support device (MCS). (c) Canadian Cardiovascular Society

11 functional angina classification. (d) The groups treated with a single stent, two stents, and left

12 main shaft stenting alone. (e) The groups of radial and nonradial access. (f) The groups of

13 true bifurcation lesion, non-true bifurcation lesion, and non-bifurcation lesion.

14

15

1 **Table 1. Patient and lesion background**

2

Patient background		
Age	years	73.0 ±10.1
Male	n, (%)	583 (78.7)
Hypertension	n, (%)	553 (74.6)
Dyslipidemia	n, (%)	526 (71.0)
Diabetes	n, (%)	365 (49.3)
Smoking	n, (%)	237 (32.0)
Hemodialysis	n, (%)	34 (4.6)
Chronic obstructive pulmonary disease	n, (%)	17 (2.3)
Peripheral artery disease	n, (%)	86 (11.6)
Prior myocardial infarction	n, (%)	187 (25.2)
Prior PCI/CABG	n, (%)	323 (43.6)
Family history	n, (%)	95 (12.8)
Left ventricular ejection fraction	%	56±15
Clinical presentation		
Stable angina	n, (%)	290 (39.2)
Old myocardial infarction	n, (%)	38 (5.1)

Silent myocardial ischemia	n, (%)	145 (19.6)
Acute coronary syndrome	n, (%)	231 (31.2)
Cardiogenic shock	n, (%)	45 (6.1)
Cardio-pulmonary arrest	n, (%)	18 (2.4)
Pulmonary edema	n, (%)	45 (6.1)
CCS classification		
I	n, (%)	288 (39.1)
II	n, (%)	158 (21.5)
III	n, (%)	100 (13.6)
IV	n, (%)	189 (25.7)
Pre-PCI		
Total cholesterol	mg/dL	169.4±42.5
Triglyceride	mg/dL	130.7±82.6
High density lipoprotein cholesterol	mg/dL	49.0±13.7
Low density lipoprotein cholesterol	mg/dL	98.6±36.8
Hemoglobin A ₁ C	%	6.6±1.2
Serum creatinine	mg/dL	1.27±1.38
Estimated glomerular filtration ratio	mL/min/1.73 m ²	58±23

Lesion background

Bifurcation lesion	n, (%)	573 (78.0)
Medina 1-0-0	n, (%)	54 (9.4)
Medina 1-1-0	n, (%)	173 (30.1)
Medina 1-1-1	n, (%)	139 (24.2)
Medina 1-0-1	n, (%)	31 (5.4)
Medina 0-1-0	n, (%)	136 (23.7)
Medina 0-1-1	n, (%)	29 (5.1)
Medina 0-0-1	n, (%)	12 (2.1)
True bifurcation lesion	n, (%)	199 (34.7)

1

2 PCI, percutaneous coronary intervention; CABG, coronary artery bypass graft; CCS,

3 Canadian Cardiovascular Society functional angina classification

4

5

6

1 **Table 2. Procedures of left main percutaneous coronary intervention**

2

Access		
Radial	n, (%)	519 (70.1)
Femoral	n, (%)	198 (26.8)
Brachial	n, (%)	23 (3.1)
System		
6 Fr	n, (%)	383 (51.9)
7 Fr	n, (%)	309 (41.8)
8 Fr	n, (%)	47 (6.4)
Imaging guide	n, (%)	726 (97.7)
Optical coherence tomography	n, (%)	90 (12.2)
Drug-eluting stent		
First generation	n, (%)	0 (0)
Current generation	n, (%)	742 (99.9)
Two-stent implantation	n, (%)	65 (8.8)
Elective	n, (%)	14 (21.5)
Culotte	n, (%)	26 (40.0)

Crush	n, (%)	16 (24.6)
T-stenting	n, (%)	21 (32.3)
Proximal optimization technique	n, (%)	333 (53.1)
Side branch dilation in 1-stent	n, (%)	472 (75.0)
Kissing balloon inflation	n, (%)	390 (62.0)
Side branch dilation alone	n, (%)	82 (13.0)
Mechanical cardiac support device	n, (%)	122 (16.4)
Intra-aortic balloon pumping	n, (%)	117 (15.8)
Extracorporeal membrane oxygenation	n, (%)	20 (2.7)
Lesion modification		
Rotational/Orbital atherectomy	n, (%)	68 (9.2)
Directional coronary atherectomy	n, (%)	10 (1.4)
Scoring balloon	n, (%)	145 (19.7)
Main vessel stent		
Size: ≥ 4.0 mm	n, (%)	117 (16.0)
3.5–4.0 mm	n, (%)	390 (53.3)
3.0–3.5 mm	n, (%)	187 (25.5)
2.5–3.0 mm	n, (%)	33 (4.5)

<2.5 mm	n, (%)	5 (0.7)
Length	mm	23.0±8.5
Product		
Xience	n, (%)	359 (49.4)
Synergy/Promus	n, (%)	129 (17.8)
Resolute Integrity/Onyx	n, (%)	79 (10.9)
Ultimaster	n, (%)	106 (14.6)
Nobori/BioFreedom	n, (%)	38 (5.2)
Orsilo	n, (%)	14 (1.9)
Bare metal stent	n, (%)	1 (0.1)
Side branch		
Size: ≥4.0 mm	n, (%)	4 (4.8)
3.5–4.0 mm	n, (%)	7 (8.4)
3.0–3.5 mm	n, (%)	34 (41.0)
2.5–3.0 mm	n, (%)	29 (34.9)
<2.5 mm	n, (%)	9 (10.8)
Length	mm	21.6±7.8
Product		

Xience	n, (%)	34 (41.0)
Synergy/Promus	n, (%)	16 (19.3)
Resolute Integrity/Onyx	n, (%)	13 (15.7)
Ultimaster	n, (%)	17 (20.5)
Nobori/BioFreedom	n, (%)	1 (1.2)
Orsilo	n, (%)	2 (2.4)
Bare metal stent	n, (%)	0 (0)
Procedural success	n, (%)	730 (98.6)

1

2

1 **Table 3. Clinical outcomes at the 1-year follow-up**

2

Adverse events		frequency
All-cause death	n (%)	66 (8.9)
Cardiac death	n (%)	25 (3.4)
Cerebrovascular disorder	n (%)	9 (1.2)
Clinically driven revascularization	n (%)	61 (8.2)
Target vessel revascularization	n (%)	34 (4.6)
Target lesion revascularization	n (%)	15 (2.0)
Stent thrombosis	n (%)	2 (0.3)
Myocardial infarction	n (%)	14 (1.9)
Worsening renal function	n (%)	12 (1.6)
Major adverse cardiovascular and cerebrovascular events	n (%)	130 (17.5)

3

4

1 **Table 4. Multivariate analysis of the risk of major adverse cardiovascular and**
 2 **cerebrovascular events**

3

Variables	Hazard ratio	95% CI	P value
Age (10 years increase)	1.00	0.79–1.27	0.979
Male	1.13	0.71–1.81	0.597
Smoker	1.31	0.89–1.93	0.178
Body mass index (1 kg/m ² increase)	1.04	0.95–1.14	0.372
eGFR (10 mL/min/1.73 m ² increase)	0.84	0.67–1.04	0.107
Left ventricular ejection fraction (10% increase)	0.72	0.52–0.99	0.041
Dyslipidemia	0.90	0.60–1.33	0.592
Hypertension	1.19	0.76–1.86	0.438
Diabetes mellitus	0.99	0.68–1.43	0.952
CCS ≥class III	2.07	1.39–3.07	<0.001
Residual significant stenosis after PCI	1.31	0.85–2.00	0.221
Radial access	0.62	0.42–0.91	0.015
Mechanical cardiac support device	2.17	1.43–3.30	<0.001
Lesion modification: rotational or orbital	1.40	0.78–2.53	0.260

atherectomy			
Left main stent size >3.5 mm	0.75	0.51–1.10	0.140
Two-stent implantation	2.49	1.48–4.18	0.001
True bifurcation lesion	0.91	0.55–1.48	0.693
Proximal optimization technique	0.89	0.62–1.29	0.542

1

2 CI, confidence interval; eGFR, estimated glomerular filtration ratio; CCS, Canadian

3 Cardiovascular Society functional angina classification

Figure 1. Study flow of the extraction of the analyzed patients.

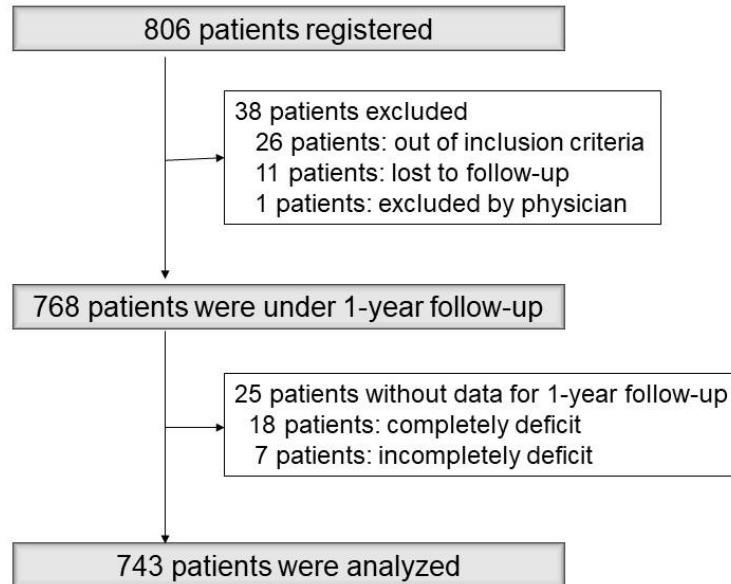


Figure 2. Cumulative curve of major adverse cardiovascular and cerebrovascular events. (a) Entire group. (b) The groups using or not using a mechanical cardiac support device (MCS). (c) Canadian Cardiovascular Society functional angina classification. (d) The groups treated with a single stent, two stents, and left main shaft stenting alone. (e) The groups of radial and nonradial access. (f) The groups of true bifurcation lesion, non-true bifurcation lesion, and non-bifurcation lesion.

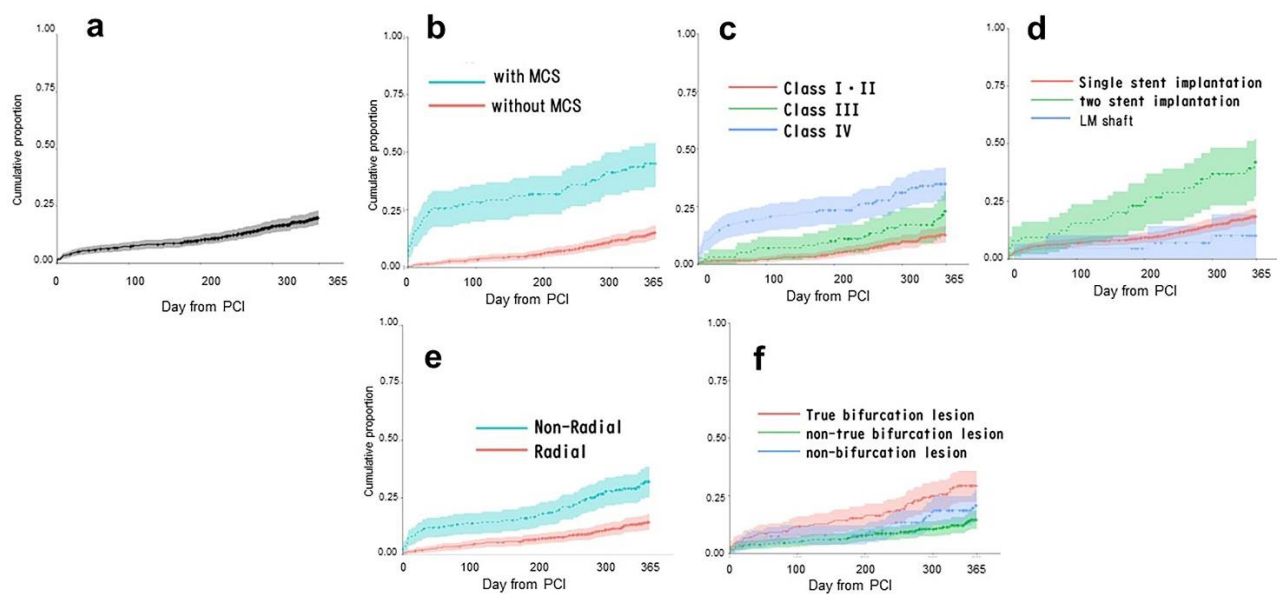


Figure 3. Cumulative curve of all-cause mortality. (a) Entire group. (b) The groups using or not using a mechanical cardiac support device (MCS). (c) Canadian Cardiovascular Society functional angina classification. (d) The groups treated with a single stent, two stents, and left main shaft stenting alone. (e) The groups of radial and nonradial access. (f) The groups of true bifurcation lesion, non-true bifurcation lesion, and non-bifurcation lesion.

