

Human-AI Collaboration in Large Language Model-Assisted Brain MRI Differential Diagnosis: A Usability Study

*Su Hwan Kim*¹, *Severin Schramm*¹, *Cornelius Berberich*¹, *Enrike Rosenkranz*¹, *Lena Schmitzer*¹, *Kerem Serguen*¹, *Christopher Klenk*², *Nicolas Lenhart*², *Claus Zimmer*¹, *Benedikt Wiestler*¹, *Dennis M. Hedderich*¹

¹*Department of Diagnostic and Interventional Neuroradiology, Klinikum rechts der Isar, School of Medicine, Technical University Munich, Munich, Germany*

²*Department of Diagnostic and Interventional Radiology, Klinikum rechts der Isar, School of Medicine, Technical University Munich, Munich, Germany*

Abbreviations

MRI Magnetic Resonance Imaging

LLM Large Language Model

NOTE: This preprint reports new research that has not been certified by peer review and should not be used to guide clinical practice.

Abstract

Background

Prior studies have shown the potential of large language models (LLMs) to support in differential diagnosis in radiology. However, the interaction of human users with LLMs in this context has not been evaluated.

Purpose

To investigate the impact of human-LLM collaboration on accuracy and efficiency of brain MRI differential diagnosis.

Methods

In this retrospective study, twenty brain MRI cases with a challenging but definitive diagnosis were selected and randomized into two groups. Six inexperienced radiology residents were instructed to determine the three most likely differential diagnoses for each of these cases via conventional internet search or utilizing an LLM-based search engine (© Perplexity AI, powered by GPT-4). Accuracy of suggested differential diagnoses was analyzed using the chi-square test and Mann-Whitney U test. Interpretation times were analyzed using the student's t-test. Benefits and challenges in human-LLM interaction were derived from observations and participant feedback.

Results

LLM-assisted brain MRI differential diagnosis yielded superior accuracy (38/59 [LLM-assisted] vs 25/59 [conventional] correct diagnoses, $p = 0.03$). No difference in interpretation time (8.12 +/- 3.22 min [LLM-assisted] vs 7.96 +/- 2.65 min [conventional], $p = 0.76$) or level of confidence (median of 2.5 [LLM-assisted] vs 3.0 [conventional], $p = 0.96$) was observed. Several challenges related to human errors and technical limitations were identified.

Conclusion

Human-LLM collaboration has the potential to improve brain MRI differential diagnosis. Yet, several challenges must be addressed to ensure effective adoption and user acceptance.

Introduction

Radiological differential diagnosis plays a crucial role in clinical care, profoundly influencing diagnostic and therapeutic decisions. Accurate determination of relevant differential diagnoses from image findings demands highly specialized knowledge of anatomy and pathophysiology along with proficiency in recognizing visual patterns and synthesizing comprehensive clinical information.

Recent studies suggest the emerging potential of large language models (LLMs) to execute radiological differential diagnosis based on case presentations (1–5). These studies compared the diagnostic suggestions of an LLM to expert assessments or confirmed diagnoses. Yet, the intricate interactions between human users and LLM systems in this context have not been explored.

Previous literature reveals the critical impact of human-AI interaction on diagnostic performance in radiology (6–8). One study employing an AI-based mammogram classification system demonstrated that inexperienced and experienced readers alike are susceptible to automation bias, which describes the inclination of human users to adhere to incorrect recommendations from automated decision-making systems (6). Similarly, incorrect AI results were shown to negatively impact radiologist performance in lung cancer detection based on chest radiography (7). Yet another study highlighted the significance of establishing effective human-AI collaboration protocols in AI-assisted knee MRI reading (8). Analogously, elements of human-AI collaboration could affect the outcomes of LLM-assisted differential diagnosis. In real-world practice, it is plausible that radiologists or radiology residents would use LLMs as an adjunct tool to support diagnostic reasoning rather than for fully autonomous differential diagnosis (9). Under these circumstances, the human medical professional assumes a pivotal position in contextualizing the available clinical and visual information, formulating the prompt, critically reviewing the LLM response, and conducting further research to eventually derive a conclusion. Particularly considering the well-known propensity of LLM systems to generate factually incorrect information (so-called hallucinations) (10,11), a comprehensive evaluation of how users realistically interact with these systems is imperative. Therefore, this study aimed to investigate the impact of human-LLM collaboration on accuracy and efficiency of brain MRI differential diagnosis.

Methods

Ethical approval was waived by the institutional review board.

Study Sample

Six radiology residents with less than 6 months of experience in neuroradiology were recruited from the local departments of radiology and neuroradiology as participants of the usability study and randomized into two groups. All participants provided informed consent. A total of twenty brain MRI exams obtained between 01/01/2016 and 12/31/2023 were selected from the local imaging database and randomized into two sets (Figure 1). In each brain MRI scan, the image finding in question was denoted by an arrow. Selection criteria for participants and MRI scans are shown in Table 1.

Large Language Model (LLM) and Chatbot Interface

PerplexityAI (© Perplexity AI Inc., San Francisco, USA) was chosen as chatbot interface, given its ability to access real-time web content and to indicate its sources of information. GPT-4 (Generative Pre-trained Transformer 4), OpenAI's most up-to-date LLM, was selected as the model powering the search queries.

Study Design

Initially, the LLM system was introduced to participants in a 10–15-minute training session to ensure familiarity with its operation and functionality. During this training, participants were presented several sample prompts and explored the tool using a selection of sample brain MRI cases. Then, each participant was tasked to determine the most likely differential diagnoses of the annotated image finding in the brain MRI scans via conventional internet search for half ($n = 10$) and via LLM-assisted search (© PerplexityAI) for the other half ($n = 10$) (Figure 1). Cases were excluded from the analysis if participants were familiar with the case, or the image finding was not recognized despite the annotation. Importantly, participants performing LLM-assisted search were allowed to conduct additional conventional internet search to validate LLM suggestions. Participants were allowed to submit up to three differential diagnoses, ranked by relevance. Alongside the MRI scan, participants received demographic and clinical details of the patient case. All prompts were phrased in

English. Interpretation times were measured using a time tracking software (Toggl Track, © Toggl OÜ, Tallinn, Estonia). Level of confidence was recorded for each case on a Likert scale from 1-5 (1: very low confidence, 5: very high confidence). During the usability sessions, notes of relevant observations and comments were taken by SHK and SS. Before and after the sessions, participants completed a questionnaire to evaluate the LLM-assisted search workflow and capture concerns, benefits, and limitations.

Analysis

To determine accuracy of differential diagnoses, two different scoring systems were applied. In the first approach, participant responses were classified as “correct” if the correct diagnosis was included among the submitted differential diagnoses and “incorrect” if it was not (binary scoring system). In the second approach, participant responses were assigned a score from 0 – 3, depending on the rank of the correct diagnosis within the response (numeric scoring system) (Table 2). Inferential statistics were performed using the chi-square test for binary scores and the Mann-Whitney U test for numeric scores and level of confidence. Interpretation times were analyzed using the student’s t-test. The level of significance was set at $p < 0.05$.

Likert-scale questions of the questionnaires were analyzed by descriptive statistics. Qualitative data from observation notes, comments and questionnaire responses were summarized in tables categorizing data by relevant topics. Data manipulation, analysis and visualization were performed using Python (version 3.9.7).

	Criteria	Rationale
Brain MRI Scans	Adult patient (at least 18 years old at time of exam)	To exclude conditions highly specific to a pediatric subpopulation
	Focal image finding	To define a clearly delimited finding for the participants to interpret
	Confirmed diagnosis	Confirmed diagnosis served as reference standard for comparison
	Initial diagnosis at time of exam	To simulate a more realistic scenario requiring differential diagnosis
	Non-trivial, less common conditions	To ensure cases were challenging enough to require further research
Radiology Residents	Less than 6 months of dedicated experience in neuroradiology	Inexperienced readers were hypothesized to benefit more from LLM-assistance than experienced ones

Table 1: Inclusion Criteria

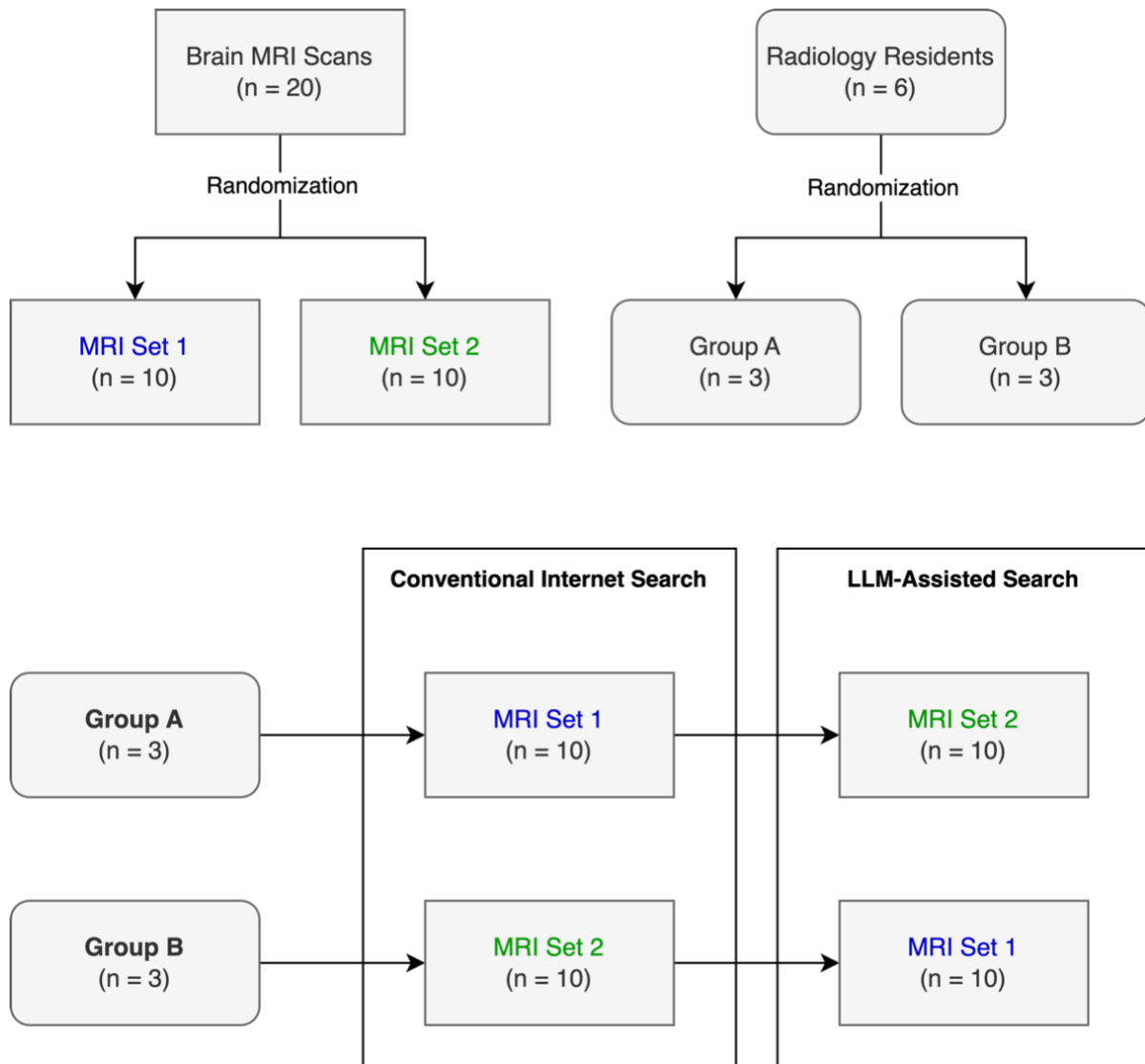


Figure 1: Study Design.

Score	Condition
3	Correct diagnosis ranked first
2	Correct diagnosis ranked second
1	Correct diagnosis ranked third
0	Correct diagnosis was not included in the response

Table 2: Numeric scoring system for evaluating differential diagnoses.

Results

Two responses were excluded from the analysis due to the participant's familiarity with the MRI scan or inability to recognize the annotated image finding. An overview of selected clinical cases is provided in Supplement 1.

Quantitative Findings

LLM-assisted brain MRI differential diagnosis yielded superior accuracy, as evaluated by both binary (38/59 [LLM-assisted] vs 25/59 [conventional] correct diagnoses, $p = 0.03$) and numeric scoring approach (median score of 2 [LLM-assisted] vs 0 [conventional], $p = 0.04$) (Figure 2). No difference in interpretation time (8.12 +/- 3.22 min [LLM-assisted] vs 7.96 +/- 2.65 min [conventional], $p = 0.76$) was observed (Figure 3). Similarly, the level of confidence did not differ significantly (median of 2.5 [LLM-assisted] vs 3.0 [conventional], $p = 0.96$). A screenshot of a sample LLM response is shown in Figure 4. Questionnaire results revealed a moderately positive evaluation of the LLM-assisted workflow. Participants showed a slight tendency in favor of using the LLM tool in clinical practice (median: 4). Quality of LLM responses were rated rather positively (median: 4). The LLM system was easily adopted into the diagnostic workflow by most participants (median: 4). The overall experience of the LLM-assisted search workflow was mixed (median: 3.5) (Figure 5).

Qualitative Findings

Several challenges in human-LLM interaction related to both human errors and technical limitations were observed (Table 3). Misleading or inaccurate search results attributable to human errors included inaccurate descriptions of image findings (e.g. describing the location of a cerebral cavernous venous malformation as "extra-axial") or an omission of relevant imaging features (e.g. omission of multinodular morphology of a multinodular and vacuolating neuronal tumor; MVNT). LLM search, in contrast, exhibited bias based on clinical information irrelevant to the diagnosis (e.g. history of kidney transplantation in a patient with posterior reversible encephalopathy syndrome; PRES) or connotative terminology (e.g. the term "juxtacortical" was strongly associated with multiple sclerosis). Participant feedback on LLM-assisted differential diagnosis is illustrated in Table 4. Prior to the usability sessions, several participants

expressed concerns about excessive reliance on the LLM system and consecutive impairment of their own radiological training. Following the testing, participants pointed out the ability to give flexible instructions regarding scope (e.g. quantity of differential diagnoses) and format (e.g. bullet points, table, sample images) of the search result as a key advantage over conventional internet search. Participants believed that usability of the LLM system for differential diagnosis could be enhanced by enabling voice-based interactions and improving the accuracy of returned sample images.

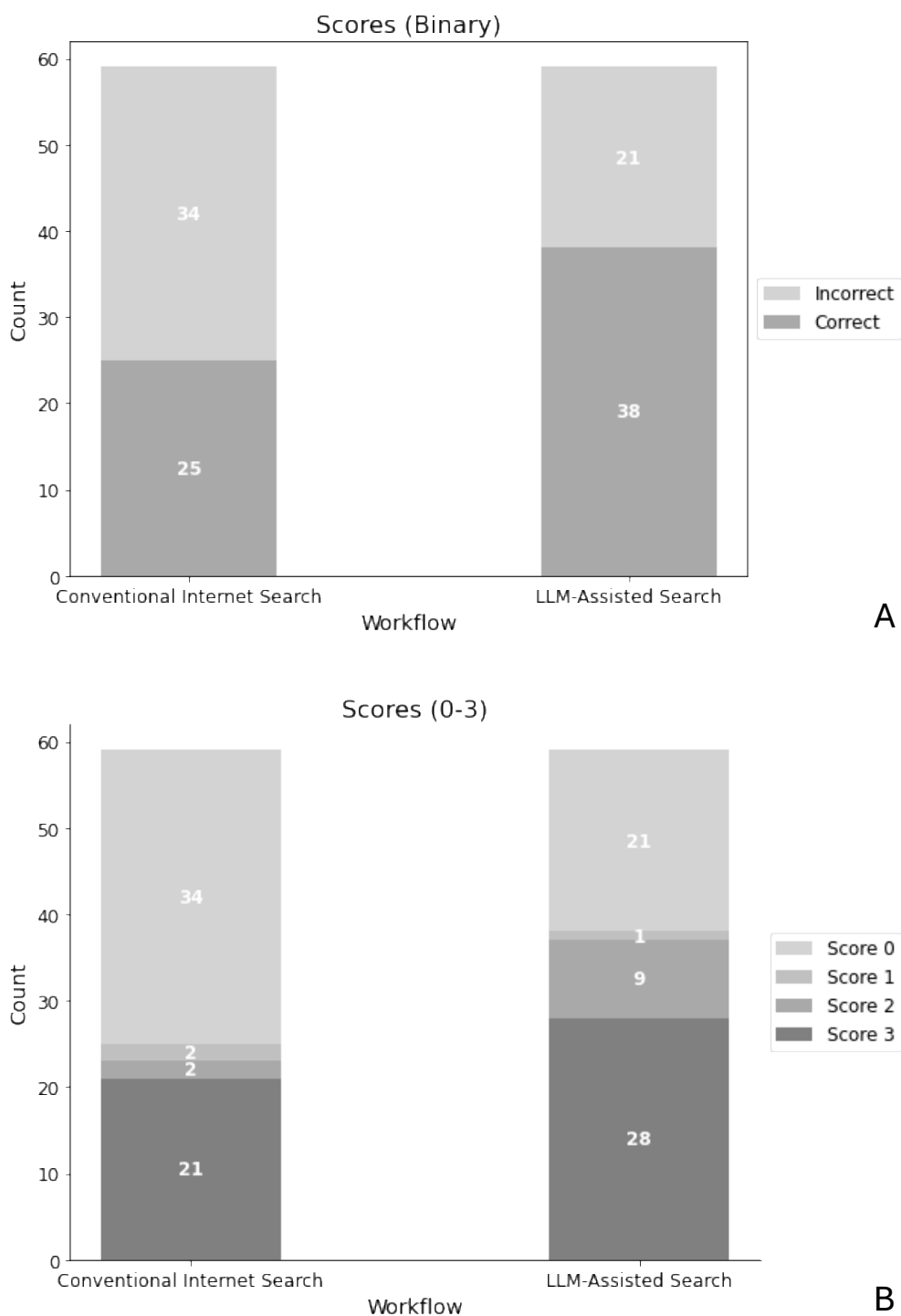


Figure 2: Accuracy of differential diagnoses by workflow. A: Binary scoring system. Participant responses were classified as either correct or incorrect. LLM-assisted workflow yielded superior scores ($p = 0.03$). B: Numeric scoring system. A participant's response was assigned a score between 0 and 3, depending on the rank of the correct diagnosis within the response (3: correct diagnosis ranked first, 0: correct diagnosis not included in response). LLM-assisted workflow yielded superior scores ($p = 0.04$).

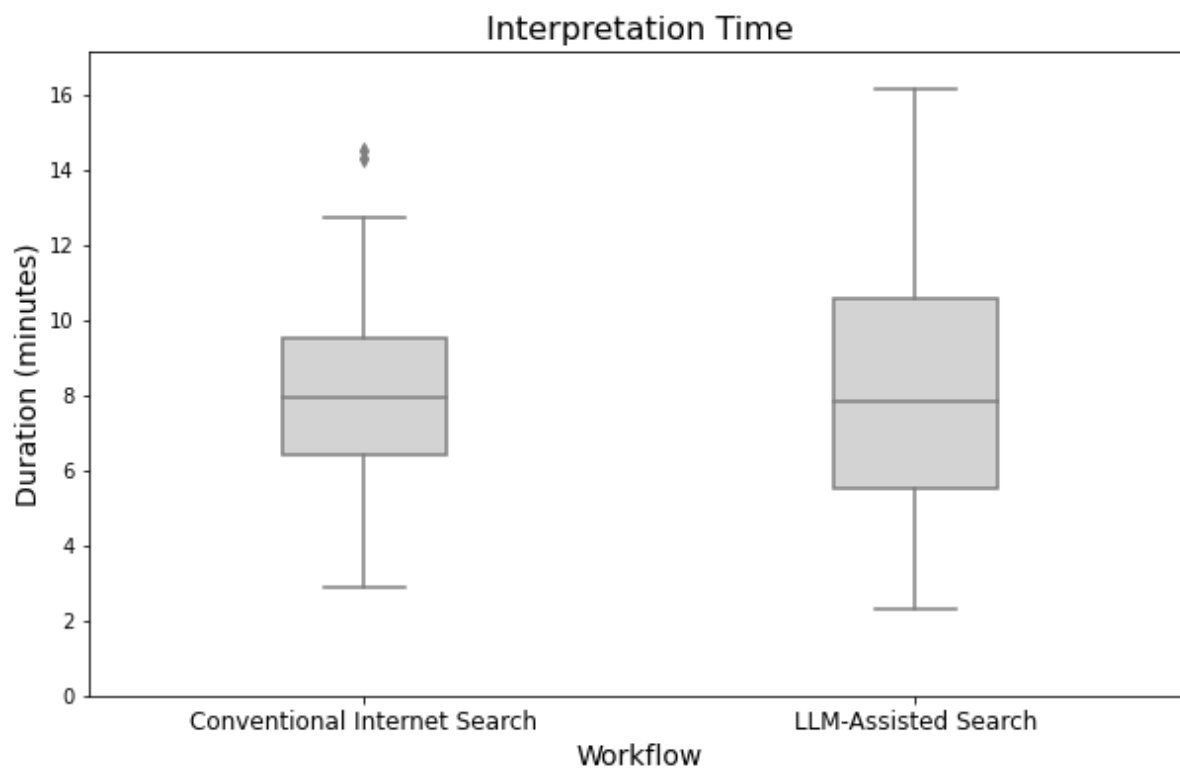


Figure 3: Interpretation time. Interpretation times did not exhibit any statistically significant difference ($p = 0.76$).

In a brain MRI of a male in his 30s, there is a partially cystic, contrast-enhancing, hypervascularized tumor in the cerebellum. What are the most likely differential diagnoses?

Sources

Differential Diagnosis of Intracranial Masses [nih](#) · 1

Differential diagnosis of posterior fossa brain... [nih](#) · 2

Differential diagnoses for temporal lobe tumors [...]
[radiopaedia](#) · 3

[View 2 more](#)

Answer

Based on the description of a partially cystic, contrast-enhancing, hypervascularized tumor in the cerebellum of a male in his 30s, the most likely differential diagnoses include:

- Hemangioblastoma: These are often cystic and can be hypervascular, commonly found in the cerebellum.
- Metastasis: Secondary tumors can present with contrast enhancement and cystic components, although they may not be as hypervascular.
- Pilocytic astrocytoma: Typically seen in younger patients, these can be cystic and enhance with contrast, but they are less commonly hypervascular.
- Medulloblastoma: Although more common in children, they can occur in young adults and present with similar imaging features.

It is important to note that the definitive diagnosis would require further clinical correlation and possibly biopsy for histopathological examination.

[Share](#) [Rewrite](#)

[GPT-4](#)

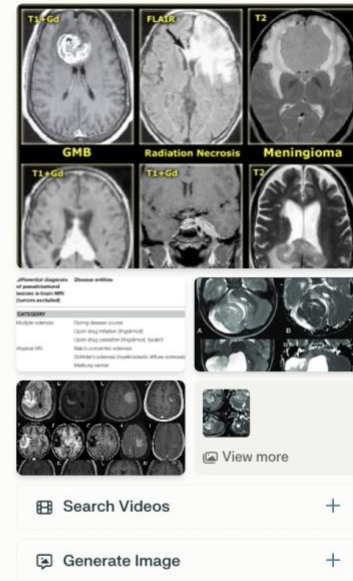


Figure 4: Screenshot of a sample LLM query (PerplexityAI). The correct diagnosis sought in this case was hemangioblastoma.

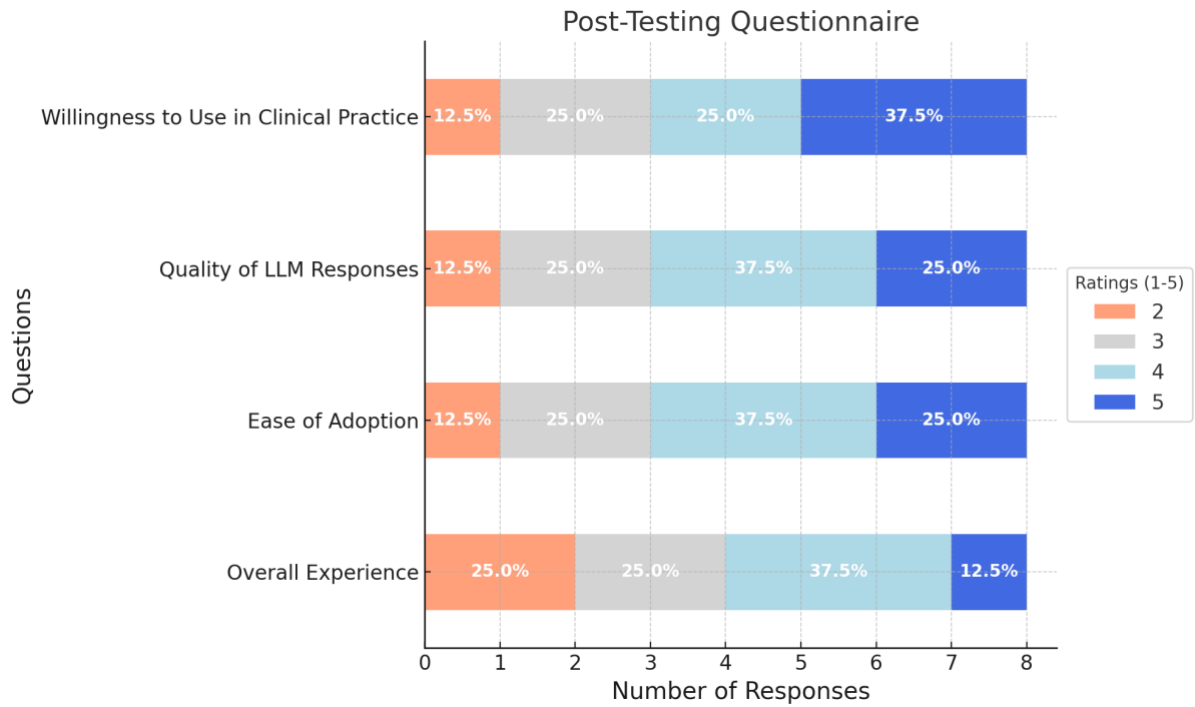


Figure 5: Post-testing questionnaire results (1: very low, 5: very high).

Challenges	Examples
Omission of relevant clinical information	- Omitting the age in a patient with spinocerebellar ataxia (resulted in misleading suggestions such as atypical Parkinson syndrome)
Inclusion of clinical information irrelevant to the diagnosis	- Indicating recent history of head trauma in a patient with an incidental finding (benign enhancing foramen magnum lesion) - Indicating a history of kidney transplantation in a patient with posterior reversible encephalopathy syndrome (PRES)
Inaccurate description of imaging findings	- Describing the location of a cerebral cavernous venous malformation as “subarachnoid” or “extra-axial” - Searching for differential diagnoses of global brain atrophy in a patient with focal atrophy of the caudate head
Omission of relevant imaging features	- Omitting the bubbly or multinodular appearance of a multinodular and vacuolating neuronal tumor (MVNT) resulted in highly unspecific suggestions
Usage of connotative terminology	- Describing the location of a lesion as “juxtacortical” in a patient with MVNT (was strongly associated with multiple sclerosis)
LLM returning completely unrelated content (very few)	- Upon a request for sample images of progressive multifocal leukoencephalopathy (PML), images of the prime minister of India were returned

Table 3: Challenges during human-LLM interaction derived from observations and participant comments.

Theme	Comments
Concerns (pre-testing)	Residents might develop a strong dependence on the tool, educational effect could be impaired
	Excessive reliance on LLM tool can promote intellectual laziness and carelessness in image interpretation
	LLMs are known to create hallucinations, source of information is not always clear
	The role of the radiologist might become obsolete as core tasks are increasingly overtaken by AI tools including LLMs
Benefits	Possibility to phrase open questions rather than rigid keyword searches is liberating
	Links to information sources are embedded in the response
	Instructions can be given regarding the scope (e.g. quantity of differential diagnoses suggested) and format of the response (e.g. table, bullet points)
	The context of prior queries is retained so that follow-up questions can be posed
	Useful to obtain a quick overview of a broad range of differential diagnoses
Suggestions for improvement	Interaction with the LLM system via voice
	Improved search of relevant sample images
	Quantitative data regarding the probability of certain diagnoses in the presence of specific imaging features

Table 4: Participant comments on LLM-assisted differential diagnosis.

Discussion

In this study, we conducted usability experiments to explore the role of human-LLM collaboration in brain MRI differential diagnosis. Our results suggest that an LLM-assisted workflow has the potential to increase diagnostic accuracy as compared to conventional internet search. Yet, no clear effect on interpretation times and reader confidence was observed. Participant ratings of the LLM-assisted workflow were only neutral to slightly positive. These findings are consistent with the observed frustration and delays caused by misleading LLM outputs. These were frequently due to irrelevant or omitted information in prompts, highlighting the critical role of human readers to contextualize and filter available information. In addition, effective differential diagnosis was contingent on critical evaluation and validation of initial LLM recommendations. Readers typically conducted further research to correlate image findings with sample images of suggested diagnoses. Focused internet search on trusted websites (e.g. Radiopaedia) proved more effective for this purpose, indicating that the joint use of LLMs and conventional internet search might outperform the exclusive use of LLMs. A conceptual model illustrating the role of the human agent in LLM-assisted differential diagnosis and potential sources of error is shown in Figure 6. Altogether, our results underline the necessity to study collaborative efforts between humans and LLMs over LLMs in isolation to better reflect real-world conditions. While LLMs can augment human capabilities, traditional neuroradiological expertise remains indispensable for their effective utilization.

Notably, rapid advancements in LLM technology demand continuous evaluations. Recent innovations, such as voice assistants enabling conversational interactions (e.g. as featured in OpenAI's ChatGPT), are transforming LLM usability. Earlier, the introduction of speech recognition dictation systems has enhanced productivity in radiology departments (12). It is yet to be determined whether voice interaction with LLMs can yield similar benefits. The emergence of multimodal LLMs capable of processing image inputs is expected to create new possibilities. Few recent studies have demonstrated their potential to generate chest x-ray reports (13), and answer USMLE questions involving radiological images (14). In radiological differential diagnosis, direct image processing by LLMs could significantly alter human-LLM interactions by eliminating the need for human image descriptions. Seamless integration of LLMs into established health information systems could further boost

productivity. For instance, prompt generation could be streamlined by directly importing clinical information from a RIS or selecting a key image from a PACS system as input.

This study has several limitations. First, only radiology residents with less than six months of experience in neuroradiology were included, based on the assumption that this group would be most likely to require additional research for differential diagnosis. It is unclear whether our findings would apply to more experienced readers. Second, human-LLM interactions were evaluated in a controlled environment but not in a real-world clinical setting, where frequent interruptions and intense workload might alter reader behavior. Third, the participants' familiarity with the LLM system was limited, compared to their extensive experience with conventional internet search. Additional exposure and training could help users formulate more effective prompts, thereby reducing frustration and inefficiencies. Finally, a general-purpose LLM (GPT-4) was used. Models specifically trained for medicine (e.g. MED-PALM, GlassAI) (15–17) or radiology (18–20) are anticipated to further enhance clinical utility.

In conclusion, our study shows that human-LLM collaboration has the potential to enhance differential diagnosis of brain MRI but recognizes the necessity to mitigate both human and technical errors to maximize effectiveness.

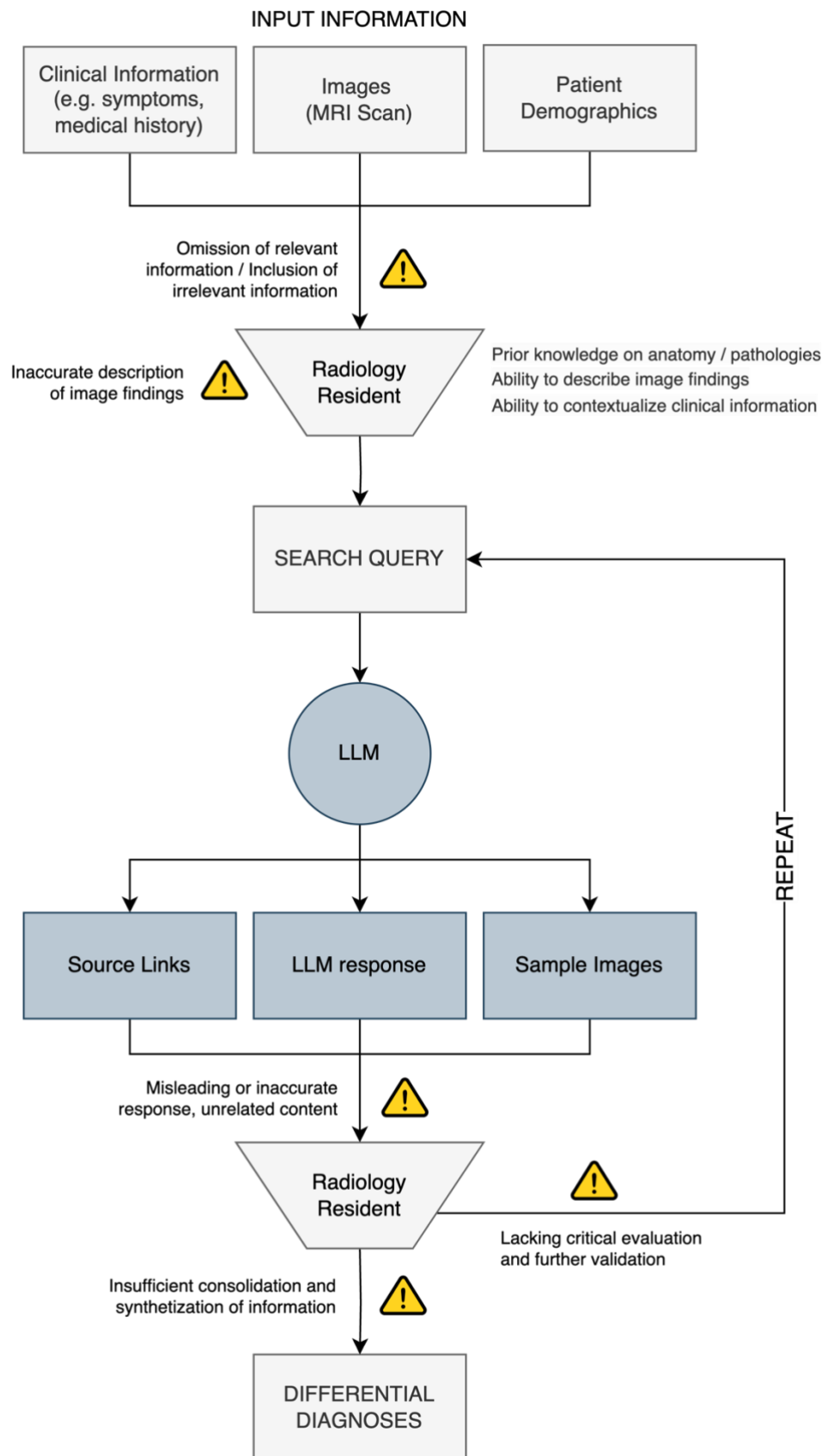


Figure 6: Conceptual model of human-LLM-Interaction for radiological differential diagnosis. Warning icons indicate potential sources of error in human-LLM collaboration.

References

1. Kumar Sarangi P, Irodi A, Panda S, Swapnesh Kumar Nayak D, Mondal H. Radiological Differential Diagnoses Based on Cardiovascular and Thoracic Imaging Patterns: Perspectives of Four Large Language Models. *Indian Journal of Radiology and Imaging*. 2023; doi: 10.1055/s-0043-1777289.
2. Horiuchi D, Tatekawa H, Shimono T, et al. Accuracy of ChatGPT generated diagnosis from patient's medical history and imaging findings in neuroradiology cases. *Neuroradiology*. *Neuroradiology*; 2024;66(1). doi: 10.1007/S00234-023-03252-4.
3. Ueda D, Mitsuyama Y, Takita H, et al. ChatGPT's Diagnostic Performance from Patient History and Imaging Findings on the Diagnosis Please Quizzes. *Radiology*. *Radiological Society of North America Inc.*; 2023;308(1). doi: 10.1148/RADIOL.231040.
4. Kottlors J, Bratke G, Rauen P, et al. Feasibility of Differential Diagnosis Based on Imaging Patterns Using a Large Language Model. *Radiology*. *Radiological Society of North America Inc.*; 2023;308(1). doi: 10.1148/radiol.231167.
5. Bhayana R, Bleakney RR, Krishna S. GPT-4 in Radiology: Improvements in Advanced Reasoning. *Radiology*. *Radiological Society of North America Inc.*; 2023;307(5). doi: 10.1148/RADIOL.230987.
6. Dratsch T, Chen X, Mehrizi MR, et al. Automation Bias in Mammography: The Impact of Artificial Intelligence BI-RADS Suggestions on Reader Performance. *Radiology*. *Radiological Society of North America Inc.*; 2023;307(4). doi: 10.1148/RADIOL.222176.
7. Bernstein MH, Atalay MK, Dibble EH, et al. Can incorrect artificial intelligence (AI) results impact radiologists, and if so, what can we do about it? A multi-reader pilot study of lung cancer detection with chest radiography. *Eur Radiol*. Springer Science and Business Media Deutschland GmbH; 2023;33(11):8263–8269. doi: 10.1007/S00330-023-09747-1.
8. Cabitza F, Campagner A, Sconfienza LM. Studying human-AI collaboration protocols: the case of the Kasparov's law in radiological double reading. *Health Inf Sci Syst*. Springer Science and Business Media Deutschland GmbH; 2021;9(1):1–20. doi: 10.1007/S13755-021-00138-8.

9. Shah NH, Entwistle D, Pfeffer MA. Creation and Adoption of Large Language Models in Medicine. *JAMA*. American Medical Association; 2023;330(9):866–869. doi: 10.1001/JAMA.2023.14217.
10. Pal A, Umapathi LK, Sankarasubbu M. Med-HALT: Medical Domain Hallucination Test for Large Language Models. arXiv preprint. Association for Computational Linguistics (ACL); 2023;314–334. doi: 10.18653/v1/2023.conll-1.21.
11. Azamfirei R, Kudchadkar SR, Fackler J. Large language models and the perils of their hallucinations. *Crit Care*. BioMed Central Ltd; 2023;27(1):1–2. doi: 10.1186/S13054-023-04393-X.
12. Al-Aiad A, Momani AK, Alnsour Y, Alsharo M. The Impact of Speech Recognition Systems on The Productivity and The Workflow in Radiology Departments: A Systematic Review. *AMCIS 2020 TREOs*. 2020; https://aisel.aisnet.org/treos_amcis2020/62. Accessed January 14, 2024.
13. Hyland SL, Bannur S, Bouzid K, et al. MAIRA-1: A specialised large multimodal model for radiology report generation. arXiv preprint. 2023; <https://arxiv.org/abs/2311.13668v1>. Accessed January 14, 2024.
14. Yang Z, Yao Z, Tasmin M, et al. Performance of Multimodal GPT-4V on USMLE with Image: Potential for Imaging Diagnostic Support with Explanations. medRxiv. Cold Spring Harbor Laboratory Press; 2023;2023.10.26.23297629. doi: 10.1101/2023.10.26.23297629.
15. Nazario-Johnson L, Zaki HA, Tung GA. Use of Large Language Models to Predict Neuroimaging. *Journal of the American College of Radiology*. Elsevier; 2023;20(10):1004–1009. doi: 10.1016/J.JACR.2023.06.008.
16. Singhal K, Tu T, Gottweis J, et al. Towards Expert-Level Medical Question Answering with Large Language Models. 2023; <https://arxiv.org/abs/2305.09617v1>. Accessed January 15, 2024.
17. Li Y, Li Z, Zhang K, Dan R, Jiang S, Zhang Y. ChatDoctor: A Medical Chat Model Fine-Tuned on a Large Language Model Meta-AI (LLaMA) Using Medical Domain Knowledge. *Cureus*. Springer Science and Business Media LLC; 2023; doi: 10.7759/cureus.40895.
18. Yan A, McAuley J, Lu X, et al. RadBERT: Adapting Transformer-based Language Models to Radiology. *Radiol Artif Intell*. Radiological Society of North America Inc.; 2022;4(4):210258. doi: 10.1148/ryai.210258.

19. Liu Z, Li Y, Shu P, et al. Radiology-Llama2: Best-in-Class Large Language Model for Radiology. 2023; <https://arxiv.org/abs/2309.06419v1>. Accessed January 15, 2024.
20. Liu Z, Zhong A, Li Y, et al. Tailoring Large Language Models to Radiology: A Preliminary Approach to LLM Adaptation for a Highly Specialized Domain. Lecture Notes in Computer Science (including subseries Lecture Notes in Artificial Intelligence and Lecture Notes in Bioinformatics). Springer Science and Business Media Deutschland GmbH; 2024;14348 LNCS:464–473. doi: 10.1007/978-3-031-45673-2_46.