

1 **Interstitial Fibrosis and Arrhythmic Mitral Valve Prolapse: Unravelling Sex-**
2 **Based Differences**

3 Lionel Tastet, Ph.D.¹; Shalini Dixit, M.D.¹; Thuy Nguyen, M.D.¹; Lisa J. Lim, M.S.¹; Mohammad
4 Al-Akchar, M.D.²; Dwight Bibby, RDCS¹; Farzin Arya, M.D.¹; Luca Cristin, M.D.¹; Shafkat
5 Anwar, M.D.³; Satoshi Higuchi, M.D.⁴; Henry Hsia, M.D.⁴; Yoo Jin Lee, M.D.⁵; Francesca N.
6 Delling, M.D., M.P.H.¹

7 ¹Department of Medicine (Cardiovascular Division), University of California, San Francisco,
8 California, USA

9 ²Carle Illinois School of Medicine, University of Illinois-Urbana Champaign, Illinois, USA

10 ³Department of Pediatrics, Division of Cardiology, University of California, San Francisco,
11 California, USA

12 ⁴Department of Electrophysiology, Division of Cardiology, University of California, San
13 Francisco, California, USA

14 ⁵Department of Radiology, Division of Cardiology, University of California, San Francisco,
15 California, USA

16 **Address for correspondence:**

17 Dr Francesca N. Delling
18 University of California, San Francisco
19 555 Mission Bay Blvd South
20 San Francisco, CA 94158
21 E-mail: Francesca.Delling@ucsf.edu
22 Telephone number: 4154762796
23 Fax number: 4155027949

24 **Short title:** Interstitial Fibrosis and Sex in Arrhythmic MVP

25

1 ABSTRACT

2 **Background:** Interstitial fibrosis as quantified by cardiac magnetic resonance (CMR) has been
3 demonstrated in arrhythmic mitral valve prolapse (MVP), a condition with known female
4 predominance. However, prior studies included only MVP cases with significant mitral
5 regurgitation (MR) or mitral annular disjunction (MAD). We sought to evaluate the association
6 between interstitial fibrosis and complex ventricular ectopy (ComVE) in MVPs unselected for
7 MAD or severe MR, and to investigate the contribution of sex to this association.

8 **Methods:** We performed contrast CMR in consecutive individuals with MVP between 2020 and
9 2022. Extracellular volume fraction (ECV%), a surrogate marker for interstitial fibrosis, was
10 quantified using T₁ mapping. Replacement fibrosis was assessed using late gadolinium
11 enhancement (LGE). ComVE, defined as frequent premature ventricular contractions and/or non-
12 sustained/sustained ventricular tachycardia (VT), was detected using ambulatory ECG
13 monitoring.

14 **Results:** We identified 59 MVP cases without severe MR (49% women, 80% with mild or less
15 MR) and available ECV% measurement. Among these, 23 (39%) had ComVE, including a case
16 of aborted ventricular fibrillation (VF) and one with sudden arrhythmic death, both females.
17 Global ECV% was significantly greater in ComVE versus non-ComVE (31%[27-33] vs 27%[23-
18 30], p=0.002). In MVP-ComVE, higher segmental ECV% was not limited to the
19 inferolateral/inferior LV wall, but was also demonstrated in atypical segments including the
20 anterior/anterolateral wall (p<0.05). The association between ComVE and ECV% was driven by
21 female sex (32%[30-33] vs 28%[26-30], p=0.003 in females; 31%[25-33] vs 26%[23-30], p=0.22
22 in males). ECV% remained independently associated with an increased risk of ComVE, including
23 VT/VF, after adjustment for cardiovascular risk factors, MAD, and LGE (p<0.01).

1 **Conclusion:** In MVP without significant MR, interstitial fibrosis by CMR is associated with an
2 increased risk of ComVE, suggesting a primary myopathic process. The stronger association
3 between interstitial fibrosis and ComVE in females may explain why severe arrhythmic
4 complications are more prevalent among women.

5
6 **KEY WORDS:** Mitral valve prolapse, interstitial myocardial fibrosis, arrhythmia, sex
7 differences

8

1

ABBREVIATIONS

2 MVP = mitral valve prolapse

3 MR = mitral regurgitation

4 SCD = sudden cardiac death

5 LV = left ventricular/ventricle

6 ComVE = complex ventricular ectopy

7 LGE = late gadolinium enhancement

8 CMR = cardiac magnetic resonance

9 ECV = extracellular volume fraction

10

1 INTRODUCTION

2 Mitral valve prolapse (MVP) is a common heritable condition affecting 2% to 3% of individuals
3 worldwide.¹ MVP without significant mitral regurgitation (MR) is generally considered a benign
4 condition. However, a small but non-negligible subset of MVP subjects (0.14% to 1.8% yearly)
5 are at risk of life-threatening arrhythmic events and sudden cardiac death (SCD).^{2, 3} This
6 “malignant” form of MVP has been commonly associated with female sex, younger age, bileaflet
7 involvement with multi-segmental myxomatous disease, replacement fibrosis in the papillary
8 muscles and adjacent left ventricular (LV) wall, and complex ventricular ectopy (ComVE).³⁻⁵
9 ComVE, defined as non-sustained or sustained ventricular tachycardia (VT) and/or frequent
10 pleomorphic PVCs, may be found even in MVP without significant MR and is associated with
11 excess mortality.⁵⁻⁷

12 The role of myocardial fibrosis as a substrate for ComVE and SCD in MVP is supported by
13 seminal histologic and imaging studies.⁸⁻¹¹ Indeed, MVP-related abnormal valvular-myocardial
14 mechanics related to greater prolapse, mitral annular disjunction (MAD), excessive displacement
15 of papillary muscles, and curling of the basal myocardium may induce myocardial fibrosis.¹²
16 Replacement fibrosis, typically involving the papillary muscles and LV inferolateral wall, can be
17 detected by late gadolinium enhancement (LGE) on cardiac magnetic resonance (CMR) and
18 relates to arrhythmic MVP.^{9, 13-15} However, ComVE may be present even in the absence of
19 replacement myocardial fibrosis.^{10, 16} In addition to LGE, CMR can detect diffuse or interstitial
20 fibrosis using the extracellular volume fraction (ECV%) calculated from T₁ mapping.^{17, 18} As
21 shown by our group in a post-mortem investigation¹⁹, diffuse interstitial myocardial fibrosis
22 could represent an alternative substrate for life-threatening arrhythmia in MVP²⁰, regardless of
23 MR severity or replacement fibrosis. Prior studies investigating the role of T₁ mapping/ECV% in
24 arrhythmic MVP have included mostly cases with severe MR, limiting our understanding about

1 the presence of a primary myopathic process in MVP.^{20, 21} Furthermore, it remains uncertain
2 whether sex-related differences, which may impact not only the mitral valve apparatus, but also
3 myocardial structure and function, could influence the contribution of diffuse myocardial fibrosis
4 to ComVE in MVP.²²

5 We therefore hypothesized that among MVPs without significant MR: *1*) interstitial fibrosis as
6 quantified by global ECV% on CMR is increased in those with ComVE, suggesting a primary
7 myopathy in MVP; and *2*) the relationship between interstitial fibrosis and ComVE is influenced
8 by female sex.

9

10 **METHODS**

11 **Study Population**

12 We identified 113 consecutive MVPs recruited as part of the University of California San
13 Francisco (UCSF) MVP Registry from 2020 to 2022 with adequate contrast CMR/T1 mapping
14 and without the following: i) severe MR and/or prior mitral valve (MV) intervention; ii) ischemic
15 or non-ischemic cardiomyopathy (including sarcoidosis); iii) LV ejection fraction <35%; iv)
16 complex congenital heart disease; v) >mild aortic valve disease; or vi) prior defibrillator
17 implantation. Eleven studies were excluded because of the lack of comprehensive ambulatory
18 ECG monitoring to ascertain ventricular arrhythmia. All remaining 59 MVPs had complete
19 demographic/ clinical variables within a calculated Charlson comorbidities index,²³ and
20 laboratory, ambulatory ECG and CMR data. Ethics Committee of UCSF approved the study and
21 participants gave informed consent. All data produced in the present study are available upon
22 reasonable request to the authors.

23

24 **Ascertainment of Ventricular Arrhythmia**

1 Ventricular arrhythmia data were ascertained through 48-hour Holter monitors. ComVE was
2 defined as: $\geq 5\%$ burden of pleomorphic premature ventricular contractions (PVCs) (isolated
3 and/or in couplets/triplets), presence of sustained or non-sustained ventricular tachycardia
4 (NSVT), or ventricular fibrillation (VF).^{7, 16} Arrhythmic cause of death was ascertained using the
5 National Death Index for SCD cases. PVC burden and origin (i.e., papillary muscles, mitral
6 valve/annulus, LV/RV outflow tract, or other) were also recorded. Pleomorphic ventricular
7 ectopy was defined as PVCs of at least 2 different morphologies. NSVT was defined as > 3 PVCs
8 with a rate > 100 bpm lasting < 30 seconds.¹⁶

9

10 **Cardiac Magnetic Resonance Imaging**

11 *Acquisition*

12 Imaging was performed using the UCSF Core using 3.0T scanners Discovery MR750w or
13 SIGNA Premier (GE Healthcare, Milwaukee, WI).²⁴ Briefly, standard long- and short-axis cine
14 images covering the entire LV were obtained using a balanced steady-state free precession
15 sequence. Typical parameters were TR/TE 2.8/1.3ms, flip angle 45° . LGE was performed 5-15
16 min following injection of 0.1 mmol/kg gadobutrol, and images were obtained using a high-
17 resolution breath-hold two-dimensional sequence at three separate levels in the short-axis plane
18 (basal, mid, and apical). An inversion-recovery fast gradient-echo sequence was performed in
19 two phase-encoding directions to differentiate true late enhancement from artefact.^{25, 26} The
20 inversion time was optimized to achieve satisfactory nulling of the myocardium. T_1 mapping data
21 were acquired using a Modified Look-Locker Inversion-recovery (MOLLI) sequence with built-
22 in motion correction and an acquisition scheme of 3(3)-3(3)-5 both before and following contrast
23 agent administration. Two-dimension (2D) phase-contrast (through-plane), velocity-encoded,
24 imaging approach through the aortic valve was performed to quantify MR.

1

2 *Image Analysis*

3 Image analysis was performed offline using a standardized approach (cvi42 version 5.14.0, Circle
4 Cardiovascular Imaging Inc., Calgary, Canada). LV volume and mass were indexed to body
5 surface area. Papillary muscles were included when measuring LV mass and excluded when
6 measuring volumes.²⁶ MVP was defined as superior displacement of one or both mitral leaflets
7 >2 mm beyond the mitral annulus on long axis view, as previously described.⁸ The MVP
8 phenotype was further subdivided as: bileaflet or single-leaflet (anterior or posterior). MR
9 volume was calculated as the difference between LV stroke volume and the forward aortic flow
10 volume. MR fraction was obtained by dividing MR volume by the LV stroke volume. MR
11 severity was assessed using on a qualitative and/or quantitative approach, with visual assessment
12 or 2D phase-contrast imaging when available.

13 The presence of MAD (inferolateral vs inferior, anterior, or anterolateral) was assessed
14 qualitatively on cine long-axis views as a separation between the left atrial wall at the level of
15 MV junction and the LV free wall.²⁷ In addition, LV “curling”, defined as an abnormal or
16 exaggerated basal myocardial systolic motion, was qualitatively and quantitatively assessed as
17 previously described.^{12, 14}

18 On dedicated images, LGE was quantified in a semi-automated manner using a signal intensity
19 threshold of >5 standard deviations above the mean value in a region of normal myocardium.
20 Areas of inversion artefact or signal contamination by epicardial fat or blood pool were manually
21 excluded. LGE quantification was expressed as percentage of LV mass.

22 T₁ mapping data were generated from a short-axis cine stack of the LV, and the regions of the
23 endocardium and epicardium on the native T₁ maps were manually contoured to avoid partial-
24 volume or cardiac-motion-related blurring of the myocardium-blood boundary, where blood

1 signal may contaminate myocardial data. The LV mid-section was selected due to its greater
2 reproducibility and use in prior MVP-based CMR studies.^{21, 28} A 10% offset was also applied to
3 avoid signal contamination from the blood pool and epicardial fat. The pre-contrast contours were
4 then copied onto the corresponding post-contrast maps with minor adjustments made to avoid
5 partial volume effects. Regions of interest were then drawn in the blood, avoiding myocardium
6 and papillary muscles. ECV fraction was calculated according to the following formula: $ECV\% =$
7 $\text{partition coefficient} \times [1 - \text{hematocrit}]$, where $\text{partition coefficient} = [\Delta R1_{\text{myocardium}} / \Delta R1_{\text{blood-pool}}]$
8 and $\Delta R1 = (1 / \text{post-contrast } T1 - 1 / \text{native } T1)$.²⁹ Hematocrit was measured as per protocol
9 immediately before CMR study. Native myocardial T1 and ECV% were also recorded for all
10 myocardial segments, including the LV inferolateral wall, a location typically subject to abnormal
11 traction by the prolapsing leaflets.^{14, 21, 30}

12

13 **Statistical Analysis**

14 Continuous variables were expressed as mean \pm SD or median (interquartile range [IQR]), and
15 were tested for normality of distribution and homogeneity of variances with the Shapiro-Wilk and
16 Levene tests, respectively. Continuous variables with normal distribution were compared between
17 groups with Student's t test. Continuous variables non-normally distributed were compared with
18 Wilcoxon-Mann-Whitney test. Categorical variables were presented as frequencies and
19 percentages and were compared with χ^2 test or Fisher's exact test as appropriate. Univariable and
20 multivariable linear regression analyses were performed to identify the factors significantly
21 associated with diffuse myocardial fibrosis (i.e. ECV%). The multivariable model included all
22 clinically relevant factors and those with a p-value < 0.20 in univariable analysis to predict ECV%

1 (i.e. age, inverted lateral T waves, MR severity, LV end-systolic volume index, LGE, and
2 hematocrit). Results were presented as standardized beta coefficient (β) with standard error.
3 A two-tailed p value ≤ 0.05 was considered significant. Statistical analyses were performed with
4 Stata software version 14.2 (StataCorp, College Station, Texas).

5

6 **RESULTS**

7 *Study Population*

8 Demographic, arrhythmic, and CMR characteristics of the study population are presented in
9 **Table 1**. Of the 59 MVPs included in this analysis, a total of 23 (39%) cases (48% women, and
10 30% men) had ComVE. Among these, one later experienced sudden arrhythmic death, and
11 another had an aborted VF arrest treated with an implantable cardiac defibrillator (ICD). Both
12 were females.

13 PVC burden was significantly higher in the ComVE group, and by definition all cases in this
14 group had PVC burden $\geq 5\%$ (**Table 1**). PVCs were pleomorphic in all cases with PVCs burden
15 $\geq 5\%$, and originated from typical MVP sites such as the papillary muscles and MV annulus³¹
16 (**Table 1**). The proportion of T-wave inversion, including inverted inferolateral T-waves, was
17 comparable between groups (**Table 1**).

18 CMR characteristics, including MR severity (mild or less versus moderate), LV volumes,
19 presence of MAD (inferolateral: 48% vs 54%, $p=0.63$) and LGE in the LV inferolateral segment
20 (13% vs 16%, $p=1.00$) and papillary muscles (13% vs 8%, $p=0.66$), were comparable between
21 groups (**Table 1**). However, the ComVE group had lower LV ejection fraction ($59\pm 7\%$ vs
22 $62\pm 5\%$, $p=0.05$) and a trend toward more bileaflet involvement (78% vs 55%, $p=0.07$) compared
23 to the non-ComVE group.

1 *Ventricular Arrhythmia, Diffuse Interstitial Fibrosis and Sex-Based Differences*

2 Native T1 was greater in the ComVE than non-ComVE group (1284±10 vs 1247±43 ms,
3 p=0.004), while post-contrast T1 was slightly lower in the ComVE group (554±72 vs 580±57 ms,
4 p=0.13). Mean hematocrit value was similar between groups (42.5±3.1 vs 42.6±3.9 ms, p=0.94).

5 Median global ECV% was significantly greater in MVP with ComVE compared to non-
6 ComVE (31.0% [27.0-33.0] vs 27.5% [23.0-30.0], p=0.006) (**Figure 2**). Moreover, exclusion of
7 MVPs with LGE (n=19) provided similar results (31.0% [27.0-33.0] vs 27.0% [23.0-30.0],
8 p=0.01). Regardless of ComVE, women demonstrated greater ECV% compared to men (30.0%
9 [27.0-32.0] vs 27.0% [23.0-32.0]), although the comparison was not statistically significant
10 (p=0.10). Importantly, women with ComVE had significantly greater ECV% than those without
11 ComVE (31.5% [30.0-33.0] vs 28.0% [26.0-30.0], p=0.003) (**Figure 2**). In men, there was no
12 significant difference in ECV% between ComVE and non-ComVE (31.0% [25.0-33.0] vs 27.0%
13 [23.0-30.0], p=0.32) (**Figure 2**).

14 **Figure 3** shows the distribution of ECV% across the mid LV segments between ComVE
15 and non-ComVE. Median ECV% was significantly greater in ComVE versus non-ComVE across
16 all segments (all p≤0.05), except for the anteroseptal segment (**Figure 3A**). Furthermore, in
17 MVPs with ComVE, median ECV% was significantly increased in the inferolateral segment
18 compared to the other segments (all p≤0.05), with the exception of the inferior segment (**Figure**
19 **3A**). MVPs without ComVE had a different distribution of ECV%, with no increase in median
20 ECV% in the inferolateral segment compared to other myocardial segments (**Figure 3A**).
21 Similarly, women with ComVE had significantly greater ECV% across all segments compared to
22 those without ComVE (all p≤0.05), except for the anteroseptal and anterior segments (**Figure**
23 **3B**). Moreover, median ECV% in the inferolateral segment was markedly increased compared to
24 other myocardial segments in women with ComVE, but not in those without ComVE (**Figure**

1 **3B**). In the subset of men, there were no significant differences in median ECV% across all
2 myocardial segments between ComVE versus non-ComVE (**Figure 3C**). Moreover, in the
3 ComVE group, median ECV% in the inferolateral segment was significantly increased only when
4 compared to the anterolateral segment. In the non-ComVE group, median ECV% in the
5 inferolateral segment was not significantly increased compared to the other myocardial segments
6 (**Figure 3C**).

7 **Table 2** shows ECG and CMR characteristics according to ComVE and sex. Overall,
8 there were no significant differences between groups, with the exception of higher global native
9 T_1 (1302 ± 49 vs 1249 ± 50 ms, $p=0.008$) and inferolateral native T_1 (1335 ± 73 vs 1263 ± 78 ms,
10 $p=0.01$) in women with ComVE compared to those without ComVE. In men, global native T_1
11 (1255 ± 55 vs 1245 ± 39 ms, $p=0.52$) and inferolateral native T_1 (1292 ± 38 vs 1277 ± 60 ms, $p=0.48$)
12 were similar between ComVE and non-ComVE. MVPs with ComVE were more likely to have
13 bileaflet involvement and lower LVEF in both women and men (**Table 2**). The proportion of
14 MVPs with MAD and/or LGE did not differ between groups among women and men (**Table 2**).

15 *Predictors of Complex Ventricular Ectopy*

16 In an exploratory analysis, we assessed the association of ECV% with the risk of ComVE after
17 adjusting for the Charlson comorbidities index, presence of LGE, bileaflet MVP, inferolateral
18 MAD, and LVEF. In univariable analysis, ComVE risk was only predicted by ECV% (OR: 1.18,
19 95% CI 1.04 - 1.35; $p=0.01$). Of note, when stratified based on sex, ECV% was significantly
20 associated with the risk of ComVE in women (OR: 1.44, 95% CI 1.07 - 1.94; $p=0.01$), but not in
21 men (OR: 1.08, 95% CI 0.93 - 1.26; $p=0.31$). After multiple multivariable models, ECV%
22 remained independently associated with an increased risk of ComVE in all multivariable models
23 (**Figure 4**).

1

2 **DISCUSSION**

3 In this cross-sectional analysis of consecutive and unselected MVPs with predominantly no or
4 mild MR undergoing CMR, we investigated the relationship of interstitial myocardial fibrosis
5 with ComVE, including cases with VT, VF arrest and SCD. The main findings were as follows:

6 **1)** Diffuse interstitial fibrosis as quantified by global ECV%/T₁ mapping was significantly greater
7 in MVPs with ComVE, regardless of presence of LGE; **2)** In the arrhythmic MVP group, higher
8 segmental ECV% was not limited to the inferolateral/inferior LV wall, but was also demonstrated
9 in segments not typically subject to myocardial traction, suggesting a diffuse myopathic process
10 in MVP beyond abnormal valvular-myocardial mechanics; **3)** The association between interstitial
11 fibrosis and ComVE was more prominent in women compared to men with MVP (**Graphical**
12 **Abstract**).

13

14 *Myocardial Fibrosis and Arrhythmic MVP*

15 Seminal studies support the role of myocardial fibrosis, resulting from increased mechanical
16 traction of prolapsing valve, as a substrate for ComVE and SCD in MVP.^{5, 8, 9, 11} Basso et al.⁹
17 previously reported that replacement fibrosis is a common feature of young SCD victims (≤40
18 years of age) with arrhythmic MVP. However, replacement fibrosis is not consistently found in
19 SCD victims with MVP,¹⁰ nor in those with ComVE alone (prevalence of LGE 36-45%).^{20, 32}
20 These findings suggest that other myocardial substrates are contributing to arrhythmic outcomes
21 in MVP.

22 Non-invasive measurement of diffuse interstitial fibrosis can be achieved by measuring
23 ECV% by T₁ mapping on CMR, a technique that has been validated against histology.^{33, 34} Prior
24 studies have reported abnormal myocardial T₁ and ECV%, suggestive of greater diffuse

1 interstitial fibrosis in arrhythmic MVP.^{21, 28, 35} However, such investigations have included
2 predominantly MVP cases with severe MR or MAD, or have linked abnormal ECV% to a few
3 cases of sudden cardiac arrest rather than the wider spectrum of ComVE.^{20, 21} ComVE is
4 frequently detected (>80%) in patients with MVP before lethal events and has been linked to
5 mortality excess.^{5, 6} Therefore, the identification of imaging parameters able to predict ComVE
6 are essential for detection of intermediate categories of risk and overall improved arrhythmic risk
7 stratification. Selection of specific categories of MVP in prior studies (severe MR or MVP with
8 MAD and abnormal valve-myocardial mechanics) have limited our understanding of the
9 distribution and pattern of interstitial fibrosis in MVP beyond a simple response to chronic
10 volume load or a focal fibrotic response to myocardial traction. Another study has assessed
11 ECV% in mild or moderate MR, but only in 12 MVP patients and without investigating
12 segmental contributions to global ECV%.³⁶ In the present study, we demonstrate for the first time
13 in a larger sample of CMR studies unselected for severe MR or MAD, that ComVE in MVP is
14 strongly linked to greater ECV%, even in the subset without LGE or abnormal valvular-
15 myocardial mechanics. Our imaging findings are in line with our prior post-mortem data
16 demonstrating that multisite interstitial fibrosis was more prevalent than replacement fibrosis
17 (100% vs 30%) on autopsy in consecutive and unselected MVPs with sudden arrhythmic death
18 adjudication.¹⁰ Therefore, diffuse interstitial fibrosis may represent an alternative substrate for
19 ComVE and SCD in MVP with mild MR, even in the absence of LGE. As such, MVP patients
20 undergoing CMR for assessment of more traditional parameters of risk such as MAD or LGE,
21 may greatly benefit from routine T₁ mapping/ECV% calculation as part of their clinical care.
22 To date, the exact mechanisms for ventricular arrhythmia and SCD in MVP without severe MR
23 are not well understood. It has been hypothesized that the arrhythmogenic risk associated with
24 bileaflet MVP with mild MR could be attributed to stretching forces exerted on the papillary

1 muscles and adjacent LV wall by the prolapsing leaflets.^{11, 12} These mechanical stresses could
2 trigger myocardial inflammation and contribute to fibrosis as a substrate for ventricular
3 arrhythmia.³⁶ Moreover, MAD, which is more common in bileaflet MVP,³⁷ can augment such
4 abnormal valve-myocardial mechanics. In the present study, we confirmed the regionalized
5 expansion of myocardial fibrosis in arrhythmic MVP. Among MVP ComVE, the inferolateral
6 segment had the highest ECV% within the LV mid-section. Further, the absolute ECV% in the
7 LV inferolateral segment was significantly greater in MVP with ComVE compared to non-
8 ComVE. However, among MVP patients with mild MR, we also highlight a global, multi-
9 segment pattern of interstitial fibrosis which may underline a diffuse myopathic process initially
10 proposed in genetic studies highlighting mutations in cardiomyopathy genes (*FLNC*, *LMNA*,
11 *ALPK3A*).^{38, 39} A primary myopathy may represent the “substrate” for ventricular arrhythmia in
12 the presence of bileaflet MVP, MAD and myocardial stretch (the “trigger”). Alternatively, such
13 diffuse myopathy may act alone, when bileaflet MVP and associated imaging arrhythmic features
14 are absent. Indeed, in our study sample only 50% of MVP patients with mild MR had the
15 traditional phenotype of bileaflet MVP with MAD and curling. Longitudinal studies are needed to
16 determine the prognostic role of CMR-based diffuse interstitial myocardial fibrosis in arrhythmic
17 MVP either as an imaging surrogate of a primary myopathy or, when regionalized to the
18 inferolateral LV, as a precursor of replacement fibrosis.

19

20 *Sex Differences, Expansion of Myocardial Fibrosis, and Risk of Arrhythmias*

21 There are conflicting findings regarding the potential effect of sex on MVP arrhythmogenicity.
22 Prior reports of MVP-related SCD/SCA cases have showed a predominance of young women.^{5, 9}

23 In our study, there was a predominance of women with ComVE (60%), which is
24 consistent with prior observations.⁴⁰ Importantly, we observed a stronger association between

1 global ECV% and ComVE in women compared to men. In addition, women with MVP and
2 ComVE had significantly greater ECV% in the LV inferolateral segment but also in other
3 segments typically not subject to myocardial traction. Of note, both women and men had similar
4 distributions of replacement fibrosis as quantified by LGE. To our knowledge, this is the first
5 study to investigate and report sex-related differences in the expansion of myocardial fibrosis as
6 measured by CMR in MVP.

7 Several factors may contribute to sex-specific mechanisms of interstitial fibrosis in
8 arrhythmic MVP including neurohormonal differences, cardiac structural and functional
9 variations, and genetic predisposition.^{41, 42} Sex hormones, particularly estrogen, are well-known
10 for their impact on the myocardium.⁴³ In this setting, hormonal fluctuations may contribute to
11 ventricular fibrosis and arrhythmias.^{41, 44} Greater global/diffuse interstitial fibrosis in women with
12 MVP, mild MR, and ComVE may suggest a primary/genetic diffuse myopathy with variable, sex-
13 related penetrance similar to that observed for valvular features, i.e. bileaflet MVP and MAD,
14 which are more prevalent in women.⁴⁵ Indeed, in addition to greater global ECV%, women with
15 arrhythmic MVP in our study exhibited greater “regionalized” interstitial fibrosis, specifically
16 higher ECV% in the mid inferolateral LV, which was not observed in men. Altogether, these
17 findings support the role of sex-specific factors in the development of myocardial fibrosis and
18 subsequent risk of ventricular arrhythmia in MVP. However, further studies are needed to
19 provide a clearer understanding of the effect of sex in arrhythmic MVP.

20

21 *Clinical Implications*

22 The identification of those at highest risk for ventricular arrhythmia and SCD within the larger
23 population of benign MVP cases remains a major and unmet challenge.¹ Current guidelines focus
24 on management of significant MR, with less emphasis on routine monitoring of ComVE in MVP

1 without MR.^{46, 47} In the absence of LGE, arrhythmic risk stratification in MVP is even less clear
2 to the practicing cardiologist. In our study, we demonstrate greater interstitial fibrosis in
3 arrhythmic MVP, regardless of MR or LGE, and more so in women. Hence, ECV% quantified by
4 T₁ mapping represents an alternative surrogate marker for myocardial fibrosis that is expected to
5 improve risk stratification of “malignant” MVP. Individuals with MVP and abnormal ECV%,
6 particularly women without significant MR and/or LGE, may benefit from closer clinical and
7 imaging monitoring. Furthermore, our findings support the need for better understanding of the
8 underlying sex-specific mechanisms involved in the pathogenesis of arrhythmic MVP.

9

10 *Limitations*

11 The retrospective design and small sample size of the present study require additional studies to
12 confirm our findings. Nonetheless, this study is the first to our knowledge to characterize the
13 association between interstitial fibrosis and ComVE, in a large series of MVPs undergoing CMR
14 studies unselected for severe MR or ventricular arrhythmia. Importantly, our findings suggest for
15 the first-time sex differences in patterns of fibrosis in MVP which may explain the higher
16 prevalence of arrhythmic complications in women. Our findings need to be validated in further
17 experimental and longitudinal observational studies.

18

19 **CONCLUSION**

20 In the first large series of consecutive MVP patients with mild MR, ComVE is associated with
21 greater interstitial fibrosis as quantified by ECV% using CMR/T1 mapping, even in the absence
22 of LGE. Measurement of ECV% could help enhance arrhythmic risk stratification particularly in
23 female arrhythmic MVP patients, who exhibit greater interstitial fibrosis compared to men.

- 1 Further studies are needed to determine if sex-specific mechanisms are involved in the
- 2 pathogenesis of arrhythmic MVP.

- 1 **Sources of Funding:** This work was supported by the National Institute of Health NHLBI
- 2 R01HL153447.
- 3 **Disclosures:** Nothing to disclose.

1

REFERENCES

- 2 1. Delling FN, Noseworthy PA, Adams DH, Basso C, Borger M, Bouatia-Naji N, et al.
3 Research opportunities in the treatment of mitral valve prolapse: Jacc expert panel. *J Am*
4 *Coll Cardiol.* 2022;80:2331-2347
- 5 2. Narayanan K, Uy-Evanado A, Teodorescu C, Reinier K, Nichols GA, Gunson K, et al.
6 Mitral valve prolapse and sudden cardiac arrest in the community. *Heart Rhythm.*
7 2016;13:498-503
- 8 3. Nalliah CJ, Mahajan R, Elliott AD, Haqqani H, Lau DH, Vohra JK, et al. Mitral valve
9 prolapse and sudden cardiac death: A systematic review and meta-analysis. *Heart (British*
10 *Cardiac Society).* 2019;105:144-151
- 11 4. Corrado D, Basso C, Nava A, Rossi L, Thiene G. Sudden death in young people with
12 apparently isolated mitral valve prolapse [comment] [see comments]. *G Ital Cardiol.*
13 1997;27:1097-1105
- 14 5. Sriram CS, Syed FF, Ferguson ME, Johnson JN, Enriquez-Sarano M, Cetta F, et al.
15 Malignant bileaflet mitral valve prolapse syndrome in patients with otherwise idiopathic
16 out-of-hospital cardiac arrest. *J Am Coll Cardiol.* 2013;62:222-230
- 17 6. Essayagh B, Sabbag A, Antoine C, Benfari G, Yang LT, Maalouf J, et al. Presentation and
18 outcome of arrhythmic mitral valve prolapse. *J Am Coll Cardiol.* 2020;76:637-649
- 19 7. Sabbag A, Essayagh B, Barrera JDR, Basso C, Berni A, Cosyns B, et al. Ehra expert
20 consensus statement on arrhythmic mitral valve prolapse and mitral annular disjunction
21 complex in collaboration with the esc council on valvular heart disease and the european
22 association of cardiovascular imaging endorsed cby the heart rhythm society, by the asia
23 pacific heart rhythm society, and by the latin american heart rhythm society. *Europace.*
24 2022;24:1981-2003
- 25 8. Han Y, Peters DC, Salton CJ, Bzymek D, Nezafat R, Goddu B, et al. Cardiovascular
26 magnetic resonance characterization of mitral valve prolapse. *JACC. Cardiovascular*
27 *imaging.* 2008;1:294-303
- 28 9. Basso C, Perazzolo MM, Rizzo S, De Lazzari M, Giorgi B, Cipriani A, et al. Arrhythmic
29 mitral valve prolapse and sudden cardiac death. *Circulation.* 2015;132:556-566
- 30 10. Delling FN, Aung S, Vittinghoff E, Dave S, Lim LJ, Olgin JE, et al. Antemortem and
31 post-mortem characteristics of lethal mitral valve prolapse among all countywide
32 sudden deaths. *JACC Clin Electrophysiol.* 2021;7:1025-1034
- 33 11. Morningstar JE, Gensemer C, Moore R, Fulmer D, Beck TC, Wang C, et al. Mitral valve
34 prolapse induces regionalized myocardial fibrosis. *J Am Heart Assoc.* 2021;10:e022332
- 35 12. Nagata Y, Bertrand PB, Baliyan V, Kochav J, Kagan RD, Ujka K, et al. Abnormal
36 mechanics relate to myocardial fibrosis and ventricular arrhythmias in patients with mitral
37 valve prolapse. *Circulation. Cardiovascular imaging.* 2023;16:e014963
- 38 13. Han Y, Peters DC, Kissinger KV, Goddu B, Yeon SB, Manning WJ, et al. Evaluation of
39 papillary muscle function using cardiovascular magnetic resonance imaging in mitral
40 valve prolapse. *Am J Cardiol.* 2010;106:243-248
- 41 14. Perazzolo Marra M, Basso C, De Lazzari M, Rizzo S, Cipriani A, Giorgi B, et al.
42 Morphofunctional abnormalities of mitral annulus and arrhythmic mitral valve prolapse.
43 *Circulation. Cardiovascular imaging.* 2016;9:e005030
- 44 15. Kitkungvan D, Nabi F, Kim RJ, Bonow RO, Khan MA, Xu J, et al. Myocardial fibrosis in
45 patients with primary mitral regurgitation with and without prolapse. *J Am Coll Cardiol.*
46 2018;72:823-834

- 1 16. Tison GH, Abreau S, Barrios J, Lim LJ, Yang M, Crudo V, et al. Identifying mitral valve
2 prolapse at risk for arrhythmias and fibrosis from electrocardiograms using deep learning.
3 *JACC: Advances*. 2023;2:100446
- 4 17. Taylor AJ, Salerno M, Dharmakumar R, Jerosch-Herold M. T1 mapping: Basic
5 techniques and clinical applications. *JACC. Cardiovascular imaging*. 2016;9:67-81
- 6 18. Everett RJ, Treibel TA, Fukui M, Lee H, Rigolli M, Singh A, et al. Extracellular
7 myocardial volume in patients with aortic stenosis. *J Am Coll Cardiol*. 2020;75:304-316
- 8 19. Tseng ZH, Olgin JE, Vittinghoff E, Ursell PC, Kim AS, Sporer K, et al. Prospective
9 countywide surveillance and autopsy characterization of sudden cardiac death: Post scd
10 study. *Circulation*. 2018;137:2689-2700
- 11 20. Bui AH, Roujol S, Foppa M, Kissinger KV, Goddu B, Hauser TH, et al. Diffuse
12 myocardial fibrosis in patients with mitral valve prolapse and ventricular arrhythmia.
13 *Heart (British Cardiac Society)*. 2017;103:204-209
- 14 21. Pavon AG, Arangalage D, Pascale P, Hugelshofer S, Rutz T, Porretta AP, et al.
15 Myocardial extracellular volume by t1 mapping: A new marker of arrhythmia in mitral
16 valve prolapse. *J Cardiovasc Magn Reson*. 2021;23:102
- 17 22. DesJardin JT, Chikwe J, Hahn RT, Hung JW, Delling FN. Sex differences and similarities
18 in valvular heart disease. *Circ Res*. 2022;130:455-473
- 19 23. Charlson M, Pompei P, Ales K, MacKenzie C. A new method of classifying prognostic
20 comorbidity in longitudinal studies: Development and validation. *J Chronic Dis*.
21 1987;40:373-383
- 22 24. Marano PJ, Lim LJ, Sanchez JM, Alvi R, Nah G, Badhwar N, et al. Long-term outcomes
23 of ablation for ventricular arrhythmias in mitral valve prolapse. *J Interv Card
24 Electrophysiol*. 2021;61:145-154
- 25 25. Biglands JD, Radjenovic A, Ridgway JP. Cardiovascular magnetic resonance physics for
26 clinicians: Part ii. *J Cardiovasc Magn Reson*. 2012;14:66
- 27 26. Schulz-Menger J, Bluemke DA, Bremerich J, Flamm SD, Fogel MA, Friedrich MG, et al.
28 Standardized image interpretation and post processing in cardiovascular magnetic
29 resonance: Society for cardiovascular magnetic resonance (scmr) board of trustees task
30 force on standardized post processing. *J Cardiovasc Magn Reson*. 2013;15:35
- 31 27. Dejgaard LA, Skjølsvik ET, Lie ØH, Ribe M, Stokke MK, Hegbom F, et al. The mitral
32 annulus disjunction arrhythmic syndrome. *J Am Coll Cardiol*. 2018;72:1600-1609
- 33 28. Kitkungvan D, Yang EY, El Tallawi KC, Nagueh SF, Nabi F, Khan MA, et al.
34 Extracellular volume in primary mitral regurgitation. *JACC. Cardiovascular imaging*.
35 2021;14:1146-1160
- 36 29. Messroghli DR, Moon JC, Ferreira VM, Grosse-Wortmann L, He T, Kellman P, et al.
37 Clinical recommendations for cardiovascular magnetic resonance mapping of t1, t2, t2*
38 and extracellular volume: A consensus statement by the society for cardiovascular
39 magnetic resonance (scmr) endorsed by the european association for cardiovascular
40 imaging (eacvi). *J Cardiovasc Magn Reson*. 2017;19:75
- 41 30. Basso C, Iliceto S, Thiene G, Perazzolo Marra M. Mitral valve prolapse, ventricular
42 arrhythmias, and sudden death. *Circulation*. 2019;140:952-964
- 43 31. Hourdain J, Clavel MA, Deharo J-C, Asirvatham S, Avierinos JF, Habib G, et al.
44 Common phenotype in patients with mitral valve prolapse who experienced sudden
45 cardiac death. *Circulation*. 2018;138:1067-1069
- 46 32. Constant D, Beaufils AL, Huttin O, Jobbe-Duval A, Senage T, Filippetti L, Piriou N, et
47 al. Replacement myocardial fibrosis in patients with mitral valve prolapse: Relation to

- 1 mitral regurgitation, ventricular remodeling, and arrhythmia. *Circulation*. 2021;143:1763-
2 1774
- 3 33. Flett AS, Hayward MP, Ashworth MT, Hansen MS, Taylor AM, Elliott PM, et al.
4 Equilibrium contrast cardiovascular magnetic resonance for the measurement of diffuse
5 myocardial fibrosis: Preliminary validation in humans. *Circulation*. 2010;122:138-144
- 6 34. Miller CA, Naish JH, Bishop P, Coutts G, Clark D, Zhao S, et al. Comprehensive
7 validation of cardiovascular magnetic resonance techniques for the assessment of
8 myocardial extracellular volume. *Circulation. Cardiovascular imaging*. 2013;6:373-383
- 9 35. Guglielmo M, Fusini L, Muscogiuri G, Baessato F, Loffreno A, Cavaliere A, et al. T1
10 mapping and cardiac magnetic resonance feature tracking in mitral valve prolapse. *Eur*
11 *Radiol*. 2021;31:1100-1109
- 12 36. Miller MA, Devesa A, Robson PM, Liao SL, Pyzik R, El-Eshmawi A, et al. Arrhythmic
13 mitral valve prolapse with only mild or moderate mitral regurgitation: Characterization of
14 myocardial substrate. *JACC Clin Electrophysiol*. 2023;9:1709-1716
- 15 37. Essayagh B, Sabbag A, Antoine C, Benfari G, Batista R, Yang LT, et al. The mitral
16 annular disjunction of mitral valve prolapse: Presentation and outcome. *JACC.*
17 *Cardiovascular imaging*. 2021;14:2073-2087
- 18 38. Bains S, Tester DJ, Asirvatham SJ, Noseworthy PA, Ackerman MJ, Giudicessi JR. A
19 novel truncating variant in flnc-encoded filamin c may serve as a proarrhythmic genetic
20 substrate for arrhythmogenic bileaflet mitral valve prolapse syndrome. *Mayo Clin Proc*.
21 2019;94:906-913
- 22 39. Roselli C, Yu M, Nauffal V, Georges A, Yang Q, Love K, et al. Genome-wide association
23 study reveals novel genetic loci: A new polygenic risk score for mitral valve prolapse.
24 *European heart journal*. 2022;43:1668-1680
- 25 40. Zuppiroli A, Mori F, Favilli S, Barchielli A, Corti G, Monterecci A, et al. Arrhythmias in
26 mitral valve prolapse: Relation to anterior mitral leaflet thickening, clinical variables, and
27 color doppler echocardiographic parameters. *Am Heart J*. 1994;128:919-927
- 28 41. Zeitler EP, Poole JE, Albert CM, Al-Khatib SM, Ali-Ahmed F, Birgersdotter-Green U, et
29 al. Arrhythmias in female patients: Incidence, presentation and management. *Circ Res*.
30 2022;130:474-495
- 31 42. Tastet L, Kwiecinski J, Pibarot P, Capoulade R, Everett RJ, Newby DE, et al. Sex-related
32 differences in the extent of myocardial fibrosis in patients with aortic valve stenosis.
33 *JACC. Cardiovascular imaging*. 2020;13:699-711
- 34 43. Pedram A, Razandi M, Narayanan R, Levin ER. Estrogen receptor beta signals to
35 inhibition of cardiac fibrosis. *Mol Cell Endocrinol*. 2016;434:57-68
- 36 44. Bao AM, Liu RY, van Someren EJ, Hofman MA, Cao YX, Zhou JN. Diurnal rhythm of
37 free estradiol during the menstrual cycle. *Eur J Endocrinol*. 2003;148:227-232
- 38 45. Groeneveld SA, Kirkels FP, Cramer MJ, Evertz R, Haugaa KH, Postema PG, et al.
39 Prevalence of mitral annulus disjunction and mitral valve prolapse in patients with
40 idiopathic ventricular fibrillation. *J Am Heart Assoc*. 2022;11:e025364
- 41 46. Otto CM, Nishimura RA, Bonow RO, Carabello BA, Erwin JP, 3rd, Gentile F, et al. 2020
42 acc/aha guideline for the management of patients with valvular heart disease: Executive
43 summary: A report of the american college of cardiology/american heart association joint
44 committee on clinical practice guidelines. *J Am Coll Cardiol*. 2021;77:450-500
- 45 47. Vahanian A, Beyersdorf F, Praz F, Milojevic M, Baldus S, Bauersachs J, et al. 2021
46 esc/eacts guidelines for the management of valvular heart disease. *European heart*
47 *journal*. 2022;43:561-632

1

2

1
2
3
4
5
6
7
8
9
10
11
12
13
14
15
16
17
18
19
20
21
22
23

FIGURE LEGEND

FIGURE 1: Study Flow Chart.

CMR = cardiac magnetic resonance; ComVE = complex ventricular ectopy; ECV = extracellular volume; ECV% = ECV fraction; HCT = hematocrit; MR = mitral regurgitation; MVP = mitral valve prolapse; UCSF = University of California San Francisco.

FIGURE 2: Distribution of Extracellular Volume Fraction According to Complex Ventricular Ectopy.

Caption: Comparison of ECV% according to ComVE in the whole cohort, subset of women, and men. The violin plot shows the median value (white square), the interquartile range (IQR), the error bars, and the kernel density plot. The numbers on top of the dot plot indicate the median with IQR between brackets. The numbers between brackets below the graph indicate the number of patients for each subgroup.

Abbreviation as in **Figure 1**.

FIGURE 3: Distribution of Extracellular Volume Fraction in Myocardial Segments According to Complex Ventricular Ectopy.

Caption: Comparison of ECV% in the mid LV myocardial segments according to ComVE in the whole cohort (**A**), subset of women (**B**), and men (**C**).

A = anterior; AL = anterolateral; AS = anteroseptal; I = inferior; IL = inferolateral; IS = inferoseptal; other abbreviation as in **Figure 1**.

FIGURE 4: Factors Associated with Risk of Complex Ventricular Ectopy.

1 **Caption:** ECV% remained associated with increased risk of ComVE in multiple multivariable
2 models including several risk factors.
3 CI = confidence interval; LGE = late gadolinium enhancement; LVEF = left ventricular ejection
4 fraction; MAD = mitral annular disjunction; MV = multivariable; OR = odd ratio; other
5 abbreviation as in **Figure 1**.
6
7 **GRAPHICAL ABSTRACT:** Expansion of Interstitial Myocardial Fibrosis in Mitral Valve
8 Prolapse with Complex Ventricular Ectopy.
9 **Caption:** Illustrative MVP case with ComVE and greater interstitial fibrosis as demonstrated by
10 T₁ mapping on CMR (**Top**). The violin plot shows significantly greater ECV% in MVPs with
11 ComVE compared to non-ComVE (**Top**). The association between greater interstitial fibrosis (i.e.
12 ECV%) and ComVE was stronger in women than men (**Bottom**).
13 MR = mitral regurgitation

TABLE 1: Characteristics of the Study Population

	All Patients (N = 59)	MVP ComVE (n = 23; 39%)	MVP Non-ComVE (n = 36; 61%)	p Value
<i>Demographic data</i>				
Age, years	54 ± 15	57 ± 16	53 ± 14	0.29
Female sex, n (%)	29 (49)	14 (60)	15 (41)	0.15
Body surface area, m ²	1.82 ± 0.19	1.82 ± 0.20	1.82 ± 0.18	0.94
Symptoms, n (%)	16 (27)	8 (35)	8 (22)	0.29
Dyspnea, n (%)	2 (3)	2 (8)	0 (0)	0.14
Chest pain, n (%)	3 (5)	2 (8)	1 (2)	0.31
Palpitations, n (%)	9 (15)	3 (13)	6 (16)	1.00
Syncope, n (%)	4 (6)	2 (8)	2 (5)	0.63
Cardiac arrest/SCD, n (%)	1 (1)	1 (4)	0 (0)	-
Family history of SCD, n (%)	9 (15)	5 (22)	4 (11)	0.28
<i>ECG/Holter data</i>				
Pleomorphic ventricular ectopy, n (%)	33 (58)	15 (71)	18 (51)	0.14
Non-sustained VT, n (%)	19 (34)	19 (90)	0 (0)	-
PVCs burden, (%)	1.6 ± 3.6	3.4 ± 5.1	0.3 ± 0.5	0.001
PVCs burden ≥5%, n (%)	5 (12)	5 (33)	0 (0)	-
PVCs by origin				0.02
Posterior papillary muscles, n (%)	11 (25)	7 (47)	4 (13)	
Anterior papillary muscles, n (%)	8 (18)	2 (13)	6 (21)	
Anterior/posterior MV, n (%)	2 (5)	2 (13)	0 (0)	
LV/RV outflow tract, n (%)	7 (16)	1 (7)	6 (21)	
Other, n (%)	16 (36)	3 (20)	13 (45)	
Inverted T waves, n (%)	20 (35)	9 (39)	11 (33)	0.65
Inverted inferolateral T waves, n (%)	3 (5)	1 (4)	2 (6)	1.00
Inverted inferior T waves, n (%)	23 (40)	11 (47)	12 (35)	0.34
Inverted lateral T waves, n (%)	1 (2)	0 (0)	1 (3)	1.00
<i>CMR data</i>				
MVP subtype				0.24

Bileaflet, n (%)	38 (64)	18 (78)	20 (55)	
Anterior, n (%)	8 (13)	2 (8)	6 (16)	
Posterior, n (%)	13 (22)	3 (13)	10 (27)	
No or mild MR, n (%)	47 (80)	19 (83)	28 (78)	0.75
Mitral annular disjunction				
Any site, n (%)	39 (66)	16 (70)	23 (64)	0.65
Inferolateral, n (%)	30 (51)	11 (48)	19 (54)	0.63
LV end-diastolic volume index, ml/m ²	83 ± 18	82 ± 16	83 ± 20	0.80
LV end-systolic volume index, ml/m ²	32 ± 10	33 ± 10	31 ± 10	0.47
LV ejection fraction, %	61 ± 6	59 ± 7	62 ± 5	0.05
LV mass index, g/m ²	45 ± 14	48 ± 10	44 ± 16	0.31
LV systolic curling, n (%)	36 (66)	16 (76)	20 (60)	0.23
LV systolic curling, mm	3.8 ± 1.7	4.0 ± 2.0	3.5 ± 1.5	0.40
LGE present, n (%)	19 (30)	8 (35)	11 (30)	0.73
Inferolateral LV wall, n (%)	9 (15)	3 (13)	6 (16)	1.00
Papillary muscles, n (%)	6 (10)	3 (13)	3 (8)	0.66
T ₁ mapping mid LV				
Native T ₁ , ms	1261 ± 49	1284 ± 10	1247 ± 43	0.004
Post contrast T ₁ , ms	570 ± 64	554 ± 72	580 ± 57	0.13
Hematocrit, %	42.5 ± 3.6	42.5 ± 3.1	42.6 ± 3.9	0.94
Extracellular volume fraction, %				
Mean, %	28.4 ± 4.8	30.3 ± 4.7	27.2 ± 4.6	0.01
Median, %	29.0 (24.0 - 32.0)	31.0 (27.0 - 33.0)	27.5 (23.0 - 30.0)	0.006
Maximum ECV inferolateral, n (%)	33 (56)	16 (69)	17 (48)	0.11

Values are mean ± SD or median (25th – 75th percentiles).

CMR = cardiac magnetic resonance; ECG = electrocardiogram; ECV = extracellular volume; LGE = late gadolinium enhancement; LV = left ventricular; MR = mitral regurgitation; MV = mitral valve; MVP = mitral valve prolapse; PVC = premature ventricular contraction; VT = ventricular tachycardia; SCD = sudden cardiac death.

TABLE 2: ECG and CMR Characteristics According to Sex and Arrhythmia.

	Women			Men		
	MVP ComVE (n = 14; 48%)	MVP Non-ComVE (n = 15; 52%)	p Value	MVP ComVE (n = 9; 30%)	MVP Non-ComVE (n = 21; 70%)	p Value
<i>ECG/Holter data</i>						
Pleomorphic ventricular ectopy, n (%)	7 (54)	7 (50)	0.84	8 (89)	11 (52)	0.01
Non-sustained VT, n (%)	12 (92)	0 (0)	-	7 (87)	0 (0)	-
PVCs burden, (%)	2.7 ± 4.5	0.2 ± 0.3	0.10	4.5 ± 6.1	0.3 ± 0.5	0.004
PVCs burden ≥5%, n (%)	2 (29)	0 (0)	-	3 (38)	0 (0)	-
PVCs by origin			0.73			0.07
Posterior papillary muscles, n (%)	3 (43)	2 (20)		4 (50)	2 (10)	
Anterior papillary muscles, n (%)	1 (14)	2 (20)		1 (12)	4 (21)	
Anterior/posterior MV, n (%)	1 (14)	0 (0)		1 (12)	0 (0)	
LV/RV outflow tract, n (%)	0 (0)	1 (10)		1 (13)	5 (26)	
Other, n (%)	2 (29)	5 (50)		1 (13)	8 (42)	
Inverted T waves, n (%)	6 (42)	5 (35)	0.69	3 (33)	6 (31)	0.92
Inverted inferolateral T waves, n (%)	1 (7)	1 (7)	1.00	0 (0)	1 (5)	0.48
Inverted inferior T waves, n (%)	7 (50)	6 (42)	0.70	4 (44)	6 (30)	0.67
Inverted lateral T waves, n (%)	0 (0)	0 (0)	-	1 (5)	0 (0)	0.48
<i>CMR data</i>						
MVP subtype			0.28			0.56
Bileaflet, n (%)	10 (71)	6 (40)		8 (88)	14 (66)	

Anterior, n (%)	2 (14)	4 (26)		1 (11)	6 (28)	
Posterior, n (%)	2 (14)	5 (33)		0 (0)	1 (4)	
No or mild MR, n (%)	12 (86)	13 (87)	1.00	7 (78)	15 (71)	1.00
Mitral annular disjunction						
Any site, n (%)	9 (64)	11 (73)	0.70	7 (77)	12 (57)	0.42
Inferolateral, n (%)	7 (50)	8 (57)	0.70	4 (44)	11 (52)	0.69
LV end-diastolic volume index, ml/m ²	78 ± 13	79 ± 18	0.90	86 ± 19	85 ± 20	0.90
LV end-systolic volume index, ml/m ²	30 ± 6	28 ± 8	0.41	36 ± 12	33 ± 10	0.43
LV ejection fraction, %	60 ± 6	64 ± 4	0.08	57 ± 9	61 ± 6	0.14
LV mass index, g/m ²	44 ± 8	40 ± 11	0.25	53 ± 11	46 ± 18	0.34
LV systolic curling, n (%)	11 (84)	8 (57)	0.20	5 (62)	12 (63)	1.00
LV systolic curling, mm	4.3 ± 2.2	3.4 ± 1.5	0.35	3.5 ± 1.6	3.6 ± 1.6	0.89
LGE present, n (%)	3 (21)	4 (26)	1.00	5 (55)	7 (33)	0.41
Inferolateral LV wall, n (%)	1 (7)	2 (13)	1.00	2 (22)	4 (19)	1.00
Papillary muscles, n (%)	1 (7)	2 (13)	1.00	2 (22)	1 (4)	0.20
T ₁ mapping mid LV						
Native T ₁ , ms	1302 ± 49	1249 ± 50	0.008	1255 ± 35	1245 ± 39	0.52
Post contrast T ₁ , ms	549 ± 84	571 ± 67	0.43	562 ± 53	586 ± 50	0.24
Inferolateral native T ₁ , ms	1335 ± 73	1263 ± 78	0.01	1292 ± 38	1277 ± 60	0.48
Hematocrit, %	42.0 ± 3.5	41.0 ± 2.7	0.39	43.2 ± 2.3	43.7 ± 4.2	0.77

Values are mean ± SD or median (25th – 75th percentiles).

Abbreviations as in **Table 1**.

FIGURE 1

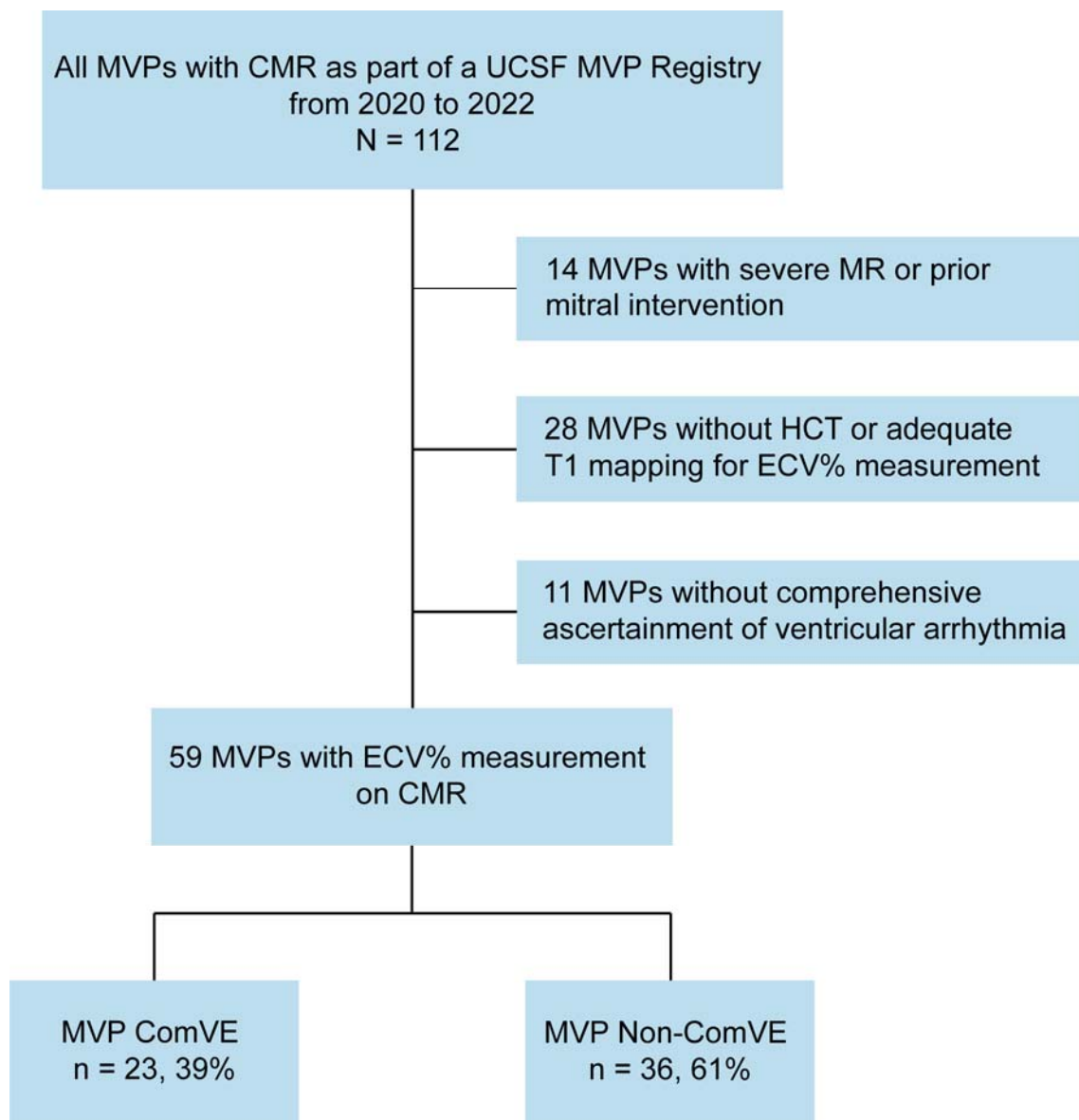


FIGURE 2

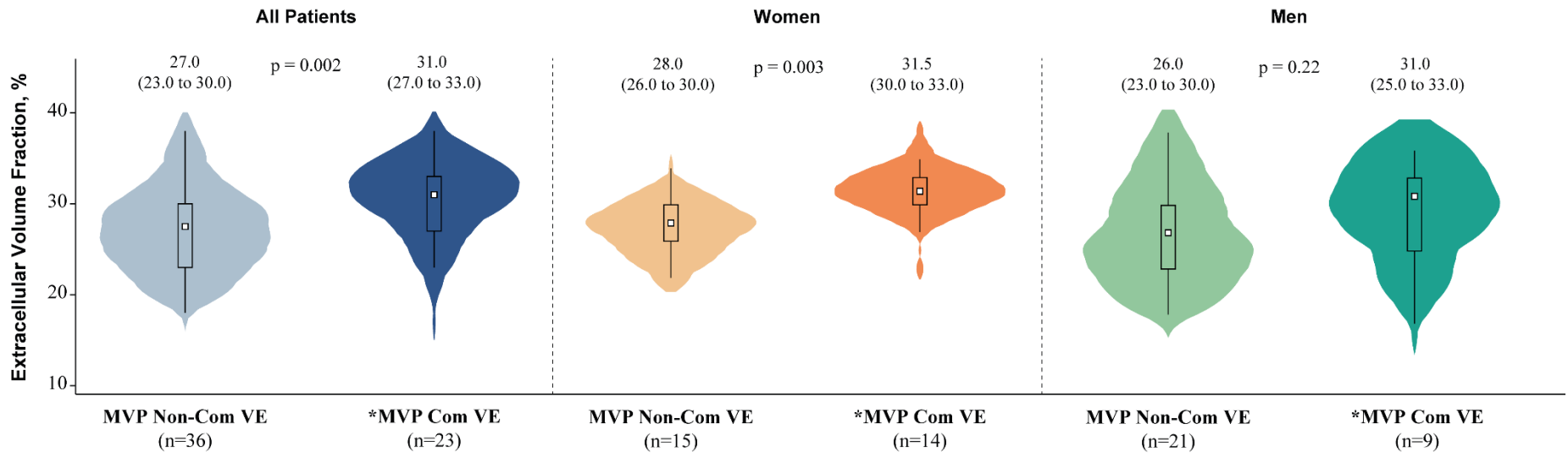


FIGURE 3

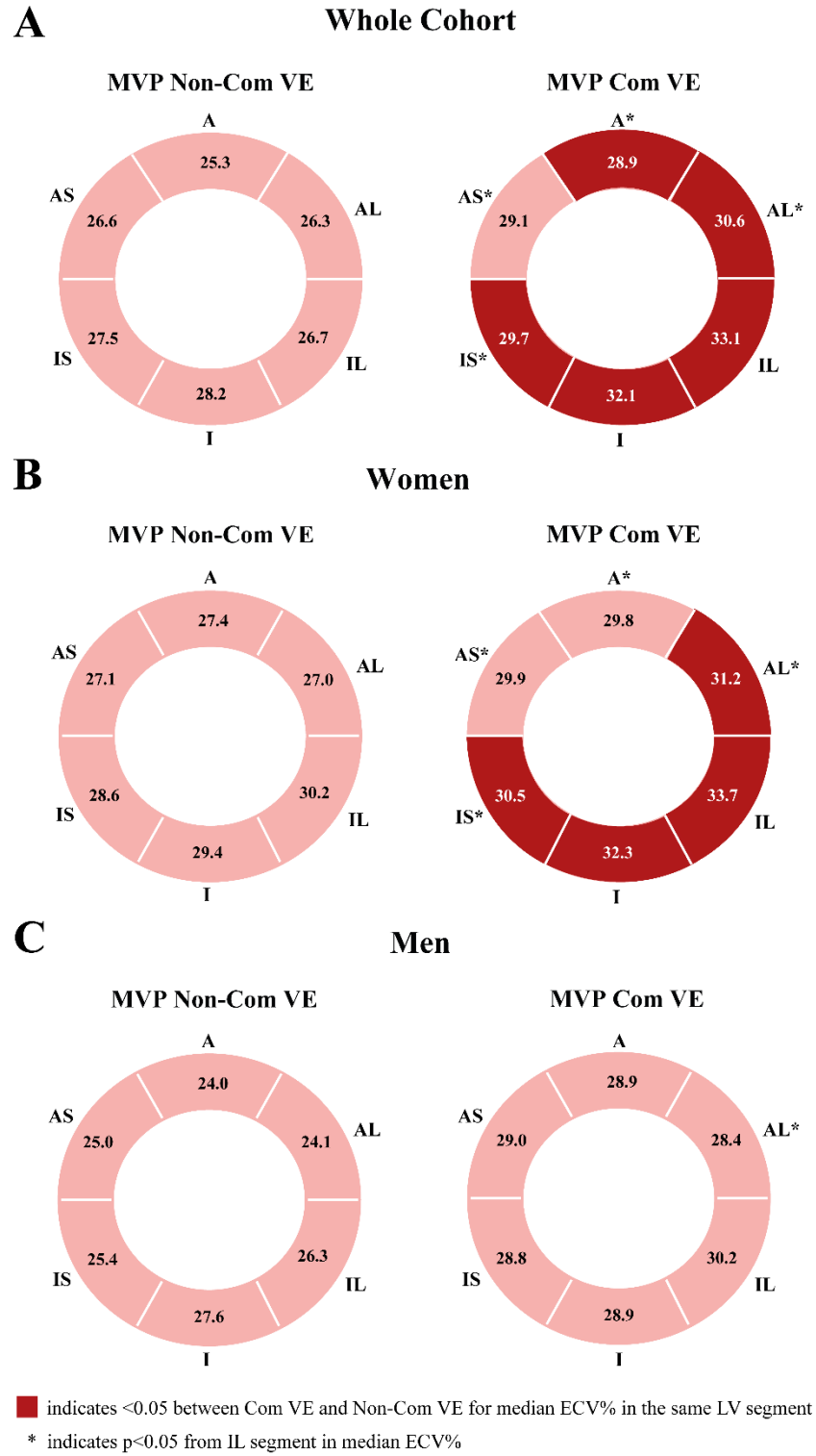
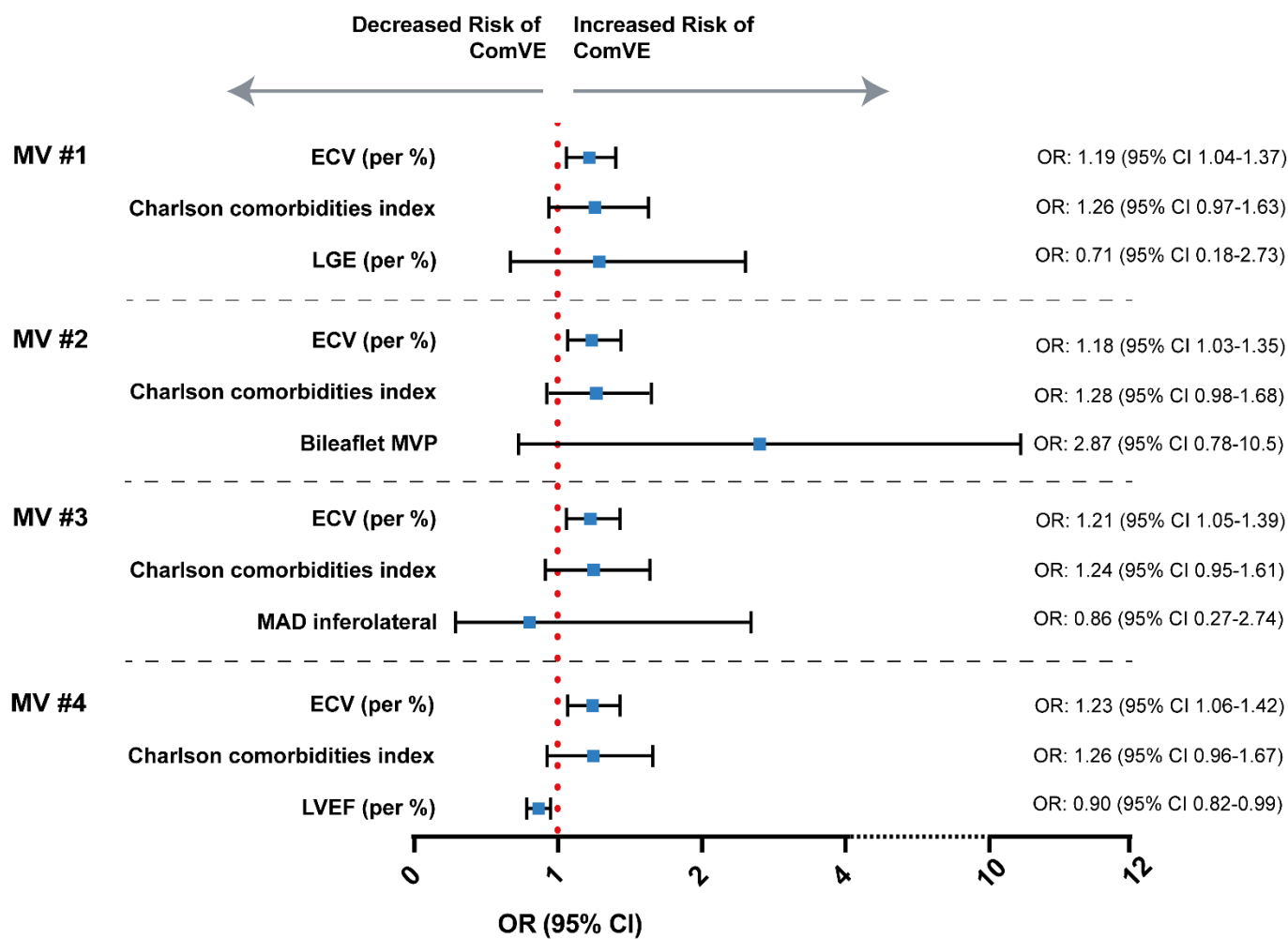


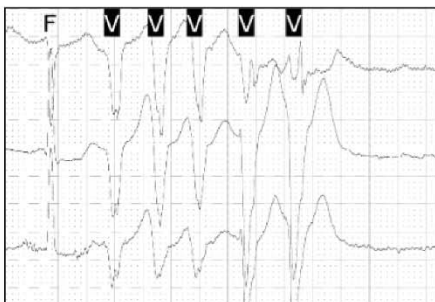
FIGURE 4



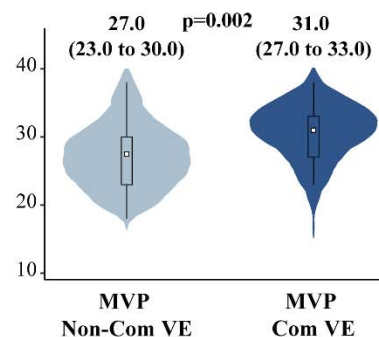
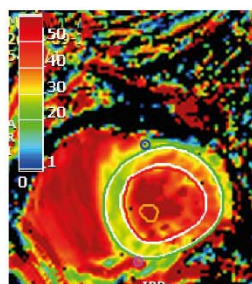
GRAPHICAL ABSTRACT

Interstitial Myocardial Fibrosis in Arrhythmic MVP Without Significant MR

Complex Ventricular Ectopy (ComVE)

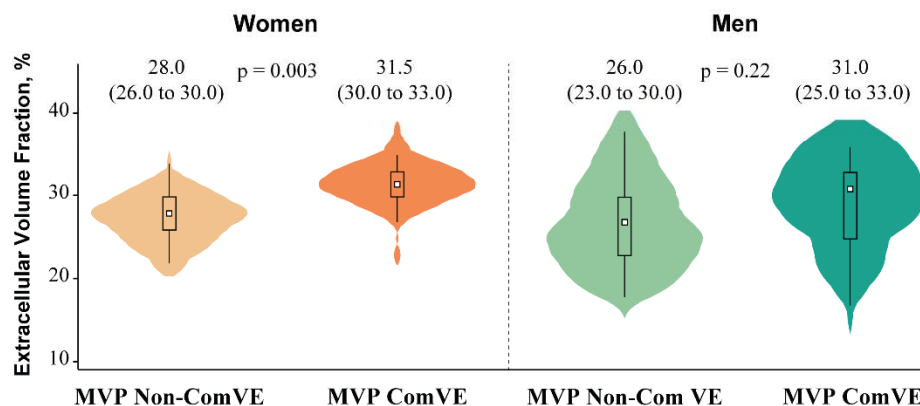


Extracellular Volume Fraction (%) by T₁ Mapping



- Interstitial fibrosis as quantified by T1 mapping/extracellular volume fraction is associated with increased risk of complex ventricular ectopy

Sex-Related Differences in Arrhythmic MVP Without Significant MR



- Stronger association between extracellular volume fraction and ComVE in women
- Greater expansion of interstitial diffuse myocardial fibrosis could explain the higher risk of severe arrhythmic events in women with MVP