

1 **Patterns of sacral dysmorphism in pelvic CT scans at a national referral hospital in Kenya**

2 **Short title: Patterns of sacral dysmorphism in Kenya**

3 **AUTHORS**

4 Valentine B Nyang'au^{1, 2¶*}, Fred Sitati^{2¶}, Edward Gakuya^{2&}, Oline Amunga^{1&}

5 1. Department of Orthopedics, University Health Services, University of Nairobi, Kenya

6 2. Department of Surgery, Orthopaedic Unit, University of Nairobi, Kenya

7 Corresponding author:

8 Email valentineb@uonbi.ac.ke

9 ¶These authors contributed equally to this work

10 &These authors also contributed equally to this work

11

12

13

14

15

16

17

18

19 **ABSTRACT**

20 **Background:** Sacral dysmorphism refers to morphological variations found in the first two
21 sacral segments that limit the safe placement of percutaneous sacral iliac screws. The prevalence
22 is documented in European, North American and some Asian populations. However, studies
23 within the African population including Kenya are lacking. The aim of the study was to describe
24 the patterns of sacral dysmorphism in pelvic computerized tomography (CT) scans at a national
25 referral hospital in Kenya.

26 **Methods:** A cross-sectional study carried out at the Radiology Department, Kenyatta National
27 Hospital from March 2020 to March 2021 involving the radiographic evaluation of 293 stored
28 abdominal pelvic CT scans of patients. Sacral dysmorphism was identified based on the sacral
29 dysmorphism score >70 and the presence of any of the six morphological features of sacral
30 dysmorphism.

31 **Results:** A sacral dysmorphism score of more than 70 was found to in 64% of the population.
32 The prevalence of dysmorphic sacra (based on the presence of at least one qualitative feature)
33 was 100%. The most prevalent feature of sacral dysmorphism was the lack of recession of the S1
34 segment (82%) followed by an unfused sacral segment (76%). Of note is that some qualitative
35 features of sacral dysmorphism were protective against a high sacral dysmorphism score. There
36 was no statistical significance of gender in sacral dysmorphism.

37 **Conclusion:** There is a high prevalence of sacral dysmorphism score in this population. There is
38 a need for further studies to revisit the concept of dysmorphic sacra based on the presence of at
39 least one qualitative feature as all our participants had at least one feature.

40 **Key Words:** sacral dysmorphism, sacral dysmorphism score, pelvic CT (computed
41 tomography), sacroiliac screws, S1, S2

42

43 INTRODUCTION

44 The term “*dysmorphic or dysplastic*” sacra refers to abnormal variations in the upper sacral
45 segments (S1 and S2) that may create a narrow or more angulated intraosseous corridor that
46 would limit the safe passage of percutaneous sacral iliac screws. These set of features were first
47 described on review of plain pelvic radiographs(1). These features include:- lack of sacral fusion,
48 irregular sacral foramina, lack of collinearity of the iliac crest, presence of mammillary bodies,
49 acute alar slopes and presence of a tongue in groove phenomenon. The determination of sacral
50 dysmorphism is done based on the presence of these descriptive features with some studies
51 defining sacral dysmorphism as the presence of all of the descriptive features while others base it
52 on the presence of any of the above descriptive features. This has led to increased research on
53 quantitative methods to determine sacral dysmorphism.

54 Percutaneous sacral iliac screws is the current gold standard in fixing posterior pelvic
55 disruption(2). These screws provide effective stability and haemorrhage control and are superior
56 to traditional open approaches which are associated with significant morbidity and mortality. It is
57 important for the surgeon to be conversant with the identification of sacral dysmorphism to make
58 relevant pre-operative plans to ensure safe placement of these screws.

59 There is a significant knowledge gap globally on sacral dysmorphism. Qualitative methods of
60 identifying sacral dysmorphism are subjective; newer quantitative techniques such as the sacral

61 dysmorphism score are being described(3). The prevalence of sacral dysmorphism has been
62 found to be high ranging from 40-70 percent; these studies have mostly been done in
63 European(4), North American(3) and Asian populations(5). There was no data in the African set
64 up.

65

66 The aim of the study was to describe the patterns of sacral dysmorphism in pelvic computerized
67 tomography (CT) scans at a national referral hospital in Kenya and this goal was achieved.

68

69 **MATERIALS AND METHODS**

70 This was a cross-sectional study. It involved radiographic evaluation of 293 lumbosacral and
71 pelvic helical CT scans (T12-L5). We included scans of patients aged between 18 and 70 years
72 and had visualization of the lowest rib-bearing vertebra up to the lesser trochanter. Scans with
73 unstable pelvic ring injury, implants obscuring the lumbosacral junction, sacral tumors or
74 infection and lumbar scoliosis of more than 20 degrees, or spina bifida were excluded. Any scan
75 that did not meet the above criteria was replaced by selecting the next randomized participant.

76 This study was conducted at Kenyatta National Hospital (KNH), a national referral hospital,
77 Kenya Essential Package for Health (KEPH) level six, in Nairobi County. The institution is a
78 tertiary referral facility with specialized radiologic and orthopaedic services and staff. The study
79 used digital repositories of stored pelvic CT scan images in the Radiology Department at KNH
80 for a period of 13 months from March 2020 to March 2021. A simple random sampling
81 technique was used in this study because it offered an equal chance of selection in the study

82 population. The study population was tabulated on Microsoft Excel and randomized using the
83 random function.

84 The direction of the scanning was cranio caudal; no contrast was given, and the respiratory phase
85 was suspended. Patients lay supine with hips and knee joints extended. Original axial images
86 were presented in different presets including bone window and converted to multiplanar
87 reconstruction (MPR) and three-dimensional rendering. The CT was conducted with a
88 NEOSOFTE-64 slice scanner. Images taken were reformatted to 2mm thickness to better define
89 features.

90 The population size, N , was 1200 pelvic CT scans, these are from the CT scan repository in KNH
91 for the duration of the study period. The anticipated frequency of sacral dysmorphia, p was
92 40%(3). The confidence interval was 95% and the design effect (DEFF) was one. The value of
93 standard normal distribution corresponding to a 95 percent significant level, $Z^2_{1-\alpha}$. Finally, the
94 study had a powered², of 80 percent. A sample size of 283 was calculated using the OpenEpi
95 online sample size calculator (*Epi Calc*, 2021.)Using the sampling equation for a finite
96 population: $sample\ size\ n = [DEFF * Np(1-p)] / [(d^2 / Z^2_{1-\alpha/2} * (N-1) + p*(1-p)]$.

97 In our final data collection, 303 CT scans were sampled, 10 records were omitted during data
98 cleaning; as they has spurious data and finally 293 records were analysed; this figure ensured our
99 study was adequately powered. Outliers, especially for sagittal angle of more than 70 and below
100 10 degrees were dropped since they are not physiologically plausible.

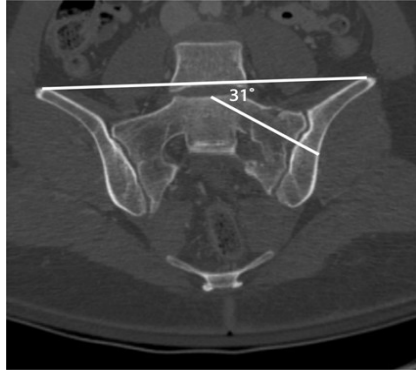101 Excluded data was not analysed. There was no missing data since the electronic data extraction
102 tool had mandatory questions and skip patterns inbuilt in it based on the inclusion and exclusion
103 criteria.

104 The study population was tabulated on Microsoft Excel and randomized using the random
105 function.

106

107 **Sacral Dymorphism Score**

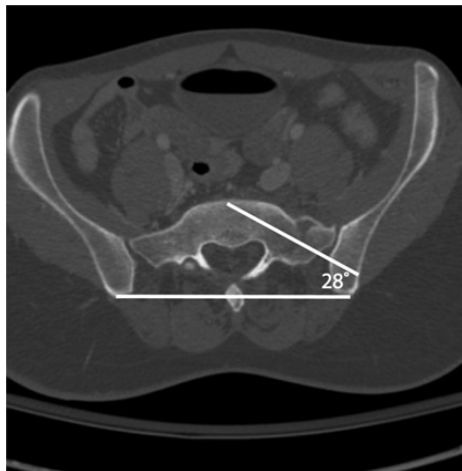
108 To calculate the sacral Dymorphism Score, each CT scan was reformatted along the axis of the
109 sacrum to obtain cross-sectional imaging of the S1 and S2 sacral osseous corridor, or “*safe*
110 *zone*” for iliosacral screw placement(7). For standardization and reproducibility; the scans were
111 reformatted in true coronal and axial planes by defining the sagittal axis as the posterior border
112 of the sacrum and the axial reformats along the upper-end plate of the S2 vertebrae(8).Coronal
113 angulation was measured by an angle formed by a line drawn along the axis of the osseous
114 corridor and a line connecting the top of the iliac crests(7). The top of the iliac crest was found
115 by correlating the axial and sagittal views on multi-planar reconstruction. Axial angulation was
116 measured as the angle formed by a line drawn on the axis of the osseous corridor and a line
117 connecting the posterior iliac spines. The tip of the posterior superior iliac spine was found by
118 correlating the axial and sagittal views on MPR reconstruction. The sacral dymorphism score =
119 (first sacral coronal angle) + 2 (first sacral axial angle)(7).The outcome variable, sacral
120 dymorphism, was defined as a dymorphic score of more than 70 on the quantitative
121 analysis(3).



122

123 *Figure 1: Coronal angulation was measured as the angle subtended by a line drawn along the*
124 *axis of the osseous corridor and a line connecting the top of the iliac crests(7)*

125



126

127 *Figure 2: Axial angulation was measured as the angle formed by a line drawn on the axis of the*
128 *osseous corridor and a line connecting the posterior iliac spines(7).*

129 **Sacral dysmorphism based on qualitative characteristics**

130 To evaluate the qualitative characteristics of sacral dysmorphism, we created pelvic outlet
131 reconstruction in which neutral horizontal rotation was corrected by aligning lumbar spinous
132 processes with the symphysis pubis. The vertical rotation was adjusted to align the superior

133 cortex of the pubis with the second sacral segment body(7). Each outlet reconstruction was
134 reviewed and the presence or absence of each of the radiographic qualitative characteristics of
135 sacral dysmorphism that included: an upper sacral segment not recessed in the pelvis; the
136 presence of mammillary processes; an acute alar slope; a residual disc between the first and
137 second sacral segments; and noncircular upper sacral neural foramina determined. In addition,
138 axial CT scans were reviewed for the presence or absence of a “*tongue-in-groove*” sacroiliac
139 morphology(1). The definition of sacral dysmorphism based on the number of dysmorphic
140 features has been controversial in our case we assessed dysmorphism as the presence of any of
141 the above features. This is because each of these features has been associated with narrowing the
142 safe corridor for passage of sacral iliac screws(1) .

143 **Ethical approval**

144 The study was approved by Kenyatta National Hospital-University of Nairobi Ethics and Research
145 Committee (KNH-UON ERC) approval number KNH-ERC/A/9 as required by the Department of
146 Surgery, Orthopaedic Unit Faculty of Health Sciences, University of Nairobi. The study was also
147 approved by the National Commission for Science Technology and Innovation NACOSTI reference
148 NACOSTI/P/22/15319.

149

150 **Data analysis**

151 We performed univariate analysis using Stata 14 ® to produce proportions, tables, charts, and
152 graphs. In addition, bivariate analysis was done as a measure of association with sacral
153 dysmorphism score as the outcome variable and other exposure variable such as sex, age and
154 each of the six qualitative features.

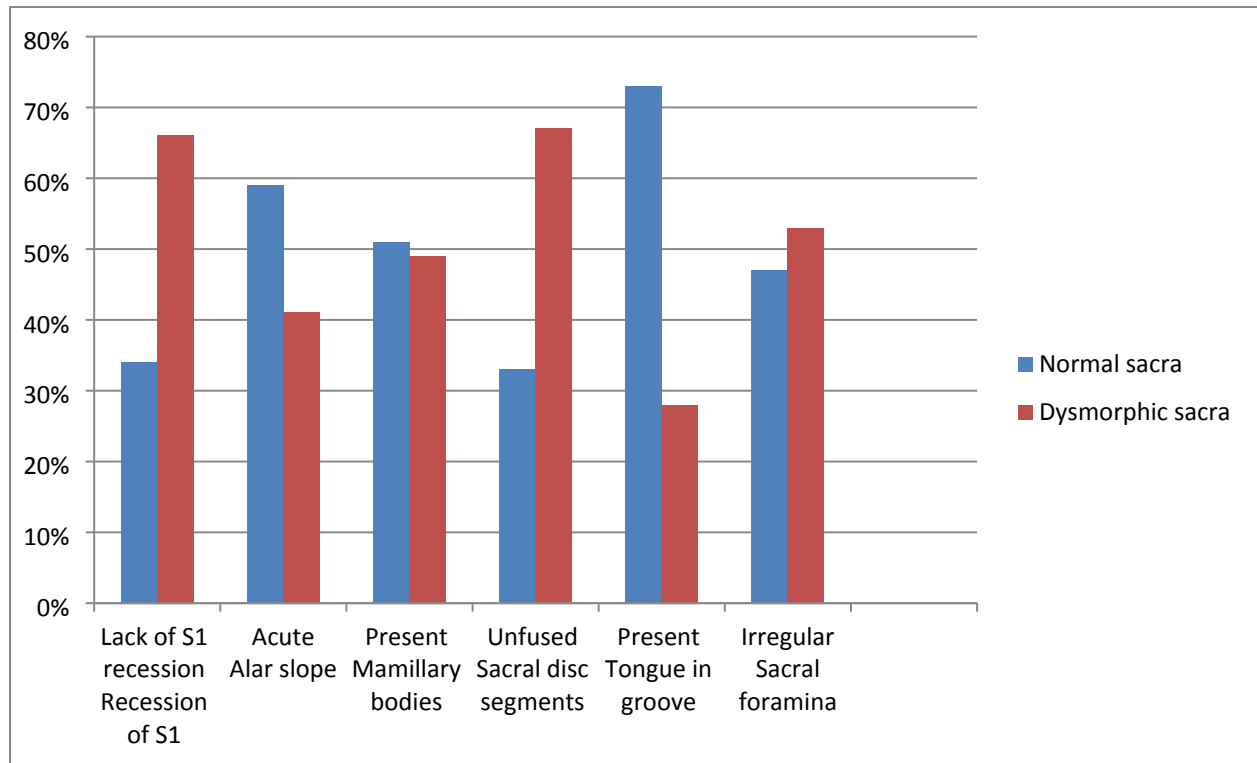
155 **RESULTS**

156 Out of the 293 randomly selected CT scans, the majority were male (53%). The median age was
157 44 years with an inter quartile range of 34-55 years. Sacral dysmorphism score of more than 70
158 was found in 64% of the study participants, with it being more prevalent among males at 69%
159 compared to females respectively. The prevalence of sacral dysmorphism based on presence of
160 at least one qualitative feature was 100%.

161 The most prevalent dysmorphic feature in the normal population was tongue in groove (73%)
162 and acute alar slope (59%) respectively, whereas the most prevalent features of sacral
163 dysmorphism in the dysmorphic population was the unfused sacral segment (67%) and lack of
164 recession of the s1 segment (66%). See Figure 3.

165

166



167

168 *Figure 3: Proportion of radiological features of sacral dysmorphism in the normal sacra and*
169 *dysmorphic sacra as categorized by the sacral dysmorphism score*

170 Sacral dysmorphism score was significantly higher in males compared to females $p=0.0459$. We
171 found that the prevalence of four radiological features of sacral dysmorphism were statistically
172 significant $p \leq 0.01$ compared to the normal sacral features these are non acute slope, absent
173 mammillary bodies, absent tongue in groove and regular sacral foramen. These four features
174 were more prevalent in the dysmorphic sacra as compared to the normal sacra. See Table 1.

175

176

177

178 **Table 1: Comparative analysis of sacral dysmorphism score by sex and radiological**
 179 **features**

Variable		Sacral dysmorphism score		Total	p-value
		Normal sacra	Dysmorphic sacra		
Sex	Female	56 (41%)	81 (59%)	137	0.0459
	Male	49 (31%)	107 (69%)	156	
Recession of S1	Lack of S1 recession	81 (34%)	159 (66%)	240	0.0565
	Recessed S1	24 (45%)	29 (55%)	53	
Alar slope	Not acute	58 (27%)	155 (73%)	213	<0.0001
	Acute	47 (59%)	33 (41%)	80	
Mamillary bodies	Absent	67 (31%)	151 (69%)	218	0.0010
	Present	38 (51%)	37 (49%)	75	
Sacral disc segments	Unfused	75 (33%)	149 (67%)	224	0.0650
	Fused	30 (43%)	39 (57%)	69	
Tongue in groove	Absent	47 (22%)	166 (78%)	213	<0.0001
	Present	58 (73%)	22 (28%)	80	
Sacral foramina	Regular	54 (29%)	130 (71%)	184	0.0013
	Irregular	51 (47%)	58 (53%)	109	

180 ***Two-sample test of proportions- z test was used to test if the difference between the proportions was**
 181 **significant**

182 Crudes odds ratio was carried out as a measure of association between the various radiological
 183 features of sacral dysmorphism and the sacral dysmorphism score. We found significant results
 184 P<0.01 in four radiological features; acute alar slope, mamillary bodies, tongue in groove
 185 formation and sacral foramina. Scans that had a non acute alar slope, absent mamillary bodies,

186 absent tongue in groove malformation and regular sacral foramina were more likely to have a
 187 sacral dysmorphism score of >70. See Table 2.

188 **Table 2: Bivariable analysis of factors associated with sacral dysmorphism**

Variable		Sacral dysmorphism score		Total	Odds ratio	95% CI	p-value
		Normal sacra	Dysmorphic sacra				
Sex	Female	56 (41%)	81 (59%)	137	1.5	0.9-2.5	0.0918
	Male	49 (31%)	107 (69%)	156			
Recession of S1	Lack of S1 recession	81 (34%)	159 (66%)	240	0.6	0.3-1.2	0.1130
	Recessed S1	24 (45%)	29 (55%)	53			
Alar slope	Not acute	58 (27%)	155 (73%)	213	0.3	0.1-0.5	<0.0001
	Acute	47 (59%)	33 (41%)	80			
Mamillary bodies	Absent	67 (31%)	151 (69%)	218	0.4	0.2-0.8	0.0019
	Present	38 (51%)	37 (49%)	75			
Sacral disc segments	Unfused	75 (33%)	149 (67%)	224	0.7	0.4-1.2	0.1300
	Fused	30 (43%)	39 (57%)	69			
Tongue in groove	Absent	47 (22%)	166 (78%)	213	0.1	0.1-0.2	<0.0001
	Present	58 (73%)	22 (28%)	80			
Sacral foramina	Regular	54 (29%)	130 (71%)	184	0.5	0.3-0.8	0.0026
	Irregular	51 (47%)	58 (53%)	109			

189

190 **DISCUSSION**

191 Identification of sacral dysmorphism is important for pre-operative planning when placing
 192 percutaneous sacral iliac screws(4).Percutaneous sacral iliac screws are likely to be misplaced in

193 cases of dysmorphism(9). Misplaced screws may cause long term morbidity due to injury of
194 close neurovascular structures. However, the definition of sacral dysmorphism is not
195 standardized; with the question of how many radiological features does it take to label a sacrum
196 as dysmorphic not answered(4). Studies carried out in the African population are to the best of
197 our knowledge absent with most done in European(10), North American(9) and Asian
198 populations(11).

199 In our study, the prevalence of sacral dysmorphism based on the sacral dysmorphism score was
200 64 % whereas the prevalence of sacral dysmorphism based on the presence of at least one feature
201 was 100%. Sacral dysmorphism score of more than 70 in the original study by Kaiser et al was
202 found to be 41% in the American population(3), 84.7% in the Iranian population(12) and a mean
203 of 47.4 ± 15.8 in the German population(10).

204 The most prevalent dysmorphic features were the presence of unfused sacral segments 67% and
205 lack of recession of the s1 segments at 66%. This was similar to other studies where presence of
206 unfused sacral segments was the most prevalent dysmorphic feature 70% in a German based
207 study (4); 71% in the Iranian study(12) and 50% in the Mugla region in Turkey(13). As
208 evidenced by these studies, unfused sacral segments may be used as a screening tool for sacral
209 dysmorphism as it has been largely associated with the dysmorphic sacrum (sacral dysmorphism
210 score >70) unlike other features which have been highly variable. The sacral discs are separated
211 in childhood with the lower segments S3-S4 and S4-S5 fusing in adolescence and the upper
212 segments by the 3rd decade of life(14). This may suggest a relationship with age, however in our
213 study no age association was found similar findings to other studies(4).

214

215 It is important to note that the dysmorphic features were also present in the normal sacrum(
216 sacral dysmorphism score < 70). These findings are similar to other studies , where dysmorphic
217 features are still found within the normal population(12). Some of these features such as
218 mammillary bodies, an acute alar slope, the presence of a tongue in groove formation and
219 irregular sacral foramina were found to be more prevalent in the normal population. This
220 suggests that these features may form a normal anatomical variant in our population in our
221 population. The finding on the tongue in groove feature as seen on axial views of the CT scan
222 has been found to negatively correlate with sacral dysmorphism, similar to our study
223 findings(3). We found no evidence in gender differences in sacral dysmorphism based on the
224 sacral dysmorphism score. This is similar to other recent studies which noted no statistical
225 gender differences in sacral dysmorphism occurrence(3).

226 The high prevalence of sacral dysmorphism based on qualitative features within our population
227 may suggest that these features could be normal anatomical variants. These features alone may
228 not be objective in determining the presence of dysmorphism. We found that all the pelvises had
229 at least one dysmorphic characteristic based on the initial descriptions of sacral dysmorphism
230 (15). We found studies that showed high rates of dysmorphism, such as up to 85%(4); however
231 none showed a 100% prevalence where each scan had at least one dysmorphic feature. These are
232 suggestive of a normal anatomical variant in our population.

233 Our study is to the best of our knowledge, the first in an African population. This was limiting to
234 our findings as we could not compare local results to other studies carried out within the African
235 continent. The role of ethnicity in the prevalence and patterns of sacral dysmorphism cannot be
236 ignored and presents an exciting front for future research.

237 **CONCLUSION**

238 Sacral dysmorphism is highly prevalent within our study population. Care should be taken in
239 screening patients for sacral dysmorphism as part of the pre-operative planning for sacral iliac
240 screw fixation. Descriptive or qualitative features of sacral dysmorphism do not allow for a
241 reliable way of predetermining sacral dysmorphism. Quantitative measures such as the sacral
242 dysmorphism score offer a more objective way to evaluate sacral dysmorphism. This is relevant
243 for both orthopaedic surgeons and radiologists.

244 **ACKNOWLEDGMENTS**

245 We wish to acknowledge the training and support from the University of Nairobi's Building
246 Capacity for Writing Scientific Manuscripts (UANDISHI) Program at the Faculty of Health
247 Sciences. This work was funded in part through the ADVANCE program at IAVI. This work is
248 made possible by the support of the American People through the U.S. President's Emergency
249 Plan for AIDS Relief (PEPFAR) through United States Agency for International Development
250 (USAID). *The contents of this study are the sole responsibility of the authors and do not*
251 *necessarily reflect the views of PEPFAR, USAID, or the United States Government.*

252

253 **REFERENCES**

- 254 1. Routt ML, Simonian PT, Agnew SG, Mann FA. Radiographic recognition of the sacral alar slope
255 for optimal placement of iliosacral screws: a cadaveric and clinical study. J Orthop Trauma
256 [Internet]. 1996 Apr;10(3):171–7. Available from: [http://journals.lww.com/00005131-199604000-](http://journals.lww.com/00005131-199604000-00005)
257 00005

- 258 2. Laux CJ, Weigelt L, Osterhoff G, Slankamenac K, Werner CML. Feasibility of iliosacral screw
259 placement in patients with upper sacral dysplasia. *J Orthop Surg Res* [Internet]. 2019 Dec
260 9;14(1):418. Available from: [https://josr-online.biomedcentral.com/articles/10.1186/s13018-019-](https://josr-online.biomedcentral.com/articles/10.1186/s13018-019-1472-7)
261 1472-7
- 262 3. Kaiser SP, Gardner MJ, Liu J, Routt MLC, Morshed S. Anatomic Determinants of Sacral
263 Dysmorphism and Implications for Safe Iliosacral Screw Placement. *J Bone Joint Surg Am*
264 [Internet]. 2014 Jul 16;96(14):e120. Available from:
265 <http://www.ncbi.nlm.nih.gov/pubmed/25031382>
- 266 4. Weigelt L, Laux CJ, Slankamenac K, Ngyuen TDL, Osterhoff G, Werner CML. Sacral
267 Dysmorphism and its Implication on the Size of the Sacroiliac Joint Surface. *Clin Spine Surg A*
268 *Spine Publ* [Internet]. 2019 Apr;32(3):E140–4. Available from:
269 <https://journals.lww.com/01933606-201904000-00011>
- 270 5. Wu L-P, Li Y-K, Li Y-M, Zhang Y-Q, Zhong S-Z. Variable morphology of the sacrum in a
271 Chinese population. *Clin Anat* [Internet]. 2009 Jul;22(5):619–26. Available from:
272 <http://doi.wiley.com/10.1002/ca.20809>
- 273 6. Epi calc [Internet]. Available from: <https://www.openepi.com/SampleSize/SSPropor.htm>
- 274 7. Gardner MJ, Morshed S, Nork SE, Ricci WM, Chip Routt ML. Quantification of the Upper and
275 Second Sacral Segment Safe Zones in Normal and Dysmorphic Sacra. *J Orthop Trauma* [Internet].
276 2010 Oct;24(10):622–9. Available from: <https://journals.lww.com/00005131-201010000-00005>
- 277 8. Morshed S, Choo K, Kandemir U, Kaiser SP. Internal Fixation of Posterior Pelvic Ring Injuries
278 Using Iliosacral Screws in the Dysmorphic Upper Sacrum. *JBJS Essent Surg Tech* [Internet]. 2015
279 Feb 11;5(1):e3. Available from: <https://journals.lww.com/01709766-201505010-00003>
- 280 9. Hasenboehler EA, Stahel PF, Williams A, Smith WR, Newman JT, Symonds DL, et al. Prevalence

- 281 of sacral dysmorphia in a prospective trauma population: Implications for a “safe” surgical
282 corridor for sacro-iliac screw placement. *Patient Saf Surg* [Internet]. 2011 May 10;5(1):8.
283 Available from: <http://www.ncbi.nlm.nih.gov/pubmed/21569232>
- 284 10. Wendt H, Gottschling H, Schröder M, Marintschev I, Hofmann GO, Burgkart R, et al.
285 Recommendations for iliosacral screw placement in dysmorphic sacrum based on modified
286 in-out-in corridors. *J Orthop Res* [Internet]. 2019 Mar 5;37(3):689–96. Available from:
287 <https://onlinelibrary.wiley.com/doi/10.1002/jor.24199>
- 288 11. Iga T. Iliosacral screw corridors in Japanese subjects: a study using reconstruction CT scans. *OTA*
289 *Int open access J Orthop trauma* [Internet]. 2021 Sep;4(3):e145. Available from:
290 <http://www.ncbi.nlm.nih.gov/pubmed/34746676>
- 291 12. Ali Reza Manafi; Mohamad Qoreishi, Ali Fotouhi Maleky, Reza Zandi, Mohsen Elahi FD.
292 Determination of Anatomical Sacral Dysmorphism Criteria based on CT scan Findings for
293 Iliosacral Screw Fixation in a Sample of Iranian Population without Pelvic Ring Fracture. *Trauma*
294 *Mon* [Internet]. 2020;25(4):153–9. Available from:
295 http://www.traumamon.com/article_110878_fe7355de441ff51eb55dfd45b4d38d7e.pdf
- 296 13. KILINÇ R, KILINÇ CY, CAN F, GÜLTAÇ E, ŞAHİN İG, AYDOĞAN N. Frequency of Sacral
297 Dysmorphism Findings in Mugla Region. *Muğla Sıtkı Koçman Üniversitesi Tıp Derg* [Internet].
298 2021 Apr 30;8(1):47–51. Available from:
299 <https://dergipark.org.tr/en/doi/10.47572/muskutd.852455>
- 300 14. Diel J, Ortiz O, Losada RA, Price DB, Hayt MW, Katz DS. The Sacrum: Pathologic Spectrum,
301 Multimodality Imaging, and Subspecialty Approach. *RadioGraphics* [Internet]. 2001
302 Jan;21(1):83–104. Available from: <http://pubs.rsna.org/doi/10.1148/radiographics.21.1.g01ja0883>
- 303 15. Routt ML, Simonian PT, Agnew SG, Mann FA. Radiographic recognition of the sacral alar slope

304 for optimal placement of iliosacral screws: a cadaveric and clinical study. J Orthop Trauma
305 [Internet]. 1996;10(3):171–7. Available from: <http://www.ncbi.nlm.nih.gov/pubmed/8667109>

306