

1 Research Protocol for a Randomised Controlled Trial Comparing the Outcome of the 3D-Printed  
2 Patient-Specific-Instrument Assisted Lapidus Fusion vs Conventional Lapidus Fusion for Surgical  
3 Correction of Hallux Valgus Deformity

4 **Authors (s):**

5 **Samuel Ka-Kin Ling, Rachel Xiaoyu Wei, Elvis Chun-Sing Chui, Boon Hor Chong, Michael**  
6 **Tim-Yun Ong, Pauline Po-Yee Lui, Patrick Shu-Hang Yung**

7

8 Correspondence address and affiliations of all authors:

9 Department of Orthopaedics and Traumatology, Faculty of Medicine, The Chinese University of Hong  
10 Kong (CUHK), Hong Kong SAR, China

11

12 \* Corresponding author: Samuel Ka-Kin Ling

13 E-mail: [samuel.ling@link.cuhk.edu.hk](mailto:samuel.ling@link.cuhk.edu.hk)

14 Mailing address: 5/F, Dept. of Orthopaedics and Traumatology, LCW Clinical Science Building, Prince  
15 of Wales Hospital, Shatin, Hong Kong SAR

16 Telephone: (852) 3505-2010

17

18 Ethics: The study will comply with the Declaration of Helsinki and ICH-GCP. The Joint CUHK-NTEC  
19 CREC Ref 2020.633-T has granted ethics approval for this proposed study.

20 Trial Registration: [clinicaltrials.gov](https://clinicaltrials.gov) NCT05602844

21 Protocol Version: 28 Oct 2022 version 01

22 Principal Investigator: Samuel KK Ling, CUHK

23

24 Abstract

25 Introduction

26 Hallux valgus (HV) affects up to 30% of the population. Lapidus surgery with 1st tarsal-metatarsal joint  
27 arthrodesis is one of the most common surgical options for HV. Despite its popularity, the current  
28 procedure is not without complications. This investigation will be the world's first Lapidus arthrodesis  
29 surgery utilising patient-specific instruments (PSI) as an assistive tool. We hypothesise that the PSI will

30 **NOTE: This preprint reports new research that has not been certified by peer review and should not be used to guide clinical practice.**  
enhance surgical precision, accelerate fusion rates, decrease non-unions, and reduce the need to use bone

31 grafts.

32

33 Methods and analysis:

34 This is a single-blinded, parallel-group, randomised controlled trial comparing the outcome of the 3D-  
35 Printed PSI Assisted Lapidus Fusion (n=27) vs Conventional Lapidus Fusion (n=27) for HV deformity.  
36 Both groups will receive an identical postoperative rehabilitation of protected weight bearing and  
37 splinting. Outcomes will include foot function scores, radiological alignment and arthrodesis site  
38 assessment with X-ray and High-Resolution Peripheral Quantitative-Computed Tomography, and foot  
39 pressure analysis.

40

41 Keywords:

42 Hallux valgus; Bunion; Arthrodesis; Patient Specific Instrument; 3D printing

43

44 Strengths and Limitations

45 Strengths:

- 46 • This will be the world's first randomised control trial utilising PSI for hallux valgus surgery.
- 47 • Surgeries are done by a team of experienced foot and ankle surgeons.

48 Limitations:

- 49 • A single-centre study with a follow-up of only 1 year. However, the authors believe that traditional  
50 Lapidus surgery has known term results, and the chief hypothetical benefit of PSI-assisted surgery is  
51 faster bony fusion and less surgical complications, which will be evident within 1 year.

52

### 53 **Introduction**

54 Hallux valgus (HV) is one of the most common(1, 2) foot disease among the population; the prevalence  
55 could be up to 36%(3). The first ray plays a crucial role in biomechanics for weight bearing and  
56 complicated motion during daily activities(4). The instability of the first ray, particularly the first  
57 tarsometatarsal joint (TMTJ), is one of the key associations in HV(5-7). Lapidus arthrodesis is a  
58 commonly used procedure to attain medial column stability for hallux valgus correction(8).

59 The most common complication of Lapidus arthrodesis is a high non-union rate(9) which may require  
60 revision procedures like bone grafting and revision fixation(10). Inadequate contact of the fusion surfaces

61 due to suboptimal osteotomies lead to delayed fusion and subsequent loss of implant stability.

62 Aside from difficulty getting a perfect osteotomy contact plane, the post-arthrodesis alignment of the 1st  
63 metatarsal is also an important factor determining treatment success(11). Optimal 1<sup>st</sup> metatarsal length is  
64 important for the distribution of foot pressure and prevention of postoperative metatarsalgia(12).

65 However, it is difficult to utilise conventional intra-operative 2D fluoroscopy to create a precise cutting  
66 plane since hallux valgus is not a simple single-plane deformity but a complex multi-planar deformity(13,  
67 14). Pre-operative planning with 3D CT has been increasingly used in orthopaedics, especially in  
68 navigation and robotic-assisted surgery around the spine and knee. However, it is difficult to apply  
69 trackers in the foot and ankle region due to the multiple articulations and relatively smaller bones.

70 3D printing technology has also been applied to orthopaedic surgeries (15) and has allowed the creation  
71 of customised patient-specific cutting jigs. The technology is currently applied to high tibial osteotomies  
72 (16), fracture fixation (17), tumour resection (18) and spinal surgery(19), with previous studies showing  
73 promising results for its application.

74 In brief, image acquisition, image processing and 3D printing are the three main steps during pre-  
75 operation. After acquiring high-quality medical images from CT and processing the images, computer-  
76 aided design (CAD) will transform the STereoLithography file (STL), which represents the 3D model of  
77 the interested objects, into a series of cross-sectional layers. Several methods, including  
78 stereolithography apparatus (SLA), fused deposition modelling (FDM), selective laser sintering (SLS)  
79 and electron beam melting (EBM), are utilised for printing these objects with the appropriate materials  
80 (15). The printed jigs are able to provide a visual and tactile understanding of the anatomical and  
81 pathological information of each specific patient. This will greatly help the planning for Lapidus surgery,  
82 considering the complex 3D anatomical deformation occurring at the TMTJ.

83 Duan et al. investigated the availability of 3D-printed customised guides assisting subtalar joint  
84 arthrodesis and found that it improved accuracy for drilling the Kirschner wires into the ideal position,  
85 reducing the operative time as well as reducing intra-operative radiation(20). The application has also  
86 been reported for complex foot reconstruction surgery in patients with Charcot arthropathy(21).

87 The use of 3D-printed jigs in orthopaedics is a relatively new technology. To our best knowledge, no  
88 published clinical studies have investigated the outcomes of using 3D-printed jigs in hallux valgus  
89 correction surgery.

90

91 **Methods and analysis**

92 The study will comply with The Declaration of Helsinki.

93 **Study Design**

94 This is an open-label, randomised controlled trial where a team of foot and ankle specialists shall be the  
95 surgeons. An ITT (intent-to-treat) analysis shall include all randomised patients that not only fit our  
96 inclusion and exclusion criteria but gave consent to join this study. From recruitment to outcome  
97 measurement timeline please refer to the consort diagram.

98 **Study Setting**

99 Department of Orthopaedics and Traumatology, Prince of Wales Hospital, Hong Kong

100 **Objectives and hypothesis**

101 The objective of the current study is to investigate whether a 3D printed patient-specific Lapidus  
102 arthrodesis jig will 1) improve bone-to-bone arthrodesis success rates; 2) resume more normal post-  
103 operation gait and foot pressure distribution in HV patients. We hypothesise that a patient-specific  
104 Lapidus arthrodesis jig will decrease non-union rates and improve clinical outcomes. Measured outcomes  
105 include: FAOS score, X-rays, HR pQCT, deformity severity, delayed-union rate, non-union rate and  
106 plantar pressure distribution at the relevant designated timeline (refer to Outcomes).

107 **Sample Size Estimation**

108 Unfortunately, no information was available from previous similar studies which also investigated the  
109 clinical outcomes of using 3D printed jigs in Lapidus procedure to correct HV deformity based on Foot  
110 and Ankle Outcome Score (FAOS). Therefore, the FAOS Pain Score from a previous survey, which  
111 conducted the validation of FAOS for Hallux Valgus, was extracted as the standard deviation (SD) of  
112 that in pre-surgery HV patients (SD = 19.4) (22).

113 When using FAOS to evaluate the improvement of pain in HV, a 15.3-point difference is the smallest  
114 score change achievable by an individual and is considered a Minimally Important Change (MIC)

115 (Sierevelt et al., 2016). Using the Normally Distributed Continuous Data-comparing Two Means, a  
116 standardised effect size of 0.79 was calculated (Effect size = Mean difference/SD) (23). With a two-sided  
117 5% significance level and 80% power, an estimated sample size in each group of 27 was figured out  
118 using G\*Power 3.1.

119

## 120 **Allocation**

121 To achieve a lower risk of bias, blocked randomisation will be utilised to form the allocation list for two  
122 groups (24). A computer random number generator will be used to select random permuted blocks with  
123 a block size of 20 and an equal allocation ratio.

124

## 125 **Participants**

126 Inclusion criteria:

- 127 • All hallux valgus patients scheduled for primary Lapidus arthrodesis.
- 128 • Hallux Valgus Angle >20°
- 129 • 1,2 Inter-metatarsal Angle >9°
- 130 • Age >18

131 Exclusion criteria:

- 132 • Disabilities (both physical and mental) which may impair adherence to the rehabilitation.
- 133 • Revision surgery
- 134 • Concomitantly undergone additional procedures on the same foot (e.g. lesser toe surgery)
- 135 • Recent (3 months) use of medications which may influence bone turnover (e.g. chemotherapy,  
136 osteoporotic medications)
- 137 • Medical comorbidity leading to contraindication for surgery (e.g. active infection, severe  
138 uncontrolled diabetes etc.)
- 139 • Mentally/physically unable to consent

## 140 **Patient and public involvement**

141 Patients who fit both the inclusion and exclusion criteria are briefed with the randomised controlled trial  
142 nature of this study. They are informed that all randomisation is done via a computer program, and

143 patients and subsequent doctors they see in outpatient clinics are blinded to the subject group allocation.  
144 After the surgery, patients can reflect their own assessment via finishing the FAOS survey (one of the  
145 primary outcomes). Results of the study shall be shared with the involved patients via phone if prompted  
146 by these participants after this study has ended.

## 147 **Intervention**

148 Interventions for each group with sufficient detail to allow replication, including how and when they will  
149 be administered. For the experiment group, there are three main steps of the surgery.

### 150 1. Surgical Planning

151 DICOM files will be imported into the Model Intestinal Microflora in Computer Simulation (MIMICS  
152 21.0) 3D image processing software (Materialise, Belgium) for 3D reconstruction. A threshold-based  
153 segmentation of the CT images (figure 2) make use of the bone, generating a 3D reconstruction of the  
154 medium cuneiform and the 1st metatarsal of the involved foot for surgical simulation. The corresponding  
155 surgeon will define the cutting plane on the cuneiform and the metatarsal respectively, which produces  
156 the bone segment that will be removed for further fusion. This will help provide electronic data for the  
157 design of the computer-aided modelling (CAM) surgical jigs (figure 3).

### 158 2. Prepare for CAM surgical jigs

159 The data of the designed jigs were converted into stereolithographic (STL) format and imported into a  
160 3D printer (Fortus 400mc Fused Deposition Modeling system, Stratasys Inc., Eden Prairie, MN) for  
161 printing.

### 162 3. Lapidus Surgery

163 After exposing the TMT (tarsometatarsal) joint completely by a medial longitudinal incision and  
164 capsulotomy, the custom jig will be set on the surface at the planned bone resection site. The surgeon  
165 will hold the jig against the bone by manual pressure. An oscillating saw will then remove the bone  
166 segment from the medium cuneiform and the base of the 1st metatarsal according to the jig-based  
167 guidance (figure 4). The free remaining bone segment will be adjusted to a normal alignment and be  
168 compressed for fusion. The Lapidus arthrodesis will be fixed with two 3.5mm cross-joint headless  
169 compression screws. In addition, an arthroscopic assisted lateral soft tissue release with a fluoroscopic  
170 assisted bunionectomy will be performed. (1, 25, 26)

171

172 For the control group, fluoroscopic assisted open arthrodesis, a fixation with two 3.5mm cross-joint  
173 headless compression screws as per routine, and a pairing with an arthroscopic assisted lateral soft tissue  
174 release with a fluoroscopic assisted bunionectomy as in the intervention group shall be performed..

175

176 Both groups will undergo the same rehabilitation - 2 weeks of non-weight bearing walking(25) followed  
177 by 10 weeks of heel walking using a sandal.

178 **Outcomes** (Timeline of the outcomes, please refer to consort diagram)

179 **Primary outcomes:**

180 1. Foot and Ankle Outcome Score (FAOS)

181 FAOS is a reliable and validated patient-reported questionnaire widely used in clinical settings. It  
182 consists of five subscales: pain, symptoms, activities of daily living, ability to perform sports and  
183 recreational activities and quality of life.(2) The score of each part is recorded on a 0–100 scale, with  
184 100 representing no symptoms. Chinese FAOS has passed all its validity and reliability. (27)

185 2. X-ray feet:

186 Lateral and dorsal-plantar foot X-rays shall be ordered to investigate if there are any trabeculations  
187 crossing the fusion site. Should there be trabeculation extending more than 1½ of the fusion site, this  
188 shall be a successful union.

189 3. High-resolution peripheral quantitative- Computed Tomography (HR pQCT)

190 This allows us to visualise the bony micro-architecture at the fusion site and is a more accurate  
191 investigation of bone growth evaluation compared to traditional X-rays.(7) With a region of interest at  
192 the fusion site, both inner callus and external callus, the volumetric changes in bone mineral density in  
193 the area mentioned above shall be further analysed.

194

195 **Secondary Outcomes:**

196 4. Deformity severity:

197 1,2 intermetatarsal angle (IMA) and hallux valgus angle (HVA) will be measured using dorsal-planar  
198 weight-bearing X-rays. By drawing an angle from lines bisecting both the 1<sup>st</sup> and 2<sup>nd</sup> metatarsal bone

199 shaft, we will have IMA. On the other hand, by calculating the angle between 1<sup>st</sup> metatarsal bone shaft  
200 and 1<sup>st</sup> proximal phalanx shaft, we can derive the HVA angle.

#### 201 5. Delayed-union rate

202 Delayed union was defined as greater than 50% lucency on either the AP and lateral radiographs or  
203 broken hardware at the fusion site at 12 weeks post-surgery. If lucency, sclerosis, or lack of trabeculation  
204 extended more than one-half the length of the fusion site on either the A-P or lateral radiograph, a  
205 radiographic delayed union was declared (28).

#### 206 6. Non-union rate

207 Non-union was defined as greater than 50% lucency on either the AP and lateral radiographs or broken  
208 hardware at the fusion site at 26 weeks post-surgery. If lucency, sclerosis, or lack of trabeculation  
209 extended more than one-half the length of the fusion site on either the A-P or lateral radiograph, a  
210 radiographic non-union was declared (28).

#### 211 7. Plantar pressure distribution

212 It has been demonstrated that plantar pressure distribution is highly related to foot biomechanics (29),  
213 and plenty of previous work has investigated the change of pressure distribution in HV patients (30, 31).  
214 Variation has been found between HV and normal populations. More importantly, this deviation of  
215 pressure may lead to transferred pain, namely, metatarsalgia. Considering the potential influence of  
216 shortened metatarsal after Lapidus and consequential changed foot biomechanics, the plantar pressure  
217 distribution is worthwhile observing in HV patients who receive Lapidus procedure.

218 The Tekscan Matscan (Tekscan Inc., Boston MA) system will be used to measure the plantar pressure at  
219 different anatomical regions during the gait cycle. The sampling frequency of the map will be set as 40  
220 Hz, which is considered sufficient for such data collection (32). Patients will be asked to walk at a self-  
221 selected speed across the mat. The two-step method will be adopted, meaning participants will step on  
222 the pressure map on the second step (32). The scan will then be masked, and the foot will be divided into  
223 eight regions: the hallux, lesser toes, lateral and medial forefoot, lateral and medial midfoot, and lateral  
224 and medial hindfoot (33). Peak pressure and impulse in each region will be calculated to see the before-  
225 and-after change. Additionally, the centre of pressure excursion index (CPEI) will also be calculated,  
226 reflecting the excursion of the centre of pressure. The first and last points of a centre of pressure curve  
227 will be connected to construct a line measured in the distal tertile of the foot and normalised by the foot's  
228 width (34).



229 8. Intraoperative complications

230 All intra-operative complications will be recorded and documented.

231 Ethical approval will be sought from the ethical committee from the Chinese University of Hong Kong.

232 At the beginning of each experiment, the research purpose and the experimental procedures will be

233 clearly explained to the participants, and they will be asked to sign a Consent Form before being tested.

#### 234 **Timeline**

##### 235 **Baseline assessment**

236 All the patients will come to the clinic and receive the assessment one week before their operation date.

##### 237 **Post-operation assessment**

238 All the patients will return for the assessment at 0 weeks, 2 weeks, 6 weeks, 12 weeks, 26 weeks and 52

239 weeks post-operation. (Refer to consort diagram attached)

240

#### 241 **Statistics**

242 For all the primary and second outcomes, an independent t-test will be used to compare the difference

243 between the PSI and the control groups. Repeated measured ANOVA will be used to investigate the

244 changes over time at pre-surgery, 0-week, 12-week, 26-week and 1-year post surgery in the PSI group.

#### 245 **Data monitoring**

246 A research assistant (both reporting directly to the principal investigator) will be responsible for data

247 collection while the principal investigator will be responsible for data analysis. The principal investigator

248 himself will make decisions to terminate the trial if needed.

249

#### 250 **Ethics and dissemination**

251 Research ethics application will be submitted to The Joint Chinese University of Hong Kong – New

252 Territories East Cluster Clinical Research Ethics Committee (The Joint CUHK-NTEC CREC).

253

#### 254 **Consent**

255 The principal investigator or co-investigators will obtain informed consent from participants.

256

257 **Confidentiality**

258 All collected personal data and medical information relevant to this study about the subjects will be  
259 strictly confidential. Subjects will only be identified by a study number and initials in the study database,  
260 and no personal identity will be disclosed when study results are being reported and/or published. The  
261 data can be accessed only by the principal investigator, co-investigators and the research assistant(s) in  
262 charge.

263 **Author's contributions:**

264 SKKL is the main contributor to the design, surgery and analysis of the data. RXW, ECSC, BHC, PPYL,  
265 MTYO helped design and engineer the PSI implant as well as draft the proposal. PSHY will oversee the  
266 study.

267 **Funding statement:**

268 This work has been funded by the Health and Medical Research Fund, Health Bureau, the Government  
269 of the Hong Kong SAR (Ref 09202926).

270 **Declaration of interests**

271 The authors declare that they have no conflict of interest.

272

273 Word count: 2500

274

275 **Reference**

276

- 277 1. Ling SKK, Lui TH. Arthroscopic-Assisted Correction of Hallux Valgus Deformity. Cham:  
278 Springer International Publishing; 2016. p. 803-9.
- 279 2. Ling SKK, Lui TH. Endoscopy-Assisted Hallux Valgus Correction Provides Sustainable  
280 Long-Term >10-Year Outcomes. Arthroscopy: The Journal of Arthroscopic & Related Surgery.  
281 2018;34(6):1958-63.
- 282 3. Coughlin MJ, Jones CP. Hallux Valgus: Demographics, Etiology, and Radiographic

- 283 Assessment. *Foot & Ankle International*. 2007;28(7):759-77.
- 284 4. Rush SM, Christensen JC, Johnson CH. Biomechanics of the first ray. Part II: Metatarsus  
285 primus varus as a cause of hypermobility. A three-dimensional kinematic analysis in a cadaver  
286 model. *The Journal of Foot and Ankle Surgery*. 2000;39(2):68-77.
- 287 5. Coughlin MJ, Jones CP. Hallux Valgus and First Ray Mobility: A Prospective Study. *JBJS*.  
288 2007;89(9):1887-98.
- 289 6. Dayton P, Kauwe M, Feilmeier M. Is Our Current Paradigm for Evaluation and  
290 Management of the Bunion Deformity Flawed? A Discussion of Procedure Philosophy Relative  
291 to Anatomy. *The Journal of Foot and Ankle Surgery*. 2015;54(1):102-11.
- 292 7. Wei RX, Ko VM-C, Chui EC-S, Fu BS-C, Hung VW-Y, Yung PS-H, et al. Investigation on  
293 the site of coronal deformities in Hallux valgus. *Sci Rep [Internet]*. 2023 2023/02; 13(1):[1815  
294 p.]. Available from: <http://europepmc.org/abstract/MED/36725901>
- 295
- 296 8. Faber FWM, Mulder PGH, Verhaar JAN. Role of First Ray Hypermobility in the Outcome  
297 of the Hohmann and the Lapidus Procedure: A Prospective, Randomized Trial Involving One  
298 Hundred and One Feet. *JBJS*. 2004;86(3):486-95.
- 299 9. Buddecke DE, Reese ER, Prusa ER. Revision of Malaligned Lapidus and Nonunited  
300 Lapidus. *Clinics in Podiatric Medicine and Surgery*. 2020;37(3):505-20.
- 301 10. McInnes BD, Bouché RT. Critical evaluation of the modified lapidus procedure. *The*  
302 *Journal of Foot and Ankle Surgery*. 2001;40(2):71-90.
- 303 11. Petratos DV, Anastasopoulos JN, Plakogiannis CV, Matsinos GS. Correction of  
304 adolescent hallux valgus by proximal crescentic osteotomy of the first metatarsal. *Acta*

- 305 Orthopædica Belgica. 2008;74(4):496-502.
- 306 12. Nakagawa S, Fukushi J-i, Nakagawa T, Mizu-Uchi H, Iwamoto Y. Association of  
307 metatarsalgia after hallux valgus correction with relative first metatarsal length. Foot & Ankle  
308 International. 2016;37(6):582-8.
- 309 13. Wagner P, Wagner E. Role of coronal plane malalignment in hallux valgus correction. Foot  
310 and Ankle Clinics. 2020;25(1):69-77.
- 311 14. Won H-J, Oh C-S. Variations of the plantar tarsometatarsal ligaments. Clin Anat.  
312 2019;32(5):699-705.
- 313 15. Rengier F, Mehndiratta A, von Tengg-Kobligk H, Zechmann CM, Unterhinninghofen R,  
314 Kauczor HU, et al. 3D printing based on imaging data: review of medical applications.  
315 International Journal of Computer Assisted Radiology and Surgery. 2010;5(4):335-41.
- 316 16. Jones GG, Jaere M, Clarke S, Cobb J. 3D printing and high tibial osteotomy. EFORT Open  
317 Rev. 2018;3(5):254-9.
- 318 17. Kim HN, Liu XN, Noh KC. Use of a real-size 3D-printed model as a preoperative and  
319 intraoperative tool for minimally invasive plating of comminuted midshaft clavicle fractures.  
320 Journal of Orthopaedic Surgery and Research. 2015;10(1):91.
- 321 18. Helguero CG, Kao I, Komatsu DE, Shaikh S, Hansen D, Franco J, et al. Improving the  
322 accuracy of wide resection of bone tumors and enhancing implant fit: A cadaveric study. Journal  
323 of Orthopaedics. 2015;12:S188-S94.
- 324 19. Cai H, Liu Z, Wei F, Yu M, Xu N, Li Z. 3D Printing in Spine Surgery. Adv Exp Med Biol.  
325 2018;1093:345-59.
- 326 20. Duan X, Fan HQ, Wang FY, He P, Yang L. Application of 3D-printed Customized Guides

- 327 in Subtalar Joint Arthrodesis. *Orthop Surg*. 2019;11(3):405-13.
- 328 21. Giovinco NA, Dunn SP, Dowling L, Smith C, Trowell L, Ruch JA, et al. A Novel  
329 Combination of Printed 3-Dimensional Anatomic Templates and Computer-assisted Surgical  
330 Simulation for Virtual Preoperative Planning in Charcot Foot Reconstruction. *The Journal of*  
331 *Foot and Ankle Surgery*. 2012;51(3):387-93.
- 332 22. Chen L, Lyman S, Do H, Karlsson J, Adam SP, Young E, et al. Validation of Foot and  
333 Ankle Outcome Score for Hallux Valgus. *Foot & Ankle International*. 2012;33(12):1145-55.
- 334 23. Sierevelt IN, van Eekeren IC, Haverkamp D, Reilingh ML, Terwee CB, Kerkhoffs GM.  
335 Evaluation of the Dutch version of the Foot and Ankle Outcome Score (FAOS):  
336 Responsiveness and Minimally Important Change. *Knee Surg Sports Traumatol Arthrosc*.  
337 2016;24(4):1339-47.
- 338 24. Schulz KF, Grimes DA. Generation of allocation sequences in randomised trials: chance,  
339 not choice. *The Lancet*. 2002;359(9305):515-9.
- 340 25. Ling SKK, Wu Y-M, Li C, Lui TH, Yung PS-H. Randomised control trial on the optimal  
341 duration of non-weight-bearing walking after hallux valgus surgery. *Journal of Orthopaedic*  
342 *Translation*. 2020;23:61-6.
- 343 26. Ling SKK, Lui TH, Yung PSH. Arthroscopic Lateral Soft Tissue Release for Hallux Valgus.  
344 *The Journal of Foot and Ankle Surgery*. 2020;59(1):210-2.
- 345 27. Ling SKK, Chan V, Ho K, Ling F, Lui TH. Reliability and validity analysis of the open-source  
346 Chinese Foot and Ankle Outcome Score (FAOS). *Foot (Edinb)*. 2018;35:48-51.
- 347 28. Mani SB, Lloyd EW, MacMahon A, Roberts MM, Levine DS, Ellis SJ. Modified Lapidus  
348 Procedure with Joint Compression, Meticulous Surface Preparation, and Shear-Strain-

- 349 Relieved Bone Graft Yields Low Nonunion Rate. *HSS J.* 2015;11(3):243-8.
- 350 29. Stolwijk NM, Keijsers NLW, Pasma JH, Nanhoe-Mahabier W, Duysens J, Louwerens JWK.  
351 Treatment of metatarsalgia based on claw toe deformity through soft tissue release of the  
352 metatarsophalangeal joint and resection of the proximal interphalangeal joint: Evaluation based  
353 on foot kinematics and plantar pressure distribution. *Foot and Ankle Surgery.* 2020;26(7):755-  
354 62.
- 355 30. Hida T, Okuda R, Yasuda T, Jotoku T, Shima H, Neo M. Comparison of plantar pressure  
356 distribution in patients with hallux valgus and healthy matched controls. *Journal of Orthopaedic*  
357 *Science.* 2017;22(6):1054-9.
- 358 31. Martínez-Nova A, Sánchez-Rodríguez R Fau - Pérez-Soriano P, Pérez-Soriano P Fau -  
359 Llana-Belloch S, Llana-Belloch S Fau - Leal-Muro A, Leal-Muro A Fau - Pedrera-Zamorano JD,  
360 Pedrera-Zamorano JD. Plantar pressures determinants in mild Hallux Valgus. *Gait & Posture.*  
361 2010;32(3):425-7.
- 362 32. Zammit GV, Menz HB, Munteanu SE. Reliability of the TekScan MatScan®system for the  
363 measurement of plantar forces and pressures during barefoot level walking in healthy adults.  
364 *Journal of Foot and Ankle Research.* 2010;3(1):11.
- 365 33. Galica AM, Hagedorn TJ, Dufour AB, Riskowski JL, Hillstrom HJ, Casey VA, et al. Hallux  
366 valgus and plantar pressure loading: the Framingham foot study. *Journal of Foot and Ankle*  
367 *Research.* 2013;6(1):42.
- 368 34. Song J, Hillstrom HJ, Secord D, Levitt J. Foot type biomechanics. comparison of planus  
369 and rectus foot types. *J Am Podiatr Med Assoc.* 1996;86(1):16-23.

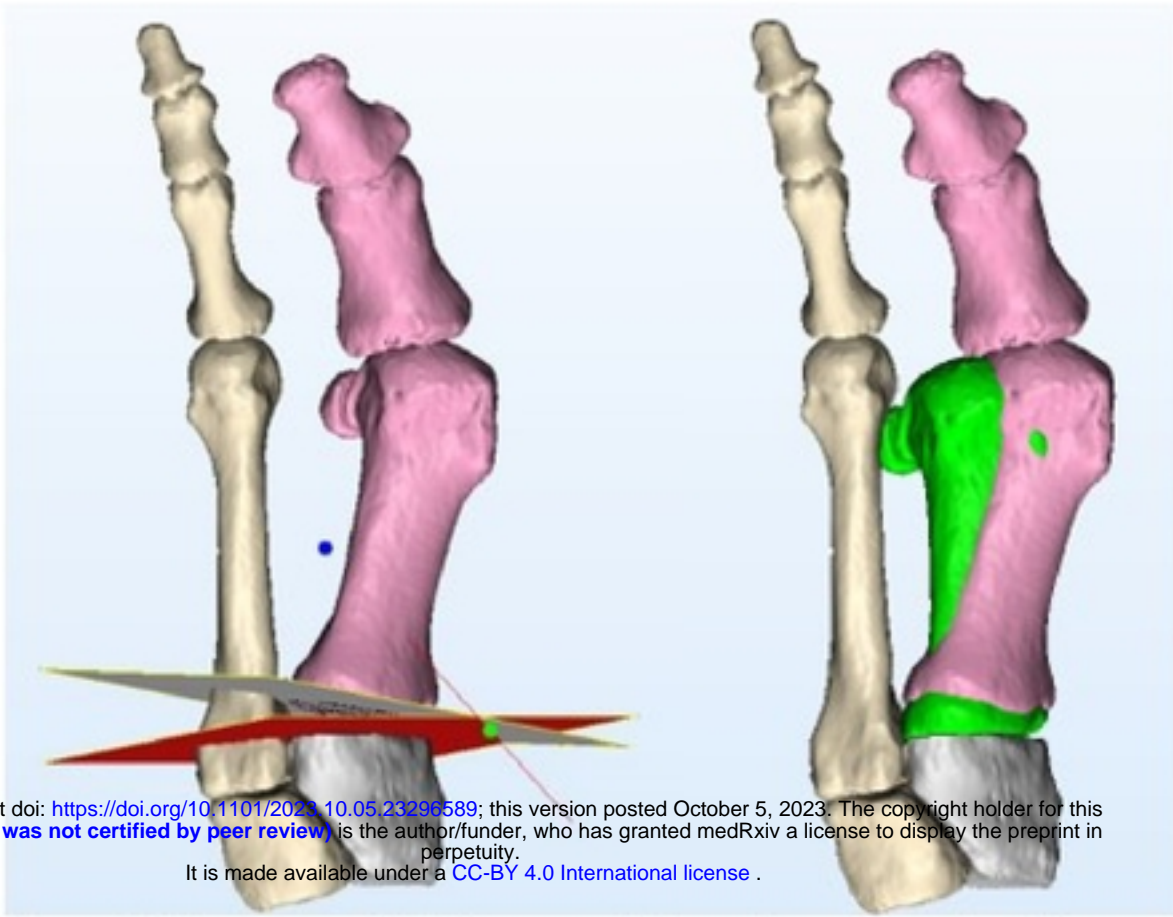
Figure 1. Spirit schedule

	Enrolment	Intervention	Post-allocation					Close-out
TIMEPOINT**	0 week	0 week	2 week	6 week	12 week	26 week	52 week	53 week
<b>ENROLMENT:</b>								
Eligibility screen	X							
Informed consent	X							
		↔						
<b>ASSESSMENTS:</b>								
<i>[Deformity]</i>	X		X	X	X	X	X	
<i>[Computed tomography]</i>				X				
<i>[FAOS]</i>	X				X	X	X	
<i>[X-ray: delay union]</i>					X			
<i>[X-ray: non-union]</i>						X		
<i>[Plantar pressure distribution]</i>	X					X	X	
<i>Data analysis</i>								X

medRxiv preprint doi: <https://doi.org/10.1101/2023.10.05.23296589>; this version posted October 5, 2023. The copyright holder for this preprint (which was not certified by peer review) is the author/funder, who has granted medRxiv a license to display the preprint in perpetuity. It is made available under a [CC-BY 4.0 International license](https://creativecommons.org/licenses/by/4.0/).

\*Recommended content can be displayed using various schematic formats. See SPIRIT 2013 Explanation and Elaboration for examples from protocols.

\*\*List specific timepoints in this row.



medRxiv preprint doi: <https://doi.org/10.1101/2023.10.05.23296589>; this version posted October 5, 2023. The copyright holder for this preprint (which was not certified by peer review) is the author/funder, who has granted medRxiv a license to display the preprint in perpetuity. It is made available under a [CC-BY 4.0 International license](#) .

**Figure 2: Segmented CT images with cutting plane planning and anticipated final position (green)**



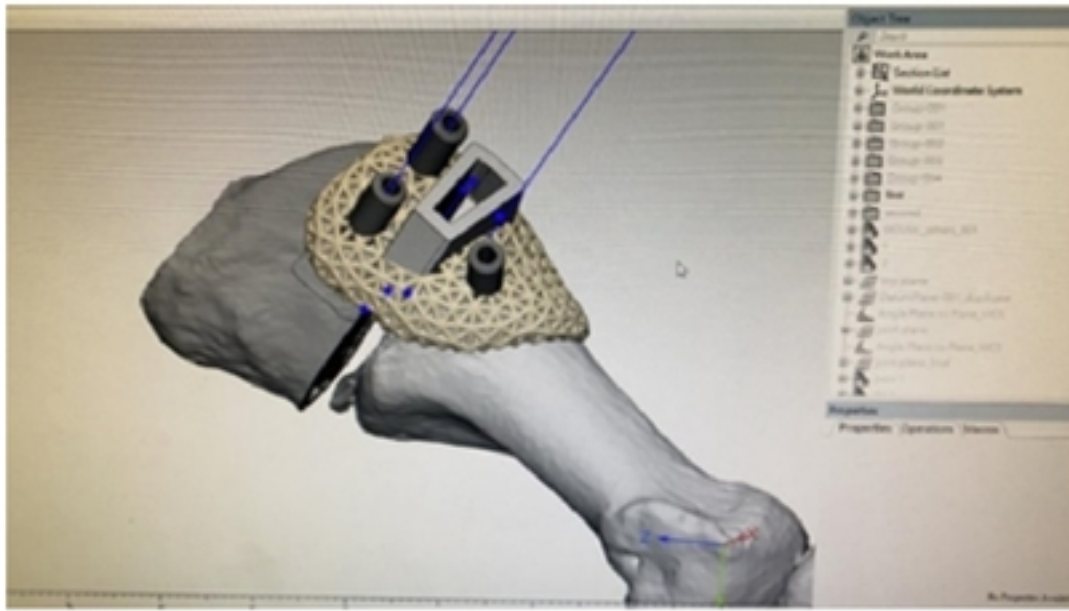
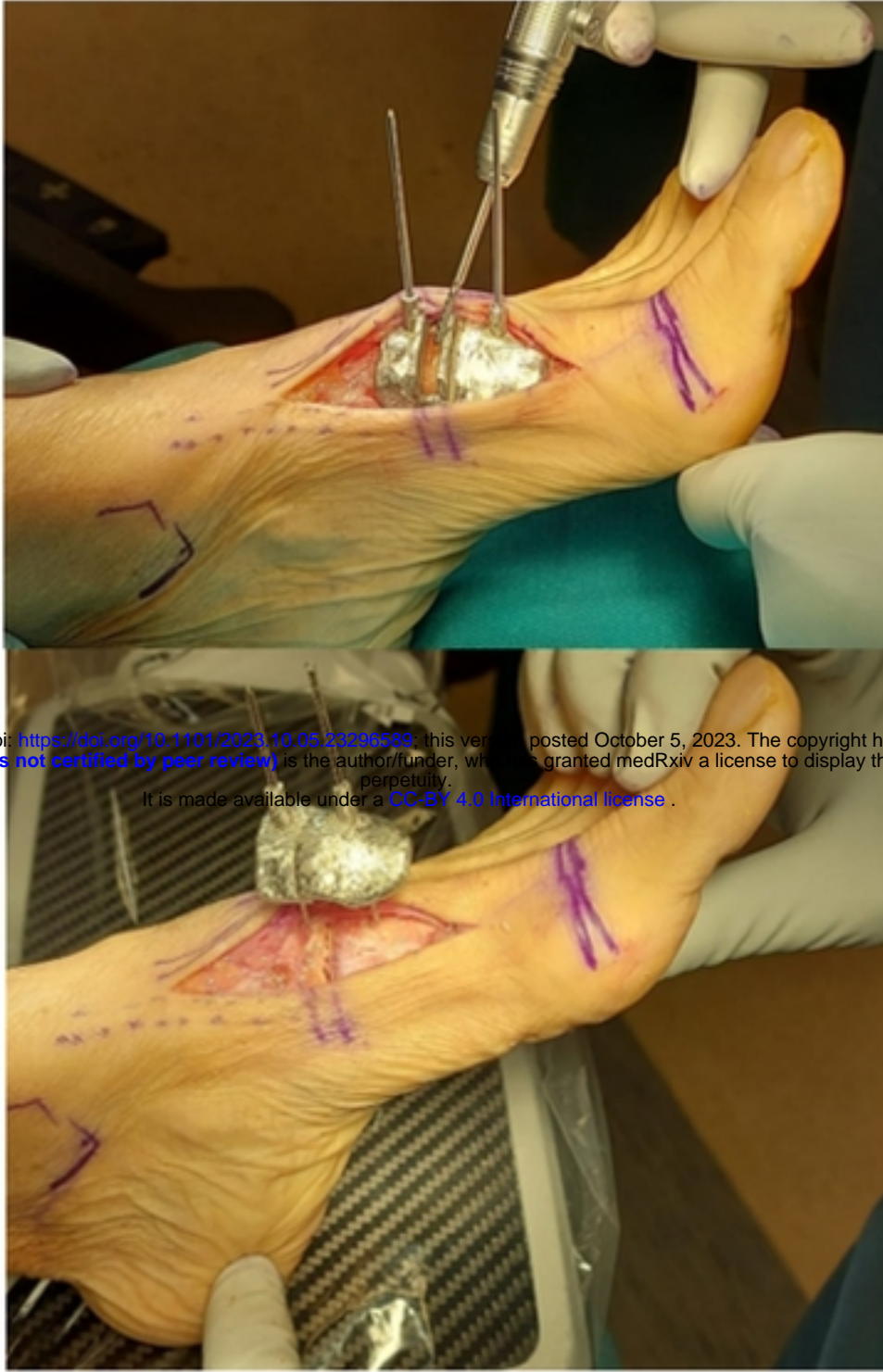

Figure 3: Design of cutting jig

medRxiv preprint doi: <https://doi.org/10.1101/2023.10.05.23296589>; this version posted October 5, 2023. The copyright holder for this preprint (which was not certified by peer review) is the author/funder, who has granted medRxiv a license to display the preprint in perpetuity. It is made available under a [CC-BY 4.0 International license](https://creativecommons.org/licenses/by/4.0/).



medRxiv preprint doi: <https://doi.org/10.1101/2023.10.05.23290589>; this version posted October 5, 2023. The copyright holder for this preprint (which was not certified by peer review) is the author/funder, who has granted medRxiv a license to display the preprint in perpetuity. It is made available under a [CC-BY 4.0 International license](https://creativecommons.org/licenses/by/4.0/).

Figure 4: (top) Intraoperative photo of arthrodesis site preparation with a side cutting burr through the “cutting jig”. (bottom) Intraoperative photo showing good compression at the arthrodesis site after application of the “fixation jig”.