

Human *Paenibacillus* Infections: A Systematic Review with Comparison of Adult and Infant Cases

Danielle Smith¹, Kristen Bastug², Kathy Burgoine³, James R. Broach⁴, Christine Hehnly⁵, Sarah U. Morton⁵, Marwan Osman⁶, Steven J. Schiff⁶, Jessica E. Ericson¹

¹Department of Pediatrics, Penn State College of Medicine, Hershey, USA; ²Department of Pediatrics, University of Minnesota, Minneapolis, USA; ³Mbale Regional Referral Hospital, Mbale, Uganda; ⁴Department of Biochemistry, Penn State University, Hershey, USA; ⁵Department of Pediatrics, Boston Children's Hospital and Harvard University, Boston, USA; ⁶Department of Neurosurgery, Yale University, New Haven, USA

All authors have seen and approved the final version of the manuscript.

All authors have no conflicts of interest related to the content of the manuscript.

Data availability: All data produced in the present work are contained in the manuscript.

Funding: This study was funded by the National Institutes of Health under NIH Director's Pioneer Award 1DP1HD086071 (S.J.S) and NIH Director's Transformative Award 1R01AI145057 (S.J.S). J.E.E. was supported by the National Center for Advancing Translational Sciences, National Institutes of Health, through Grant UL1TR002014. The content is solely the responsibility of the authors and does not necessarily represent the official views of the NIH.

Abstract

Neonatal infections due to *Paenibacillus species* have increasingly been reported over the last few years. We performed a structured literature review of human *Paenibacillus* infections in infants and adults to compare the epidemiology of infections between these distinct patient populations. Thirty-nine reports describing 176 infections met our inclusion criteria and were included. There were 37 *Paenibacillus* infections occurring in adults caused by 23 species. The clinical presentations of infections were quite variable. In contrast, infections in infants were caused by only 3 species: *P. thiaminolyticus* (112/139, 80%), *P. alvei* (2/139, 1%) and *P. dendritiformis* (2/139, 1%). All of the infants with *Paenibacillus* infection presented with a sepsis syndrome or meningitis, often complicated by extensive cerebral destruction and hydrocephalus. Outcomes were commonly poor with 17% (24/139) mortality. Cystic encephalomalacia due to brain destruction was common in both Ugandan and American cases and 92/139 (66%) required surgical management of hydrocephalus following their infection. *Paenibacillus* infections are likely underappreciated in infants and effective treatments are urgently needed.

Neonatal sepsis is a rare but devastating disease affecting infants worldwide.¹ Over 2 million deaths occur each year and even for survivors of neonatal sepsis, sequelae include neurodevelopmental delays, hearing impairment, seizure disorders and hydrocephalus.² The etiology of neonatal sepsis often remains unknown especially in low-resource settings.³ Bacterial culture of the blood and spinal fluid sometimes identifies the causative pathogen but is limited by: 1) access to laboratory facilities that can perform cultures; 2) reduced sensitivity of culture results due to community-based antibiotic administration prior to culture collection; or 3) inability to grow the causative pathogen due to the growth requirements of the organism. Technologic advances in molecular diagnostics have enabled improved detection and identification of microbial organisms in patient specimens throughout the world. Organisms previously considered environmental contaminants that are identified in patients who are critically ill could represent emerging pathogens, particularly in high-mortality illnesses such as neonatal sepsis.

In our long-term effort to identify the etiology of neonatal sepsis, meningitis and their much feared sequela of postinfectious hydrocephalus in Uganda, we identified *Paenibacillus* species to be both the most commonly identified genera in infants with postinfectious hydrocephalus⁴ and also present in 6% of neonates with clinical sepsis.⁵ Further, we have found that *Paenibacillus* species are variably detected by standard aerobic microbial culture, likely due to high requirements for thiamine in growth media.⁶ Since 2021, there have been increasing reports of paenibacillosis in infants in the United States with severe sequelae occurring in most published cases. *Paenibacillus* may represent an unrecognized cause of global neonatal sepsis, meningitis and postinfectious hydrocephalus.

Paenibacillus species are spore-forming facultative anaerobic Gram-variable rods. *Paenibacillus* was first described in the early 1990s as a separate genus from *Bacillus*, which was previously thought to encompass these bacteria.⁷ These organisms were historically

believed to be primarily opportunistic, causing infection only in those who were immunocompromised or using illicit intravenous drugs.⁸ Subsequent case reports have suggested that a broader population, including infants, is at risk for severe infection. We performed a structured literature review of human *Paenibacillus* infections in infants and adults to compare the epidemiology of infections between these distinct patient populations.

Methods

Using Pubmed, we used the search term “*Paenibacillus* infection” limited to human studies to identify manuscripts for review. The authors reviewed papers to confirm that they were about a human infection; those found to describe infections of a plant or insect were excluded as were those describing identification of the organism from environmental samples. The references of included papers were reviewed for additional papers meeting our inclusion criteria. Finally, because the *Paenibacillus* genus was reclassified from the *Bacillus* genus, we also searched for each *Paenibacillus* species using *Bacillus* in place of *Paenibacillus*. Patient-level data from full-text papers confirmed to be about human infection due to a *Paenibacillus* species were abstracted from each paper using a structured data collected instrument in Excel (Microsoft, Redmond, WA, USA).

Results

Our search terms identified 84 papers for review (Figure 1). After review, 63 were excluded: 4 were not about *Paenibacillus*, 6 described *Paenibacillus* infections of plants or insects, 12 described isolation of *Paenibacillus* from the environment, 26 described *in vitro* studies of the bacteria, mostly related to its antimicrobial properties against other pathogens; 6 noted the presence of *Paenibacillus* as part of the human microbiome but were not about infection; 4 did not provide patient-level data; 2 discussed the role of *Paenibacillus* in food

spoilage; 2 did not have full text versions of the manuscript available for review and were excluded. One additional paper included patients that were described in more detail elsewhere and was excluded. Twenty-one papers remained that described *Paenibacillus* infection in humans. Review of the references of these papers identified an additional 16 papers meeting our inclusion criteria and searches for each species using *Bacillus* as the genus identified an additional 2 cases. We ultimately included 176 cases of *Paenibacillus* infection, 37 in adults and 139 in infants. Cases in adults occurred sporadically over time; most cases in infants have been reported in the last 3 years (Figure 2).

We identified 30 reports describing 37 *Paenibacillus* infections occurring in adults. Cases caused by 23 species were reported from 15 countries spanning 4 continents (Europe, n=21; Asia, n=8; North America, n=7, and South America, n=1) (Table 1). Surprisingly, there were no reports from Africa of *Paenibacillus* infections occurring in an adult; 27/37 (73%) were from developed countries, where laboratory technologies and other aspects of healthcare delivery are well established. The clinical presentations of the infections were also quite variable and included 16 bloodstream infections⁸⁻¹⁷, 3 of which occurred in the setting of endocarditis^{14,15,17} and 1 related to a dialysis catheter¹³; 8 wound infections¹⁸⁻²⁵, 3 of which involved the bone^{19,20,23} and 1 involved a breast implant¹⁸; 3 central nervous system infections²⁶⁻²⁸ including 2 with a brain abscess^{26,28}; 2 urinary tract infections^{27,29}; 3 lung infections³⁰⁻³²; 2 joint infections^{33,34} one of which involved a prosthetic hip³⁴; and 1 each of keratitis³⁵, gingivitis³⁶, superficial skin abscess³⁷. There was a single death reported in a 55-year-old Korean man who developed *P. pasadensis* bacteremia following clipping of an intracranial aneurysm.¹¹ His postoperative course was complicated by acute respiratory distress syndrome and he was intubated and mechanically ventilated for nearly two weeks before decompensating. Six of 6 blood cultures grew *P. pasadensis* and, due to the severity of his illness and complications that had already occurred prior to developing bacteremia, the focus of his care became palliative and he died a few days

later. Three patients had a recurrence of their infection but were ultimately cured following repeat or long-term antibiotic therapy; the remaining 31 patients recovered. Interestingly, the 2 patients with brain abscess due to *P. lactis* and *P. macerans* fully recovered and had no neurologic sequelae after being treated with vancomycin, meropenem and metronidazole for an unknown duration and for 6 weeks, respectively.^{26,28}

One hundred and thirty-nine *Paenibacillus* infections in infants were reported in 9 papers. They included two separate Ugandan cohorts previously described by our group^{4,5} and 6 single case reports from throughout the United States (Table 2).³⁸⁻⁴⁴ In contrast to the infections occurring in adults, *Paenibacillus* infections in infants were caused by only 3 species: *P. thiaminolyticus* (112/139, 80%), *P. alvei* (2/139, 1%) and *P. dendritiformis* (2/139, 1%). An additional 25/139 (18%) were identified only to the genus level. All of the infants with *Paenibacillus* infection presented with a sepsis syndrome with or without clinical signs of meningitis, or with confirmed meningitis, often complicated by extensive cerebral destruction and hydrocephalus. Outcomes were commonly poor with 17% (24/139) mortality. Cystic encephalomalacia due to brain destruction was common in both Ugandan and American cases and 92/139 (66%) required surgical management of hydrocephalus following their infection. We have additionally received personal communications about 2 additional neonates with sepsis due to *Paenibacillus*, one from Minnesota and one from Maryland. One presented in extremis, was intubated and received extra corporeal support but succumbed to the illness within 2 days. Blood culture grew *Paenibacillus species*; CSF culture was not performed due to the infant's critical illness. The other infant was unexpectedly delivered at home with unknown gestational age, thought to be term with a birthweight of 4082 grams. Maternal toxicology screen was positive for amphetamines, methamphetamines, and tetrahydrocannabinol. The infant developed tachypnea on day of life 1 and had an elevated C-reactive protein of 5.8 mg/L. Blood culture grew *Paenibacillus species*. Lumbar puncture was not performed due to caregiver

decision. The infant remained clinically stable and was treated with 8 days of gentamicin; he was discharged in stable condition at 13 days old with no appreciable neurologic sequelae.

Discussion

Based on rRNA homology and a distinct phenotypic cluster of *Bacillus*, the *Paenibacillus* genus was split off from *Bacillus* in 1993.⁷ Since then, it has generally been considered an environmental commensal with little concern for its role as a pathogen. There has been some interest in the genus for its ability to produce antibacterial compounds such as paenibacterin, a novel cyclic lipopeptide, which have activity against *Staphylococcus aureus*, *Pseudomonas aeruginosa*, and *Escherichia coli*.⁴⁵⁻⁴⁷ More recently, the possibility that *Paenibacillus* may be a useful probiotic with agricultural,⁴⁸⁻⁵⁰ aquacultural,^{51,52} and human⁵³ applications has even been considered.

Paenibacillus growth on culture has sometimes been found to be due to contamination.⁵⁴ We sought to compile all of the reports of human disease caused by *Paenibacillus* species to evaluate its role as a human pathogen. In doing so, we found that adult cases seem to be sporadic with no single clinical syndrome or species emerging as characteristic. Adult infections tended to occur in patients with comorbidities, indwelling hardware such as prosthetic joints or pacemakers, and were effectively treated with standard antibiotics in most cases. A single death was reported related to a *Paenibacillus* infection in an adult.¹¹ This was in marked contrast to *Paenibacillus* infections in infants where most infections were due to *P. thiaminolyticus* and severe disease was common. Death occurred in 17% of cases and extensive destruction of the brain was common. Notably, there have been only two reported cases (5.4%) of *P. thiaminolyticus* in adults, with the bacteria isolated from the blood and the wounds of two patients in the United States and Switzerland, respectively.^{13,25} The current study is potentially limited by publication bias such that many clinical cases may not be reported in the literature.

However, the pattern of reports suggests that *Paenibacillus* species' cause a different pattern of illness in infants compared to older patients.

Interestingly, most cases in infants have been published within the last 3 years. This may be due to improvements in diagnostic technology: bacterial identification methods that use biochemical tests may misidentify *Paenibacillus* as a "*Bacillus* species" or otherwise be unable to resolve the bacterial identification down to the genus level. Now that more clinical laboratories are using matrix assisted laser desorption ionization-time of flight (MALDI-TOF) systems for pathogen identification, and the databases that underly this technology's ability to identify pathogens has become more robust over time, specimens that were previously identified only as a Gram-positive rod, *Bacillus* or *Bacillus*-like bacteria are now properly being identified as *Paenibacillus* species. Another possible explanation is that changes in environmental ecology or other risk factors lead to more *Paenibacillus* infections than before. If the latter is true, then *P. thiaminolyticus*, and other *Paenibacillus* species, may represent emerging pathogens among infants.

Optimal treatment is not currently known, and attempts to use standard therapies in reported cases have frequently resulted in poor outcomes. Clinical trials to determine optimal antibiotic therapy of *Paenibacillus* neonatal sepsis and *Paenibacillus* central nervous system infections in infants are urgently needed. Because *P. thiaminolyticus* predominates as the cause of neonatal paenibacillosis, adjunctive therapies such as thiamine supplementation may also be helpful.⁴³ Thiamine deficiency has well-described neurologic sequelae (i.e. Wernicke's encephalopathy) which may contribute to the severity of cerebral destruction in neonatal *Paenibacillus* infections.⁵⁵ Supplementation has been proposed as a neuroprotective strategy for infants with hypoxic-ischemic encephalopathy.⁵⁶ It is possible that thiamine supplementation could blunt the effects of local thiamine depletion that may in the brain when *P. thiaminolyticus* produces thiaminase as part of its typical metabolic pathways.⁵⁷ Most of the infants for whom a

treatment regimen was recorded received ampicillin with or without gentamicin. Ceftriaxone was also commonly administered. One American infant who had severe disease at the time of presentation with seizures, infarction of the thalamus and corona radiata, cystic encephalomalacia, venous sinus thrombosis and ultimately required an endoscopic third ventriculostomy for management of hydrocephalus, was found to have appropriate neurodevelopment at age 18 months after being treated with supplemental thiamine and 6 weeks of intravenous meropenem.⁴³ It is not clear whether it was the meropenem, the thiamine or the combination of both that was instrumental in achieving this good outcome.

Importantly, resistance to penicillin, ampicillin, erythromycin and vancomycin was reported for both adult and infant *Paenibacillus* infections. Notably, *Paenibacillus* spp. can exhibit intrinsic resistance to critically important antibiotics due to the natural presence of multiple resistance genes, such as rifampin phosphotransferase (*rph*), chloramphenicol acetyltransferase (*cat*), chloramphenicol–florfenicol resistance (*cfi*), streptogramin B lyase (*vgb*), streptogramin A acetyltransferase (*vat*), and macrolide kinase (*mph*) genes.^{58,59} Antibiotic susceptibility results should be used to guide antimicrobial therapy. Ampicillin and vancomycin, antibiotics commonly used for Gram-positive neonatal infections, are not reliably effective for *Paenibacillus* infection.^{5,15,22,24} Additional caution should be exercised in using ampicillin because some *Paenibacillus* isolates have been shown to have beta-lactamase genes which could confer inducible resistance; the clinical relevance of these genes in human infections is not well established.⁶⁰ Ceftriaxone seems to be susceptible in most human cases but has not been shown to achieve good clinical outcomes and resistance has been noted in environmental isolates.^{5,61} Meropenem has been successfully used in a few cases.⁴³

Changes in environmental ecology, whether due to climate change or other factors, may increase human contact with *Paenibacillus* in the environment. Our work has suggested that neonates with paenibacillosis are more like to have had non-sterile substances applied to their

umbilical stumps.⁵ These neonates often also live in agrarian and herding communities with close contacts with livestock where use of antibiotics may impact antibiotic resistance in environmental reservoirs.^{61,62} An approach to neonatal paenibacilliosis that uses a One Health perspective to understanding the epidemiology, pathogenesis and treatment of this infection is likely to be more successful than one focused entirely on a single aspect of the disease.⁶³

Conclusion

Human infections due to *Paenibacillus* species' have been sporadically reported in adults and have recently been described as causing a distinct clinical syndrome of sepsis, meningitis and multiple brain abscesses leading to cystic encephalomalacia and hydrocephalus in infants that we have termed "neonatal paenibacilliosis". The high mortality and the severity of the sequelae secondary to neonatal paenibacilliosis warrant further and urgent investigation to better understand the mechanisms, risk factors and optimal treatments for this devastating infection. Given the evidence that *Paenibacillus* is an important neonatal pathogen, its use as a probiotic should be avoided until the safety of specific species has been carefully studied. Similarly, widespread application of the organism or its spores in agricultural applications should not be implemented until the pathophysiology of neonatal disease, route of neonatal exposure, prevention strategies and effective treatments are better understood. Neonatal paenibacilliosis requires further investigation in order to elucidate the role of *Paenibacillus* species as a possible emerging pathogen and to define optimal treatments to improve neurodevelopmental outcomes.

References

1. Fleischmann C, Reichert F, Cassini A, et al. Global incidence and mortality of neonatal sepsis: a systematic review and meta-analysis. *Arch Dis Child*. Jan 22 2021;doi:10.1136/archdischild-2020-320217
2. Rosa-Mangeret F, Benski AC, Golaz A, et al. 2.5 Million Annual Deaths-Are Neonates in Low- and Middle-Income Countries Too Small to Be Seen? A Bottom-Up Overview on Neonatal Morbi-Mortality. *Trop Med Infect Dis*. Apr 21 2022;7(5)doi:10.3390/tropicalmed7050064
3. Saha SK, Schrag SJ, El Arifeen S, et al. Causes and incidence of community-acquired serious infections among young children in south Asia (ANISA): an observational cohort study. *Lancet*. 07 2018;392(10142):145-159. doi:10.1016/S0140-6736(18)31127-9
4. Morton SU, Hehnly C, Burgoine K, et al. Paenibacillus spp infection among infants with postinfectious hydrocephalus in Uganda: an observational case-control study. *Lancet Microbe*. Aug 2023;4(8):e601-e611. doi:10.1016/S2666-5247(23)00106-4
5. Ericson JE, Burgoine K, Kumbakumba E, et al. Neonatal Paenibacilliosis: Paenibacillus infection as a Novel Cause of Sepsis in Term Neonates with High Risk of Sequelae in Uganda. *Clin Infect Dis*. Jun 05 2023;doi:10.1093/cid/ciad337
6. Paulson JN, Williams BL, Hehnly C, et al. infection with frequent viral coinfection contributes to postinfectious hydrocephalus in Ugandan infants. *Sci Transl Med*. Sep 2020;12(563)doi:10.1126/scitranslmed.aba0565
7. Ash C, Priest FG, Collins MD. Molecular identification of rRNA group 3 bacilli (Ash, Farrow, Wallbanks and Collins) using a PCR probe test. Proposal for the creation of a new genus Paenibacillus. *Antonie Van Leeuwenhoek*. 1993-1994 1993;64(3-4):253-60. doi:10.1007/BF00873085
8. Rieg S, Martin Bauer T, Peyerl-Hoffmann G, et al. Paenibacillus larvae Bacteremia in injection drug users. *Emerg Infect Dis*. Mar 2010;16(3):487-9. doi:10.3201/eid1603.091457
9. Roux V, Raoult D. Paenibacillus massiliensis sp. nov., Paenibacillus sanguinis sp. nov. and Paenibacillus timonensis sp. nov., isolated from blood cultures. *Int J Syst Evol Microbiol*. Jul 2004;54(Pt 4):1049-1054. doi:10.1099/ijs.0.02954-0
10. Ko KS, Kim YS, Lee MY, et al. Paenibacillus konsidensis sp. nov., isolated from a patient. *Int J Syst Evol Microbiol*. Sep 2008;58(Pt 9):2164-8. doi:10.1099/ijs.0.65534-0
11. Yoon HJ, Yim HW, Ko KS. A Case of Paenibacillus pasadenensis Bacteremia in a Patient with Acute Respiratory Distress Syndrome after Microsurgical Clipping. *Infect Chemother*. Mar 2015;47(1):64-7. doi:10.3947/ic.2015.47.1.64
12. Wenzler E, Kamboj K, Balada-Llasat JM. Severe Sepsis Secondary to Persistent Lysinibacillus sphaericus, Lysinibacillus fusiformis and Paenibacillus amylolyticus Bacteremia. *Int J Infect Dis*. Jun 2015;35:93-5. doi:10.1016/j.ijid.2015.04.016
13. Ouyang J, Pei Z, Lutwick L, et al. Case report: Paenibacillus thiaminolyticus: a new cause of human infection, inducing bacteremia in a patient on hemodialysis. *Ann Clin Lab Sci*. 2008;38(4):393-400.
14. Pinho-Gomes AC, Nasir A, Mosca R, Mirza S, Kadir I. Intraoperative diagnosis of mitral valve endocarditis secondary to Paenibacillus provencensis. *Ann R Coll Surg Engl*. Feb 2017;99(2):e54-e55. doi:10.1308/rcsann.2016.0312
15. Ferrand J, Hadou T, Selton-Suty C, et al. Cardiac device-related endocarditis caused by Paenibacillus glucanolyticus. *J Clin Microbiol*. Oct 2013;51(10):3439-42. doi:10.1128/JCM.00864-13
16. Vecchia ID, Fasan D, Pegoraro M, Benedetti P. Febrile sepsis: first report of human disease due to. *Access Microbiol*. 2023;5(6)doi:10.1099/acmi.0.000580.v3

17. Wu YJ, Hong TC, Hou CJ, Chou YS, Tsai CH, Yang DI. Bacillus popilliae endocarditis with prolonged complete heart block. *Am J Med Sci.* Apr 1999;317(4):263-5. doi:10.1097/00000441-199904000-00010
18. Marchese A, Barbieri R, Pesce M, Franchelli S, De Maria A. Breast implant infection due to Paenibacillus residui in a cancer patient. *Clin Microbiol Infect.* Aug 2016;22(8):743-4. doi:10.1016/j.cmi.2016.05.012
19. Schade M, French CN. Infected Nonunion of the Tibia Due to. *Open Forum Infect Dis.* Jul 2021;8(7):ofab290. doi:10.1093/ofid/ofab290
20. Anikpeh YF, Keller P, Bloemberg GV, Grünenfelder J, Zinkernagel AS. Spacecraft bacterium, Paenibacillus pasadenensis, causing wound infection in humans. *BMJ Case Rep.* Dec 29 2010;2010doi:10.1136/bcr.06.2010.3058
21. Glaeser SP, Falsen E, Busse HJ, Kämpfer P. Paenibacillus vulneris sp. nov., isolated from a necrotic wound. *Int J Syst Evol Microbiol.* Feb 2013;63(Pt 2):777-782. doi:10.1099/ijs.0.041210-0
22. Szaniawski MA, Spivak AM. Recurrent. *Oxf Med Case Reports.* May 2019;2019(5):omz034. doi:10.1093/omcr/omz034
23. Quénard F, Aubry C, Palmieri M, Edouard S, Parola P, Lagier JC. First case of bone infection caused by Paenibacillus turicensis. *New Microbes New Infect.* May 2016;11:45-6. doi:10.1016/j.nmni.2016.02.004
24. de Salazar A, Ferrer F, Vinuesa D, Chueca N, de Luis-Perez C, García F. Unusual case report of skin infection by Paenibacillus timonensis. *Rev Esp Quimioter.* Apr 2020;33(2):139-140. doi:10.37201/req/079.2019
25. Di Micco R, Schneider M, Nüesch R. Postoperative Paenibacillus thiaminolyticus Wound Infection, Switzerland. *Emerg Infect Dis.* 07 2021;27(7):1984-1986. doi:10.3201/eid2707.203348
26. Inkov Kehayov I, Miroslavova Angelova P, Dimitrov Kitov B. Brain abscess caused by Paenibacillus lactis. *J Infect Dev Ctries.* Mar 31 2023;17(3):418-422. doi:10.3855/jidc.17209
27. Roux V, Fenner L, Raoult D. Paenibacillus provencensis sp. nov., isolated from human cerebrospinal fluid, and Paenibacillus urinalis sp. nov., isolated from human urine. *Int J Syst Evol Microbiol.* Mar 2008;58(Pt 3):682-7. doi:10.1099/ijs.0.65228-0
28. Wang J, Fraser JF. An Intracranial Petri Dish? Formation of Abscess in Prior Large Stroke After Decompressive Hemicraniectomy. *World Neurosurg.* Nov 2015;84(5):1495.e5-9. doi:10.1016/j.wneu.2015.05.013
29. Padhi S, Dash M, Sahu R, Panda P. Urinary Tract Infection due to Paenibacillus alvei in a Chronic Kidney Disease: A Rare Case Report. *J Lab Physicians.* Jul 2013;5(2):133-5. doi:10.4103/0974-2727.119872
30. Kim KK, Lee KC, Yu H, Ryoo S, Park Y, Lee JS. Paenibacillus sputi sp. nov., isolated from the sputum of a patient with pulmonary disease. *Int J Syst Evol Microbiol.* Oct 2010;60(Pt 10):2371-2376. doi:10.1099/ijs.0.017137-0
31. Coudron PE, Payne JM, Markowitz SM. Pneumonia and empyema infection associated with a Bacillus species that resembles B. alvei. *J Clin Microbiol.* Sep 1991;29(9):1777-9. doi:10.1128/jcm.29.9.1777-1779.1991
32. Leão RS, Pereira RH, Ferreira AG, Lima AN, Albano RM, Marques EA. First report of Paenibacillus cineris from a patient with cystic fibrosis. *Diagn Microbiol Infect Dis.* Jan 2010;66(1):101-3. doi:10.1016/j.diagmicrobio.2009.06.011
33. Zhang E, Lu H, Liu Q, et al. Paenibacillus assamensis in Joint Fluid of Man with Suspected Tularemia, China. *Emerg Infect Dis.* 08 2018;24(8):1589-1591. doi:10.3201/eid2408.180260
34. Reboli AC, Bryan CS, Farrar WE. Bacteremia and infection of a hip prosthesis caused by Bacillus alvei. *J Clin Microbiol.* Jun 1989;27(6):1395-6. doi:10.1128/jcm.27.6.1395-1396.1989

35. Hassan A, Rampat R, Vasquez-Perez A. Severe Keratitis and Corneal Perforation by *Paenibacillus glucanolyticus*. *Cornea*. Aug 01 2021;40(8):1062-1064. doi:10.1097/ICO.0000000000002584
36. Park SN, Lim YK, Shin JH, et al. *Paenibacillus oralis* sp. nov., Isolated from Human Subgingival Dental Plaque of Gingivitis Lesion. *Curr Microbiol*. Mar 2020;77(3):509-515. doi:10.1007/s00284-019-01843-0
37. Shaalan M, Omer A, Elrih M, Kutty S. *Paenibacillus* Isolated from Superficial Infection of the Left Knee Region in Middle-Aged Man. *Int Arch Orthop Surg*. 2020;3(023)
38. Wiedermann BL. Non-anthrax Bacillus infections in children. *Pediatr Infect Dis J*. Feb 1987;6(2):218-20.
39. DeLeon SD, Welliver RC. *Paenibacillus alvei* Sepsis in a Neonate. *Pediatr Infect Dis J*. Mar 2016;35(3):358. doi:10.1097/INF.0000000000001003
40. Jan M, Hanna I, Maraqa N. *Paenibacillus dendritiformis* hemorrhagic meningoencephalitis in an infant: Case report and literature review. *The Florida Pediatrician*. 2022;(Winter)
41. Tabarani C, Heresi GP, Murphy JR, et al. *Paenibacillus dendritiformis* Meningitis, Brain Abscesses and Cystic Encephalomalacia in an Infant: Case Presentation and Review of the Literature. *Pediatr Infect Dis J*. Dec 01 2022;41(12):e544-e547. doi:10.1097/INF.0000000000003684
42. Hunt B, Rogers C, Blais RM, Adachi K, Sathyavagiswaran L. *Paenibacillus* Sepsis and Meningitis in a Premature Infant: A Case Report. *Am J Forensic Med Pathol*. Mar 01 2021;42(1):96-98. doi:10.1097/PAF.0000000000000610
43. Smallcomb LS, Dixon TC, Azad KN, Marvin WE. A rare case of neonatal meningoencephalitis from *Paenibacillus thiaminolyticus*. *Access Microbiology*. 2022;4(12)
44. Bastug K, Siddappa A, Maroushek S. *Paenibacillus thiaminolyticus* sepsis and meningoencephalitis in a 37-day old preterm infant. *J Case Rep Images Pediatr*. 2023;5(1):16-20.
45. Yi T, Huang Y, Chen Y. Production of an antimicrobial peptide AN5-1 in *Escherichia coli* and its dual mechanisms against bacteria. *Chem Biol Drug Des*. May 2015;85(5):598-607. doi:10.1111/cbdd.12449
46. Cochrane SA, Vederas JC. Lipopeptides from *Bacillus* and *Paenibacillus* spp.: A Gold Mine of Antibiotic Candidates. *Med Res Rev*. Jan 2016;36(1):4-31. doi:10.1002/med.21321
47. Huang E, Yousef AE. *Paenibacterin*, a novel broad-spectrum lipopeptide antibiotic, neutralises endotoxins and promotes survival in a murine model of *Pseudomonas aeruginosa*-induced sepsis. *Int J Antimicrob Agents*. Jul 2014;44(1):74-7. doi:10.1016/j.ijantimicag.2014.02.018
48. Soni R, Nanjani S, Keharia H. Genome analysis reveals probiotic propensities of *Paenibacillus polymyxa* HK4. *Genomics*. Jan 2021;113(1 Pt 2):861-873. doi:10.1016/j.ygeno.2020.10.017
49. McSpadden Gardener BB. Ecology of *Bacillus* and *Paenibacillus* spp. in Agricultural Systems. *Phytopathology*. 2004;94:1252-1258.
50. Moon SG, Kothari D, Lee WD, et al. Potential Probiotic Acceptability of a Novel Strain of *Animals (Basel)*. Jun 06 2022;12(11)doi:10.3390/ani12111471
51. Lin P-H, Chen S-W, Wen Z-H, Hu S-Y. Administration of the Potential Probiotic *Paenibacillus ehimensis* NPUST1 Enhances Expression of Indicator Genes Associated with Nutrient Metabolism, Growth and Innate Immunity against *Aeromonas hydrophila* and *Streptococcus indie* Infections in Zebrafish (*Danio rerio*). *Fishes*. 2022;7(6)
52. Hong HA, Duc IH, Cutting SM. The use of bacterial spore formers as probiotics. *FEMS Microbiol Rev*. Sep 2005;29(4):813-35. doi:10.1016/j.femsre.2004.12.001

53. Elshaghabee FMF, Rokana N, Gulhane RD, Sharma C, Panwar H. As Potential Probiotics: Status, Concerns, and Future Perspectives. *Front Microbiol.* 2017;8:1490. doi:10.3389/fmicb.2017.01490
54. Noskin GA, Suriano T, Collins S, Sesler S, Peterson LR. Paenibacillus macerans pseudobacteremia resulting from contaminated blood culture bottles in a neonatal intensive care unit. *Am J Infect Control.* Apr 2001;29(2):126-9. doi:10.1067/mic.2001.111535
55. Dhir S, Tarasenko M, Napoli E, Giulivi C. Neurological, Psychiatric, and Biochemical Aspects of Thiamine Deficiency in Children and Adults. *Front Psychiatry.* 2019;10:207. doi:10.3389/fpsy.2019.00207
56. Sechi GP, Bardanzellu F, Pintus MC, Sechi MM, Marcialis MA, Fanos V. Thiamine as a Possible Neuroprotective Strategy in Neonatal Hypoxic-Ischemic Encephalopathy. *Antioxidants (Basel).* Dec 25 2021;11(1)doi:10.3390/antiox11010042
57. Lonsdale D. A review of the biochemistry, metabolism and clinical benefits of thiamin(e) and its derivatives. *Evid Based Complement Alternat Med.* Mar 2006;3(1):49-59. doi:10.1093/ecam/nek009
58. Siew SW, Musa SM, Sabri N, Farida Asras MF, Ahmad HF. Evaluation of pre-treated healthcare wastes during COVID-19 pandemic reveals pathogenic microbiota, antibiotics residues, and antibiotic resistance genes against beta-lactams. *Environ Res.* Feb 15 2023;219:115139. doi:10.1016/j.envres.2022.115139
59. Pawlowski AC, Wang W, Koteva K, Barton HA, McArthur AG, Wright GD. A diverse intrinsic antibiotic resistome from a cave bacterium. *Nat Commun.* Dec 08 2016;7:13803. doi:10.1038/ncomms13803
60. Hehnlly C, Zhang L, Paulson JN, et al. Complete Genome Sequences of the Human Pathogen Paenibacillus thiaminolyticus Mbale and Type Strain P. thiaminolyticus NRRL B-4156. *Microbiol Resour Announc.* Apr 09 2020;9(15)doi:10.1128/MRA.00181-20
61. Sáez-Nieto JA, Medina-Pascual MJ, Carrasco G, et al. spp. isolated from human and environmental samples in Spain: detection of 11 new species. *New Microbes New Infect.* Sep 2017;19:19-27. doi:10.1016/j.nmni.2017.05.006
62. Aidara-Kane A. Containment of antimicrobial resistance due to use of antimicrobial agents in animals intended for food: WHO perspective. *Rev Sci Tech.* Apr 2012;31(1):277-87. doi:10.20506/rst.31.1.2115
63. McEwen SA, Collignon PJ. Antimicrobial Resistance: a One Health Perspective. *Microbiol Spectr.* Mar 2018;6(2)doi:10.1128/microbiolspec.ARBA-0009-2017

Table 1. Reported infections due to *Paenibacillus* species in adults.

Year	Age, years	Organism	Clinical Illness	Comorbidity	Country	Treatment	Outcome
1989 ³⁴	26	<i>P. alvei</i>	prosthetic hip infection	sickle cell disease	USA	6 weeks vancomycin, ceftriaxone	cured
1991 ³¹	62	<i>P. alvei</i>	pneumonia, empyema	congestive heart failure	USA	penicillin	recurrence of pneumonia 1 year later, retreated and cured
1999 ¹⁷	57	<i>P. popilliae</i>	Endocarditis	None	China	6 weeks penicillin	cured
2004 ⁹	13	<i>P. massiliensis</i>	bacteremia	leukemia	France	unknown	unknown
2004 ⁹	49	<i>P. sanguinis</i>	bacteremia	oropharyngeal cancer	France	unknown	unknown
2004 ⁹	75	<i>P. timonensis</i>	bacteremia		France	unknown	unknown
2008 ¹⁰	75	<i>P. konsidensis</i>	bacteremia		Korea	unknown	unknown
2008 ¹³	80	<i>P. thiaminolyticus</i>	bacteremia, dialysis catheter infection	ESRD, CHF, colon cancer	USA	3 weeks vancomycin	unknown
2008 ²⁷	54	<i>P. provencesnsis</i>	positive CSF culture	Wippel's disease	France	none	unknown
2008 ²⁷	36	<i>P. urinalis</i>	urinary tract infection	IVDU	France	none	unknown

2010 ⁸	28	<i>P. larvae</i>	bacteremia	IVDU	Germany	14 days meropenem + 14 days penicillin	recurrence of BSI, peritonitis then cured
2010 ⁸	32	<i>P. larvae</i>	bacteremia	IVDU	Germany	none	unknown
2010 ⁸	20	<i>P. larvae</i>	bacteremia	IVDU	Germany	none	unknown
2010 ⁸	35	<i>P. larvae</i>	bacteremia	IVDU	Germany	7 days cefuroxime	unknown
2010 ⁸	27	<i>P. larvae</i>	bacteremia	IVDU	Germany	21 days imipenem	pulmonary embolism then cured
2010 ³²	25	<i>P. cineris</i>	pneumonia	cystic fibrosis	Brazil	7 days amox-clav + levofloxacin	cured
2010 ³⁰	60	<i>P. sputi</i>	pneumonia	NTM lung disease	Korea	unknown	unknown
2010 ²⁰	79	<i>P. pasadensis</i>	mediastinitis	myocardial infarction	Switzerland	2 weeks vancomycin/ciprofloxacin + 4 weeks clindamycin/ciprofloxacin	cured
2013 ¹⁵	65	<i>P. glucanolyticus</i>	bacteremia, endocarditis, pacemaker associated	diabetes, pacemaker	France	6 weeks ceftriaxone	cured
2013 ²⁹	60	<i>P. alvei</i>	pyelonephritis		India	7 days cefotaxime	cured
2013 ²¹	35	<i>P. vulneris</i>	wound	unknown	Norway	not described	not described
2015 ¹¹	55	<i>P. pasadensis</i>	bacteremia	ARDS, intracranial aneurysm clipping	Korea	teicoplanin, moxifloxacin, meropenem	died

2015 ²⁸	42	<i>P. macerans</i>	brain abscess	Ischemic stroke, craniectomy	USA	6 weeks vancomycin, cefepime, metronidazole	cured
2015 ¹²	36	<i>P. amylolyticus</i>	bacteremia, gingivitis	IVDU, trauma	USA	amox-clav	unknown
2016 ¹⁸	54	<i>P. residui</i>	wound, breast implant infection	breast cancer	Italy	amox-clav, surgical drainage	cured
2016 ²³	65	<i>P. turicensis</i>	traumatic bone infection	intramedullary nail	Laos	6 months amoxicillin	cured
2017 ¹⁴	70	<i>P. provencensis</i>	bacteremia, endocarditis	myocardial infarction	England	4 weeks vancomycin/meropenem + 2 weeks daptomycin	cured
2018 ³³	44	<i>P. assamensis</i>	joint, septic knee	none	China	unknown	prolonged knee symptoms
2019 ³⁶		<i>P. oralis</i>	gingivitis		Korea	unknown	unknown
2019 ²²	66	<i>P. macerans</i>	wound infection	diabetes, prostate cancer	USA	tmp/smx	recurred so now on suppressive tmp/smx and doing well
2020 ³⁷	49	<i>P. provencensis</i>	Skin abscess	none	Ireland	clindamycin, flucloxacillin x 60 days	Cured
2020 ²⁴	37	<i>P. timonensis</i>	traumatic wound infection	hypertension, NF1	Spain	vancomycin x 10 days + 3 weeks tmp/smx	cured

2021 ³⁵		<i>P. glucanolyticus</i>	corneal abscess	IVDU	England	ocular gentamicin, po doxycycline	infection resolved, permanent vision loss
2021 ²⁵	33	<i>P. thiaminolyticus</i>	wound infection	none	Switzerland	4 weeks amox-clav	cured
2021 ¹⁹	19	<i>P. turicensis</i>	fracture nonunion	none	USA	6 weeks ciprofloxacin	cured
2023 ¹⁶	57	<i>P. silvae</i>	bacteremia	obesity	Italy	2 weeks amox-clav + doxycycline	cured
2023 ²⁶	30	<i>P. lactis</i>	brain abscess, meningitis	IVDU	Bulgaria	vancomycin, meropenem, metronidazole (duration unknown)	cured without neurologic sequelae

Abbreviations: ESRD: end-stage renal disease; CHF: congestive heart failure; IVDU: intravenous drug use; NTM: nontuberculous mycobacterium; ARDS: acute respiratory distress syndrome; NF1: neurofibromatosis type 1; tmp/smx: trimethoprim-sulfamethoxazole

Table 2. Reported infections due to *Paenibacillus* species in infants.

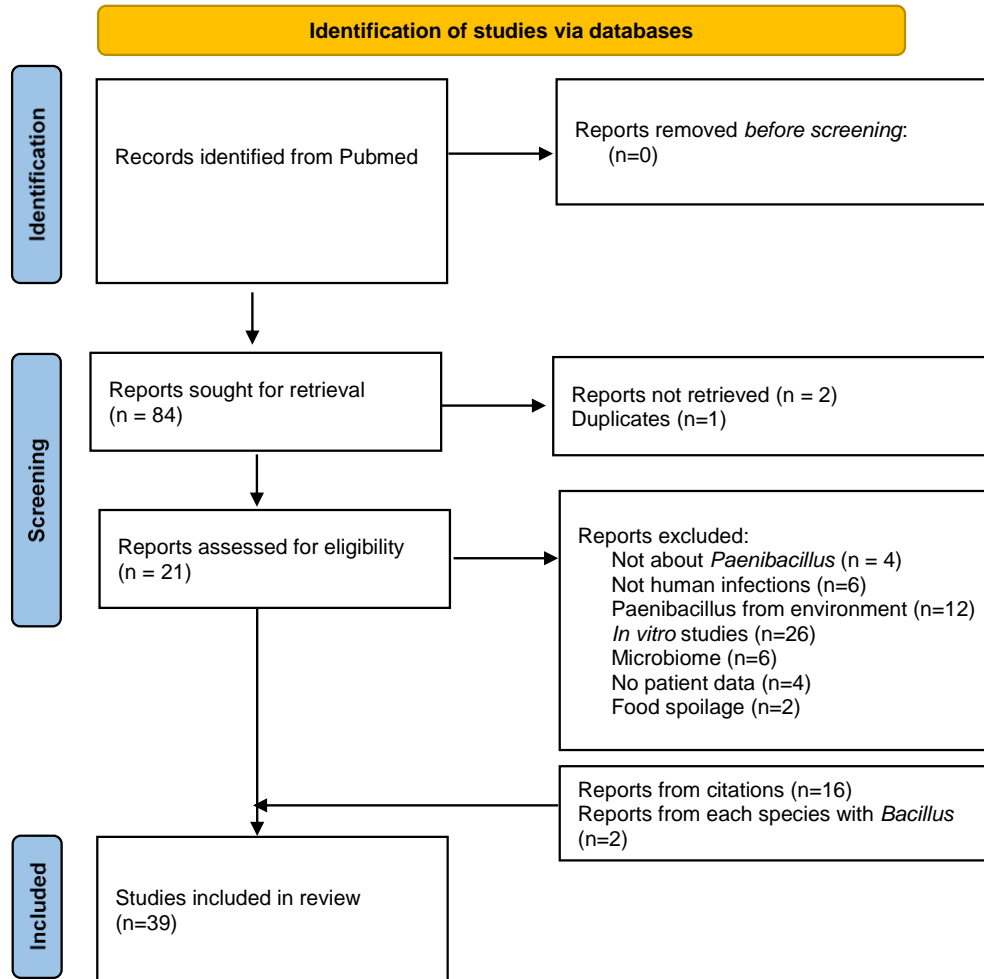
Year	Age, days	Organism	Clinical Illness	Gestational age	State, Country	Treatment	Outcome
1987 ³⁸	20	<i>P. alvei</i>	Neonatal sepsis, meningitis	Term	Texas, USA	21 days ampicillin	Healthy at 3.5 years old
2016 ³⁹	28	<i>P. alvei</i>	Neonatal sepsis, meningitis	33 weeks	Oklahoma, USA	21 days ampicillin, vancomycin	cystic encephalomalacia, seizures, died at 5 months old
2021 ⁴²	25	<i>P. thiaminolyticus</i>	Neonatal sepsis, meningitis	35 weeks	California, USA	Ampicillin, cefepime, gentamicin	Cerebral infarction, died at 29 days old
2022 ⁴⁰	31	<i>P. dendritiformis</i>	Meningitis	33 weeks	Florida, USA	6 weeks ampicillin	seizures, abscess, encephalomalacia, EVD placement; severe language and gross motor impairment
2022 ⁴¹	35	<i>P. dendritiformis</i>	Meningitis	34 weeks	Texas, USA	6 weeks ampicillin	seizures, abscess, encephalomalacia, hydrocephalus managed with ETV
2022 ⁴³	16	<i>P. thiaminolyticus</i>	Neonatal sepsis, meningitis	39 weeks	South Carolina, USA	6 weeks meropenem, thiamine	venous sinus thrombosis, infantile spasms, healthy at 18 months old
2023 ⁴⁴	37	<i>P. thiaminolyticus</i>	Sepsis, meningitis	33 weeks	Minnesota, USA	21 days ampicillin	seizures, ischemic strokes, cystic encephalomalacia, hydrocephalus

							managed with VP shunt, died at 11 months old
2023 ⁵	3 (1, 7)*	24 <i>P. thiaminolyticus</i> 13 <i>P. species</i>	Neonatal sepsis, meningitis	Term	Uganda	Various	14% died 14% survived with hydrocephalus
2023 ⁴	58 (44, 68)*	85 <i>P. thiaminolyticus</i> 10 <i>P. species</i>	Meningitis	Term	Uganda	Various	
Unpublished	Unknown	<i>P. species</i>	Neonatal sepsis	Unknown	Maryland, USA	Unknown	ECMO, died
Unpublished	1	<i>P. species</i>	Neonatal sepsis	Term	Minnesota, USA	8 days gentamicin	

*median (25th, 75th percentiles)

Abbreviations: ECMO: extra-corporeal membrane oxygenation; EVD: externalized ventricular drain; ETV: endoscopic third ventriculostomy; VP: ventriculoperitoneal shunt

Figure 1.



From: Page MJ, McKenzie JE, Bossuyt PM, Boutron I, Hoffmann TC, Mulrow CD, et al. The PRISMA 2020 statement: an updated guideline for reporting systematic reviews. *BMJ* 2021;372:n71. doi: 10.1136/bmj.n71

Figure 2. Annual published cases of infection due to *Paenibacillus* species in adults (A) and infants (B).

