

Comparison of the effects of methylene blue with adrenaline and
Marcaine with adrenaline on pain control after hemorrhoidectomy
Ramin Azhough MD¹; Mohammad Reza Dashti² MD; Sahar Taher
MD³; Pooya Jalali MD⁴

Keywords: Hemorrhoidectomy; Methylene Blue; Postoperative pain;
Pain control

1. Assistant Professor of General Surgery, Tabriz University of Medical Sciences, Tabriz, Iran.
2. MD, Tabriz University of Medical Sciences, Tabriz, Iran.
3. MD, Islamic Azad University Tabriz Branch, Tabriz, Iran.
4. Basic and Molecular Epidemiology of Gastrointestinal Disorders Research Centre, Research Institute for Gastroenterology and Liver Diseases, Shahid Beheshti University of Medical Sciences, Tehran, Iran.

Article type: Original Article

Corresponding author: Pooya jalali

Mobile: +98 9187859587

Email: pooya.jalali1995@gmail.com

Iran, East Azerbaijan Province, Tabriz, Univesity Main St

The authors declare that they have no conflict of interest.

Abstract

Background: Hemorrhoidectomy is still considered the mainstay of treatment for advanced and/or complicated hemorrhoids, although post-hemorrhoidectomy pain remains a challenging problem.

Objectives: This study aimed to comparison the effect of intradermal methylene blue with adrenaline and Marcaine with adrenaline injection in pain relief after hemorrhoidectomy.

Material and methods

In this single-center prospective double-blind randomized trial, Patients aged 18-60 years with the diagnosis of hemorrhoids with grade three or four candidate for open hemorrhoidectomy were enrolled. Patients were randomly divided into two groups. Intradermal injection during hemorrhoidectomy of 4 ml 1% methylene blue with adrenaline and 16 ml 0.5% Marcaine for patients in methylene blue group and 16 ml 0.5% Marcaine with adrenaline and 4 ml saline without methylene blue in control group was used. Patients' information were recorded prospectively.

Results

Ninety seven patients were enrolled. Postoperative pain in patients in methylene group between the 1st and 7th days after surgery was significantly lower than patients in control group. However, no significant difference was detected in pain scores between the two groups from 8th to the 14th days after surgery. Also, patients in methylene blue group received analgesic drugs were significantly less than control group between days 1 and 7 after the surgery.

Conclusion

An intradermal application of 1 % methylene blue with adrenaline solution is associated with a positive effect on pain relief with low side effects related to sensory cutaneous innervation in all patients. It can achieve a long-acting analgesic effect with few complications.

Background

Hemorrhoids is the most common benign anal disease that physicians and surgeons encounter [1]. It has been predicted that a lifetime risk of hemorrhoids can be as high as 75% in the general population [2]. The treatment of hemorrhoids depends on the stage of the disorder and symptoms [3]. For symptomatic hemorrhoids of the third and fourth degree, surgical hemorrhoidectomy is indicated [4]. Hemorrhoidectomy requires deep anesthesia because the surgical area has multiple nerve sources and is reflexogenic. Operations under light anesthesia cause severe pain, reflex body movements, tachypnea and laryngeal spasm. Virtually all patients go through different degrees of postoperative pain [5], which terrifies the patients. Pain management, especially in the first 24 hours after surgery, leads to reduced urinary retention and constipation, as well as increased patient satisfaction [6]. Although various methods including general, spinal, caudal, local and combined techniques have been used for hemorrhoidectomy, there is no ideal method, each of them has advantages and disadvantages. Regional anesthesia provides preemptive analgesia [7]. It can decrease or prevent the risks and discomforts of general anesthesia, including sore throat, airway trauma, and muscle pain [7]. It is easily learned and simple to perform; when used in surgical patients, it does not appear to significantly interfere with the surgery's progress; and as long as the anesthetic is not injected intravenously and extreme doses are not administered, it is generally safe for patients [7]. But regional anesthesia has disadvantages such as drug reactions [7]. Pudendal nerve block can lead to complications such as hematoma, sciatic nerve injury, and rectal perforation. Since this is a blind technique in a vascular area near the bowel and bladder, they guide a needle by palpation along the path of their fingers to touch the appropriate landmarks. This puts such surgeons at high risk of accidentally sticking their fingers with needles [7]. Intradermal injection of methylene blue is a reported treatment for refractory idiopathic pruritus (IPA) and has already been used in small series with promising results [8]. Hemorrhoidectomy is still considered the mainstay of treatment for advanced and/or complicated hemorrhoids, although post-hemorrhoidectomy pain remains a challenging problem [9,10]. This study aimed to compare the effect of intradermal methylene blue with adrenaline and Marcaine with adrenaline injection in pain relief after hemorrhoidectomy.

Material and methods

Study design

A single-center prospective double-blind randomized trial was conducted. Patients aged 18–60 years with the diagnosis of hemorrhoids with grade three or four candidate for open hemorrhoidectomy were enrolled. Informed written consent was obtained from all patients included in the study. Patients with perianal infectious, previous history of perianal surgery, addicted to opioids, and pregnant women were excluded from the study.

Study design

This trial was conducted in Imam Reza Hospital, Tabriz, Iran, January and December 2021. The study was approved by the research ethics committee of Tabriz University of Medical Sciences and registered in the Iranian Registry of clinical trials with registration number IRCT20190325043107N27 (the full trial protocol can be accessed at: <http://www.irct.ir>). All procedures performed in this study were in accordance with the ethical standards of the institutional and/or national research committee and with the 1964 Helsinki declaration and its later amendments or comparable ethical standards. A sample size of 50 people in each study group was calculated with 90% power and 5% significance level based on power analysis. Patients' information were recorded prospectively including age, weight, height, Body Mass Index (BMI), gender, number of hemorrhoids excised, Postoperative pain after hemorrhoidectomy (using visual analogue scale(VAS)), postoperative complications, length of surgery, length of hospital stay, analgesia requirement measured by daily oral tramadol consumption in the 14 days after hemorrhoidectomy.

Intervention

All patients underwent standard Milligan-Morgan[11] open hemorrhoidectomy under general anesthesia by a surgical team. To ensure uniformity of surgical technique, all patients were operated by the same surgeon, a uniform anesthesia protocol was used for all patients, and the excision procedure was the same for both groups. All patients were randomly divided into two groups. Intradermal injection of 4 ml 1% methylene blue with adrenaline and 16 ml 0.5% Marcaine during hemorrhoidectomy for patients in methylene blue group (Figure 1) and 16 ml 0.5% Marcaine with adrenaline and 4 ml saline without methylene blue in control group was used. The needlepoint was approximately 2 cm away from the incision edge. The needle orientation was approximately 45 degrees from the skin. The hemorrhoidal mass was collected and diathermy dissection was performed. All patients were asked to clean the wound twice a day. The patients were asked to record their maximum pain during the day until 14 days after surgery and followed up in the clinic two and four weeks after surgery.

WITHDRAWN
see manuscript DOI for details

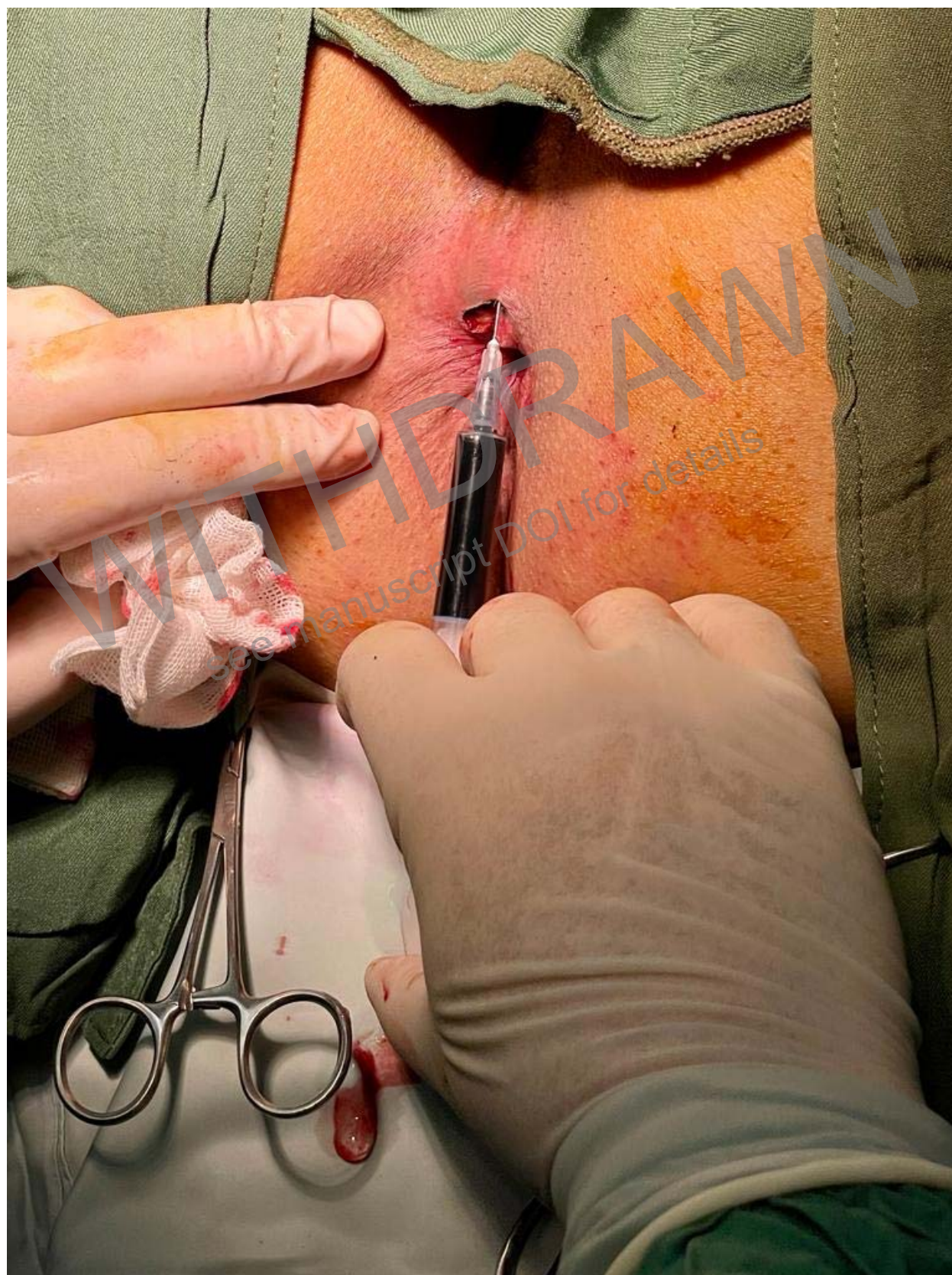

Figure 1: Intradermal injection of Methylene blue.

Randomization

All patients were randomized into two groups according to a simple randomization procedure using a computer-generated table of random numbers (1–2). Patients were assigned to the intervention by a person who was unaware of the randomization code and was not involved in the subsequent treatment process. Patients and investigators (statistician and assessor) were blinded to allocation and randomization codes were not available to investigators or patients until the trial was completed.

Statistical analysis

Data were analyzed using SPSS version 21 (Chicago, IL, USA). Statistical parameters performed descriptions of data based on their distribution. Categorical variables are given as counts and percentages. Continuous variables are expressed as mean \pm standard deviation (SD). Student's t test was used to compare the quantitative data and the χ^2 test was used to compare the qualitative data between groups. P-values of less than 0.05 were regarded as statistically significant for any differences.

Results

Of 100 recruited for this trial, 3 were excluded because of opioid addiction not recognized before their enrolment in the trial, leaving 97 patients (48 patients in methylene group and 49 patients in control group) for analysis (Figure2). The characteristics of the study participants were shown in Table1. There were no significant difference in gender distribution ($P = 0.219$), mean age ($P = 0.154$), mean weight ($P = 0.947$), mean height($P = 0.559$),and mean BMI ($P = 0.545$) of patients between two group. Also, there were also no differences in the number of hemorrhoids excised ($P = 0.616$), length of hospital stay($P = 0.622$), and length of surgery($P = 0.328$) between two groups. Postoperative pain in patients in methylene group between the 1st and 7th days after surgery was significantly lower than patients in coltrol group($P < 0.05$). However, no significant difference was detected in pain scores between the two groups from 8th to the 14th days after surgery ($P > 0.05$)(Figure3). Also, patients in methylene blue group received analgesic drugs were significantly less than control group between days 1 and 7 after the surgery($P < 0.05$)(Figure4). There were no statistically significant differences in complication rates between the two groups(Table 2).

Figure 2: The Flow chart for patient selection.

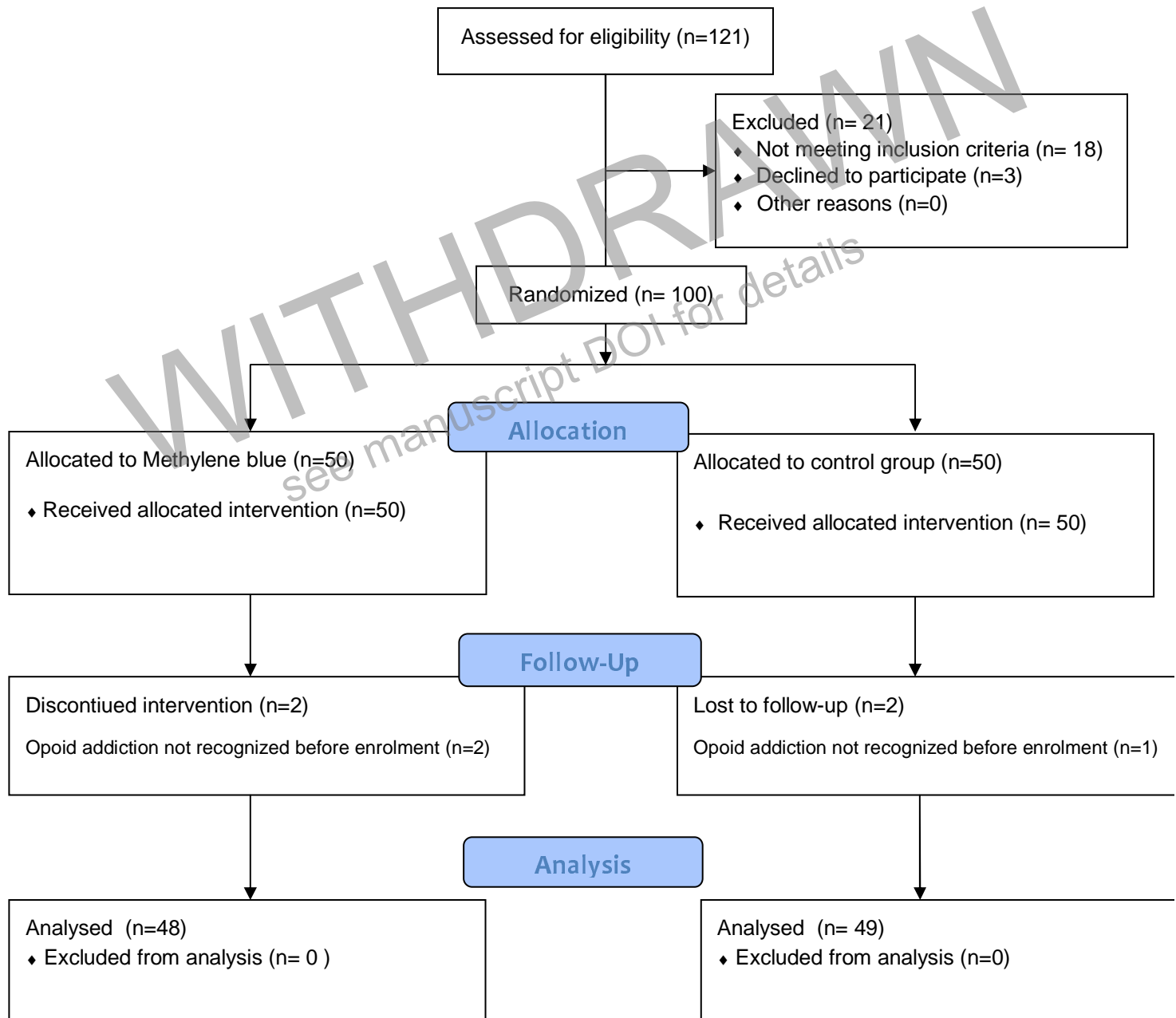


Table 1: The characteristics of the study participants

	Methylene blue group (n = 48)	Control group (n=49)	<i>P</i> -value
Age (Years)	46.02 ± 9.90	48.57 ± 7.40	0.154
Male gender	37 (75.5%)	41 (85.4%)	0.219
Height (CM)	170.29 ± 7.43	171.16 ± 7.21	0.559
Weight (Kg)	79.25 ± 7.47	79.34 ± 6.90	0.947
BMI	28.25 ± 3.95	27.79 ± 3.41	0.545
Number of hemorrhoids excised	2.33 ± 0.48	2.29 ± 0.46	0.616
Duration of surgery	26.46 ± 2.90	25.86 ± 3.12	0.328
length of hospital stay	0.46 ± 0.50	0.41 ± 0.50	0.622

Table 2: Postoperative complications of studied patients.

	Methylene blue group (n = 48)	Control group (n=49)	<i>P</i> -value
Uroschesis	5 (10.4%)	5 (10.2%)	0.973
Pain requiring readmission	0 (0%)	1 (2%)	0.320
Pain requiring unscheduled visit	1 (2.1%)	2 (4.1%)	0.570
Skin necrosis	0 (0%)	0 (0%)	NA
Anal incontinence temporarily	3 (6.3%)	1 (2%)	0.297

Wound infection	0	0	NA
Acute urinary Retention	0 (0%)	1 (2%)	0.320
Local skin Reaction	0	0	NA
Pruritus	1 (2.1%)	1 (2%)	0.988
Secondary haemorrhag	0 (0%)	2 (4.1%)	0.157

NA: not analysis.

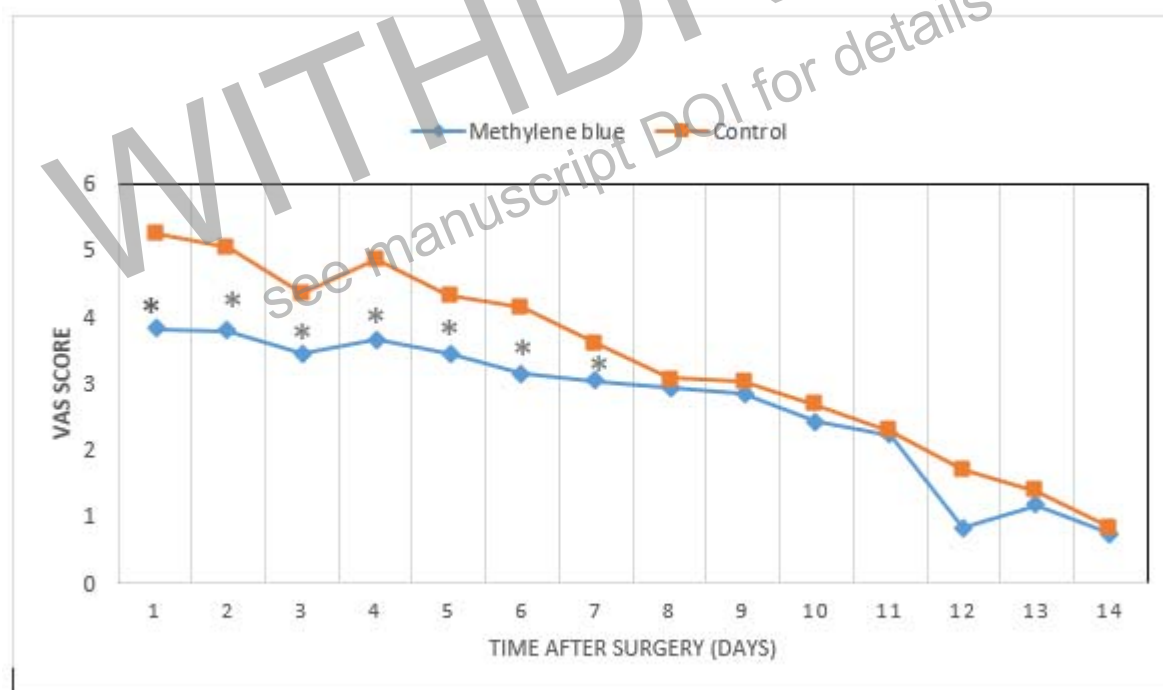


Figure3: Pain scores after surgery between two groups. *P < 0.01

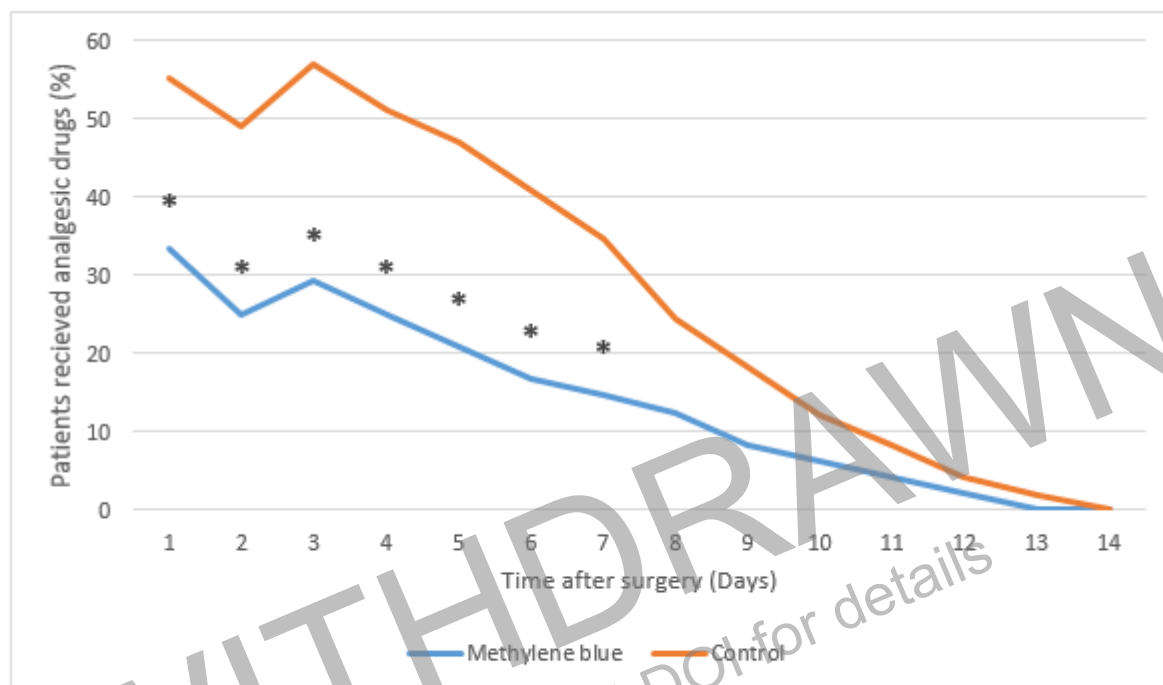


Figure 4: Patients received analgesic drugs. *P < 0.01

Discussion

Excisional hemorrhoidectomy is the most effective treatment for reducing recurrent symptoms in patients with grade 3 or 4 hemorrhoids, patients with mixed internal and external hemorrhoids, and those with recurrent hemorrhoids for whom other treatments have failed [12,13]. In recent years, numerous surgical techniques have been developed for the treatment of hemorrhoids, such as stapled circular hemorrhoidopexy and partial stapled hemorrhoidopexy [14,15], with the advantages of low trauma, little postoperative pain, and few complications. However, these procedures still require traditional excision of external hemorrhoids while treating mixed hemorrhoids [16]. The anus is very sensitive to the pain caused by a surgical incision, which leads to severe regional pain after the operation with a long duration [17].

The most common complication after hemorrhoidectomy is postoperative pain, which is usually severe during the first stools passage. Pain is the most common reason for delayed patient discharge. Studies showed that, as a result of pain, patients need 4 to 16 days to return to their normal activities [18]. Ineffective pain control also increases the need for opioid requirements, postoperative nausea and vomiting, urinary retention, and increased readmission [18]. A study by HL et al, [19] they reported that the analgesic effect of methylene blue plus ropivacaine was significant only in the first 3 days after surgery. They used the intradermal injection of methylene blue along with bupivacaine before the incision. Unlike those, Xiang et al. [16] reported a significant analgesic effect of methylene blue plus ropivacaine within first 5 days after surgery. At the end of the operation, they used the intradermal injection of methylene blue plus bupivacaine.

The present study shows a significant reduction in pain scores in methylene blue group in the first seven days after surgery. Some patients in the methylene blue group even reported a pain score of 0, whereas none of the patients in the control group reported a pain score of 0 during the first 4 days after surgery. One week after surgery, most of the patients reported much lower pain scores there was no significant difference between the two groups. These results suggested that methylene blue with adrenaline has a significant analgesic effect.

Methylene blue is a water-soluble thiazine dye that has been used to treat many conditions. Rygick was the first to report the use of methylene blue in the treatment of IPA in 1968 [20]. Eusebio et al. first proposed a promising method of intradermal methylene blue injection [21]. They also modified this method by decreasing the concentration of methylene blue and adding a local anesthetic to reduce local complications [22]. The reason for this IPA treatment is as follows: methylene blue may act by inducing direct toxicity to the nerves supplying the perianal skin. This is based on electron micrographs of cutaneous nerves taken at 1 and 7 years after treatment. Axons appear to be normal, but different nerve terminals cannot be established [21, 23]. In a prospective series on lateral sphincterotomy, it had found that this property can be used to reduce postoperative pain [24]. There are some post procedural transient complications reported following methylene blue injection like cellulitis, superficial abscess, urinary retention, transient fecal incontinence, and skin necrosis [25-29]. In our study, skin necrosis, wound infection, acute urinary retention were not seen in methylene blue group.

This study had potential limitations. First limitation was the severity of the pain and its expression by qualitative individuals, and an individual with high resistance to the pain can express the severity of the pain more or less. Second, this was not triple-blind trial and colleagues carrying out the statistical analysis were not blinded. An intradermal application of 1 % methylene blue with adrenaline solution is associated with a positive effect on pain relief with low side effects related to sensory cutaneous innervation in all patients. It can achieve a long-acting analgesic effect with few complications.

References

1. Nelson R.L., Abcarian H., Davis F.G., Persky V. Prevalence of benign anorectal disease in a randomly selected population. *Dis. Colon Rectum*. 1995;38:341–344. doi: 10.1007/BF02054218. [PubMed] [CrossRef] [Google Scholar]
2. Lohsiriwat V. Treatment of hemorrhoids: A coloproctologist's view. *World J. Gastroenterol*. 2015;21:9245–9252. doi: 10.3748/wjg.v21.i31.9245. [PMC free article] [PubMed] [CrossRef] [Google Scholar]
3. Holzheimer RG. Hemorrhoidectomy: indications and risks. *Eur J Med Res*. 2004;9:18–36. [PubMed] [Google Scholar] [Ref list]
4. Nisar PJ, Scholefield JH. Managing haemorrhoids. *BMJ*. 2003;327:847–851. doi: 10.1136/bmj.327.7419.847. [PMC free article] [PubMed] [CrossRef] [Google Scholar] [Ref list]
5. Wu JI, Lu SF, Chia YY, Yang LC, Fong WP, Tan PH. Sevoflurane with or without antiemetic prophylaxis of dexamethasone in spontaneously breathing Patients undergoing Outpatient anorectal surgery. *J Clin Anesth* 2009; 21: 469-473.
6. Liu ST, Wu CT, Yeh CC, Ho ST, Wong CS, Jao SW, et al. Premedication with dextromethorphan provides posthemorrhoidectomy pain relief. *Dis Colon Rectum*. 2000;43:507–510. [PubMed] [Google Scholar] [Ref list]
7. Rajabi, M., Hosseinpour, M., Jalalvand, F., Afshar, M., Moosavi, G., & Behdad, S. (2012). Ischiorectal block with bupivacaine for post hemorrhoidectomy pain. *The Korean journal of pain*, 25(2), 89–93. <https://doi.org/10.3344/kjp.2012.25.2.89>

8. Wolloch Y, Dintsman M (1979) A simple and effective method of treatment for intractable pruritus ani. *Am J Proctol Gastroenterol Colon Rectal Surg* 30:34–36
9. Lohsiriwat V. (2012). Hemorrhoids: from basic pathophysiology to clinical management. *World journal of gastroenterology*, 18(17), 2009–2017. <https://doi.org/10.3748/wjg.v18.i17.2009>
10. Gallo G, Martellucci J, Sturiale A, Clerico G, Milito G, Marino F, Cocorullo G, Giordano P, Mistrangelo M, Trompetto M. Consensus statement of the Italian society of colorectal surgery (SICCR): management and treatment of hemorrhoidal disease. *Tech Coloproctol*. 2020 Feb;24(2):145-164. doi: 10.1007/s10151-020-02149-1. Epub 2020 Jan 28. PMID: 31993837; PMCID: PMC7005095.
11. Milligan ET, Morgan CN, Jones LE et al (1937) Surgical anatomy of the anal canal and the operative treatment of haemorrhoids. *Lancet* 2:1119–1124
12. Karanlik H, Akturk R, Camlica H et al (2009) The effect of glyceryl trinitrate ointment on posthemorrhoidectomy pain and wound healing: results of a randomized, double-blind placebocontrolled study. *Dis Colon Rectum* 52:280–285
13. Ratnasingham K, Uzzaman MM, Andreani SM et al (2010) Metaanalysis of the use of glyceryl trinitrate ointment after haemorrhoidectomy as an analgesic and in promoting wound healing. *Int J Surg* 8:606–611
14. Kim JS, Vashist YK, Thielges S, Zehler O, Gawad KA, Yekebas EF, Izbicki JR, Kutup A. Stapled hemorrhoidopexy versus Milligan-Morgan hemorrhoidectomy in circumferential third-degree hemorrhoids: long-term results of a randomized controlled trial. *J Gastrointest Surg*. 2013 Jul;17(7):1292-8. doi: 10.1007/s11605-013-2220-7. Epub 2013 May 14. PMID: 23670518.
15. Lin HC, Ren DL, He QL, Peng H, Xie SK, Su D, Wang XX. Partial stapled hemorrhoidopexy versus circular stapled hemorrhoidopexy for grade III-IV prolapsing hemorrhoids: a two-year prospective controlled study. *Tech Coloproctol*. 2012 Oct;16(5):337-43. doi: 10.1007/s10151-012-0815-8. Epub 2012 Mar 9. PMID: 22402919.
16. Xiang, Feng and Jingjuan Feng. “Postoperative analgesic effect of methylene blue compound in anal diseases.” (2016).
17. Hetzer FH, Demartines N, Handschin AE, Clavien PA. Stapled vs excision hemorrhoidectomy: long-term results of a prospective randomized trial. *Arch Surg* 2002; 137: 337-340.
18. Uzzaman MM, Siddiqui (2011) A brief literature review on the management of post-haemorrhoidectomy pain. *Surg Tech Dev* 1(e32):82–87 Rygick AN (1968) Treatment of pruritus ani by intracutaneous injections of methylene blue (Rygick’s method). In: *Atlas of the operations on the rectum and colon*. Meduchposobie, Moscow, p 162
19. Sim, H. L., & Tan, K. Y. (2014). Randomized single-blind clinical trial of intradermal methylene blue on pain reduction after open diathermy haemorrhoidectomy. *Colorectal disease : the official journal of the Association of Coloproctology of Great Britain and Ireland*, 16(8), O283–O287. <https://doi.org/10.1111/codi.12587>

20. Rygick AN (1968) Treatment of pruritus ani by intracutaneous injections of methylene blue (Rygick's method). In: Atlas of the operations on the rectum and colon. Meduchposobie, Moscow, p 162
21. Eusebio EB, Graham J, Mody N (1990) Treatment of intractable pruritus ani. Dis Colon Rectum 33:770–772
22. Eusebio EB, Graham J, Mody N (1990) Treatment of intractable pruritus ani. Dis Colon Rectum 33:770–772
23. Wolloch Y, Dintsman M (1979) A simple and effective method of treatment for intractable pruritus ani. Am J Proctol Gastroenterol Colon Rectal Surg 30:34–36
24. Tan KY, Seow-Choen F. Methylene blue injection reduces pain after lateral anal sphincterotomy. Tech Coloproctol 2007; 11: 68–9.
25. Eusebio, E. B., Graham, J., & Mody, N. (1990). Treatment of intractable pruritus ani. Diseases of the colon and rectum, 33(9), 770–772. <https://doi.org/10.1007/BF02052324>
26. Mendes, B. B., Akin, M., Leventoglu, S., Gultekin, F. A., & Oguz, M. (2004). Intradermal methylene blue injection for the treatment of intractable idiopathic pruritus ani: results of 30 cases. Techniques in coloproctology, 8(1), 11–14. <https://doi.org/10.1007/s10151-004-0043-y>
27. Farouk, R., & Lee, P. W. (1997). Intradermal methylene blue injection for the treatment of intractable idiopathic pruritus ani. The British journal of surgery, 84(5), 670.
28. Botterill, I. D., & Sagar, P. M. (2002). Intra-dermal methylene blue, hydrocortisone and lignocaine for chronic, intractable pruritus ani. Colorectal disease : the official journal of the Association of Coloproctology of Great Britain and Ireland, 4(2), 144–146. <https://doi.org/10.1046/j.1463-1318.2002.00329.x>
29. Sutherland, A. D., Faragher, I. G., & Frizelle, F. A. (2009). Intradermal injection of methylene blue for the treatment of refractory pruritus ani. Colorectal disease : the official journal of the Association of Coloproctology of Great Britain and Ireland, 11(3), 282–287. <https://doi.org/10.1111/j.1463-1318.2008.01587.x>

WITHDRAWN
see manuscript DOI for details