

1 **Defining the extracellular matrix in non-cartilage soft tissues in osteoarthritis**

2 **– a systematic review**

3 Jolet Y. Mimpfen^{1*#}, Iwan G. A. Raza^{2#}, Sarah J. B. Snelling¹

4 ¹ *Botnar Research Centre, Nuffield Department of Orthopaedics Rheumatology and Musculoskeletal*
5 *Sciences, University of Oxford, Oxford, UK*

6 ² *Medical Sciences Division, University of Oxford, UK*

7 # Jolet Y. Mimpfen and Iwan Raza contributed equally to this work

8

9 *** Correspondence:**

10 Dr Jolet Mimpfen

11 Botnar Research Centre

12 Old Road

13 Oxford

14 OX3 7LD

15 United Kingdom

16 jolet.mimpfen@ndorms.ox.ac.uk

17 ORCID: 0000-0003-4464-242X

18

19 **Keywords:** osteoarthritis, extracellular matrix, human, animal models, synovium, meniscus

20

21 **Abstract** (max 250 words)

22

23 **Objective**

24 Osteoarthritis (OA) is increasingly seen as a disease of global joint dysfunction, affecting not only
25 cartilage but also the other joint tissues. Extracellular matrix (ECM) is a critical determinant of tissue
26 mechanobiology, but ECM is poorly understood in osteoarthritic joint tissues beyond cartilage in
27 human OA and animal models of OA. Therefore, we aimed to define the structural composition and
28 architecture of non-cartilage soft joint tissue ECM in human OA, and to compare the ECM changes
29 observed in humans to those seen in animal models of OA.

30

31 **Design**

32 A systematic search strategy, devised using relevant matrix, tissue, and disease nomenclature, was
33 run through the MEDLINE, EMBASE, and Scopus databases. Demographic, clinical, and biological
34 data were extracted from eligible studies. Bias analysis was performed.

35

36 **Results**

37 142 studies were included, which covered capsule, ligaments, meniscus, skeletal muscle, synovium,
38 and tendon in both humans and animals, and fat pad and intervertebral disc in humans only. Overall,
39 included studies show that the expression of structural ECM components changes in disease within
40 an ECM that becomes disorganised with increasing joint degeneration.

41

42 **Conclusions**

43 This systematic review consolidates existing knowledge of a poorly defined aspect of OA
44 pathophysiology. Changes in ECM composition and architecture occur across soft joint tissues in OA,
45 but most of these remain poorly defined due to the low number of studies and lack of healthy

46 comparator groups. Further research to better understand the context within which cartilage is
47 damaged in OA may enable a better understanding of OA and its potential treatments.

48

49 **Key messages**

50 What is already known on this topic

- 51 • Extracellular matrix (ECM) is a critical determinant of tissue mechanobiology and cell
52 behaviour, but it is poorly described in osteoarthritic joint tissues beyond cartilage.

53 What this study adds

- 54 • Our study highlights the global nature of ECM dysregulation across the osteoarthritic joint.
55 In addition, this study describes practical and methodological challenges that should be
56 addressed to improve the contribution of future studies to define the role of ECM in non-
57 cartilage soft tissues in osteoarthritis.

58 How this study might affect research, practice or policy

- 59 • A better understanding of ECM changes and their underlying mechanisms throughout the
60 osteoarthritic joint may assist with disease classification and patient stratification and also
61 holds promise for the development of ECM-targeting treatments which could modify the
62 pathogenic cell behaviour that may drive osteoarthritis progression.

63

64 **1 Introduction**

65 Osteoarthritis (OA) is the most common joint disease globally, affecting over 500 million people. OA
66 is typically attributed to mechanically-driven joint damage and is characterised by articular cartilage
67 degeneration and subchondral bone remodelling[1]. However, these tissues are not affected in
68 isolation from the wider joint, with pathology in other soft joint tissues contributing to the
69 symptoms and progression of OA[2, 3]. Damage to menisci and ligaments disrupts joint
70 biomechanics, while inflammation, fibrosis, and distension of the synovium and joint capsule are
71 associated with joint pain and stiffness[4–8]. Despite significant clinical need and substantial efforts
72 to identify disease modifying OA drugs, there is no effective way of inhibiting or decelerating OA-
73 related joint damage by targeting cartilage directly. Given the important role of other soft tissues in
74 joint biomechanics and the release of pro-inflammatory and matrix-degrading mediators into the
75 synovial fluid[9], understanding the whole joint context of OA might provide novel therapeutic
76 strategies and prognostic markers.

77

78 Joint tissues are rich in extracellular matrix (ECM), a network of structural and regulatory
79 macromolecules within which cells are embedded[10]. The role of ECM as a major determinant of
80 the biophysical properties of a tissue has clear relevance in a disease such as OA[11, 12]. ECM not
81 only provides structure to the tissue, but can also affect cell function through receptor engagement,
82 mechanical cues, and the sequestration of growth factors and cytokines[13–16]. Significant crosstalk
83 occurs between cells and matrix components, such that pathological ECM may exacerbate cellular
84 dysfunction in disease[15, 17]. Therefore, ECM composition and architecture cannot be disregarded
85 when attempting to understand OA pathophysiology. However, outside of cartilage, ECM
86 remodelling in OA has received relatively little attention.

87

88 Studying OA in the clinical setting is challenging due to the slow and unpredictable nature of the
89 course of the disease. In addition, clinical symptoms often appear late in the disease process, making

90 it difficult to study its onset and early progression. Therefore, many animal models for OA have been
91 developed and are used to overcome these issues and to facilitate the development and evaluation
92 of new therapies and diagnostic tools[18]. However, since there is no single “gold standard” animal
93 model that accurately reflects all aspects of human disease, a major challenge is selecting the “right”
94 model for each study[19].

95

96 The main aim of this systematic review is to consolidate existing data describing ECM architecture
97 and structural composition in the synovium, joint capsule, skeletal muscle, tendon, ligament,
98 meniscus, intervertebral disc, and fat pad of osteoarthritic joints. Secondly, we aim to define the
99 changes in ECM architecture and structural composition in these tissues in animal models of OA to
100 address their ability to replicate human disease pathophysiology.

101 2 Methods

102 This review was conducted according to a protocol registered on the PROSPERO database
103 [CRD42021231241] and guidelines set out in the Preferred Reporting Items for Systematic Reviews
104 and Meta-Analyses (PRISMA) statement[20].

105

106 Database and search strategy

107 The search strategy, written by JM and a medical librarian, can be found in the **Supplementary**
108 **Information**. ECM components and architectural features were defined using National Centre for
109 Biotechnology Information Medical Subject Heading terms. Non-cartilage soft joint tissues and
110 disease nomenclature were also specified. The search strategy was validated against relevant papers
111 identified in a preliminary literature search. The search strategy was run on the Ovid MEDLINE, Ovid
112 EMBASE and Scopus platforms on 30 October 2020 and repeated on 1 October 2021.

113

114 Eligibility criteria and screening

115 Abstracts were de-duplicated in Mendeley Reference Manager (Elsevier B.V., Netherlands) before
116 importing into the Covidence platform. The remaining studies were screened independently at
117 title/abstract and full-text stages by two reviewers (IR & JM), with conflicts resolved through
118 consensus or a third reviewer (SS). Included studies were required to have ≥ 3 OA participants.

119

120 In human studies, eligible patients and controls were ≥ 18 years. Non-OA diseases, including
121 inflammatory arthritides and crystalline arthropathies, were excluded. The presence of a valid control
122 group was not a requirement for human studies. However, control groups were included if present
123 and a minimum of 3 participants were included in this group. Valid control groups include tissues
124 from healthy people or near-healthy tissues, including cadavers, individuals with osteosarcoma, and
125 traumatic joint injuries provided that the comparator tissue was not directly damaged by the
126 trauma.

127

128 In contrast to human studies, all animal studies required a control group. Studies that induced OA
129 unilaterally and only used a contralateral control joint were excluded, as non-physiological loading of
130 the contralateral joint induces ECM remodelling[21, 22]. Excluded animal models included the
131 genetic deletion of ECM components, the introduction of matrix-degrading enzymes into the joint,
132 surgical damage of a tissue subsequently reported on, and the ovariectomised rat model, as this is
133 more commonly used as a model for osteoporosis[23, 24].

134

135 Regarding outcome measures, included studies evaluated at least one of the following tissues:
136 intervertebral disc, ligament, skeletal muscle, tendon, meniscus, articular capsule, synovium, and fat
137 pad. Papers that only studied these tissues after treatment, including – but not limited to – surgical
138 or drug treatment, or after these tissues were purposely injured to induce the development of OA,
139 were excluded. Papers evaluating non-ECM tissue components (cells, cytokines, matrix-degrading
140 enzymes) were ineligible for inclusion. Given the focus on structural ECM, regulatory extracellular
141 proteins, as well as neopeptides generated during ECM turnover, were not included. Studies using *in*
142 *vitro* or *ex vivo* culture systems were excluded as the ECM proteins cells synthesise differ in culture
143 and *in vivo*. Transcriptomic analyses were excluded as gene expression is a determinant, not a
144 measure, of protein abundance. Finally, only English-language articles were included.

145

146 Data extraction and bias analysis

147 Data were extracted from all included studies by one reviewer (JM or IR) using a standardised
148 extraction form in Microsoft Excel; the extraction was verified by the other reviewer. Where there
149 was uncertainty, extraction was performed in duplicate by both reviewers. Number of participants
150 (or animals) in each group was recorded as well as the presence/absence of a control group; if a
151 control group was present, the control population and control tissue were described. For animal
152 studies, the species, strain, and type of OA model were recorded. When available, participant age,

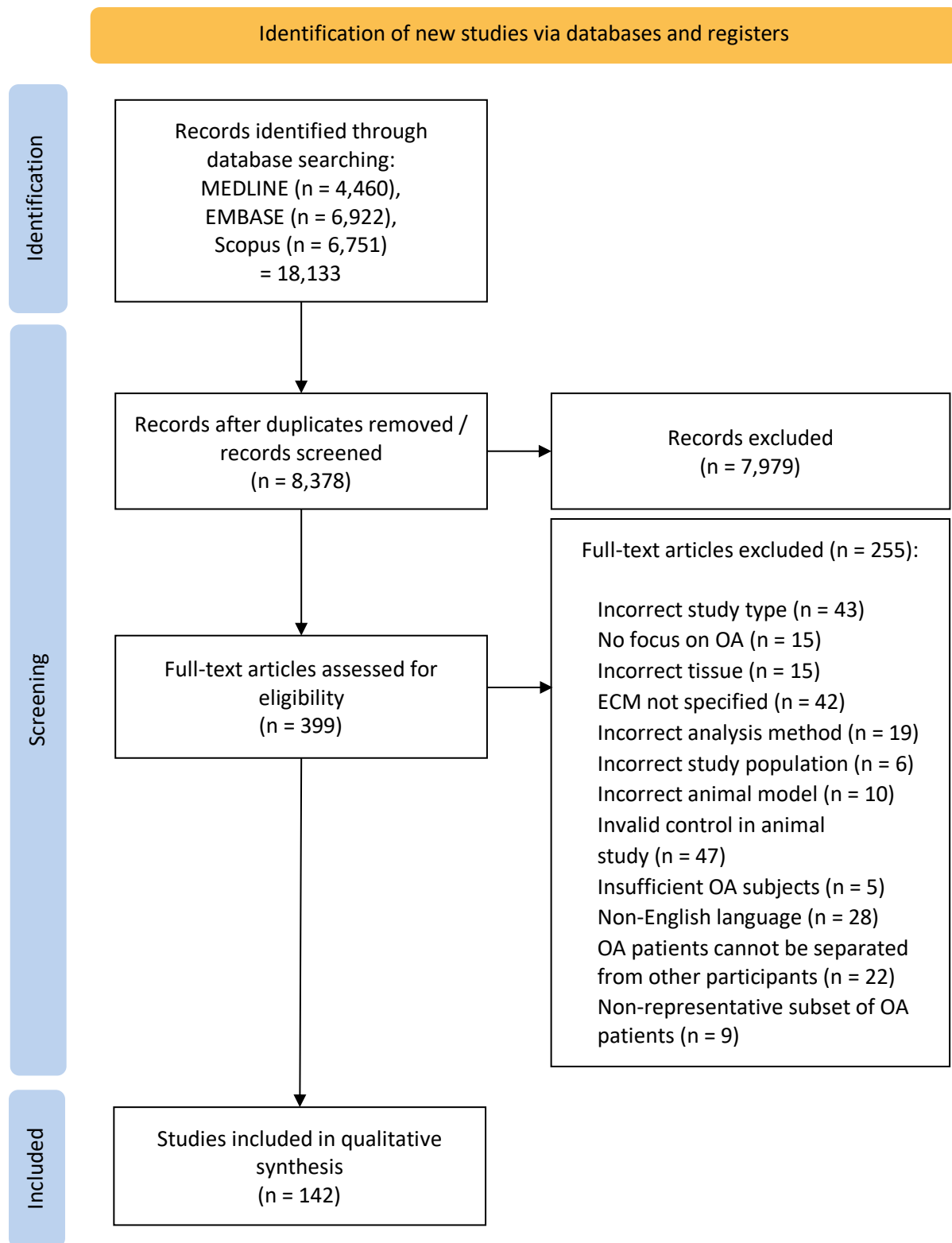
153 sex, body mass index (BMI) and disease severity were recorded, as were the joint and tissue being
154 studied. Relevant ECM components and architectural features were described; comparisons to
155 control tissues and statistical analysis were noted when applicable. Results were grouped by tissue,
156 followed by ECM feature, and finally the direction of change compared to control (increase, no
157 change, decrease, or no control group present) and presented in Tables 1 (human studies) and 2
158 (animal studies). Due to the large number of different included ECM features, accepted research
159 methods, and accepted measures of effect, a quantitative meta-analysis was not deemed
160 appropriate. Bias analysis was performed by IR, with all included studies assessed using the 2015
161 Office of Health Assessment and Translation (OHAT) Risk of Bias Rating Tool for Human and Animal
162 Studies. The results of the bias analysis can be found in Supplementary Table 3.

163 **3** **Results**

164

165 **3.1. Study overview**

166 18,133 potentially relevant articles were identified by the search strategy (Figure 1). Following the
167 removal of duplicates, 8,378 abstracts were screened. Of the 399 studies assessed for eligibility at
168 full-text screening, 142 met all criteria for inclusion in this review. The characteristics of all included
169 studies are summarised in ***Supplementary Tables 1 and 2 (human and animal studies, respectively)***.
170 A schematic overview of the included studies can be found in Figure 2.

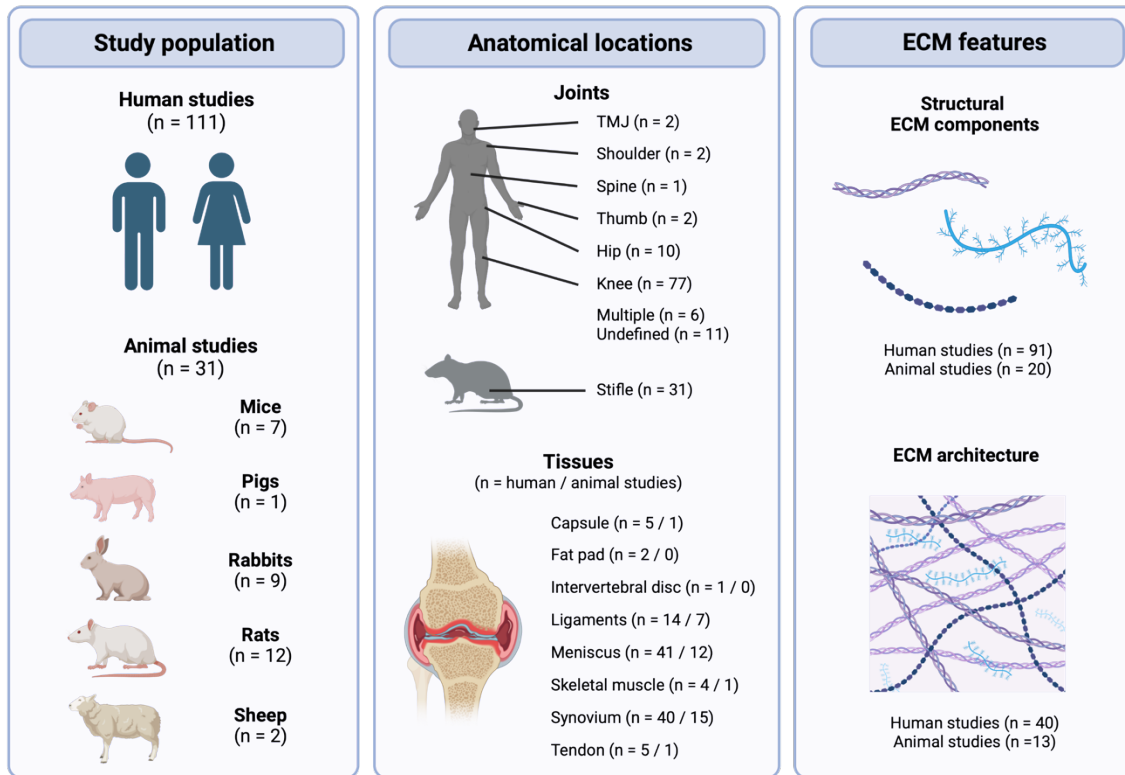


171

172 **Figure 1.** PRISMA 2022 flow diagram.

173

174



175

176 **Figure 2.** Schematic overview of the study population, anatomical locations, and ECM features

177 studied in the included studies. Created with BioRender.com.

178

179

180 **3.2 Human studies**

181 Most studies investigated meniscus (n = 41) and synovium (n = 40), followed by ligaments (n = 14),

182 tendon (n = 5), capsule (n = 5), skeletal muscle (n = 4), fat pad (n = 2) and intervertebral disc (n = 1)

183 (Supplementary Table 1). Studies mostly commonly investigated the knee joint (n = 77), but papers

184 on hip (n = 10), thumb (n = 2), temporomandibular joint (TMJ) (n = 2), shoulder (n = 2), and spine OA

185 (n = 1) were also identified. While most studies on synovium, tendon, and capsule focussed on the

186 presence/absence and distribution of specific ECM components, a large proportion of the papers on

187 meniscus and ligaments investigated ECM architecture and viscoelastic properties (Table 1).

188

189 **3.2.1 Capsule in human OA**

190 Of 5 studies which assessed the capsule (hip (n = 3), knee (n = 2)) [25–29], 4 were published before
191 the year 2000. These studies covered both ECM components and architecture, but no two studies
192 investigated the same ECM feature. Of note, DiFrancesco *et al.* (1995) studied several different ECM
193 features (calcification, collagen fibre organisation, elastic fibres, and GAG/proteoglycan content) in
194 parallel[27], providing an overview of this tissue in OA.

195

196 3.2.2 Fat pad in human OA

197 Two studies were identified for infrapatellar fat pad[30, 31]. Grevenstein *et al.* (2020) showed no
198 change in COMP content between OA and control fat pads[30] and Belluzzi *et al.* (2020) showed that
199 there was a decrease in collagen I and III expression in OA fat pads compared to controls [31].

200

201 3.2.3 Intervertebral disc in human OA

202 One study was identified for intervertebral disc. Cheng *et al.* (1996) showed an increase in
203 calcification with increasing OA grade in intervertebral discs[32].

204

205 3.2.4 Ligaments in human OA

206 Out of the 14 studies on ligaments, 12 studies focussed on ACL and/or PCL of the knee[33–44], and
207 two studies looked at ligaments in the thumb, one covering the palmar beak ligament and one
208 covering volar anterior oblique (AOL) and dorsoradial (DRL) ligaments[45, 46]. Studies mostly
209 focussed on collagen fibre organisation, which generally decreased in OA compared to control[38,
210 39, 41]. Studies without controls report disorganised and irregular collagen fibre organisation in OA
211 ligaments. Other identified studies confirmed the presence of aggrecan, collagens I, II, and III, and
212 decorin, suggest an increase in calcification and GAG/proteoglycan content, and no change in overall
213 collagen content.

214

215 3.2.5 Meniscus in human OA

216 Studies on human meniscus (n = 41) covered a wide range of ECM components, architectural
217 changes, as well as measurements of viscoelastic properties[47–87]. Most studies concur on an
218 increase in calcification and GAG/proteoglycan content, and consistently show a decrease in
219 collagen fibre diameter and organisation. The presence or change in many other ECM components
220 has been studied, including aggrecan, biglycan, cartilage intermediate layer protein, collagens and
221 collagen crosslinks, COMP, decorin, fibromodulin, GAG components, hydroxyproline, keratocan,
222 lubricin, and lumican. Most notable, all proteomics studies included in this systematic review
223 evaluated human OA meniscus, identifying a range of ECM and ECM-associated proteins[52, 76, 79].
224 Two of these studies (Folkesson *et al.* (2020) and Roller *et al.* (2015)) also analysed control samples
225 and found several proteins to be changed in OA compared to control tissue. For example, both
226 studies report an increase in collagen type VI alpha 1 and collagen type VI alpha 2 in OA, and
227 Folkesson *et al.* (2020) found a change in protein abundance in several small leucin-rich
228 proteoglycans, such as an increase lumican and decrease in decorin, an increase in the proteoglycans
229 aggrecan and versican, and a decrease in collagens type III and V [52, 79]. Finally, the results on
230 viscoelastic properties are conflicting: whereas some studies show an increase in elastic modulus
231 [66] and instantaneous modulus[77], another study showed a decrease in these moduli [47].

232

233 3.2.6 Skeletal muscle in human OA

234 All four studies on human skeletal muscle studied the ECM components in the vastus medialis or
235 vastus lateralis of the quadriceps muscle[88–91]. These studies demonstrated the presence [89] or
236 increase [91] in collagens type I, III, and IV compared to control. In addition, these studies show the
237 presence of calcification and laminin[88, 91], and an increase in collagen and GAG content[90].

238

239 3.2.7 Synovium in human OA

240 Synovial tissue was studied in several joints, including 17 studies on the knee[68, 92–107], 5 studies
241 on hip[108–112], 6 studies used a combination of knee and hip synovium [113–118], 2 studies on

242 TMJ[119, 120], and 10 studies did not report the joint site[121–130]. The ECM components that
243 were most often studied in human synovium were collagens, fibronectins, and laminins. Other ECM
244 features covered by the included studies are calcification, collagen content, collagen fibre
245 organisation, collagen cross-links, COMP, elastin, fibromodulin, GAG components, latent TGF- β -
246 binding protein 1, lumican, reticulin, and vitronectin. While the presence and tissue distribution of
247 these components has been clearly shown by several studies, the changes between OA and normal
248 tissue remains unclear with most studies lacking healthy control groups; instead, OA is often the
249 comparator group in studies investigating rheumatoid arthritis.

250

251 3.2.8 Tendon in human OA

252 Human tendon studies covered a range of different tendons across the body, including Achilles,
253 (long head of) biceps, subscapularis, gluteus medius, and internal obturator[131–135]. Discordant
254 results between studies of anatomically distinct tendons are unsurprising, but disagreement was
255 also seen for two studies on biceps tendon. For example, GAG/proteoglycan content was increased
256 in the long head of biceps and internal obturator tendon[134, 135], unchanged in another study on
257 biceps tendon and subscapularis tendon[132], and decreased in gluteus medius tendon in OA
258 compared to control[133]. Similarly, increased calcification was seen in obturator tendon[135], while
259 there was no difference in subscapularis, and a decrease in biceps tendon[132]. In terms of
260 architecture, 3 out of 4 studies reporting on collagen fibre organisation report a decrease in
261 organisation[132, 133, 135], while the last reported no difference compared to control[134]. An
262 increase in collagen fibre diameter was found in internal obturator and biceps tendon[132, 135],
263 while no difference was seen in subscapularis and gluteus medius tendons[132, 133]. Finally, no
264 difference was found in the protein expression of collagen I and II and decorin[134].

265

266 **3.3 Animal studies**

267 Animal studies followed a similar pattern as human studies regarding the most studied tissues:
268 synovium (n = 15), meniscus (n = 12), ligament (n = 6), skeletal muscle (n = 1), tendon (n = 1), and
269 capsule (n = 1) (Supplementary Table 2). A broad range of species, strains, and models were used, all
270 looking at the stifle joint of these animals. Overall, these studies generally found increases in ECM
271 components such as collagen and disrupted ECM architecture, including a decrease in collagen fibre
272 organisation in most tissues (Table 2). Viscoelastic properties were mainly studied in meniscus,
273 where the elastic and instantaneous modulus tended to decrease.

274

275 3.3.1 Capsule in animal models of OA

276 Only one study was identified on capsule. Loeser *et al.* (2013) studied capsule in the DMM model in
277 CD57BL/6 mice[136]. Collagen III was found to be diffusely expressed in OA capsule, and mostly
278 present in vascular endothelium. Interestingly, this study also assessed the meniscus, ligament, and
279 synovium, taking a whole-joint approach to OA; they report a diffuse distribution of collagen type III
280 similar to capsule in ligaments and synovium, while there was a pericellular distribution in meniscus.

281

282 3.3.2 Ligament in animal models of OA

283 Ligaments were studied in animal models of OA in 4 studies using mouse models[136–139], 1 study
284 using a rabbit model[140], and 2 studies using sheep models[141, 142]. A decrease in collagen fibre
285 organisation was reported by two studies[140, 141]. All other reported ECM features were only
286 present in one study. These features include calcification, mineralisation, collagen II and III, collagen
287 cross-links, collagen fibre diameter, GAG/proteoglycan content, and mechanical strength.

288

289 3.3.3 Meniscus in animal models of OA

290 ECM changes in meniscus in animal models of OA were investigated by 5 studies using mouse
291 models [136, 138, 143–145], 5 studies using rabbit models [146–150], 1 study using a rat
292 model[151], and 1 study using a pig model[152]. Overall, these studies show an increase in

293 calcification and collagen types I, II, III, and X, and a decrease in collagen fibre organisation. Most
294 studies show a decrease in GAG/proteoglycan content and viscoelastic properties in at least parts of
295 the meniscus. In addition, thickening of the collagen fibres and no change in fibromodulin were
296 found.

297

298 *3.3.4 Skeletal muscle in animal models of OA*

299 One study was identified that investigated skeletal muscle. Shi *et al.* (2020) studied the elastic
300 modulus in biceps femoris and rectus femoris muscles in an adapted Videman method in rabbits;
301 they report an increase in elastic modulus in OA compared to control[153].

302

303 *3.3.5 Synovium in animal models of OA*

304 Synovium was investigated in 2 studies using mouse models[136, 143], 10 studies using rat
305 models[154–163], and 2 studies using rabbit models[164, 165], and 1 study using a sheep model of
306 OA[141]. All studies on calcification, collagen content, and collagen I showed an increase in OA
307 compared to control. However, results on collagen fibre organisation and collagen fibre diameter
308 were less clear, with some studies reporting no change, while others reported a decrease in collagen
309 fibre organisation and increase in collagen fibre diameter. Other studied features included type III
310 collagen, COMP, fibromodulin, lubricin, and viscoelastic properties (elastic modulus), which were all
311 only reported on by a single study.

312

313 *3.3.6 Tendon in animal models of OA*

314 Tendon was investigated in one study by McErlain *et al.* (2008) using an ACL transection model in
315 rats. They found calcification of the patellar tendon to be more common in OA than control
316 animals[166].

317

318

319 **3.4 Bias analysis**

320 The risk of bias varied between studies but was generally high (Supplementary Table 3). The
321 potential for confounding bias was common, with many human studies failing to report on the age,
322 sex and BMI of participants. Frequently, OA diagnoses were stated without reference to the
323 diagnostic criteria used. Most studies failed to report on the blinding of assessors, even when
324 qualitative histological observations were made. Purely qualitative observations were common,
325 although semi-quantitative scoring systems were increasingly used in more recent studies. However,
326 many quantitative and semi-quantitative differences between healthy and osteoarthritic tissues
327 were not statistically analysed.

328 **Table 1.** Structural ECM components and architectural features in non-cartilage soft tissues of human osteoarthritic joints.

329 **Abbreviations:** AA = amino acid, ACL = anterior cruciate ligament, CILP = cartilage intermediate layer protein, CHS = chondroitin sulphate, CPPD = calcium
 330 pyrophosphate deposition, CT = computed tomography, DS = dermatan sulphate, ECM = extracellular matrix, EDA = ethylenediamine, ED + F = enzymatic
 331 digestion and fractionation, EM = electron microscopy, FCCIS = fine cationic colloidal iron staining, FITR = Fourier-transformed infrared spectroscopy, Fn =
 332 fibronectin, F-UAA-EP = Fractination - uronic acid assay – electrophoresis, GAG = glycosaminoglycan, HA = hyaluronic acid, H&E = haematoxylin and eosin,
 333 HS = heparan sulphate, IB = immunoblotting, IEC = ion exchange chromatography, IHC = immunohistochemistry, IP = immunoprecipitation, IRT =
 334 indentation relaxation tests, KL-grade = Kellgren-Lawrence grade, LC = liquid chromatography, LM = light microscopy, N/A = not applicable, NI =
 335 nanoindentation, NR = not reported, OA = osteoarthritis, PAS = periodic acid Schiff, PCL = posterior cruciate ligament, PLM = polarised light microscopy, qual
 336 = qualitative, quant = quantitative, s-quant = semi-quantitative, SPA = sandwich-binding protein assay, TEM = transmission electron microscopy, WB =
 337 western blot.

Tissue	ECM feature	Change vs control	Description of feature in OA tissue	Measurement technique(s)	Analysis	Stat. test	Ref
Capsule	Calcification	No control	Minute shards of calcific detritus commonly abutted on the degenerative areas.	NR	Qual	N/A	[27]
	Collagen content	No control	Capsule tissue is mostly collagenous (range 15.6-88.8% of area; average 57.0% and 70.4% in two different OA groups)	Trichrome	Qual	N/A	[26]
	Collagen cross-links	↑	All OA samples contained reducible cross-links not seen (or in minor quantities) in the joint capsule of healthy adults, namely intermediate Schiff-base cross-links.	IEC	Quant	No	[29]
	Collagen fibre organisation	↓	Disordered compared to control: the normal, smooth, orderly arrangement of collagen fibres is lost and replaced by a jumbled mass like a tangled Klein of wool.	EM	Qual	N/A	[25]
	ECM organisation	No control	Matrix appeared pale and more fibrillary and whorled in degenerated than in non-degenerated chondroid areas.	EM, Safranin O-Fast Green	Qual	N/A	[27]

	Elastic fibres	No control	Degenerated areas were more intensely stained than the non-degenerated chondroid areas.	Adehyde-fuchsin	Qual	N/A	[27]
	GAG / proteoglycan	No control	Degenerated areas were less intensely stained with Safranin O	Safranin O	Qual	N/A	[27]
	GAG: Chondroitin sulphate (CHS)	No control	Chondroitin-6-sulphate (CHS-C) present in joint capsule; major polysaccharide component together with DS and HA. Ratio of CHS-C to DS of approximately 1:1.	ED + F	Quant	N/A	[28]
	GAG: Dermatan sulphate (DS)	No control	Present in joint capsule; major polysaccharide component together with CHS-C and HA. Ratio of CHS to DS of approximately 1:1.	ED + F	Quant	N/A	[28]
	GAG: Hyaluronic acid (HA)	No control	Present in joint capsule. Major polysaccharide component together with CHS-C and DS.	ED + F	Quant	N/A	[28]
	GAG: Hexosamine	No control	~1.1% hexosamine concentration in joint capsule, of which ~80% was glucosamine and ~20% was galactosamine	ED + F	Quant	N/A	[28]
Fat pad	Collagen I	↓	From ~0.6% in controls to ~0.1% area stained in end-stage OA	Sirius red	Quant	Yes	[31]
	Collagen III	↓	From ~1.6% in controls to ~0.4% area stained in end-stage OA	Sirius red	Quant	Yes	[31]
	COMP	=	Variable staining, more intense in fibrous than adipose regions of fat pad	IHC, IB	S-quant	Yes	[30]
Intervertebral disc	Calcification	No control	Increasing calcification with increasing OA severity	CT	Quant	N/A	[32]
Ligament	Aggrecan	No control	Weak expression around cells in OA ACL and PCL, only in higher grades of degeneration	IHC	Qual	N/A	[37]
	Calcification	↑	Present in 3-31% of ACL tissue area	not specified	Quant	No	[36]
	Collagen content	=	63.4% (femoral region); 65.1% (midportion); 59.2% (tibial side); reduced collagen occupancy in PCL with increasing degree of OA	TEM; LM	Quant	Yes	[34]
	Collagen I	No control	Present throughout most of ECM of ACL and PCL; prevalence similar with different degrees of degeneration	IHC	Qual	N/A	[37]
	Collagen II	↑	Present in areas of fibrocartilaginous metaplasia in ACL; appears increased	IF	Qual	N/A	[36]
		No control	Focal deposits found around cells in OA ACL and PCL, only present in higher grades of degeneration	IHC	Qual	N/A	[37]
	Collagen III	No control	Present in ECM surrounding cells in early and advanced degeneration in OA ACL and PCL	IHC	Qual	N/A	[37]
Collagen fibre density	No control	Mean fibre density in ACL: 142.51/μm ²	TEM	Qual	N/A	[44]	

	Collagen fibre diameter	=	84.0nm (femoral region); 81.6nm (midportion); 85.5nm (tibial region). Fibril diameter of PCL smaller in OA patients with marked degeneration (75.1 nm) than those with less marked degeneration (87.5 nm)	TEM	Quant	Yes	[34]
		No control	Fibres most commonly 50-100nm in diameter (0-50nm: 9.0%, 50-100nm: 60.6%, 100-150nm: 19.5%, 150-200nm: 10.8%, >200nm: 0.0%) in ACL	SEM/TEM	Qual	N/A	[44]
	Collagen fibre organisation	↓	Organisation in ACL and PCL decreases with increased OA severity; fibre disorganisation higher in ACL than PCL	H&E + LM	S-quant	Yes	[38]
			Collagen fibre degeneration in PCL positively correlated with severity of OA	Van Gieson and Gomori	S-quant	Yes	[39]
			Collagen fibres in ACL frequently disoriented compared to normal group	H&E + LM	Qual	N/A	[41]
		No control	Disorganised (ACL & PCL)	H&E + LM	Qual	N/A	[33]
			Range from normal to degeneration in >2/3 of tissue (ACL & PCL); ACL more likely to have significant degeneration (no stats test); positive correlation between ACL appearance and collagen degeneration in PCL	H&E + LM	S-quant	N/A	[35]
			Increasingly severe OA associated with reduced collagen organisation at bony insertion of palmar beak ligament	H&E + LM	Qual	N/A	[45]
			Highly variable in ACL and PCL; reduced organisation seen as grade of ligament degeneration increased	H&E + LM	Qual	N/A	[37]
			Most PCLs (65.2%) showed severe collagen fibre degeneration; no correlation between OA grade and fibre degeneration	Gomori trichrome & H&E	S-quant	N/A	[40]
			Dorsoradial ligament: organized collagen bundles with collinear orientation. Anterior oblique ligament: disorganized connective tissue with few collagen fibers, appearance similar to synovial tissue	IF	Qual	N/A	[46]
			Range from parallel to irregular in PCL; organisation decreased with higher OA grades	von Gieson stain + LM	S-quant	N/A	[42]
			Organisation normal in 79% of PCL samples	H&E/Alcian blue + LM	S-quant	N/A	[43]
			Collagen fibres in ACL largely parallel but disordered particularly at bony insertions	Toluidene blue + H&E	Qual	N/A	[44]
		Decorin	No control	Greatest staining in the middle region of the ACL	IHC	Qual	N/A
GAG / proteoglycan	↑	Increased in ACL, especially in areas of cartilaginous metaplasia	Safranin-O	Qual	N/A	[36]	
	No control	Present around cells in ACL and PCL	Alcian blue	Qual	N/A	[37]	
Meniscus	Aggrecan	↑	Strong (significant) increase in staining, which was more prominent in the deep zone than the surface zone	IHC	S-quant	Yes	[83]

	No control	Highest density of staining around cell clusters, followed by staining in degenerative areas, and finally staining in intact areas.	IHC	Quant	N/A	[65]	
Biglycan	=	No change in fragmentation compared to age-matched controls	WB	Qual	N/A	[70]	
Calcification	↑	Extensive calcified areas; increase in size and frequency compared to control	Alizarin red	Qual	N/A	[49]	
		Significant increase in calcification in both medial (11.9% vs 5.2%) and lateral regions (11.1% vs 4.2%), as well as both menisci (11.5% vs 4.7% of surface area)	H&E	Quant	Yes	[69]	
	↑/=	Increase in lateral anterior and medial anterior regions. Non-significant increase in lateral posterior and non-significant decrease in medial posterior regions.	Von Kossa	S-quant	Yes	[47]	
	No control		Heterogeneous distribution, indicating micro-calcifications; contained within both apatite and calcium pyrophosphate crystals in cartilaginous areas	X-ray AS, X-ray F, FTIS	Quant	N/A	[50]
			Calcified areas found	Alizarin red	Qual	N/A	[60]
			Presence of mineral deposition; approximately 80% of mineral areas co-localised with CPPD crystals.	Alizarin Red + Eosin Y	Qual	N/A	[64]
			Calcium deposits found in 16% of OA menisci	IHC	Qual	N/A	[67]
			Increase in calcification in menisci with complete tears vs menisci with no or partial tears	Alizarin Red	Quant	N/A	[75]
			Calcification in all OA menisci, but not the two adults in normal group. Small/medium-sized deposits at the edges of sections (almost all patients); clusters of small-sized deposits inside the meniscus (65% of patients); and widespread medium/large-sized deposits (35% of patients).	Alizarin red	S-quant	Yes	[82]
			4/18 patients had calcification	X-ray	Qual	N/A	[84]
Extensive meniscal calcification			H&E	Qual	N/A	[87]	
Cartilage intermediate layer protein (CILP)	↑	CILP was abundant in the matrix separating lacunae of the central region, but undetectable in peripheral regions. Sparse expression in areas of apoptosis and calcification.	IHC	Qual	N/A	[60]	
Collagen content	↑	Significant increase in collagen content compared to control	Colorimetry	Quant	Yes	[78]	
	=	No difference in hydroxyproline content (major component of collagen)	Amino acid analyser system	Quant	Yes	[84]	
	↓	Statistically significant decrease in staining in OA (grade 0-2) compared to normal (grade 2)	Picrosirius red	S-quant	Yes	[83]	
		Significant decrease in collagen content in degenerated vs non-degenerated areas	Colorimetry	Quant	N/A	[54]	

		No control	Collagen per dry mass did not show much variation among anterior, central, and posterior regions but varied in the radial direction: outer region was higher than other regions. Lower content in medial than lateral meniscus. Collagen per wet mass showed little variation.	Spectrophotometry	Quant	N/A	[81]
			Collagen content decreased from no to high degeneration; no differences between regions.	IR spectroscopy	S-quant	N/A	[86]
	Collagen cross-links	↑/↓	Significant decrease in mature cross-links pyridinoline and deoxypyridinoline in OA compared to controls. Pentosidine (senescent cross-link) was non-significantly increased.	HPLC	Quant	Yes	[84]
	Collagen I	↓	Significant decreased throughout meniscus, particularly in the middle zone and deep zones, indicating greater decrease in the middle and deep zones than in the surface zones.	IHC	S-quant	Yes	[83]
		No control	Non-degenerated menisci: expression varied by subject; expression throughout tissue except peripheral vascular area; intense expression in circumferential and radial fibres. Degenerated menisci: expression decreased in degenerated areas and was almost absent in severely degenerated menisci.	IHC	Quant	N/A	[71]
			Decrease in staining with increase in damage (no tear > partial tear > complete tear).	IHC	Quant	N/A	[75]
			Expression decreased in menisci that showed degeneration (compared to samples without degeneration), particularly in the body of meniscus using a S-quantitative score, but not using a quantitative score.	IHC	S-quant / quant	N/A	[80]
	Collagen II	↓	Significant prominent decrease in type II collagen in surface, middle, deep zones.	IHC	S-quant	Yes	[83]
		No control	Highest to lowest expression: anterior, central, and posterior region.	IHC	Quant	N/A	[56]
			Highest density of staining around cell clusters, followed by staining in degenerative areas, and finally staining in intact areas.	IHC	Quant	N/A	[65]
			Non-degenerated menisci: expression similar between subjects; intense expression at exterior peripheral border, on meniscal surface, and along vessels but not in any internal region that expressed collagen II. Degenerated menisci: expression decreased in degenerated areas but increased slightly in degenerative menisci; expression almost absent in severely degenerative menisci.	IHC	Quant	N/A	[71]
			Increase in staining with increase in damage (no tear > partial tear > complete tear).	IHC	Quant	N/A	[75]
	Collagen III	No control	Non-degenerated menisci: expression similar between subjects; expression throughout tissue except peripheral vascular area; intense expression in circumferential and radial fibres. Degenerated menisci: expression decreased in degenerated areas and was almost absent in severely degenerative menisci.	IHC	Quant	N/A	[71]
	Collagen X	No control	Positive staining in superficial layers	IHC	Qual	N/A	[57]
			High levels throughout the tissue; co-localised with calcium mineral staining	IHC	Qual	N/A	[64]
Collagen fibre diameter	↓/=	Collagen fibril diameter was decreased and number of fibrils per area was significantly increased in medial menisci, but not in lateral menisci.	TEM	Quant	Yes	[63]	
	↓	Decreased diameter in OA compared to control: 35-45 nm in OA compared to 70-80 nm in controls	TEM	Quant	No	[49]	

		No control	Average transverse collagen diameter was 95.39 +- 15.87 nm and longitudinal diameter was 96.3 +- 14 nm for control method	TEM	Quant	N/A	[58]
Collagen fibre organisation		↓/=	Percentage of area occupied by fibrils was reduced in medial but not in lateral menisci.	TEM	Quant	Yes	[63]
	↓		Disorganized collagen fibres in OA; collagen fibres were aligned with a regular pattern of distribution and diameter in controls	TEM	S-quant	No	[49]
			Organised collagen network was lost in medial OA meniscus; medial OA meniscus 24-25 degrees lower orientation angles compared to lateral OA or donor menisci	μCT	Quant	N/A	[61]
			Lateral menisci: fibril bundles tended to be obscure in the surface regions, but were well preserved in the inner area. Medial menisci: less even distribution of fibril bundles; tended to be thicker than controls and were not clearly recognised in the surface regions; obvious wearing and fraying in degenerated areas.	H&E, Masson's trichrome,	Qual	N/A	[63]
			Some separation of individual collagen fibre bundles in patients without a tear; disorganised collagen architecture in patients with a partial tear; collagen architecture completely disorganised.	Safranin O, H&E, Picosirius red	Qual	N/A	[75]
			Collagen networks were less organised and less compact than the well-organised, parallel-arranged, and compact collagen bundles in normal menisci.	Picosirius red, H&E	Qual	N/A	[83]
			Collagen fibres were separated and concentrated in the OA meniscus. Also homogenised collagen fibres surrounding cells	H&E	Qual	N/A	[48]
	No control		Fibre angle compared to tidemark remained constant in medial entheses but increase in lateral entheses as tissue transitioned from ligament zone to subchondral bone. Significant differences in fibre angle and deviation in calcified fibrocartilage of lateral meniscus.	Picosirius red + PLM	Quant	N/A	[55]
			Tears in collagen fibres found in all studied OA subjects	H&E	Qual	N/A	[74]
			A collection of transverse collagen fibres (transverse ligament) were found running from the synovial edge into the vascular region, which presented a "tree-like" formation of fibres interwoven into the avascular region in all samples	H&E	Qual	N/A	[85]
COMP	No control	Significant decrease in staining: in OA tissue the median staining of ECM was 0 (range 0-1); it was 1 (range 0.66-3) in tissue from meniscal horn tears	IHC	S-quant	Yes	[67]	
Compressive modulus	↓		Instantaneous and equilibrium elastic modulus decreased, particularly in lateral anterior and medial anterior regions	NI	Quant	Yes	[47]
			Aggregate modulus of OA medial menisci was 40% lower than that of control medial menisci, whereas it differed little in lateral menisci	Indentation	Quant	Yes	[63]
	No control	Lateral anterior, lateral posterior, and medial anterior regions showed decreasing instantaneous and equilibrium moduli with increasing degeneration. The medial posterior region had no apparent trend in mechanical properties with degeneration	IRT	Quant	N/A	[51]	
Decorin	↑	Increase in fragmentation compared to age-matched controls	WB	Qual	N/A	[70]	

	Fibromodulin	=	No change in fragmentation compared to age-matched controls	WB	Qual	N/A	[70]
	GAG / proteoglycan	↑	Increase in GAG compared to control	Safranin O/fast green	Qual	N/A	[49]
			Intense proteoglycan staining in OA, weak staining in healthy tissue	Safranin O/Fast Green	Qual	N/A	[66]
			Increase in median Safranin-O score throughout the whole meniscus (3 vs 1 in control).	Safranin O	S-quant	Yes	[77]
			Significant increase in proteoglycan content (overall, medial, and lateral) compared to controls; significant increase in medial compared to lateral OA menisci.	Spectrophotometric analysis	Quant	Yes	[78]
			Significantly stronger proteoglycan staining in OA than normal menisci. The increase of safranin-O staining was more prominent in the deep zone than that in the surface zone	Safranin-O Fast green, Alcian Blue, Toluidine Blue	S-quant	Yes	[83]
		No control	Zone 1 (basis to the most peripheral blood vessel): mostly neutral carbohydrates but acid mucopolysaccharide around vessels. Zones 2 & 3 (peripheral blood vessel to the centre in two halves): zone 2 mostly acid mucopolysaccharide; zone 3 mix of neutral carbohydrates and acid mucopolysaccharides, with acid mucopolysaccharides in central meniscus, neutral carbohydrates at the top and some edges.	Alcian blue/PAS	S-quant	N/A	[53]
			Higher proteoglycan staining in anterior 1/3 than central or posterior thirds	Safranin O	Quant	N/A	[56]
			Weak proteoglycan staining in superficial regions	Safranin O	Qual	N/A	[57]
			Specific proteoglycan staining in/around meniscal cell clusters	Safranin O	Qual	N/A	[65]
			42% of OA menisci had none/weak staining.	Alcian blue	S-quant	No	[67]
	GAG thickness	↑/=	Non-degenerated: GAG expression on surface of meniscus, vessels, and internal regions where collagen II was expressed. Degenerated: increase in GAG expression.	IHC	Quant	N/A	[71]
			Proteoglycan score 2.7 ± 0.4 (score 0-3)	Safranin O-Fast Green	S-quant	N/A	[72]
			Little variation in sGAG per dry mass among anterior, central, and posterior regions. Outer and middle regions were higher than inner region. Higher in medial than lateral meniscus. sGAG per wet mass was higher in medial meniscus for the anterior and central regions, but not the posterior region. Content highest to lowest: middle > outer > inner region. Staining confirmed the greatest intensity in middle and lowest inner regions.	DMMB assay / Safranin-O	Quant	N/A	[81]
			Significantly more GAG staining in vascular than avascular areas of meniscus. The inner borders stained more strongly than the other zones.	Toluidine blue	S-quant	N/A	[85]
Non-significant decrease in proteoglycan content with increasing degeneration; no differences between regions.			IR spectroscopy	Quant	N/A	[86]	
			Increased in the lateral anterior, medial anterior and medial posterior regions of calcified zones; no difference in uncalcified zones	Toluidine blue	Quant	Yes	[47]

	GAG: chondroitin sulphate (CHS)	=	CHS-A and CHS-C present. OA menisci showed same composition as those from a comparable age group.	F-UAA-EP	Quant	No	[62]
	GAG: dermatan sulphate (DS)	=	Present. OA menisci showed same composition as those from a comparable age group.	F-UAA-EP	Quant	No	[62]
		No control	Staining present in fibrous matrix of the superficial layer	IHC	Qual	N/A	[68]
	GAG: Hexosamines	No control	Significant increase in hexosamine content in degenerated vs non-degenerated areas	Colorimetry	Quant	N/A	[54]
	GAG: Hyaluronic acid (HA)	=	Present. OA menisci showed same composition as those from a comparable age group.	F-UAA-EP	Quant	No	[62]
		No control	Strong staining in vascular zone, particularly in intima and subintima, in the vicinity of blood vessels and fatty tissue; moderate/weak staining in the inner zones	IHC	S-quant	N/A	[53]
	GAG: heparan sulphate (HS)	=	Present. OA menisci showed same composition as those from a comparable age group.	F-UAA-EP	Quant	No	[62]
	GAG: Keratan sulphate (KS)	=	Present. OA menisci showed same composition as those from a comparable age group.	F-UAA-EP	Quant	No	[62]
	Hydroxyproline	=	No difference in hydroxyproline content	AA analyser system	Quant	Yes	[84]
	Keratocan	=	No change in fragmentation compared to age-matched controls	WB	Qual	N/A	[70]
	Lubricin	↓	Weak expression in OA (moderate expression in outer and middle rim, and weak expression in inner rim), while expression was strong in normal donors in all compartments.	IHC	S-quant	No	[73]
		No control	Staining in all patients, ranging from weak to very strong. Matrix staining strongest directly beneath the surface and decreasing in intensity in deeper tissue. Discrete granular deposits observed. Staining followed crimp and trabecular patterns of collagen fibrils.	IHC	S-quant	N/A	[87]
	Lumican	=	No change in fragmentation compared to age-matched controls	WB	Qual	N/A	[70]
	Viscoelastic properties	↑	Wide distribution of elastic moduli demonstrates stiffer mean values in the outer (364.3 ± 72.2 kPa), middle (401.9 ± 39.2 kPa), and inner regions (365.9 ± 106.5), compared to 303.0 ± 28.3 kPa, 282.4 ± 30.2 kPa, and 274 ± 8.7 kPa, respectively, in aged normal donors	AFM	Quant	No	[66]
↑/=		Non-significant ($p = 0.06$) increase in instantaneous modulus in posterior horn (0.17 ± 0.1 MPa vs 0.12 ± 0.07 MPa in control) and entire meniscus (0.17 ± 0.07 MPa vs 0.14 ± 0.08 MPa in control), but significant increase in maximum applied load for both.	Indentation test	Quant	Yes	[77]	
=/↓		Aggregate modulus of OA medial menisci was 40% lower than that of control medial menisci, whereas it differed little in lateral menisci	Indentation	Quant	Yes	[63]	
↓		Instantaneous and equilibrium elastic modulus decreased, particularly in lateral anterior and medial anterior regions	NI	Quant	Yes	[47]	

	No control		Lateral anterior, lateral posterior, and medial anterior regions showed decreasing instantaneous and equilibrium moduli with increasing degeneration. The medial posterior region had no apparent trend in mechanical properties with degeneration	IRT	Quant	N/A	[51]	
			No significant differences were found between degenerative groups for the tensile modulus. Average tensile modulus: lateral anterior 128.8±62.5 MPa, lateral posterior 119.4±75.6 MPa, medial anterior 112.5±56.6 MPa, and medial posterior 95.9±55.6 MPa. Regardless of degenerative grade or region the average strain at failure was 18.2±5.2%.	Pulling to failure	Quant	N/A	[51]	
			Tensile elasticity modulus was 11.66 MPa for control method (cryoprotective preservation). The stress-strain curve revealed a slow-slope curve with a non-abrupt rupture (ductile material). Different results were found for other methods of preservation	Tensile testing machine	Quant	N/A	[59]	
			The average values for equilibrium compressive modulus, dynamic compressive modulus, and dynamic shear modulus were 52.2 (39.9, 72.6) kPa, 212.3 (157.8, 282.3) kPa, and 15.5 (12.0, 20.1) kPa, shown as mean (95% upper limit, 95% lower limit) respectively. Overall, mechanical properties exhibited little regional variation.	Torsional rheometer / Microtester	Quant	N/A	[81]	
			Equilibrium modulus decreases with increased degeneration (not dependent on region). Hydraulic permeability increased 50% from no to high degeneration, with the anterior being lower than intermedia and posterior regions. Non-significant decrease in tensile modulus from no to high degeneration; no difference between regions.	Compression / tensile test	Quant	N/A	[86]	
	ECM composition (proteomics)	↑/=/↓	Differences in medial region, but not in lateral region. Full details in paper.	MS	Quant	Yes	[52]	
			Both in- and decreases found in ECM components in OA compared to control. Full details in paper.	MS	Quant	No	[79]	
		No control	131 ECM or ECM-associated proteins were identified in meniscal tissue by MatrisomeDB 2.0. COMP, CILP, aggrecan, and 7 collagens were dominantly identified in both lateral and medial menisci. 14 ECM proteins were differentially expressed between medial and lateral meniscus. Full details in paper.	MS	Quant	N/A	[76]	
	Skeletal muscle	Calcification	No control	Marked calcification of perimysium & juxtavascular tissue of the vastus medialis muscle	H&E + LM	Qual	N/A	[88]
		Collagen content	↑	Collagen content higher in OA vastus lateralis muscle vs controls and negatively correlated with muscle strength	Sirius red	Quant	Yes	[90]
Collagen I		↑	Weak to moderate staining of OA vastus lateralis muscles, appears increased compared to control	IHC	S-quant	No	[91]	
		No control	All vastus lateralis muscles stained at least weakly positive	IHC	S-quant	N/A	[89]	
Collagen III		↑	Light to strong staining of OA vastus lateralis muscles, appears increased compared to control	IHC	S-quant	No	[91]	
		No control	All vastus lateralis muscles stained at least weakly positive	IHC	S-quant	N/A	[89]	
Collagen IV		↑	Weak to strong staining in OA vastus lateralis muscles, appears increased compared to control	IHC	S-quant	No	[91]	

		No control	All vastus lateralis muscles stained at least weakly positive	IHC	S-quant	N/A	[89]
	GAG / proteoglycan	↑	Increased GAG content in OA vastus lateralis muscle vs control; GAG co-localised with collagen	Wheat germ agglutinin	Quant	Yes	[90]
	Laminin	No control	Present in the basement membrane of OA vastus lateralis muscles	IHC	Qual	N/A	[91]
Synovium	Calcification	↑	Presence of ectopic calcification in OA, but not control samples	H&E	Qual	N/A	[103]
		No control	Calcium deposits found in synovium of nearly all KL-grades, including KL 0	Alicarin red, FITR	Qual	N/A	[95]
			Primary OA: calcification present in subsynovial foci in cases with minimal hyperplasia Rapidly destructive OA: ossification was well defined in the sublining Secondary OA: large areas of calcification were observed.	H&E	Qual	N/A	[112]
			Calcium was found in most OA patients (14/16), mostly located close to the synovial surface; ~1% of the relative volume of the synovium.	IHC (Alizarin red)	S-quant	N/A	[117]
	Collagen content	No control	Found in all OA patients; ~15.37% of the volume of synovium	Movat's pentachrome	S-quant	N/A	[117]
	Collagen I	↑	Expression present and increased in sublining; present but unchanged in lining	IF	Qual	N/A	[128]
		No control	Expression in synoviocytes, their matrix, and the intimal layer of small vessels of the synovium.	IHC	Qual	N/A	[68]
	Collagen II	No control	Small cartilage particles found in OA synovium	IHC	Qual	N/A	[124]
			Collagen 2-positive fragments surrounded by lining cells of villi in all OA synovial specimens; on average 9.1 fragments (range 3-26) in each x400 magnification field	IHC	S-quant	N/A	[100]
			Cartilaginous fragments of varying sizes entrapped between synovial lining cells.	IHC	S-quant	N/A	[105]
			Cartilage/bone fragments were found in 3 out of 16 samples.	unclear	Qual	N/A	[117]
	Collagen III	↑	Present in sublining	IF	Qual	N/A	[128]
		No control	Intense nitrated type III collagen expression found in the basement membranes of blood vessels and the lining layer within the fibrous tissue surrounding synoviocytes	IHC	Qual	N/A	[104]
			Expression found in vascular walls and in surrounding connective tissue matrix	IF	Qual	N/A	[129]
Collagen IV	↑	Present in sublining	IF	Qual	N/A	[128]	
	=	Present in basement membranes of vasculature and pericellular distribution in the intimal layer but not underlying connective tissue. No change compared to trauma control.	IHC	Qual	N/A	[114]	

	No control	Present in sublining	IHC	Qual	N/A	[110]
		Present in basement membrane of blood vessels	IF	Qual	N/A	[129]
Collagen V	↑	Present in sublining	IF	Qual	N/A	[128]
Collagen fibre architecture	No control	Accumulation of collagen fibres in early OA; collagen fibres become disordered in late OA.	H&E	Qual	N/A	[96]
		Dense collagen bundles present in sublining; increasingly so with more severe OA. Giant collagen fibrils occasionally found in more severely degraded sublining.	EM, LM	Qual	N/A	[119]
Collagen cross-links	No control	Pyridinoline (Pyr) and deoxypyridinoline (Dpy) ratio was 14.5+-6.2: Pyr 0.84 mol/mol collagen and Dpy 0.07 mol/mol collagen	LC	Quant	N/A	[98]
		Pyr:Dpr ratio was 25.6	LC	Quant	N/A	[106]
COMP	No control	Expressed in and around synovial cells, less expression in sublining	IHC	Qual	N/A	[94]
Elastin	No control	Intense staining in the internal elastic lamina	IHC	Qual	N/A	[108]
		Elastic fibrils increased in intermediate degeneration	EM, LM	Qual	N/A	[119]
Fibromodulin	=	Little fibromodulin expression found in OA synovial tissue. Tenancy towards lower expression than control, but not statistically significant	IHC	S-quant	Yes	[120]
Fibronectin (Fn) (including isoforms)	↑	High expression areas close to blood vessels or high inflammation	MS & IHC	Quant	No	[92]
		ED-A and ED-B-Fn mainly expressed in the lining; t-FN found throughout the lining and sublining	IHC	Qual	N/A	[93]
		Fn expression in sublining	IF	Qual	N/A	[128]
	No control	Small amount of Fn staining detected in sublining layer / Fn detected by WB	IHC & IP + WB	Quant	N/A	[121]
		Little Fn staining found in deep sublining	IF	Qual	N/A	[97]
		Weak staining of EDA+ Fn only in proliferative region of OA synovium	IHC	Qual	N/A	[122]
		EDA+ Fn found in OA synovium; most intense staining in the lining layer	IF	Qual	N/A	[99]
		Fn detected in lining, sublining, and blood vessels	IHC	Qual	N/A	[110]
		tFn detected in lining, sublining, and blood vessels; EDA-Fn mainly in lining and vessels, limited expression in the sublining; expression of glycosylated-Fn was similar to EDA-Fn but with reduced intensity; EDB-Fn reduced expression in lining, few vessels stained, limited expression in sublining.	IHC	S-quant	N/A	[125]
Expression of Fn and EDA-Fn was strong in lining and blood vessels, but weak and irregular in the sublining	IHC	Qual	N/A	[111]		

			Fn expression found in lining layer, blood vessels, and area of high collagen content.	IHC	Qual	N/A	[113]
			Fn expression found in lining layer	IHC	Qual	N/A	[101]
			Expression of Fn in blood vessels and surrounding matrix.	IF	Qual	N/A	[129]
			Patchy expression on synovial villi and in irregular ECM masses.	IF	Qual	N/A	[116]
GAG: Chondroitin sulphate (CHS)	↑		CHS-A/C expression increased in interstitial space below the lining layer compared to control. Present in perivascular and highly fibrous regions.	IHC (FCCIS)	Qual	N/A	[102]
	↓		CHS-C absent from the lining layer in OA, while expression was found in normal synovium. Expression found in patches of faint staining in sublining, in a narrow band underlying vascular endothelium, and as a diffuse band outlining smooth muscle cells of the tunica media in larger vessels.	IHC	Qual	N/A	[118]
GAG: Dermatan sulphate (DS)	↑		Expression increased in interstitial space below the lining layer compared to control. Present in perivascular regions (in and around vascular endothelial cells) and subsurface interstitial space.	IHC (FCCIS)	Qual	N/A	[102]
	=		Distributed through superficial and deep matrix; faint condensation in the adventitia. No differences with normal synovium reported.	IHC	Qual	N/A	[118]
	No control		Expression found in synoviocytes and their surrounding matrix at the adventitial layer of small blood vessels	IHC	Qual	N/A	[68]
GAG: Hyaluronic acid (HA)	↑		HA found in blood vessels (at times extending into surrounding matrix), in areas of infiltrating cells, and reticular staining in the lining, which decreased upon hyperplasia. Low-to-moderate staining in OA compared to faint staining in normal tissue.	IHC	Qual	N/A	[130]
	=		HA mainly found in lining, content varied strongly between patients; mean content (249 +/- 34.8 µg/g) not significantly different from control (227.7 +/- 35.4 µg/g).	IHC + SPA	Quant	Yes	[123]
	No control		Staining was weak and restricted to the lining layer.	IHC	S-quant	N/A	[110]
			Present in perivascular regions.	IHC (FCCIS)	Qual	N/A	[102]
GAG: Heparin sulphate (HS)	↑		HS expression increased in interstitial space below the lining layer compared to control. Present on and around vascular endothelial cells.	IHC (FCCIS)	Qual	N/A	[102]
	No control		HS was detected with a diffuse pattern involving all vessels in OA sections	IF	Qual	N/A	[127]
Laminins	↑		EHS laminin (laminin-111) strongest expression in lining, areas of the sublining, and blood vessel basement membranes; occasional weaker staining in stromal pericellular areas. Moderate to strong staining for α5 and β1 (mainly in blood vessels but also in lining and sublining) and β2 laminin, which stained more extensively but less so in blood vessels.	IHC	S-quant	No	[109]
	=		α2 and α3 laminin showed no/weak staining. No changed compared to trauma control.	IHC	S-quant	No	[109]

			α 4 laminin showed weak expression in lining, strong staining in vascular basement membranes.	IF	Qual	N/A	[126]
			EHS-laminin expression in basement membrane of vasculature and pericellular in intimal layer.	IHC	Qual	N/A	[114]
			Laminin (unspecified) present in vascular basement membranes and areas of sublining with early connective tissue proliferation but not in mature fibrous tissue.	IF	Qual	N/A	[129]
		↓	Weak α 5 laminin expression in lining, strong staining in vascular basement membranes.	IF	Qual	N/A	[126]
		No control	Pericellular distribution in the synovial lining layer. Expression appears to decrease in cases of severe inflammation	IHC	S-quant	N/A	[115]
	Latent TGF- β -binding protein 1 (LTBP-1)	↑	Increased expression (by IHC); 2-fold increase in expression (by WB).	IHC, WB	Quant	Yes	[107]
	Lumican	=	High levels throughout synovial and subsynovial tissue	IHC	S-quant	NR	[120]
	Reticulin	No control	Expression found in vascular walls and in surrounding connective tissue matrix	IF	Qual	N/A	[129]
Vitronectin	No control	Expression found in the lining layer and some expression is present in the sublining often in fibril like structures.	IHC	Qual	N/A	[101]	
Tendon	Calcification	↑	Increase in internal obturator tendon calcification in OA compared to control	Von Kossa	S-quant	Yes	[135]
		= / ↓	Lower percentage of calcification in OA biceps but no difference in subscapularis tendon	Von Kossa + LM	S-quant	Yes	[132]
		No control	Mean calcification score in OA Achilles tendon 2.79 (scored 0-6 for both tendons: 0=none, 1 = <5mm, 2 = 5-10mm, 3 = ossification >10mm)	Ultrasound	S-quant	N/A	[131]
	Collagen I	=	Present in all OA long head of biceps tendons	IHC	S-quant	Yes	[134]
	Collagen III	=	Present in all OA long head of biceps tendons	IHC	S-quant	Yes	[134]
	Collagen fibre diameter	↑	Relatively fewer small and medium sized fibres (<30 & 31-60 nm) in OA internal obturator tendon vs control	TEM	Quant	Yes	[135]
		↑ / =	Increase in biceps (66.1nm vs 59.0nm in control); no changes in subscapularis (55.3nm vs 54.0nm in control)	H&E + LM, TEM	Quant	Yes	[132]
		=	Mean diameter 68.3nm for in OA gluteus medius tendon (vs 67.6nm in control)	TEM	Quant	Yes	[133]
	Collagen fibre organisation	=	Distal portion of long head of biceps tendon has more organised collagen than proximal; no difference with control	Polarised light	Quant	Yes	[134]
		↓	Irregular collagen structure more common in OA biceps and subscapularis tendon vs control	TEM	S-quant	Yes	[132]
Slightly higher disorganisation of fibre structure in OA gluteus medius tendon than control			H&E + Alcian blue/PAS	S-quant	No	[133]	

			Irregular patterns (in ultrastructure) of collagen fibrils in OA internal obturator tendon compared to control	H&E + LM, TEM	Quant	Yes	[135]
	Decorin	=	Present in all OA long head of biceps tendons	IHC	S-quant	Yes	[134]
	GAG / proteoglycan	↑	Greater proteoglycan content in OA long head of biceps tendon than control; greater proteoglycan content in proximal compared to distal tendon	Alcian blue	Quant	Yes	[134]
			Increase in GAG between collagen fibrils in OA internal obturator tendon	Alcian blue	Quant	Yes	[135]
		=	No difference in GAG in OA biceps and subscapularis tendon compared to control	Alcian blue	S-quant	Yes	[132]
		↓	Slight decrease in average GAG score in OA gluteus medius tendon compared to control	Alcian blue/PAS	S-quant	No	[133]

339 **Table 2.** Structural ECM composition and architecture in animal models of OA. The studied joint in all studies is the stifle joint.

340 Abbreviations: AA = amino acid, ACL = anterior cruciate ligament, ACLT = anterior cruciate ligament transection, AFM = atomic force microscopy, CT =

341 computed tomography, DMM = destabilisation of the medial meniscus, ECM = extracellular matrix, EM = electron microscopy, GAG = glycosaminoglycan,

342 H&E = haematoxylin and eosin, IHC = immunohistochemistry, IRT = indentation relaxation tests, LCL = lateral cruciate ligament, MCL = medial cruciate

343 ligament, MIA = monoiodoacetate, Mx = meniscectomy, N/A = not applicable, NR = not reported, NZW = New Zealand white, OA = osteoarthritis, PAS =

344 periodic acid Schiff, PCL = posterior cruciate ligament, qual = qualitative, quant = quantitative, s-quant = semi-quantitative, WB = western blot.

Tissue	ECM feature	Change vs control	Species (strain)	Model	Description of feature in OA tissue	Measurement technique(s)	Analysis	Stat. test	Ref
Capsule	Collagen III	=	Mouse (C57BL/6)	DMM	Diffuse expression; present in vascular endothelium	IHC	Qual	No	[136]
Ligament	Calcification / mineralisation	↑	Mouse (CBA, STR/ort)	STR/ort	Areas of bone formation in the collateral ligaments of STR/ort mice, which were more significant in severe OA	Toluidine blue	Qual	No	[138]
			Mouse (CBA, STR/ort)	STR/ort	Calcification more common in MCLs and LCLs of OA mice vs control; MCL calcification positively correlated and LCL mineralisation was negatively correlated with OA progression	X-ray	S-quant	Yes	[139]
	Collagen II	↑	Mouse (CBA, STR/ort)	STR/ort	Collateral ligaments: collagen 2 deposition in OA mice, but not in controls. ACL: collagen 2 deposition at the insertion site, while none was observed in controls.	Toluidine blue	Qual	No	[138]
	Collagen III	=	Mouse (C57BL/6)	DMM	Diffuse expression in ligaments of the hind limb; present in vascular endothelium	IHC	Qual	No	[136]
	Collagen cross-links	↑/=	Mouse (STR/ort)	SRT/ort	Increased immature cross-links in ACL of young OA mice vs young control (22-30 weeks), but no difference in ACL of old OA mice vs old control; higher in ACL of young OA mice than old OA mice.	Cellulose chromatography, AA analysis	Quant	Yes	[137]
	Collagen fibre diameter	See text	Sheep (Suffolk cross)	ACL + MCL transection	Modal collagen fibril diameter 48-96nm in LCL & PCL. OA PCLs had fewer medium size fibrils (96-192nm) than control ligaments	TEM	Yes	Yes	[142]
	Collagen fibre organisation	↓	Sheep (Suffolk cross)	Partial ACLT	Decrease in collagen fibre organisation in PCL in OA compared to control	H&E	S-quant	Yes	[141]
			Rabbit (NZW)	ACLT	Decrease in collagen fibre organisation in MCL in OA compared to control	Ultrasound	S-quant	Yes	[140]
GAG / Proteoglycan	↑	Mouse (CBA, STR/ort)	STR/ort	Collateral ligaments: increase in staining in in OA compared to control. ACL: Increase in staining in OA ACL (grade 2 or higher), which expanded through the entire ACL in severe OA, while only weak staining was seen in control mice.	Toluidine blue	Qual	No	[138]	

	Mechanical strength	↓	Mouse (STR/ort)	STR/ort	Lower ultimate strength in ACL in OA compared to control	Tensile strength machine	Quant	Yes	[137]
Meniscus	Calcification / mineralisation	↑	Mouse (C57BL/6)	Mechanical loading	Increase in ectopic mineralisation	μCT	Quant	No	[143]
			Mouse (C57BL/6J)	DMM	At 8 weeks, significant increase in meniscal ossicle formation	nanoCT	Quant	Yes	[145]
			Mouse (CBA, STR/ort)	STR/ort	Ossification in fibrous region of meniscus in OA	Toluidine blue	Qual	No	[138]
		↑/=	Rabbit (NZW)	ACLT	Calcification detected in torn OA menisci, but not in non-altered regions of OA menisci or normal menisci.	Alizarin Red	Qual	No	[147]
	Collagen I	↑	Rabbit (NZW)	ACLT	At 3 and 8 weeks, staining intensity increased in the outer region adjacent to the fissure medially and increased throughout the tissue laterally.	IHC	Qual	No	[146]
	Collagen II	↑	Mouse (BALB/cByJ)	DMM	Abnormal expression (in vascular region associated with hypertrophic changes)	IHC	Qual	No	[144]
			Mouse (CBA, STR/ort)	STR/ort	Staining in the fibrous region, particularly in areas surrounding bone formation and in the outer areas near the capsular attachment site, while it was only detected at cartilage surfaces of the meniscus in controls.	IHC	Qual	No	[138]
		↑/=	Rabbit (NZW)	ACLT	At 3 and 8 weeks, staining intensity increased in the outer region adjacent to the fissure and in inner medial meniscus and was not significantly altered laterally.	IHC	Qual	No	[146]
	Collagen III	↑	Rabbit (NZW)	ACLT	At 3 and 8 weeks, staining intensity increased in the outer region adjacent to the fissure medially and staining was increased throughout the tissue laterally.	IHC	Qual	No	[146]
		=	Mouse (C57BL/6)	DMM	In OA and control mice, staining was found in pericellular distribution and in vascular endothelium	IHC	Qual	No	[136]
	Collagen X	↑/=	Rabbit (NZW)	ACLT	Detected in torn OA menisci, but not in non-altered regions of OA menisci or normal menisci.	IHC	Qual	No	[147]
	Collagen fibre diameter	↑	Rabbit (Chinese)	Cartilage injury	Collagen thickening present in animals after 1-2 weeks	H&E	Qual	No	[150]
	Collagen fibre organisation	= / ↓	Rabbit (NZW)	ACLT	Tie fibre organisation decreased: non-significant increase in tie fibre organisation score in the anterior, and significant increase in posterior region	Biphotonic confocal imaging	S-quant	Yes	[149]
ACLT				Disorganisation seen at 3 weeks, not seen in control	H&E	Qual	No	[146]	
↓		ACLT		OA menisci displayed less compact collagen bundles, with undulated fibres in both regions, while bundles in healthy menisci were made of straight fibres aligned in the circumferential direction in both regions.	Biphotonic confocal imaging	Qual	No	[149]	

			ACLT	OA menisci had less compact bundles with undulated fibres in both regions compared to healthy menisci, which had compact collagen bundles made of straight fibres aligned in circumferential direction	Biphotonic confocal imaging	Qual	No	[148]	
				ACLT	Tie fibre organisation decreased: increase in tie fibre organisation score in both anterior and posterior region.	Biphotonic confocal imaging	S-quant	No	[148]
			Rabbit (Chinese)	Cartilage injury	At 6 weeks, collagen fibres are disordered in OA, while they are ordered in healthy menisci	H&E	Qual	No	[150]
	Fibromodulin	=	Mouse (C57BL/6)	DMM	Minimal presence in meniscus, no differences noted	IHC	Qual	No	[136]
	Proteoglycan / GAG content	↑	Mouse (CBA, STR/ort)	STR/ort	Increase in proteoglycan content	Toluidine blue	Qual	No	[138]
		ACLT	Significant decrease in GAG coverage in anterior; non-significant increase in posterior region.	Safranin O/Fast Green	S-quant	Yes	[149]		
		ACLT	Significant decrease in GAG coverage in anterior meniscus, but no significant differences in posterior region.	Safranin O/Fast Green	S-quant	Yes	[148]		
		↓	Pig (Yucutan minipig)	DMM	Anterior horn: significant decrease in proteoglycan ratio 1 and 3 months after DMM. Posterior horn: small decrease after 1 month and significant decrease after 3 months.	Safranin O/Fast Green	Quant	Yes	[152]
					Rat (Wistar)	ACLT	Slight loss of Safranin O staining	Safranin O	Qual
	Viscoelastic properties	=	Rabbit (NZW)	ACLT	Instantaneous modulus decreased in both anterior and posterior regions, but no significant differences.	IRT	Quant	Yes	[148]
				=/ ↓	ACLT	Instantaneous modulus decreased significantly in the anterior region (2.9MPa for healthy, 1.3MPa for OA). Non-significant decrease (1.5x) in posterior. Anterior was stiffer than posterior region in health and disease.	IRT	Quant	Yes
		ACLT			Elastic fraction was unaffected in anterior, but significantly decreased in posterior region. No significant differences between anterior and posterior regions.	IRT	Quant	Yes	[149]
		ACLT			Equilibrium modulus was significantly decreased in anterior region (0.6MPa for healthy, 0.26MPa for OA), non-significant decrease in posterior region.	IRT	Quant	Yes	[148]
		ACLT			Elastic fraction was significantly lower in posterior region (0.21MPa for healthy, 0.16MPa for OA); no differences in anterior region.	IRT	Quant	Yes	[148]
↓		ACLT		Equilibrium modulus significantly decreased in anterior (57%; 0.6MPa in healthy, 0.14 MPA in OA) and posterior regions (45%: 0.14MPa in healthy, 0.099MPa in OA)	IRT	Quant	Yes	[149]	

Skeletal muscle	Viscoelastic properties	↑	Rabbit (NZW)	Adapted Videman method	Elastic modulus increased vs control in biceps femoris & rectus femoris	Micro-force tension-torsion	Quant	Yes	[153]
Synovium	Calcification	↑	Mouse (C57BL/6)	Mechanical loading	Ectopic mineralisation	3D μ CT	Quant	No	[143]
	Collagen content	↑	Rat (albino)	Cartilage defect	Significant increase in the mean area covered by collagen fibres in the subintimal stroma	Mallory stain	Quant	Yes	[158]
			Rabbit (domestic)	Modified Hulth method	Significant increase in collagen volume fraction in rabbits 4 and 12 weeks after OA induction compared to 12 weeks sham control.	Masson's trichrome	S-quant	Yes	[165]
			Rat (Sprague-Dawley)	MIA	Marked increase in collagen content compared to control	Sirius red	Qual	No	[163]
				ACLT	Significant increase in collagen staining	Sirius red	S-quant	Yes	[162]
				ACLT, DMM, MIA	Significant increase in amount of Sirius red positive staining and Masson's positive areas in all 3 OA models compared to control on day 14 and 28 after OA induction	Sirius red, Masson's trichrome	S-quant	Yes	[161]
				MIA	Marked increased collagen deposition	Sirius red	Qual	No	[160]
	Type I collagen	↑	Rabbit (domestic)	Modified Hulth method	Significant increase in collagen 1 immunofluorescence in rabbits 4 and 12 weeks after OA induction compared to 12 weeks sham control.	IF	S-quant	Yes	[165]
			Rat (Sprague-Dawley)	MIA	Increased collagen 1 deposition (Sirius red); significant increase in COL1A1 expression (WB)	Sirius red, WB	Qual, S-quant	No, Yes	[159]
				MIA	Significant increase in collagen 1 relative protein level	WB	S-quant	Yes	[163]
				ACLT, DMM, MIA	Significant increase in amount of collagen 1 staining in all 3 OA models compared to control on day 14 and 28 after OA induction	IHC	S-quant	Yes	[161]
				MIA	Significant increase in the percentage of collagen I-positive areas	IHC	S-quant	Yes	[160]
	Type III collagen	=	Mouse (C57BL/6)	DMM	Diffuse pattern expression; present in vascular endothelium	IHC	Qual	No	[136]
	Collagen fibre diameter	↑	Rat (Wistar albino)	Mx	Thick collagen fibres in the lining and sublining and around the blood vessel, compared to thin fibres in controls. Strong PAS reaction present, which demonstrates the presence of glycogen and mucoproteins.	H&E, Alcian blue w/ PAS	Qual	No	[154]
		=	Rat (Sprague-Dawley)	ACLT	In all groups: minimum= 133+-10.27 nm; maximum = 133.62+-21.03 nm.	AFM	Quant	Yes	[157]

	Collagen fibre organisation	=	Rat (Sprague-Dawley)	ACLT	No significant difference between the maximum and minimum D-periodic banding in all groups (68.19±12.73 nm vs 65.43±2.57 nm)	AFM	Quant	Yes	[157]
		↓	Rat (Sprague-Dawley)	ACLT	Fibre alignment more disordered vs control in both anterior and posterior capsule	AFM	Qual	No	[157]
			Rabbit (Flanders Giant)	Vitamin A injection	Decrease in collagen fibre arrangement over-time after OA induction: no change after 3 days, collagen fibres were closely packed and showed areas of calcium-like deposits after 6 days, and they were numerous and intermingled with electron transparent areas after 9 days	EM, Toluidine blue	Qual	No	[164]
	COMP	↑/↓	Rats (Wistar)	MIA	Increase in COMP level day 2 after MIA injection (but no increase on days 7, 21, 28)	WB	S-quant	Yes	[155]
	Fibromodulin	=	Mouse (C57BL/6)	DMM	Variable immunopositivity, no differences noted	IHC	Qual	No	[136]
	Lubricin	↓	Rat (Wistar)	ACLT	Decrease in lubricin immunolabelling (moderate in OA vs strong in control).	IHC	S-quant	Yes	[156]
	Viscoelastic properties	↓	Rat (Sprague-Dawley)	ACLT	Elastic modulus increased with severity of OA (time post-surgery) and was higher in the anterior than posterior capsule	AFM	Quant	Yes	[157]
Tendon	Calcification	↑	Rat (Sprague-Dawley)	ACLT	Calcification began inferior to mid-section of patella and progressed to ossification. Calcification more common in OA than control	μCT	Qual	No	[166]

346 **4 Discussion**

347

348 Despite OA becoming more widely accepted as a whole joint disease, the role of and the changes to
349 non-cartilage soft joint tissues remain underexplored. This study aimed to collate current knowledge
350 on the structural ECM of these tissues to summarise and highlight gaps in existing knowledge. For
351 instance, tissues such as the joint capsule and fat pad are very poorly defined, perhaps reflecting
352 their perceived importance in OA. Overall, the studies included in this review show that the
353 expression of many structural ECM components changes in disease, within an ECM that becomes
354 less organised with increasing joint degeneration.

355

356 Human studies covered a range of tissues and ECM features, but focused mainly on calcification, the
357 expression of proteoglycans, and the expression, fibre diameter, and fibre organisation of collagens.

358 While recent studies begin to define the presence and distribution of many ECM components, a
359 frequent lack of well-defined controls limit understanding of the changes in disease. Most ECM

360 features are only described by one or a few studies, highlighting the broader studies on the subject.

361 While studies that did look at the same ECM feature mostly agreed, this was not always the case.

362 This included studies with control groups that investigated the collagen content in meniscus[78, 83],
363 elastic modulus in meniscus[47, 66], chondroitin sulphate in synovium[102, 118], and calcification

364 and GAG/proteoglycan content in tendon[132–135], which all contradict each other in terms of the
365 direction of change. The summary and results tables highlight several potential factors for these

366 differences already, including different analysis methods, differences in tissue joint origin, and

367 differences between the microanatomical area of tissue studied. This emphasizes the importance of
368 in-depth reporting of tissue metadata and methods.

369

370 Several recent human studies, mostly in ligaments, tendon, and meniscus, have begun to study both
371 compositional and architectural ECM features within a single tissue. Importantly, such studies can

372 begin to dissect the relationship, including causality, between changes in ECM composition, ECM
373 architecture, and viscoelastic properties. For example, calcification of tendon has been shown to
374 change its viscoelastic properties[167], while the mechanical properties of fibril-forming collagens
375 are dependent on covalent cross-linking[168], and different matrix proteoglycans differ in their
376 effects on cell-mediated collagen reorganisation[169].

377

378 Whole tissue proteomics, which can be used to study the ECM composition of a tissue holistically,
379 was performed in three studies which all investigated OA meniscus[52, 76, 79]. While the study of
380 ECM proteins using proteomic techniques are subject to methodological biases due to the fact that
381 ECM proteins are large, heavily post-translationally modified, and highly insoluble[170], they are a
382 powerful tool to better understand overall tissue composition and formulate new research
383 questions. The application of this technique to other osteoarthritic tissues is likely to provide
384 important insights.

385

386 In animal models, OA is induced in a range of species using varied surgical techniques and
387 pharmacological interventions, with no animal model truly replicating human disease[171, 172].
388 Joint mechanics, inflammatory responses, and disease chronicity all vary between animal models
389 [172, 173]. If ECM remodelling also differs between species and procedures, it can be assumed that
390 not all animal models are equally suited to the study of changes in osteoarthritic ECM. Certain
391 models may be generally more representative of changes seen in human OA, or better suited to the
392 study of particular joint tissues or ECM features. This review covers a range of ECM changes in
393 several different musculoskeletal soft tissues across different species and models. Although limited
394 animal studies were eligible for inclusion in this review, some changes in ECM features could be
395 compared between human OA and animal models. Generally similar trends could be seen as in
396 humans, including a decrease in collagen fibre organisation and an increase in calcification across
397 ligaments, meniscus, and synovium. However, other observations seem to contradict those in

398 humans; for example, the decreased expression of collagens in human osteoarthritic menisci [54, 83,
399 86] is not reflected in data from any animal models in this review [138, 144, 146]. Therefore, the
400 models used by these studies, namely the mouse STR/ort, rabbit ACLT, and mouse DMM models,
401 respectively, might not be suitable to infer OA-related changes in human menisci. These results
402 emphasize that more studies on ECM changes in non-cartilage soft-joint tissues in human OA and
403 animal models must be compared before the validity of the latter can be accurately defined.

404

405 The strength of any systematic review is partly contingent on the quality of included studies. As
406 discussed in section 3.4, the methodology of many studies conferred a high risk of bias, resulting in a
407 low confidence in the evidence provided. In basic science studies utilising human samples, the
408 baseline characteristics and clinical characterisation of OA patients are often missing, or lack
409 necessary detail. Clinical background is a particularly important consideration in the context of soft
410 tissue calcification, given that crystal depositional diseases, such as pseudogout, can drive OA
411 pathology[174]. Patients' clinical background is poorly reported throughout the literature, as is
412 disease severity, despite ECM and other tissue components differing more from the physiological
413 state with OA progression[38]. Although the search strategy covered many non-cartilage soft joint
414 tissues, some tissues, such as the temporomandibular joint disc and acetabular labrum, were not
415 included. In addition, the focus of this review was on structural components of the ECM, which are
416 the elements that are studied most extensively and make up the majority of tissue ECM. However,
417 this does mean that this work does not provide a complete account of all OA ECM, as non-structural
418 matrix elements such as matricellular proteins or neoepitopes have not been reported on. Finally, a
419 limitation of the review process is the data extraction, which was not done by two independent
420 reviewers, but rather extracted by one reviewer and verified by the other reviewer. However, the
421 effect of this is likely limited as a previous study has reported that while extraction by two
422 independent reviewers is preferable, extraction by one reviewer with verification by a second

423 reviewer has limited influence on the conclusions of a systematic review, especially considering a
424 meta-analysis was not performed in the current work[175].

425

426 In the process of consolidating the current literature on this topic, this work highlights several
427 practical and methodological challenges that have limited advances in knowledge of the
428 understanding of structural ECM components, architectural features, and viscoelastic properties in
429 non-cartilage soft tissues in OA. One of these problems, is the cross-sectional nature of studies.
430 Cross-sectional studies are common across the OA field as tissues are only accessible at the time of
431 joint replacement. Since OA can take decades to progress, the study of end-stage or advanced OA
432 might not be very informative of the processes that are driving these changes. In addition, the lack
433 of a healthy, or non-OA, comparator group in combination with the fact that many studies only
434 report qualitative results, vastly reduces the depth of knowledge that can be gained from these
435 studies. Finally, while many screened human and animal studies investigated both cartilage and
436 other soft joint tissues, ECM is often studied exclusively in cartilage, with other features, such as
437 cellularity and inflammatory markers being the focus in other tissues. This shows that while there is
438 access to both the tissues and the methods to study ECM changes in non-cartilage soft tissues, their
439 analysis is not seen as a priority. However, due to the limited definition of ECM in these tissues and
440 their unknown contribution to disease development and progression, it is also possible that it
441 remains unclear which ECM features should be focused on. Structural ECM encompasses a wide
442 range of features that can be investigated with a plethora of different methods. To evaluate the
443 most critical ECM features and applicable methods, studies investigating multiple ECM features in
444 non-cartilage soft tissues across different stages of disease are required.

445

446 Recent studies have started to highlight the importance of ECM as a determinant of tissue
447 architecture and cell behaviour in disease. For example, a recent review has highlighted the changes
448 in microenvironment in rheumatoid arthritis synovium that occur in early in the development of the

449 disease, which form important extracellular cues that shape the pathogenic cell behaviour during
450 the onset and progression of disease[176]. Therefore, they argue that understanding the ECM
451 changes across different tissues in a particular disease might not only be able to help with disease
452 classification and patient stratification but could also hold promise for the development of
453 treatments that target ECM[176]. These treatments might not only be able to modify pathogenic cell
454 behaviour that could be driving the disease, but also impact on joint stiffness, which is one of the
455 most common symptoms of OA[177]. All in all, more research is needed to unravel the presence and
456 distribution of different ECM components and architectural features in joint tissues in health and in
457 (different stages of) OA and interplay with tissue-resident and tissue-infiltrating cells. Future
458 research will also help to differentiate between the remodelling process in different joint tissues,
459 which contain unique cell populations and are exposed to different mechanical and inflammatory
460 stimuli in OA. ECM remodelling may also differ between synovial joints, given their varied
461 anatomical locations, mechanical functions, and the presence of joint-specific tissues such as
462 menisci. Potential variation in pathophysiology between osteoarthritic joints has received little
463 attention, with the predominance of studies on knee OA likely due to high disease prevalence in this
464 joint and tissue being relatively accessible during commonly performed knee replacements.
465 Therefore, the future of this field is both dependent on the thorough investigation of ECM features
466 in soft joint tissues across multiple OA joints and varied stages of disease progression, as well as the
467 rigorous reporting of patient characteristics of all tissue donors.

468

469 In conclusion, this systematic review gives an overview of the current knowledge of the presence
470 and distribution of structural ECM components, as well as the changes in ECM components and
471 architecture that occur throughout the osteoarthritic joint. Overall, the studies included in this
472 review show that the expression of many structural ECM components changes in disease and that
473 the ECM architecture becomes more disorganised with increasing joint degeneration. Furthermore,
474 this review highlights practical and methodological challenges that have limited progress in the

475 understanding of changes in ECM composition and architecture in non-cartilage soft tissues during
476 OA development and progression, including the fact that historically studies have mainly focussed
477 on other aspects of the disease in these tissues, such as inflammation. Given the role of ECM in
478 influencing cell behaviour, further research to better understand the broad context within which
479 cartilage is damaged in OA may enable a better understanding of the disease as well as potential
480 treatments.
481

482 **Acknowledgements**

483 We would like to thank Oxford University medical librarian Eli Harriss for her support in generating
484 and executing the search strategy. We would like to thank Dr Mathew Baldwin for his helpful
485 feedback on the design of this study.

486

487 **Author contributions**

488 Conceptualization, J.Y.M. and S.J.B.S.; Formal analysis, J.Y.M. and I.G.A.R.; Investigation, J.Y.M. and
489 I.G.A.R.; Data curation, J.Y.M. and I.G.A.R.; Writing - original draft, J.Y.M. and I.G.A.R.; Writing -
490 review & editing, S.J.B.S; Project Administration, J.Y.M. and S.J.B.S.

491

492 **Funding statement**

493 This work was supported by the National Institute for Health Research Oxford Biomedical Research
494 Centre. JYM is funded by Versus Arthritis (22873) and was supported the Chan Zuckerberg Initiative
495 (CZIF2019-002426). SJBS is funded by the Chan Zuckerberg Initiative (CZIF2019-002426 and
496 CZIF2021-240342) and supported by the National Institute for Health Research Oxford Biomedical
497 Research Centre. The funders had no role in study design, data collection and analysis, decision to
498 publish, or preparation of the manuscript.

499

500 **Data availability statement**

501 The authors confirm that the data supporting the findings of this study are available within the
502 article and its supplementary materials. In addition, the raw data from the data extraction process,
503 which was used to populate Tables 1 and 2 and Supplementary Tables 1 and 2, is available upon
504 reasonable request from the corresponding author (JYM).

505

506 **Competing interest**

507 The authors declare that they have no competing interests.

508 **References**

- 509 1. Goldring SR, Goldring MB (2016) Changes in the osteochondral unit during osteoarthritis:
510 structure, function and cartilage–bone crosstalk. *Nature Reviews Rheumatology* 2016 12:11
511 12:632–644
- 512 2. Mimpfen JY, Snelling SJB (2019) Chondroprotective Factors in Osteoarthritis: a Joint Affair.
513 *Curr Rheumatol Rep* 21:1–14
- 514 3. Poole AR (2012) Osteoarthritis as a Whole Joint Disease. *HSS Journal* 8:4–6
- 515 4. Zhang K, Li L, Yang L, Shi J, Zhu L, Liang H, Wang X, Yang X, Jiang Q (2019) The biomechanical
516 changes of load distribution with longitudinal tears of meniscal horns on knee joint: A finite
517 element analysis. *J Orthop Surg Res* 14:1–12
- 518 5. Shirazi R, Shirazi-Adl A (2009) Analysis of partial meniscectomy and ACL reconstruction in
519 knee joint biomechanics under a combined loading. *Clinical Biomechanics* 24:755–761
- 520 6. Wellsandt E, Gardinier ES, Manal K, Axe MJ, Buchanan TS, Snyder-Mackler L (2015) Decreased
521 Knee Joint Loading Associated With Early Knee Osteoarthritis After Anterior Cruciate
522 Ligament Injury. <https://doi.org/10.1177/0363546515608475> 44:143–151
- 523 7. Hill CL, Hunter DJ, Niu J, Clancy M, Guermazi A, Genant H, Gale D, Grainger A, Conaghan P,
524 Felson DT (2007) Synovitis detected on magnetic resonance imaging and its relation to pain
525 and cartilage loss in knee osteoarthritis. *Ann Rheum Dis* 66:1599–1603
- 526 8. Hill CL, Gale DG, Chaisson CE, Skinner K, Kazis L, Gale ME, Felson DT (2001) Knee effusions,
527 popliteal cysts, and synovial thickening: association with knee pain in osteoarthritis. *J*
528 *Rheumatol* 28:
- 529 9. Sanchez-Lopez E, Coras R, Torres A, Lane NE, Guma M (2022) Synovial inflammation in
530 osteoarthritis progression. *Nature Reviews Rheumatology* 2022 18:5 18:258–275
- 531 10. Theocharis AD, Skandalis SS, Gialeli C, Karamanos NK (2016) Extracellular matrix structure.
532 *Adv Drug Deliv Rev* 97:4–27

- 533 11. Urbanczyk M, Layland SL, Schenke-Layland K (2020) The role of extracellular matrix in
534 biomechanics and its impact on bioengineering of cells and 3D tissues. *Matrix Biology* 85–
535 86:1–14
- 536 12. Felson DT (2013) Osteoarthritis as a disease of mechanics. *Osteoarthritis Cartilage* 21:10–15
- 537 13. Klees RF, Salaszyk RM, Kingsley K, Williams WA, Boskey A, Plopper GE (2005) Laminin-5
538 Induces Osteogenic Gene Expression in Human Mesenchymal Stem Cells through an ERK-
539 dependent Pathway. *Mol Biol Cell* 16:881
- 540 14. Du J, Zu Y, Li J, Du S, Xu Y, Zhang L, Jiang L, Wang Z, Chien S, Yang C (2016) Extracellular matrix
541 stiffness dictates Wnt expression through integrin pathway. *Scientific Reports* 2016 6:1 6:1–
542 12
- 543 15. Allen JL, Cooke ME, Alliston T (2012) ECM stiffness primes the TGF β pathway to promote
544 chondrocyte differentiation. *Mol Biol Cell* 23:3731–3742
- 545 16. Wijelath ES, Rahman S, Namekata M, Murray J, Nishimura T, Mostafavi-Pour Z, Patel Y, Suda
546 Y, Humphries MJ, Sobel M (2006) Heparin-II Domain of Fibronectin Is a Vascular Endothelial
547 Growth Factor-Binding Domain. *Circ Res* 99:853–860
- 548 17. Thomas CM, Murray R, Sharif M (2011) Chondrocyte apoptosis determined by caspase-3
549 expression varies with fibronectin distribution in equine articular cartilage. *Int J Rheum Dis*
550 14:290–297
- 551 18. McCoy AM (2015) Animal Models of Osteoarthritis: Comparisons and Key Considerations. *Vet*
552 *Pathol* 52:803–818
- 553 19. Teeple E, Jay GD, Elsaid KA, Fleming BC (2013) Animal models of osteoarthritis: Challenges of
554 model selection and analysis. *AAPS Journal* 15:438–446
- 555 20. Page MJ, McKenzie JE, Bossuyt PM, et al (2021) The PRISMA 2020 statement: an updated
556 guideline for reporting systematic reviews. *BMJ*. <https://doi.org/10.1136/BMJ.N71>
- 557 21. Poulet B, de Souza R, Kent A V., Saxon L, Barker O, Wilson A, Chang YM, Cake M, Pitsillides AA
558 (2015) Intermittent applied mechanical loading induces subchondral bone thickening that

- 559 may be intensified locally by contiguous articular cartilage lesions. *Osteoarthritis Cartilage*
560 23:940–948
- 561 22. Zhu J, Zhu Y, Xiao W, Hu Y, Li Y (2020) Instability and excessive mechanical loading mediate
562 subchondral bone changes to induce osteoarthritis. *Ann Transl Med* 8:350–350
- 563 23. Kalu DN (1991) The ovariectomized rat model of postmenopausal bone loss. *Bone Miner*
564 15:175–191
- 565 24. Yousefzadeh N, Kashfi K, Jeddi S, Ghasemi A (2020) Ovariectomized rat model of
566 osteoporosis: a practical guide. *EXCLI J* 19:89
- 567 25. Cameron HU, Macnab I (1973) Scanning electron microscopic studies of the hip joint capsule
568 and synovial membrane. *Canadian Journal of Surgery* 16:388–392
- 569 26. Campbell TM, Trudel G, Laneuville O (2015) Knee flexion contractures in patients with
570 osteoarthritis: clinical features and histologic characterization of the posterior capsule. *Pm &*
571 *R* 7:466–473
- 572 27. DiFrancesco L, Sokoloff L (1995) Lipocondral degeneration of capsular tissue in
573 osteoarthritic hips. *American Journal of Surgical Pathology* 19:278–283
- 574 28. Heinegård D, Hernborg J, Lundberg BJ, Heinegard D, Hernborg J, Lundberg BJ, Heinegård D,
575 Hernborg J, Lundberg BJ (1968) The glycosaminoglycans of the human joint capsule: isolation
576 and characterizaion. *Arthritis Rheum* 11:787–795
- 577 29. Herbert C, Jayson MI V, Bailey AJ (1973) Joint capsule collagen in osteoarthrosis. *Ann Rheum*
578 *Dis* 32:510–514
- 579 30. Grevenstein D, Heilig J, Dargel J, Oppermann J, Eysel P, Brochhausen C, Niehoff A (2020)
580 COMP in the Infrapatellar Fat Pad—Results of a Prospective Histological, Immunohistological,
581 and Biochemical Case–Control Study. *Journal of Orthopaedic Research* 38:747–758
- 582 31. Belluzzi E, Macchi V, Fontanella CG, et al (2020) Infrapatellar Fat Pad Gene Expression and
583 Protein Production in Patients with and without Osteoarthritis. *Int J Mol Sci* 21:21

- 584 32. Cheng XG, Brys P, Nijs J, Nicholson P, Jiang Y, Baert AL, Dequeker J (1996) Radiological
585 prevalence of lumbar intervertebral disc calcification in the elderly: an autopsy study. *Skeletal*
586 *Radiol* 25:231–235
- 587 33. Abdul Sahib NS, Al-Sharqi SAH, Wahab MS (2017) Study histopathological changes in the
588 anterior and posterior cruciate ligament after knee replacement: Correlations with Vitamin D,
589 calcium and c-reactive protein in Iraqi patients with osteoarthritis. *Pakistan Journal of*
590 *Biotechnology* 14:393–400
- 591 34. Akisue T, Stulberg BN, Bauer TW, McMahon JT, Wilde AH, Kurosaka M (2002) Histologic
592 evaluation of posterior cruciate ligaments from osteoarthritic knees. *Clin Orthop Relat Res*
593 165–173
- 594 35. Allain J, Goutallier D, Voisin MC (2001) Macroscopic and histological assessments of the
595 cruciate ligaments in arthrosis of the knee. *Acta Orthop Scand* 72:266–269
- 596 36. Komro J, Gonzales J, Marberry K, Main DC, Cramberg M, Kondrashov P (2020)
597 Fibrocartilaginous metaplasia and neovascularization of the anterior cruciate ligament in
598 patients with osteoarthritis. *Clinical Anatomy* 33:899–905
- 599 37. Kumagai K, Sakai K, Kusayama Y, Akamatsu Y, Sakamaki K, Morita S, Sasaki T, Saito T, Sakai T
600 (2012) The extent of degeneration of cruciate ligament is associated with chondrogenic
601 differentiation in patients with osteoarthritis of the knee. *Osteoarthritis Cartilage* 20:1258–
602 1267
- 603 38. Levy YD, Hasegawa A, Patil S, Koziol JA, Lotz MK, D’Lima DD (2013) Histopathological changes
604 in the human posterior cruciate ligament during aging and osteoarthritis: correlations with
605 anterior cruciate ligament and cartilage changes. *Ann Rheum Dis* 72:271–277
- 606 39. Marczak D, Kowalczewski J, Okon T, Synder M, Sibinski M (2017) An evaluation of the
607 posterior cruciate ligament function in total knee arthroplasty with regard to its morphology
608 and clinical properties. *Folia Morphologica (Warszawa)* 76:94–99

- 609 40. Martins GC, Camanho G, Rodrigues MI, Filho LFM, Demange MK (2018) Histopathological
610 analysis of the posterior cruciate ligament in primary osteoarthritis. *European journal of*
611 *orthopaedic surgery & traumatologie* 28:691–699
- 612 41. Nakahara H, Hasegawa A, Otabe K, Ayabe F, Matsukawa T, Onizuka N, Ito Y, Ozaki T, Lotz MK,
613 Asahara H (2013) Transcription factor Mohawk and the pathogenesis of human anterior
614 cruciate ligament degradation. *Arthritis Rheum* 65:2081–2089
- 615 42. Nelissen RGHH, Hogendoorn PCW (2001) Retain or sacrifice the posterior cruciate ligament in
616 total knee arthroplasty? A histopathological study of the cruciate ligament in osteoarthritic
617 and rheumatoid disease. *J Clin Pathol* 54:381–384
- 618 43. Rajgopal A, Vasdev N, Pathak A, Gautam D, Vasdev A (2014) Histological changes and neural
619 elements in the posterior cruciate ligament in osteoarthritic knees. *Journal of Orthopaedic*
620 *Surgery* 22:142–145
- 621 44. Zhu J, Zhang X, Ma Y, Zhou C, Ao Y (2012) Ultrastructural and Morphological Characteristics of
622 Human Anterior Cruciate Ligament and Hamstring Tendons. *Anatomical Record* 295:1430–
623 1436
- 624 45. Doerschuk SH, Hicks DG, Chinchilli VM, Pellegrini Jr. VD (1999) Histopathology of the palmar
625 beak ligament in trapeziometacarpal osteoarthritis. *Journal of Hand Surgery - American*
626 *Volume* 24:496–504
- 627 46. Mobargha N, Ludwig C, Ladd AL, Hagert E (2014) Ultrastructure and innervation of thumb
628 carpometacarpal ligaments in surgical patients with osteoarthritis. *Clin Orthop Relat Res*
629 472:1146–1154
- 630 47. Abraham AC, Pauly HM, Donahue TL, Haut Donahue TL (2014) Deleterious effects of
631 osteoarthritis on the structure and function of the meniscal enthesis. *Osteoarthritis Cartilage*
632 22:275–283

- 633 48. Atik OS, Erdogan D, Seymen CM, Bozkurt HH, Kaplanoglu GT (2016) Is there crosstalk
634 between subchondral bone, cartilage, and meniscus in the pathogenesis of osteoarthritis?
635 *Eklemler Hastalik Cerrahisi* 27:62–67
- 636 49. Battistelli M, Favero M, Burini D, et al (2019) Morphological and ultrastructural analysis of
637 normal, injured and osteoarthritic human knee menisci. *European Journal of Histochemistry*
638 63:11
- 639 50. Dessombz A, Nguyen C, Ea HK, et al (2013) Combining μ X-ray fluorescence, μ XANES and μ XRD
640 to shed light on Zn²⁺ cations in cartilage and meniscus calcifications. *Journal of Trace*
641 *Elements in Medicine and Biology* 27:326–333
- 642 51. Fischenich KM, Lewis J, Kindsfater KA, Bailey TS, Haut Donahue TL (2015) Effects of
643 degeneration on the compressive and tensile properties of human meniscus. *J Biomech*
644 48:1407–1411
- 645 52. Folkesson E, Turkiewicz A, Ali N, Ryden M, Hughes H V, Tjornstrand J, Onnerfjord P, Englund
646 M (2020) Proteomic comparison of osteoarthritic and reference human menisci using data-
647 independent acquisition mass spectrometry. *Osteoarthritis Cartilage* 28:1092–1101
- 648 53. Fuhrmann IK, Steinhagen J, Ruther W, Schumacher U, Ruther W, Schumacher U, Ruther W,
649 Schumacher U (2015) Comparative immunohistochemical evaluation of the zonal distribution
650 of extracellular matrix and inflammation markers in human meniscus in osteoarthritis and
651 rheumatoid arthritis. *Acta Histochem* 117:243–254
- 652 54. Ghosh P, Ingman AM, Taylor TK (1975) Variations in collagen, non-collagenous proteins, and
653 hexosamine in menisci derived from osteoarthritic and rheumatoid arthritic knee joints.
654 *Journal of Rheumatology* 2:100–107
- 655 55. Haut Donahue TL, Pauly HM (2021) Osteoarthritic meniscal entheses exhibit altered collagen
656 fiber orientation. *Connect Tissue Res* 1–5

- 657 56. Hino T, Furumatsu T, Miyazawa S, Fujii M, Kodama Y, Kamatsuki Y, Okazaki Y, Masuda S,
658 Okazaki Y, Ozaki T (2020) A histological study of the medial meniscus posterior root tibial
659 insertion. *Connect Tissue Res* 61:546–553
- 660 57. Ishizuka S, Sakai T, Hiraiwa H, et al (2016) Hypoxia-inducible factor-2 α induces expression of
661 type X collagen and matrix metalloproteinases 13 in osteoarthritic meniscal cells.
662 *Inflammation Research* 65:439–448
- 663 58. Jacquet C, Erivan R, Argenson JN, Parratte S, Ollivier M (2018) Effect of 3 Preservation
664 Methods (Freezing, Cryopreservation, and Freezing + Irradiation) on Human Menisci
665 Ultrastructure: An Ex Vivo Comparative Study With Fresh Tissue as a Gold Standard. *American*
666 *Journal of Sports Medicine* 46:2899–2904
- 667 59. Jacquet C, Erivan R, Sharma A, Pithioux M, Parratte S, Argenson JN, Ollivier M (2019)
668 Preservation Methods Influence the Biomechanical Properties of Human Lateral Menisci: An
669 Ex Vivo Comparative Study of 3 Methods. *Orthop J Sports Med* 7:2325967119841622
- 670 60. Johnson K, Hashimoto S, Lotz M, Pritzker K, Goding J, Terkeltaub R (2001) Up-regulated
671 expression of the phosphodiesterase nucleotide pyrophosphatase family member PC-1 is a
672 marker and pathogenic factor for knee meniscal cartilage matrix calcification. *Arthritis Rheum*
673 44:1071–1081
- 674 61. Karjalainen VP, Kestila I, Finnila MA, Folkesson E, Turkiewicz A, Onnerfjord P, Hughes V,
675 Tjornstrand J, Englund M, Saarakkala S (2021) Quantitative three-dimensional collagen
676 orientation analysis of human meniscus posterior horn in health and osteoarthritis using
677 micro-computed tomography. *Osteoarthritis Cartilage* 29:762–772
- 678 62. Karube S, Shoji H (1981) Compositional changes of glycosaminoglycans of the human menisci
679 with age and degenerative joint disease. *Journal of the Japanese Orthopaedic Association*
680 56:51–57
- 681 63. Katsuragawa Y, Saitoh K, Tanaka N, et al (2010) Changes of human menisci in osteoarthritic
682 knee joints. *Osteoarthritis Cartilage* 18:1133–1143

- 683 64. Kiraly AJ, Roberts A, Cox M, Mauerhan D, Hanley E, Sun Y (2017) Comparison of Meniscal Cell-
684 Mediated and Chondrocyte-Mediated Calcification. *Open Orthop J* 11:225–233
- 685 65. Kodama Y, Furumatsu T, Maehara A, Ozaki T (2018) Composition of Cell Clusters in Torn
686 Menisci and Their Extracellular Matrix Components. *Acta Med Okayama* 72:499–506
- 687 66. Kwok J, Grogan S, Meckes B, Arce F, Lal R, D’Lima D (2014) Atomic force microscopy reveals
688 age-dependent changes in nanomechanical properties of the extracellular matrix of native
689 human menisci: Implications for joint degeneration and osteoarthritis. *Nanomedicine*
690 10:1777–1785
- 691 67. Lopez-Franco M, Lopez-Franco O, Murciano-Anton MA, Canamero-Vaquero M, Fernandez-
692 Acenero MJ, Herrero-Beaumont G, Gomez-Barrena E (2016) Meniscal degeneration in human
693 knee osteoarthritis: in situ hybridization and immunohistochemistry study. *Arch Orthop*
694 *Trauma Surg* 136:175–183
- 695 68. Masuda I, Ishikawa K, Usuku G (1991) A histologic and immunohistochemical study of calcium
696 pyrophosphate dihydrate crystal deposition disease. *Clin Orthop Relat Res* 272–287
- 697 69. McDaniel D, Tilton E, Dominick K, Flory K, Ernest T, Johnson JC, Main DC, Kondrashov P (2017)
698 Histological characteristics of knee menisci in patients with osteoarthritis. *Clinical Anatomy*
699 30:805–810
- 700 70. Melrose J, Fuller ES, Roughley PJ, Smith MM, Kerr B, Hughes CE, Caterson B, Little CB (2008)
701 Fragmentation of decorin, biglycan, lumican and keratocan is elevated in degenerate human
702 meniscus, knee and hip articular cartilages compared with age-matched macroscopically
703 normal and control tissues. *Arthritis Res Ther.*
704 <https://doi.org/http://dx.doi.org/10.1186/ar2453>
- 705 71. Mine T, Ihara K, Kawamura H, Date R, Umehara K (2013) Collagen expression in various
706 degenerative meniscal changes: an immunohistological study. *Journal of Orthopaedic Surgery*
707 21:216–220

- 708 72. Monibi FA, Pannellini T, Otero M, Warren RF, Rodeo SA (2021) Histologic and molecular
709 features in pathologic human menisci from knees with and without osteoarthritis. *Journal of*
710 *Orthopaedic Research* 01:1
- 711 73. Musumeci G, Trovato FM, Loreto C, Leonardi R, Szychlinska MA, Castorina S, Mobasher A
712 (2014) Lubricin expression in human osteoarthritic knee meniscus and synovial fluid: a
713 morphological, immunohistochemical and biochemical study. *Acta Histochem* 116:965–972
- 714 74. Nagata N, Koshino T, Saito T (2000) Up-regulation of CD44-positive cells in medial meniscus
715 of medial compartmental osteoarthritis of the knee. *Knee* 7:3–9
- 716 75. Park DY, Min BH, Choi BH, et al (2015) The Degeneration of Meniscus Roots Is Accompanied
717 by Fibrocartilage Formation, Which May Precede Meniscus Root Tears in Osteoarthritic
718 Knees. *American Journal of Sports Medicine* 43:3034–3044
- 719 76. Park J, Lee HS, Go EB, Lee JY, Kim JY, Lee SY, Lee DH (2021) Proteomic analysis of the
720 meniscus cartilage in osteoarthritis. *Int J Mol Sci* 22:30
- 721 77. Pordzik J, Bernstein A, Mayr HO, Latorre SH, Maks A, Schmal H, Seidenstuecker M (2020)
722 Analysis of proteoglycan content and biomechanical properties in arthritic and arthritis-free
723 menisci. *Applied Sciences (Switzerland)* 10:1–12
- 724 78. Roller BL, Monibi FA, Stoker AM, Kuroki K, Bal BS, Cook JL (2015) Characterization of knee
725 meniscal pathology: correlation of gross, histologic, biochemical, molecular, and radiographic
726 measures of disease. *J Knee Surg* 28:175–182
- 727 79. Roller BL, Monibi F, Stoker AM, Bal BS, Stannard JP, Cook JL (2015) Characterization of
728 Meniscal Pathology Using Molecular and Proteomic Analyses. *J Knee Surg* 28:496–505
- 729 80. Sladojevic I, Krivokuca Z, Gajanin V, Manojlovic S (2016) Expression of Collagen Type I in
730 Unaltered and Osteoarthritic Menisci of Knee Joint. *Med Pregl* 69:16–23
- 731 81. Son M, Goodman SB, Chen W, Hargreaves BA, Gold GE, Levenston ME (2013) Regional
732 variation in T1rho and T2 times in osteoarthritic human menisci: correlation with mechanical
733 properties and matrix composition. *Osteoarthritis Cartilage* 21:796–805

- 734 82. Sun Y, Mauerhan DR, Honeycutt PR, Kneisl JS, Norton HJ, Zinchenko N, Hanley Jr EN, Gruber
735 HE (2010) Calcium deposition in osteoarthritic meniscus and meniscal cell culture. *Arthritis*
736 *Res Ther.* <https://doi.org/http://dx.doi.org/10.1186/ar2968>
- 737 83. Sun Y, Mauerhan DR, Kneisl JS, James Norton H, Zinchenko N, Ingram J, Hanley Jr. EN, Gruber
738 HE (2012) Histological examination of collagen and proteoglycan changes in osteoarthritic
739 menisci. *Open Rheumatol J* 6:24–32
- 740 84. Takahashi M, Suzuki M, Kushida K, Hoshino H, Inoue T (1998) The effect of aging and
741 osteoarthritis on the mature and senescent cross-links of collagen in human meniscus.
742 *Arthroscopy - Journal of Arthroscopic and Related Surgery* 14:366–372
- 743 85. Wang J, Roberts S, Kuiper JH, Zhang W, Garcia J, Cui Z, Wright K (2020) Characterization of
744 regional meniscal cell and chondrocyte phenotypes and chondrogenic differentiation with
745 histological analysis in osteoarthritic donor-matched tissues. *Sci Rep* 10:21658
- 746 86. Warnecke D, Balko J, Haas J, et al (2020) Degeneration alters the biomechanical properties
747 and structural composition of lateral human menisci. *Osteoarthritis Cartilage* 28:1482–1491
- 748 87. Zhang D, Cheriyan T, Martin SD, Schmid TM, Spector M (2012) Lubricin Distribution in the
749 Menisci and Labra of Human Osteoarthritic Joints. *Cartilage* 3:165–172
- 750 88. Fink B, Egl M, Singer J, Fuerst M, Bubenheim M, Neuen-Jacob E (2007) Morphologic changes
751 in the vastus medialis muscle in patients with osteoarthritis of the knee. *Arthritis Rheum*
752 56:3626–3633
- 753 89. Mattiello-Sverzut AC, Petersen SG, Kjaer M, Mackey AL (2013) Morphological adaptation of
754 muscle collagen and receptor of advanced glycation end product (RAGE) in osteoarthritis
755 patients with 12 weeks of resistance training: influence of anti-inflammatory or glucosamine
756 treatment. *Rheumatol Int* 33:2215–2224
- 757 90. Noehren B, Kosmac K, Walton RG, Murach KA, Lyles MF, Loeser RF, Peterson CA, Messier SP
758 (2018) Alterations in quadriceps muscle cellular and molecular properties in adults with
759 moderate knee osteoarthritis. *Osteoarthritis Cartilage* 26:1359–1368

- 760 91. Serrao PRMS, Vasilceac FA, Gramani-Say K, Lessi GC, Reiff RBM, Mattiello-Sverzut AC,
761 Mattiello SM (2014) Expression of receptors of advanced glycation end product (RAGE) and
762 types I, III and IV collagen in the vastus lateralis muscle of men in early stages of knee
763 osteoarthritis. *Connect Tissue Res* 55:331–338
- 764 92. Cillero-Pastor B, Eijkel GB, Blanco FJ, Heeren RM (2015) Protein classification and distribution
765 in osteoarthritic human synovial tissue by matrix-assisted laser desorption ionization mass
766 spectrometry imaging. *Anal Bioanal Chem* 407:2213–2222
- 767 93. Cutolo M, Picasso M, Ponassi M, Sun MZ, Balza E (1992) Tenascin and fibronectin distribution
768 in human normal and pathological synovium. *Journal of Rheumatology* 19:1439–1447
- 769 94. Di Cesare PE, Fang C, Leslie MP, Della Valle CJ, Gold JM, Tulli H, Perris R, Carlson CS (1999)
770 Localization and expression of cartilage oligomeric matrix protein by human rheumatoid and
771 osteoarthritic synovium and cartilage. *Journal of Orthopaedic Research* 17:437–445
- 772 95. Ea HK, Chobaz V, Nguyen C, et al (2013) Pathogenic Role of Basic Calcium Phosphate Crystals
773 in Destructive Arthropathies. *PLoS ONE* [Electronic Resource].
774 <https://doi.org/http://dx.doi.org/10.1371/journal.pone.0057352>
- 775 96. Ene R, Sinescu RD, Ene P, Cirstoiu MM, Cirstoiu FC (2015) Synovial inflammation in patients
776 with different stages of knee osteoarthritis. *Rom J Morphol Embryol* 56:169–173
- 777 97. Fan L, Wang Q, Liu R, Zong M, He D, Zhang H, Ding Y, Ma J (2012) Citrullinated fibronectin
778 inhibits apoptosis and promotes the secretion of pro-inflammatory cytokines in fibroblast-like
779 synoviocytes in rheumatoid arthritis. *Arthritis Res Ther*. <https://doi.org/10.1186/ar4112>
- 780 98. Kaufmann J, Mueller A, Voigt A, Carl HD, Gursche A, Zacher J, Stein G, Hein G (2003)
781 Hydroxypyridinium collagen crosslinks in serum, urine, synovial fluid and synovial tissue in
782 patients with rheumatoid arthritis compared with osteoarthritis. *Rheumatology* 42:314–320
- 783 99. Kragstrup TW, Sohn DH, Lepus CM, Onuma K, Wang Q, Robinson WH, Sokolove J (2019)
784 Fibroblast-like synovial cell production of extra domain A fibronectin associates with
785 inflammation in osteoarthritis. *BMC Rheumatol* 3:46

- 786 100. Nakashima K, Koshino T, Saito T (1998) Synovial immunohistochemical changes after high
787 tibial osteotomy for osteoarthritis of the knee. Two-year prospective follow-up. *Bull Hosp*
788 *Joint Dis* 57:187–194
- 789 101. Nikkari L, Haapasalmi K, Aho H, Torvinen A, Sheppard D, Larjava H, Heino J (1995) Localization
790 of the αV subfamily of integrins and their putative ligands in synovial lining cell layer. *Journal*
791 *of Rheumatology* 22:16–23
- 792 102. Nishida K, Inoue H, Toda K, Murakami T (1995) Localization of the glycosaminoglycans in the
793 synovial tissues from osteoarthritic knees. *Acta Med Okayama* 49:287–294
- 794 103. Rafael MS, Cavaco S, Viegas CSB, Santos S, Ramos A, Willems BAG, Herfs M, Theuwissen E,
795 Vermeer C, Simes DC (2014) Insights into the association of Gla-rich protein and
796 osteoarthritis, novel splice variants and gamma-carboxylation status. *Mol Nutr Food Res*
797 58:1636–1646
- 798 104. Richardot P, Charni-Ben Tabassi N, Toh L, Marotte H, Bay-Jensen AC, Miossec P, Garnero P
799 (2009) Nitrated type III collagen as a biological marker of nitric oxide-mediated synovial tissue
800 metabolism in osteoarthritis. *Osteoarthritis Cartilage* 17:1362–1367
- 801 105. Saito I, Koshino T, Nakashima K, Uesugi M, Saito T (2002) Increased cellular infiltrate in
802 inflammatory synovia of osteoarthritic knees. *Osteoarthritis Cartilage* 10:156–162
- 803 106. Takahashi M, Kushida K, Hoshino H, Suzuki M, Sano M, Miyamoto S, Inoue T (1996)
804 Concentrations of pyridinoline and deoxypyridinoline in joint tissues from patients with
805 osteoarthritis or rheumatoid arthritis. *Ann Rheum Dis* 55:324–327
- 806 107. Wang X, Dong C, Li N, Ma Q, Yun Z, Cai C, An M, Ma B (2018) Modulation of TGF- β activity by
807 latent TGF- β -binding protein 1 in human osteoarthritis fibroblast-like synoviocytes. *Mol Med*
808 *Rep* 17:1893–1900
- 809 108. Christensen AF, Sorensen GL, Junker K, Revald P, Varnum C, Issa SF, Junker P, Sorensen FB
810 (2019) Site-specific absence of microfibrillar-associated protein 4 (MFAP4) from the internal
811 elastic membrane of arterioles in the rheumatoid arthritis synovial membrane: an

- 812 immunohistochemical study in patients with advanced rheumatoid arthritis versus osteoar.
813 APMIS 127:588–593
- 814 109. Konttinen YT, Li TF, Xu JW, et al (1999) Expression of laminins and their integrin receptors in
815 different conditions of synovial membrane and synovial membrane-like interface tissue. Ann
816 Rheum Dis 58:683–690
- 817 110. Konttinen YT, Li TF, Mandelin J, Ainola M, Lassus J, Virtanen I, Santavirta S, Tammi M, Tammi
818 R (2001) Hyaluronan synthases, hyaluronan, and its CD44 receptor in tissue around loosened
819 total hip prostheses. Journal of Pathology 194:384–390
- 820 111. Li TF, Xu JW, Santavirta S, Nordsletten L, Michelsson O, Takagi M, Virtanen I, Konttinen YT
821 (2000) Distribution of fibronectins and their integrin receptors in interface tissue from aseptic
822 loosening of hip prostheses. Clin Exp Rheumatol 18:221–225
- 823 112. Turdean SG, Jung I, Gurzu S, Zazgyva A, Fetyko A, Roman CO, Turcu M, Pop TS (2017)
824 Histopathological evaluation and expression of the pluripotent mesenchymal stem cell-like
825 markers CD105 and CD44 in the synovial membrane of patients with primary versus
826 secondary hip osteoarthritis. Journal of Investigative Medicine 65:363–369
- 827 113. Mapp PI, Revell PA (1985) Fibronectin production by synovial intimal cells. Rheumatol Int
828 5:229–237
- 829 114. Pollock LE, Lalor P, Revell PA (1990) Type IV collagen and laminin in the synovial intimal layer:
830 an immunohistochemical study. Rheumatol Int 9:277–280
- 831 115. Rinaldi N, Barth TF, Weis D, Schwarz-Eywill M, Pezzutto A, Lukoschek M, Brocai D, Brado B
832 (1998) Loss of laminin and of the laminin receptor integrin subunit alpha 6 in situ correlates
833 with cytokine induced down regulation of alpha 6 on fibroblast-like synoviocytes from
834 rheumatoid arthritis. Ann Rheum Dis 57:559–565
- 835 116. Scott DL, Wainwright AC, Walton KW, Williamson N (1981) Significance of fibronectin in
836 rheumatoid arthritis and osteoarthrosis. Ann Rheum Dis 40:142–153

- 837 117. van Linthoudt D, Beutler A, Clayburne G, Sieck M, Fernandes L, Schumacher Jr HR,
838 Schumacher Jr. HR, Schumacher Jr HR (1997) Morphometric studies on synovium in
839 advanced osteoarthritis: is there an association between apatite-like material and collagen
840 deposits? *Clin Exp Rheumatol* 15:493–497
- 841 118. Worrall JG, Wilkinson LS, Bayliss MT, Edwards JCW (1994) Zonal distribution of chondroitin-4-
842 sulphate/dermatan sulphate and chondroitin-6-sulphate in normal and diseased human
843 synovium. *Ann Rheum Dis* 53:35–38
- 844 119. Dijkgraaf LC, Liem RSB, de Bont LGM (1997) Ultrastructural characteristics of the synovial
845 membrane in osteoarthritic temporomandibular joints. *Journal of Oral & Maxillofacial*
846 *Surgery* 55:1269–1280
- 847 120. Okamoto K, Kiga N, Shinohara Y, Tojyo I, Fujita S (2015) Effect of interleukin-1beta and
848 dehydroepiandrosterone on the expression of lumican and fibromodulin in fibroblast-like
849 synovial cells of the human temporomandibular joint. *European Journal of Histochemistry*
850 59:2440
- 851 121. Chang X, Yamada R, Suzuki A, Kochi Y, Sawada T, Yamamoto K (2005) Citrullination of
852 fibronectin in rheumatoid arthritis synovial tissue. *Rheumatology* 44:1374–1382
- 853 122. Hino K, Shiozawa S, Kuroki Y, Ishikawa H, Shiozawa K, Sekiguchi K, Hirano H, Sakashita E,
854 Miyashita K, Chihara K (1995) EDA-containing fibronectin is synthesized from rheumatoid
855 synovial fibroblast-like cells. *Arthritis Rheum* 38:678–683
- 856 123. Itokazu M, Shinozaki M, Ohno T (1998) Quantitative analysis of hyaluronan in the synovial
857 tissues of patients with joint disorders. *Clin Rheumatol* 17:261–262
- 858 124. Klareskog L, Johnell O, Hulth A, Holmdahl R, Rubin K (1986) Reactivity of monoclonal anti-
859 type II collagen antibodies with cartilage and synovial tissue in rheumatoid arthritis and
860 osteoarthritis. *Arthritis Rheum* 29:730–738

- 861 125. Kriegsmann J, Berndt A, Hansen T, et al (2004) Expression of fibronectin splice variants and
862 oncofetal glycosylated fibronectin in the synovial membranes of patients with rheumatoid
863 arthritis and osteoarthritis. *Rheumatol Int* 24:25–33
- 864 126. Poduval P, Sillat T, Virtanen I, Dabagh M, Konttinen YT (2010) Immigration check for
865 neutrophils in RA lining: Laminin $\alpha 5$ low expression regions act as exit points. *Scand J*
866 *Rheumatol* 39:132–140
- 867 127. Santiago B, Baleux F, Palao G, Gutiérrez-Cañás I, Ramírez JC, Arenzana-Seisdedos F, Pablos JL
868 (2006) CXCL12 is displayed by rheumatoid endothelial cells through its basic amino-terminal
869 motif on heparan sulfate proteoglycans. *Arthritis Res Ther*. <https://doi.org/10.1186/ar1900>
- 870 128. Schneider M, Voss B, Rauterberg J, Menke M, Pauly T, Miehlke RK, Friemann J, Gerlach U
871 (1994) Basement membrane proteins in synovial membrane: distribution in rheumatoid
872 arthritis and synthesis by fibroblast-like cells. *Clin Rheumatol* 13:90–97
- 873 129. Scott DL, Salmon M, Morris CJ, Wainwright AC, Walton KW (1984) Laminin and vascular
874 proliferation in rheumatoid arthritis. *Ann Rheum Dis* 43:551–555
- 875 130. Worrall JG, Bayliss MT, Edwards JCW (1991) Morphological localization of hyaluronan in
876 normal and diseased synovium. *Journal of Rheumatology* 18:1466–1472
- 877 131. Exposito Molinero MR, de Miguel Mendieta E, Expósito Molinero MR, de Miguel Mendieta E
878 (2016) Discriminant validity study of Achilles enthesitis ultrasound. *Reumatol Clin* 12:206–209
- 879 132. Ibrahim M, Kartus JT, Steigen SE, Olsen R, Meknas K (2019) More tendon degeneration in
880 patients with shoulder osteoarthritis. *Knee Surgery, Sports Traumatology, Arthroscopy*
881 27:267–275
- 882 133. Ibrahim M, Hedlundh U, Sernert N, Meknas K, Haag L, Movin T, Papadogiannakis N, Kartus JT
883 (2021) Histological and ultrastructural degenerative findings in the gluteus medius tendon
884 after hip arthroplasty. *J Orthop Surg Res* 16:339

- 885 134. Mazzocca AD, McCarthy MBR, Ledgard FA, et al (2013) Histomorphologic changes of the long
886 head of the biceps tendon in common shoulder pathologies. *Arthroscopy - Journal of*
887 *Arthroscopic and Related Surgery* 29:972–981
- 888 135. Meknas K, Johansen O, Steigen SE, Olsen R, Jorgensen L, Kartus J (2012) Could tendinosis be
889 involved in osteoarthritis? *Scand J Med Sci Sports* 22:627–634
- 890 136. Loeser RF, Olex AL, McNulty MA, Carlson CS, Callahan M, Ferguson C, Fetrow JS (2013)
891 Disease Progression and Phasic Changes in Gene Expression in a Mouse Model of
892 Osteoarthritis. *PLoS ONE [Electronic Resource]*.
893 <https://doi.org/http://dx.doi.org/10.1371/journal.pone.0054633>
- 894 137. Anderson-Mackenzie JM, Billingham ME, Bailey AJ (1999) Collagen remodeling in the anterior
895 cruciate ligament associated with developing spontaneous murine osteoarthritis. *Biochem*
896 *Biophys Res Commun* 258:763–767
- 897 138. Ramos-Mucci L, Javaheri B, Van THR, Bou-Gharios G, Pitsillides AA, Comerford E, Poulet B
898 (2020) Meniscal and ligament modifications in spontaneous and post-traumatic mouse
899 models of osteoarthritis. *Arthritis Res Ther*.
900 <https://doi.org/http://dx.doi.org/10.1186/s13075-020-02261-5>
- 901 139. Walton M (1977) Degenerative joint disease in the mouse knee; radiological and
902 morphological observations. *Journal of Pathology* 123:97–107
- 903 140. Miller D, Desutter C, Scott A, Koglin L, Hart DA, Salo P, Leonard C, Mammoto T, Bray RC
904 (2014) Vascular structure and function in the medial collateral ligament of anterior cruciate
905 ligament transected rabbit knees. *Journal of Orthopaedic Research* 32:1104–1110
- 906 141. Barton KI, Heard BJ, Kroker A, et al (2021) Structural Consequences of a Partial Anterior
907 Cruciate Ligament Injury on Remaining Joint Integrity: Evidence for Ligament and Bone
908 Changes Over Time in an Ovine Model. *American Journal of Sports Medicine* 49:637–648

- 909 142. Funakoshi Y, Hariu M, Tapper JE, Marchuk LL, Shrive NG, Kanaya F, Rattner JB, Hart DA, Frank
910 CB (2007) Periarticular ligament changes following ACL/MCL transection in an ovine stifle
911 joint model of osteoarthritis. *Journal of Orthopaedic Research* 25:997–1006
- 912 143. Bedingfield SK, Colazo JM, Di Francesco M, et al (2021) Top-Down Fabricated microPlates for
913 Prolonged, Intra-articular Matrix Metalloproteinase 13 siRNA Nanocarrier Delivery to Reduce
914 Post-traumatic Osteoarthritis. *ACS Nano* 19:14475–14491
- 915 144. Lee KI, Gamini R, Olmer M, et al (2020) Mohawk is a transcription factor that promotes
916 meniscus cell phenotype and tissue repair and reduces osteoarthritis severity. *Sci Transl Med*
917 12:28
- 918 145. Muschter D, Fleischhauer L, Taheri S, Schilling AF, Clausen-Schaumann H, Grassel S (2020)
919 Sensory neuropeptides are required for bone and cartilage homeostasis in a murine
920 destabilization-induced osteoarthritis model. *Bone*.
921 <https://doi.org/http://dx.doi.org/10.1016/j.bone.2019.115181>
- 922 146. Hellio Le Graverand MP, Vignon E, Otterness IG, Hart DA (2001) Early changes in lapine
923 menisci during osteoarthritis development: Part I: cellular and matrix alterations.
924 *Osteoarthritis Cartilage* 9:56–64
- 925 147. Le Graverand MPH, Sciore P, Eggerer J, et al (2001) Formation and phenotype of cell clusters
926 in osteoarthritic meniscus. *Arthritis Rheum* 44:1808–1818
- 927 148. Levillain A, Magoariec H, Boulocher C, Decambron A, Viateau V, Hoc T (2017) Effects of a
928 viscosupplementation therapy on rabbit menisci in an anterior cruciate ligament transection
929 model of osteoarthritis. *J Biomech* 58:147–154
- 930 149. Levillain A, Magoariec H, Boulocher C, Decambron A, Viateau V, Hoc T (2017) Viscoelastic
931 properties of rabbit osteoarthritic menisci: A correlation with matrix alterations. *J Mech*
932 *Behav Biomed Mater* 65:1–10

- 933 150. Zhao J, Huang S, Zheng J, Zhong C, Tang C, Zheng L, Zhang Z, Xu J (2014) Changes of rabbit
934 meniscus influenced by hyaline cartilage injury of osteoarthritis. *Int J Clin Exp Med* 7:2948–
935 2956
- 936 151. Endo J, Sasho T, Akagi R, Muramatsu Y, Watanabe A, Akatsu Y, Fukawa T, Tahara M,
937 Yamaguchi S (2018) Comparative Analysis of Gene Expression between Cartilage and Menisci
938 in Early-Phase Osteoarthritis of the Knee-An Animal Model Study. *Journal of Knee Surgery*
939 31:664–669
- 940 152. Bansal S, Miller LM, Patel JM, et al (2020) Transection of the medial meniscus anterior horn
941 results in cartilage degeneration and meniscus remodeling in a large animal model. *Journal of*
942 *Orthopaedic Research* 14:14
- 943 153. Shi X, Yu W, Wang T, Battulga O, Wang C, Shu Q, Yang X, Liu C, Guo C (2020)
944 Electroacupuncture alleviates cartilage degradation: Improvement in cartilage biomechanics
945 via pain relief and potentiation of muscle function in a rabbit model of knee osteoarthritis.
946 *Biomedicine and Pharmacotherapy*.
947 <https://doi.org/http://dx.doi.org/10.1016/j.biopha.2019.109724>
- 948 154. Almasry SM, Soliman HM, El-Tarhouny SA, Algaidi SA, Ragab EM (2015) Platelet rich plasma
949 enhances the immunohistochemical expression of platelet derived growth factor and
950 vascular endothelial growth factor in the synovium of the meniscectomized rat models of
951 osteoarthritis. *Annals of Anatomy* 197:38–49
- 952 155. Bryk M, Chwastek J, Mlost J, Kostrzewa M, Starowicz K (2021) Sodium Monoiodoacetate
953 Dose-Dependent Changes in Matrix Metalloproteinases and Inflammatory Components as
954 Prognostic Factors for the Progression of Osteoarthritis. *Front Pharmacol* 12:643605
- 955 156. Castrogiovanni P, Di Rosa M, Ravalli S, Castorina A, Guglielmino C, Imbesi R, Vecchio M, Drago
956 F, Szychlinska MA, Musumeci G (2019) Moderate physical activity as a prevention method for
957 knee osteoarthritis and the role of synoviocytes as biological key. *Int J Mol Sci*.
958 <https://doi.org/10.3390/ijms20030511>

- 959 157. Dai S, Liang T, Fujii T, He S, Zhang F, Jiang H, Liu B, Shi X, Luo Z, Yang H (2020) Increased elastic
960 modulus of the synovial membrane in a rat ACLT model of osteoarthritis revealed by atomic
961 force microscopy. *Brazilian Journal of Medical & Biological Research* 53:e10058
- 962 158. Gamal N, Abou-Rabia NM, El Ebiary FH, Khalaf G, Raafat MH (2019) The possible therapeutic
963 role of platelet rich plasma on a model of osteoarthritis in male albino rat. *Histological and*
964 *immunohistochemical study. Egyptian Journal of Histology* 42:554–566
- 965 159. Li X, Mei W, Huang Z, et al (2020) Casticin suppresses monoiodoacetic acid-induced knee
966 osteoarthritis through inhibiting HIF-1 α /NLRP3 inflammasome signaling. *Int*
967 *Immunopharmacol.* <https://doi.org/http://dx.doi.org/10.1016/j.intimp.2020.106745>
- 968 160. Zhang L, Li X, Zhang H, Huang Z, Zhang N, Zhang L, Xing R, Wang P (2021) Agnuside Alleviates
969 Synovitis and Fibrosis in Knee Osteoarthritis through the Inhibition of HIF-1 α and NLRP3
970 Inflammasome. *Mediators Inflamm.* <https://doi.org/10.1155/2021/5534614>
- 971 161. Zhang L, Li M, Li X, Liao T, Ma Z, Xing R, Wang P, Mao J (2021) Characteristics of sensory
972 innervation in synovium of rats within different knee osteoarthritis models and the
973 correlation between synovial fibrosis and hyperalgesia. *J Adv Res.*
974 <https://doi.org/10.1016/j.jare.2021.06.007>
- 975 162. Zhang L, Xing R, Huang Z, Zhang N, Zhang L, Li X, Wang P (2019) Inhibition of Synovial
976 Macrophage Pyroptosis Alleviates Synovitis and Fibrosis in Knee Osteoarthritis. *Mediators*
977 *Inflamm.* <https://doi.org/10.1155/2019/2165918>
- 978 163. Zhang L, Zhang L, Huang Z, et al (2019) Increased HIF-1 α in knee osteoarthritis aggravate
979 synovial fibrosis via fibroblast-like synoviocyte pyroptosis. *Oxid Med Cell Longev.*
980 <https://doi.org/10.1155/2019/6326517>
- 981 164. Lapadula G, Nico B, Cantatore FP, La Canna R, Roncali L, Pipitone V (1995) Early
982 ultrastructural changes of articular cartilage and synovial membrane in experimental vitamin
983 A-induced osteoarthritis. *Journal of Rheumatology* 22:1913–1921

- 984 165. Wei Q, Kong N, Liu X, Tian R, Jiao M, Li Y, Guan H, Wang K, Yang P (2021) Pirfenidone
985 attenuates synovial fibrosis and postpones the progression of osteoarthritis by anti-fibrotic
986 and anti-inflammatory properties in vivo and in vitro. *J Transl Med* 19:157
- 987 166. McErlain DD, Appleton CTG, Litchfield RB, Pitelka V, Henry JL, Bernier SM, Beier F, Holdsworth
988 DW (2008) Study of subchondral bone adaptations in a rodent surgical model of OA using in
989 vivo micro-computed tomography. *Osteoarthritis Cartilage* 16:458–469
- 990 167. Dabrowska S, Ekiert-Radecka M, Karbowniczek J, Weglarz WP, Heljak M, Lojkowski M,
991 Obuchowicz R, Swieszkowski W, Mlyniec A (2023) Calcification alters the viscoelastic
992 properties of tendon fascicle bundles depending on matrix content. *Acta Biomater.*
993 <https://doi.org/10.1016/j.actbio.2023.05.010>
- 994 168. Ricard-Blum S (2011) The Collagen Family. *Cold Spring Harb Perspect Biol* 3:1–19
- 995 169. Chen D, Smith LR, Khandekar G, Patel P, Yu CK, Zhang K, Chen CS, Han L, Wells RG (2020)
996 Distinct effects of different matrix proteoglycans on collagen fibrillogenesis and cell-mediated
997 collagen reorganization. *Sci Rep.* <https://doi.org/10.1038/s41598-020-76107-0>
- 998 170. Naba A (2023) Ten Years of Extracellular Matrix Proteomics: Accomplishments, Challenges,
999 and Future Perspectives. *Mol Cell Proteomics* 22:100528
- 1000 171. McCoy AM (2015) Animal Models of Osteoarthritis: Comparisons and Key Considerations. *Vet*
1001 *Pathol* 52:803–818
- 1002 172. Cope PJ, Ourradi K, Li Y, Sharif M (2019) Models of osteoarthritis: the good, the bad and the
1003 promising. *Osteoarthritis Cartilage* 27:230–239
- 1004 173. Proffen BL, McElfresh M, Fleming BC, Murray MM (2012) A comparative anatomical study of
1005 the human knee and six animal species. *Knee* 19:493–499
- 1006 174. Derfus BA, Kurian JB, Butler JJ, Daft LJ, Carrera GF, Ryan LM, Rosenthal AK (2002) The high
1007 prevalence of pathologic calcium crystals in pre-operative knees. *J Rheumatol* 29:

- 1008 175. Mathes T, Klößen P, Pieper D (2017) Frequency of data extraction errors and methods to
1009 increase data extraction quality: a methodological review. BMC Med Res Methodol.
1010 <https://doi.org/10.1186/S12874-017-0431-4>
- 1011 176. Buckley CD, Ospelt C, Gay S, Midwood KS (2021) Location, location, location: how the tissue
1012 microenvironment affects inflammation in RA. Nature Reviews Rheumatology 2021 17:4
1013 17:195–212
- 1014 177. Sharma L (2021) Osteoarthritis of the Knee. New England Journal of Medicine 384:51–59
1015