

1 **Coronary Artery anomalies in Patients Undergoing transcatheter**
2 **aortic valve REplacement.**

3 **The CAPTURE registry**

4
5 Omar A. Oliva¹, MD; Lorenzo Scalia¹, MD; Antonio Sisinni¹, MD; Enrico Poletti¹, MD; Jessica
6 Zannoni¹, MD; Mattia Mazzucca¹, MD; Enrico Criscione¹, MD; Antonio Popolo Rubbio¹, MD;
7 Riccardo Gorla¹, MD, PhD; Mauro Agnifili¹, MD; Francesco Bedogni¹, MD; Luca Testa¹, MD, PhD.

8
9 ¹Department of Clinical and Interventional Cardiology, IRCCS Policlinico San Donato, 20097 San
10 Donato Milanese (MI), Italy

11 *Address for correspondence:*

12 Luca Testa, MD, PhD

13 Department of Clinical and Interventional Cardiology, IRCCS Policlinico San Donato

14 Piazza Edmondo Malan 2, 20097 San Donato Milanese (Milano), Italy.

15 Email: luctes@gmail.com

16

17
18 Text word count: 5000

19

20 **Short title:** The CAPTURE registry

21 **Abstract**

22 **Background:** The incidence and possible implications of coronary artery anomalies (CAA) in
23 patients undergoing transcatheter aortic valve replacement (TAVR) are uncertain.

24 **Aims:** To evaluate the impact of CAA on TAVR outcomes, and to suggest possible strategies to
25 prevent CAA related complications.

26 **Methods:** Among 2,164 consecutive patients who underwent TAVR in our center, 15 (0.69%) were
27 identified to have a CAA, based on pre-operative Computed Tomography (CT) scans.

28 **Results:** CT-angiography revealed the following features of CAA: the majority of anomalous CAA
29 concerned the right coronary artery (80%), followed by the left main (13.3%) and the left
30 circumflex (6.7%). An intramural course was observed only in 26.7% patients, whereas an acute
31 take-off was detected in more than half of the study cohort (53.3%). High-risk sudden cardiac death
32 features were observed in 6 (40%) patients.

33 Technical success was 86.7%, device success was 80%. One patient experienced a cardiac arrest 15
34 minutes after procedure, resulting from occlusion of the anomalous right coronary artery with the
35 ostium located at the right-to-non coronary commissure. There were no cases of \geq moderate
36 paravalvular leak or stroke. One non-cardiac related death was recorded 4 months after the
37 procedure.

38 **Conclusions:** The interaction between transcatheter bioprosthesis and different CAA types could
39 lead to ominous sequelae, if not promptly recognized and treated accordingly.

40

41 **Keywords**

42 Coronary artery anomalies; TAVI; bioprosthesis; aortic valve replacement; aortic stenosis.

43

44 **Abbreviations list**

45 BEV, balloon-expandable valve; CAA, coronary artery anomalies; CT, Computed Tomography;
46 LAD, left anterior descending; LCx, left circumflex artery; LSV, left sinus of Valsalva; PVL,
47 paravalvular leak; RCA, right coronary artery; RSV, right sinus of Valsalva; SAVR, surgical aortic
48 valve replacement; STJ, sino-tubular junction; TAVR, transcatheter aortic valve replacement; TTE,
49 transthoracic echocardiography; VARC-3, Valve Academic Research Consortium-3; SEV, self-
50 expanding valve.

51 **Introduction**

52 Coronary artery anomalies (CAA) are rare findings, often incidentally encountered. The most
53 common phenotype is an anomalous origin from the aorta,¹ occurring in approximately 0.8% of
54 patients undergoing coronary artery angiography. However, if we exclude cases where the left
55 anterior descending (LAD) and left circumflex artery (LCx) have separated origins from the left
56 sinus of Valsalva (LSV), the incidence drops to 0.2%.² The assessment of the risk of sudden cardiac
57 death and subsequent treatment is still a matter of debate due to limited data availability.³
58 Nevertheless, there are few anomalies that could be injured during surgical aortic valve replacement
59 (SAVR), mainly LCx from right sinus of Valsalva (RSV) with a retro-aortic course.^{4,5}

60 In this variant, the peri-procedural is determined by the prosthesis compression or suture
61 ligation.⁶ Surgeons have implemented different precautions to ensure the safety of surgical
62 treatment, including the following: i) undersizing of the aortic valve bioprosthesis;^{5,7,8} ii) dissection
63 of the LCx from the aortic annulus;⁸⁻¹⁰ iii) tilting of the bioprosthesis;¹¹ sutureless bioprosthesis,
64 thanks to ligation risk absence and to inferior impact on the aortic annulus;¹² iv) supranular or
65 stentless bioprosthesis implantation⁵ and/or v) revascularization only in case of overt ischemia,
66 through coronary artery bypass grafting^{4,13} or drug eluting stent implantation.^{6,13}

67 Other anomalies can be treated with transection and re-implantation (e.g. RCA from LSV with
68 retro-aortic course)¹⁴ or with remodelling of the adjacent structure (e.g. pulmonary trunk and right
69 ventricle) to avoid compression (e.g. RCA from LSV with an inter-arterial course).¹⁵

70 Transcatheter aortic valve replacement (TAVR) has been established as an effective treatment
71 for patients with severe aortic stenosis¹⁶. Since the number of TAVR cases is meant to grow with
72 the expansion of the indication to younger and lower risk patients, the likelihood of performing
73 TAVR in the presence of a CAA should consistently increase.

74 The aim of the study is to evaluate the incidence and clinical implications of CAAs in patients
75 undergoing TAVR, and to propose possible management algorithms.

76 **Methods**

77 *Study design and data collection*

78 This observational retrospective single-center study analyzed all consecutive patients with
79 evidence of CAA who underwent TAVR procedure from July 2015 to March 2023 at our Center.

80 Inclusion criteria were: 1- detection of CAA at pre-TAVR computed tomography (CT) scan; 2-
81 patient with severe aortic stenosis of a native valve or degenerated bioprosthesis with an indication
82 for transcatheter treatment. Exclusion criteria was previous cardiac surgery for CAA re-
83 implantation.

84 Data regarding baseline clinical and echocardiographic characteristics, CT scan, procedural
85 features, as well as follow-up at 30 day and 1 year, were collected into our electronic prospective
86 institutional database.

87 Patients were deemed suitable for TAVR after Heart Team evaluation, and they all provided written
88 informed consent for the procedure.

89 The study complied with the Declaration of Helsinki. The local ethics committees approved the use
90 of retrospective anonymized data for this study.

91

92 *CT scan and transthoracic echocardiography*

93 CT-angiography scans were performed on 64- or 128-row electrocardiography gated multidetector
94 scanner (Somatom Definition; Siemens healthcare, Forchheim, Germany). The 3-Mensio valves
95 software (version 8.2, Pie Medical Imaging, Maastricht, The Netherlands) enabled multiplanar
96 reconstruction analysis of the aortic root and of the coronary arteries, evaluating both the diastolic
97 and systolic phases.¹⁷ The following features of coronary arteries were evaluated: i) take-off level,
98 below or above aortic valve commissure; ii) take-off angle, acute ($<45^\circ$) or non-acute ($\geq 45^\circ$); iii)
99 course, pre-pulmonic, inter-arterial, sub-pulmonic, retro-aortic or retro-cardiac; iv) ostia type,
100 separate, shared or branch vessel; v) proximal tract morphology, normal, oval or slit-like and vi)
101 evidence of intramural location, as suggested by Cheezum et al.¹⁸, allowing to plan a strategy to
102 avoid negative interaction with TAVR devices. Measurements were made by a dedicated laboratory

103 of radiology technicians.

104 Oversizing was determined as: calculated perimeter oversizing (%) = [(prosthesis perimeter/CT
105 valve perimeter -1) *100].

106 Transthoracic echocardiography (TTE) was performed pre- and post-procedural, the latter
107 repeated at discharge. Post-procedural paravalvular leak (PVL) was arranged evaluated by
108 experienced echocardiographers, according to Valve Academic Research Consortium-3 (VARC-3)
109 criteria.¹⁹

110

111 *TAVR procedure*

112 Transfemoral TAVR was performed under local anesthesia. Conscious sedation was added
113 according to patient's tolerance. The type of bioprosthesis was selected by the first operator based
114 on the CT scan images.

115

116 *Study end-points*

117 Technical success was defined in accordance with VARC-3 criteria as: i) freedom from
118 mortality; ii) successful access, delivery of the device, and retrieval of the delivery system; iii)
119 correct positioning of a single prosthetic heart valve into the proper anatomical location and iv)
120 freedom from surgery or intervention related to the device (permanent pacemaker implantation
121 excluded), or to a major vascular or access-related, or cardiac structural complication.

122 Device success at 30 days was referred to the attainment of technical success and the
123 fulfillment of the following situations: i) freedom from mortality; ii) freedom from surgery or
124 intervention related to device (permanent pacemaker implantation excluded), major vascular,
125 access-related or cardiac structural complication; and iii) intended performance of the valve, as
126 mean gradient <20 mmHg, peak velocity <3 m/s, Doppler velocity index ≥ 0.25 , and less than
127 moderate aortic regurgitation.¹⁹

128

129 *Statistical analysis*

130 Categorical and dichotomous variables are displayed as frequencies and percentages,
131 meanwhile, continuous variables are reported as mean and standard deviation, or median and
132 interquartile range, as appropriate.

133 Analyses were performed using SPSS statistical analysis software version 28.0 (IBM
134 Corporation, Armonk, NY, USA).

135 **Results**

136 *Baseline characteristics*

137 Among the last 2,164 patients treated by means of TAVR, only 15 (0.69%) were identified to
138 have a CAA on pre-operative CT scan.

139 The mean age was 83.7 ± 7.9 years, and the majority were female (80.0%). Mean STS score
140 was 4.0 ± 2.8 . One patient (ID 10) had prior SAVR with a Trifecta 23 bioprosthesis, meanwhile 2
141 patients (20%) suffered of coronary artery disease. Of those, one (ID 2) had previous coronary
142 artery bypass surgery with evidence of occlusion of the saphenous graft for the anomalous RCA,
143 whereas the other one (ID 7) suffered from a chronic total occlusion of the anomalous RCA due to
144 intrastent restenosis in the middle and proximal tract.

145 CT-angiography identified CAA features: most anomalies affected RCA (80%), with LM
146 (13.3%) and LCx (6.7%) to follow. Intramural course was observed only in 4 patients (26.7%),
147 meanwhile, acute take-off was detected in more than half (53.3%) of the study cohort. Ostia with
148 high-risk sudden cardiac death features (oval or slit like) were observed in 6 patients (40%), as
149 shown in *Table 1 and Suppl Table 1*.

150

151 *Procedural data and outcomes*

152 All the procedures were performed through trans-femoral approach and in 3 cases the
153 procedure was performed with an embolic cerebral protection system. Rate of predilatation was
154 66.7%, meanwhile postdilatation was performed only in 20% of patients. Three patients received a

155 balloon expandable valve (BEV). Only one (ID 2) patient required femoral artery stenting due to
156 main access vascular complication (*Table 2 and Suppl Table 2*).

157 Minimal oversizing was achieved, with an overall median oversizing of 11% [5%-17%].

158 One patient (ID 11) experienced cardiac arrest 15 minutes after the end the procedure, due to
159 anomalous RCA occlusion (height 14 mm). The phenotype was a CAA originating from a
160 commissure and necessitated bailout emergency coronary artery stenting with Impella (®Abiomed)
161 mechanical ventricular assist device. Of note, the CT scan finding was underestimated due to lack
162 of data: a high frame valve was implanted without coronary protection and with 5 mm implantation
163 depth, postdilatation was performed and no final selective CAA angiography was conducted.

164 *Table 3* shows which valve and size has been used for each CAA phenotype.

165 Technical success was (86.7%), due to a cardiac arrest and a main access vascular
166 complication, whereas device success at 30 days was lower (80%), due to the two cases of technical
167 unsuccess and one case of aortic valve mean gradient >20 mmHg. There was no evidence of ≥
168 moderate PVL and of cerebral strokes. One patient deceased 4 months after the procedure, due to
169 non-cardiac related causes (*Table 2*).

170

171 **Discussion**

172 CAAs are rare but increasingly recognized by cardiac imaging, and a wide spectrum of alteration
173 can be observed.²⁰ The phenotypes observed in elderly patients undergoing TAVR are usually
174 benign, even if CAAs show high-risk features.²¹

175 The main findings of this study can be summarized as follows:

- 176 1) the incidence of a CAA in patients undergoing TAVR is rare, below 1% of the cases;
- 177 2) myocardial infarction represents a major concern in patients with CAA undergoing TAVR as
178 having an incidence of 6.7%: a meticulous risk assessment using CT scan is imperative.

179 To the best of our knowledge, this is the largest cohort of patients with a CAA undergoing TAVR,
180 and a number of technical considerations can be done based on the cases performed; as such, we

181 hereby propose a classification, based on phenotypes of CAA, and two algorithms aimed at
182 preventing possible CAA related complications.

183 The first group is composed by patients deemed “at risk of ab extrinseco CAA compression”, due to
184 valve implantation (*Central Illustration A*). In this subset of patients, occlusion of coronary arteries
185 with a retroaortic course is the most common complication described in literature, due to the strict
186 anatomical relationship between the CAA and the aortic root, where the radial forces generated by
187 the bioprosthesis are exerted^{22–25} An interarterial course is more common and theoretically
188 associated with a lower risk of compression due to the shorter vessel segment at risk (to be
189 evaluated case by case)^{26–28}. The intramural course can be combined with the previous ones and it is
190 the least described in literature,²⁹ probably due to the low impact on coronary artery perfusion in
191 patients who did not show sudden cardiac death in a lifelong.

192 There are a few strategies described in literature to avoid CAA compression:

193 1) to assess the effective risk with an aortogram taken during balloon predilatation.^{24,26,27}

194 As a matter of fact, this procedure is not performed as a routine practice, but it is reserved only for
195 patients exhibiting high-risk features (e.g. retro-aortic course). Additionally, predilatation with
196 selective CAA angiography is feasible;²³ however it is technically more demanding and entails the
197 risk of proximal vessel injury.

198 2) the use of self-expandable valves (SEV) which have the capability to be recaptured, thus
199 allowing for valve removal in cases of relevant overt compression.^{24,29,30} In our study, recapturable
200 devices were used in 9 out of 15 patients: low radial force SEV,³¹ such as the Portico³² and Acurate
201 Neo, have the advantage of exerting lesser impact on the aortic root with minimal deformation.

202 In our series, low radial force SEV were utilized in 6/15 patients.

203 3) the use of BEV that, unlike SEV, do not keep generating forces on the aortic root after
204 deployment.²⁷ BEV was used in 3 out of 15 patients.

205 4) Bioprosthesis undersizing allows lower stress and aortic anulus deformation. Oversizing in high-
206 risk features is always not recommended,²²

207 5) coronary protection with the chimney technique, especially when there is evidence of CAA
208 obstruction during balloon valvuloplasty, in order to quickly deal with the abrupt coronary
209 occlusion.³³ In our series it was performed in 2/15 patients.

210

211 The second group is composed by patients deemed “at risk of CAA ostium occlusion” (*Central*
212 *Illustration B*). Historically, CAA originating from the commissure between two cusps have not
213 been considered at risk for coronary occlusion: this is true when the aortic root is large enough to
214 accommodate the bioprosthesis and still there is enough space between the latter and the coronary
215 ostium. This measure is typically evaluated while planning a VIV procedure, i.e. the “VTC: valve-
216 to-coronary”. Of note, there is no standard reference to consider in case of a CAA^{33,34}

217 In our sample, 1 patient over 4 experienced an acute CAA occlusion.

218 Consequently, we propose the following strategies:

219 1) mild “intentional” misalignment, to avoid placing a strut in front of the CAA ostia.³³ In our series
220 the only valve that could be deliberately misaligned were the Acurate Neo and Evolut. However,
221 being a retrospective study, it was not systematically used.

222 2) Low frame valve deployment (BE might be appropriate), to lessen the interaction of the upper
223 crown with leaflets and CAA ostium (1/4 patients).

224 3) A slightly deeper implantation, to reduce leaflets eversion although it may increase the risk of
225 conduction disturbances.³⁵

226 4) Coronary protection thorough the chimney technique, as described previously. We suggest
227 performing this technique in anatomies with highest risk of occlusion.

228 Additional general strategies for these two groups are: i) avoidance of postdilatation, if feasible
229 (20% patients in our sample), in order to avoid further stress on the aortic root and eventual
230 compression and ii) final selective CAA angiography^{31,34} to verify patency of the CAA (3/15 in our
231 sample).

232

233 The final group consists of patients at “high risk of impaired CAA re-access”. This group
234 encompasses (a) CAA located above the sino-tubular junction (STJ), as well as (b) CAA originating
235 from the commissure and (c) from the opposite sinus of Valsalva (*Central Illustration C*) where the
236 distance is enough to make an abrupt occlusion of the coronary artery unlikely but still the
237 cannulation might be cumbersome. For the latter two types, the suggested strategies for preventing
238 CAA ostium occlusion remain the same. However, there are two main strategies that we suggest to
239 preserve coronary re-access in a CAA above the STJ:

- 240 1) use of a valve with a lower height than the origin of the CAA (ID 9: in this case it was not
241 applied due to the patient’s age of 90 years old and no coronary artery disease), and
- 242 2) use of an open frame valve, as the Acurate Neo (ID 6). Both strategies are intended to avoid the
243 interference of the upper crown with catheters.

244

245 To systematically evaluate and manage the possible consequences of the presence of a CAA during
246 TAVR, we hereby present two algorithms.

247 The first algorithm is based on the mechanism of CAA flow impairment, and it is described in
248 *Figure 1*. Firstly, if the patient belongs to group 1 (risk of ab extrinseco compression), balloon
249 predilatation with concomitant angiography should be performed. The subsequent strategy depends
250 on the presence of compression. If the patient is in group 2 (risk of coronary ostium occlusion), the
251 strategies will be different according to the type of CAA (commissural origin vs. low origin from
252 opposite sinus of Valsalva). General strategies for both groups are avoidance of postdilatation and
253 final selective CAA angiography.

254 The second algorithm is based on the risk of impaired coronary re-access (group 3), as shown
255 in *Figure 2*. Strategies are different based on the phenotype: origin above the STJ, commissural
256 origin and low origin from opposite sinus of Valsalva.

257

258 **Study limitations**

259 Data analysis has been conducted retrospectively and the small number of patients did not
260 allow more extensive data investigation.

261 Due to CAA rarity and their heterogeneity, the results of the analysis still must be considered
262 exploratory; further studies applying the proposed algorithms are needed for a thorough validation.

263

264

265 **Conclusions**

266 The presence of a CAA may significantly increase the risk of threatening complications during
267 TAVR. The possible interaction between the transcatheter bioprosthesis and the different CAA types
268 should be comprehensively evaluated upfront and the procedure planned accordingly.

269

270 **Acknowledgements**

271 None

272 **Sources of funding**

273 This work was supported by IRCCS Policlinico San Donato, a clinical research hospital partially
274 funded by the Italian Ministry of Health.

275 **Disclosures**

276 Francesco Bedogni is consultant for Medtronic, Abbott, and Boston Scientific; Luca Testa is
277 consultant for Abbott, Meril, Medtronic and Boston Scientific. The other authors declare no conflict
278 of interest.

279 **References**

- 280 1. Gentile F, Castiglione V, De Caterina R. Coronary Artery Anomalies. *Circulation*. 2021;144(12):983–996.
- 281 2. Yildiz A, Okcun B, Peker T, Arslan C, Olcay A, Bulent Vatan M. Prevalence of coronary artery anomalies
282 in 12,457 adult patients who underwent coronary angiography. *Clinical cardiology*. 2010;33(12).
- 283 3. Baumgartner H, de Backer J, Babu-Narayan S V., Budts W, Chessa M, Diller GP, Iung B, Kluin J, Lang
284 IM, Meijboom F, Moons P, Mulder BJM, Oechslin E, Roos-Hesselink JW, Schwerzmann M, et al. 2020 ESC
285 Guidelines for the management of adult congenital heart disease. *European heart journal*. 2021;42(6):563–645.
- 286 4. Vaishnava P, Pyo R, Filsoufi F, Sharma S. Compression of an anomalous left circumflex artery after aortic
287 and mitral valve replacement. *The Annals of thoracic surgery*. 2011;92(5):1887–1889.
- 288 5. Pellicano M, Toth G, Di Gioia G, Rusinaru D, Wijns W, Barbato E, De Bruyne B, Degrieck I, Van
289 Mieghem C. Unrecognized anomalous left circumflex coronary artery arising from right sinus of Valsalva: a
290 source of perioperative complication. *Journal of cardiovascular medicine (Hagerstown, Md.)*. 2016;17 Suppl
291 2:e228–e230.
- 292 6. López Castillo M, Martín Reyes R, Palfy J, Franco JA, Piñero A, Navarro F, Tomás M, Aldámiz G, Farré
293 J. Successful Treatment of Compression of an Anomalous Circumflex Artery After Aortic Valve Replacement
294 With Percutaneous Coronary Intervention. *JACC. Cardiovascular interventions*. 2016;9(15):1629–1630.
- 295 7. Yokoyama S, Takagi K, Mori R, Aoyagi S. Aortic valve replacement in patients with an anomalous left
296 circumflex artery: technical considerations. *Journal of cardiac surgery*. 2012;27(2):174–177.
- 297 8. Castillo JG, Sanz J, Fischer GW, Bowman K, Filsoufi F. Management of anomalous left circumflex artery
298 encircling the aortic annulus in a patient undergoing multivalvular surgery. *Journal of cardiac surgery*.
299 2009;24(6):667–669.
- 300 9. Flores RM, Byrne JG. Aortic valve replacement with an anomalous left circumflex coronary artery
301 encircling the aortic anulus. *The Journal of thoracic and cardiovascular surgery*. 2001;121(2):396–397.
- 302 10. Liebrich M, Tzanavaros I, Scheid M, Voth W, Doll KN, Hemmer WB. Aortic valve/root
303 procedures in patients with an anomalous left circumflex coronary artery and a bicuspid aortic valve: anatomical
304 and technical implications. *Interactive cardiovascular and thoracic surgery*. 2015;21(1):114–116.
- 305 11. Umakanthan R, Brewer ZE, Byrne JG, Ahmad RM. Use of the hybrid operating room for aortic
306 valve replacement in a patient with anomalous left circumflex artery. *The Journal of thoracic and cardiovascular
307 surgery*. 2010;139(6).

- 308 12. Harky A, Hof A, Ahmad MU, Uppal R. Incidental finding of anomalous circumflex coronary
309 artery from right coronary sinus prior to aortic valve surgery. *BMJ case reports*. 2017;2017.
- 310 13. Alameddine AK, Binnall BJ, Conlin FT, Broderick PJ. Aortic Valve Replacement in 8 Adults
311 with Anomalous Aortic Origin of Coronary Artery. *Texas Heart Institute journal*. 2019;46(3):189–194.
- 312 14. Inan K, Ucak A, Onan B, Tamtekin B, Temizkan V, Yilmaz AT. Posterior root enlargement for
313 aortic valve replacement associated with unexpected anomalous right coronary artery. *Journal of cardiac surgery*.
314 2010;25(1):92–95.
- 315 15. Roughneen PT, Al-Dossari GA. The Anomalous Coronary Artery in Aortic Valve Replacement: A
316 Case For Caution. *The Annals of thoracic surgery*. 2016;102(2):e113–e115.
- 317 16. Vahanian A, Beyersdorf F, Praz F, Milojevic M, Baldus S, Bauersachs J, Capodanno D, Conradi
318 L, De Bonis M, De Paulis R, Delgado V, Freemantle N, Gilard M, Haugaa KH, Jeppsson A, et al. 2021
319 ESC/EACTS Guidelines for the management of valvular heart disease. *European heart journal*. 2022;43(7):561–
320 632.
- 321 17. Jilaihawi H, Kashif M, Fontana G, Furugen A, Shiota T, Friede G, Makhija R, Doctor N, Leon
322 MB, Makkar RR. Cross-sectional computed tomographic assessment improves accuracy of aortic annular sizing
323 for transcatheter aortic valve replacement and reduces the incidence of paravalvular aortic regurgitation. *Journal*
324 *of the American College of Cardiology*. 2012;59(14):1275–1286.
- 325 18. Cheezum MK, Liberthson RR, Shah NR, Villines TC, O’Gara PT, Landzberg MJ, Blankstein R.
326 Anomalous Aortic Origin of a Coronary Artery From the Inappropriate Sinus of Valsalva. *Journal of the American*
327 *College of Cardiology*. 2017;69(12):1592–1608.
- 328 19. Généreux P, Piazza N, Alu MC, Nazif T, Hahn RT, Pibarot P, Bax JJ, Leipsic JA, Blanke P,
329 Blackstone EH, Finn MT, Kapadia S, Linke A, Mack MJ, Makkar R, et al. Valve Academic Research Consortium
330 3: Updated Endpoint Definitions for Aortic Valve Clinical Research. *Journal of the American College of*
331 *Cardiology*. 2021;77(21):2717–2746.
- 332 20. Villa AD, Sammut E, Nair A, Rajani R, Bonamini R, Chiribiri A. Coronary artery anomalies
333 overview: The normal and the abnormal. *World journal of radiology*. 2016;8(6):537.
- 334 21. Gräni C, Benz DC, Steffen DA, Clerc OF, Schmied C, Possner M, Vontobel J, Mikulicic F,
335 Gebhard C, Pazhenkottil AP, Gaemperli O, Hurwitz S, Kaufmann PA, Buechel RR. Outcome in middle-aged
336 individuals with anomalous origin of the coronary artery from the opposite sinus: a matched cohort study.
337 *European heart journal*. 2017;38(25):2009–2016.

- 338 22. Acosta-Vélez JG, Del Blanco BG, Guindo J, Serrano JM, Calabria HC, Aguasca GM, Gonzalez-
339 Alujas T, Durán I, Tornos P. Acute artery occlusion during transcatheter aortic valve replacement in a patient with
340 an anomalous origin of the circumflex artery. *JACC. Cardiovascular interventions*. 2014;7(11):1324–1325.
- 341 23. Tabachnick D, Obokhae B, Harrington K, Brown DL. Assessing the risk of an anomalous
342 circumflex artery using balloon aortic valvuloplasty prior to transcatheter aortic valve replacement.
343 *Catheterization and cardiovascular interventions : official journal of the Society for Cardiac Angiography &*
344 *Interventions*. 2020;96(2):497–499.
- 345 24. Mennuni MG, Pagnotta P, Presbitero P. Percutaneous aortic valve implantation in severe stenosis
346 associated with anomalous origin of the circumflex coronary artery. *European heart journal*. 2011;32(13):1687.
- 347 25. Mizote I, Conradi L, Schäfer U. A case of anomalous left coronary artery obstruction caused by
348 lotus valve implantation. *Catheterization and cardiovascular interventions : official journal of the Society for*
349 *Cardiac Angiography & Interventions*. 2017;90(7):1227–1231.
- 350 26. Giri J, Szeto WY, Bavaria J, Herrmann HC. Transcatheter aortic valve replacement with coronary
351 artery protection performed in a patient with an anomalous left main coronary artery. *Journal of the American*
352 *College of Cardiology*. 2012;60(6).
- 353 27. Weich H, Ackermann C, Viljoen H, Van Wyk J, Mabin T, Doubell AF. Transcatheter aortic valve
354 replacement in a patient with an anomalous origin of the right coronary artery. *Catheterization and cardiovascular*
355 *interventions : official journal of the Society for Cardiac Angiography & Interventions*. 2011;78(7):1013–1016.
- 356 28. Birkl K, Plank F, Bonaros N, Feuchtner G, Friedrich G. Transcatheter Aortic Valve Repair in a
357 Patient With Anomalous Right Coronary Artery Originating From the Left Aortic Sinus and Myelodysplastic
358 Syndrome. *Cureus*. 2020;12(7).
- 359 29. Marcus GU, Orbach A, Fremes S, Vijayaraghavan R, Kerner A, Oikonomou A, Roifman I,
360 Wijeysondera HC. TAVR in a Patient With Anomalous Origin and Course of the Left Main Coronary Artery.
361 *JACC. Case reports*. 2022;4(22):1467–1471.
- 362 30. Cho SW, Kim BG, Park TK, Choi SH, Gwon HC, Park SJ, Nah JC. Transcatheter aortic valve
363 replacement in a patient with anomalous origin of the left coronary artery. *Journal of cardiology cases*.
364 2019;19(4):133–135.
- 365 31. Tzanis G, Ancona M, Romano V, Bellini B, Sgura F, Montorfano M. TAVR in a patient with an
366 anomalous left main: Self-expanding prosthesis might be the preferred choice. *Hellenic journal of cardiology :*
367 *HJC = Hellenike kardiologike epitheorese*. 2020;61(5):344–345.

- 368 32. Gorla R, Oliva OA, Poletti E, Finotello A, Morganti S, Zannoni J, Agnifili M, Barletta M,
369 Squillace M, Criscione E, Tusa M, Brambilla N, Auricchio F, Testa L, Bedogni F. Impact of Nodular
370 Calcifications in the Aortic Annulus and Left Ventricular Outflow Tract on TAVI Outcome with New-Generation
371 Devices. *Reviews in Cardiovascular Medicine*. 2022;23(11).
- 372 33. Costa G, Sgroi C, Strazzieri O, Reddavid C, Valvo R, Motta S, Frittitta V, Dipietro E, Tamburino
373 C, Barbanti M. Intentional Misalignment of a Transcatheter Aortic Valve to Preserve Reaccess to Coronaries of
374 Anomalous Origin. *JACC. Case reports*. 2022;4(2):83–86.
- 375 34. Geyer M, Tamm AR, Da Rocha E Silva JG, Gori T, Münzel T, Von Bardeleben RS. Beware of the
376 commissure - transcatheter aortic valve replacement in a rare anomaly of the left main coronary. *Journal of*
377 *cardiovascular medicine (Hagerstown, Md.)*. 2022;23(7):477–478.
- 378 35. Casenghi M, Oliva OA, Squillace M, Bellamoli M, Poletti E, Popolo Rubbio A, Testa L, Bedogni
379 F, De Marco F. Bailout From Sinus Jailing: In-Series TAVR-in-TAVR to Avoid Coronary Flow Obstruction.
380 *JACC. Case reports*. 2021;3(4):678–681.
- 381
- 382

383 **Table 1. Baseline characteristics of patients with CAA who underwent TAVR.**

Variables		Overall (N=15)
Clinical characteristics	Age (years)	83.7 ± 7.9
	Female sex	12 (80.0%)
	Hypertension	10 (66.7%)
	Diabetes	2 (13.3%)
	Dyslipidemia	8 (53.3%)
	COPD	3 (6.7%)
	Coronary artery disease	2 (13.3%)
	Prior cardiac surgery	2 (13.3%)
	Prior CABG	1 (6.7%)
	Prior PCI	1 (6.7%)
	Prior AMI	2 (13.3%)
	STS score (%)	4.0 ± 2.8
Laboratory and TTE	Creatinine clearance (mL/min/1.73 m ²)	61.9 ± 20.6
	Haemoglobin (g/dL)	12.7 ± 1.8
	Ejection fraction (%)	55.3 ± 9.6
	Mean aortic gradient (mmHg)	45.2 ± 15.0
	AR ≥moderate	4 (26.7%)
Aortic valve CT scan evaluation	Annulus min diameter (mm)	20.5 ± 2.5
	Annulus max diameter (mm)	25.1 ± 2.8
	Annulus mean diameter (mm)	22.8 ± 2.6
	Annulus perimeter (mm)	72.0 ± 8.0
	Annulus area (mm ²)	406.7 ± 87.6
	Sinus of Valsalva diameter (mm)	31.4 ± 2.5
	Calcium volume 800 HU (mm ³)	256.8 [100.0–382.9]
	Aortic angulation (°)	46.3 ± 9.6
	Index of eccentricity	0.18 ± 0.06
	LVOT diameter (mm)	22.5 ± 3.3
Ascending aorta (mm)	28.3 ± 3.6	
CAA CT scan evaluation	LM height (mm)	13.4 ± 2.9
	RCA height (mm)	18.5 ± 3.2
	Anomalous RCA	12 (80.0%)
	Anomalous LCx	1 (6.7%)
	Anomalous LM	2 (13.3%)
	Intramural course	4 (26.7%)
	Oval ostium	4 (26.7%)
	Slit-like ostium	2 (13.3%)
Acute take-off	8 (53.3%)	

Values expressed as mean±SD, median (25th–75th percentile) or N (%). AMI, acute myocardial infarction; AR, aortic regurgitation; CAA, coronary artery anomalies; CABG, coronary artery bypass grafting; COPD, chronic obstructive pulmonary disease; CT, computed tomography; HU, Hounsfield Units; LM, left main; LVOT, left ventricular outflow tract; PCI, percutaneous coronary intervention; RCA, right coronary artery; STS, Society of

Thoracic Surgeons; TTE transthoracic echocardiography.

384

385

386 **Table 2. Procedural and follow up data of patients with CAA who underwent TAVR.**

Variables		Overall (N=15)
Procedure	Femoral route	15 (100.0%)
	Subclavian route	0 (0.0%)
	Embolic protection system	3 (20.0%)
	Any vascular complications	1 (6.7%)
	PTA with stenting of access site	1 (6.7%)
	PCI with stenting	1 (6.7%)
	Predilatation	10 (66.7%)
	Postdilatation	3 (20.0%)
	Emergent cardiac surgery	0 (0.0%)
	Need for second valve	0 (0.0%)
	Contrast volume (mL)	173.8 ± 57.8
	Fluoroscopy time (min)	21.2 ± 9.8
	Outcomes	Ejection fraction (%)
Mean gradient (mmHg)		8.2 ± 4.4
PVL absent/trivial		5 (33.3%)
PVL mild		10 (66.7%)
PVL >moderate		0 (0.0%)
Technical success		13 (86.7%)
Device success (at 30 days)		12 (80.0%)
PPI		1 (6.7%)
Stroke (including not disabling)		0 (0.0%)
30-day mortality		0 (0.0%)
1-year mortality		1 (11.1%)
<p>Values expressed as mean±SD, median (25th-75th percentile) or N (%). LCC, left coronary cusp; NCC, non-coronary cusp; PCI, percutaneous coronary intervention; PPI, permanent pacemaker implantation; PTA, percutaneous transluminal angioplasty; PVL, paravalvular leak.</p>		

387

388

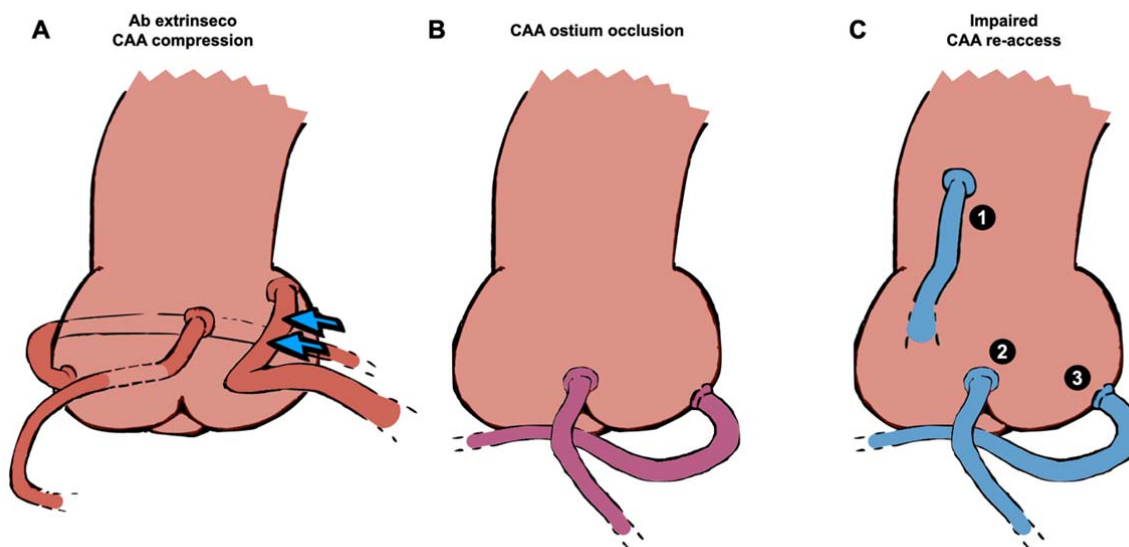
389 **Table 3. Data of CAA features and TAVR prosthesis choice.**

Patient ID	Anomalous CA	Anomalous origin	Course	Intramural tract	TAVR prosthesis	Size
1	LCx	RSV	Retro-aortic	No	Portico	25
2	RCA	LSV	Inter-arterial	Yes	Myval	26
3	RCA	LSV	Inter-arterial	No	Acurate Neo	M
4	RCA	LSV	Inter-arterial	No	Evolut-R	26
5	RCA	LSV	Inter-arterial	No	Acurate Neo	S
6	RCA	Above STJ	Inter-arterial	No	Acurate Neo	S
7	RCA	RCC-LCC commissure	Inter-arterial	No	Evolut-R	26
8	LM	NCC-LCC commissure	Retro-aortic	No	Myval	27,5
9	RCA	Above STJ	Inter-arterial	No	Evolut-R	26
10	RCA	LSV	Inter-arterial	Yes	Myval	23
11	RCA	RCC-NCC commissure	Inter-arterial	No	Evolut-PRO	29
12	RCA	LSV	Inter-arterial	Yes	Navitor	29
13	RCA	LSV	Inter-arterial	Yes	Evolut-R	34
14	LM	RSV	Retro-aortic	No	Portico	23
15	RCA	RCC-LCC commissure	Inter-arterial	No	Portico	25

CAA, coronary artery anomalies; LCC, left coronary cusp; LCx, left circumflex artery; LM, left main LSV, left sinus of Valsalva; NCC, non-coronary cusp; RCA, right coronary artery; RCC, right coronary cusp; RSV, right sinus of Valsalva; STJ, sino-tubular junction

390

391 **Figure Titles and Legends**



392

393 **Central Illustration. Most common phenotypes of CAA in patients undergoing TAVR,**

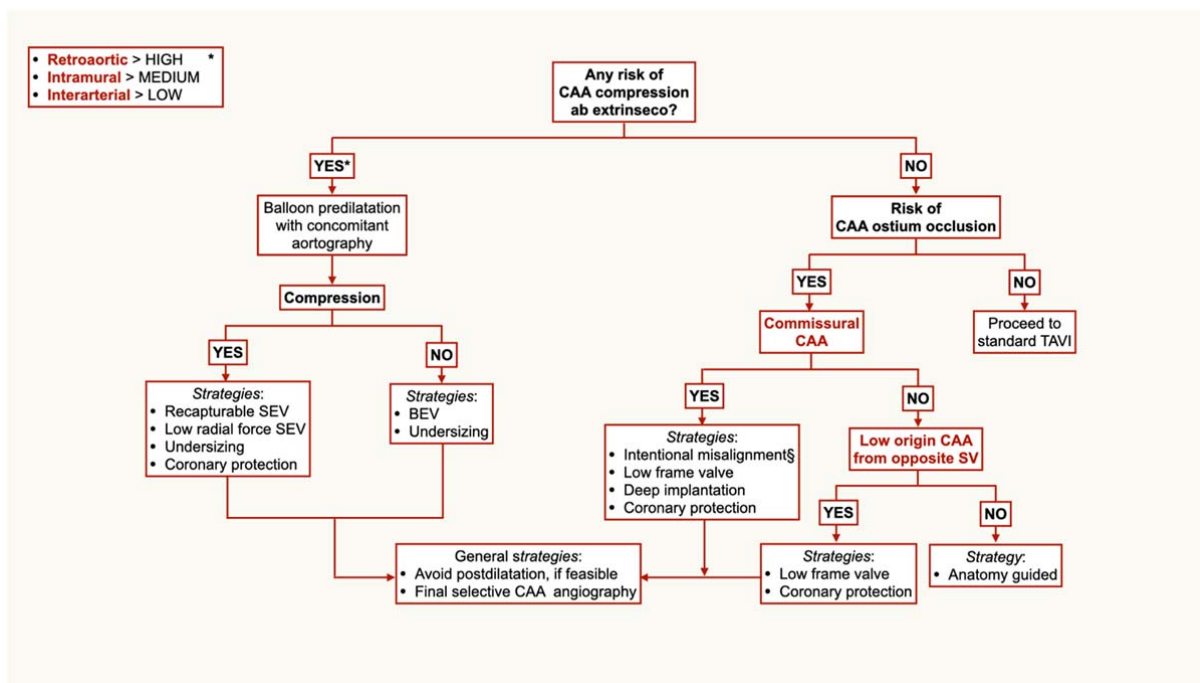
394 **classified by mechanism of impairment. (A) Compression ab extrinseco (red). From left to right:**

395 retroaortic course, intramural course and interarterial course (blue arrows to represent pulmonary

396 artery compression). (B) Ostium occlusion (purple). From left to right: commissural origin and low

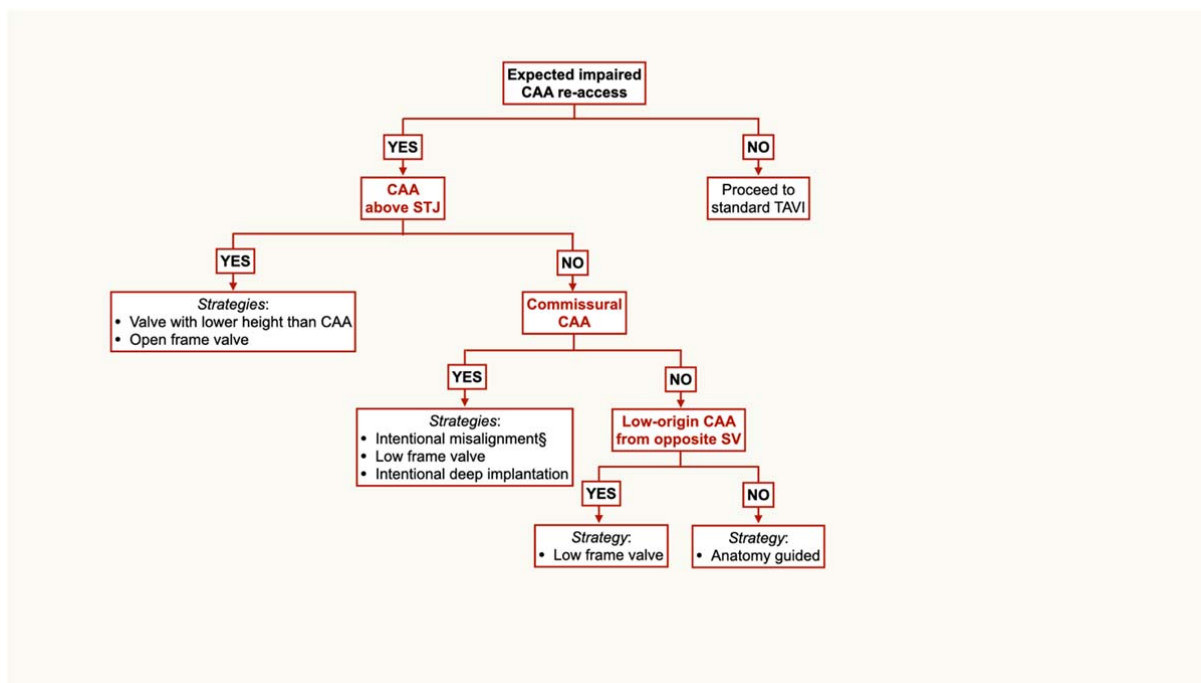
397 origin from opposite SV. (C) Challenging re-access (blue). 1) above STJ origin; 2) commissural

398 origin and 3) low origin from opposite SV.



399

400 **Figure 1. Algorithm for valve choice in patient with CAA undergoing TAVR, at risk of**
 401 **coronary occlusion.** *Retroaortic, intramural and interarterial CAA have different risk of coronary
 402 compression and subsequent occlusion, but the anatomy must be assessed case-by-case. However,
 403 the algorithm is not affected, due to data paucity and unpredictable behavior in real world. §Placing
 404 of a neocommissure in front of the CAA ostium, through a custom projection, detected by CT scan.
 405 BEV, balloon-expandable valve; CAA, coronary artery anomaly; SEV, self-expandable valve; SV,
 406 sinus of Valsalva.



407

408 **Figure 2. Algorithm for valve choice in patient with CAA who undergo TAVR, at risk of**

409 **impaired coronary re-access.** §Placing of a neocommissure in front of the CAA ostium, through a

410 custom projection, detected by CT scan.

411 CAA, coronary artery anomaly; STJ, sino-tubular junction; SV, sinus of Valsalva.