

Diagnostic accuracy of MRI compared to CTPA for pulmonary Embolism : A meta analysis

Authors:

- 1) Dr. Dev H. Desai
Smt. NHLMMC, Ahmedabad, India
Email: devhdesai01@gmail.com

- 2) Dr. Abhijay Shah
Smt. NHLMMC, Ahmedabad, India
Email: abhijayshah0610@gmail.com

- 3) Dr. Hetvi Shah
Smt. NHLMMC, Ahmedabad, India
Email: shahhetvi1026@gmail.com

- 4) Dr. Aarya A.Naik
Smt. NHLMMC, Ahmedabad, India
Email: aaryanaik1999@gmail.com

- 5) Dr. Sharif Mohammed Sadat
Bangladesh Medical college,Dhaka,Bangladesh
Email: sadat.bm33@gmail.com

- 6) Dr. Dwija Raval (Corresponding Author)
Dr. M. K. Shah Medical College and Research Centre, Ahmedabad, India
Email: dwijaraval2005@gmail.com
Mobile No: +91 6354224881

ABSTRACT :

Background: This meta-analysis presents a comparison between Computed Tomography Pulmonary Angiography (CTPA) and Magnetic Resonance Angiography (MRA), to diagnose a pulmonary embolism. Computed tomography presents the advantage of imaging the entire thorax, facilitating the diagnosis of conditions that are commonly mistaken for pulmonary embolism, such as pneumonia, aortic dissection, and malignancy. UK and US guidelines have established CT amongst the basic investigations for pulmonary embolism. MRA does not require the use of ionizing radiation or iodinated contrast, thus making it possible for routine use of multiphasic acquisitions as well as for repeated contrast injections

Methodology: For the collection of the data, a search was done by two individuals using PubMed, Google Scholar, and Cochrane Library databases for all relevant literature. Full - Text Articles written only in English were considered. Each qualifying paper was independently evaluated by two reviewers. Each article was analyzed for the number of patients, their age, procedure modality, and incidence of the pre decided complications.

Results: The results also showed a high positive predictive value of 0.947 or 94.7% for MRA in the diagnosis of Pulmonary embolism, as compared with CTPA. Some analyses have marked MRA to have low specificity. These results establish MRA as a respectable alternative for diagnosis of APE, especially in cases when reducing radiation exposure is desired. However, the gold standard of diagnosis remains Computed Tomography Pulmonary Angiography.

Conclusion: As the results show, though MRA has high statistical value for the diagnosis of pulmonary embolism, it also has its drawbacks. MRA cannot be used in severely ill patients as it continues to be challenging, with the longer scan times and multiple breath holds that are required in different MR protocols are difficult to follow in these patients. CTPA remains the gold standard for diagnosis of Pulmonary embolism, with MRA as a secondary test used when CTPA is contraindicated.

Key words: Computed Tomography Pulmonary Angiography; Magnetic Resonance Angiography; Pulmonary Embolism; Diagnosis

INTRODUCTION:

Pulmonary embolism covers a wide spectrum of presentations, ranging from asymptomatic individuals to life-threatening medical emergencies.

The importance of identifying pulmonary artery embolism (PE) is well established .

Unfortunately, symptoms are often not specific, making a diagnosis of PE very challenging, based only on clinical presentation. The common symptoms such as acute chest pain and dyspnea are not specific to PE. As a result, imaging is frequently requested to exclude pulmonary embolus. [1]

Pulmonary embolus (PE) is estimated to cause from 200,000 to 300 000 deaths a year. The patients at risk are generally hemodynamically unstable. The choice of treatment in PE depends on the risk of poor result. Hypotension is the most significant predictor of poor outcome and defines those with massive PE.[2][3]

Overall, the diagnosis of Pulmonary embolism involves a combination of diagnostic tests, including CTPA, MRA, ultrasound, blood tests, and chest X-ray. The choice of test may depend on factors such as the patient's medical history, the availability of imaging equipment, and the expertise of the medical team

Computed tomography presents the advantage of imaging the entire thorax, facilitating the diagnosis of conditions that are commonly mistaken for pulmonary embolism, such as pneumonia, aortic dissection, and malignancy. UK and US guidelines have established CT amongst the basic investigations for pulmonary embolism.[2]

In critically ill patients, computed tomographic pulmonary angiography appears to be the investigation of choice for many physicians. In patients of renal insufficiency or contrast allergy, ventilation-perfusion scans are an alternative choice that may be used.

In patients who are unstable, and cannot be shifted for radiological tests, echocardiography, especially transesophageal echocardiography is an option.

[4] A positive Doppler ultrasound of the lower extremity indicating a deep vein thrombosis in the setting of chest pain and dyspnea may also help in the decision for treatment of a pulmonary embolism

Another alternative to computed tomography angiography is contrast enhanced magnetic resonance angiography (CT-MRA). With the recent enhancements in scanner technology, recent studies have shown great capacity in detecting pulmonary embolisms. [5]

MRA does not require the use of ionizing radiation or iodinated contrast, thus making it possible for routine use of multiphasic acquisitions as well as for repeated contrast injections.[6]

Magnetic resonance pulmonary angiography(MRA) and magnetic resonance venography (MRV) when performed together, have a higher sensitivity than magnetic resonance pulmonary angiography alone in patients with technically adequate images. However, it is harder to obtain technically adequate images with the combination of procedures.

METHODOLOGY:

DATA COLLECTION

For the collection of the data, a search was done by two individuals using PubMed, Google Scholar, and Cochrane Library databases for all relevant literature. Full - Text Articles written only in English were considered.

The medical subject headings (MeSH) and keywords ‘CT Pulmonary Angiogram’, ‘MR Pulmonary Angiography’, and ‘Pulmonary Embolism’ were used. References, reviews, and meta-analyses were scanned for additional articles.

INCLUSION AND EXCLUSION CRITERIA

Titles and abstracts were screened, and Duplicates and citations were removed. References of relevant papers were reviewed for possible additional articles. Papers with detailed patient information and statically supported results were selected.

We searched for papers that show more accurate diagnoses, where procedures considered were CTPA and MRPA.

The inclusion criteria were as follows: (1) studies that provided information about the accurate diagnosis with CTPA and MRPA; (2) studies published in English; (3) Studies comparing MRPA with CTPA as a Diagnosis modality for cases of pulmonary embolism.

The exclusion criteria were: (1) articles that were not full text, (2) unpublished articles, and (3) articles in other languages.

DATA EXTRACTION

Each qualifying paper was independently evaluated by two reviewers. Each article was analyzed for the number of patients, their age, procedure modality, and incidence of the pre decided complications. Further discussion or consultation with the author and a third party was used to resolve conflicts. The study's quality was assessed using the modified Jadad score. In the end, According to PRISMA, a total of 39 RCTs with a total of 6273 patients were selected for further analysis.

ASSESSMENT OF STUDY QUALITY

Using the QualSyst tool, two writers independently assessed the caliber of each included study. This test consists of 10 questions, each with a score between 0 and 2, with 20 being the maximum possible overall score. Two authors rated each article independently based on the above criteria. The interobserver agreement for study selection was determined using the weighted Cohen's kappa (K) coefficient. For deciding the bias risk for RCTs, we also employed

the Cochrane tool. No assumptions were made about any missing or unclear information. there was no funding involved in collecting or reviewing data.

STATISTICAL ANALYSIS

The statistical software packages RevMan (Review Manager, version 5.3), SPSS (Statistical Package for the Social Sciences, version 20), Google Sheets, and Excel in Stata 14 were used to perform the statistical analyses. The data was obtained and entered into analytic software[7] [21]. Heterogeneity and the diagnostic accuracy were performed. the latter of which was calculated by pooled estimates of sensitivity, specificity, positive predictive value (PPV), diagnostic odds ratios (DOR), and relative risk (RR) with 95 percent confidence intervals to examine critical clinical outcomes (CIs). Diagnosis accuracy and younden index were calculated for each result. Individual study sensitivity and specificity were plotted on Forest plots and in the receiver operating characteristic (ROC) curve. The forest plot and Fagan's Nomogram were used to illustrate the sensitivity and specificity of different papers.

Heterogeneity was detected by Cochrane Q test and I² (inconsistency) statistics, with $P < 0.10$ or $I^2 > 50\%$, indicating a significance in heterogeneity.[10] Furthermore, if there was significant heterogeneity ($I^2 > 50\%$ or $P \leq 0.05$), the random-effects model (DerSimonian-Laird method) was preferred over the fixed-effects model (Mantel-Haenszel method); otherwise, the fixed-effects model was the first choice.

BIAS STUDY

The risk of bias was evaluated by using QUADAS-2 analysis. This tool includes 4 domains as Patient selection, Index test, Reference standard, Flow of the patients, and Timing of the Index tests.

RESULT:

Author name	year of publishing	Methodology	Gold Standard	True Positive (TP)	False Negative (FN)	True Negative (TN)	False Positive (FP)	Sensitivity	Specificity
Anderson[8]	2007	Magnetic resonance vs Computer tomography pulmonary angiogram	CTPA	115	9	522	0	0.924	0.999
Bajo [9]	2002	Magnetic resonance vs Computer tomography pulmonary angiogram	CTPA	26	4	85	1	0.867	0.988
Blum[10]	2005	Magnetic resonance vs Computer tomography pulmonary angiogram	CTPA	45	18	24	2	0.71	0.92
Ellas[11]	2004	Magnetic resonance vs Computer tomography pulmonary angiogram	CTPA	61	12	125	1	0.836	0.992
Eng [12]	2009	Magnetic resonance vs Computer tomography pulmonary angiogram	CTPA	49	0	178	0	0.99	0.997
Ersoy [13]	2007	Magnetic resonance vs Computer tomography pulmonary angiogram	CTPA	2	7	13	2	0.22	0.87
Grist [14]	1993	Magnetic resonance vs Computer tomography pulmonary angiogram	CTPA	6	0	5	3	1	0.63
Gupta [15]	1999	Magnetic resonance vs Computer tomography pulmonary angiogram	CTPA	11	2	22	1	0.85	0.96
Hantous Zannad [16]	2010	Magnetic resonance vs Computer tomography pulmonary angiogram	CTPA	69	8	107	0	0.891	0.995
Jimenez [17]	2006	Magnetic resonance vs Computer tomography pulmonary angiogram	CTPA	60	35	64	0	0.63	0.992
Kluge[18]	2006	Magnetic resonance vs Computer tomography pulmonary angiogram	CTPA	19	0	40	3	1	0.93
Van beek EJ [19]	1997	Magnetic resonance vs Computer tomography pulmonary angiogram	CTPA	28	3	1	1	0.9	0.5
MD Silverstein [20]	1998	Magnetic resonance vs Computer tomography pulmonary angiogram	CTPA	18	3	31	15	0.86	0.67
Andrew J Einstein [21]	2007	Magnetic resonance vs Computer tomography pulmonary angiogram	CTPA	29	7	18	1	0.81	-
Loubeyre [22]	1994	Magnetic resonance vs Computer tomography pulmonary angiogram	CTPA	10	2	11	0	0.83	1
Macdenaid [23]	2005	Magnetic resonance vs Computer tomography pulmonary angiogram	CTPA	22	5	77	9	0.815	0.895
Ferretti [24]	1997	Magnetic resonance vs Computer tomography pulmonary angiogram	CTPA	144	50	150	8	0.71	-
Piipe [25]	2012	Magnetic resonance vs Computer tomography pulmonary angiogram	CTPA	27	1	3	2	0.96	-
Pearce [26]	2012	Magnetic resonance vs Computer tomography pulmonary angiogram	CTPA	41	1	8	4	0.98	-
Mathis [27]	1999	Magnetic resonance vs Computer tomography pulmonary angiogram	CTPA	66	4	41	6	0.94	-
Meaney [5]	1997	Magnetic resonance vs Computer tomography pulmonary angiogram	CTPA	8	0	21	1	1	0.95
Megyri [28]	2014	Magnetic resonance vs Computer tomography pulmonary angiogram	CTPA	36	2	184	4	0.947	0.979
Xiang LI [29]	2011	Magnetic resonance vs Computer tomography pulmonary angiogram	CTPA	22	9	33	10	0.74	-
Moores [30]	2016	Magnetic resonance vs Computer tomography pulmonary angiogram	CTPA	364	4	95	0	0.988	0.995
Ohno [31]	2004	Magnetic resonance vs Computer tomography pulmonary angiogram	CTPA	11	1	34	2	0.92	0.94
Oludkerk [32]	2002	Magnetic resonance vs Computer tomography pulmonary angiogram	CTPA	27	8	81	2	0.77	0.98
Pacouret [33]	2002	Magnetic resonance vs Computer tomography pulmonary angiogram	CTPA	46	0	46	4	0.989	0.912
Perez de Liano [34]	2006	Magnetic resonance vs Computer tomography pulmonary angiogram	CTPA	77	3	95	0	0.957	0.995
Perrier [35]	2011	Magnetic resonance vs Computer tomography pulmonary angiogram	CTPA	78	1	3	0	0.981	0.875
JR mayo [36]	1997	Magnetic resonance vs Computer tomography pulmonary angiogram	CTPA	7	3	16	7	0.7	-
Pleszewski [37]	2006	Magnetic resonance vs Computer tomography pulmonary angiogram	CTPA	9	2	37	0	0.82	1
Goodman [38]	2000	Magnetic resonance vs Computer tomography pulmonary angiogram	CTPA	35	9	23	2	0.8	-
Revel [39]	2012	Magnetic resonance vs Computer tomography pulmonary angiogram	CTPA	87	16	94	1	0.84	0.99
Righini [40]	2008	Magnetic resonance vs Computer tomography pulmonary angiogram	CTPA	19	0	3	0	0.975	0.875
Sostman[1]	1996	Magnetic resonance vs Computer tomography pulmonary angiogram	CTPA	3	4	16	2	0.43	0.89
Stein [41]	2010	Magnetic resonance vs Computer tomography pulmonary angiogram	CTPA	59	17	201	2	0.78	0.99
Stein [42]	2006	Magnetic resonance vs Computer tomography pulmonary angiogram	CTPA	150	31	567	25	0.829	0.958
Subramaniam [43]	2007	Magnetic resonance vs Computer tomography pulmonary angiogram	CTPA	105	1	380	0	0.986	0.999
Wei Huang[44]	2014	Magnetic resonance vs Computer tomography pulmonary angiogram	CTPA	181	1	243	0	0.992	0.998

Table1. Table of description

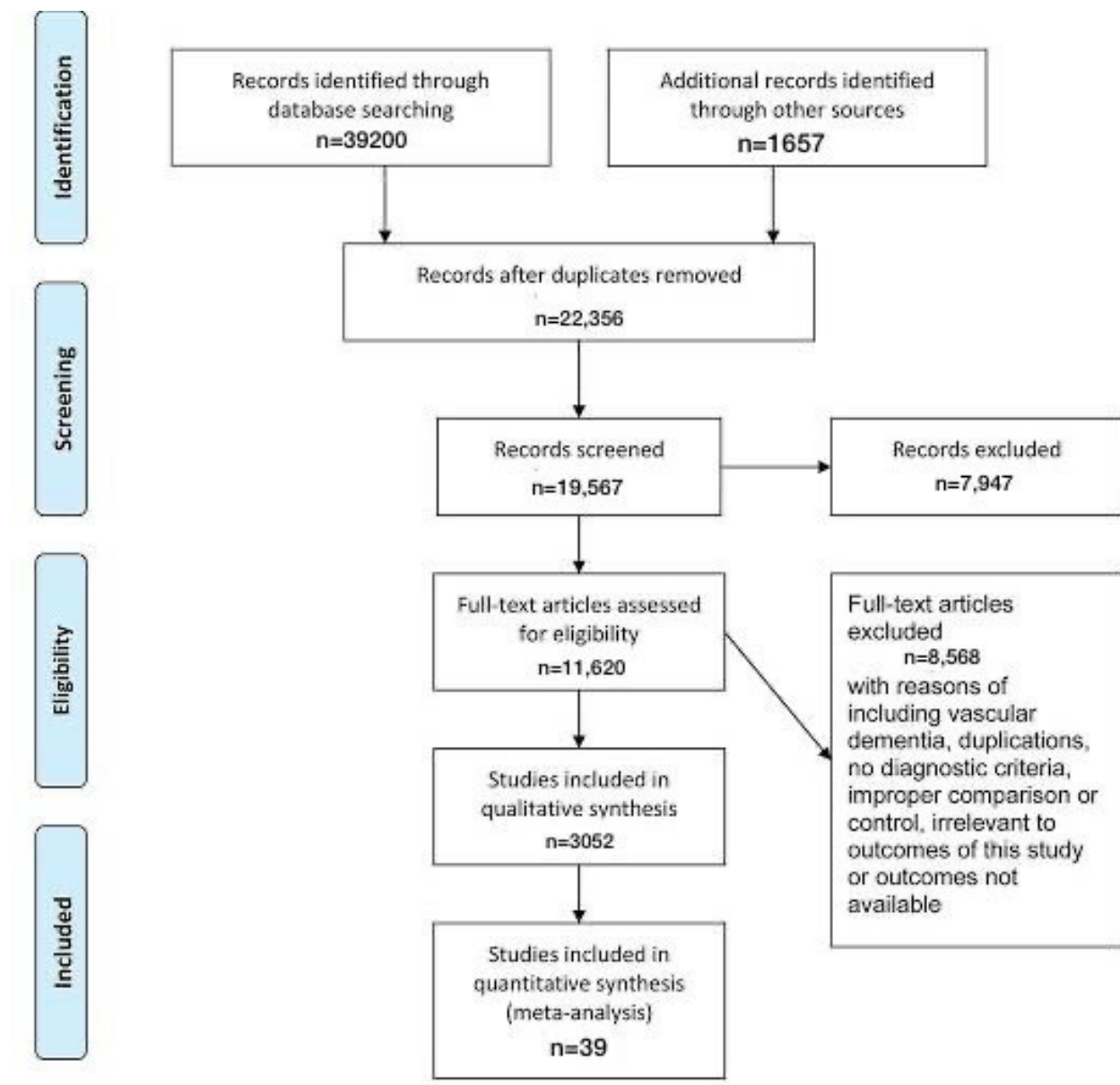


Figure-1 Prisma chart

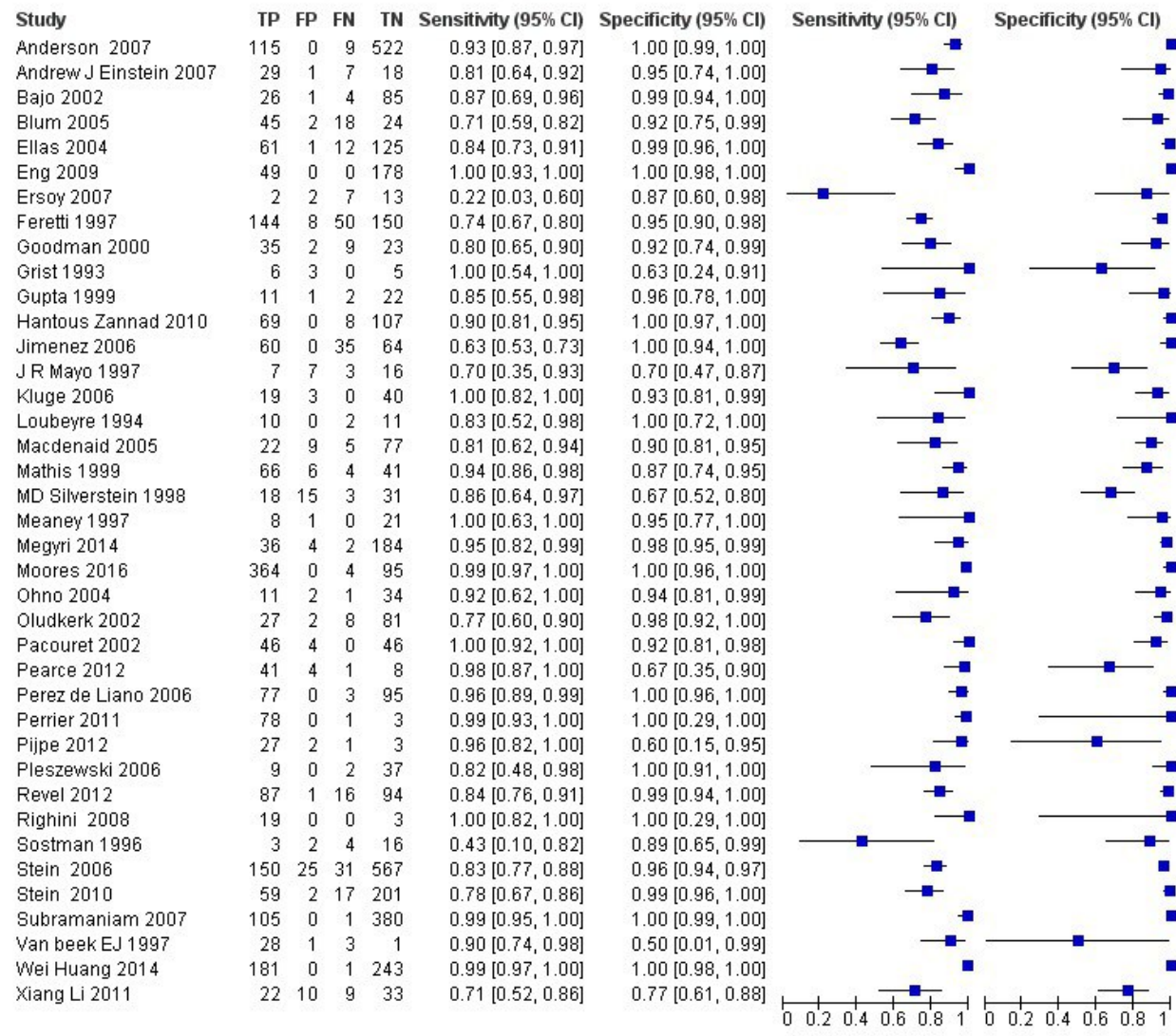


Figure 2 : The forest chart summary for MRPA and CTPA.

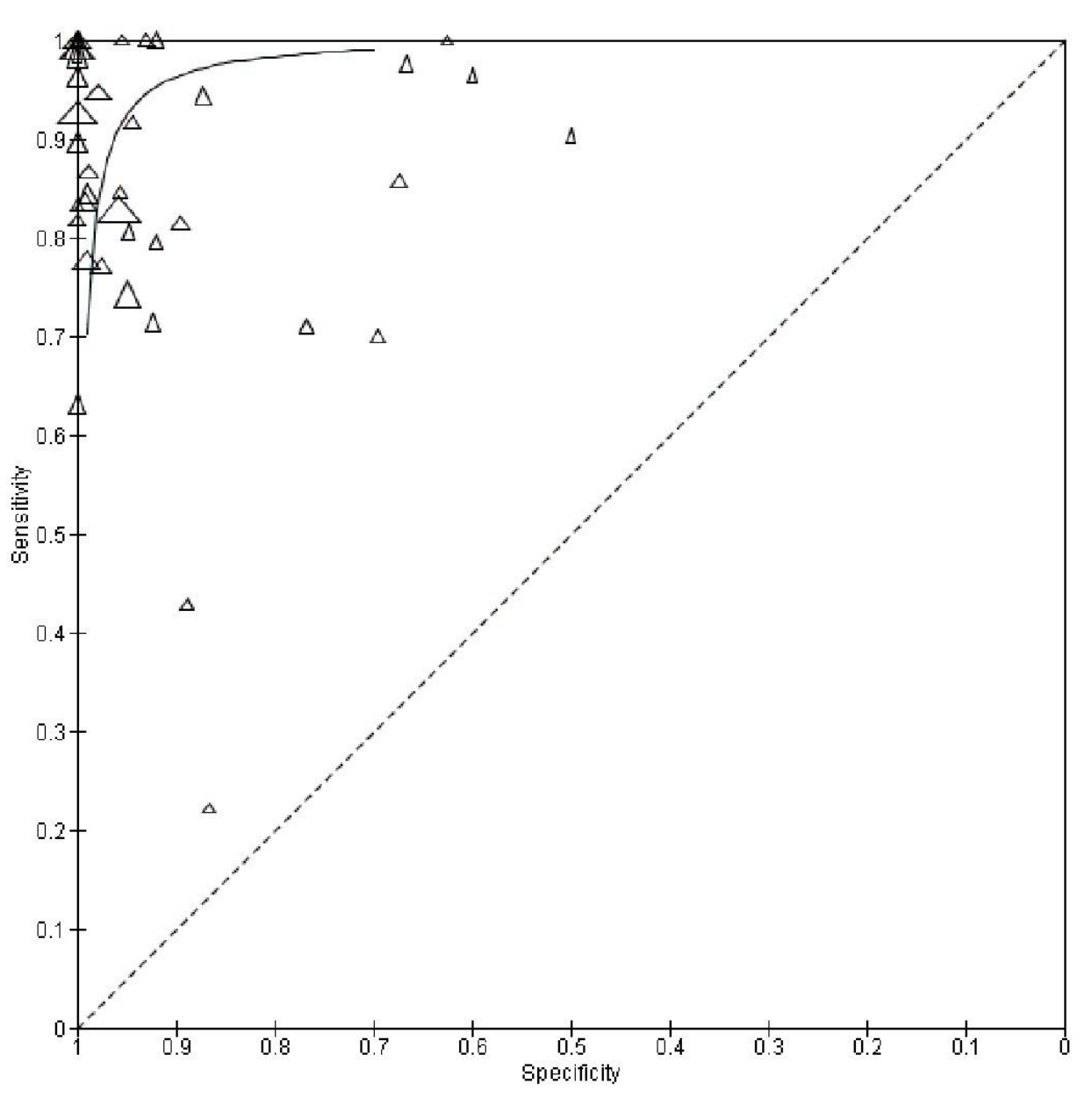


Figure 3 : The SROC plot summary for MRPA vs CTPA.

MRPA v CTPA

Here, Table 1 describes all the descriptions of papers used for the MRPA vs CTPA study. All the results described above, in the forest chart (figure 2), the comparison of the sensitivity and specificity of different papers can be observed. The same is illustrated in the SROC curve. (Figure 3). A total of 39 RCTs with 6273 were selected for the study, out of which 14 studies showed sensitivity above 95%, and 23 studies showed specificity above 95%. There were 9 studies that showed both sensitivity and specificity, to be over 95%. The value of True Positive (TP) was 2172, that of True Negative (TN) was 3697, that of False Positive (FP) was 121, and that of False Negative (FN) was 283. With a confidence interval 95%, sensitivity, specificity and

positive predictive values were calculated, a summary of which is available in figure 2. The sensitivity of MRPA is 0.885, with a CI of 95% in a range of 0.834 to 0.936; the mean being 0.051. The specificity of MRPA is 0.968, with a CI of 95% in a range of 0.927 to 1.010; the mean being 0.042.

The summary of the ROC curve is described in figure 3. It shows that the area under the curve for MRPA was 0.9265 and the overall diagnostic odds ratio (DOR) was 142.67 (CI95 = 76.10 to 267.48) with index Q* of intersection at 0.9128 (SE=0.0159) and Younden Index being 0.853

P value for Cochran Q for DOR was lower than 0.0001 and I² was at 76.3%

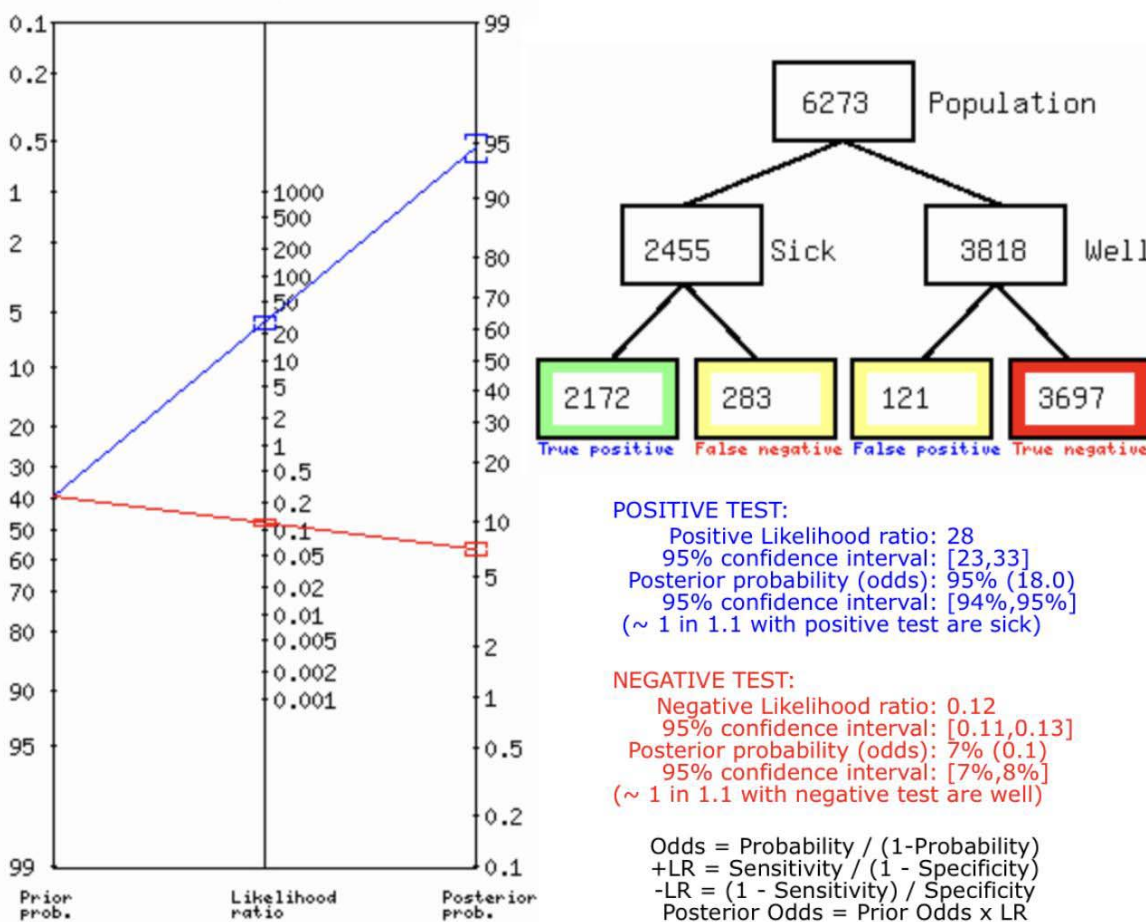


Figure 4 : Fagan's Analysis for MRPA vs CTPA.

Figure 4 describes the summary of Fagan plot analysis for all the studies considered for MRPA vs CTPA, showing a prior probability of 39% (0.6); a Positive Likelihood Ratio of 28; a probability of post-test 95% (18.0); a Negative likelihood ratio of 0.12, and a probability of post-test 7%(0.1).

No.s	Author Name and Year	Risk Of Bias				Applicability Concerns			
		Patient Se	Index Test	Reference	Flow and Timing	Patient Se	Index Test	Reference	Standard
1	Anderson 2007	+	+	+	+	+	+	+	
2	Bajo 2002	?	?	+	+	+	+	+	
3	Bham 2005	?	+	+	+	+	+	+	
4	Elias 2004	+	+	?	+	+	+	+	
5	Eng 2009	+	+	+	?	+	+	+	
6	Ersoy 2007	?	+	?	+	+	+	+	
7	Grist 1993	+	+	?	+	+	+	+	
8	Gupta 1999	+	+	+	?	+	+	+	
9	Hankou Zannad 2010	?	+	?	+	+	+	+	
10	Jimenez 2006	+	+	+	?	+	+	+	
11	Kluze 2006	?	+	?	+	+	+	+	
12	Van beek EJ 1997	+	+	+	+	+	+	+	
13	MD Silverstein 1998	+	+	+	+	+	+	+	
14	Andrew J Einstein 2007	+	+	?	+	+	+	+	
15	Loubeyre 1994	+	+	+	+	+	?	+	
16	Macedmad 2005	?	+	?	+	+	+	+	
17	Ferretti 1997	+	+	+	+	+	+	+	
18	Pipje 2012	+	+	?	+	+	+	+	
19	Pearce 2012	+	+	?	+	+	+	+	
20	Mathis 1999	?	+	?	+	?	+	+	
21	Meaney 1997	+	+	+	+	+	+	+	
22	Megyeri 2014	?	+	?	+	+	?	+	
23	Xiang LJ 2011	+	+	?	+	+	+	+	
24	Moore 2016	+	+	?	?	+	+	+	
25	Otmo 2004	+	+	+	?	+	+	+	
26	Ohadkerk 2002	+	+	+	+	+	?	+	
27	Pacouret 2002	+	+	+	+	+	+	+	
28	Perez de Liano 2006	+	+	?	?	+	+	+	
29	Perrier 2011	?	+	+	+	?	+	+	
30	JR Mayo 1997	+	?	+	+	+	+	+	
31	Plaszewski 2006	?	+	?	+	+	+	+	
32	Goodman 2000	+	+	+	+	+	+	+	
33	Revel 2012	?	?	+	+	+	+	+	
34	Righini 2008	+	+	+	+	+	+	+	
35	Sostman 1996	+	?	+	+	+	+	+	
36	Stein 2006	+	+	+	+	+	+	+	
37	Stein 2010	+	+	+	+	?	+	+	
38	Subramaniam 2007	?	+	?	+	+	+	+	
39	Wei Huang 2014	+	+	+	+	+	+	+	

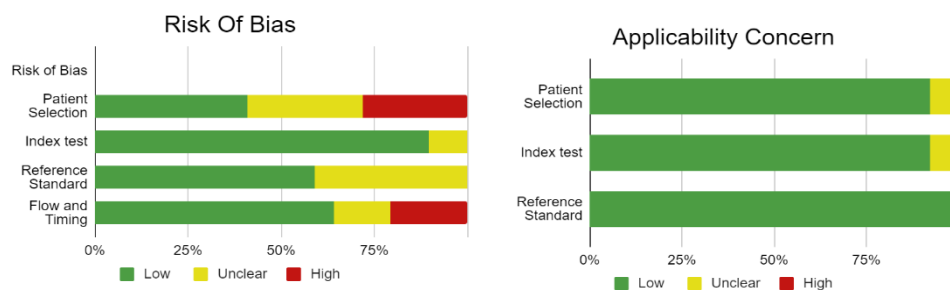


Figure 5 Risk of Bias and Applicability concern

Figure 5 describes the bias study and applicability concern. The tool used for this is QUADAS-2 analysis. The study is having low risk of bias and low risk of applicability concern. The reference standard is suggestive of risk of bias and having low applicability concern.

DISCUSSION:

Pulmonary embolism is a sudden and potentially life-threatening condition that occurs due to blockage of one or more pulmonary arteries from embolic material. The embolus or blood clot generally forms in one of the deep veins of the legs or pelvis. This blockage reduces or stops blood flow and can elevate pressures within the right ventricle of the heart.

It is an often underdiagnosed condition, due to its non specific signs and symptoms. Thus, though early treatment is very effective, diagnosis using objective tests that can establish or refute diagnosis are the standard of care. Diagnosis should be based on the clinical probability of PE.[6]

This meta-analysis presents a comparison between Computed Tomography Pulmonary Angiography (CTPA) and Magnetic Resonance Angiography (MRA), to diagnose a pulmonary embolism.

This review has many strengths, chief among which is the systematic approach to identifying and including comprehensive studies, which makes it unlikely that relevant studies were not included.

Computed tomography pulmonary angiography has made the diagnosis of pulmonary embolism in clinically suspected cases easier. CTAP has high sensitivity and specificity, which are comparable with invasive pulmonary angiography. It has been shown to confirm or rule out APE with satisfactory certainty, removing the need for additional imaging tests. Nevertheless, inherent limitations of CT include substantial radiation exposure, thus, alternative tests and imaging are still encouraged.[45]

One such test with a high rate of success in diagnosis is MRA.

2.1 Our results

This meta-analysis was conducted using 39 scientific papers. After thorough perusal of each scientific paper, the data was collated and statistical tests were conducted.

The established gold standard for diagnosis of pulmonary embolism continues to be Computed Tomography. However, in recent years, the use of MRA has increased, with promising results. This meta-analysis showed a high sensitivity (0.885) as well as high specificity (0.968) for MRA. The results also showed a high positive predictive value of 0.947 or 94.7% for MRA in the diagnosis of Pulmonary embolism, as compared with CTPA.

These results establish MRA as a respectable alternative for diagnosis of APE, especially in cases when reducing radiation exposure is desired.

2.2 Compare with other papers

A recent analysis indicated that on a patient-based level, MRI can yield high diagnostic accuracy in the detection of acute pulmonary embolism, especially in images that are technically adequate.

MRA carries a more attractive potential as an alternative diagnostic test to CTAP due to the lack of ionizing radiation that is associated with CTAP, as well as lower risk of complications that are linked with use of contrast media.

Inconclusive MRI examinations can occur due to many reasons, including poor arterial opacification or artifact in the plate due to motion at the time of scan.

A combination of MRI tests with greater ability to differentiate, than single techniques appears to be more promising in the diagnosis of PE.

From a vessel based perspective, MRI exhibits better diagnostic capability in for embolisms in proximal arteries, but has low sensitivity for peripheral embolisms.[45][46]CTPA is routinely applied in practice, even in severe cases, emergency settings and dyspneic patients, as it only requires short infrequent breath holding. However, in patients who have contraindications to use of contrast material, such as allergies or younger patients, MRA is an alternative method for pulmonary imaging, as it does not require ionizing radiation or contrast material.

However, the use of MRA in severely ill patients continues to be challenging, as the longer scan times and multiple breath holds that are required in different MR protocols are difficult to follow in these patients. [26]Other analyses have marked MRI to have high specificity but limited or low sensitivity in the diagnosis of PE.

A major limitation for the practical application of MRA is inconclusive results. [33]

Thus, as the results show, in diagnosis of Pulmonary Embolism, Magnetic Resonance Angiography is a good alternative, but the gold standard of diagnosis remains Computed Tomography Pulmonary Angiography.

CONCLUSION :

As the results suggest, MRA stands to be a good test for the diagnosis of pulmonary embolism when CTPA cannot be used. MRA has been noted to have lower sensitivity in other analyses, as well as to have inconclusive results. CTPA is routinely applied in practice, even in severe cases, emergency settings and dyspneic patients, as it only requires short infrequent breath holding. CTPA can be used in severely ill patients as well, with its shorter test times. MRA may be used in patients with contraindications to use of contrast material, as well as in patients who require lower radiation exposure. This meta- analysis found a high positive predictive value of 94.7% for MRA. However, CTPA remains the gold standard for the diagnosis of PE with its higher sensitivity and specificity for the diagnosis of PE, as well as the ease of testing for patients and physicians.

REFERENCES:

- [1] Sostman HD, Layish DT, Tapson VF, Spritzer CE, DeLong DM, Trotter P, MacFall JR, Patz EF Jr, Goodman PC, Woodard PK, Foo TK, Farber JL. Prospective comparison of helical CT and MR imaging in clinically suspected acute pulmonary embolism. *J Magn Reson Imaging*. 1996 Mar-Apr;6(2):275-81. doi: 10.1002/jmri.1880060203. PMID: 9132089.
- [2] Tsuchiya N, van Beek EJ, Ohno Y, Hatabu H, Kauczor HU, Swift A, Vogel-Claussen J, Biederer J, Wild J, Wielpütz MO, Schiebler ML. Magnetic resonance angiography for the primary diagnosis of pulmonary embolism: A review from the international workshop for pulmonary functional imaging. *World J Radiol*. 2018 Jun 28;10(6):52-64. doi: 10.4329/wjr.v10.i6.52. PMID: 29988845; PMCID: PMC6033703.
- [3] Nagle SK, Schiebler ML, Repplinger MD, François CJ, Vigen KK, Yarlagadda R, Grist TM, Reeder SB. Contrast enhanced pulmonary magnetic resonance angiography for pulmonary embolism: Building a successful program. *Eur J Radiol*. 2016 Mar;85(3):553-63. doi: 10.1016/j.ejrad.2015.12.018. Epub 2015 Dec 29. PMID: 26860667; PMCID: PMC4751592.
- [4] Marshall PS, Mathews KS, Siegel MD. Diagnosis and management of life-threatening pulmonary embolism. *J Intensive Care Med*. 2011 Sep-Oct;26(5):275-94. doi: 10.1177/0885066610392658. Epub 2011 May 23. PMID: 21606060.
- [5] Meaney JF, Weg JG, Chenevert TL, Stafford-Johnson D, Hamilton BH, Prince MR. Diagnosis of pulmonary embolism with magnetic resonance angiography. *N Engl J Med*. 1997 May 15;336(20):1422-7. doi: 10.1056/NEJM199705153362004. PMID: 9145679.
- [6] Hogg K, Brown G, Dunning J, Wright J, Carley S, Foex B, Mackway-Jones K. Diagnosis of pulmonary embolism with CT pulmonary angiography: a systematic review. *Emerg Med J*. 2006 Mar;23(3):172-8. doi: 10.1136/emj.2005.029397. PMID: 16498151; PMCID: PMC2464412.
- [7] D. Desai, “Dev’s Formulae for Diagnostic Test Accuracy Meta-analysis,” *medRxiv*, p. 2023.03.27.23287186, Jan. 2023, doi: 10.1101/2023.03.27.23287186.
- [8] Anderson DR, Kahn SR, Rodger MA, et al. Computed tomographic pulmonary angiography vs ventilation-perfusion lung scanning in patients with suspected pulmonary embolism: a randomized controlled trial. *JAMA*. 2007;298(23):2743-2753.
- [9] Bajc M, Albrechtsson U, Olsson CG, Olsson B, Jonson B. Comparison of ventilation/perfusion scintigraphy and helical CT for diagnosis of pulmonary embolism; strategy using clinical data and ancillary findings. *Clin Physiol Funct Imaging*. 2002;22(6):392-397.
- [10] Blum, A, Bellou, F, Guillemin, P, Douek, M.C, Laprèvote-Heully, D, Wahl, GENEPI Study Group, Performance of magnetic resonance angiography in suspected acute pulmonary embolism, *Thromb. Haemost.* 93 (2005) 503–511.
- [11] Elias A, Colombier D, Victor G, et al. Diagnostic performance of complete lower limb venous ultrasound in patients with clinically suspected acute pulmonary embolism. *Thromb Haemost.* 2004;91(1):187-195.

- [12] Eng CW, Wansaicheong G, Goh SK, Earnest A, Sum C. Exclusion of acute pulmonary embolism: computed tomography pulmonary angiogram or D-dimer? *Singapore Med J.* 2009 Apr;50(4):403-6. PMID: 19421686.
- [13] H. Ersoy, S.Z. Goldhaber, T. Cai, T. Luu, J. Rosebrook, R. Mulkern, F. Rybicki, Time-resolved MR angiography: a primary screening examination of patients with suspected pulmonary embolism and contraindications to administration of iodinated contrast material, *Am. J. Roentgenol.* 188 (2007) 1246–1254
- [14] T.M. Grist, H.D. Sostman, J.R. MacFall, T.K. Foo, C.E. Spritzer, L. Witty, G.E. Newman, J.F. Debatin, V. Tapsan, H.A. Saltzman, Pulmonary angiography with MR imaging: preliminary clinical experience, *Radiology* 189 (1993) 523–530.
- [15] A. Gupta, C.K. Frazer, J.M. Ferguson, A.B. Kumar, S.J. Davis, M.J. Fallon, I.T. Morris, P.J. Drury, L.A. Cala, Acute pulmonary embolism: diagnosis with MR angiography, *Radiology* 210 (1999) 353–359.
- [16] Hantous-Zannad S, Esseghaier S, Ridene I, et al. Acute pulmonary embolism: epidemiologic and tomodesitometric study. *Tunis Med.* 2010;88(12): 880-884.
- [17] Jimenez D, Gómez M, Herrero R, et al. Thromboembolic events in patients after a negative computed tomography pulmonary angiogram: a retrospective study of 165 patients [in Spanish]. *Arch Bronconeumol.* 2006;42(7):344-348. doi:[https://doi.org/10.1016/S1579-2129\(06\)60544-2](https://doi.org/10.1016/S1579-2129(06)60544-2).
- [18] Kluge, W. Luboldt, G. Bachmann, Acute pulmonary embolism to the subsegmental level: diagnostic accuracy of three MRI techniques compared with 16-MDCT, *Am. J. Roentgenol.* 187 (2006) W7–14.
- [19] van Beek EJ, Kuijter PM, Büller HR, Brandjes DP, Bossuyt PM, ten Cate JW. The clinical course of patients with suspected pulmonary embolism. *Arch Intern Med.* 1997 Dec 8-22;157(22):2593-8. doi: 10.1001/archinte.157.22.2593. PMID: 9531228.
- [20] Silverstein MD, Heit JA, Mohr DN, Petterson TM, O'Fallon WM, Melton LJ 3rd. Trends in the incidence of deep vein thrombosis and pulmonary embolism: a 25-year population-based study. *Arch Intern Med.* 1998 Mar 23;158(6):585-93. doi: 10.1001/archinte.158.6.585. PMID: 9521222.
- [21] Einstein AJ, Henzlova MJ, Rajagopalan S. Estimating risk of cancer associated with radiation exposure from 64-slice computed tomography coronary angiography. *JAMA.* 2007 Jul 18;298(3):317-23. doi: 10.1001/jama.298.3.317. PMID: 17635892.
- [22] Loubeyre P, Revel D, Douek P, Delignette A, Baldy C, Genin G, Amiel M. Dynamic contrast-enhanced MR angiography of pulmonary embolism: comparison with pulmonary angiography. *AJR Am J Roentgenol.* 1994 May;162(5):1035-9. doi: 10.2214/ajr.162.5.8165977. PMID: 8165977.
- [23] Macdonald WB, Patrikeos AP, Thompson RI, Adler BD, van der Schaaf AA. Diagnosis of pulmonary embolism: ventilation perfusion scintigraphy versus helical computed tomography pulmonary angiography. *Australas Radiol.* 2005;49(1):32-38.
- [24] Ferretti GR, Bosson JL, Buffaz PD, Ayanian D, Pison C, Blanc F, Carpentier F, Carpentier P, Coulomb M. Acute pulmonary embolism: role of helical CT in 164 patients with intermediate probability

- at ventilation-perfusion scintigraphy and normal results at duplex US of the legs. *Radiology*. 1997 Nov;205(2):453-8. doi: 10.1148/radiology.205.2.9356628. PMID: 9356628.
- [25] Pijpe A, Andrieu N, Easton DF, Kesminiene A, Cardis E, Noguès C, Gauthier-Villars M, Lasset C, Fricker JP, Peock S, Frost D, Evans DG, Eeles RA, Paterson J, Manders P, van Asperen CJ, Ausems MG, Meijers-Heijboer H, Thierry-Chef I, Hauptmann M, Goldgar D, Rookus MA, van Leeuwen FE; GENEPSO; EMBRACE; HEBON. Exposure to diagnostic radiation and risk of breast cancer among carriers of BRCA1/2 mutations: retrospective cohort study (GENE-RAD-RISK). *BMJ*. 2012 Sep 6;345:e5660. doi: 10.1136/bmj.e5660. PMID: 22956590; PMCID: PMC3435441.
- [26] Pearce MS, Salotti JA, Little MP, McHugh K, Lee C, Kim KP, Howe NL, Ronckers CM, Rajaraman P, Sir Craft AW, Parker L, Berrington de González A. Radiation exposure from CT scans in childhood and subsequent risk of leukaemia and brain tumours: a retrospective cohort study. *Lancet*. 2012 Aug 4;380(9840):499-505. doi: 10.1016/S0140-6736(12)60815-0. Epub 2012 Jun 7. PMID: 22681860; PMCID: PMC3418594.
- [27] Tyler Andrew Scott, Nicola Ulibarri, Omar Perez Figueroa, NEPA and National Trends in Federal Infrastructure Siting in the United States, Review of Policy Research, 10.1111/ropr.12399, **37**, 5, (605-633), (2020). Tyler Andrew Scott, Nicola Ulibarri, Omar Perez Figueroa, NEPA and National Trends in Federal Infrastructure Siting in the United States, Review of Policy Research, 10.1111/ropr.12399, **37**, 5, (605-633), (2020).
- [28] Megyeri B, Christe A, Schindera ST, et al. Accuracy of computed tomography angiography in the detection of pulmonary embolism in patients with high body weight. *Eur J Intern Med*. 2014;25(8):724-730.
- [29] Li X, Samei E, Segars WP, Sturgeon GM, Colsher JG, Frush DP. Patient-specific radiation dose and cancer risk for pediatric chest CT. *Radiology*. 2011 Jun;259(3):862-74. doi: 10.1148/radiol.11101900. Epub 2011 Apr 5. PMID: 21467251; PMCID: PMC3099041.
- [30] Moores L, Kline J, Portillo AK, et al. Multidetector computed tomographic pulmonary angiography in patients with a high clinical probability of pulmonary embolism. *J Thromb Haemost*. 2016;14(1):114-120.
- [31] Ohno Y, Higashino T, Takenaka D, Sugimoto K, Yoshikawa T, Kawai H, Fujii M, Hatabu H, Sugimura K. MR angiography with sensitivity encoding (SENSE) for suspected pulmonary embolism: comparison with MDCT and ventilation-perfusion scintigraphy. *AJR Am J Roentgenol*. 2004 Jul;183(1):91-8. doi: 10.2214/ajr.183.1.1830091. PMID: 15208117.
- [32] Oudkerk M, van Beek EJ, Wielopolski P, van Ooijen PM, Brouwers-Kuyper EM, Bongaerts AH, Berghout A. Comparison of contrast-enhanced magnetic resonance angiography and conventional pulmonary angiography for the diagnosis of pulmonary embolism: a prospective study. *Lancet*. 2002 May 11;359(9318):1643-7. doi: 10.1016/S0140-6736(02)08596-3. PMID: 12020524.
- [33] Palud L, Laurent M, Guéret P, Meunier C, Garin E, Benoît PO, Belléguic C, Bernard du Haut Cilly F, Almange C, Daubert JC. Intérêt de l'association du dosage des D-dimères et de l'évaluation de la probabilité clinique dans une stratégie diagnostique non invasive de l'embolie pulmonaire [Value of the association of D-dimer measurement and the evaluation of clinical probability in a non-invasive

diagnostic strategy of pulmonary embolism]. *Arch Mal Coeur Vaiss.* 2004 Feb;97(2):93-9. French. PMID: 15032407.

[34] Perez de Llano LA, Veres Racamonde A, Ortiz Piquer M, et al. Safety of withholding anticoagulant therapy in patients who have clinically suspected pulmonary embolism and negative results on helical computed tomography. *Respiration.* 2006;73(4):514-519.

[35] Perrier A, Roy PM, Aujesky D, et al. Diagnosing pulmonary embolism in outpatients with clinical assessment, D-dimer measurement, venous ultrasound, and helical computed tomography: a multicenter management study. *Am J Med.* 2004;116(5):291-299.

[36] Mayo JR, Remy-Jardin M, Müller NL, Remy J, Worsley DF, Hossein-Foucher C, Kwong JS, Brown MJ. Pulmonary embolism: prospective comparison of spiral CT with ventilation-perfusion scintigraphy. *Radiology.* 1997 Nov;205(2):447-52. doi: 10.1148/radiology.205.2.9356627. PMID: 9356627.

[37] B. Pleszewski, C. Chartrand-Lefebvre, S.D. Qanadli, R. Déry, P. Perreault, V.L. Oliva, J. Prenovault, A. Belblidia, G. Soulez, Gadolinium-enhanced pulmonary magnetic resonance angiography in the diagnosis of acute pulmonary embolism: a prospective study on 48 patients, *Clin. Imaging* 30 (2006) 166–172.

[38] Goodman LR, Lipchik RJ, Kuzo RS, Liu Y, McAuliffe TL, O'Brien DJ. Subsequent pulmonary embolism: risk after a negative helical CT pulmonary angiogram--prospective comparison with scintigraphy. *Radiology.* 2000 May;215(2):535-42. doi: 10.1148/radiology.215.2.r00ma23535. PMID: 10796937.

[39] M.P. Revel, O. Sanchez, S. Couchon, B. Planquette, A. Hernigou, R. Niarra, G. Meyer, G. Chatellier, Diagnostic accuracy of magnetic resonance imaging for an acute pulmonary embolism: results of the 'IRM-EP' study, *J. Thromb. Haemost.* 10 (2012) 743–750.

[40] Le Gal G, Righini M, Roy PM, et al. Value of D-dimer testing for the exclusion of pulmonary embolism in patients with previous venous thromboembolism. *Arch Intern Med.* 2006;166(2):176-180.

[41] P.D. Stein, T.L. Chenevert, S.E. Fowler, L.R. Goodman, A. Gottschalk, C.A. Hales, R.D. Hull, K.A. Jablonski, K.V. Leeper Jr., D.P. Naidich, D.J. Sak, H.D. Sostman, V.F. Tapson, J.G. Weg, P.K. Woodard, PIOPED III (Prospective Investigation of Pulmonary Embolism Diagnosis III) Investigators, Gadolinium-enhanced magnetic resonance angiography for pulmonary embolism: a multicenter prospective study (PIOPED III), *Ann. Intern. Med.* 152 (2010) 434–443.

[42] Stein PD, Fowler SE, Goodman LR, et al; PIOPED II Investigators. Multidetector computed tomography for acute pulmonary embolism. *N Engl J Med.* 2006;354(22):2317-2327.

[43] Subramaniam RM, Blair D, Gilbert K, Coltman G, Sleigh J, Karalus N. Withholding anticoagulation after a negative computed tomography pulmonary angiogram as a stand-alone imaging investigation: a prospective management study. *Intern Med J.* 2007;37(9):624-630.

[44] Huang W, Goldberg RJ, Anderson FA, Kiefe CI, Spencer FA. Secular trends in occurrence of acute venous thromboembolism: the Worcester VTE study (1985-2009). *Am J Med.* 2014;127(9):829-39.e5.

[45] Zhou M, Hu Y, Long X, Liu D, Liu L, Dong C, Wang J, Kong X. Diagnostic performance of magnetic resonance imaging for acute pulmonary embolism: a systematic review and meta-analysis. *J Thromb Haemost.* 2015 Sep;13(9):1623-34. doi: 10.1111/jth.13054. Epub 2015 Aug 11. PMID: 26179627.

[46] Klok FA, Mos IC, Kroft LJ, de Roos A, Huisman MV. Computed tomography pulmonary angiography as a single imaging test to rule out pulmonary embolism. *Curr Opin Pulm Med.* 2011 Sep;17(5):380-6. doi: 10.1097/MCP.0b013e328348b3de. PMID: 21681098.