

1 **Title: Multimodal Molecular Imaging Reveals Tissue-Based T Cell Activation and Viral RNA**
2 **Persistence for Up to 2 Years Following COVID-19**

3
4 **Short Title:** Tissue T Cell Activation and Viral RNA Persistence Following COVID-19

5
6 Michael J. Peluso^{1*}, Dylan Ryder^{2*}, Robert Flavell^{3*}, Yingbing Wang³, Jelena Levi⁴, Brian H. LaFranchi²,
7 Tyler-Marie Deveau², Amanda M. Buck², Sadie E. Munter², Kofi A. Asare², Maya Aslam³, Wally Koch³,
8 Gyula Szabo⁵, Rebecca Hoh¹, Monika Deswal¹, Antonio Rodriguez¹, Melissa Buitrago¹, Viva Tai¹, Uttam
9 Shrestha³, Scott Lu⁶, Sarah A. Goldberg⁶, Thomas Dalhuisen⁶, Matthew S. Durstenfeld⁷, Priscilla Y. Hsue⁷,
10 J. Daniel Kelly⁶, Nitasha Kumar¹, Jeffrey N. Martin⁶, Aruna Gambir⁴, Ma Somsouk⁸, Youngho Seo³, Steven
11 G. Deeks¹, Zoltan G. Laszik⁵, Henry F. VanBrocklin^{3^}, Timothy J. Henrich^{2^}

12
13 *,^ authors contributed equally

14
15 **Affiliations:**

16 ¹ Division of HIV, Infectious Diseases, and Global Medicine, University of California San Francisco, San
17 Francisco, CA USA

18 ² Division of Experimental Medicine, University of California San Francisco

19 ³ Department of Radiology and Biomedical Imaging, University of California San Francisco

20 ⁴ CellSight Technologies, San Francisco, CA

21 ⁵ Department of Pathology, University of California San Francisco

22 ⁶ Department of Epidemiology and Biostatistics, University of California San Francisco

23 ⁷ Division of Cardiology, University of California San Francisco

24 ⁸ Division of Gastroenterology, University of California San Francisco

25
26 **To Whom Correspondence**

27 Should Be Addressed: Timothy J. Henrich, MD
28 Division of Experimental Medicine
29 1001 Potrero Ave.
30 San Francisco, CA, USA 94110
31 timothy.henrich@ucsf.edu

32
33 Michael J. Peluso, MD
34 Division of HIV, Infectious Diseases, and Global Medicine
35 1001 Potrero Ave.
36 San Francisco, CA, USA 94110
37 michael.peluso@ucsf.edu

38
39 Henry F. VanBrocklin, PhD
40 Department of Radiology and Biomedical Imaging
41 185 Berry Street Bldg B, #165
42 San Francisco CA 94158
43 Henry.vanbrocklin@ucsf.edu

44 **ABSTRACT**

45 The etiologic mechanisms of post-acute medical morbidities and unexplained symptoms (Long COVID)
46 following SARS-CoV-2 infection are incompletely understood. There is growing evidence that viral
47 persistence and immune dysregulation may play a major role. We performed whole-body positron emission
48 tomography (PET) imaging in a cohort of 24 participants at time points ranging from 27 to 910 days
49 following acute SARS-CoV-2 infection using a novel radiopharmaceutical agent, [¹⁸F]F-AraG, a highly
50 selective tracer that allows for anatomical quantitation of activated T lymphocytes. Tracer uptake in the
51 post-acute COVID group, which included those with and without Long COVID symptoms, was significantly
52 higher compared to pre-pandemic controls in many anatomical regions, including the brain stem, spinal
53 cord, bone marrow, nasopharyngeal and hilar lymphoid tissue, cardiopulmonary tissues, and gut wall.
54 Although T cell activation tended to be higher in participants imaged closer to the time of the acute illness,
55 tracer uptake was increased in participants imaged up to 2.5 years following SARS-CoV-2 infection. We
56 observed that T cell activation in spinal cord and gut wall was associated with the presence of Long COVID
57 symptoms. In addition, tracer uptake in lung tissue was higher in those with persistent pulmonary
58 symptoms. Notably, increased T cell activation in these tissues was also observed in many individuals
59 without Long COVID. Given the high [¹⁸F]F-AraG uptake detected in the gut, we obtained colorectal tissue
60 for *in situ* hybridization SARS-CoV-2 RNA and immunohistochemical studies in a subset of participants
61 with Long COVID symptoms. We identified cellular SARS-CoV-2 RNA in rectosigmoid lamina propria tissue
62 in all these participants, ranging from 158 to 676 days following initial COVID-19 illness, suggesting that
63 tissue viral persistence could be associated with long-term immunological perturbations.

64

65 **Keywords:** COVID-19, SARS-CoV-2; post-acute sequelae of SARS-CoV-2 (PASC); Long COVID; PET
66 imaging; viral persistence; immune activation

67

68

69 INTRODUCTION

70 Some people do not return to their baseline health following SARS-CoV-2 infection^{1,2}. Following the acute
71 phase, such individuals may experience an increased burden of new onset medical conditions such as
72 cardiovascular disease or diabetes mellitus³. They may also experience Long COVID (LC), defined as
73 unexplained symptoms or changes in health not attributable to an alternative diagnosis². The U.S. Centers
74 for Disease Control and Prevention (CDC) recently reported that approximately 15% of American adults
75 have experienced Long COVID at any time and that 6% are currently experiencing the condition⁴; up to 18
76 million adults in the U.S. alone might be affected⁵. Despite the scale of the problem, there are currently no
77 accepted treatments and massive efforts are now underway to understand the pathophysiology of these
78 post-acute sequelae, including Long COVID^{6,7}.

79
80 Acute COVID-19 is a highly inflammatory illness^{8,9}. In the post-acute phase, inflammation, immune
81 activation and long-term dysregulation of virus-specific immune responses have consistently been
82 identified in peripheral blood¹⁰⁻²². These immune responses have been associated with a variety of factors
83 including clotting dysfunction,²³⁻²⁶ reactivation of latent viral infections such as Epstein Barr Virus
84 (EBV),^{10,27,28} and autoimmune responses^{10,29-33}. Importantly, there is a growing body of evidence that
85 persistent SARS-CoV-2 RNA or protein can be detected in various tissue compartments for many months
86 following acute infection³⁴⁻⁴¹. This may explain, at least in part, ongoing aberrant immune responses,
87 inflammation, and clinical symptomatology^{42,43}.

88 Despite advances in understanding systemic inflammation in Long COVID, data regarding the role of
89 SARS-CoV-2 persistence or aberrant T cell responses in non-blood tissues are sparse. Most studies to
90 date have been limited to small autopsy or biopsy samples from convenience cohorts^{35,38}, with many
91 individuals requiring hospitalization during acute infection or without detailed data on the post-acute course.
92 Clinical studies that have evaluated tissue pathology in living participants have assessed limited quantities
93 of tissue obtained through minimally invasive clinical biopsies. Furthermore, anatomic regions such as
94 brain, spinal cord, cardiopulmonary tissue, vascular tissue, and other potential sites of SARS-CoV-2
95 persistence cannot be sampled in living individuals via biopsy procedures^{44,45}. As a result, characterization

96 of the immune responses in these anatomical locations, including processes like T cell activation and
97 trafficking, has been limited. When it has been attempted, it has utilized non-specific tracers or limited
98 follow-up of clinical symptoms⁴⁶⁻⁵³. Therefore, there is an urgent need to develop non-invasive techniques
99 to identify more specific persistent and/or aberrant immune responses in highly characterized cohorts over
100 the long-term to better understand the tissue-level biology that might drive findings observed in peripheral
101 blood.

102 In this study, we performed whole-body positron emission tomography (PET) imaging in 24 highly
103 characterized participants from the UCSF-based LIINC cohort (NCT04362150)⁵⁴ at time points ranging
104 from 27 to 910 days following COVID-19 symptom onset. We used a novel radiopharmaceutical agent,
105 [¹⁸F]F-AraG (Fluorine-18 labeled arabino furanosyl guanine), a selective and sensitive tracer that allows
106 for anatomical localization of activated CD8+ and CD4+ T lymphocytes⁵⁵⁻⁵⁷. We found that [¹⁸F]F-AraG
107 uptake was significantly higher in many anatomical regions among post-acute COVID participants
108 compared to pre-pandemic controls. These included the brain stem, spinal cord, bone marrow,
109 nasopharyngeal and hilar lymphoid tissue, cardiopulmonary tissues, and gut wall. Increased uptake was
110 identified up to 2.5 years following SARS-CoV-2 infection in the absence of known re-infection.
111 Furthermore, [¹⁸F]F-AraG uptake in some tissues was associated with a higher number of Long COVID
112 symptoms. Lastly, we identified cellular SARS-CoV-2 RNA in rectosigmoid lamina propria tissue in all
113 participants with Long COVID symptoms who underwent biopsy, ranging from 158 to 676 days following
114 initial COVID-19 symptom onset, suggesting that tissue viral persistence could be associated with these
115 immunologic findings.

116 **RESULTS**

117 **Study cohort.**

118 Following local institutional review board and radiation safety committee approvals, [¹⁸F]F-AraG PET/CT
119 imaging was performed on 24 participants identified from the University of California San Francisco
120 (UCSF)-based Long-term Impact of Infection with Novel Coronavirus (LIINC) study (NCT04362150)⁵⁴. We

121 enrolled two groups of individuals: (1) in the early post-acute phase (<90 days from COVID-19 symptom
122 onset with and without complete recovery (n=3 and n=6, respectively), and (2) in the later post-acute phase
123 (>90 days from COVID-19 symptom onset) with and without complete recovery (n=3 who recovered quickly
124 and n=15 with Long COVID symptoms (**Table 1**). In addition, images obtained from 6 participants who
125 underwent [¹⁸F]F-AraG PET imaging (3 females and 3 males) prior to 2020 were used as pre-pandemic
126 controls. We elected to use pre-pandemic rather than contemporaneous comparators to avoid
127 misclassification of such individuals, given the high rate of subclinical or undiagnosed SARS-CoV-2
128 infection during the study period.

129 **Table 1** lists participant demographics, clinical factors and Long COVID symptoms present at the time of
130 imaging. Eleven participants were female, a majority were infected prior to emergence of Omicron variants,
131 and only two were hospitalized during the acute phase of SARS-CoV-2 infection; one had required
132 supplemental oxygen, but not intensive care or mechanical ventilation and the other had not required
133 supplemental oxygen or intensive care. The median age was 39.5 years (range 26 to 65), median number
134 of Long COVID symptoms at the PET screening visit was 5.5 (range 0 to 15), and median number of days
135 from initial COVID-19 symptom onset and PET imaging was 199 (range 27 to 910). The most common
136 symptoms were fatigue (n=16) and neurocognitive complaints (n=14). Six participants did not report any
137 Long COVID symptoms at the time of imaging. All but one participant had received at least one COVID-19
138 vaccination prior to PET imaging (median number of days from the most recent vaccine dose to tracer
139 injection was 183 days).

140 To minimize the impact of vaccination on T cell activation, PET imaging was performed greater than 60
141 days from any vaccine dose (SARS-CoV-2 or otherwise), but one participant received a SARS-CoV-2
142 booster vaccine dose 6 days prior to imaging without notifying the study team. One participant (number 17)
143 was initially infected during the ancestral wave but experienced two documented re-infections with
144 presumed Omicron variants prior to PET imaging. Except for participant 17, no one reported acute
145 symptoms suggestive of infection with another virus or reinfection with SARS-CoV-2 reinfection between

146 the initial COVID-19 episode and PET imaging; during the study period none had subsequent positive
147 COVID-19 PCR or antigen results beyond their initial confirmatory test.

148 **Chest CT findings.**

149 Review of the chest CTs demonstrated four participants with mild apical scarring and/or reticulation
150 suggesting mild pulmonary fibrosis, one of which demonstrated a bulla in the right lower lobe. The
151 remainder of the scans were normal except for incidental findings likely not attributable to prior COVID-19
152 infection (e.g., calcified granulomas) as detailed in **Supplemental Table 1**. These findings are consistent
153 with prior studies demonstrating relatively a relatively low rate of clinically significant fibrotic lung disease
154 detectable by CT in patients with recent SARS-CoV-2 infection⁵⁸.

155

156 **[¹⁸F]F-AraG PET/CT imaging.**

157 [¹⁸F]F-AraG is a novel PET imaging agent developed for the purpose of assessing T cell activation and
158 cycling. It is an analog of arabinosyl guanine (AraG), an FDA-approved chemotherapy drug (nelarabine)
159 used for treatment of refractory malignancies of the T cell lineage⁵⁹. [¹⁸F]F-AraG can be phosphorylated by
160 cytoplasmic deoxycytidine kinase (dCK) and deoxyguanosine kinase (dGK), two enzymes upregulated in
161 activated T cells, which traps [¹⁸F]F-AraG intracellularly⁶⁰. The selective uptake of [¹⁸F]F-AraG by activated
162 T cells has been confirmed *in vivo* using murine models^{55,61}. [¹⁸F]F-AraG has been shown to be safe with
163 no major adverse events in the context of healthy volunteers, metastatic cancer, and other immune
164 deficiencies⁵⁵⁻⁵⁷.

165

166 [¹⁸F]F-AraG was prepared in a two-step method using a modified, previously reported procedure⁵⁹. [¹⁸F]F-
167 AraG was administered intravenously (166.5-185 MBq) followed by PET/CT (Siemens Biograph Vision) for
168 convalescent COVID-19 participants and without Long COVID symptoms and (299.7-329.3 MBq) followed
169 by PET/MRI (GE SIGNA) for pre-pandemic controls. Whole-body imaging was carried out over an interval
170 approximately 50 minutes post injection, covering regions from vertex to mid-thigh. Regions of interest
171 were drawn around various tissues using isometric 3-dimensional sphere depending on the anatomical
172 structure and the maximum and mean standardized uptake values (SUVmax and SUVmean) were

173 determined. SUVs are a function of the concentration of radioactivity within a ROI, the administered
174 activity, participant weight as a surrogate for volume, and uptake time⁶², allowing cross-participant
175 comparisons of PET activity. Overall, the tracer was well-tolerated, with no serious adverse events reported
176 during and/or following tracer injection and PET/CT imaging. CT was chosen for anatomical localization
177 and PET attenuation correction to provide information on lung parenchymal and structural pathology
178 following COVID infection.

179

180 **Increased [¹⁸F]F-AraG tissue uptake in post-acute COVID participants compared to pre-pandemic**
181 **controls.**

182 As shown in **Figs 1 & 2**, significantly higher SUVmax and SUVmean values were observed across a
183 variety of anatomic regions and tissue types in post-acute COVID participants compared with uninfected
184 controls using two-tailed Kruskal-Wallis tests adjusting for false discovery rates within specific tissue
185 regions (e.g., lymphoid tissues, glandular tissue, vascular, spinal cord, etc.). Maximum Intensity Projections
186 (MIP) of PET data from all post-acute COVID and pre-pandemic control participants are shown in
187 **Supplemental Fig 1**. Although [¹⁸F]F-AraG uptake was low overall in brain and spinal cord tissues (*i.e.*,
188 SUVmax and SUVmean <1), significantly higher SUVmax and SUVmean were identified in the thoracic
189 spinal cord and cauda equina (at the level of the fourth lumbar vertebra) and higher SUVmean was
190 identified in the brain stem (pons) as in **Fig 2**. The CNS choroid plexus is known to express high levels of
191 ACE-2, but this region had high background uptake and there were no differences between post-acute
192 COVID cases and pre-pandemic controls. Significantly higher levels of [¹⁸F]F-AraG uptake (SUVmax and
193 SUVmean) were also observed in the aortic arch, pulmonary artery and lower lung lobes compared with
194 pre-pandemic controls. Significant increases in [¹⁸F]F-AraG uptake were observed in nasal turbinates
195 (SUVmax and SUVmean), hilar lymph node regions (right-sided; SUVmax), proximal colon wall (SUVmax),
196 rectal wall (SUVmax and SUVmean), lumbar (SUVmax) and iliac crest (SUVmax and SUVmean) bone
197 marrow and pharyngeal tonsils (SUVmax). Although not achieving statistical significance, increased tracer
198 uptake was observed in parotid glands and right heart ventral wall in post-acute COVID participants
199 compared to pre-pandemic controls (**Fig 2**). Uptake in the liver (a metabolic and excretory organ for

200 [18F]F-AraG), abdominal adipose tissue, and quadriceps muscles were similar across all participants. No
201 significant differences in SUV were observed in testes, penile tissue, prostate, or uterine tissue, although
202 sample size was limited for these comparisons (**Supplemental Fig 2**).

203

204 **Sex differences in [¹⁸F]F-AraG tissue uptake.**

205 [¹⁸F]F-AraG uptake grouped by male and female sex is shown in **Supplemental Fig 3**. Although statistical
206 power was limited in these four-way comparison between male and female case and control participants,
207 male participants had trends toward higher tracer uptake in some tissues (pharyngeal tonsils, rectal wall)
208 and significantly higher uptake in hilar ROIs compared to female participants (**Supplemental Fig 3**).

209

210 **Impact of time between acute COVID-19 and PET imaging on biodistribution of [¹⁸F]F-AraG.**

211 We performed imaging over a span of nearly two and a half years following COVID-19 symptom onset to
212 determine the duration of T cell activation states in tissues. **Fig 3a** shows [¹⁸F]F-AraG SUVmax for tissues
213 of interest stratified by timing of PET imaging before or after 90 days following initial COVID-19 symptom
214 onset. We observed modestly decreased uptake in spinal cord and colon/rectal wall ROIs in participants
215 imaged beyond 90 days following COVID-19 symptom onset, but SUVs in these later-imaged individuals
216 remained significantly elevated compared to pre-pandemic controls, with the exception of the right colon
217 wall. When stratified by time since initial COVID-19 symptom onset, [¹⁸F]F-AraG uptake in the right
218 ventricle wall was significantly higher in post-acute COVID participants compared with pre-pandemic
219 controls (**Fig 3a**). Of note, no significant correlations between [¹⁸F]F-AraG uptake in any tissue ROI and
220 time from initial infection to PET imaging in those imaged beyond 90 days were observed (all P>0.05 by
221 two-tailed Spearman tests).

222

223 **Long COVID symptoms are associated with higher [¹⁸F]F-AraG uptake in some tissues.**

224 To determine the association between T cell activation and Long COVID-19 symptoms, we compared post-
225 acute COVID participants with (N=18) and without (N=6) Long COVID symptoms at the time of PET
226 imaging. Participants with Long COVID symptoms were generally highly symptomatic with a median 5.5

227 symptoms reported at the time of imaging. We observed modestly higher uptake in spinal cord, hilar lymph
228 nodes and colon/rectal wall in participants with Long COVID symptoms (**Fig 3b**). To assess relationships
229 between Long COVID symptoms and T cell activity, SUVs in various tissue ROIs were first compared
230 between participants with >5 Long COVID symptoms (N=12) reported at the time of PET imaging, <5 Long
231 COVID symptoms (N=6) and pre-pandemic controls (N=6). SUVmax levels for each group are shown in
232 **Supplementary Fig 4**.

233

234 **Association between Long COVID symptom phenotypes and [¹⁸F]F-AraG tissue uptake.**

235 Next, we investigated whether specific Long COVID symptom phenotypes in our cohort correlated with
236 mean SUVmax uptake in tissue ROIs. Participants with pulmonary Long COVID symptoms (e.g., cough,
237 shortness of breath, dyspnea) present at time of imaging had higher SUVmax values in lower lung and hilar
238 ROIs compared to those without pulmonary symptoms (**Figure 3c**). However, direct relationships between
239 other symptom phenotypes (neurocognitive, gastrointestinal, constitutional/fatigue) and tissue uptake in
240 related tissues were not observed. For example, we found similarly increased signal in those with and
241 without specific symptoms phenotypes and pre-pandemic volunteers (representative data shown in **Figure**
242 **3d,e**).

243

244 **Impact of SARS-CoV-2 vaccination on biodistribution of [¹⁸F]F-AraG.**

245 Since SARS-CoV-2 or other vaccination may impact T cell activation, we analyzed [¹⁸F]F-AraG uptake in
246 participants grouped by receipt of a SARS-CoV-2 vaccine dose greater than or less than 180 days prior to
247 PET imaging. Timing from most recent vaccination to imaging appeared to have little effect on [¹⁸F]F-AraG
248 uptake across most tissues, with the exception of modestly lower gut wall tracer uptake in those whose last
249 dose of SARS-CoV-2 vaccine was >180 days prior to imaging (**Supplemental Figure 5a**). Of note,
250 although our protocol excluded those who had received any vaccine within 4 weeks of imaging, one
251 participant received a SARS-CoV-2 mRNA booster 6 days prior to imaging without informing the study
252 team. Post-hoc investigation of this participant's PET/CT images revealed similar [¹⁸F]F-AraG uptake

253 across all tissue ROIs to other post-acute COVID participants (*i.e.*, was in the middle range of observed
254 SUVmax) and without marked uptake in the deltoid muscle injection site.

255

256 **SARS-CoV-2 antibody responses.**

257 SARS-CoV-2 nucleocapsid IgG levels were measured from plasma obtained at the time of PET imaging to
258 provide information about potential recent reinfection that may have influenced our findings. Ten of 24 post-
259 acute COVID participants had no detectable nucleocapsid antibody detection at the time of PET imaging
260 (Signal to Cutoff [SC] ratio <1; **Table 1**). Overall, among the post-acute COVID group, the presence of a
261 detectable nucleocapsid IgG response did not have a major influence on [¹⁸F]F-AraG uptake across ROIs
262 compared to post-acute COVID (SUVmax values are shown in **Supplemental Figure 5b**). Both those with
263 and without detectable nucleocapsid IgG responses had significantly higher tracer uptake than control
264 volunteers in major ROIs of interest.

265

266 **Circulating markers of inflammation and immune activation correlate with [¹⁸F]F-AraG PET uptake** 267 **in some tissues.**

268 To identify associations between [¹⁸F]F-AraG PET imaging and levels of systemic inflammation and
269 immune activation, we assessed circulating protein biomarkers in the plasma of participants just prior to the
270 time of PET imaging using the Olink Explore 384 Inflammation panel. Proteomic data were available for 19
271 of 24 participants. Several differentially expressed gene products were observed in participants grouped by
272 time since initial COVID-19 symptom onset, Long COVID symptom count (proteomic data were only
273 available on two cases without any Long COVID symptoms), and higher PET tracer uptake in various ROIs
274 of interest. Although these did not achieve individual significance after conservative adjustments for
275 multiple comparisons in this small cohort, some interesting patterns were observed. Clustered heatmaps
276 including modules of proteins defined by non-hierarchical k-means clustering by time from initial COVID-19
277 symptom onset to PET imaging > or ≤90 days, the presence of >5 or ≤5 Long COVID symptoms at the
278 time of imaging, and high or low tracer [¹⁸F]F-AraG uptake across various anatomical ROIs are shown in
279 **Figure 4**. High and low [¹⁸F]F-AraG uptake was defined as participants with ROI SUVmax values one to

280 three standard deviations above the mean SUVmax value of the pre-pandemic-19 control subjects
281 (standard deviations cutoffs were based on overall variation within case and control SUVmax values to
282 define clusters of individuals with [¹⁸F]F-AraG uptake higher than the control population). Time from initial
283 COVID-19 symptom onset to imaging appeared to have a modest impact on differential levels of circulating
284 inflammation markers, with different clusters of differentially expressed gene products in those imaged
285 either <60 or >60 days. In participants reporting >5 Long COVID symptoms at the time of imaging, we
286 observed higher levels of inflammatory markers, including proteins involved in immune responses,
287 chemokine signaling, inflammation responses, and nervous system development (e.g. increased
288 expression of proteins such as TGFb1, TANKIL7, TANK, IL20RA, CCL13, SPRY2, PRKAB1, BCR, TAF2).
289 We also observed clusters of gene products upregulated in participants with high levels of lower lung
290 parenchymal [¹⁸F]F-AraG uptake including those involved in inflammatory response, cell signaling fibroblast
291 transformation, response to mitogenic stimulation among others (e.g. differential increased expression of
292 IL-7, CXCL3, CD40, EGF, TRNSF14, TIMP3, CRKI, CXCL3, BKAP2, PDGFB). High parotid gland [¹⁸F]F-
293 AraG uptake was related to differential expression of gene products involved with matrix metalloprotease,
294 response to bacterial infection, vascular development and coagulation and hypoxic stress as in **Figure 4**.
295 Differential protein expression was more subtle in post-acute COVID participants with high uptake in other
296 tissue ROIs (bone marrow, pharyngeal tonsils, gut wall, nasal turbinates) as in **Supplemental Fig 6**,
297 although there was some evidence for increased differential expression of gene products in post-acute
298 COVID participants with high uptake in the spinal cord which, interestingly, included gene products
299 associated with Alzheimer disease (AGER)⁶³, myogenesis/myelination (Cdon⁶⁴), and oxidative stress and
300 monocyte adhesion (MEGF10) protein also involved in mediation of apoptotic cell phagocytosis and
301 amyloid-beta peptide brain uptake and various myopathies⁶⁵⁻⁶⁷.

302

303 **High-dimensional flow cytometric evaluation of peripheral blood and gut-derived mononuclear cell** 304 **phenotypes.**

305 A multi-dimensional spectral flow cytometry panel that characterized CD4+ and CD8+ T cell, NK cell, and B
306 cell phenotypes, including markers of activation, naive/memory phenotypes, regulatory function and

307 immune checkpoint/exhaustion was performed on peripheral blood mononuclear cells (PBMC) from 16
308 participants who had sufficient PBMCs available from timepoints around the time of PET imaging and from
309 gut tissue from 5 participants who underwent colorectal biopsies. Overall, we observed higher frequencies
310 of effector memory CD8+ and CD4+ T cells in gut tissue versus peripheral blood, but similar frequencies of
311 both CD8+ and CD4+ lymphocytes expressing activation markers CD38/HLA-DR and immune checkpoint
312 (PD-1). In addition, there were no significant correlations between PET tissue uptake levels, Long COVID
313 symptoms counts, timing of infection or vaccination or specific Long COVID symptom phenotypes with
314 CD4+ and CD8+ T cell phenotypes (**Supplemental Figures 7 & 8**) or with early and late B cell memory
315 phenotypes.

316

317 **Intestinal biopsies in a subset of post-acute COVID participants show evidence of persistent SARS-**
318 **CoV-2 spike RNA in rectal tissue.**

319 Prior studies suggest that SARS-CoV-2 RNA or proteins may be detected in the gut or shed in stool for
320 several months following acute COVID-19^{34,68}. Given the higher [¹⁸F]F-AraG uptake in proximal colon and
321 rectal wall across many post-acute COVID participants compared with pre-pandemic controls, it is possible
322 that viral persistence may be driving, at least in part, increased activated T cell migration to gastrointestinal
323 tissues. We explored the potential for viral persistence by collecting rectosigmoid tissue by flexible
324 sigmoidoscopy in a subset of 5 participants who had undergone PET imaging ranging from 158 to 676
325 days following initial infection (**Table 1**). Four of 5 participants had biopsies within 63 days of PET imaging;
326 one participant (participant 14) was biopsied 182 days after imaging. All participants reported at least one
327 Long COVID symptoms at the time of biopsy. None had received a SARS-CoV-2 vaccine dose in the prior
328 month. None reported any history, symptoms, or testing suggestive of SARS-CoV-2 reinfection, and three
329 of the five participants (participants 15, 16 and 18) who underwent rectosigmoid biopsy had no detectable
330 SARS-CoV-2 nucleocapsid IgG detected within a short time frame of tissue collection (SC ratios <1 at the
331 time of PET imaging) suggesting no recent SARS-CoV-2 re-infection.

332

333 SARS-CoV-2 RNA was readily detected in multiple cells from all three tissue regions surveyed from all but
334 one individual (participant 15) who had rare RNA+ cells detected in only one of three gut tissue regions 645
335 days following initial infection. However, another participant biopsied at a similar interval (participant 19)
336 had higher spike RNA levels in gut tissue. Nearly all RNA was detected in cells in the lamina propria,
337 without an epithelial signal (**Figure 6**). A small percentage of RNA+ cells expressed CD68, a macrophage
338 monocyte lineage marker, but many RNA+ cells did not express CD68 and virtually none expressed CD3.
339 [¹⁸F]F-AraG SUVmax values in proximal colon and rectal tissue in the post-acute COVID participants who
340 underwent biopsy were at least 3 standard deviation above the mean SUVmax of pre-pandemic controls
341 (1.86 vs 0.95 and 1.5 vs 0.9, respectively). PCR was also performed on RNA isolated from bulk rectal
342 tissue lysates (separate biopsy from FFPE tissue used above) targeting the N1, N2, Envelope (E) and
343 RNA-dependent RNA polymerase (RdRp) regions of SARS-CoV-2. No RNA was detected in any
344 participant.

345

346 **DISCUSSION**

347 In this first-in-human T cell activation PET imaging study of individuals in the post-acute phase of SARS-
348 CoV-2 infection, we found that SARS-CoV-2 infection may result in persistent T cell activation in a variety
349 of body tissues. In some individuals, this activity may persist for years following initial symptom onset and
350 associate with systemic changes in immune activation as well as the presence of Long COVID symptoms.
351 Finally, we found that SARS-CoV-2 persistence in gut tissue may contribute to these processes. Taken
352 together, these observations suggest that even remote, clinically mild SARS-CoV-2 infection could have
353 long-term consequences on tissue-based immune homeostasis. Our findings provide additional evidence
354 to support the role of tissue-based immune activation and viral persistence as contributors to post-acute
355 sequelae of SARS-CoV-2 infection, including Long COVID.

356

357 This study adds substantially to the existing literature on tissue-based immune responses in the post-acute
358 phase of SARS-CoV-2 infection. Whereas traditional positron emission tomography (PET)-based imaging
359 using radio-labeled glucose (FDG) as a marker of tissue inflammation has been applied to the study of

360 acute and, to a lesser extent, post-acute COVID-19⁴⁶⁻⁵², this method is non-specific because FDG is taken
361 up by any metabolically active tissue. One pilot PET study using a CD8-specific minibody radiotracer
362 provides some evidence that T cells traffic to tissues such as bone marrow following acute infection and
363 remain up to 4 months thereafter⁵³, <https://paperpile.com/c/E2nfg2/yPPn> but the relationship between T cell
364 activation state, clinical symptoms, and viral persistence in the post-acute phase and over the years
365 following COVID-19 was not addressed.

366

367 We found that [¹⁸F]F-AraG uptake was significantly higher in post-acute COVID participants compared to
368 pre-pandemic controls in many anatomical regions, including brain stem, spinal cord, bone marrow,
369 nasopharyngeal and hilar lymphoid tissue, cardiopulmonary vasculature, lung parenchyma, and gut wall.
370 These observations were identified up to 2.5 years following initial COVID-19 symptom onset, in the
371 absence of confirmed or suspected re-infection. Although [¹⁸F]F-AraG uptake in some tissues (spinal cord,
372 colon/rectal wall) appeared to decline with time, the levels of uptake often remained elevated above those
373 measured in pre-pandemic healthy control volunteers. These data significantly extend prior observations of
374 a durable and dysfunctional cellular immune response to SARS-CoV-2^{13,21,22,69} and suggest that SARS-
375 CoV-2 infection could result in a new immunologic steady state in the years following COVID-19.

376 In this study, T cell activation in some tissues (spinal cord and gut wall) tended to be higher in participants
377 reporting Long COVID symptoms of any type compared to both pre-pandemic controls and those post-
378 COVID with complete recovery. Increased lung and hilar [¹⁸F]F-AraG uptake was identified in those with
379 persistent pulmonary symptoms, suggesting a potential link between ongoing aberrant tissue immune
380 responses and long-term clinical symptoms. It is now well-established that at least a subset of individuals
381 with Long COVID exhibit prolonged systemic immune activation following SARS-CoV-2 infection^{7,10-21}. This
382 study provides evidence for ongoing immune responses in tissues, a potentially important source of
383 inflammation observed in peripheral blood. Furthermore, as Long COVID is increasingly being framed as
384 having potential neurological underpinnings, it is possible that spinal cord and brainstem [¹⁸F]F-AraG
385 uptake observed in our study may represent T cell trafficking to CNS tissues with residual viral
386 components. This is consistent with a prior autopsy study, which demonstrated the presence of SARS-

387 CoV-2 spike RNA and protein in the spinal cord and basal ganglia in two individuals that died during the
388 post-acute phase following COVID-19 (65 and 230 days post infection)³⁸.

389 We identified cellular SARS-CoV-2 RNA in rectosigmoid lamina propria tissue *in situ* in participants studied
390 for up to two years following initial infection. This observation extends prior reports limited to 4-6 months
391 post-COVID^{34,35,38}. We employed several measures to guarantee virus-specific RNA *in situ* hybridization,
392 including use of pre-pandemic control tissue on each slide to minimize technique differences or batch
393 testing effects and repeated RNA staining in contiguous slices to verify consistency of location of the viral
394 RNA signal. PCR from bulk tissue lysates was unsuccessful (and hence viral sequencing could not be
395 performed), but SARS-CoV-2 RNAscope methods have been shown to be more sensitive in gut tissues in
396 prior analyses³⁵. As [¹⁸F]F-AraG uptake was observed in this anatomical region in nearly all participants,
397 this finding suggests that virus persistence might contribute to the sustained levels of T cell activation
398 observed in our participants. Because all of the participants who underwent gut biopsy met Long COVID
399 criteria at the time of the procedure, it is difficult to draw concrete conclusions regarding the impact of gut
400 viral persistence on Long COVID symptoms or [¹⁸F]F-AraG uptake. Further investigation, including
401 assessment of fully recovered comparators, will be needed to determine whether persistence is clearly
402 associated with Long COVID or occurs even in those who are believed to have fully recovered.

403 A key question for the field is in which cell type(s) SARS-CoV-2 might persist. We observed that some, but
404 not a majority, of intracellular Spike RNA was associated with regions of CD68+ immune cell infiltrates
405 (although not only within CD68+ cells), which likely represent tissue-resident macrophages within the
406 lamina propria. ACE-2 expression in the lamina propria and on myeloid immune cells has been previously
407 shown to be low, and we observed little-to-no RNA in the gut epithelium, where ACE-2 expression is
408 higher^{34,70}. These data suggest that macrophages or other immune cells may be acquiring virus or viral
409 contents either through phagocytosis of other infected cells or through viral-immune complexes as
410 previously proposed⁷¹. Viral transcriptional activity may lead to innate immune sensing and downstream,
411 tissue-based inflammation that could lead to infiltration of other immune cells (e.g., T cells), tissue damage
412 and systemic inflammation even without replication or *de novo* infection.

413 Collectively, our data are consistent with a model in which persistence of SARS-CoV-2 results in chronic
414 tissue-based inflammation, T cell activation and perhaps Long COVID. However, we acknowledge that this
415 story of persistent immune activation and viral antigen in Long COVID is still developing. For example, we
416 did not observe direct correlations between other Long COVID organ system-based phenotypes, such as
417 gastrointestinal, neurologic, cardiac, and fatigue, and [¹⁸F]F-AraG uptake in anatomically related tissues.
418 We also did not observe significant differences in overall T cell phenotypes in peripheral blood (memory
419 subset, activation, exhaustion) between those with and without Long COVID or between participants with
420 high or low [¹⁸F]F-AraG uptake in tissue ROIs in this cohort, in contrast to our previous observations in
421 larger cohorts.^{13,21} Our negative findings may be due to a smaller cohort or the well-known challenges in
422 defining and measuring Long COVID⁵⁴. Larger studies will be needed to further define the relationships
423 between immune responses at the tissue level and specific Long COVID endotypes.

424 This study has several limitations, many inherent to PET imaging protocols. First, whereas the relatively
425 small sample size limited power in certain tissue and immune correlative studies, we were powered to
426 examine primary imaging endpoints (PET tracer uptake across post-acute COVID-19 cases and pre-
427 pandemic controls). Second, because of the rapidly evolving pandemic, including intermittent variant
428 waves, the recognition of Long COVID as a relevant clinical entity, and the rapid but inconsistent rollout of
429 SARS-CoV-2 vaccines, we were required to adapt the protocol over time. This resulted in a shift from
430 imaging participants closer to the time of initial SARS-CoV-2 symptom onset to prioritizing those with Long
431 COVID symptoms months to years after COVID-19. As a result, those enrolled earlier in the pandemic
432 tended to be imaged closer to the time of acute infection and were not selectively enrolled based upon the
433 presence of Long COVID symptoms. Third, we relied mainly on pre-pandemic controls in healthy
434 volunteers who were imaged in [¹⁸F]F-AraG protocols using similar PET acquisition strategies and timing
435 from tracer injection to image acquisition. Pre-pandemic control volunteers were imaged using PET/MRI
436 and, on average, received a higher dose of [¹⁸F]F-AraG, but SUV were used as comparison which take into
437 account tracer injection dose, participant size and isotope decay rates and sensitivity of the PET-CT and
438 PET/MRI scanners are similar. In addition, we would expect any confounding from this higher tracer dose
439 to lead to higher uptake in the pre-pandemic controls compared to post-acute COVID participants. We

440 note that it has become extraordinarily difficult to enroll contemporary, never-infected control participants in
441 research studies now that most of the population has been either formally diagnosed or subclinically
442 infected with SARS-CoV-2⁷². Finally, although mitigated by frequent assessments in the parent LIINC
443 cohort, it remains possible that some participants may have had asymptomatic or undetected reinfections
444 between the initial COVID-19 symptom onset and their rectosigmoidoscopy or [¹⁸F]F-AraG PET imaging.

445 In summary, our results provide provocative evidence of long-term immune system activation in several
446 specific tissues following SARS-CoV-2 infection, including in those experiencing Long COVID symptoms.
447 We identified that SARS-CoV-2 persistence is one potential driver of this ongoing activated immune state,
448 and we show that SARS-CoV-2 RNA may persist in gut tissue for nearly 2 years after the initial infection.
449 Overall, these observations challenge the paradigm that COVID-19 is a transient acute viral infection and
450 provide evidence for T cell activation and viral persistence in tissues well beyond the initial illness.

451

452

453 **METHODS**

454 **Participants.** Study volunteers were participants in the University of California, San Francisco-based Long-
455 term Impact of Infection with Novel Coronavirus (LIINC) study (NCT04362150⁵⁴) and additionally opted into
456 the imaging protocol (NCT04815096). Study procedures for the parent study have been described in detail
457 elsewhere⁵⁴. Briefly, adults with SARS-CoV-2 infection confirmed on nucleic acid-based or antigen-based
458 testing were enrolled 14 days or longer following initial COVID-19 symptom onset and assessed
459 prospectively approximately every 4 months following initial symptom onset. Participants were excluded
460 from the imaging protocol if they had a history of excessive radiation, underwent a prior research study
461 involving radiation within 1 year of enrollment, were pregnant or breastfeeding, had screening absolute
462 neutrophil count <1000 cells/mm³, platelet count <75,000 cells/mm³, hemoglobin <8 g/dL, estimated
463 creatinine clearance <60 mL/min, aspartate aminotransferase >3x ULN units/L, alanine aminotransferase
464 >3x ULN units/L, had recent use of medication including guanosine or cysteine analogs, had known SARS-
465 CoV-2 nasopharyngeal shedding within 5 days of scan, had a SARS-CoV-2 vaccine within 4 weeks of
466 scan, or had a prior history of immunoproliferative or autoimmune disease.

467

468 **Questionnaire-based measurements.** At the first visit, participants completed an interviewer-
469 administered questionnaire that assessed demographics, medical history, and SARS-CoV-2 infection,
470 vaccination, and treatment history. At all visits, participants completed additional interview-administered
471 questionnaires that queried the presence and severity of any symptoms that were new or worsened since
472 the initial SARS-CoV-2 diagnosis, quality of life, interim medical diagnoses, and interim treatments and
473 vaccinations. Symptoms that predated SARS-CoV-2 infection and were unchanged were not considered to
474 represent Long COVID. Concurrent with PET imaging, detailed histories were obtained including
475 symptoms, prior or subsequent SARS-CoV-2 PCR or antigen testing, and clinical symptoms potentially
476 related to SARS-CoV-2 re-infection.

477

478 **[¹⁸F]F-AraG imaging.** Following study entry and eligibility screening, participants were administered
479 intravenously [¹⁸F]F-AraG (166.5-185 MBq) and PET/CT whole-body imaging was carried out for 20 min at
480 approximately 50 min post injection. [¹⁸F]F-AraG was prepared as documented elsewhere (15). Images
481 were taken from the top of head to mid thighs. Participants were observed at imaging visit or reported by
482 participants after [¹⁸F]F-AraG imaging per phone calls by study coordinators 2, 7, and 30 days after
483 imaging. Routine urinalysis was performed 7-14 days after imaging to ensure proper excretion of [¹⁸F]F-
484 AraG.

485

486 **PET and CT image analysis.** Standardized uptake values (SUV) in various tissue regions of interest
487 (ROI) from PET/CT data were determined using the OsiriX DICOM viewer software package (Pixmeo;
488 Bernex Switzerland). ROI determination was performed in complex structures such as brain sections, heart
489 wall, spleen, and gut wall using two-dimensional isometric ROIs. For simpler structures such as the spinal
490 cord at various levels, bone marrow, and whole lymph nodes, three-dimensional spherical ROIs were used.
491 For axillary and inguinal lymph node ROI selection, the most prominent nodes on both the right and left
492 side were included and SUV values averaged. ROI selection was performed independently by two
493 individuals blinded to the study group following ROI selection upon a subcohort and comparison to ensure

494 consistency across reviewers. Two- and three-dimensional PET or PET/CT images were generated in
495 OsiriX keeping window levels consistent between participants. SUVs from participants reporting PASC
496 symptoms were compared with six pre-pandemic PET/MRI controls and, in two post-pandemic
497 (contemporary) PET/CT controls. ROI selection on bowel tissue was challenging as we observed
498 intermittent intraluminal collection of tracer, which was highly anatomically variable across all participants.
499 As intraluminal signal does not represent specific tissue tracer uptake, ROI selection was performed in gut
500 wall tissue only in areas without clear contiguous intraluminal signal. As a result, ROI selection was not
501 possible in 3 and 5 post-acute COVID participants for proximal colon and rectal wall ROIs, respectively,
502 and 3 pre-pandemic control participants for proximal colon. All PET images and CT images of the chest
503 were further reviewed independently by two dual board-certified radiologists and nuclear medicine
504 physicians (R.R.F. and Y.W.). Qualitative abnormalities were reviewed and tabulated.

505

506 ***Circulating Markers of Inflammation.*** A Protein Extension Assay (PEA) using the Olink EXPLORE
507 Inflammation panel from plasma samples was performed in post-acute COVID imaging participants to
508 characterize 365 unique plasma proteins associated with inflammation and immune signaling. Briefly, PEA
509 involves dual-recognition of two matched antibodies labeled with unique DNA oligonucleotides that
510 simultaneously bind to specific target proteins. The simultaneous antibody binding leads to hybridization of
511 unique DNA oligonucleotides that serve as templates for polymerase-dependent extension (DNA
512 barcoding) followed by PCR amplification and NovaSeq (Illumina) DNA sequencing. Clustered heatmaps
513 were generated by the UCSF Gladstone Bioinformatics Core using the R package HOPACH to find the
514 best cluster number. Gene product expression values were log-transformed and centered using the
515 average expression value for each protein. Gene products were then clustered by running the Kmeans
516 algorithm using the best cluster number K found, and the results were plotted using the pheatmap package
517 as modules. Standard deviation (SD) cutoff levels between those with higher and lower [¹⁸F]F-AraG uptake
518 for each tissue were decided based on variance of SUVmax values of uninfected controls, with higher
519 variance allowing for one or more SDs above the mean to qualify as “higher” uptake.

520

521 **SARS-CoV-2 qPCR on Rectal Biopsies, PCR and *In situ* hybridization of SARS-CoV-2 Spike RNA.**
522 Rectal wall tissue samples were obtained via flexible sigmoidoscopy with tissue being fixed in fresh
523 paraformaldehyde (PFA) followed by Paraffin embedding approximately 48 hours after fixation or were
524 cryopreserved at -180°C in Fetal Bovine Serum (FBS) and 20% Dimethyl sulfoxide (DMSO) as described⁷³.
525 A minimum of three formalin-fixed paraffin embedded (FFPE) rectosigmoid tissue biopsies from each
526 participant were used for RNAscope experiments, along with comparative uninfected tissue, were mounted
527 on the same slide to control for batch effects from processing, staining, microscopy and image analysis.
528 Experiments were performed at least twice on contiguous sections to verify signal over non-specific
529 staining or autofluorescence. Contiguous sections underwent hematoxylin and eosin staining and
530 immunohistochemical visualization of CD3 and CD68 expression in order to localize viral RNA signals with
531 anatomical tissue regions and immune cell types of interest. Quantitative PCR assays were performed
532 using Integrated DNA Technology's (IDT) SARS-CoV-2 RUO qPCR Primer & Probe Kits for N1, N2, E, and
533 RDRP detection (catalog no. 10006713, 10006804, 10006805, and 10006806). Positive controls consisted
534 of fragments of human RPP30 and SARS-CoV-2 isolate Wuhan-Hu-1 (GenBank: NC_045512.2) provided
535 in each IDT kit. Quantitative PCR was performed with TaqPath™ 1-Step RT-qPCR Master Mix with the
536 following conditions: 95°C 2 min, 95°C 3 sec, 55°C 30 sec using the StepOnePlus™ Real-Time PCR
537 System. SARS-Cov-2 RNA was considered detectable for cycle threshold (ct) values <40. Positive and
538 non-template controls were run for all samples tested.

539
540 The manual RNAscope 2.5 HD assay (Advanced Cell Diagnostics; catalog no. 322310) was used to
541 identify SARS-CoV-2 Spike RNA *in situ*. Paraffin-embedded tissue blocks were sectioned at 5 µm,
542 mounted onto SuperFrost Plus slides, and stored at 4°C prior to staining. Slides were baked in a dry-air
543 oven at 60°C for 1 h, then deparaffinized in 100% Xylene (5 min) twice and washed in 95% ethanol (3 min)
544 twice, 80% ethanol (3 min) once, and dH₂O (1 min) twice, all at room temperature. To prevent drying, 3-4
545 drops of TBS were placed on each tissue section. A hydrophobic barrier was then drawn around each
546 tissue section and allowed to dry for 10 min. To block endogenous peroxidase slides were then pretreated
547 with hydrogen peroxide for 10 mins at room temperature followed by washing with dH₂O. Next, heat-

548 induced epitope retrieval was performed with Target Retrieval Reagent (ACDBio) and incubated at 100°C
549 for 15 minutes followed by rinsing with dH₂O. Protease digestion was accomplished by treatment with
550 Protease Plus solution (ACDBio) for 30 minutes at 40°C followed by dH₂O wash. Hybridization was
551 performed with RNAscope™ probe-V-nCoV2019-S (catalog no. 848561-C3, Advanced Cell Diagnostics) at
552 40°C for 2 h at a 1:50 dilution. Following hybridization, 3 amplification steps were carried out as indicated in
553 the original protocol. Slides were then incubated with HRP-C3 at room temperature for 15 min, TSA Vivid
554 Fluorophore 520 for 40°C for 30 min, and HRP blocker at 40°C for 15 min. Finally, slides were
555 counterstained with DAPI, washed in PBS, and cover-slipped using Prolong Diamond Mounting Media.

556

557 Images were captured using the Zeiss AxioObserver Z1 (RNAscope) or the Leica Aperio VERSA
558 (chromogenic staining on contiguous tissue sections). FFPE rectal tissue from a pre-pandemic control
559 participant was mounted on each participant slide to control for any staining or imaging technique
560 differences. Only linear brightness and contrast adjustments were made to image files and all adjustments
561 were applied identically for each image.

562

563 **Spectral Flow Cytometry.** PBMC or cells obtained from gut tissue following a previously published
564 collagenase disaggregation protocol⁷⁴ were Stained with the Cytex 25-plex kit (Cat# SKU R7-40002) with
565 the BioLegend antibodies (Cat#900004160), for Live-dead staining Zombie UV (Cat#423108) was used.
566 Cells were stained with titrated antibodies for 30 min at 25 degrees Celsius in a total volume of 130ul,
567 including the addition of Brilliant stain buffer plus (cat#566385). Cells were washed twice with FACS buffer
568 (PBS+10%FBS+1mM EDTA) before fixation with 1% PFA (in PBS). Cells were acquired on the 5L Cytex
569 Aurora the day after. We used Spectrflow beads to verify laser alignment and power consistency. The
570 forward and side scatter profiles were established using human PBMCs, similar to the test samples. Single
571 stained cellular reference controls were used to unmix the data according to the 25-plex Cytex acquisition
572 protocol, with unstained cells as an autofluorescence control. Unmixing errors were corrected by spillover
573 correction using OMIP-069 supplementary information as a guide. The Cytex analysis template was used

574 to replicate the gating strategy in FlowJo 10 as shown in **Supplemental Figures 9 & 10**. Data was
575 exported, and further analysis performed on GraphPad Prism.

576

577 **SARS-CoV-2 Nucleocapsid Antibody Testing.** Nucleocapsid IgG antibodies from post-acute COVID
578 participants from plasma tested at the time of PET imaging were measured using the Abbott Architect
579 i2000 two step Chemiluminescent microparticle immunoassay (CMIA). Signal to cutoff (S/C) ratios were
580 determined and samples were considered positive if the S/C ratio was above the assay-defined threshold
581 (S/C >1 were considered positive).

582

583 **Statistical analysis.** We used two-tailed, non-parametric Kruskal-Wallis tests using a Benjamini-Hochberg
584 adjustment for false discovery rates from multiple comparisons within specific tissue regions (e.g. lymphoid
585 tissues, glandular tissue, vascular, spinal cord, etc.) to compare ROI SUV data and flow cytometric data
586 across participants (adjusted P values being analogous to the Q value obtained from FPR adjustments).
587 Nonparametric tests were used given the assumption that SUV data may not be normally distributed
588 across comparator groups. Two-sided Spearman rank tests were performed to determine correlations
589 between continuous variables.

590

591 **Human subjects.** Participants provided written informed consent for both the parent study and the imaging
592 protocol. The study was approved by the UCSF Institutional Review Board and the UCSF Radiation Safety
593 Committee. ClinicalTrials.gov numbers: NCT04362150 and NCT04815096.

594

595

596 **FOOTNOTES**

597

598 **Acknowledgements**

599 We are grateful to the study participants and their medical providers. We acknowledge current and
600 former LIINC clinical study team members Tamara Abualhsan, Andrea Alvarez, Grace Anderson,
601 Khamal Anglin, Urania Argueta, Mireya Arreguin, Alexis Clark, Nicole DelCastillo, Emily Fehrman,
602 Halle Grebe, Heather Hartig, Yanel Hernandez, Beatrice Huang, Marian Kerbleski, Raushun
603 Kirtikar, Suzanna Kouzi, Megan Lew, James Lombardo, Monica Lopez, Michael Luna, Lynn Ngo,
604 Enrique Martinez Ortiz, Justin Romero, Ruth Diaz Sanchez, Matthew So, Celina Chang Song,
605 Alex Tang, Cassandra Thanh, Fatima Ticas, Leonel Torres, Brandon Tran, Daisy Valdivieso,
606 Deepshika Varma, Meghann Williams, and Andhy Zamora; and LIINC laboratory team members
607 Joanna Donatelli, Jill Hakim, Nikita Iyer, Owen Janson, and Keirstinne Turcios. We thank Jessica
608 Chen, Aidan Donovan, Carrie Forman, Rania Ibrahim, and Badri Viswanathan for assistance with
609 data entry and review. We thank the UCSF AIDS Specimen Bank for processing specimens and
610 maintaining the LIINC biospecimen repository. We are grateful to Elnaz Eilkhani for regulatory
611 support. We are also grateful for the contributions of additional LIINC leadership team members:
612 Bryan Greenhouse, Isabelle Rodriguez-Barraquer, and Rachel Rutishauser.

613

614 **Funding**

615 PET-imaging and peripheral blood immune testing was supported by a Merck Investigator Studies Program
616 Grant (to TJH). PET-imaging Gut biopsy collection and testing was supported by grants from the PolyBio
617 Research Foundation (to TJH, HV and MJP). This work was also supported by NIH/National Institute of
618 Allergy and Infectious Diseases grants (3R01AI141003-03S1, R01AI158013, K23AI157875, and
619 K24AI145806); the Zuckerberg San Francisco General Hospital Department of Medicine and Division of
620 HIV, Infectious Diseases, and Global Medicine.

621

622 **Conflicts of Interest**

623 MJP reports consulting fees for Gilead Sciences and AstraZeneca, outside the submitted work. TJH reports
624 consulting fees for Roche and Regeneron outside the submitted work.

625

626 **Author Contributions**

627 Study design: MJP, DR, RF, HV, JL, AG, TJH

628 Acquired funding: TJH, MJP, HV, SGD

629 Parent Cohort Design and Oversight: MJP, RH, MSD, PYH, JDK, JNM, SDG, TJH

630 Participant Recruitment and Clinical Data Collection: MJP, DR, KA, MA, WK, SEM, RH, MD, AR, MB, VT,
631 TJH

632 Data management and curation: SL, SAG, TD

633 Gut Tissue Collection: MD, AR, MS

634 Assay Design: DR, BL, BL, GS, ZGL, NK, TJH

635 Laboratory and Data Analysis: BHL, TMD, KA, SEM, GS, ZGL, NK, TJH

636 Image Analysis: DR, RF, YW, JL, KA, US, YS, TJH

637 Manuscript Writing: MJP, DR, RF, SGD, HV, TJH

638 Manuscript editing/reviewing: All authors

639

640

641 REFERENCES

- 642 1. Nalbandian A, Sehgal K, Gupta A, et al. Post-acute COVID-19 syndrome. *Nat Med* 2021;27(4):601-
643 615. DOI: 10.1038/s41591-021-01283-z.
- 644 2. Davis HE, McCorkell L, Vogel JM, Topol EJ. Long COVID: major findings, mechanisms and
645 recommendations. *Nat Rev Microbiol* 2023;21(3):133-146. DOI: 10.1038/s41579-022-00846-2.
- 646 3. Al-Aly Z, Xie Y, Bowe B. High-dimensional characterization of post-acute sequelae of COVID-19.
647 *Nature* 2021;594(7862):259-264. DOI: 10.1038/s41586-021-03553-9.
- 648 4. Centers for Disease Control and Prevention COVID Data Tracker. US Department of Health and
649 Human Services, CDC. (<https://covid.cdc.gov/covid-data-tracker>).
- 650 5. Robertson MM, Qasmieh SA, Kulkarni SG, et al. The Epidemiology of Long Coronavirus Disease in
651 US Adults. *Clin Infect Dis* 2023;76(9):1636-1645. DOI: 10.1093/cid/ciac961.
- 652 6. Peluso MJ, Deeks SG. Early clues regarding the pathogenesis of long-COVID. *Trends Immunol*
653 2022;43(4):268-270. DOI: 10.1016/j.it.2022.02.008.
- 654 7. Peluso MJ, Donatelli J, Henrich TJ. Long-term immunologic effects of SARS-CoV-2 infection:
655 leveraging translational research methodology to address emerging questions. *Transl Res* 2021.
656 DOI: 10.1016/j.trsl.2021.11.006.
- 657 8. Del Valle DM, Kim-Schulze S, Huang HH, et al. An inflammatory cytokine signature predicts
658 COVID-19 severity and survival. *Nat Med* 2020;26(10):1636-1643. DOI: 10.1038/s41591-020-1051-
659 9.
- 660 9. Lucas C, Wong P, Klein J, et al. Longitudinal analyses reveal immunological misfiring in severe
661 COVID-19. *Nature* 2020;584(7821):463-469. DOI: 10.1038/s41586-020-2588-y.
- 662 10. Su Y, Yuan D, Chen DG, et al. Multiple early factors anticipate post-acute COVID-19 sequelae. *Cell*
663 2022;185(5):881-895 e20. DOI: 10.1016/j.cell.2022.01.014.
- 664 11. Durstenfeld MS, Peluso MJ, Kelly JD, et al. Role of antibodies, inflammatory markers, and
665 echocardiographic findings in postacute cardiopulmonary symptoms after SARS-CoV-2 infection.
666 *JCI Insight* 2022;7(10). DOI: 10.1172/jci.insight.157053.
- 667 12. Giron LB, Peluso MJ, Ding J, et al. Markers of fungal translocation are elevated during post-acute
668 sequelae of SARS-CoV-2 and induce NF-kappaB signaling. *JCI Insight* 2022;7(18). DOI:
669 10.1172/jci.insight.164813.
- 670 13. Peluso MJ, Deitchman AN, Torres L, et al. Long-term SARS-CoV-2-specific immune and
671 inflammatory responses in individuals recovering from COVID-19 with and without post-acute
672 symptoms. *Cell Rep* 2021;36(6):109518. DOI: 10.1016/j.celrep.2021.109518.
- 673 14. Peluso MJ, Lu S, Tang AF, et al. Markers of Immune Activation and Inflammation in Individuals
674 With Postacute Sequelae of Severe Acute Respiratory Syndrome Coronavirus 2 Infection. *J Infect*
675 *Dis* 2021;224(11):1839-1848. DOI: 10.1093/infdis/jiab490.
- 676 15. Peluso MJ, Sans HM, Forman CA, et al. Plasma Markers of Neurologic Injury and Inflammation in
677 People With Self-Reported Neurologic Postacute Sequelae of SARS-CoV-2 Infection. *Neurol*
678 *Neuroimmunol Neuroinflamm* 2022;9(5). DOI: 10.1212/NXI.0000000000200003.
- 679 16. Klein J, Wood J, Jaycox J, et al. Distinguishing features of Long COVID identified through immune
680 profiling. *medRxiv* 2022. DOI: 10.1101/2022.08.09.22278592.
- 681 17. Ong SWX, Fong SW, Young BE, et al. Persistent Symptoms and Association With Inflammatory
682 Cytokine Signatures in Recovered Coronavirus Disease 2019 Patients. *Open Forum Infect Dis*
683 2021;8(6):ofab156. DOI: 10.1093/ofid/ofab156.
- 684 18. Schultheiss C, Willscher E, Paschold L, et al. The IL-1beta, IL-6, and TNF cytokine triad is
685 associated with post-acute sequelae of COVID-19. *Cell Rep Med* 2022;3(6):100663. DOI:
686 10.1016/j.xcrm.2022.100663.
- 687 19. Phetsouphanh C, Darley DR, Wilson DB, et al. Immunological dysfunction persists for 8 months
688 following initial mild-to-moderate SARS-CoV-2 infection. *Nat Immunol* 2022;23(2):210-216. DOI:
689 10.1038/s41590-021-01113-x.
- 690 20. Peluso MJ, Lu S, Tang AF, et al. Markers of Immune Activation and Inflammation in Individuals
691 With Postacute Sequelae of Severe Acute Respiratory Syndrome Coronavirus 2 Infection. *J Infect*
692 *Dis* 2021. DOI: 10.1093/infdis/jiab490.

- 693 21. Yin K, Peluso MJ, Thomas R, et al. Long COVID manifests with T cell dysregulation, inflammation,
694 and an uncoordinated adaptive immune response to SARS-CoV-2. *bioRxiv* 2023. DOI:
695 10.1101/2023.02.09.527892.
- 696 22. Woodruff MC, Bonham KS, Anam FA, et al. Chronic inflammation, neutrophil activity, and
697 autoreactivity splits long COVID. *Nat Commun* 2023;14(1):4201. DOI: 10.1038/s41467-023-40012-
698 7.
- 699 23. Kruger A, Vlok M, Turner S, et al. Proteomics of fibrin amyloid microclots in long COVID/post-acute
700 sequelae of COVID-19 (PASC) shows many entrapped pro-inflammatory molecules that may also
701 contribute to a failed fibrinolytic system. *Cardiovasc Diabetol* 2022;21(1):190. DOI: 10.1186/s12933-
702 022-01623-4.
- 703 24. Pretorius E, Venter C, Laubscher GJ, et al. Prevalence of symptoms, comorbidities, fibrin amyloid
704 microclots and platelet pathology in individuals with Long COVID/Post-Acute Sequelae of COVID-
705 19 (PASC). *Cardiovasc Diabetol* 2022;21(1):148. DOI: 10.1186/s12933-022-01579-5.
- 706 25. Pretorius E, Venter C, Laubscher GJ, Lourens PJ, Steenkamp J, Kell DB. Prevalence of readily
707 detected amyloid blood clots in 'unclotted' Type 2 Diabetes Mellitus and COVID-19 plasma: a
708 preliminary report. *Cardiovasc Diabetol* 2020;19(1):193. DOI: 10.1186/s12933-020-01165-7.
- 709 26. Pretorius E, Vlok M, Venter C, et al. Persistent clotting protein pathology in Long COVID/Post-Acute
710 Sequelae of COVID-19 (PASC) is accompanied by increased levels of antiplasmin. *Cardiovasc*
711 *Diabetol* 2021;20(1):172. DOI: 10.1186/s12933-021-01359-7.
- 712 27. Gold JE, Okyay RA, Licht WE, Hurley DJ. Investigation of Long COVID Prevalence and Its
713 Relationship to Epstein-Barr Virus Reactivation. *Pathogens* 2021;10(6). DOI:
714 10.3390/pathogens10060763.
- 715 28. Peluso MJ, Deveau TM, Munter SE, et al. Chronic viral coinfections differentially affect the
716 likelihood of developing long COVID. *J Clin Invest* 2023;133(3). DOI: 10.1172/JCI163669.
- 717 29. Bodansky A, Wang CY, Saxena A, et al. Autoantigen profiling reveals a shared post-COVID
718 signature in fully recovered and Long COVID patients. *medRxiv* 2023. DOI:
719 10.1101/2023.02.06.23285532.
- 720 30. Woodruff MC, Ramonell RP, Haddad NS, et al. Dysregulated naive B cells and de novo
721 autoreactivity in severe COVID-19. *Nature* 2022;611(7934):139-147. DOI: 10.1038/s41586-022-
722 05273-0.
- 723 31. Son K, Jamil R, Chowdhury A, et al. Circulating anti-nuclear autoantibodies in COVID-19 survivors
724 predict long COVID symptoms. *Eur Respir J* 2023;61(1). DOI: 10.1183/13993003.00970-2022.
- 725 32. Tesch F, Ehm F, Vivirito A, et al. Incident autoimmune diseases in association with SARS-CoV-2
726 infection: a matched cohort study. *Clin Rheumatol* 2023. DOI: 10.1007/s10067-023-06670-0.
- 727 33. Chang R, Yen-Ting Chen T, Wang SI, Hung YM, Chen HY, Wei CJ. Risk of autoimmune diseases
728 in patients with COVID-19: A retrospective cohort study. *EclinicalMedicine* 2023;56:101783. DOI:
729 10.1016/j.eclinm.2022.101783.
- 730 34. Gaebler C, Wang Z, Lorenzi JCC, et al. Evolution of antibody immunity to SARS-CoV-2. *Nature*
731 2021;591(7851):639-644. DOI: 10.1038/s41586-021-03207-w.
- 732 35. Zollner A, Koch R, Jukic A, et al. Postacute COVID-19 is Characterized by Gut Viral Antigen
733 Persistence in Inflammatory Bowel Diseases. *Gastroenterology* 2022;163(2):495-506 e8. DOI:
734 10.1053/j.gastro.2022.04.037.
- 735 36. Natarajan A, Zlitni S, Brooks EF, et al. Gastrointestinal symptoms and fecal shedding of SARS-
736 CoV-2 RNA suggest prolonged gastrointestinal infection. *Med (N Y)* 2022;3(6):371-387 e9. DOI:
737 10.1016/j.medj.2022.04.001.
- 738 37. Swank Z, Senussi Y, Manickas-Hill Z, et al. Persistent Circulating Severe Acute Respiratory
739 Syndrome Coronavirus 2 Spike Is Associated With Post-acute Coronavirus Disease 2019
740 Sequelae. *Clin Infect Dis* 2023;76(3):e487-e490. DOI: 10.1093/cid/ciac722.
- 741 38. Stein SR, Ramelli SC, Grazioli A, et al. SARS-CoV-2 infection and persistence in the human body
742 and brain at autopsy. *Nature* 2022;612(7941):758-763. DOI: 10.1038/s41586-022-05542-y.
- 743 39. Cheung CCL, Goh D, Lim X, et al. Residual SARS-CoV-2 viral antigens detected in GI and hepatic
744 tissues from five recovered patients with COVID-19. *Gut* 2022;71(1):226-229. DOI: 10.1136/gutjnl-
745 2021-324280.

- 746 40. Craddock V, Mahajan A, Spikes L, et al. Persistent circulation of soluble and extracellular vesicle-
747 linked Spike protein in individuals with postacute sequelae of COVID-19. *J Med Virol*
748 2023;95(2):e28568. DOI: 10.1002/jmv.28568.
- 749 41. Peluso MJ, Deeks SG, Mustapic M, et al. SARS-CoV-2 and Mitochondrial Proteins in Neural-
750 Derived Exosomes of COVID-19. *Ann Neurol* 2022;91(6):772-781. DOI: 10.1002/ana.26350.
- 751 42. Sherif ZA, Gomez CR, Connors TJ, Henrich TJ, Reeves WB, Force RMPT. Pathogenic
752 mechanisms of post-acute sequelae of SARS-CoV-2 infection (PASC). *Elife* 2023;12. DOI:
753 10.7554/eLife.86002.
- 754 43. Peluso MJ, Donatelli J, Henrich TJ. Long-term immunologic effects of SARS-CoV-2 infection:
755 leveraging translational research methodology to address emerging questions. *Transl Res*
756 2022;241:1-12. DOI: 10.1016/j.trsl.2021.11.006.
- 757 44. Henrich TJ, Hsue PY, VanBrocklin H. Seeing Is Believing: Nuclear Imaging of HIV Persistence.
758 *Front Immunol* 2019;10:2077. (In eng). DOI: 10.3389/fimmu.2019.02077.
- 759 45. Henrich TJ, Jones T, Beckford-Vera D, Price PM, VanBrocklin HF. Total-Body PET Imaging in
760 Infectious Diseases. *PET Clin* 2021;16(1):89-97. DOI: 10.1016/j.cpet.2020.09.011.
- 761 46. Verger A, Barthel H, Tolboom N, et al. 2-[(18)F]-FDG PET for imaging brain involvement in patients
762 with long COVID: perspective of the EANM Neuroimaging Committee. *Eur J Nucl Med Mol Imaging*
763 2022;49(11):3599-3606. DOI: 10.1007/s00259-022-05913-7.
- 764 47. Debs P, Khalili N, Solnes L, et al. Post-COVID-19 Brain [(18)F] FDG-PET Findings: A Retrospective
765 Single-Center Study in the United States. *AJNR Am J Neuroradiol* 2023;44(5):517-522. DOI:
766 10.3174/ajnr.A7863.
- 767 48. Ferrucci R, Cuffaro L, Capozza A, et al. Brain positron emission tomography (PET) and cognitive
768 abnormalities one year after COVID-19. *J Neurol* 2023;270(4):1823-1834. DOI: 10.1007/s00415-
769 022-11543-8.
- 770 49. Martini AL, Carli G, Kiferle L, et al. Time-dependent recovery of brain hypometabolism in neuro-
771 COVID-19 patients. *Eur J Nucl Med Mol Imaging* 2022;50(1):90-102. DOI: 10.1007/s00259-022-
772 05942-2.
- 773 50. Chen LL, van de Burgt A, Smit F, et al. Investigating the potential added value of [18 F]FDG-
774 PET/CT in long COVID patients with persistent symptoms: a proof of concept study. *Nucl Med*
775 *Commun* 2023;44(6):495-501. DOI: 10.1097/MNM.0000000000001689.
- 776 51. Goehringer F, Bruyere A, Doyen M, et al. Brain (18)F-FDG PET imaging in outpatients with post-
777 COVID-19 conditions: findings and associations with clinical characteristics. *Eur J Nucl Med Mol*
778 *Imaging* 2023;50(4):1084-1089. DOI: 10.1007/s00259-022-06013-2.
- 779 52. Wang Y, Nardo L, Spencer BA, et al. Total-Body Multiparametric PET Quantification of (18) F-FDG
780 Delivery and Metabolism in the Study of COVID-19 Recovery. *medRxiv* 2023. DOI:
781 10.1101/2023.03.26.23287673.
- 782 53. Omidvari N, Jones T, Price PM, et al. First-in-human immunoPET imaging of COVID-19
783 convalescent patients using dynamic total-body PET and a CD8-targeted minibody. *medRxiv* 2023.
784 DOI: 10.1101/2023.03.14.23287121.
- 785 54. Peluso MJ, Kelly JD, Lu S, et al. Persistence, Magnitude, and Patterns of Postacute Symptoms and
786 Quality of Life Following Onset of SARS-CoV-2 Infection: Cohort Description and Approaches for
787 Measurement. *Open Forum Infect Dis* 2022;9(2):ofab640. DOI: 10.1093/ofid/ofab640.
- 788 55. Levi J, Lam T, Goth SR, et al. Imaging of Activated T Cells as an Early Predictor of Immune
789 Response to Anti-PD-1 Therapy. *Cancer Res* 2019;79(13):3455-3465. DOI: 10.1158/0008-
790 5472.CAN-19-0267.
- 791 56. Ronald JA, Kim BS, Gowrishankar G, et al. A PET Imaging Strategy to Visualize Activated T Cells
792 in Acute Graft-versus-Host Disease Elicited by Allogenic Hematopoietic Cell Transplant. *Cancer*
793 *Res* 2017;77(11):2893-2902. DOI: 10.1158/0008-5472.CAN-16-2953.
- 794 57. Levi J, Duan H, Yaghoubi S, et al. Biodistribution of a Mitochondrial Metabolic Tracer, [(18)F]F-
795 AraG, in Healthy Volunteers. *Mol Imaging* 2022;2022:3667417. DOI: 10.1155/2022/3667417.
- 796 58. Lee JH, Yim JJ, Park J. Pulmonary function and chest computed tomography abnormalities 6-12
797 months after recovery from COVID-19: a systematic review and meta-analysis. *Respir Res*
798 2022;23(1):233. DOI: 10.1186/s12931-022-02163-x.

- 799 59. Namavari M, Chang YF, Kusler B, Yaghoubi S, Mitchell BS, Gambhir SS. Synthesis of 2'-deoxy-2'-
800 [18F]fluoro-9-beta-D-arabinofuranosylguanine: a novel agent for imaging T-cell activation with PET.
801 Mol Imaging Biol 2011;13(5):812-8. DOI: 10.1007/s11307-010-0414-x.
- 802 60. Rodriguez CO, Jr., Mitchell BS, Ayres M, Eriksson S, Gandhi V. Arabinosylguanine is
803 phosphorylated by both cytoplasmic deoxycytidine kinase and mitochondrial deoxyguanosine
804 kinase. Cancer Res 2002;62(11):3100-5. (<https://www.ncbi.nlm.nih.gov/pubmed/12036920>).
- 805 61. Guglielmetti C, Levi J, Huynh TL, et al. Longitudinal Imaging of T Cells and Inflammatory
806 Demyelination in a Preclinical Model of Multiple Sclerosis Using (18)F-FARA G PET and MRI. J Nucl
807 Med 2022;63(1):140-146. DOI: 10.2967/jnumed.120.259325.
- 808 62. Kinahan PE, Fletcher JW. Positron emission tomography-computed tomography standardized
809 uptake values in clinical practice and assessing response to therapy. Semin Ultrasound CT MR
810 2010;31(6):496-505. (In eng). DOI: S0887-2171(10)00088-0 [pii]
811 10.1053/j.sult.2010.10.001.
- 812 63. Bennet AM, Reynolds CA, Eriksson UK, et al. Genetic association of sequence variants near
813 AGER/NOTCH4 and dementia. J Alzheimers Dis 2011;24(3):475-84. DOI: 10.3233/JAD-2011-
814 101848.
- 815 64. Wang LC, Almazan G. Cdon, a cell surface protein, mediates oligodendrocyte differentiation and
816 myelination. Glia 2016;64(6):1021-33. DOI: 10.1002/glia.22980.
- 817 65. Vargas-Franco D, Kalra R, Draper I, Pacak CA, Asakura A, Kang PB. The Notch signaling pathway
818 in skeletal muscle health and disease. Muscle Nerve 2022;66(5):530-544. DOI:
819 10.1002/mus.27684.
- 820 66. Ogasawara M, Nishino I. A review of core myopathy: central core disease, multimimicore disease,
821 dusty core disease, and core-rod myopathy. Neuromuscul Disord 2021;31(10):968-977. DOI:
822 10.1016/j.nmd.2021.08.015.
- 823 67. Jakovcevski M, Akbarian S, Di Benedetto B. Pharmacological modulation of astrocytes and the role
824 of cell type-specific histone modifications for the treatment of mood disorders. Curr Opin Pharmacol
825 2016;26:61-6. DOI: 10.1016/j.coph.2015.10.002.
- 826 68. Natarajan A, Zlitni S, Brooks EF, et al. Gastrointestinal symptoms and fecal shedding of SARS-
827 CoV-2 RNA suggest prolonged gastrointestinal infection. Med 2022;3(6):371-387 e9. DOI:
828 10.1016/j.medj.2022.04.001.
- 829 69. Ryan FJ, Hope CM, Masavuli MG, et al. Long-term perturbation of the peripheral immune system
830 months after SARS-CoV-2 infection. BMC Med 2022;20(1):26. DOI: 10.1186/s12916-021-02228-6.
- 831 70. Guo Y, Wang B, Gao H, Gao L, Hua R, Xu JD. ACE2 in the Gut: The Center of the 2019-nCoV
832 Infected Pathology. Front Mol Biosci 2021;8:708336. DOI: 10.3389/fmolb.2021.708336.
- 833 71. Patterson BK, Francisco EB, Yogendra R, et al. Persistence of SARS CoV-2 S1 Protein in CD16+
834 Monocytes in Post-Acute Sequelae of COVID-19 (PASC) up to 15 Months Post-Infection. Front
835 Immunol 2021;12:746021. DOI: 10.3389/fimmu.2021.746021.
- 836 72. Centers for Disease Control and Prevention. COVID Data Tracker. Atlanta, GA: U.S. Department of
837 Health and Human Services, CDC; 2023, July 23. <https://covid.cdc.gov/covid-data-tracker>.
- 838 73. Vasquez JJ, Aguilar-Rodriguez BL, Rodriguez L, et al. CD32-RNA Co-localizes with HIV-RNA in
839 CD3+ Cells Found within Gut Tissues from Viremic and ART-Suppressed Individuals. Pathog
840 Immun 2019;4(1):147-160. (In eng). DOI: 10.20411/pai.v4i1.271
841 pai.v4i1.271 [pii].
- 842 74. Park LM, Lannigan J, Jaimes MC. OMIP-069: Forty-Color Full Spectrum Flow Cytometry Panel for
843 Deep Immunophenotyping of Major Cell Subsets in Human Peripheral Blood. Cytometry A
844 2020;97(10):1044-1051. DOI: 10.1002/cyto.a.24213.
- 845

TABLES

Table 1. Participant Demographics, Clinical Factors and Long COVID History

Pt #	Variant Wave at Time of Infection	Hosp. During Acute Infection	Days from Infection to PET Scan ^a	Days From Vaccine to PET	Sex	Age ^b	LC Symptom Count ^c	Presence of LC Symptom Phenotype at Time of Imaging					Anti-N Ab at PET ^d	Days from COVID to Gut Biopsy ^e	
								Fatigue	Pulm	Cardiac	URI	GI			Neuro
1	Pre-Omicron	N	27	135	F	25-29	2	Y	Y	N	N	N	N	Y	-
2	Pre-Omicron	N	29	113	M	35-39	1	N	Y	N	N	N	N	Y	-
3	Pre-Omicron	N	42	151	M	30-34	4	N	Y	Y	N	N	N	Y	-
4	Pre-Omicron	N	44	149	M	60-64	0	N	N	N	N	N	N	Y	-
5	Pre-Omicron	N	48	199	M	25-29	5	Y	N	Y	N	Y	Y	Y	-
6	Pre-Omicron	N	50	N/A ^f	F	30-34	4	Y	Y	N	N	N	Y	N	-
7	Omicron	N	64	6	M	40-44	14	Y	Y	N	N	Y	Y	N	-
8	Omicron	N	65	386	F	60-64	0	N	N	N	N	N	N	N	-
9	Omicron	N	83	183	F	55-59	0	N	N	N	N	N	N	Y	-
10	Omicron	N	95	246	M	45-49	0	N	N	N	N	N	N	Y	158
11	Omicron	N	114	286	F	30-34	8	Y	N	Y	Y	Y	N	Y	-
12	Pre-Omicron	N	193	137	F	25-29	13	Y	Y	N	N	Y	Y	N	-
13	Omicron	N	205	122	F	45-49	6	Y	Y	N	N	N	Y	N	-
14	Omicron	N	231	63	M	35-39	4	Y	N	Y	N	Y	Y	Y	-
15	Omicron	N	246	302	M	65-69	6	Y	N	N	Y	Y	Y	N	213
16	Pre-Omicron	Y ^g	260	118	M	50-54	8	Y	Y	N	Y	N	Y	N	442
17	Omicron ^h	N	406	219	F	30-34	0	N	N	N	N	N	N	Y	-
18	Pre-Omicron	N	617	320	F	30-34	7	Y	N	Y	N	N	Y	N	645
19	Pre-Omicron	N	625	122	M	45-49	14	Y	Y	N	N	Y	Y	Y	-
20	Pre-Omicron	N	641	321	M	25-29	11	Y	N	Y	N	Y	Y	Y	-
21	Pre-Omicron	N	654	425	F	30-34	15	Y	Y	Y	N	Y	Y	N	-
22	Pre-Omicron	N	663	248	M	50-54	6	Y	Y	N	Y	Y	Y	Y	676
23	Pre-Omicron	N	890	211	M	50-54	0	N	N	N	N	N	N	Y	-
24	Pre-Omicron	Y ⁱ	910	155	F	55-59	6	Y	Y	N	N	Y	Y	N	-

Pt = participant; Hosp. = hospitalized; Pulm = pulmonary; URI = upper respiratory; GI = gastrointestinal; Neuro = neurocognitive; LC = Long COVID; Y = Yes, N = No; F = female; M = male

^a Days from last COVID-19 vaccine dose to PET imaging

^b Age in years in 5-year age bracket

^c Number of participant reported symptoms at the time of PET imaging (out of 32 total)

^d Anti-Nucleocapsid antibody detected at time of PET

^e All participants had a least one Long COVID symptoms at the time of sigmoidoscopy and rectosigmoid tissue collection

^f Participant was not vaccinated prior to PET imaging

^g Participant did not require intensive care but received supplemental oxygen during hospitalization

^h Participant initial infected during pre-Omicron wave but had two documented re-infections. Days from infection to PET scan calculated from last Omicron reinfection

ⁱ Participant did not require intensive care or supplemental oxygen during hospitalization

FIGURES

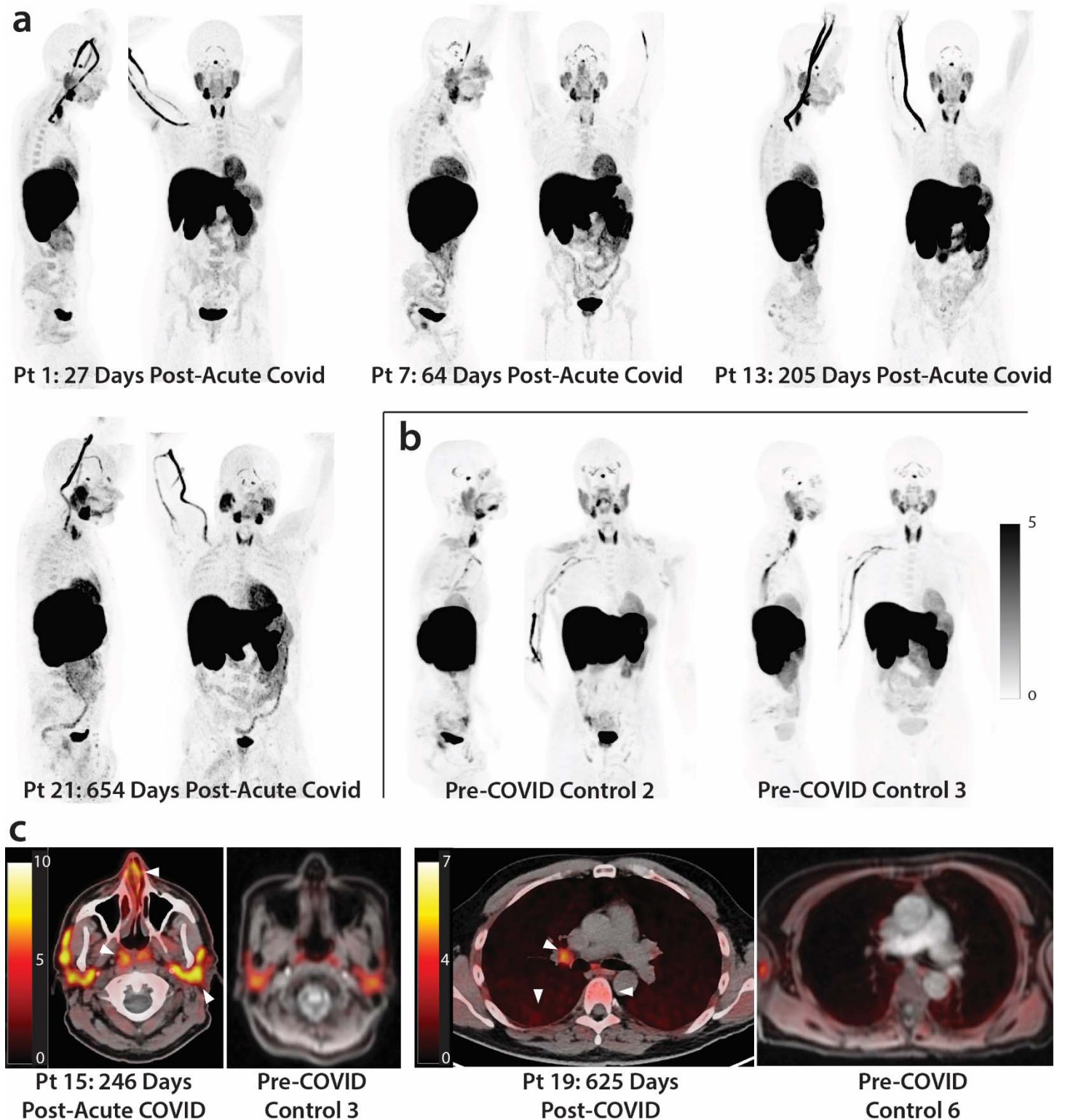


Figure 1. [^{18}F]F-AraG PET and PET/CT images from participants following COVID-19 and pre-pandemic control volunteers. Maximum intensity projections (MIP; coronal and sagittal views of 3-dimensional reconstructions) are shown for four representative participants at various times following SARS-CoV-2 infection

(a) and male and female uninfected controls (b). Axial PET/CT overlay images are shown in (c) showing increased signal in nasal turbinates, parotid glands, hilar lymph node, lung parenchyma, and lumbar bone marrow in representative post-acute COVID and pre-pandemic control participants (white arrows). MIPs for all participants are shown in **Supplemental Figure 1**.

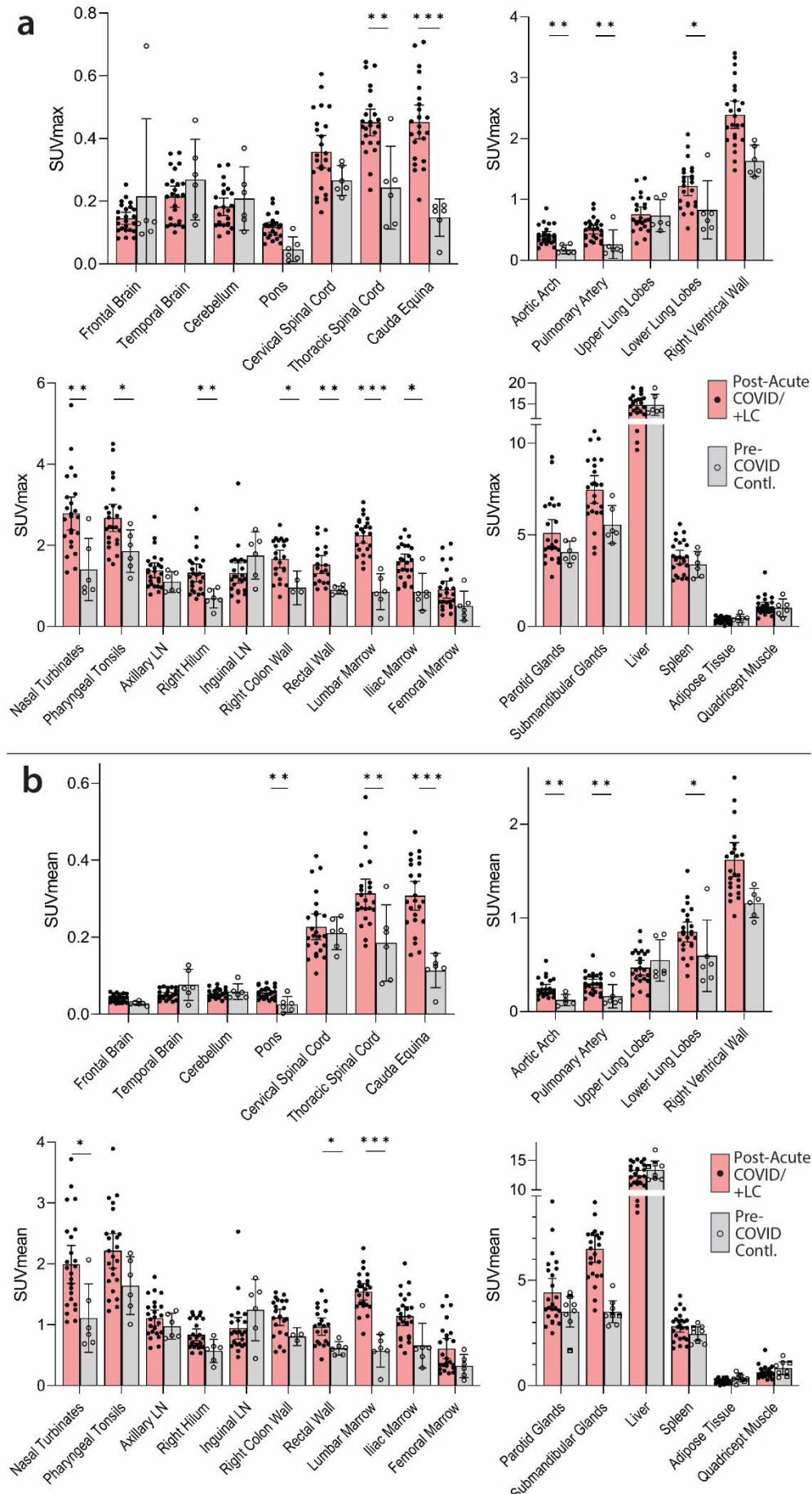


Figure 2. Comparisons of [¹⁸F]F-AraG standardized uptake values (SUV) in post-acute COVID cases and pre-pandemic control participants. Maximum SUV (SUV_{max}) (a) and mean SUV (SUV_{mean}) (b) values for various anatomical regions of interest (ROI) are shown including post-acute COVID participants including those with any number of Long COVID symptoms (Post-acute COVID/+LC; N=18) and pre-pandemic controls (N=6). Bars represent mean SUV_{max} or SUV_{mean} and error bars represent 95% confidence interval. Adjusted P values <0.05, <0.01 and <0.001 represented by *, **, and *** respectively from two-sided non-parametric Kruskal–Wallis tests using a Benjamini-Hochberg adjustment for false discovery rates across multiple comparisons (q value = adjusted P). All data points are shown on the graph. Gating was not possible in 3 and 5 post-acute COVID participants for proximal colon and rectal wall ROIs, respectively, and 3 pre-pandemic control participants for proximal colon.

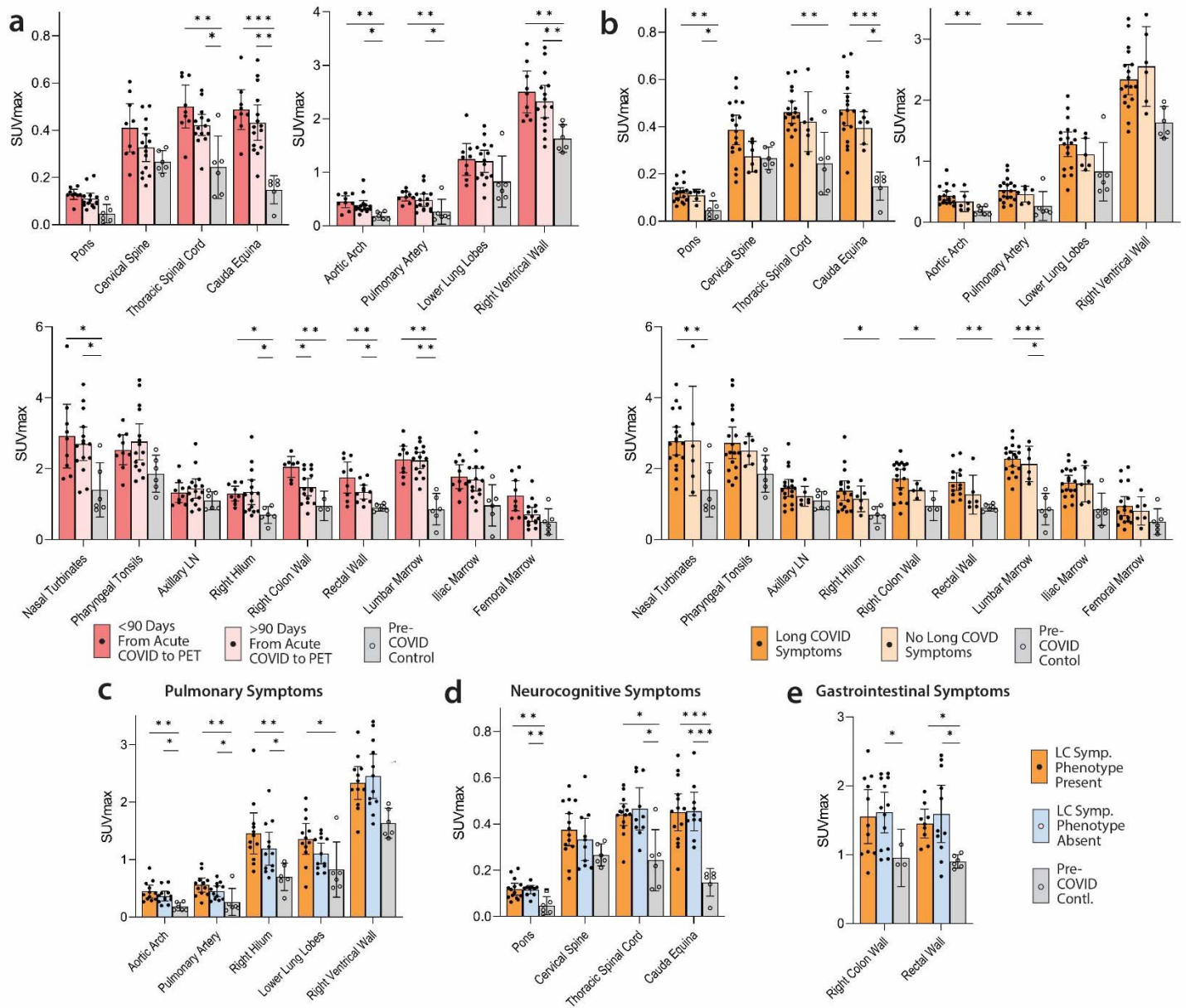


Figure 3. Comparisons of [^{18}F]F-AraG maximum standardized uptake values in post-acute COVID cases and control participants grouped by time from initial COVID-19 symptom onset to PET imaging and by Long COVID symptoms. SUVmax values in tissue ROIs in post-acute COVID participants imaged <90 days or >90 days from acute infection onset and control volunteers are shown in (a). SUVmax values in tissue ROIs in post-acute COVID participants with or without Long COVID symptoms reported at the time of imaging and control volunteers are shown in (b). SUVmax values in tissue ROIs in post-acute COVID participants with or without pulmonary symptoms (c), neurocognitive symptoms (d) and gastrointestinal symptoms (e) are also shown.

Bars represent mean SUVmax and error bars represent 95% confidence interval. Adjusted P values <0.05, <0.01 and <0.001 represented by *, **, and *** respectively from two-sided non-parametric Kruskal–Wallis tests using a Benjamini-Hochberg adjustment for false discovery rates across multiple comparisons (q value = adjusted P). All data points are shown.

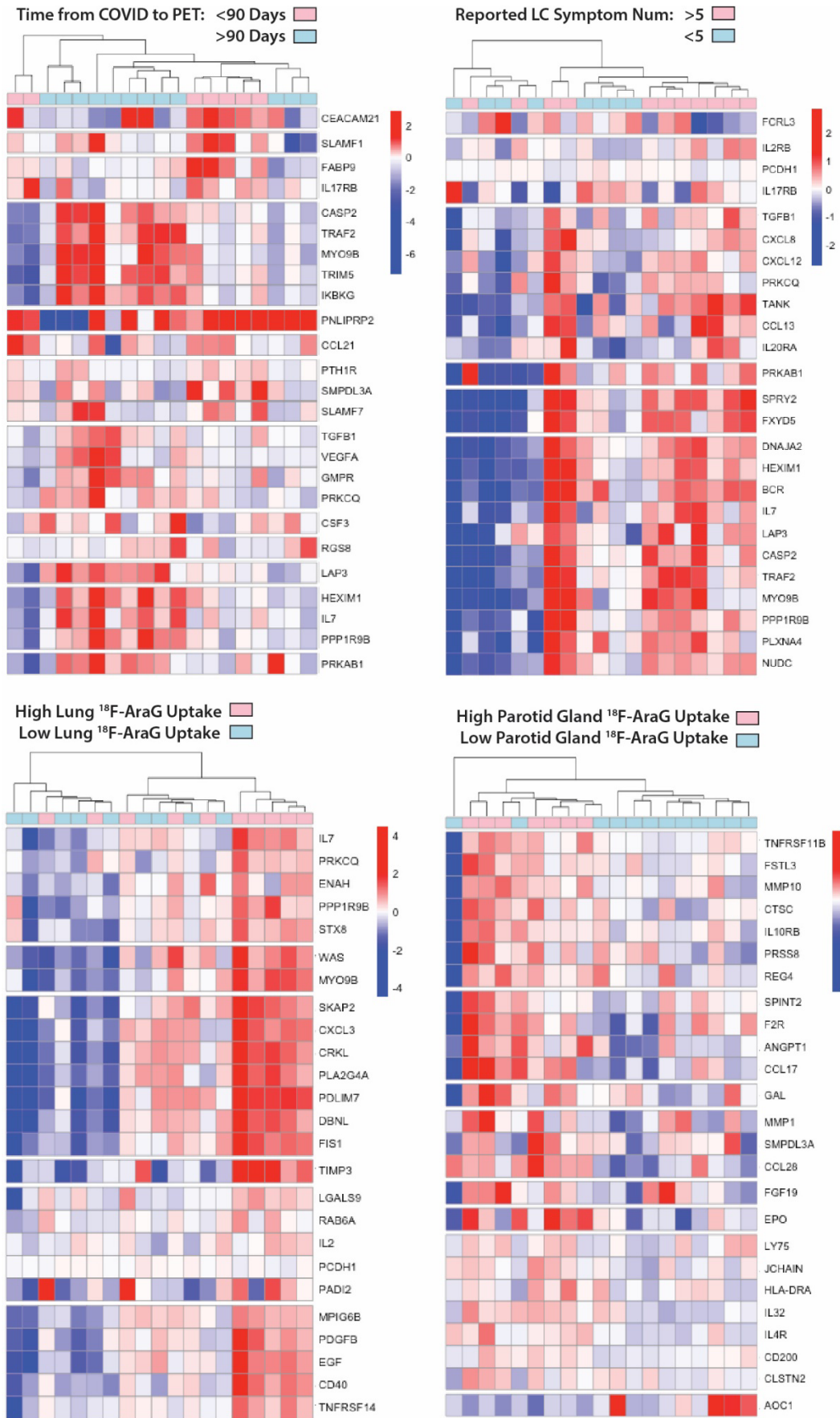


Figure 4. Differential plasma protein expression in post-acute COVID participants grouped by time of COVID to PET imaging, reported Long COVID symptom number and [¹⁸F]F-AraG uptake in representative tissues. Clustered heat maps of the top 25 differentially expressed plasma proteins from Olink Proximity Extension Assay EXPLORE 384 panel with markers grouped into k-clusters based on similarity are shown for participants imaged early (<90 days) or later (>90 days) after symptom onset (a), those reporting >5 or ≤5 Long COVID symptoms (out of a total of 32 surveyed across multiple organ systems) at the time of PET imaging (b), and in those with high lower lung lobe [¹⁸F]F-AraG uptake (c; defined as SUVmax >2 standard deviations [SD] above the average SUVmax value measured in Pre-pandemic control volunteers), and parotid gland tissue [¹⁸F]F-AraG uptake (d; defined as SUVmax >1 SD above the average SUVmax value measured in pre-pandemic control participants). Note that modules of various gene products representing inflammation and immune activation have higher differential expression in participants with >5 Long COVID symptoms and with higher [¹⁸F]F-AraG uptake in tissue. Heat maps clustered by high uptake in other tissues ROIs were less revealing and shown in **Supplemental Figure 4)**

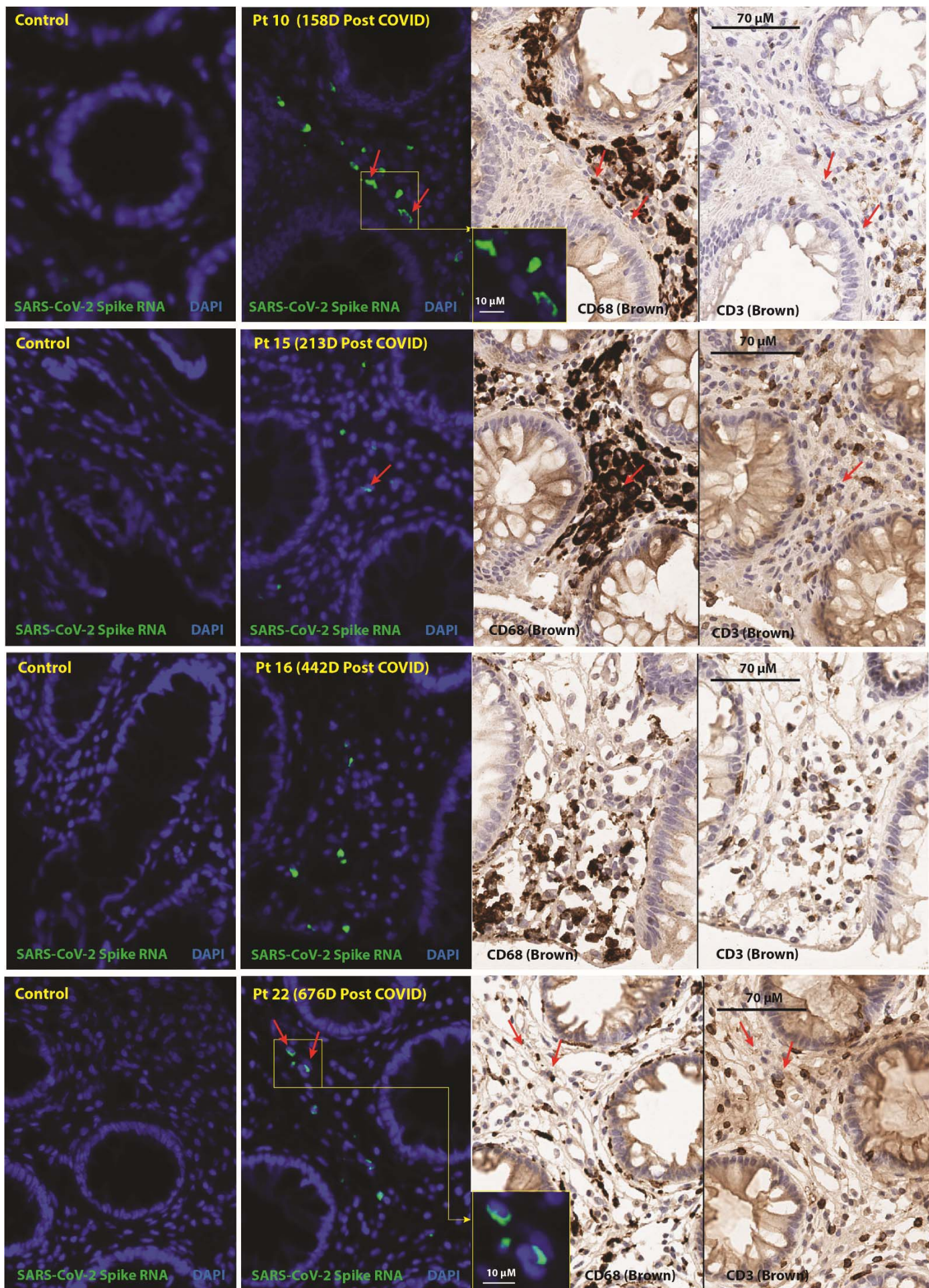


Figure 5. In situ hybridization (ISH) of SARS-CoV-2 spike RNA and immunohistochemical staining of recto-sigmoid tissue. Panels represent from left to right: SARS-CoV-2 spike RNA staining by ISH in pre-pandemic tissue, SARS-CoV-2 spike RNA staining by ISH in post-acute COVID participant sample, and CD68 and CD3 chromogenic immunostaining. Red arrows denote representative areas of RNA detection across images for each sample (not all RNA detection is marked). Spike RNA was detected in all five of the post-acute COVID participants that underwent biopsy from 158 to 676 days following initial COVID-19 symptom onset and signal was primarily observed in cells located within the lamina propria. Four participants with detectable RNA in three distinct gut regions are shown, a fifth participant had rare spike RNA detected in only one of three regions imaged. A minority of SARS-CoV-2 RNA signal was localized in CD68+ macrophages/immune cells and very rarely in CD3+ T cells. No viral RNA was detected in the pre-pandemic COVID tissue. Only linear adjustments to contrast and brightness were used during image analysis, with the same parameters being applied to all case and control tissues which underwent identical slide processing and imaging protocols.

SUPPLEMENTAL INFORMATION

Supplemental Table 1. Clinical Findings on Chest CT Scans

Pt #	Days from Infection to PET Scan ^a	Sex	Age Bracket (Years)	Hosp	LC Symptom Count ^b	Abnormal Findings on Chest CT as Determined by Two Cross-Sectional Radiologists (R1, R2)
1	27	F	25-29	N	2	None
2	29	M	35-39	N	1	R Lower Lobe Bulla (R1); Minimal basilar subpleural bands/reticulation/ground glass (R2)
3	42	M	30-34	N	4	None
4	44	M	60-64	N	0	Minimal subpleural reticulation and banding in bases, L>R (R2)
5	48	M	25-29	N	5	None
6	50	F	30-34	N	4	Few tiny subpleural micronodules, likely intrapulmonary lymph nodes (R2)
7	64	M	40-44	N	14	None
8	65	F	60-64	N	0	Mild apical scarring
9	83	F	55-59	N	0	None
10	95	M	45-49	N	0	Calcified R lower lobe granuloma, L lower lobe subpleural granuloma (R1)
11	114	F	30-34	N	8	Subpleural L lower lobe nodule, intrapulmonary lymph node (R1)
12	193	F	25-29	N	13	None
13	205	F	45-49	N	6	Minimal apical, lingular and R middle lobe consolidation or scarring (R1)
14	231	M	35-39	N	4	None
15	246	M	65-69	N	6	None
16	260	M	50-54	Y ^c	8	R lower lobe nodule <1 centimeter (R1 & R2)
17	406	F	30-34	N	7	L major fissure micronodule, intrapulmonary lymph node (R1)
18	617	F	30-34	N	14	None
19	625	M	45-49	N	11	None
20	641	M	25-29	N	15	None
21	654	F	30-34	N	6	None
22	663	M	50-54	N	0	Mild apical scarring
23	890	M	50-54	N	6	Basilar predominant subpleural reticulation and scarring
24	910	F	55-59	Y ^d	0	None

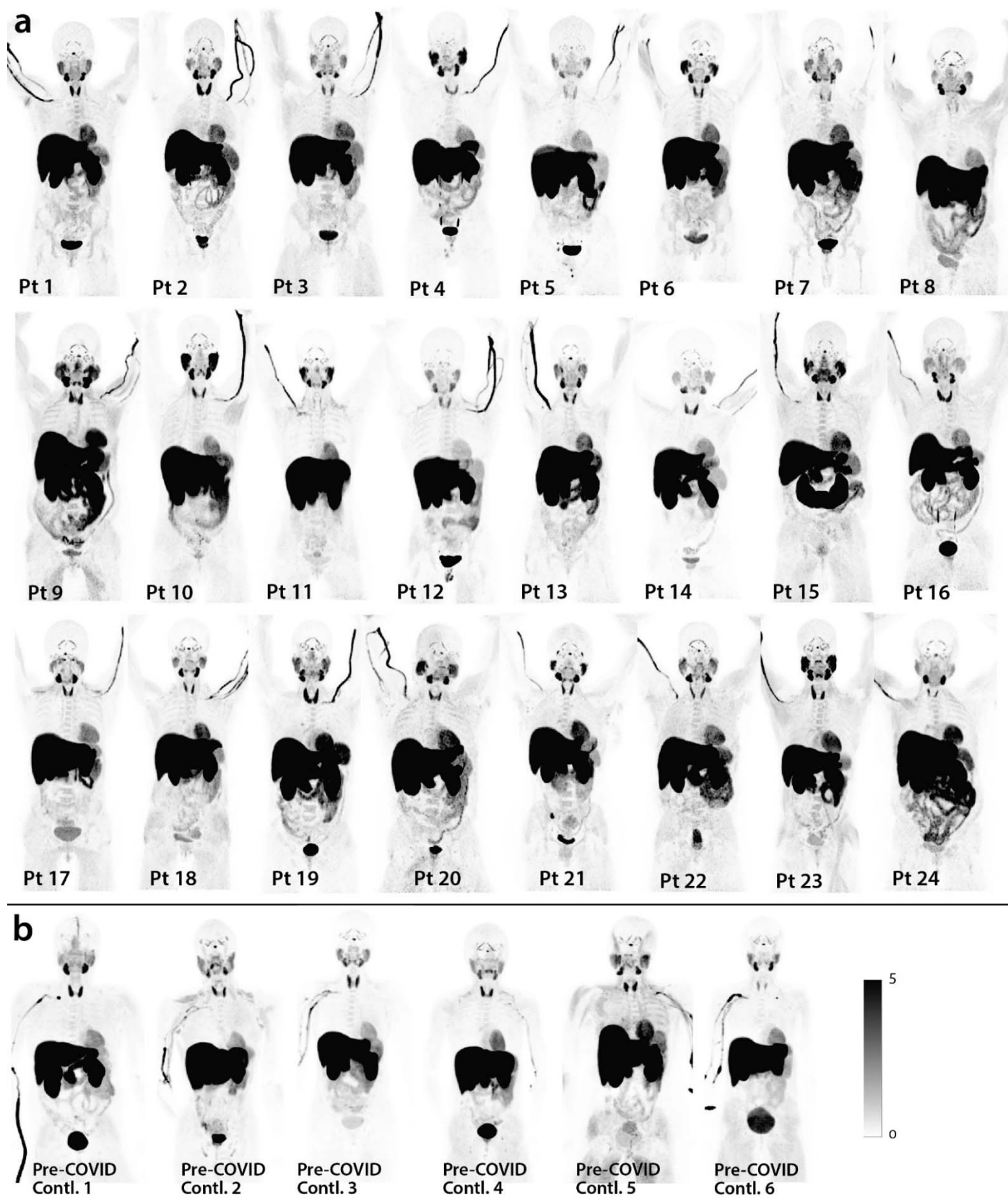
R = right; L = left; M = male; F = female

^a Days from last COVID-19 vaccine dose to PET imaging

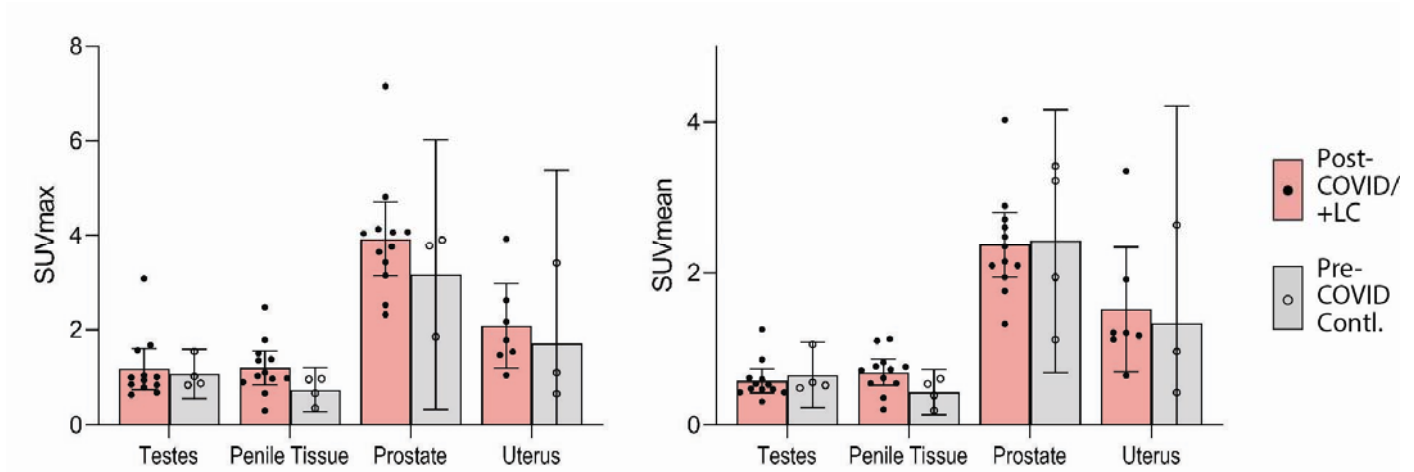
^b Number of participant reported symptoms at the time of PET imaging (out of 32 total)

^c Participant did not require intensive care but received supplemental oxygen during hospitalization

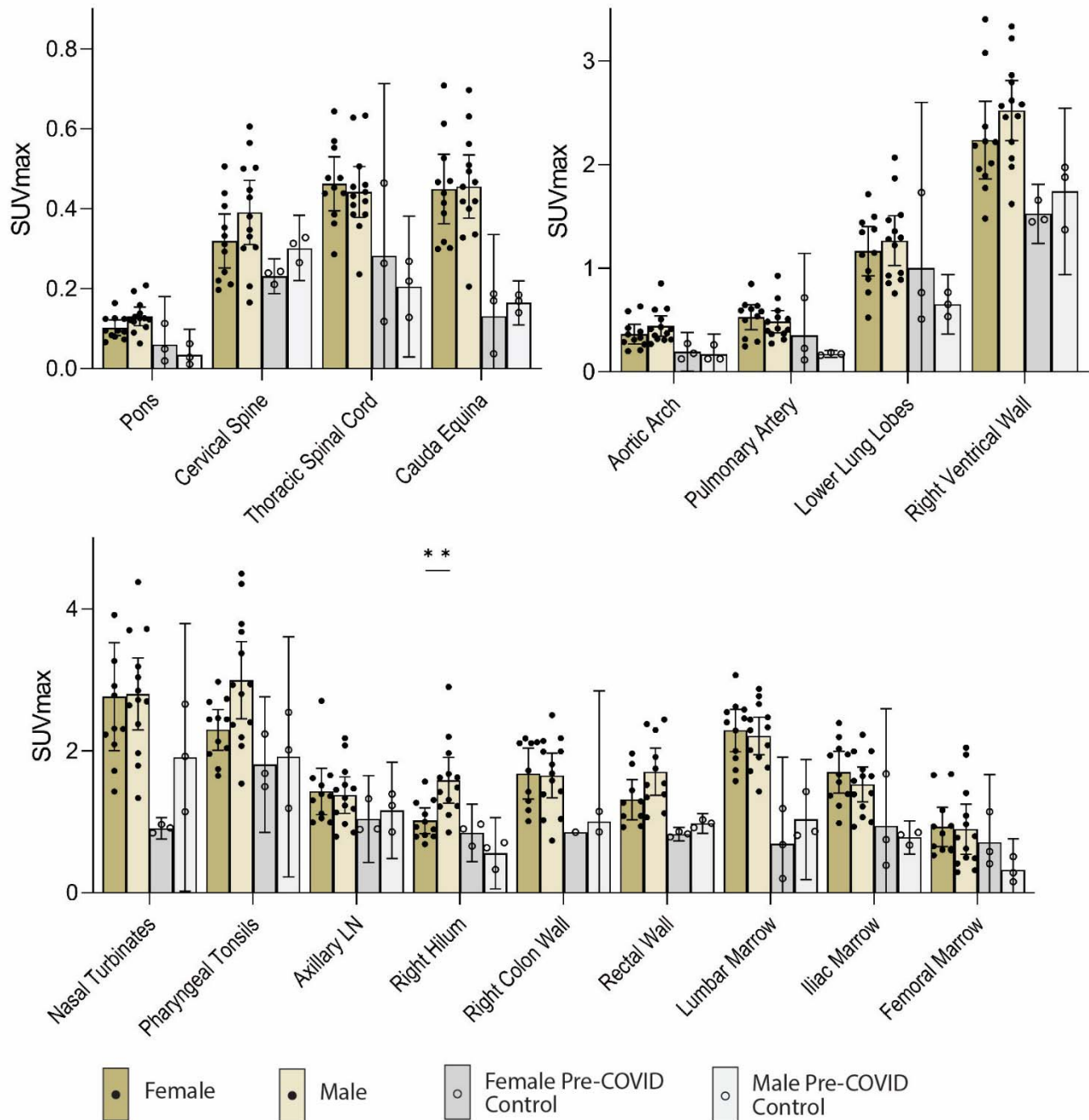
^d Participant did not require intensive care or supplemental oxygen during hospitalization



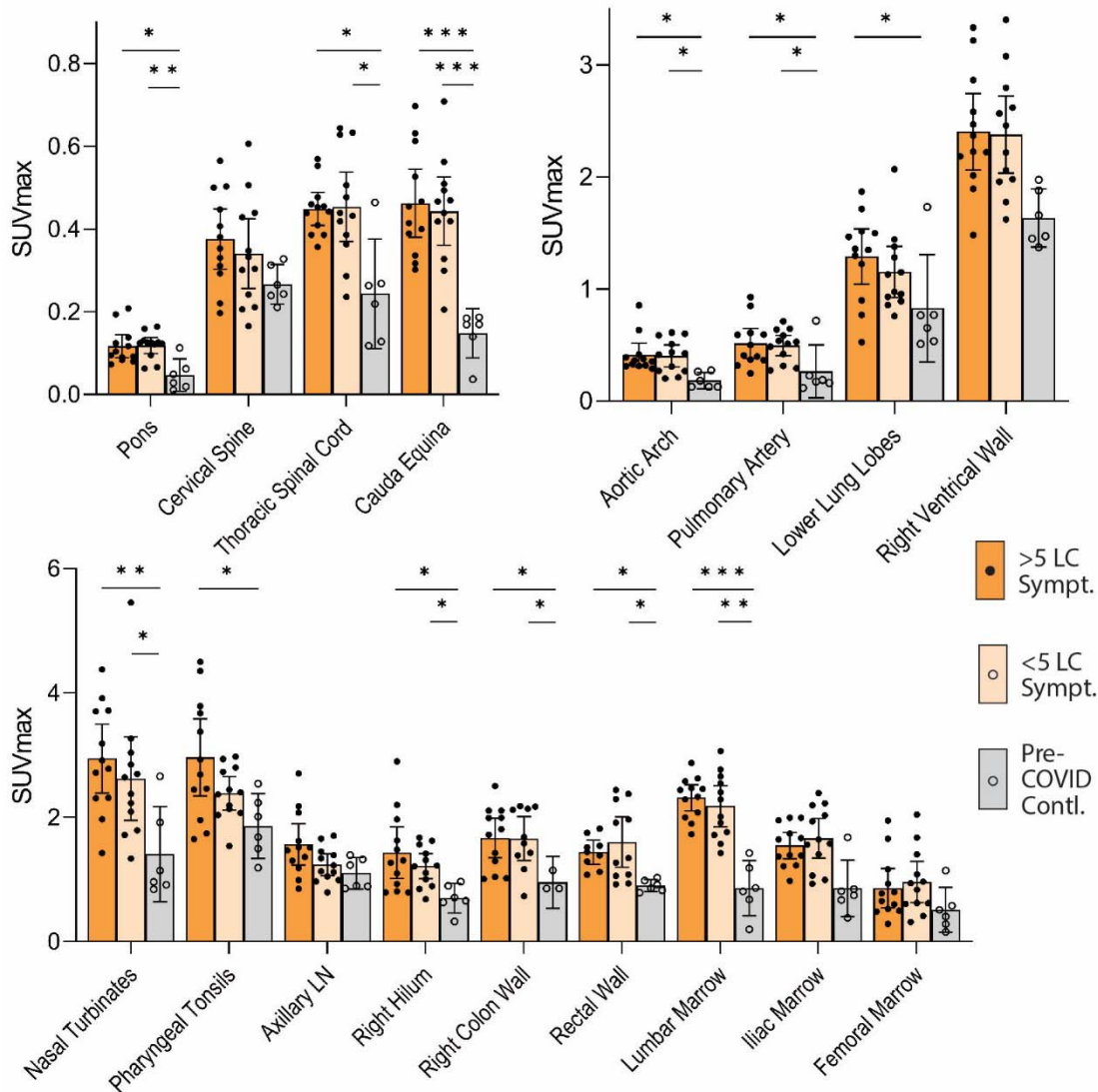
Supplemental Figure 1. Maximum intensity projections (MPI; coronal views of 3-dimesional reconstructions) are shown for all cases and pre-pandemic and contemporary control participants.



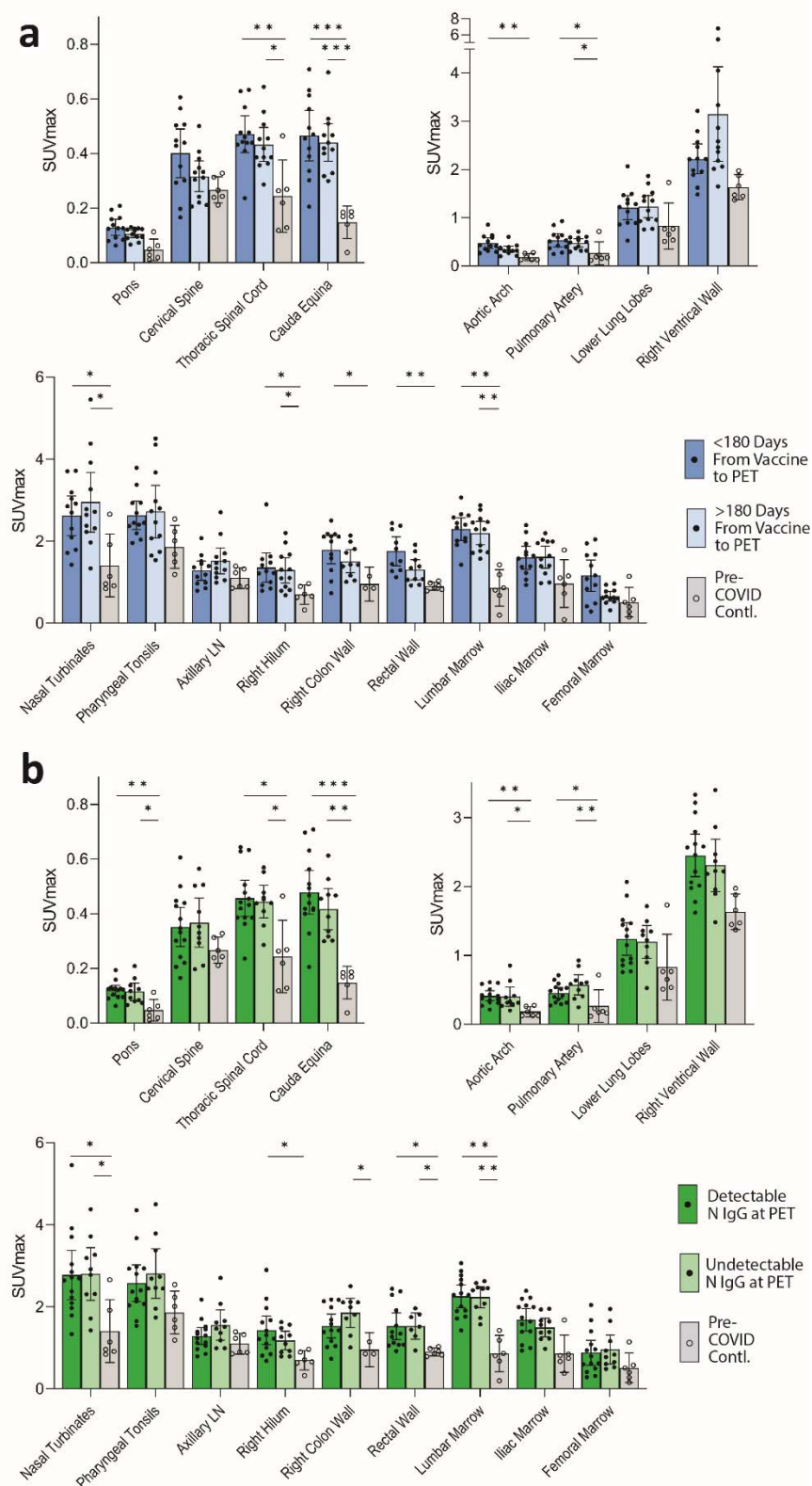
Supplemental Figure 2. [^{18}F]F-AraG SUVmax and SUVmean for reproductive tissues for cases and pre-pandemic controls are shown. Bars represent mean SUVmax and error bars represent 95% confidence interval. No statistical differences were observed between cases and controls for any reproductive tissue ROI. All data points are shown.



Supplemental Figure 3. Comparisons of [¹⁸F]F-AraG maximum standardized uptake values in post-acute COVID cases and pre-pandemic control participants grouped by sex assigned at birth are shown. Bars represent mean SUVmax and error bars represent 95% confidence interval. Adjusted P values <0.05 and <0.001 represented by * and **, respectively from two-sided non-parametric Kruskal–Wallis tests using a Benjamini-Hochberg adjustment for false discovery rates across multiple comparisons (q value = adjusted P). Given lack of power to compare cases versus controls grouped on sex, statistical analyses were only performed between female and male post-acute COVID participants. All data points are shown.

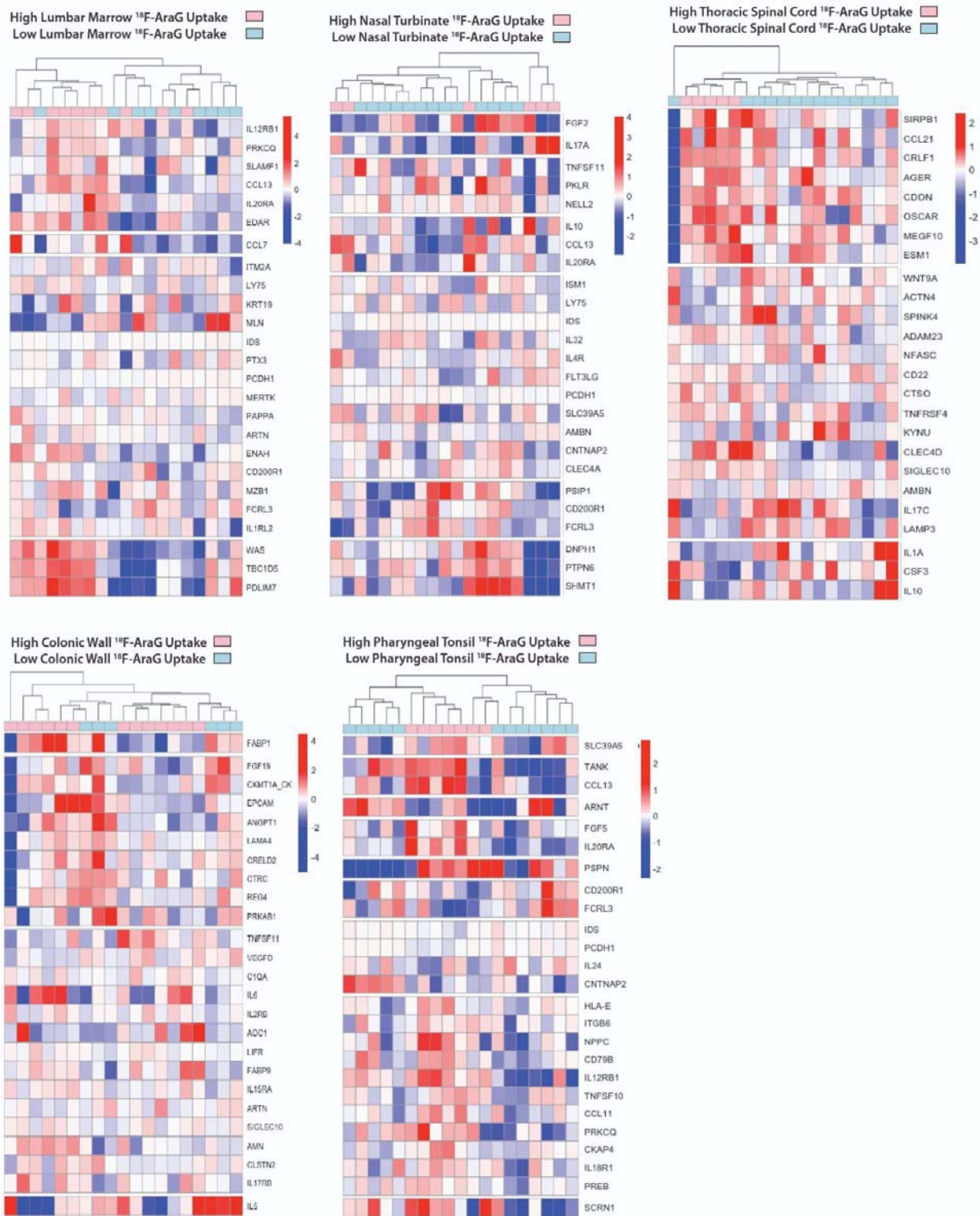


Supplemental Figure 4. Comparisons of [¹⁸F]F-AraG maximum standardized uptake values in post-acute COVID cases and pre-pandemic control participants grouped participants with >5 or ≤5 Long COVID symptoms reported at the time of imaging and control volunteers are shown. Bars represent mean SUVmax and error bars represent 95% confidence interval. Adjusted P values <0.05, <0.01 and <0.001 represented by *, **, and *** respectively from two-sided non-parametric Kruskal–Wallis tests using a Benjamini-Hochberg adjustment for false discovery rates across multiple comparisons (q value = adjusted P). All data points are shown.



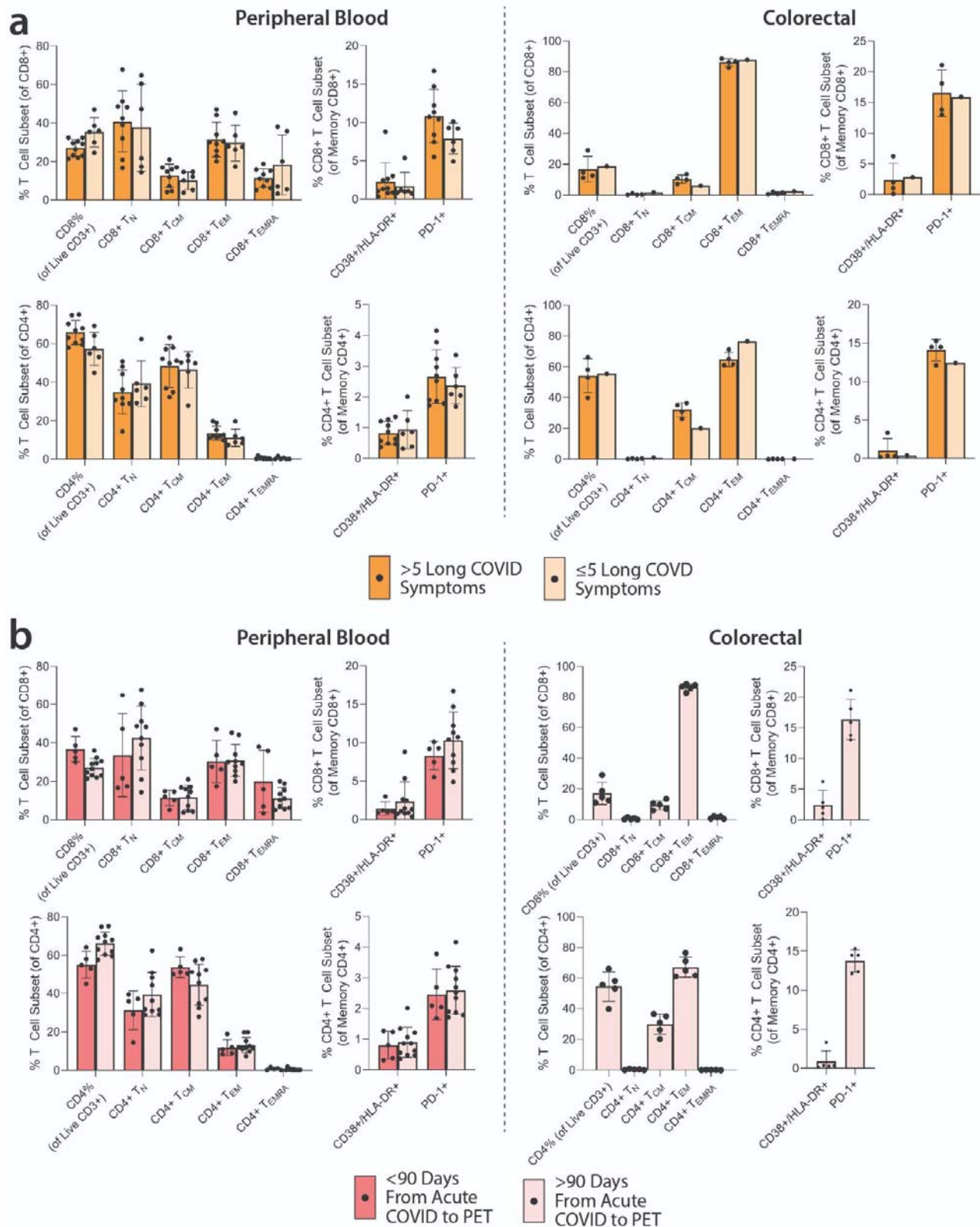
Supplemental Figure 5. Comparisons of [^{18}F]F-AraG maximum standardized uptake values in post-acute COVID cases and pre-pandemic control participants grouped by time from most recent dose of SARS-CoV-2 vaccine and PET imaging and by presence of detectable nucleocapsid (N) IgG detection at the time of imaging. SUVmax values in tissue ROIs in post-acute COVID participants imaged <180 days or >180 days

from the last dose of COVID-19 vaccine and control volunteers are shown in **(a)**. SUVmax values in tissue ROIs in post-acute COVID participants with detectable or undetectable SARS-CoV-2 N IgG measures at the time of imaging and control volunteers are shown in **(b)**. Bars represent mean SUVmax and error bars represent 95% confidence interval. Adjusted P values <0.05, <0.01 and <0.001 represented by *, **, and *** respectively from two-sided non-parametric Kruskal–Wallis tests using a Benjamini-Hochberg adjustment for false discovery rates across multiple comparisons (q value = adjusted P). All data points are shown.

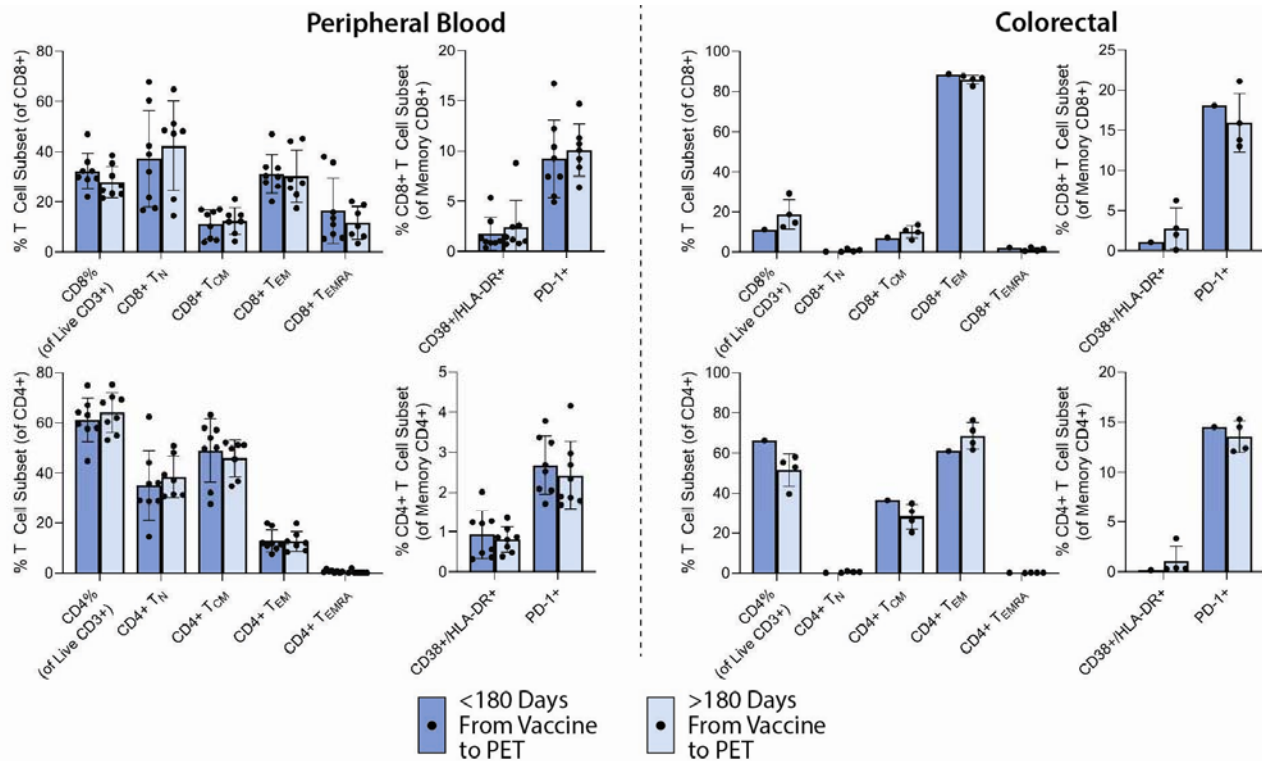


Supplemental Figure 6. Differential plasma protein expression in post-acute COVID participants grouped by high or low [¹⁸F]F-AraG uptake in representative tissues. Clustered heat maps of the top 25 differentially expressed plasma proteins from Olink Proximity Extension Assay EXPLORE 384 panel with markers grouped

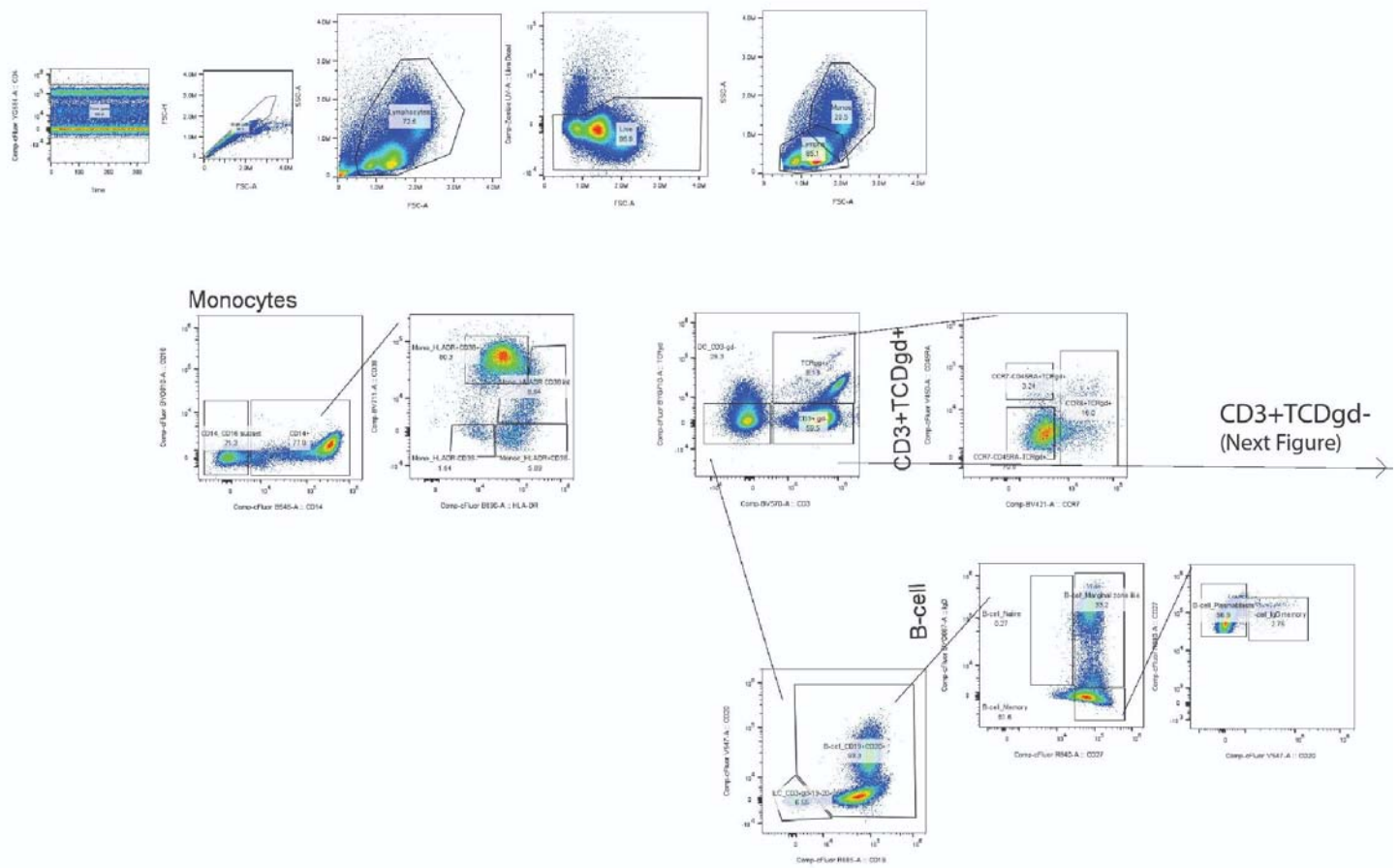
into k-clusters based on similarity are shown for participants with high or lower PET signal in various tissue ROIs.



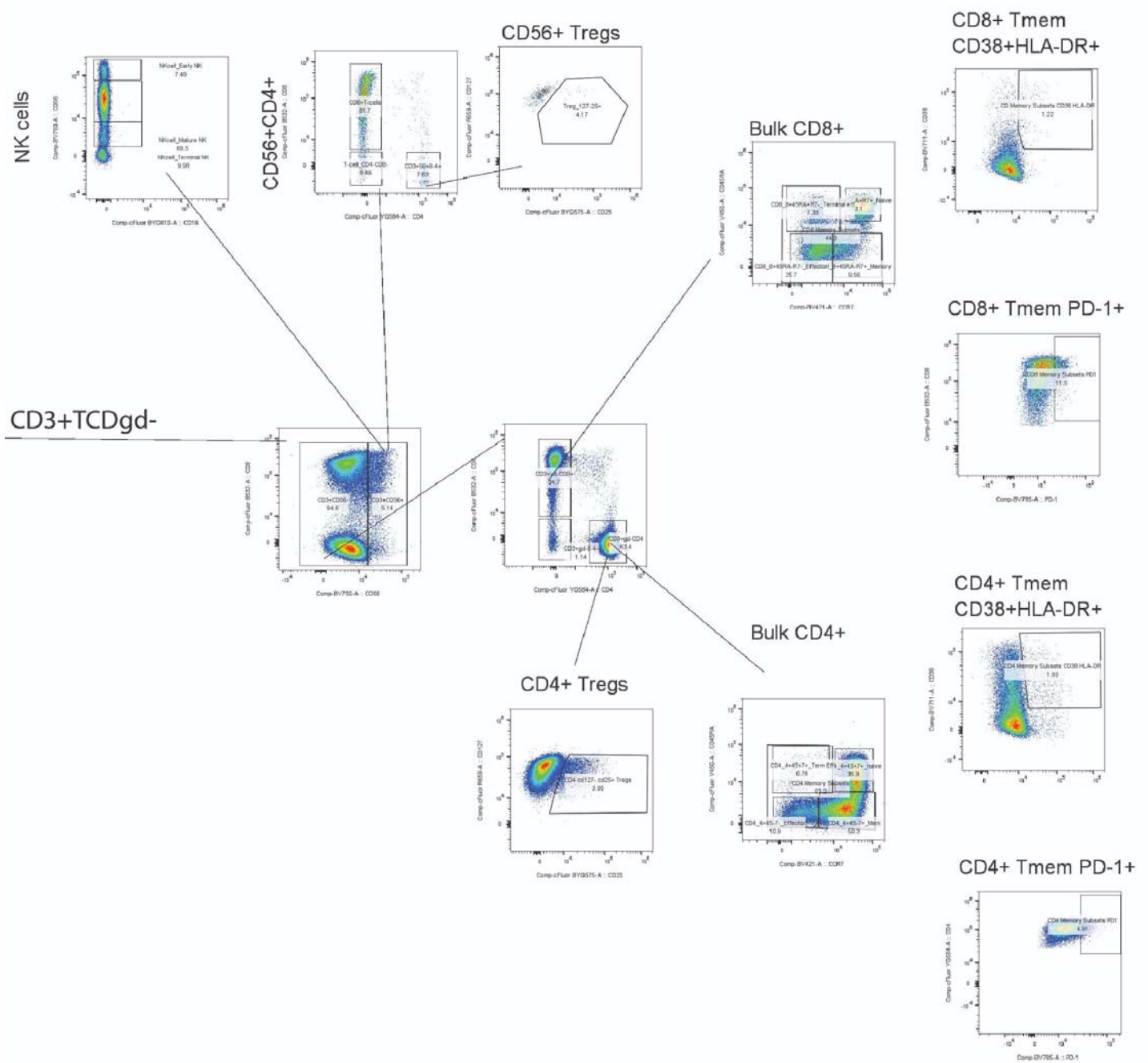
Supplemental Figure 7. Spectral flow cytometry results for T lymphocyte phenotypes. The frequency of CD8+ and CD4+ T cell subsets (TN = naïve, TCM = central memory, TEM = effector memory, TEMRA = effector memory RA+/terminally differentiated) and frequency of lymphocytes co-expressing activation markers CD38/HLA-DR and immune checkpoint PD-1 from peripheral blood and gut for those with >5 or ≤5 Long COVID symptoms (**a**) and those imaged >90 or <90 days after onset of acute COVID-19 (**b**) are shown. No significant differences between post-acute COVID groups were identified. Bars represent percent of T cells expressing markers of interest and error bars represent 95% confidence intervals.



Supplemental Figure 8. Spectral flow cytometry results for T lymphocyte phenotypes grouped by time of PET imaging from last COVID-19 vaccine dose. The frequency of CD8+ and CD4+ T cell subsets (TN = naïve, TCM = central memory, TEM = effector memory, TEMRA = effector memory RA+/terminally differentiated) and frequency of lymphocytes co-expressing activation markers CD38/HLA-DR and immune checkpoint PD-1 from peripheral blood and gut for those who underwent PET imaging <180 or >180 days following the last dose of COVID-19 vaccine are shown. No significant differences between post-acute COVID groups were identified. Bars represent percent of T cells expressing markers of interest and error bars represent 95% confidence intervals.



Supplemental Figure 9. Lymphocyte and other mononuclear cell gating strategy (part A).



Supplemental Figure 10. Lymphocyte and other mononuclear cell gating strategy (part B).