

Effect of using Diffusion-Weightage Imaging on Diagnostic Accuracy of MRI in catching Parotid carcinoma: A meta-analysis

Authors

1) Dev Desai, MBBS

Smt. NHL Municipal Medical College, Ahmedabad, India.

Email Address: devhdesai01@gmail.com

2) Marko Todorovski

Medical Faculty Skopje, University Ss Cyril, and Methodius, North Macedonia.

Email Address: markotodorovski4@gmail.com

3) Maria Eleni Malafi

Medical School, Democritus University of Thrace, Alexandroupolis, Greece.

Email Address:- marilenmalafi@gmail.com

4) Abhijay B. Shah, MBBS

Smt. NHL Municipal Medical College, Ahmedabad, India.

Email Address: abhijayshah0610@gmail.com

5) Dev Andharia, MBBS (Corresponding author)

Smt. NHL Municipal Medical College, Ahmedabad, India.

Email Address:-devu.andharia98@gmail.com

Mob No.:- +91 9099034011

Abstract

Background: A wide variety of benign and malignant tumors can develop in the salivary gland, which makes up roughly 3-5% of all head and neck tumors. Making a precise pre-operative distinction between benign and malignant salivary gland tumors, or identifying the precise histologic subtype, is crucial since this knowledge has a significant impact on the treatment strategy. The results of fine-needle aspiration cytology can occasionally be inaccurate since it is an intrusive procedure for diagnosing parotid tumors before surgery. Because of the tiny sample size or the deep placement of the tumor, it is sometimes impossible to gather adequate samples therefore Salivary gland tumors are increasingly being evaluated before surgery using MRI since it can pinpoint their precise location, size, and surrounding tissues.

Methods: Medical literature was comprehensively searched and reviewed without restrictions to particular study designs, or publication dates using PubMed, Cochrane Library, and Google Scholar databases for all relevant literature. The extraction of necessary data proceeded after specific inclusion and exclusion criteria were applied. The inclusion criteria were as follows: (1) Literature that provided information about the accurate diagnosis with MRI(DWI) and only MRI ; (2) papers published in English; (3) papers with appropriate patient criteria. The exclusion criteria were: (1) articles that were not full text, (2) unpublished articles, and (3) non-English articles. In this Meta-Analysis, a total of 8 RCTs with a total of 944 patients were selected, out of which 3 RCTs with a total of 356 patients were selected for MRI and 5 RCTs with a total of 588 patients were selected for MRI+DWI study. wherein two writers independently assessed the caliber of each study as well as the use of the Cochrane tool for bias risk apprehension. The statistical software packages RevMan (Review Manager, version 5.3), SPSS (Statistical Package for the Social Sciences, version 20), and Excel in Stata 14 were used to perform the statistical analyses.

Results: We calculated the sensitivity and specificity of MRI in diagnosing parotid gland lesions in the different papers, For the MRI, The sensitivity is 0.81 with a CI of 95% in a range of 0.77 to 0.86, the mean being 0.049. The Sensitivity of the MRI is 0.790 with a CI of 95% in a range of (0.772 to 0.809) the mean being (0.0183). The Specificity of the MRI is 0.794 with a CI of 95% in a range of (0.613 to 0.975) the mean being (0.181). For the MRI+DWI study, The Sensitivity of the MRI+DWI is 0.618 with a CI of 95% in a range of (0.498 to 0.737); the mean being (0.119). The Specificity of the MRI+DWI is 0.892 with a CI of 95% in a range of (0.813 to 0.97) the mean being (0.079).

Conclusion: In addition to simple MRI or Single DWI MRI, A combination of both would detect higher lesions and it should be helpful for staging and early diagnosis purposes only.

Keywords: ‘Parotid carcinoma imaging’, ‘Result of Diffusion-weighted imaging (DWI) MRI Scan in parotid carcinoma diagnosis’, and ‘MRI in Parotid carcinoma’

Introduction

A wide variety of benign and malignant tumors can develop in the salivary gland, which makes up roughly 3-5% of all head and neck tumors. [1] Making a precise pre-operative distinction between benign and malignant salivary gland tumors, or identifying the precise histologic subtype, is crucial since this knowledge has a significant impact on the treatment strategy. [2] Malignant tumors are typically treated with a more aggressive approach, such as a total parotidectomy that may involve removing the facial nerve, whereas benign tumors are advised to undergo local excision or superficial parotidectomy. [3] [4]

For proper surgical intervention, timely diagnosis plays a crucial role. Fine needle aspiration cytology is one of the many diagnostic modalities that can be used. However, it has a few disadvantages.

The results of fine-needle aspiration cytology can occasionally be inaccurate since it is an intrusive procedure for diagnosing parotid tumors prior to surgery. Because of the tiny sample size or the deep placement of the tumor, it is sometimes impossible to gather adequate samples.[5]

This method is an invasive method which also makes it inconvenient for the patients. Due to the various disadvantages that this method offers, it becomes a rather less preferred modality.

Salivary gland tumors are increasingly being evaluated prior to surgery using MRI since it can pinpoint their precise location, size, and surrounding tissues. [4], [6]

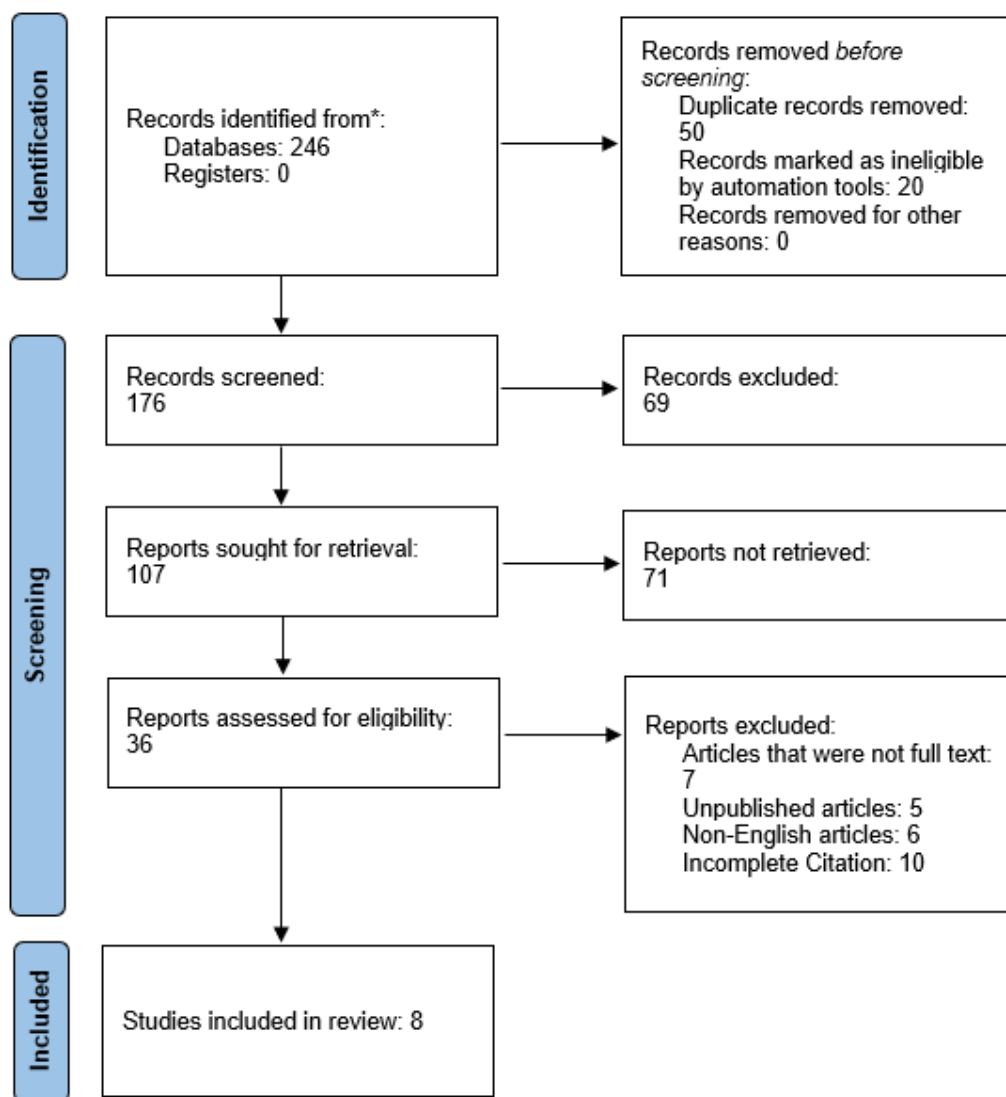
It is highly predictive of malignancy when certain MRI characteristics of parotid gland tumors obtained from conventional MRI, such as an ill-defined margin and low signal intensity (SI) on T2 weighted images (T2WIs), are present. [7]

To effectively supplement traditional MRI, apparent diffusion coefficient (ADC) values derived from diffusion-weighted imaging (DWI) data provide additional quantitative data regarding the random transport of water molecules in tissues. [8]

Based on this, it is safe to claim that MRI, together with its extra components, aids in the diagnosis of the tumor and pertinent traits needed to create a successful recovery plan.

This meta-analysis aims to ascertain the effectiveness of MRI versus the role of MRI with diffusion-weighted imaging.

PRISMA Flowchart (Figure1)



METHODOLOGY:-

DATA COLLECTION

For the collection of the data, a search was done by two individuals using PubMed, Google Scholar, and Cochrane Library databases for all available relevant literature. We only considered Full - Text Articles written only in English, for this study.

The medical subject headings (MeSH) and keywords 'Parotid carcinoma imaging', 'Result of Diffusion-weighted imaging (DWI) MRI Scan in parotid carcinoma diagnosis', and 'MRI in Parotid carcinoma' were used. References, reviews, and meta-analyses were scanned for additional articles.

INCLUSION AND EXCLUSION CRITERIA

Titles and abstracts were screened, and Duplicates and citations were removed. References of relevant articles were reviewed for possible additional literature. Papers with detailed patient information and statically proved and well-calculated results were selected.

We searched for papers that show more accurate diagnoses, where procedures considered were MRI with DWI and Only MRI in the diagnosis of parotid carcinoma.

The inclusion criteria were as follows:: (1) Literature that provided information about the accurate diagnosis with MRI(DWI) and only MRI ; (2) papers published in English; (3) papers with appropriate patient criteria.

The exclusion criteria were: (1) articles that were not full text, (2) unpublished articles, and (3) non-English articles.

DATA EXTRACTION

Each qualifying Literature was independently assessed by two reviewers. Each article was examined for the number of patients, age, sex, procedure modality, comorbidity, and incidence of the predecided complications. Further debate or consideration with the author and a third party was used to resolve conflicts. This study's quality was assessed using the modified Jadad score. In conclusion, As stated by PRISMA, a total of 8 RCTs with a total of 944 patients were selected, out of which 3 RCTs with a total of 356 patients were selected for MRI and 5 RCTs with a total of 588 patients were selected for MRI+DWI study.

ASSESSMENT OF STUDY QUALITY

Two writers independently assessed the quality of each included RCT. This test consists of 10 questions, each with a score between 0 and 2, with 20 being the maximum possible overall score. Two authors evaluated each article independently based on the above criteria. The interobserver bias for study selection was determined using the weighted Cohen's kappa (K) coefficient. For deciding the bias risk for RCTs, we also employed the Cochrane tool. No assumptions were made about any missing or unclear information. there was no financial aid involved in collecting or reviewing data.

STATISTICAL ANALYSIS

The statistical software packages RevMan (Review Manager, version 5.3), SPSS (Statistical Package for the Social Sciences, version 20), Google Sheets, and Excel in Stata 14 were used to create the statistical analyses. The data was created and entered into analytic software [9]. Fixed- or random-effects models were used to determine Sensitivity, Specificity, positive predictive value (PPV), diagnostic odds ratios (DOR), and relative risk (RR) with 95 percent confidence intervals to examine critical clinical outcomes (CIs). Diagnosis accuracy and Younden index were calculated for each result. Individual study sensitivity and specificity were plotted on

Forest plots and in the receiver operating characteristic (ROC) curve. The forest plot and Fagan's Nomogram were used to explain the sensitivity and specificity of different papers.

BIAS STUDY

The risk of bias was estimated by using the QUADAS-2 analysis tool. This tool includes 4 domains as Patient selection, Index test, Reference standard, Flow of the patients, and Timing of the Index tests.

RESULT:-

Table 1: Table of Description of papers

Author Name and year	Duration	Mean Age	Sample size	Study Design	Index test	Reference test	Favorable towards
Can Wang 2021[5]	January 2004 – December 2017	57.6	113	Retrospective review	CT + MRI	Surgery and Histopathologic examination	CT + MRI
Hao Hu 2021[10]	November 2019 – October 2020	50.4	58	Retrospective review	3D pseudo-continuous arterial spin labeling MRI	Surgery	MRI
Koshi Ikeda 1996[11]	January 1990 – August 1993	-	82	Retrospective review	MRI	Histopathologic examination	MRI
Hidetake Yabuuchi 2008[12]	April 2004 – September 2007	61	47	Retrospective review	MRI DWI + MRI DCE	Surgery + Histopathologic examination	MRI DWI + DCE
Irfan Celebi 2013[13]		47	75	Introspective	MRI DWI	Biopsy/FNAC	MRI DWI
J. Lechner Goyault 2010[14]	April 2005 – February 2008	59.4	60	Retrospective review	MRI DWI	Histopathologic examination	MRI DWI
Xiaofeng Tao 2017[15]	October 2004 – December 2012	52	148	Retrospective review	MRI + DWI + DCE	Surgery + Histopathologic examination	MRI + DWI + DCE
Ying Yuan 2016[16]	January 2010 – December 2014	48.4	207	Retrospective review	MRI + DWI + DCE	Histopathologic examination	MRI + DWI

MRI + DWI

Study	TP	FP	FN	TN	Sensitivity (95% CI)	Specificity (95% CI)	Sensitivity (95% CI)	Specificity (95% CI)
Hidetake Yabuuchi 2008	10	5	4	30	0.71 [0.42, 0.92]	0.86 [0.70, 0.95]		
Irfan Celebi 2013	30	8	17	20	0.64 [0.49, 0.77]	0.71 [0.51, 0.87]		
J Lechner Goyault 2011	14	4	2	40	0.88 [0.62, 0.98]	0.91 [0.78, 0.97]		
K Ikeda 1996	9	3	8	29	0.53 [0.28, 0.77]	0.91 [0.75, 0.98]		
Xiaofeng Tao 2017	40	6	7	95	0.85 [0.72, 0.94]	0.94 [0.88, 0.98]		

MRI

Study	TP	FP	FN	TN	Sensitivity (95% CI)	Specificity (95% CI)	Sensitivity (95% CI)	Specificity (95% CI)
Can Wang 2021	123	20	34	35	0.78 [0.71, 0.85]	0.64 [0.50, 0.76]		
Hao Hu 2021	16	2	4	38	0.80 [0.56, 0.94]	0.95 [0.83, 0.99]		
K Ikeda 1996	31	7	7	39	0.82 [0.66, 0.92]	0.85 [0.71, 0.94]		

Figure 2: Forest chart for MRI+DWI and MRI.

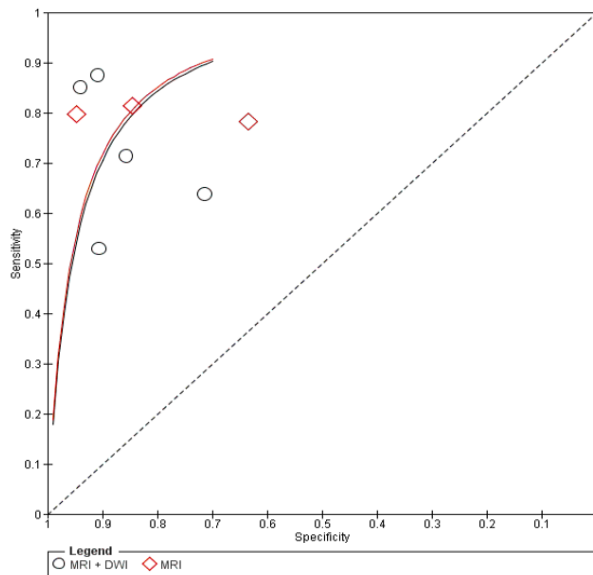


Figure 3: Summary of SROC Plot.

MRI

Here, Table 1 describes all the description of papers used for the study. As the result calculated above, in the forest chart (figure 2), the comparison of the sensitivity and specificity of different papers can be seen. The same can be seen depicted in the SROC curve (figure 3). A total of 3 RCTs with 356 patients were selected for the study. The value of True positive is 170, True Negative is 112, False negative is 45, and False Positive is 29. With a confidence interval of 95%, Sensitivity, specificity, and Positive Predictive values were also calculated and summarised. A summary of this is available in Figure 2. The Sensitivity of the MRI is 0.790 with a CI of 95% in a range of (0.772 to 0.809) the mean being (0.0183). The Specificity of the MRI is 0.794 with a CI of 95% in a range of (0.613 to 0.975) the mean being (0.181). The positive predictive value (PPV) for the MRI is 0.854 with a CI of 95% in a range of (0.812 to 0.895) the mean being (0.0416).

The summary of the ROC curve is illustrated in Figure 3. It describes that the area under the ROC (AUC) for MRI is 0.7925 and the overall diagnostic odds ratio (DOR) is 14.59. It also describes the Diagnostic Accuracy and The Youden index, which are 0.792 and 0.585 respectively.

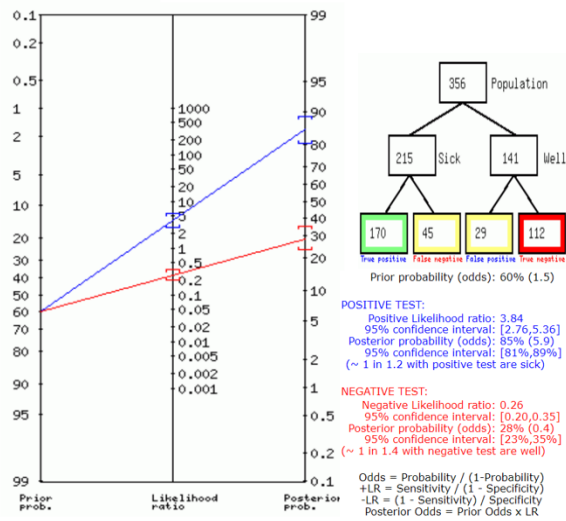


Figure 4: Fegan's analysis for MRI.

Figure 4 shows the summary of Fagan plots analysis for all the studies of MRI, it shows a Prior probability of 60% (1.5); a Positive likelihood ratio of 3.84; a probability of post-test 85% (5.9); a Negative likelihood ratio of 0.26, and a probability of post-test 28% (0.4).

MRI+DWI

Above, Table 2 Describes all the description of papers used for the MRI+DWI study. As the result showed above, in the forest chart (Figure 2), the comparison of the sensitivity and specificity of different papers can be seen. The same is illustrated in the SROC curve (figure 3). A total of 5 RCTs with 588 patients were selected for the study. The value of True positive is 215, True Negative is 214, False negative is 133, and False Positive is 26. With a confidence interval of 95%, Sensitivity, specificity, and Positive Predictive values were calculated. A summary of this is available in Figure 2. The Sensitivity of the MRI+DWI is 0.618 with a CI of 95% in a range of (0.498 to 0.737); the mean being (0.119). The Specificity of the MRI+DWI is 0.892 with a CI of 95% in a range of (0.813 to 0.97) the mean being (0.079). The positive predictive value (PPV) for MRI+DWI is 0.892 with a CI of 95% in a range of (0.801 to 0.984) the mean being (0.091).

The summary of the ROC curve is described in Figure 3. It shows that the area under the ROC (AUC) for the MRI+DWI is 0.75474 and the overall diagnostic odds ratio (DOR) is 13.305. Also, The Diagnostic Accuracy and Youden index are 0.73 and 0.509 respectively.

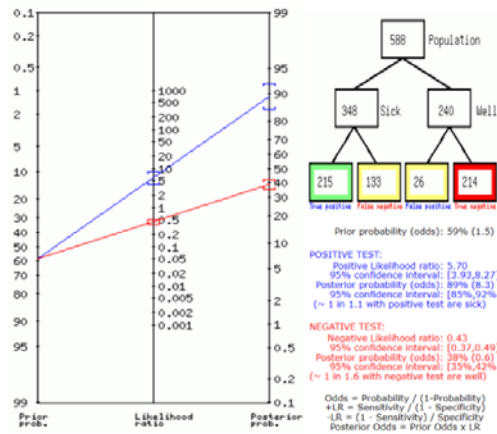


Figure 5: Fegan’s analysis for MRI+DWI.

Figure 5 describes the summary of Fagan plots analysis for all the studies of MRI+DWI, it shows a Prior probability of 59% (1.5); a Positive likelihood ratio of 5.7; a probability of post-test 89% (8.3); a Negative likelihood ratio of 0.43, and a probability of post-test 38% (0.6).

Bias Study:

No.s Author Name and Year	Risk Of Bias				Applicability Concerns		
	Patient Selection	Index Test	Reference Standard	Flow and Timing	Patient Selection	Index Test	Reference Standard
(MRI)							
1 Can Wang 2021	+	+	+	+	+	+	+
2 Hao Hu 2021	?	+	+	+	+	+	+
3 K Ikeda 1996	?	+	-	+	-	?	-
(MRI+DWI)							
Hidetake Yabuuchi 2001	+	+	+	+	+	+	?
4 Irfan Celebi 2013	+	+	?	+	+	+	-
5 J Lechner Goyault 2011	+	+	+	+	+	+	?
6 K Ikeda 1996	?	+	-	+	-	?	-
7 Xiaofeng Tao 2017	+	+	?	+	+	+	-
8 Ying Yuan 2016	+	+	?	+	+	+	-

Figure 6: Table of Bias study.

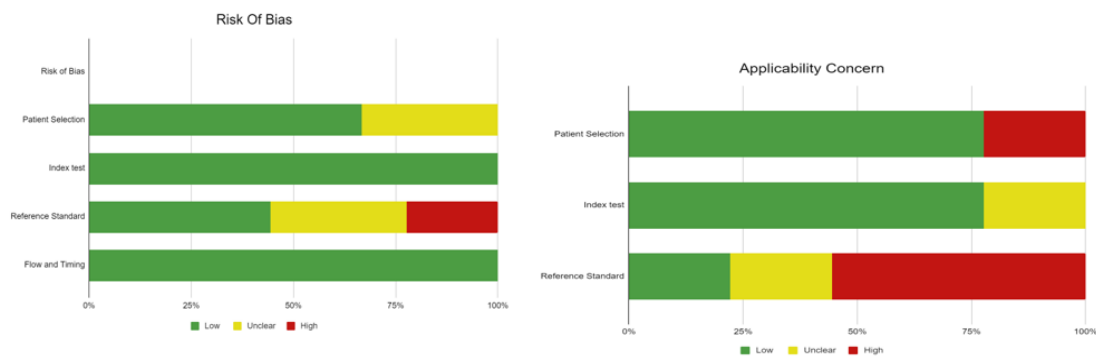


Figure 7: Summary of Bias Study.

Publication Bias

The summary of publication bias for MRI+DWI and MRI is shown in (Figure 6 and Figure 7). For the publication bias, In, patient selection, bias was low in 6 studies and unclear in 3. In the index test, it was low in 9 studies. While the reference standard was low in 4, unclear in 3, and high in 2. The flow and timing were low in 9. The applicability concerns in patient selection were low in 7 and high in 2. The index test was low in 7 and unclear in 2. The reference standard was low in 2, unclear in 2, and high in 5.

Discussion:

As different surgical techniques are used for benign and malignant lesions, the Preoperative determination of malignancy in the parotid gland tumors is clinically important [17]. Some MRI features obtained from conventional MRI for parotid gland lesions, such as ill-defined margin and low signal intensity on T2WI, are major indicators of malignancy [7], [18]. However, some researchers hold the opposite conclusion and the sensitivities and specificities of these results have been identified as low and significantly overlapping[19], [20]. DWI has been verified to be a rather beneficial technique for assessing the characteristics of head and neck tumors.[21]–[25].

For Parotid gland neoplasms, Functional MRI (DWI) can help to identify an initial diagnosis of a benign tumor rather than a malignant one, especially in those cases where the tumor is well-defined. Pleomorphic adenomas classically involve a significant amount of myxomatous tissue, which is the root for the less restriction of water diffusion, high ADCs, and high signal intensity on the ADC map when compared to metastatic nodes or primary salivary gland carcinomas. Warthin tumors, in contrast, may include ample amounts of densely packed lymphoid cells, which accounts for their lower ADCs, which overlap with those of malignancy; however, Warthin tumors are usually highly vascular compared with pleomorphic adenomas and malignant salivary gland tumors.[26] Consequently, IVIM can help to differentiate benign from malignant tumors by using high Diffusion to reflect higher pseudo-diffusion in the microcirculation in Warthin tumors and high Diffusion to reflect less restricted pure diffusion in pleomorphic adenoma.

Therefore, we tried to compare the diagnostic accuracy of the simple MRI with DWI MRI for parotid gland neoplasms. The Sensitivity of the MRI is 0.790 (CI95%,0.772-0.809) and the Specificity of the MRI is 0.794 (CI95%,0.613-0.975). and the Sensitivity of the MRI+DWI is 0.618 (95%,0.498-0.737) and the Specificity of the MRI+DWI is 0.892 (95%,0.813-0.97). There is very little improvement in Specificity here but concerns about resource usefulness and technicality regarding the procedure remain. Here we also describe the diagnostic odds ratio and Youden index for both, it shows very little or no improvement.

Therefore it is safe to say that neither simple MRI nor DWI MRI is independently and thoroughly helpful for accurate diagnosis and early detection of Parotid malignancy or in distinguishing benign lesions from malignant ones. However, using DWI MRI and Simple MRI together for the detection and differentiation of benign and malignant lesions would be very accommodating. We recommend for more powerful modalities like DCE-MRI should be incorporated for the detection and defining of the margins of parotid gland lesions before surgery. A combination of DCE-MRI with DWI has been confirmed to advance the MRI performance for characterizing benign and malignant parotid gland tumors and the difference in distinguishing histological types of benign tumors.[14] [12].

Limitations:

This meta-analysis did not add the other articles from different languages other than English. The ADC value varies depending on equipment and hospital imaging method which is why the results regarding ADC and TIC are not liberally accurate. We were not able to quantify the patient age factor as it changes the parotid gland signals in MRI, so this suggests dividing future studies into the different age groups for better results and quantification process.

Conclusion:

In conclusion, if parotid gland tumors are shown on MRI as being of irregular shape malignancy should be strongly considered. In addition to simple MRI or Single DWI MRI, A combination of both would detect higher lesions and it should be helpful for staging and early diagnosis purposes only. For perfect anatomical understanding and to plan surgical approaches, more studies, and research should be done exploring newer and more powerful modalities like DCE MRI.

References

- [1] A. O. Lawal, A. O. Adisa, B. Kolude, and B. F. Adeyemi, "Malignant salivary gland tumours of the head and neck region: A single institutions review," *Pan African Medical Journal*, vol. 20, 2015, doi: 10.11604/pamj.2015.20.121.3458.
- [2] P. D. Lam *et al.*, "Differentiating benign and malignant salivary gland tumours: Diagnostic criteria and the accuracy of dynamic contrast-enhanced MRI with high temporal resolution," *British Journal of Radiology*, vol. 88, no. 1049, 2015, doi: 10.1259/bjr.20140685.
- [3] H. C. Thoeny, "Imaging of salivary gland tumors," *Cancer Imaging*, vol. 7, no. 1, 2007. doi: 10.1102/1470-7330.2007.0008.
- [4] W. Chen *et al.*, "Differentiation of salivary gland tumor using diffusion-weighted imaging with a fractional order calculus model," *British Journal of Radiology*, vol. 93, no. 1113, 2020, doi: 10.1259/bjr.20200052.
- [5] C. Wang, Q. Yu, S. Li, J. Sun, L. Zhu, and P. Wang, "Carcinoma ex pleomorphic adenoma of major salivary glands: CT and MR imaging findings," *Dentomaxillofacial Radiology*, vol. 50, no. 7, 2021, doi: 10.1259/dmfr.20200485.
- [6] D. Maraghelli *et al.*, "Magnetic resonance imaging of salivary gland tumours: Key findings for imaging characterisation," *European Journal of Radiology*, vol. 139, 2021. doi: 10.1016/j.ejrad.2021.109716.
- [7] A. Christe, C. Waldherr, R. Hallett, P. Zbaeren, and H. Thoeny, "MR imaging of parotid tumors: Typical lesion characteristics in MR imaging improve discrimination between benign and malignant disease," *American Journal of Neuroradiology*, vol. 32, no. 7, 2011, doi: 10.3174/ajnr.A2520.
- [8] H. Yerli, E. Aydin, N. Haberal, A. Harman, T. Kaskati, and S. Alibek, "Diagnosing common parotid tumours with magnetic resonance imaging including diffusion-weighted imaging vs fine-needle aspiration cytology: A comparative study," *Dentomaxillofacial Radiology*, vol. 39, no. 6, 2010, doi: 10.1259/dmfr/15047967.
- [9] D. Desai, "Dev's Formulae for Diagnostic Test Accuracy Meta-analysis," *medRxiv*, p. 2023.03.27.23287186, Jan. 2023, doi: 10.1101/2023.03.27.23287186.
- [10] H. Hu *et al.*, "Influence of post-label delay time on the performance of 3D pseudo-continuous arterial spin labeling magnetic resonance imaging in the characterization of parotid gland tumors," *Eur Radiol*, vol. 32, no. 2, 2022, doi: 10.1007/s00330-021-08220-1.

- [11] K. Ikeda, T. Katoh, S. K. Ha-Kawa, H. Iwai, T. Yamashita, and Y. Tanaka, "The usefulness of MR in establishing the diagnosis of parotid pleomorphic adenoma," *American Journal of Neuroradiology*, vol. 17, no. 3, 1996.
- [12] H. Yabuuchi *et al.*, "Parotid gland tumors: Can addition of diffusion-weighted MR imaging to dynamic contrast-Enhanced MR imaging improve diagnostic accuracy in characterization?," *Radiology*, vol. 249, no. 3, 2008, doi: 10.1148/radiol.2493072045.
- [13] I. Celebi, A. S. Mahmutoglu, A. Ucgul, S. M. Ulusay, T. Basak, and M. Basak, "Quantitative diffusion-weighted magnetic resonance imaging in the evaluation of parotid gland masses: A study with histopathological correlation," *Clin Imaging*, vol. 37, no. 2, 2013, doi: 10.1016/j.clinimag.2012.04.025.
- [14] J. Lechner Goyault, S. Riehm, A. Neuville, A. Gentine, and F. Veillon, "Interest of diffusion-weighted and gadolinium-enhanced dynamic MR sequences for the diagnosis of parotid gland tumors," *Journal of Neuroradiology*, vol. 38, no. 2, 2011, doi: 10.1016/j.neurad.2009.10.005.
- [15] "28299943".
- [16] Y. Yuan, W. Tang, and X. Tao, "Parotid gland lesions: Separate and combined diagnostic value of conventional MRI, diffusion-weighted imaging and dynamic contrast-enhanced MRI," *British Journal of Radiology*, vol. 89, no. 1060, 2016, doi: 10.1259/bjr.20150912.
- [17] J. M. Scianna and G. J. Petruzzelli, "Contemporary management of tumors of the salivary glands," *Current Oncology Reports*, vol. 9, no. 2, 2007. doi: 10.1007/s11912-007-0011-6.
- [18] "Christe A, Waldherr C, Hallett R et al. MR imaging of parotid tumors: typical lesion characteristics in MR imaging improve discrimination between benign and malignant disease. AJNR Am J Neuroradiol 2011; 32: 1202 – 1207," *Neuroradiologie Scan*, vol. 2, no. 01, 2012, doi: 10.1055/s-0030-1257135.
- [19] V. Q. Joe and P. L. Westesson, "Tumors of the parotid gland: MR imaging characteristics of various histologic types," *American Journal of Roentgenology*, vol. 163, no. 2, 1994, doi: 10.2214/ajr.163.2.8037045.
- [20] D. M. Yousem, M. A. Kraut, and A. A. Chalian, "Major Salivary Gland Imaging," *Radiology*, vol. 216, no. 1, pp. 19–29, Jul. 2000, doi: 10.1148/radiology.216.1.r00jl4519.
- [21] "17213436".
- [22] N. Matsushima, M. Maeda, M. Takamura, and K. Takeda, "Apparent diffusion coefficients of benign and malignant salivary gland tumors. Comparison to histopathological findings," *Journal of Neuroradiology*, vol. 34, no. 3, 2007, doi: 10.1016/j.neurad.2007.04.002.
- [23] J. Wang *et al.*, "Head and neck lesions: Characterization with diffusion-weighted echo-planar MR imaging," *Radiology*, vol. 220, no. 3, 2001, doi: 10.1148/radiol.2202010063.
- [24] P. Wang, J. Yang, Q. Yu, S. Ai, and W. Zhu, "Evaluation of solid lesions affecting masticator space with diffusion-weighted MR imaging," *Oral Surgery, Oral Medicine, Oral Pathology, Oral Radiology and Endodontology*, vol. 109, no. 6, 2010, doi: 10.1016/j.tripleo.2010.01.005.
- [25] N. Yoshino *et al.*, "Salivary glands and lesions: Evaluation of apparent diffusion coefficients with split-echo diffusion-weighted MR imaging - Initial results," *Radiology*, vol. 221, no. 3, 2001, doi: 10.1148/radiol.2213010131.

- [26] Y. L. Dai and A. D. King, "State of the art MRI in head and neck cancer," *Clinical Radiology*, vol. 73, no. 1. 2018. doi: 10.1016/j.crad.2017.05.020.