

A Transdiagnostic Structural Brain Signature of Parkinsonian and Essential Tremor

Christian Ineichen^{1,2}, Fraser Callaghan³, Heide Baumann-Vogel^{1,2}, Fabian Büchele^{1,2}, Ruth O’Gorman Tuura³, Christian R. Baumann^{1,2}, Simon J. Schreiner^{1,2,*}

¹Department of Neurology, University Hospital Zurich, University of Zurich, Zurich, Switzerland

²Clinical Neuroscience Center, University Hospital Zurich, University of Zurich, Zurich, Switzerland

³Center for MR Research, University Children's Hospital Zurich, Zurich, Switzerland

*corresponding author:

Simon Schreiner, Department of Neurology, University Hospital Zurich, University of Zurich, simon.schreiner@usz.ch

Abstract

Introduction: Parkinson’s disease (PD) and essential tremor (ET) are heterogeneous and show overlapping features at the same time. These heterogeneities pose challenges for clinical management and research and may indicate shared mechanisms for tremor. To test the hypothesis that regional brain volumes correspond to phenotypes rather than diagnosis, we compared structural MRI volumetrics between patients with ET or PD with (PD-T) or without tremor-dominant phenotype (PD-nT).

Methods: We studied 166 patients (109 PD-nT, 39 PD-T, 18 ET) who were evaluated for deep brain stimulation. All patients underwent MRI, and standardized assessment of motor symptoms. We compared regional brain volumes between patients with ET, PD-T, or PD-nT.

Results: We found that three subcortical regions – namely the thalamus, pallidum, and pre-cerebellar and upper brainstem - differed across groups. These volumes were smallest in ET, intermediate (or similar to ET) in PD-T, and largest in PD-nT. Smaller volumes of the thalamus and brainstem correlated with more severe and less levodopa-responsive tremor in PD. Sub-segmentation of the brainstem indicated involvement of upper and pre-cerebellar brainstem (pons, superior cerebellar peduncle, to a lesser degree also midbrain). In contrast to the subcortical findings, cortical thickness in frontal and parietal regions was thinner in PD-nT compared to PD-T patients.

Conclusion: The clinical heterogeneity and overlap of PD and ET show corresponding structural brain changes along a phenotypic spectrum. Specifically, a transdiagnostic structural brain signature of tremor consists of reduced subcortical brain volumes in the cerebello-thalamic system and interconnected regions, suggesting shared mechanisms of tremor in PD and ET.

NOTE: This preprint reports new research that has not been certified by peer review and should not be used to guide clinical practice.

Introduction

Heterogeneity is a key feature of Parkinson's disease (PD) and essential tremor (ET). Pathophysiological heterogeneity entails how specific aetio-pathophysiological processes can supposedly lead to selective alterations of certain brain systems resulting in distinct clinical phenotypes. A prominent example of heterogeneity in PD relates to tremor, which can be absent or predominant (PD-T) and overlapping with ET [1]. This phenotypic dichotomy corresponds to other phenotype-specific differences in progression, non-motor burden, or post-mortem pathology, which collectively support the notion of distinct underlying etiologies [1-3]. Similarly, ET, phenotypically defined as an isolated tremor syndrome, is highly heterogeneous regarding age of onset, progression, symptom severity, and response to tremor treatments [4]. The list of possible etiological factors is long and pathological findings are heterogeneous, fueling the ongoing scientific debate as to whether or not ET represents a neurodegenerative disorder [5, 6].

The phenotypic heterogeneities and overlap of PD and ET pose major challenges for clinical management and research by interfering with diagnostic accuracy, therapeutic decisions, prognostication, and development of personalized treatments. Therefore, biomarkers reflecting the underlying pathophysiology are needed. Neuroimaging studies have provided valuable insights into heterogeneity: In PD, akinetic-rigid symptoms – but not tremor – closely relate to nigrostriatal dopaminergic depletion [7], and related dysfunction of basal ganglia networks [8]. PD-related tremor, on the other hand, has been linked with combined dysfunction of basal ganglia (e.g. internal pallidum) and cerebello-thalamic networks [9, 10]. Finally, ET has been related to a selective dysfunction of the cerebello-thalamic network solely [9]. Furthermore, MRI studies have corroborated structural underpinnings of motor phenotypes [11-13], showing regional atrophy within the cerebello-thalamic-cortical system both in PD-T (compared to PD without tremor) and ET patients (compared to controls) [11, 14]. These insights suggest a pathophysiological continuum ranging from pure basal ganglia dysfunction in akinetic-rigid PD

to pure cerebello-thalamic dysfunction in ET, with PD-T showing combined impairment in both systems. Still, additional evidence is warranted.

The aim of the present study was to apply structural MRI to identify imaging-based biomarkers along a clinical spectrum from PD to ET. More specifically, we tested if regional brain volumes correspond to phenotypes (motor syndromes with or without predominant tremor) or disease classification (PD or ET) (Figure 1). Further, we investigated if MRI-derived biomarkers correlate with clinical outcomes. Therefore, we studied clinical and structural MRI features in patients with long-standing PD or ET, who were evaluated to undergo deep brain stimulation. We first compared regional brain volumes between ET and PD patients with (PD-T) or without (PD-nT) tremor-dominant phenotype. Regional brain volumes that differed between groups were carried further in the analysis and related to the severity and levodopa response of cardinal motor symptoms. We hypothesized that biomarkers derived from structural MRI (1) correspond to motor phenotypes rather than diagnosis, (2) involve regions previously implicated in the pathophysiology of motor symptoms, and (3) correlate with the severity and treatment response of motor symptoms.

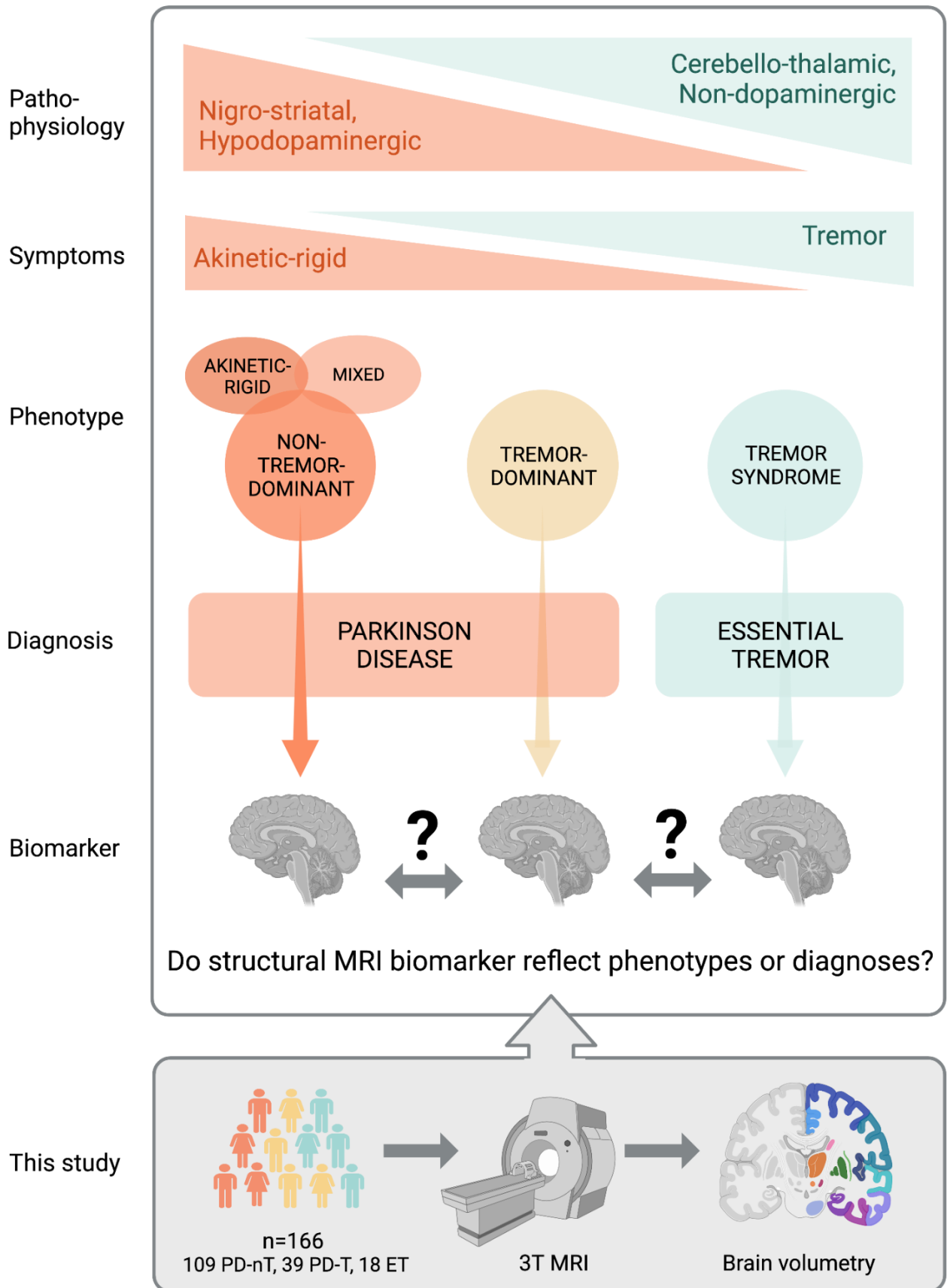


Figure 1: Background, study-aims and -design

Parkinson's disease (PD) and essential tremor (ET) can be conceptualized along a spectrum ranging from pure nigrostriatal, to combined, to pure cerebello-thalamic dysfunction, resulting in distinct clinical phenotypes ranging from akinetic-rigid, to mixed, to tremor-dominant PD, and ET. Biomarkers that inform about the heterogeneity of PD and ET would aid in disease understanding and treatment. Therefore, we compared structural MRI volumetrics between patients with long-standing ET or PD with (PD-T) or without tremor-dominant phenotype (PD-nT). We aimed to determine if biomarkers derived from structural MRI (1) correspond to motor phenotypes or diagnosis, (2) involve regions of pathophysiological relevance, and (3) correlate with symptom severity and response to levodopa. Image created with BioRender.com.

Methods

Patients

We retrospectively included consecutive patients with long-standing PD or ET who were assessed for eligibility to undergo deep brain stimulation at the Department of Neurology, University Hospital Zurich, Switzerland, between 2012 and 2018. Inclusion criteria were diagnosed PD or ET according to international diagnostic criteria [4, 15], available MRI with sufficient quality and documented standardized motor examinations. We collected the following clinical data: age, sex, disease duration, dopaminergic medication, Hoehn Yahr stage. In all patients, we documented the body side with more severe motor symptoms. In ET patients, upper extremity tremor was documented using the Washington Heights-Inwood Genetic Study of Essential Tremor (WHIGET) score [16]. Some ET patients were assessed again after the oral intake of wine (4-5 dl), to test for alcohol-related improvement of tremor. All PD patients underwent a levodopa challenge test, during which an experienced, specialized movement disorder nurse performed a standardized neurological examination collecting the third (motor) part of the Unified Parkinson's Disease Rating Scale (UPDRS) during practically defined OFF (after >12 hours of drug withdrawal) and ON state (45-60 min after oral intake of levodopa). All patients gave written consent for videotaping, allowing accurate rating of motor symptoms by the examiner and an experienced movement disorder expert (C.R.B). We calculated UPDRS III total scores, and subscores for bradykinesia, rigidity, rest tremor, and postural/kinetic tremor [17]. Based on the predominance of cardinal motor symptoms the attending neurologist assigned and documented an empirical motor subtype using the commonly used distinction of tremor-dominant, akinetic-rigid, or mixed types [1, 3]. For the purpose of the present study, we analyzed PD phenotypes with (PD-T) or without predominant tremor (PD-nT), the latter comprising akinetic-rigid and mixed phenotypes. Patients with ET were phenotyped as ET or ET plus based on the presence of additional neurological soft signs [4]. We only included ET patients with ET or ET plus with parkinsonian soft signs, and excluded patients with ET plus

with atactic (n=3) or dystonic soft signs (n=1), or isolated head tremor (n=1), allowing to investigate PD and ET patients along a spectrum of akinetic-rigid and tremor syndromes. Out of 21 remaining ET patients, we excluded two more (one who had deep brain stimulation leads in the thalamus, one patient with a cerebellar ischemic lesion). Additional patients had to be excluded owing to MRI quality (see section below).

MRI data acquisition

All patients underwent MRI scanning including a T1-weighted structural MRI sequence (turbo field echo, scan mode=3D, voxel size 1x1x1 mm, TR=10.65 ms, TE=6.04 ms) using a Philips 3 Tesla Ingenia scanner (Philips Healthcare, Cleveland, OH, USA), at the Department of Radiology, University Hospital Zurich, Switzerland.

MRI image processing

Structural T1-weighted images were analyzed using the automated image segmentation and analysis functions of FreeSurfer (version 7.1, <http://surfer.nmr.mgh.harvard.edu>) to perform cortical reconstruction and volumetric segmentation of the whole brain [18], as previously performed [19]. In addition, we performed Bayesian segmentation of brainstem regions including the midbrain, pons, superior cerebellar peduncle (SCP), and medulla oblongata [20]. For each participant, preprocessing included: correction of signal intensity non-uniformity in T1 images, smoothing and inflation of cortical surface data and removal of topological defects [18]. Freesurfer outputs of interest were volume and cortical thickness. Trained analysts visually inspected segmentation outputs. Scans with insufficient quality (7 PD, 1 ET) or critical lesions (1 ET with cerebellar ischemic lesion) were discarded. Cortical thickness was quality-checked by performing an outlier-analysis. No cases had to be removed.

Statistical maps of the between-group differences and the clinical associations were processed in FreeSurfer to visualize the cortical results. Data from all participants were pooled to create a study-specific group template by resampling each participant's data into a common space, performing spatial smoothing, and then combining all scans into a single file. For the subcortical findings, a surface map was generated to display the results on an average brain. We analyzed volumes of the putamen, caudate, pallidum, thalamus, nucleus accumbens, cerebellum, and brainstem as well as its subregions medulla oblongata, pons, midbrain, and SCP. The ventral diencephalon and vessel region from the standard Freesurfer output were not included because these regions contain multiple nuclei. Regional volumes were averaged across hemispheres and corrected for total intracranial volume, age, and sex using the residuals adjustment method [21].

Statistical analysis

We first compared subcortical volumes (and clinical data) between groups of PD-T, PD-nT and ET patients using the Kruskal-Wallis-Test with Dunn's post hoc test for continuous data, or the Chi-square test for categorical data. PD-specific data such as UPDRS III scores or levodopa equivalent dose (LED) were compared between PD-T and PD-nT patients using the Wilcoxon rank-sum test. Brain regions with significant group differences were further related to UPDRS III subscores and their improvement after oral intake of levodopa, using partial Spearman rank-correlation controlling for age, sex, and (in PD) disease duration. In ET, disease duration was not used as a control variable, owing to a very long disease course in some of the patients. Significant correlations were followed up by separate assessment in each group.

Next, we tested for differences at the cortical level. We used a general linear model (GLM), to assess if cortical thickness (dependent factor) differed as a function of phenotype (ET, PD-T, PD-nT; independent factor in the design matrix), controlling for age and sex. All subjects were registered to a normalized template allowing analysis in a common domain. The spatial image distribution was smoothed with a circularly symmetric Gaussian kernel of 15 mm full width

half maximum to provide normal distribution of the results. A FreeSurfer-programmed ‘Different Onset, Same Slope’ (DOSS) GLM was fitted to the spatially-normalized thickness data to create statistical maps displaying the relationships between cortical thickness and phenotypes because we wanted to examine whether a main effect of group exists independent of participant age and sex. The DOSS model constrains the slopes of any continuous variables to evolve at the same rate in all groups. Therefore, we first confirmed that there were no age-related differences on cortical thickness within the groups. Results were corrected for multiple comparisons using Freesurfer’s clusterwise correction, which considers the amount of smoothing and the number of contiguous significant points in the normalized domain. In addition, p-values were adjusted for two hemispheres using the Bonferroni correction.

Results

Table 1 displays demographics and clinical characteristics of all subjects and each diagnostic group (n = 109 PD-nT, 39 PD-T, 18 ET). As expected, compared to PD-nT patients, PD-T patients demonstrated more severe tremor, and less severe akinetic-rigid and axial symptoms during the OFF state. In the ON state, only tremor remained more severe in PD-T patients compared to PD-nT, presumably indicating a higher degree of levodopa-resistance of tremor compared to the other motor symptoms (Figure S1). Likewise, PD-T patients showed greater improvement of rest tremor and less improvement of axial symptoms compared to PD-nT. Total UPDRS III did not differ between groups during OFF and ON. The PD-nT group received a higher LED than the PD-T group. ET patients were older and had a longer disease duration compared to PD-T and PD-nT patients, while age did not significantly differ between PD-T and PD-nT patients.

Structural MRI biomarkers reflect phenotypes rather than diagnosis

Volumes of the thalamus, pallidum, and brainstem differed between groups (Fig. 2 A). PD-T patients showed smaller thalamic volumes compared to PD-nT patients (p=0.01), but similar

thalamic volumes compared to ET patients ($p=0.96$) (Fig. 2 B). Thalamic volumes tended to be smaller in ET compared to PD-nT patients, but this difference did not reach statistical significance ($p=0.25$) (Fig. 2 B). While PD-T and ET patients showed smaller pallidal volumes compared to PD-nT patients, statistically significant differences were limited to the comparison of ET with PD-nT patients ($p=0.002$).

PD-T and ET patients had similar brainstem volumes compared with each other, but significantly smaller brainstem volumes compared with PD-nT patients (PD-T vs. PD-nT: $p=0.046$, ET vs. PD-nT: $p=0.033$) (Fig. 2 B). A subsequent analysis focused on the brainstem showed that all subregions differed between groups except for the medulla oblongata, with strongest differences pertaining to the pons (group main effects: pons: $p=0.004$; SCP: $p=0.013$; midbrain: $p=0.023$). PD-T and ET patients had smaller pontine volumes compared to PD-nT patients ($p=0.049$ and $p=0.021$, respectively). Volume of the SCP was smaller in PD-T compared to PD-nT patients ($p=0.014$), while midbrain post-hoc contrasts remained at statistical trend-level (ET vs. PD-nT: $p=0.075$; PD-T vs. PD-nT: $p=0.127$). All brainstem subregions were similar between ET and PD-T patients (all $p>0.78$).

Taken together, results revealed that differences followed a gradient, with subcortical volumes being largest in PD-nT, intermediate in PD-T, and smallest in ET. Further, differences pertained to phenotypes rather than diagnosis, that is, PD-nT patients showed larger volumes compared to PD-T or ET, while volumes of the latter two groups did not significantly differ from each other.

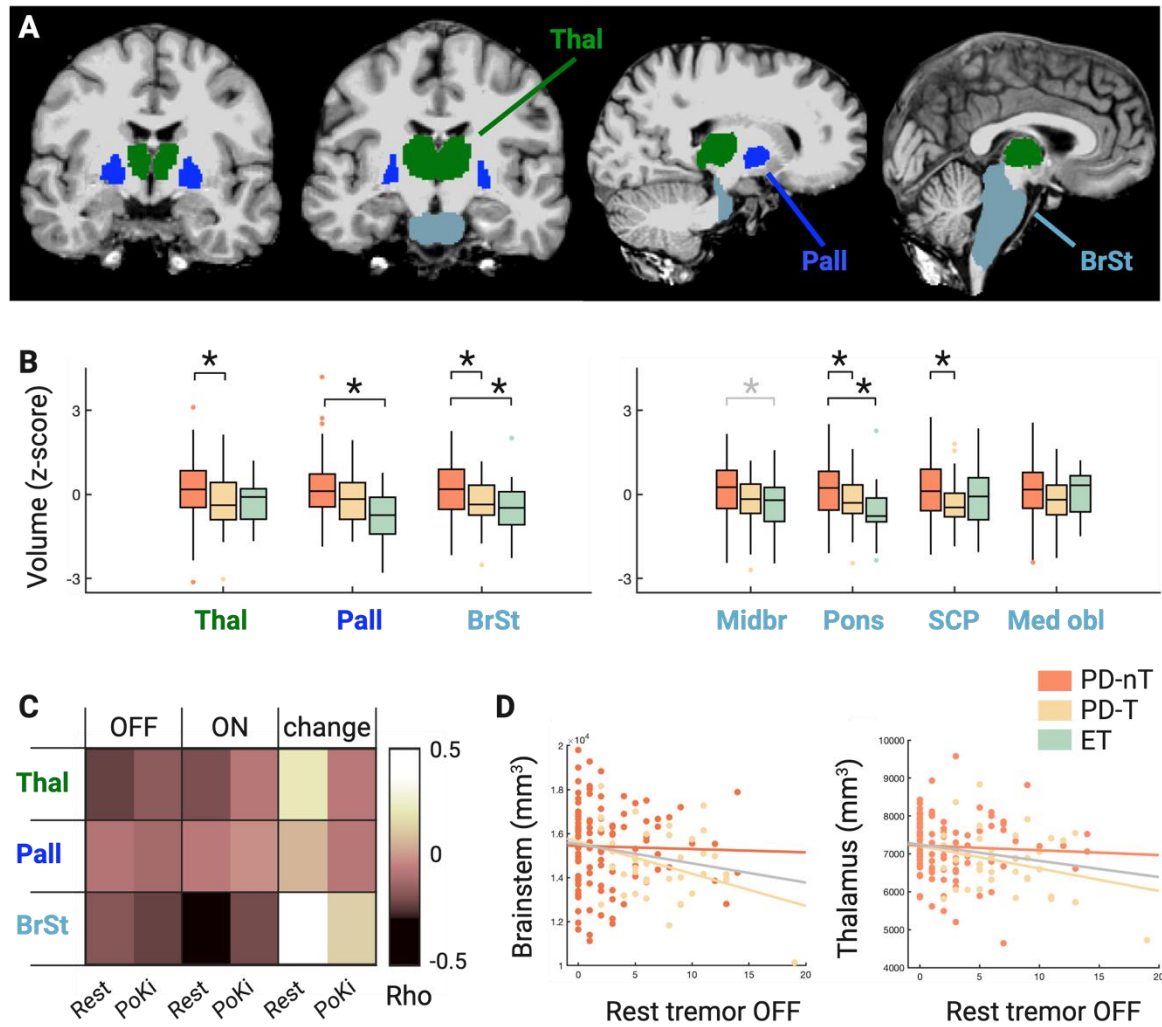


Figure 2: Subcortical brain signature along a phenotypic spectrum of Parkinsonian and Essential Tremor

A: Visualization of subcortical brain regions with significant group differences (ET, PD with [PD-T] or without [PD-nT] predominant tremor) color-highlighted (thalamus, pallidum, and brainstem). **B:** Results revealed significant differences of group, with volumes being largest in PD-nT, intermediate in PD-T, and smallest in ET (B, left). Further testing of brainstem subregions indicated that volumetric differences concerned the precerebellar and upper brainstem (B, right). Data were normalized (z-transformed), to allow uniform visualization of brain regions of different sizes. **C and D:** Heat map and selected scatter plots of correlations of regional brain volumes with the severity of tremor during practically defined OFF and after oral intake of levodopa (ON), and the % change of tremor between OFF and ON.

Thal=Thalamus, Pall=Pallidum, BrSt=Brainstem, Midbr=Midbrain, SCP=Superior cerebellar peduncle, Med obl=Medulla oblongata; PoKi=Postural/Kinetic Tremor. Black asterisks indicate significance at $p<0.05$; the gray asterisk indicates a trend at $p<0.08$;

Phenotype-related subcortical regions correlate with severity and drug-related improvement of tremor

Figure 2 C-D display the results of the correlation analysis relating brain volumes to motor symptoms and their improvement after drug intake (see Table S1 for complete results including all rho values). Across all PD patients, smaller volumes of brainstem and thalamus were associated with more severe rest tremor and less levodopa-related improvement of rest tremor. These associations were driven by PD-T patients (Figure 2 D; Table S1). The association of rest tremor with brainstem volume was stronger during the ON (Rho= -0.29, $p=0.001$) than OFF (Rho= -0.17, $p=0.04$) state, while the association of rest tremor with thalamic volume tended to be stronger in the OFF (Rho= -0.22, $p=0.007$) than ON (Rho= -0.17, $p=0.024$) state (Figure 2 C). Smaller volume of the brainstem, but not of the thalamus, was related to more severe postural/kinetic tremor during the ON (Rho= -0.20, $p=0.016$) and OFF (Rho= -0.22, $p=0.009$) state, again, driven by PD-T patients (Figure 2 C; Table S1). Smaller volumes of the pallidum showed weak associations with more severe rest tremor during ON and less levodopa-related improvement of rest tremor in PD-T patients, but these associations remained at statistical trend level ($p=0.05-0.1$, Table S1). In ET patients, smaller volume of the thalamus was associated with alcohol-related improvement of tremor at statistical trend-level (Rho=0.5, $p=0.086$), while no other associations emerged (Table S1).

Cortical signature of motor phenotypes across ET and PD

Using cortical thickness measures registered to a common domain, a GLM model controlling for age, sex and multiple comparisons, revealed thicker cortical thickness of two distinct regions within the superior-frontal cortex on the left hemisphere ($p < 0.05$, clusterwise corrected; corrected effect size, or Hedges's $g = 0.32$; Fig 3, Table 3), and the precentral and superior-parietal region of the right hemisphere ($p < 0.005$, $p < 0.01$, clusterwise corrected; corrected effect sizes, or Hedges's $g = 0.13$, 0.18 ; respectively, Fig 3, Table 3) in PD-T compared with PD-nT patients. None of the comparisons including the ET patient group revealed significant differences.

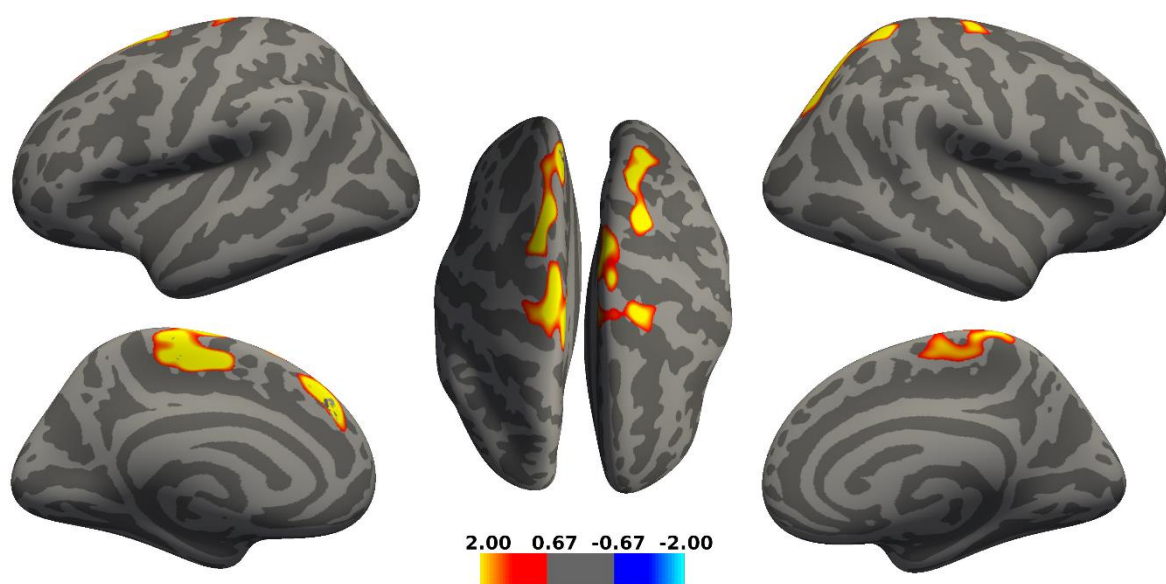


Figure 3 Cortical differences between patients with PD with (PD-T) or without (PD-nT) predominant tremor

Detected differences in cortical thickness between PD-T and PD-nT patients. After controlling for age and sex, thicker cortical thickness in PD-T compared to PD-nT was observed in frontal and parietal regions including two distinct subregions in the left superiorfrontal cortex, and right precentral and superiorparietal cortex ($p < 0.05$, clusterwise corrected). The color bar represents uncorrected significance values masked by the clusters that survived correction for multiple comparisons.

Discussion

We compared brain volumes across patients with ET, PD-T, or PD-nT, representing a phenotypic spectrum with decreasing levels of tremor and increasing levels of akinetic-rigid symptoms. We found that volumes of the brainstem, pallidum, and thalamus followed a gradient along the phenotypic spectrum, with volumes being smallest in ET, intermediate or similar to ET in PD-T, and largest in PD-nT. Therefore, subcortical volumes in the cerebello-thalamic system differed as a function of phenotype rather than diagnostic entities (PD or ET).

Volume loss of cerebello-thalamic and interconnected regions as a transdiagnostic signature of tremor

Our findings are in line with previous studies using various imaging and electrophysiological methods linking tremor to dysfunction within the cerebello-thalamic system and interconnected regions in PD [8-10] and ET [22-24]. Previous structural MRI studies found smaller thalamic and cerebellar volumes in ET compared to non-subtyped PD patients [25, 26]. Our observation suggests that differences in thalamic volumes between ET and PD could be driven by PD subtype rather than PD per se. While previous studies showed tremor-related volume loss in the cerebellum [9, 10] and cerebellar subregions [11, 14], we found no group differences in cerebellar volumes. However, our study was not designed to detect localized cerebellar volume changes as we only quantified entire cerebellar hemispheric volumes. We did, however, observe tremor-related volume loss of the pre-cerebellar and upper brainstem (SCP, pons, and to a lesser degree also midbrain). Therefore, our data suggest that cerebellar pathways and regions intimately connected to the cerebellum might undergo volume loss in the context of tremor. Importantly, regions with tremor-related volume loss did not include primary nigrostriatal projection sites such as the striatum. Thus, our observations resonate with previous studies implicating non-nigral, non-dopaminergic brainstem structures with tremor of various origins [9]. In PD, loss of the serotonergic raphe nuclei has been linked with more severe and less levodopa-responsive tremor [10, 27]. Moreover, quantitative susceptibility mapping MRI has

indicated higher iron load in the red and dentate nucleus in PD-T compared to PD-nT patients [28]. Interestingly, we observed volume loss of brainstem related to both rest and postural/kinetic tremor and more so during the dopaminergic ON than OFF state. This pattern suggests brainstem involvement in both dopaminergic and non-dopaminergic mechanisms of tremor [9, 10, 27]. Further, thalamic volume loss correlated with more PD-typical tremor, that is, rest tremor, more during the OFF than ON state. The absent correlation between pallidal volume and tremor in our study could be explained by the proposed indirect contribution of pallidal dysfunction to tremor, via interference with thalamocortical connections [29]. Taken together, these data highlight the importance of non-nigral, non-dopaminergic mechanisms with particular involvement of the brainstem and cerebellothalamic system for tremor genesis in PD, similar to ET [9, 10, 27].

In ET, some (but not all) autopsy studies have revealed increased Lewy body inclusions in brainstem nuclei, such as the locus coeruleus [5, 6], suggesting that neurodegeneration could be a feature of ET at least in some patients, or that these patients could have been prone to develop PD-overlap later on. Our observation of reduced brainstem volumes in ET could be interpreted as further potential evidence of a neurodegenerative component in ET, for which the slow progression in many ET patients provides further support. Given that we studied drug-resistant patients with long disease duration and evaluated for deep brain stimulation, one could speculate that neurodegeneration appears in a subgroup of ET with a more aggressive phenotype, or that long-standing severe ET phenotypes result from a so far poorly understood type of neurodegeneration involving the cerebello-thalamic system. Further studies using in vivo biomarkers and postmortem histopathology are warranted to investigate biological profiles of ET subgroups and to determine if neurodegeneration discriminates severe from benign cases. Intriguingly, the identified brain regions with tremor-related volume loss overlap with regions previously implicated with tremor-related functional changes. For example, PD-T patients showed higher metabolic activity in networks comprising the thalamus, pons, and premotor

cortical regions compared to PD patients without tremor [8]. Similarly, ET has been linked with metabolic activity in the cerebellum, brainstem, and thalamus [22]. A recent MRI study observed higher structural connectivity in the cerebello-thalamo-cortical system as a common feature of PD-T and ET compared to PD patients without tremor and healthy controls [30]. Future studies are warranted to investigate if tremor-related hyperactivity could be linked to volume loss in the cerebello-thalamic network, whether hyperactivity results from or causes atrophy, and potential underlying mechanisms.

Cortical thickness diverges from subcortical volume changes in PD

Whilst we detected smaller volumes at the subcortical level, we found a diverging pattern of thinner cortical thickness in PD-nT compared to PD-T patients, involving selected frontal and parietal areas. These cortical findings are in line with a previous study showing significantly lower gray matter volume in several cortical areas in patients with akinetic-rigid (“Postural Instability Gait Difficulty”) subtype compared to PD-T patients [12].

Limitations and further implications

The study limitations pertain to the retrospective study design. Nevertheless, all data were ascertained in a structured and consecutive setting, with uniform and standardized outcome measures and the same experienced experts performing the motor examinations and scoring (C.R.B., F.B., S.J.S). Group sizes were imbalanced and tended to be small, especially when conducting subgroup analyses. Therefore, the study was underpowered, reflected in the relatively modest p-values calculated for cortical thickness. However, based on the narrow confidence intervals, power may have been an issue specifically for those analyses trying to isolate ET as an independent group. Further, our findings may not be generalizable to all ET patients because we studied severely affected patients and, as per study design, excluded patients outside the spectrum of tremor and akinetic-rigid syndromes (those with ET and soft signs of ataxia or dystonia). On the other hand, owing to the higher proportion of severe tremor our cohort may have been more suitable for studying underlying mechanisms.

Direct implications for clinical practice are limited at this point. Nevertheless, our data demonstrate that structural MRI can uncover meaningful biomarkers that inform about heterogeneity in PD and ET. Further, our findings confirm that structural MRI may have limited value as a diagnostic biomarker for differentiating PD-T from ET, owing to shared volumetric brain changes among tremor-dominant phenotypes irrespective of diagnosis.

Conclusion

We identified a transdiagnostic structural brain signature of tremor in PD and ET that involves volume loss within the cerebello-thalamic system and interconnected regions, suggesting shared mechanisms in tremor genesis across PD and ET. These structural brain changes mirror clinical phenotypes in that they are heterogeneous in PD on the one hand (PD-T vs PD-nT) but surpass diagnostic boundaries between ET and PD on the other hand. This transdiagnostic structural signature of tremor is in contrast with the etiological and pathophysiological differences between PD and ET and favors the view of alterations along a spectrum rather than within clear-cut diagnostic entities. Further studies are warranted to investigate heterogeneity and transdiagnostic mechanisms, aiming to improve diagnostic accuracy and optimal treatment choices within a personalized medicine approach in PD and ET.

Acknowledgments including sources of support:

The authors thank Prof. Dr. Günther Deuschl, Department of Neurology, University Hospital Schleswig-Holstein, Campus Kiel and Kiel University, Germany, for his helpful comments on this article.

This research did not receive any specific grant from funding agencies in the public, commercial, or not-for-profit sectors.

Contributors:

Christian Ineichen:	formal analysis, methodology, visualization, writing - first draft, writing - review & editing
Fraser Callaghan:	formal analysis, methodology, visualization, writing- review & editing
Heide Baumann-Vogel:	investigation, writing - review & editing
Fabian Büchele	writing - review & editing
Ruth O’Gorman Tuura:	formal analysis, methodology, writing - review & editing
Christian R. Baumann:	supervision, writing - review & editing
Simon J. Schreiner:	conceptualization, investigation, formal analysis, methodology, visualization, writing - first draft, writing - review & editing

Disclosures:

Funding Sources and Conflict of Interest:

CI: None.

FC: None.

HBV: Received a competitive grant from the Koetser Foundation Zurich.

FB: None.

ROT: None.

CB: Received competitive grants from the Swiss National Science Foundation, the Hochschulmedizin Zurich (Flagship Grant), the LOOP Zurich, the Novartis Foundation, and Parkinson Schweiz, and unrestricted grants from AbbVie Pharma, and Roche. Is founder and shareholder of Tosoo AG, which invests into non-pharmacological sleep modulation technologies. Received speaker honoraria from AbbVie Pharma.

SJS: None.

Ethical Compliance Statement:

The study was approved by the local ethics committee (BASEC 2020-02909) and patients provided informed consent.

References

1. Mestre TA, Fereshtehnejad S-M, Berg D, et al. Parkinson's Disease Subtypes: Critical Appraisal and Recommendations. *Journal of Parkinson's disease*. 2021;11:395-404.
2. Selikhova M, Williams DR, Kempster PA, et al. A clinico-pathological study of subtypes in Parkinson's disease. *Brain*. 2009;132(Pt 11):2947-57.
3. Baumann CR, Held U, Valko PO, et al. Body side and predominant motor features at the onset of Parkinson's disease are linked to motor and nonmotor progression. *Mov Disord*. 2014;29(2):207-13.
4. Bhatia KP, Bain P, Bajaj N, et al. Consensus Statement on the classification of tremors. from the task force on tremor of the International Parkinson and Movement Disorder Society. *Mov Disord*. 2018;33(1):75-87.
5. Deuschl G, Elble R. Essential tremor--neurodegenerative or nondegenerative disease towards a working definition of ET. *Mov Disord*. 2009;24(14):2033-41.
6. Louis ED, Faust PL. Essential tremor pathology: neurodegeneration and reorganization of neuronal connections. *Nature reviews Neurology*. 2020;16(2):69-83.
7. Eggers C, Kahraman D, Fink GR, et al. Akinetic-rigid and tremor-dominant Parkinson's disease patients show different patterns of FP-CIT single photon emission computed tomography. *Mov Disord*. 2011;26(3):416-23.
8. Antonini A, Moeller JR, Nakamura T, et al. The metabolic anatomy of tremor in Parkinson's disease. *Neurology*. 1998;51(3):803-10.
9. Madelein van der Stouwe AM, Nieuwhof F, Helmich RC. Tremor pathophysiology: lessons from neuroimaging. *Current Opinion in Neurology*. 2020;33(4):474-81.

10. Zhong Y, Liu H, Liu G, et al. A review on pathology, mechanism, and therapy for cerebellum and tremor in Parkinson's disease. *npj Parkinson's Disease*. 2022;8(1):82.
11. Benninger DH, Thees S, Kollias SS, et al. Morphological differences in Parkinson's disease with and without rest tremor. *Journal of Neurology*. 2009;256(2):256-63.
12. Rosenberg-Katz K, Herman T, Jacob Y, et al. Gray matter atrophy distinguishes between Parkinson disease motor subtypes. *Neurology*. 2013;80(16):1476-84.
13. Li X, Xing Y, Martin-Bastida A, et al. Patterns of grey matter loss associated with motor subscores in early Parkinson's disease. *NeuroImage: Clinical*. 2018;17:498-504.
14. Holthbernd F, Shah NJ. Imaging the Pathophysiology of Essential Tremor—A Systematic Review. *Frontiers in neurology*. 2021;12(856).
15. Postuma RB, Berg D, Stern M, et al. MDS clinical diagnostic criteria for Parkinson's disease. *Movement Disorders*. 2015;30(12):1591-601.
16. Louis ED, Barnes L, Wendt KJ, et al. A teaching videotape for the assessment of essential tremor. *Movement Disorders*. 2001;16(1):89-93.
17. Stebbins GT, Goetz CG, Lang AE, et al. Factor analysis of the motor section of the unified Parkinson's disease rating scale during the off-state. *Movement Disorders*. 1999;14(4):585-9.
18. Fischl B, Sereno MI, Dale AM. Cortical surface-based analysis. II: Inflation, flattening, and a surface-based coordinate system. *NeuroImage*. 1999;9(2):195-207.
19. Schreiner SJ, Liu X, Gietl AF, et al. Regional Fluid-Attenuated Inversion Recovery (FLAIR) at 7 Tesla correlates with amyloid beta in hippocampus and brainstem of cognitively normal elderly subjects. *Frontiers in aging neuroscience*. 2014;6:240.
20. Iglesias JE, Van Leemput K, Bhatt P, et al. Bayesian segmentation of brainstem structures in MRI. *Neuroimage*. 2015;113:184-95.
21. Mathalon DH, Sullivan EV, Rawles JM, et al. Correction for head size in brain-imaging measurements. *Psychiatry Research: Neuroimaging*. 1993;50(2):121-39.
22. Wills AJ, Jenkins IH, Thompson PD, et al. A positron emission tomography study of cerebral activation associated with essential and writing tremor. *Arch Neurol*. 1995;52(3):299-305.
23. Schnitzler A, Münks C, Butz M, et al. Synchronized brain network associated with essential tremor as revealed by magnetoencephalography. *Mov Disord*. 2009;24(11):1629-35.
24. Muthuraman M, Deuschl G, Anwar AR, et al. Essential and aging-related tremor: Differences of central control. *Movement Disorders*. 2015;30(12):1673-80.
25. Lin CH, Chen CM, Lu MK, et al. VBM Reveals Brain Volume Differences between Parkinson's Disease and Essential Tremor Patients. *Front Hum Neurosci*. 2013;7:247.
26. Choi SM, Kim BC, Chang J, et al. Comparison of the Brain Volume in Essential Tremor and Parkinson's Disease Tremor Using an Automated Segmentation Method. *Eur Neurol*. 2015;73(5-6):303-9.
27. Pasquini J, Ceravolo R, Qamhawi Z, et al. Progression of tremor in early stages of Parkinson's disease: a clinical and neuroimaging study. *Brain*. 2018;141(3):811-21.
28. Guan X, Xuan M, Gu Q, et al. Influence of regional iron on the motor impairments of Parkinson's disease: A quantitative susceptibility mapping study. *J Magn Reson Imaging*. 2017;45(5):1335-42.
29. Helmich RC, Janssen MJ, Oyen WJ, et al. Pallidal dysfunction drives a cerebellothalamic circuit into Parkinson tremor. *Ann Neurol*. 2011;69(2):269-81.
30. Filip P, Burdová K, Valenta Z, et al. Tremor associated with similar structural networks in Parkinson's disease and essential tremor. *Parkinsonism Relat Disord*. 2022;95:28-34.

Tables

Table 1: Clinical and demographic characteristics

	ET (n=18)	PD-T (n=39)	PD-nT (n=109)	Main effect (p)	ET vs. PD-T (p)	ET vs. PD-nT (p)	PD-T vs. PD-nT (p)	ET vs. PD all (p)
Females, n (%)	7 (39)	18 (46)	40 (37)	0.58				0.98
Dominant symptoms on right side, n (%)	9 (50)	26 (67)	58 (53)	0.40				0.86
Age (years)	71.61 ± 6.51	65.70 ± 7.89	61.35 ± 9.96	<0.001	0.025	<0.001	0.085	<0.001
Disease duration (years)	41.06 ± 18.50	10.54 ± 5.69	9.85 ± 5.19	<0.001	<0.001	<0.001	0.893	<0.001
Hoehn Yahr Stage		2.24 ± 0.63	2.33 ± 0.55				<0.001	
Montréal Cognitive Assessment	25.47 ± 3.20	25.75 ± 4.00	26.62 ± 2.98	0.250	0.925	0.404	0.592	0.222
Levodopa equivalent dose (mg/d)		847.56 ± 451.65	1149.39 ± 482.15				<0.001	
UPDRS III								
Total OFF		38.59 ± 15.96	37.15 ± 13.60				0.713	
Axial OFF		9.67 ± 5.56	11.17 ± 4.66				0.019	
Rigidity OFF		7.05 ± 3.52	8.54 ± 3.27				0.013	
Bradykinesia OFF		10.85 ± 5.75	12.79 ± 5.56				0.083	
Rest Tremor OFF		7.15 ± 3.77	2.61 ± 3.35				<0.001	
Postural kinetic Tremor OFF		3.15 ± 2.28	1.43 ± 1.59				<0.001	
Total ON		19.79 ± 9.66	17.91 ± 7.40				0.400	
Axial ON		6.21 ± 3.59	5.91 ± 2.75				0.885	
Rigidity ON		3.72 ± 1.88	4.77 ± 2.76				0.069	
Bradykinesia ON		5.85 ± 4.45	6.02 ± 3.58				0.496	
Rest tremor ON		1.85 ± 2.62	0.29 ± 0.97				<0.001	
Postural kinetic tremor ON		1.69 ± 2.10	0.69 ± 0.92				0.004	
Total change (%)		47.21 ± 16.19	50.12 ± 15.80				0.278	

Axial change (%)		33.76 ± 18.58	44.58 ± 19.87				0.003	
Rigidity change (%)		40.42 ± 29.89	43.22 ± 25.31				0.515	
Bradykinesia change (%)		45.51 ± 25.95	50.87 ± 25.15				0.165	
Rest tremor change (%)		73.41 ± 32.07	90.56 ± 29.04				<0.001	
Postural kinetic tremor change (%)		44.26 ± 54.30	49.62 ± 54.16				0.567	
Tremor Scale OFF	29.44 ± 6.68							
Tremor Scale ON	18.60 ± 7.97							
Tremor Scale change (%)	34.88 ± 26.78							
Regional brain volumes	ET (n=18)	PD-T (n=39)	PD-nT (n=109)	Main effect (p)	ET vs. PD-T (p)	ET vs. PD-nT (p)	PD-T vs. PD-nT (p)	ET vs. PD all (p)
Thalamus (ml)	6836.74 ± 590.77	6742.89 ± 796.60	7139.92 ± 786.30	0.007	0.963	0.254	0.010	0.259
Pallidum (ml)	1637.95 ± 218.23	1768.03 ± 205.84	1849.45 ± 249.12	0.002	0.193	0.002	0.202	0.002
Brainstem (ml)	24007.81 ± 2710.74	24473.30 ± 2257.16	25651.67 ± 2721.33	0.006	0.871	0.033	0.046	0.035
Pons (ml)	14199.13 ± 1912.36	14586.33 ± 1549.38	15357.76 ± 1861.90	0.004	0.781	0.021	0.050	0.023
SCP (ml)	277.59 ± 62.22	269.03 ± 44.19	296.57 ± 54.41	0.013	0.890	0.435	0.014	0.410
Midbrain (ml)	5795.30 ± 567.39	5903.32 ± 534.94	6123.12 ± 585.20	0.023	0.874	0.075	0.127	0.061
Medulla oblongata (ml)	3771.70 ± 531.09	3672.37 ± 463.43	3878.24 ± 581.69	0.131	0.813	0.914	0.129	0.84
Cerebellum (ml)	48095.57 ± 3947.41	48208.80 ± 5002.41	48618.32 ± 4841.66	0.863	0.998	0.958	0.973	0.703
Caudate (ml)	3045.21 ± 467.82	3093.51 ± 369.53	3067.15 ± 436.20	0.824	0.979	1.000	0.900	0.952
Putamen (ml)	4213.31 ± 365.02	4295.57 ± 537.87	4279.56 ± 545.68	0.753	0.946	0.840	0.991	0.482
Nucleus accumbens (ml)	496.80 ± 85.05	542.76 ± 104.72	525.67 ± 106.62	0.324	0.380	0.434	0.979	0.145
Hippocampus (ml)	3662.11 ± 431.95	3741.88 ± 572.52	3744.44 ± 417.77	0.585	0.914	0.684	0.953	0.357
Amygdala (ml)	1420.66 ± 209.93	1438.50 ± 141.88	1423.50 ± 187.62	0.682	0.798	0.964	0.879	0.573

ET, essential tremor; PD, Parkinson's disease; PD-T, PD tremor-dominant; PD-nT, PD non-tremor-dominant; SCP, superior cerebellar peduncle

Table 2: Clusters with significantly thicker cortical thickness in PD-T compared with PD-nT patients

Location	side	Talairach coordinates			Cluster-wise P-value	Cluster size (mm ²)	CT _{PD-T} (mm)	CT _{PD-nT} (mm)
		x	y	z				
superior-frontal 1	L	-6.1	-11.7	53.7	0.00320	1387.91	2.55±0.13	2.50±0.14
superior-frontal 2	L	-7.2	39.4	38.3	0.01415	1103.09	2.55±0.13	2.50±0.14
precentral	R	22.6	-19.4	70.0	0.00479	1264.24	2.49±0.16	2.46±0.17
superior-parietal	R	26.2	-48.3	61.7	0.00978	1171.43	2.14±0.16	2.11±0.19

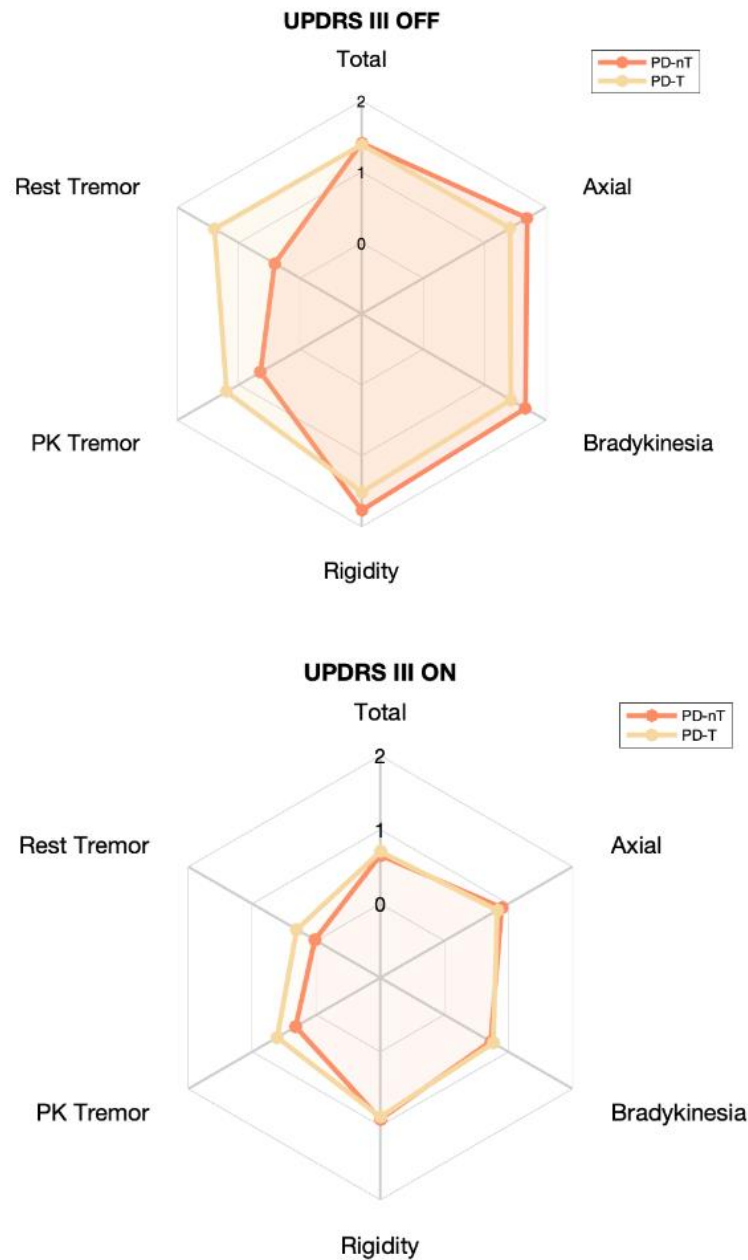
P < 0.05, corrected for multiple comparisons; CT, cortical thickness; PD-T, tremor-dominant; PD-nT, non-tremor-dominant

Table S1

	PD all (n=148)						PD-T (n=39)		PD-nT (n=109)		ET (n=18)	
Partial Rho	UPDRS III	Axial	Rigidity	Bradykinesia	Rest Tremor	Postural Kinetic Tremor	Rest Tremor	Postural Kinetic Tremor	Rest Tremor	Postural Kinetic Tremor	Upper extremity Tremor	ON OFF state
Thalamus	-0.15	-0.09	-0.04	-0.06	-0.22	-0.16	-0.19	-0.12	-0.11	-0.06	0.282	OFF
Pallidum	-0.12	-0.08	-0.04	-0.10	-0.08	-0.11	-0.04	-0.10	-0.01	-0.06	0.045	OFF
Brainstem	-0.15	-0.01	-0.15	-0.07	-0.17	-0.22	-0.34	-0.32	-0.01	-0.14	-0.035	OFF
Thalamus	-0.07	-0.04	0.10	0.00	-0.19	-0.07	-0.14	-0.23	-0.01	0.05	-0.087	ON
Pallidum	-0.10	-0.07	0.07	-0.09	-0.06	-0.01	-0.33	-0.28	0.18	0.09	-0.075	ON
Brainstem	-0.15	-0.06	0.00	0.00	-0.29	-0.20	-0.50	-0.40	-0.13	-0.13	-0.200	ON
Thalamus	-0.02	0.01	-0.06	-0.01	0.22	-0.06	0.13	0.20	0.08	-0.18	0.494	% Change
Pallidum	0.03	0.03	-0.01	0.05	0.07	-0.07	0.29	0.24	-0.15	-0.15	0.331	% Change
Brainstem	0.05	0.09	-0.05	-0.07	0.38	0.14	0.44	0.33	0.25	0.08	0.134	% Change
p values	UPDRS III	Axial	Rigidity	Bradykinesia	Rest Tremor	Postural Kinetic Tremor	Rest Tremor	Postural Kinetic Tremor	Rest Tremor	Postural Kinetic Tremor	Upper extremity Tremor	
Thalamus	0.079	0.262	0.640	0.511	0.007	0.062	0.266	0.473	0.280	0.517	0.291	OFF
Pallidum	0.140	0.327	0.650	0.219	0.338	0.178	0.803	0.545	0.925	0.567	0.869	OFF
Brainstem	0.069	0.951	0.074	0.411	0.040	0.009	0.041	0.061	0.949	0.141	0.898	OFF
Thalamus	0.423	0.623	0.234	0.992	0.024	0.402	0.400	0.185	0.941	0.625	0.776	ON
Pallidum	0.220	0.391	0.389	0.275	0.487	0.888	0.052	0.093	0.071	0.333	0.807	ON
Brainstem	0.079	0.465	0.991	0.987	0.001	0.016	0.002	0.017	0.178	0.200	0.512	ON
Thalamus	0.786	0.871	0.439	0.912	0.027	0.571	0.461	0.282	0.508	0.123	0.086	% Change
Pallidum	0.695	0.706	0.914	0.583	0.471	0.453	0.085	0.201	0.228	0.226	0.270	% Change
Brainstem	0.564	0.299	0.533	0.382	0.000	0.155	0.007	0.074	0.042	0.512	0.662	% Change

ET, essential tremor; PD, Parkinson's disease; PD-T, PD tremor-dominant; PD-nT, PD non-tremor-dominant;

Figure S1



UPDRS III total and subscores during practically defined Off (OFF) and after oral intake of levodopa (ON) across PD patients with (PD-T) or without (PD-nT) predominant tremor. The UPDRS III rates the severity of each item on a scale from zero (absent) to four (severe). In this figure, we show means of total and subscores after dividing each score by the number of items contributing to that score, resulting in an average rating between zero and four. PK=Postural/Kinetic