

1 **Modified Technique for Dissection of Working Space in Retroperitoneal**
2 **Laparoscopic Surgery**

3

4 **Running Title**

5 Modified dissection technique for creating retroperitoneal working space

6

7 **Authors:**

8 Xiaofeng Xu^{1#}, Wen Cheng^{1#}, Zhe Liu¹, Changjie Shi¹, Jianping Da¹, Xiumin Zhou^{2*}, Jingping Ge^{1*}

9 [#]These authors contributed equally to this work

10 * Correspondence author

11

12 **Author Affiliations:**

13 1.Department of Urology, Jinling Hospital, Medical School of Nanjing University, Nanjing, Jiangsu,
14 China.

15 2.Department of Oncology, First Affiliated Hospital of Soochow University, Suzhou, Jiangsu, China.

16 **Corresponding author and e-mail address:**

17 Jingping Ge

18 Telephone: +86-25-80860025; Email: gjp_doctor@qq.com

19 Xiumin Zhou

20 Telephone: +86-512-67973213; Email: alice-xm@163.com

21

22 **Word count (main text): 1973**

23 **Word count (abstract): 220**

24

25 **Keywords:** Modified dissection technique, Retroperitoneal working space, Laparoscopic dissection,
26 Laparoscopic surgery

27

28

29

30

31 **Abstract**

32 **Introduction:** The existing techniques to creat working space for retroperitoneal laparoscopic surgery
33 are often accompanied by air leakage or poor visibility due to blood and fat tissues smudging during
34 dissection.This single-center experience describes a modified dissection technique to create a
35 retroperitoneal working space during laparoscopic surgery.

36 **Materials and Methods:** From May 2021 to December 2022, we performed a modified dissection
37 technique to create a retroperitoneal working space prior retroperitoneal laparoscopic surgery in 47
38 patients. During the procedure, laparoscopic dissection is successively performed. The retroperitoneum
39 is initially accessed by puncturing the trocar through a 10-mm transverse skin incision in the
40 midaxillary line. Under endoscopic monitoring, the tip of the trocar is adjusted to a relative avascular
41 layer between the transversus abdominis muscle and the pararenal fat. Laparoscopic dissection is
42 performed to develop until the working space is fully established. All data referring to patient
43 demographics, surgery, dilation-related complication, and perioperative outcomes were collected
44 retrospectively.

45 **Results:** In all cases, a satisfactory retroperitoneal space was created for surgery. The median time of
46 creating retroperitoneal working space was 6 (IQR:5,7) minutes. No dissection-related complications
47 were noted within a median follow-up period of 9 (IQR:7,15) months.

48 **Conclusion:** Modified retroperitoneal dissection with laparoscopy is a safe, simple, effective, and
49 minimally invasive technique. It provides an adequate working space and an excellent view without
50 obvious bleeding.

51

52

53

54

55

56

57

58

59

60

61 **Introduction**

62 Creating an appropriate working space within the retroperitoneum is an essential prerequisite for
63 retroperitoneal laparoscopic surgery. Early attempts at creating adequate space were mostly
64 unsuccessful until the balloon dilation technique was first described by Gaur in 1992[1]. Consequently,
65 the use of this technique has become increasingly popular worldwide. However, this technique utilizes
66 an open surgical approach and air leakage is an inevitable problem after dilation because the incision
67 for digital dissection is larger than the diameter of the trocar [2].

68 To overcome the complications associated with the existing techniques, we have implemented a
69 modified dilation technique at our institution. This technique achieves retroperitoneal access by direct
70 trocar puncture through a 10-mm incision. The laparoscopic dissection technique is used to dissect
71 pararenal fat (PF) from the transversus abdominis muscle (TAM). Herein, we report our experience
72 with this modified dilation technique.

73

74 **Materials and methods**

75 **Patients**

76 We have successfully applied this modified dilation technique in 47 cases of benign and malignant
77 diseases of the upper retroperitoneum at our institution. Informed consent was obtained from all the
78 patients. Perioperative data were collected retrospectively after obtaining approval from the
79 Institutional Review Board of Jinling Hospital. Follow-up data were obtained by reviewing patient
80 charts or via telephone calls.

81 **Step-by-step technique**

82 After inducing general anesthesia, the patient is placed in a full-flank position with the kidney bridge
83 elevated. The surgical table is flexed to increase the distance between the ribs and iliac crest. A 10-mm
84 transverse incision is made in the midaxillary line, approximately 2 cm above the iliac crest (Fig. 1a). A
85 10-mm trocar is punctured perpendicularly through the muscular layers and transverse fascia and a
86 10-mm, 30-degree laparoscope is inserted into the trocar. The laparoscopic view is turned to 30-degrees
87 up. Under laparoscopic monitoring, the trocar is adjusted until its tip is within the layer between the
88 TAM and the PF (Fig. 1b). This layer consists of semi-transparent loose and flimsy fibroareolar tissue
89 and is relatively avascular. The eyepiece of the laparoscope is subsequently pushed downward. Using

90 this angle ensures that endoscopic vision remains in the proper layer (Fig. 1c). Thereafter, to-and-fro
91 and side-to-side laparoscopic movements are performed to separate the fibrous septae, and the PF is
92 bluntly detached from the undersurface of the flank abdominal wall. Accordingly, a working space is
93 created between the TAM and PF.

94 There are several technical tips to ensure that laparoscopic dissection remains in the appropriate layer
95 while using this technique. (1) Laparoscopic focus should be adjusted promptly when object distance is
96 too small which will lead to obscure view. (2) The retroperitoneal fat is yellow, the TAM is red, and the
97 fibroareolar tissue is semi-transparent. As the laparoscopic view is out of focus during dissection, these
98 characteristics can be regarded as landmarks (Fig. 1d-1f). (3) Strong light from the laparoscope can
99 transilluminate muscle and form a light spot on the skin. This can aid in locating the tip of the
100 laparoscope (Fig. 1g). (4) The tip of the laparoscope should be pressed onto the undersurface of the
101 flank abdominal wall and the wall will be tented during laparoscopic dissection. Thus, the movements
102 of the laparoscope under the skin are palpable (Fig. 1g).

103 The dissection area extends from the anterior axillary line to the posterior axillary line. PF is mobilized
104 en bloc from the transversalis fascia. Once the working space is fully established (Fig. 1h), additional
105 ports are inserted under laparoscopic guidance. Subsequently, the surgical procedure can be performed.

106 **Statistical analysis**

107 The following demographic and intraoperative variables were recorded: age, gender, body mass index
108 (BMI), and the time of creating retroperitoneal working space which is defined as the time elapsed
109 from the initial incision to the placement of all trocars. Complications were classified according to the
110 Clavien-Dindo system.

111 Median and inter-quartile range (IQR) was used for continuous variables. Categorical variables were
112 reported as percentages. Statistical analysis was performed by SPSS software version 22.0.

113

114 **Results**

115 Patient demographic and clinical characteristics are detailed in Table 1. Using the laparoscope, we were
116 able to adequately dissect the retroperitoneal space and obtain a satisfactory surgical field for all
117 patients. The median time of creating retroperitoneal working space was 6 (IQR:5,7) min. All
118 procedures were completed successfully. At a median follow-up of 9 (IQR:7,15) months, no
119 dissection-related complications were observed.

120

121 **Discussion**

122 Currently, the Hasson and Veress needle techniques are the two major approaches used for
123 retroperitoneal access and creating space for retroperitoneal laparoscopic surgery.

124 The Hasson technique is commonly used, wherein initial access and balloon placement for
125 retroperitoneal laparoscopy are established using an open approach [1-4]. A 1.5-2.0 cm incision is made
126 just below the tip of the 12th rib in the posterior axillary line, and the lumbodorsal fascia and muscle
127 fibers are bluntly separated using artery forceps [1,3]. Thereafter, the peritoneum is digitally pushed
128 forward to create a retroperitoneal space. Lastly, a balloon is inserted to fully dilate the retroperitoneal
129 space.

130 Using this technique, intracorporeal manipulation is not performed under direct vision and it is
131 associated with the risk of improper dilation between muscle layers caused by balloon misplacement.

132 Intramuscular dilation can lead to musculature tearing and bleeding, possibly resulting in conversion to
133 an open procedure or postoperative hernia [4]. Furthermore, if the balloon is inserted too deep and
134 dilates within the Gerota fascia, the renal vein can tear [5]. These complications can be avoided by
135 direct visualization using a commercially available transparent balloon where the laparoscope is
136 inserted into the balloon and the proper position of the balloon is confirmed endoscopically. However,
137 this results in higher costs. Another alternative is the use of ultrasound to confirm the position of the
138 balloon [6]. In addition, even if the incision is as small as possible, air leakage around the balloon
139 trocar remains a problem because the index finger is thicker than the 10-mm trocar. Thus, airtight
140 instruments or sutures must be adopted to ensure an airtight incision [2].

141 During the Veress needle technique, the Veress needle is inserted and followed by “blind” trocar
142 puncture at the midaxillary or posterior axillary lines through a 10-mm skin incision. However, this
143 procedure is associated with several complications [7]. First, the fibroareolar tissue binds to the PF in
144 the retroperitoneum and can not be sufficiently broken down by CO₂ insufflation via the Veress needle
145 alone. It is thus difficult to obtain an adequate working space, and breaking the fibroareolar septa via
146 laparoscopy is needed. Second, the tip of the trocar will be inserted into the PF (between the psoas
147 muscle posteriorly and Gerota’s fascia anteriorly) or perirenal fat (within Gerota’s fascia) due to the
148 “blind” puncture [8]. Further laparoscopic dissection is performed within fatty tissues, and en bloc fat
149 is separated into several parts, which is often accompanied by vascular breakage. Lastly, laparoscopic

150 visibility is often obscured by blood and fat tissue, and this technique is associated with frequent
151 smudging of the laparoscope and a lack of anatomical landmarks [9]. An insufficient endoscopic view
152 may result in complications, such as pneumothorax [6,7].

153 Because of the disadvantages of the existing dilation techniques, a modified technique for creating a
154 retroperitoneal working space was introduced at our institution. In this procedure, initial access is
155 obtained by trocar puncture through a 10-mm skin incision without the use of digital dissection.
156 Therefore, air leakage due to a larger incision can be avoided. The tip of the trocar is adjusted to the
157 plane between the TAM and the PF under laparoscopic monitoring. This is important because this layer
158 is composed of semi-transparent loose and flimsy fibroareolar tissue and is nearly avascular. This
159 facilitates a clear laparoscopic view during dissection and en bloc dissection of the PF from the
160 transversalis fasci.

161 After proper layer entry, dissection movements of the laparoscope are performed. The different visual
162 characteristics of the transversus abdominis muscle, PF, and fibroareolar tissue act as laparoscopic
163 anatomical landmarks, which guarantees that the correct layer is dissected. In our experience, proper
164 layer entry can fill areolar tissue with gas, which contributes to the en bloc mobilization of the PF from
165 the transversalis fasci.

166 Furthermore, both the tented portion of the flank abdominal wall and the light spot on the skin from the
167 laparoscope could indicate the precise position of the dilation. These factors also contribute to the
168 avoidance of mis- or overdistention. Ultimately, a clear laparoscopic view with rare hemorrhage is
169 possible.

170 This modified technique offers several unique advantages. First, the skin incision is small, and no blunt
171 dissection of the fascia and muscle with artery forceps is performed. Therefore, intraoperative air
172 leakage is avoided. Mattress sutures or airtight systems are not necessary. Second, a preliminary blunt
173 dissection is performed between the PF and transversalis fasci and not inside the PF. This ensures a
174 clean laparoscopic view because this layer is a relatively avascular semi-transparent reticular fibrous
175 structure. Lastly, manipulation of the entire process is performed using endoscopic monitoring.
176 Therefore, the complications associated with balloon misplacement can be avoided.

177

178 **Conclusion**

179 This modified technique is simple and requires limited experience and technical skills. The procedure

180 is performed under distinct endoscopic monitoring, which minimizes the risk of injury from obscured
181 vision or “blind” manipulation. It not only provides a clear working space but also facilitates further
182 dissection of the PF en bloc off Gerota’s fascia. In summary, the modified dilation technique was
183 initially proven safe and effective.

184

185 **Author contributions** X.F.X. conceived the idea, initial drafting of the article. Cheng: Data collection
186 and data analysis, initial drafting of the article. Z.L., C.J.S., and J.P.D. Data collection. X.M.Z.
187 Interpretation of data, critical revision of the article. J.P.G. Interpretation of data, critical revision of the
188 article.

189

190 **Author Disclosure Statement**

191 The authors declare no conflict of interest.

192

193 **Funding Information**

194 This work was supported by National Natural Science Foundation of China (NSFC81972841).

195

196

197

198

199

200

201

202

203

204

205

206

207

208

209

210

211

212 **References**

- 213 1. Gaur DD. Laparoscopic operative retroperitoneoscopy: use of a new device. *J Urol*
214 1992;148(4):1137-1139; doi: 10.1016/s0022-5347(17)36842-8.
- 215 2. Gill IS. Retroperitoneal laparoscopic nephrectomy. *Urol Clin North Am* 1998;25(2):343-360; doi:
216 10.1016/s0094-0143(05)70023-9.
- 217 3. Gaur DD, Agarwal DK, Purohit KC. Retroperitoneal laparoscopic nephrectomy: initial case report. *J*
218 *Urol* 1993;149(1):103-105; doi: 10.1016/s0022-5347(17)36012-3.
- 219 4. Adams JB 2nd, Micali S, Moore RG, et al. Complications of extraperitoneal balloon dilation. *J*
220 *Endourol* 1996;10(4):375-378; doi: 10.1089/end.1996.10.375.
- 221 5. Gaur DD, Rathi SS, Ravandale AV, et al. A single-centre experience of retroperitoneoscopy using the
222 balloon technique. *BJU Int* 2001;87(7):602-606; doi: 10.1046/j.1464-410x.2001.02149.x.
- 223 6. Rassweiler JJ, Henkel TO, Stoch C, et al. Retroperitoneal laparoscopic nephrectomy and other
224 procedures in the upper retroperitoneum using a balloon dissection technique. *Eur Urol*
225 1994;25(3):229-236; doi: 10.1159/000475289.
- 226 7. Kerbl K, Figenshau RS, Clayman RV, et al. Retroperitoneal laparoscopic nephrectomy: laboratory
227 and clinical experience. *J Endourol* 1993;7(1):23-26; doi: 10.1089/end.1993.7.23.
- 228 8. McDougall EM, Clayman RV, Fadden PT, et al. Retroperitoneoscopy: the Washington University
229 Medical School experience. *Urology* 1994;43(4):446-452; doi: 10.1016/0090-4295(94)90228-3.
- 230 9. Partin AW, Domochofski RR, Kavoussi LR, Peters CA (eds). *Campbell-Walsh-Wein Urology*, 12th
231 edn. Elsevier, Philadelphia, PA, 2021.

232

233

234

235

236

237

238

239

240

241

242

243

244

245

246 **Figure Legends**

247 **Fig. 1** Key procedures of the modified dissection technique for creating an adequate retroperitoneal
248 working space.

249 **a** The patient in a full-flank position. The first trocar is punctured perpendicularly through a 10-mm
250 incision (black arrow) in the midaxillary line, approximately 2 cm above the iliac crest. The 12th rib
251 and iliac crest have been marked. **b** Telescopic view of the 30-degree up from the first trocar. The
252 trocar tip (black arrow) is adjusted to the relatively avascular layer (RAL) between the transversus
253 abdominis muscle (TAM) and pararenal fat (PF). **c** Laparoscopic dissection within the RAL. **d,e,f** The
254 laparoscopic view is out of focus during dissection. The PF is yellow, the TAM is red, and the RAL is
255 semi-transparent. These characteristics can be regarded as landmarks. **g** Strong light from the
256 laparoscope transilluminates the muscle and forms a light spot on the skin. Movements of the
257 laparoscope are palpable by hand simultaneously. **h** The working space is fully established. PF is
258 mobilized en bloc from the transversalis fascia. A clear laparoscopic view without hemorrhage is
259 observed

260

261 **Fig. 2** Perforator vessel in fibroareolar tissue (black arrow)

262

263 **Table 1** Demographic and clinical characteristics of the 47 patients with modified dissection technique.

Variable	Value
Age, years, median (IQR)	54 (47.5, 62)
Gender, n (%)	
Male	22 (46.8)
Female	25 (53.2)
BMI, kg/m ² , median (IQR)	25.68 (21.7, 27.6)
Retroperitoneoscopic procedures	
Radical nephrectomy	5
Nephrectomy	3
Partial nephrectomy	23
Adrenalectomy	13
Renal pedicle lymphatic disconnection for chyluria	1
Renal cyst decortication	1
Nephroureterectomy	1
Total	47
Time of creating retroperitoneal working space (minutes), median (IQR)	6 (5, 7)
Dissection-related complications (%)	0 (0)

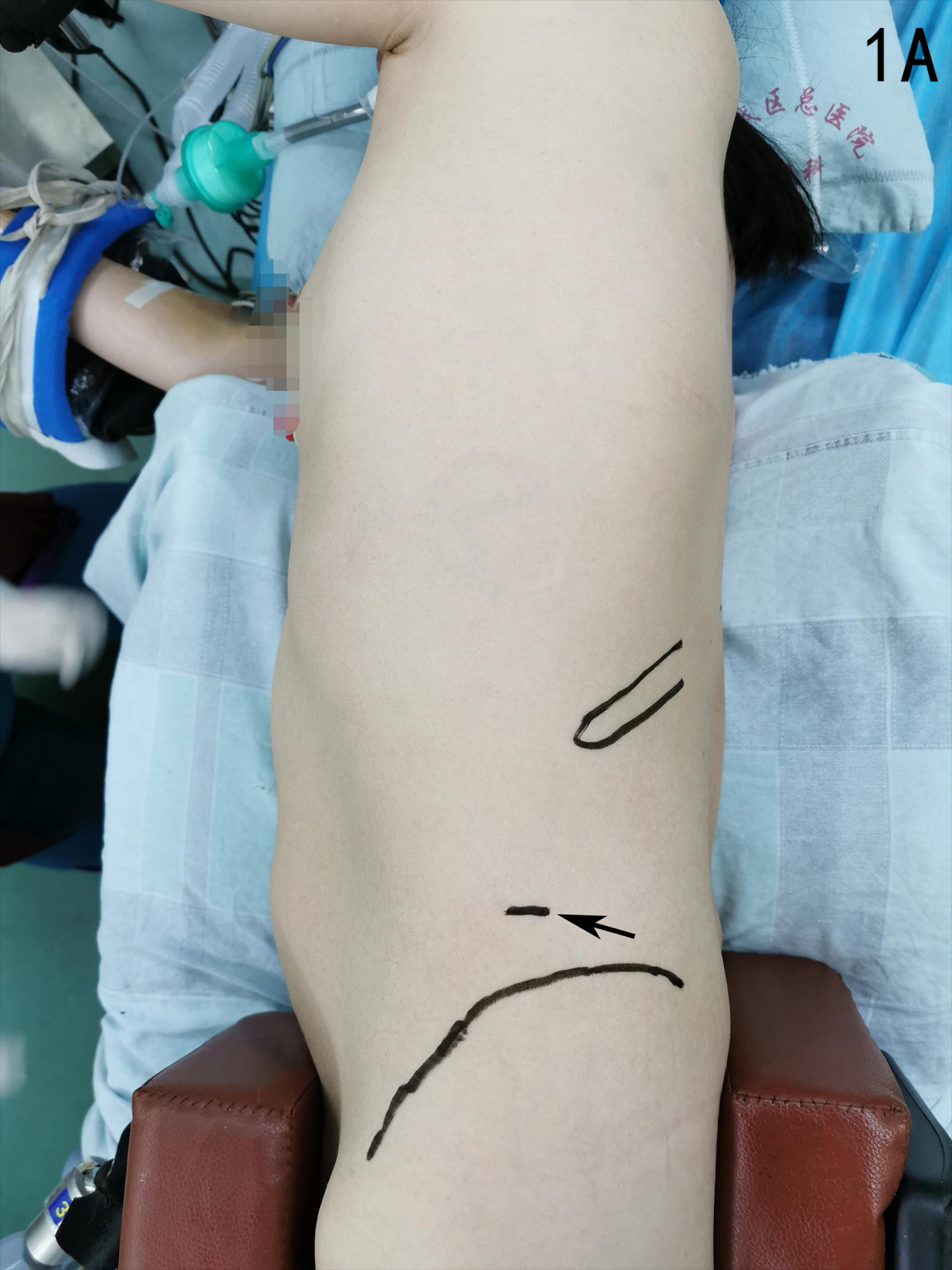264 BMI=body mass index; IQR=inter-quartile range;

265

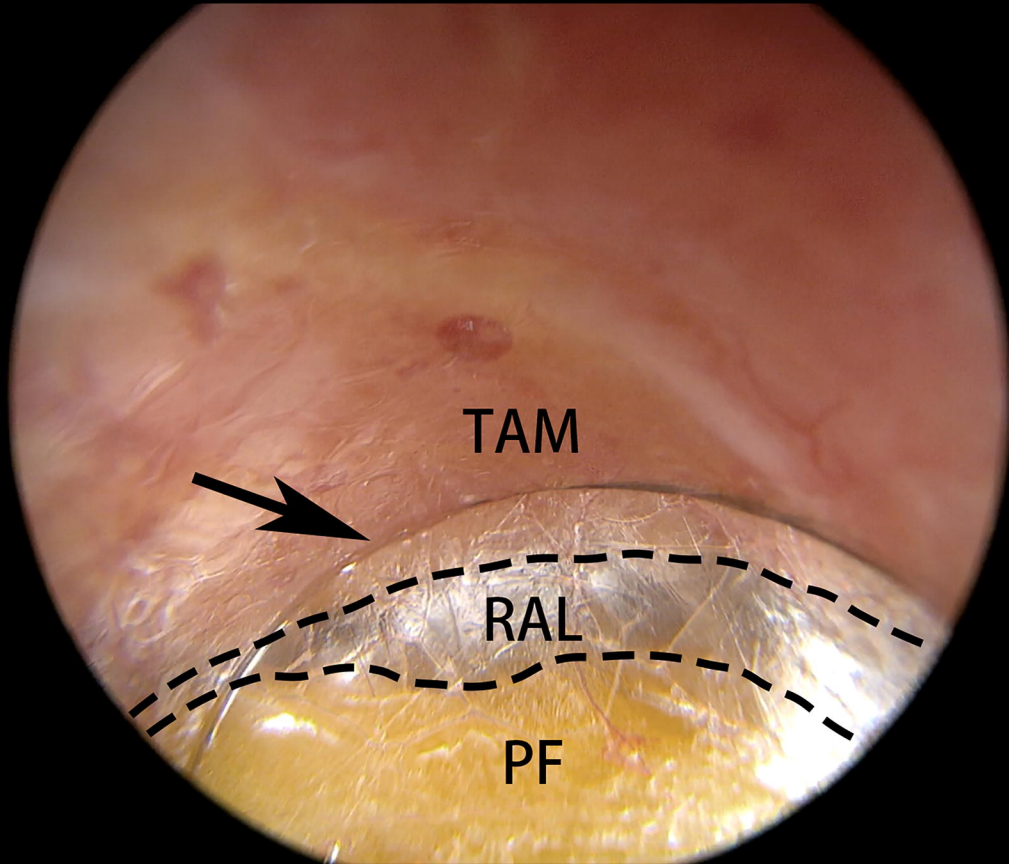
266

267

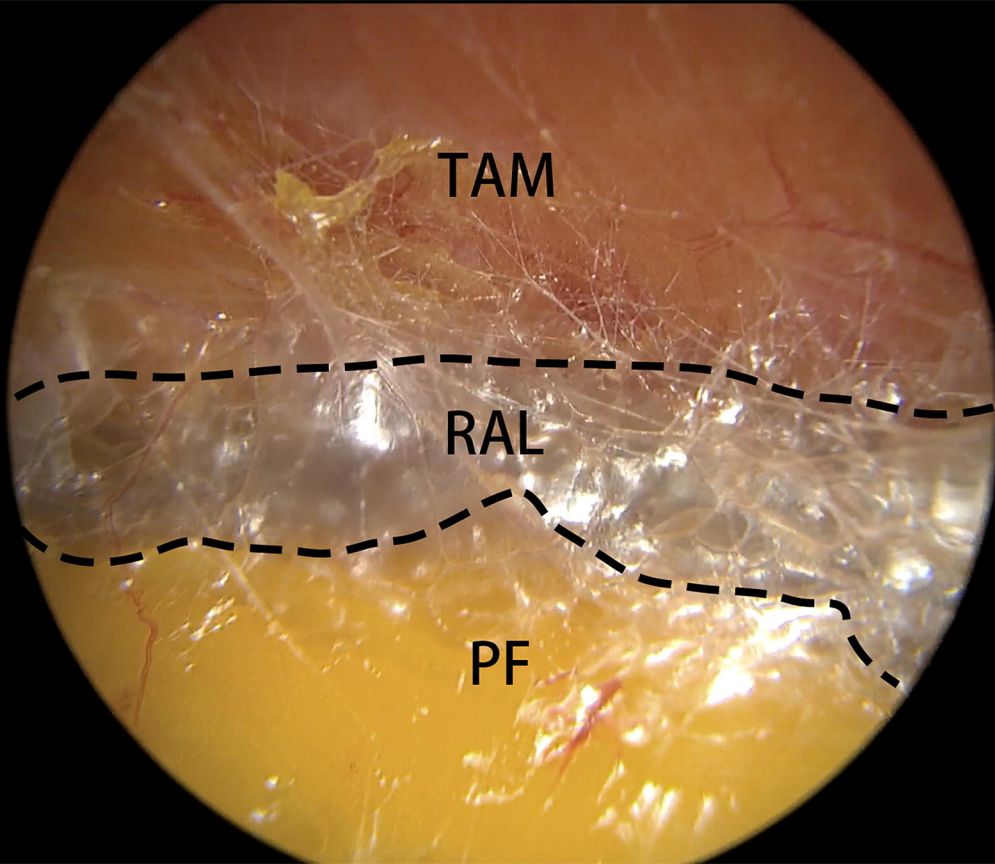
1A



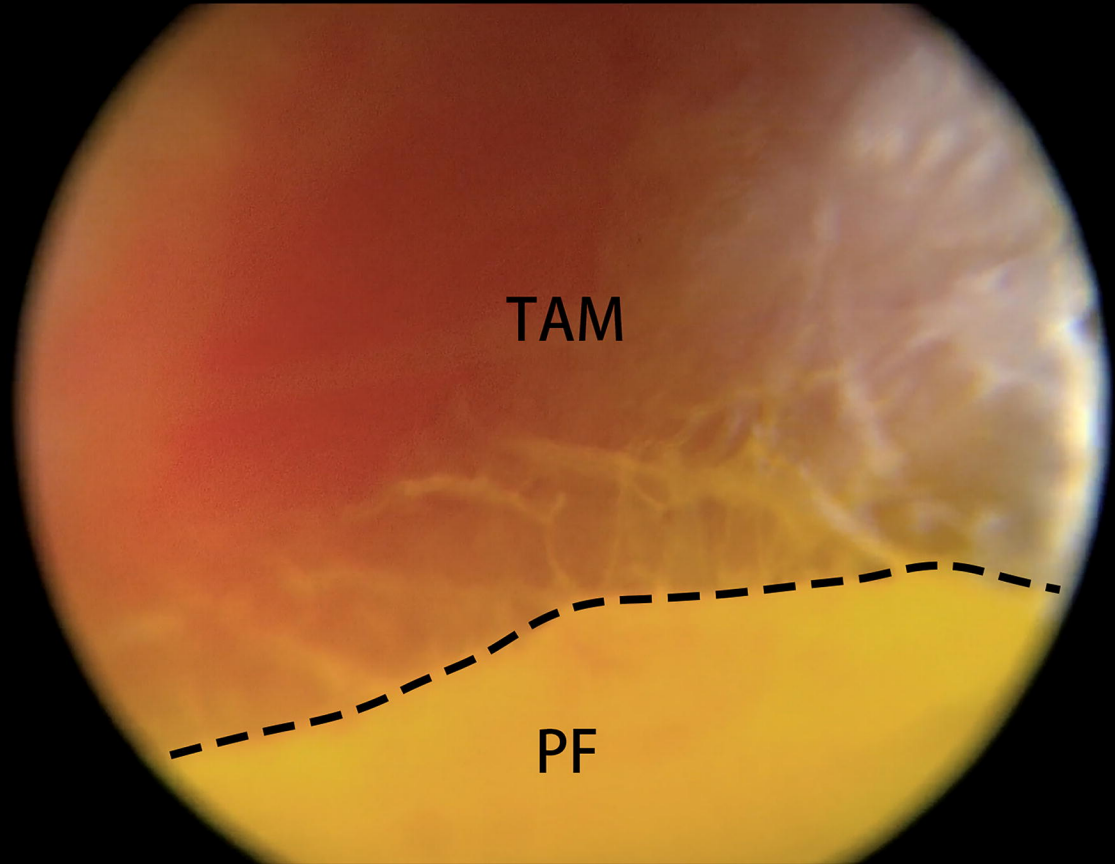
1B



1C



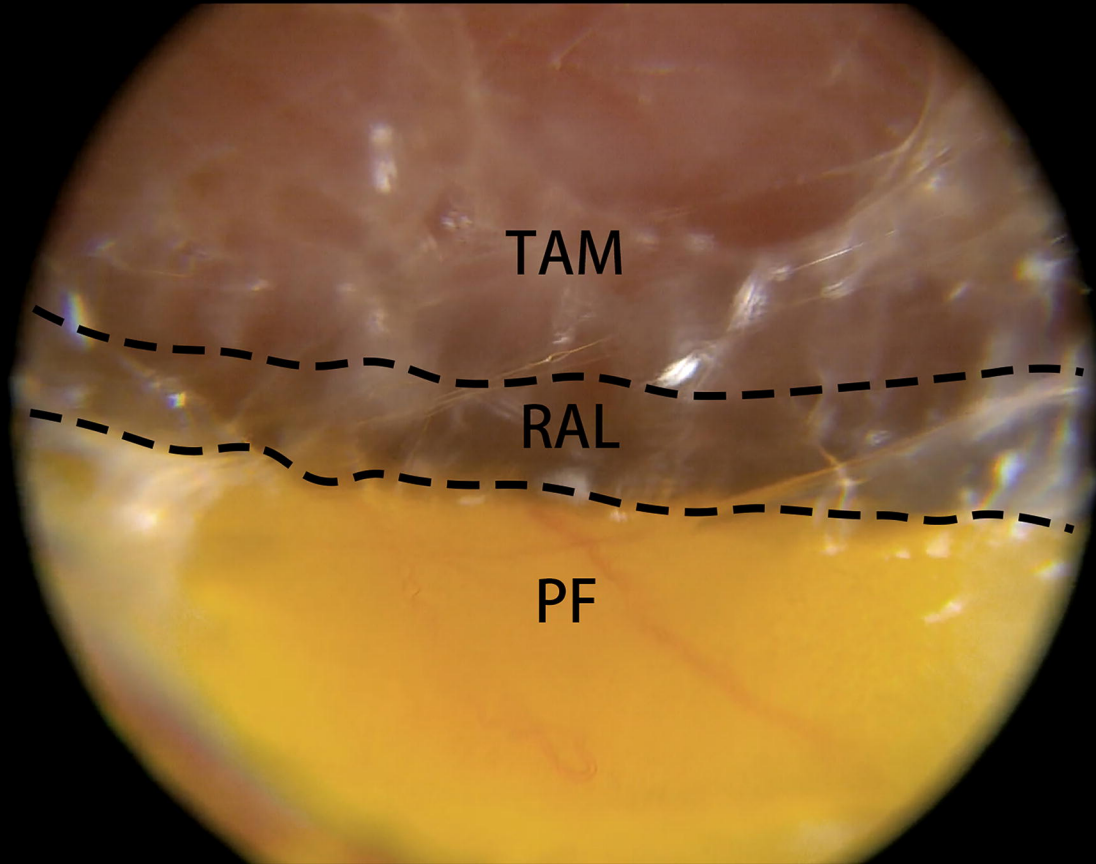
1D



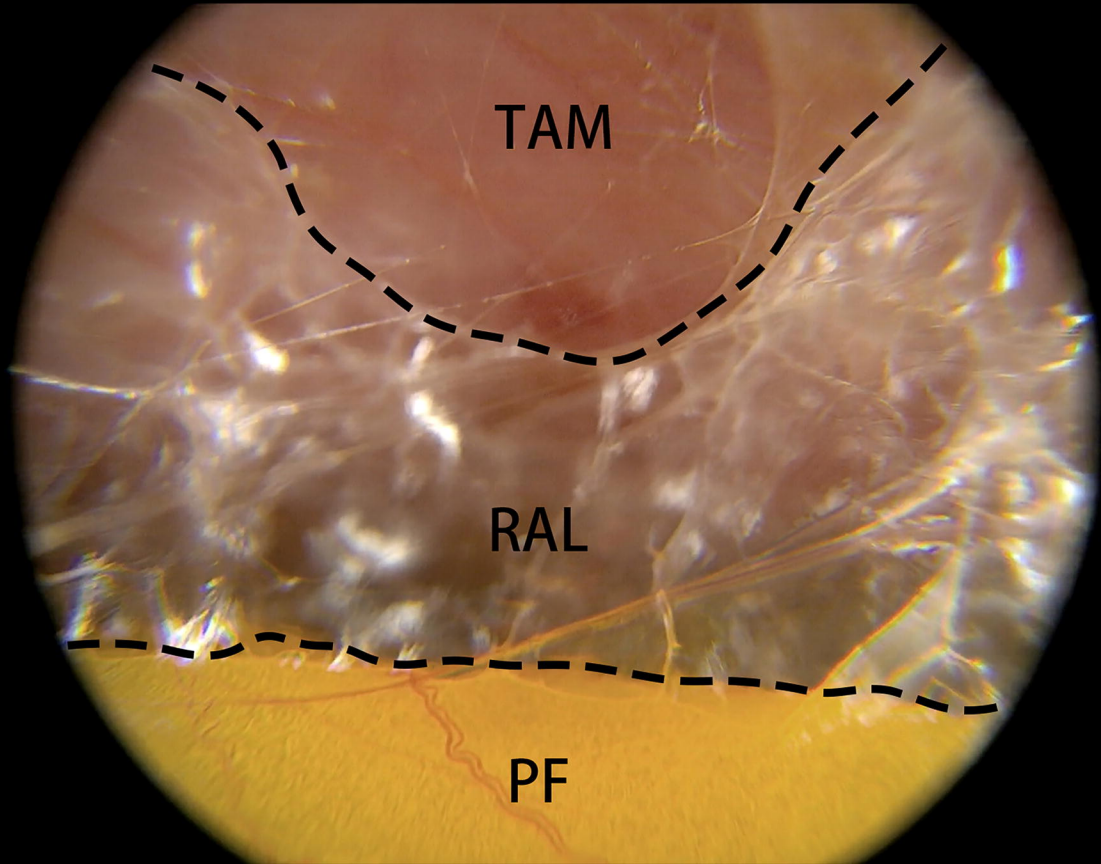
TAM

PF

1E



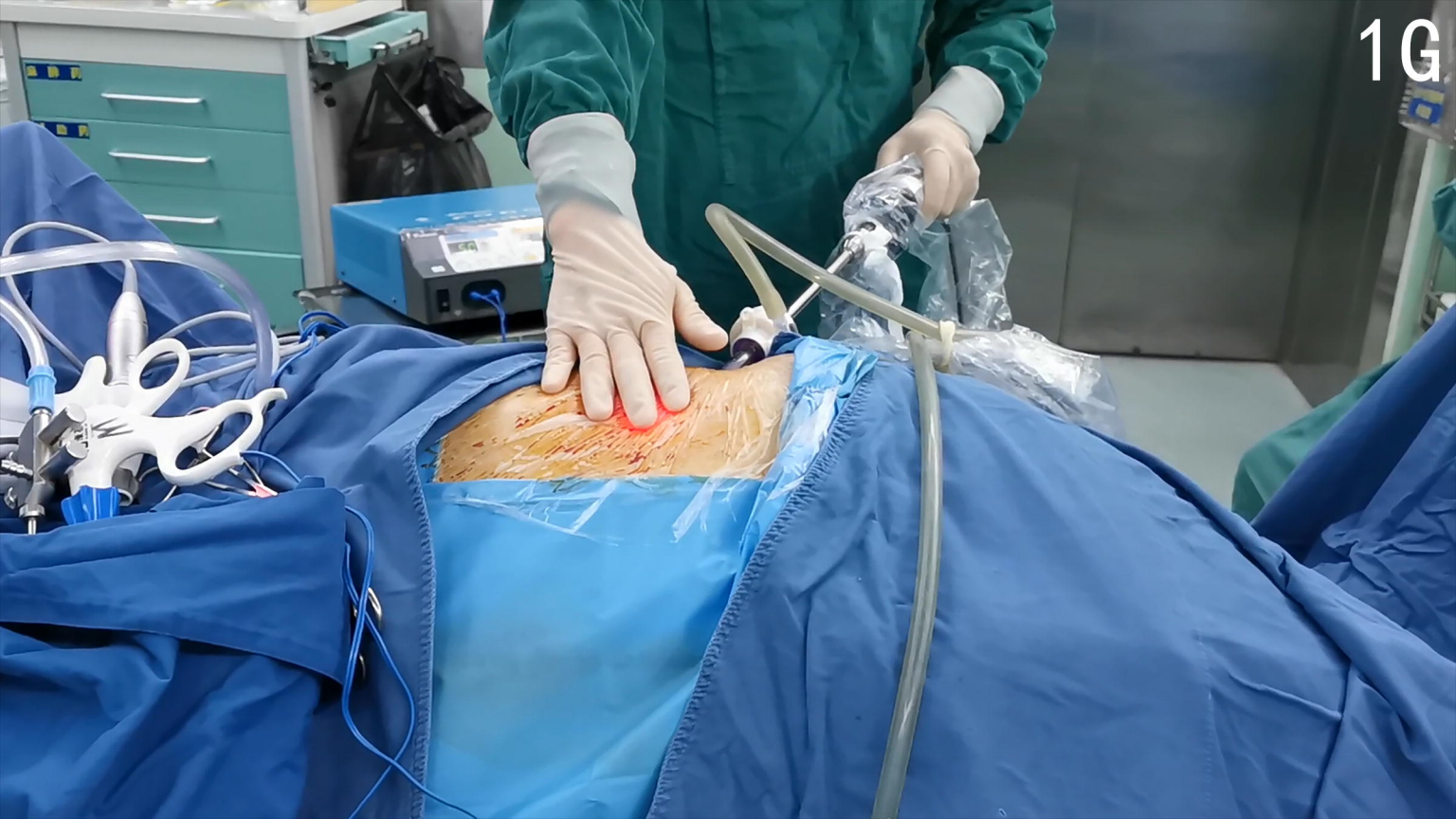1F

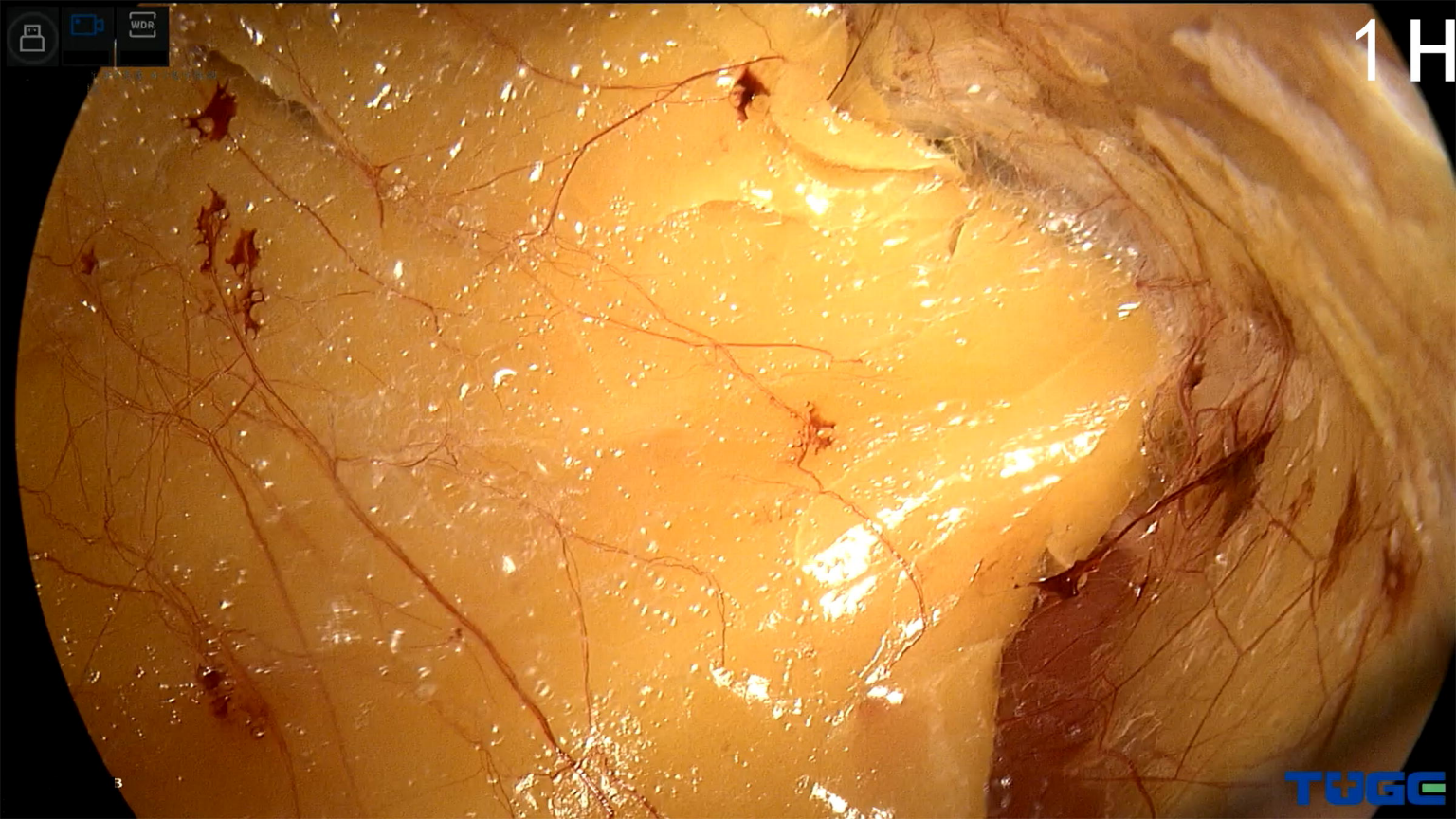


TAM

RAL


PF





1 H

TWGG



2

