

Deep Learning for Transesophageal Echocardiography View Classification

Kirsten Steffner¹, MD; Matthew Christensen²; George Gill³, MD; Michael Bowdish³, MD; Justin Rhee²; Abirami Kumaresan^{3,4}, MD; Bryan He⁵, PhD; James Zou⁴, PhD; David Ouyang², MD.

1. Department of Anesthesiology, Perioperative and Pain Medicine, Stanford University
2. Department of Cardiology, Smidt Heart Institute, Cedars-Sinai Medical Center
3. Department of Cardiac Surgery, Smidt Heart Institute, Cedars-Sinai Medical Center
4. Department of Anesthesiology, Cedars-Sinai Medical Center
5. Department of Computer Science, Stanford University
6. Department of Biomedical Data Science, Stanford University

Contact: ksteffner@stanford.edu, 300 Pasteur Drive, Room H3580, Stanford, California 94305-5640

Total Word Count (including Title Page, Abstract, Text, References, Tables and Figures Legends): 3,977

25 **Abstract**

26

27 Transesophageal echocardiography (TEE) imaging is a vital monitoring and diagnostic tool used
28 during all major cardiac surgeries, guiding perioperative diagnoses, surgical decision-making,
29 and hemodynamic evaluation in real-time. A key limitation to the automated evaluation of TEE
30 data is the complexity and unstructured nature of the images, which demonstrate significant
31 heterogeneity across varied views in the evaluation of different cardiac structures. In this study,
32 we describe the first machine learning model for TEE view classification. We trained a
33 convolutional neural network (CNN) to predict standardized TEE views using labeled
34 intraoperative and intraprocedural TEE videos from Cedars-Sinai Medical Center (CSMC). We
35 externally validated our model on intraoperative TEE videos from Stanford University Medical
36 Center (SUMC). Accuracy of our model was high across all labeled views. The highest
37 performance was achieved for the Trans-Gastric Left Ventricular Short Axis View (area under
38 the receiver operating curve [AUC] = 0.971 at CSMC, 0.957 at SUMC), the Mid-Esophageal
39 Long Axis View (AUC = 0.954 at CSMC, 0.905 at SUMC), the Mid-Esophageal Aortic Valve
40 Short Axis View (AUC = 0.946 at CSMC, 0.898 at SUMC), and the Mid-Esophageal 4-Chamber
41 View (AUC = 0.939 at CSMC, 0.902 at SUMC). Ultimately, we demonstrate that our unique
42 deep learning model can accurately classify standardized TEE views, which will facilitate further
43 downstream analyses for intraoperative TEE imaging.

44

45 **Introduction**

46
47 Cardiovascular disease is a leading cause of death and disability worldwide and has been one of
48 the top ten most important drivers of increasing global disease burden in the last three decades.¹
49 Echocardiography is the most commonly used imaging modality in the assessment of cardiac
50 structure, function, and disease.^{2,3} Despite the growth seen in the application of artificial
51 intelligence (AI) to transthoracic echocardiography (TTE)⁴⁻⁷, the application of AI and machine
52 learning to transesophageal echocardiography (TEE) remains relatively unexplored. Although
53 more invasive, TEE imaging often offers higher resolution images and is particularly valuable as
54 a monitoring and diagnostic tool in the management of cardiac surgery patients and patients
55 undergoing transcatheter procedures for structural heart disease.^{2,8,9} As the standard of care,
56 intraoperative TEE imaging is performed during all major cardiac surgeries, especially those
57 requiring an open sternotomy and cardiopulmonary bypass (CPB), to help make perioperative
58 diagnoses, guide surgical decision-making, and evaluate hemodynamic states in real-time.

59
60 Advances in AI for medical imaging demonstrate that machine learning models can be trained to
61 classify human disease states¹⁰, identify phenotypic data¹¹⁻¹³, and predict clinical outcomes with
62 accuracy that outperforms clinical experts and more traditional clinical prediction models.¹³⁻¹⁷
63 The early, landmark literature in AI for medical imaging focused on two-dimensional, static
64 images such as chest x-rays and pathology images. More recently, deep learning techniques have
65 been applied to two- and three- dimensional images over time, such as echocardiography
66 videos.^{5,11,18,19}

67
68 Given the critically important role that TEE imaging plays in the evaluation of complex
69 cardiovascular disease states and in the perioperative management of high-risk cardiac surgery
70 patients, there is great potential value to be extracted from TEE images with advanced deep
71 learning methodologies. The first step in the interpretation of any echocardiography video is to
72 classify the view, to orient the observer to the anatomy and potential pathology contained within
73 the image. Therefore, in this study we tested whether it was possible to train a convolutional
74 neural network (CNN) to accurately classify eight standardized TEE views using labeled
75 intraoperative and intraprocedural TEE images.

76

77

78 **Methods**

79

80 *Cohort Selection and Data Processing*

81

82 We obtained TEE image data for 2,144 randomly selected patients who underwent an
83 intraoperative or intraprocedural TEE exam at Cedars-Sinai Medical Center (CSMC) between
84 the years of 2016 and 2021. This resulted in 3,103 TEE videos, including intraoperative
85 echocardiography images from open (via sternotomy) cardiothoracic surgical operations and
86 intraprocedural echocardiography images from transcatheter procedures for structural heart
87 disease. We also obtained TEE image data from randomly selected adult (age 18 years and older)
88 patients who underwent an intraoperative TEE exam during open cardiothoracic surgery at
89 Stanford University Medical Center (SUMC), resulting in an additional 465 TEE videos for an
90 external test set. The Institutional Review Board at Cedars-Sinai Medical Center and the
91 Institutional Review Board at Stanford University Medical Center both granted ethical approval
92 for this study.

93

94 Guidelines established by the American Society of Echocardiography and the Society of
95 Cardiovascular Anesthesiologists identify twenty-eight different TEE views necessary to
96 complete a comprehensive intraoperative multi-plane TEE exam.²⁰ In actual clinical practice,
97 individual patient factors, anatomic variations and pathology, and time constraints can preclude
98 the acquisition of all twenty-eight views. For our multi-category deep learning view
99 classification model, we chose the eight most consistently acquired TEE views in the
100 intraoperative assessment of cardiac surgery patients, including: the Mid-Esophageal (ME) 2-
101 Chamber View, ME 4-Chamber View, ME Aortic Valve (AV) Short Axis (SAX) View, ME
102 Bicaval View, ME Left Atrial Appendage View, ME Long Axis View, Trans-Gastric (TG) LV
103 SAX View, and Aortic View. Four of our eight chosen views (ME 2-Chamber, ME 4-Chamber,
104 ME AV SAX, ME Long Axis) represent pooled categories that include two standardized views
105 that capture overlapping structures. We also chose to generalize two categories (the TG LV SAX
106 and the Aortic Views), in order to increase the sample sizes of these classes. Ultrasound image

107 data was converted from Digital Imaging and Communications in Medicine (DICOM) format
108 data to AVI videos prior to machine learning analysis. All images and their associated metadata
109 were de-identified prior to labeling, model training, and analysis.

110

111 *AI Model Design and Testing*

112

113 We trained a CNN with residual connections and spatiotemporal convolutions using the R2+1D
114 architecture²¹ to classify TEE views. Model weights were randomly initialized. Models were
115 trained to minimize the cross entropy between the predicted view and the actual labeled view.
116 We used an Adam optimizer²², a learning rate of 0.001, and a batch size of 44. We employed
117 early stopping to cease model training after no further improvement on the validation set
118 occurred. Our final model trained for nine epochs. The model was trained on 32-frame sub-clips
119 of videos in the training set, with a temporal stride of two, yielding a final model input length of
120 16 frames. The starting frame of these sub-clips within their parent clips were randomized during
121 training as a form of data augmentation. All model training was done using the Python library
122 PyTorch. Our code is available online at <https://github.com/echonet/tee-view-classifier>.

123

124 All TEE videos were labeled by a single board-certified echocardiographer. An active learning
125 approach was used to reduce the number of human annotations required. A classifier was
126 initially trained on 500 randomly selected labeled TEE videos. With the partially trained model,
127 inference was performed on unlabeled TEE videos, which were then categorized into buckets
128 based on predicted view. In the next round of video labeling, the echocardiographer focused on
129 the uncommon views and poorly performing classifications, and the model was subsequently
130 retrained based on the additional labeled TEE videos. This iterative active learning approach was
131 performed for five rounds until model performance was adequate. Only the training and
132 validation sets were constructed with this active learning approach. The videos in both the
133 internal and external test sets were independent and never seen during training.

134

135 *Statistical Analysis*

136

137 An internal hold-out test dataset from CSMC which was never seen during model training was
138 used to assess model performance. An external test set from SUMC was also used for additional
139 validation and was never seen during model training. Model performance was assessed via
140 AUROC. Two-sided 95% confidence intervals using 1,000 bootstrapped samples were computed
141 for each calculation. Unsupervised t-Distributed Stochastic Neighbor Embedding (t-SNE) was
142 used for clustering analysis²³. Statistical analysis was performed in Python.

143

144

145 **Results**

146

147 We trained a CNN to classify eight standardized TEE views. Our training and validation sets
148 contained 2,600 unique videos (split 4:1), representing 2,036 patients. The model was tested on
149 503 randomly selected videos from CSMC and 465 randomly selected videos from SUMC, none
150 of which were seen during model training. Characteristics of our training, validation, and test
151 patients are shown in Table 1. Our datasets included a broad spectrum of anatomic variation,
152 clinical pathology, and imaging indications representing the cardiac open surgical and
153 transcatheter procedural populations seen at CSMC and SUMC (Table 2). The images also
154 included a wide range of technical variation, including differences in spatial and temporal
155 resolution, field of view depth and sector width, gain, image quality, and use of color flow
156 Doppler (Figure 1).

157

158 Our view classification model achieved an overall micro-averaged area under the receiver
159 operating curve (AUC) of 0.919 on a hold-out CSMC test set of TEE videos (Figure 2). Our
160 model showed particularly good performance for the Trans-Gastric Left Ventricular Short Axis
161 View (AUC = 0.971), the Mid-Esophageal Long Axis View (AUC = 0.954), the Mid-
162 Esophageal Aortic Valve Short Axis View (AUC = 0.946), and the Mid-Esophageal 4-Chamber
163 View (AUC = 0.939).

164

165 The model performance also generalized well externally, achieving a micro-averaged AUC of
166 0.872 when tested on 465 never-before-seen TEE videos from SUMC. Our model had similar
167 performance for the Trans-Gastric Left Ventricular Short Axis View (AUC = 0.957), the Mid-

168 Esophageal Long Axis View (AUC = 0.905), the Mid-Esophageal Aortic Valve Short Axis
169 View (AUC = 0.898), and the Mid-Esophageal 4-Chamber View (AUC = 0.902) in the SUMC
170 dataset.

171
172 Clustering analysis suggests our AI model can identify a meaningful embedding space
173 representing the various TEE views from heterogeneous video input that generalizes across two
174 institutions (Figure 3). Model performance was similar in standard black-and-white 2D B-Mode
175 TEE videos (micro-averaged AUC = 0.902) and videos incorporating color flow Doppler
176 information (micro-averaged AUC = 0.877) (Figure 4), the analyses for which were performed
177 on a combination of the internal and external test videos due to the overall low prevalence of
178 color flow Doppler videos in our datasets.

179

180

181 **Conclusions**

182

183 Our deep learning model was able to classify the most commonly used intraoperative and
184 intraprocedural TEE views with high accuracy across a wide range of clinical and
185 echocardiographic characteristics. Our videos included patients undergoing many different types
186 of open cardiac surgery and transcatheter procedures, representing a broad spectrum of anatomic
187 pathology and differences in practice patterns across two institutions. The presence or absence of
188 medical devices in our images (prosthetic valves, procedural wires, pacemakers, MitraClips) was
189 highly variable among our datasets. Images also varied with respect to resolution, sizing and
190 focus of the field of view, and the use of color flow Doppler. The model performance was
191 consistent across the range of findings in both held-out internal and external test datasets,
192 demonstrating the generalizability of our view classifier in real-world clinical contexts.

193

194 Our study represents the first application of a machine learning strategy to TEE videos. Prior AI-
195 driven echocardiography studies focused primarily on TTE videos. It has been demonstrated that
196 machine learning algorithms can be trained to identify standard TTE views from labeled
197 datasets.^{18,19,24} Subsequent studies were able to take advantage of the standard clinical workflow
198 for transthoracic imaging, which incorporates anatomic tracings and quantitative measurements,

199 in order to streamline segmentation and classification tasks.^{4,7} It has also been shown that
200 machine learning algorithms trained on TTE videos are able to recognize cardiac structures,
201 approximate cardiac function, make accurate diagnoses, identify phenotypic information that is
202 otherwise not easily recognized by a human observer, and predict clinical outcomes.^{6,7,10,11,25}
203 Without an automated preprocessing and view classification pipeline for TEE, the ability to
204 perform downstream deep learning tasks for TEE remained challenging.

205
206 The greatest barrier to applying AI to intraoperative and intraprocedural TEE imaging is the
207 relatively unstructured nature of TEE data. TEE data is inherently variable because the
208 environment in the cardiac surgery operating rooms is highly dynamic, which results in the
209 acquisition of varying image sequences, non-standard views, and missing views. Moreover,
210 intraoperative TEE exams are subject to significant clinical variation within a single study and
211 across studies (changes in cardiac loading conditions, on- versus off-CPB, changes secondary to
212 surgical manipulation, pre- versus post-surgical intervention, pharmacologic interventions,
213 external cardiac pacing). However, given the significant role that TEE plays in the management
214 of complex cardiac pathology and high-risk surgical patients, attempting to extract additional
215 value from TEE images via deep learning strategies is worthy of exploration. The present study
216 represents the first deep learning-based TEE view classification model trained on TEE videos.

217
218 The development of a view classification model for TEE images will extend the application of
219 deep learning strategies to intraoperative echocardiography imaging. Previous work has already
220 shown that intraoperative TEE imaging actively informs surgical decision-making^{26,27} and is
221 associated with improved clinical outcomes after cardiac surgery.^{28,29} The development of AI-
222 driven models based on intraoperative TEE images has the potential to further enhance the value
223 of echocardiography in the perioperative and periprocedural period by improving the ability to
224 diagnose cardiac surgical diseases and complications, diagnose the underlying etiology of varied
225 hemodynamic states, and predict clinical outcomes in the immediate and long-term postoperative
226 periods.

227
228 In summary, we show that an intraoperative and intraprocedural TEE-based deep learning model
229 can accurately identify standardized TEE views, the first step in the AI interpretation of TEE

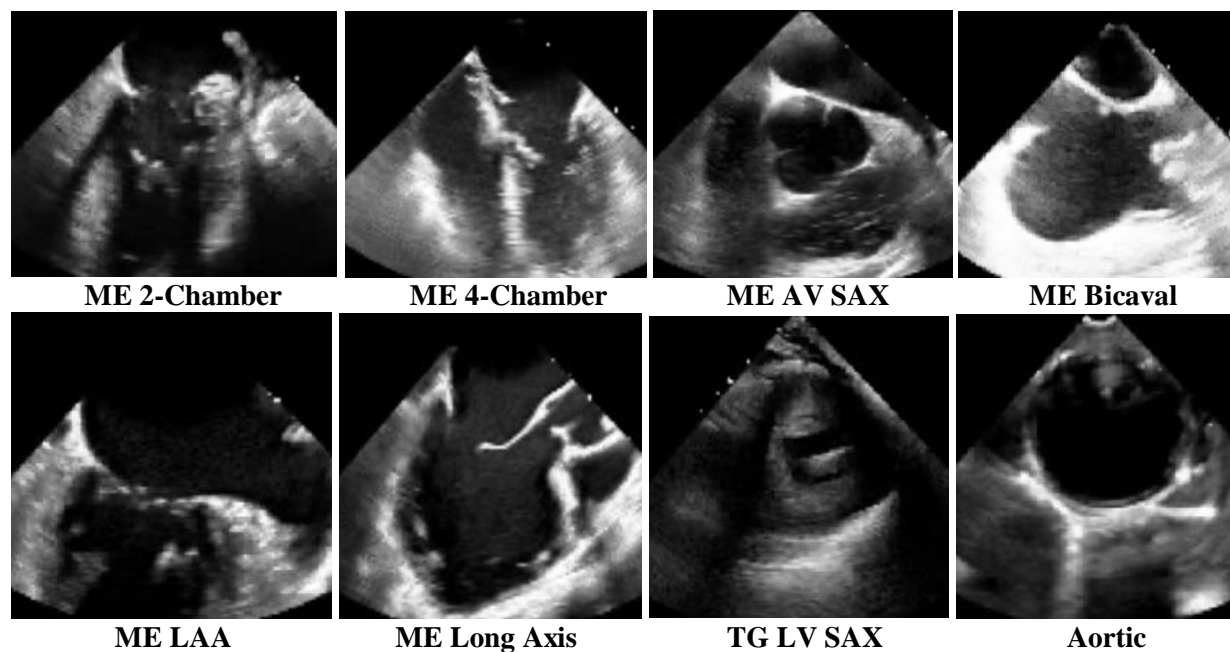
230 images. Our study represents an important first step towards the automated evaluation of
231 intraoperative imaging and the leveraging of deep learning strategies for the advancement of
232 patient care.

233

234

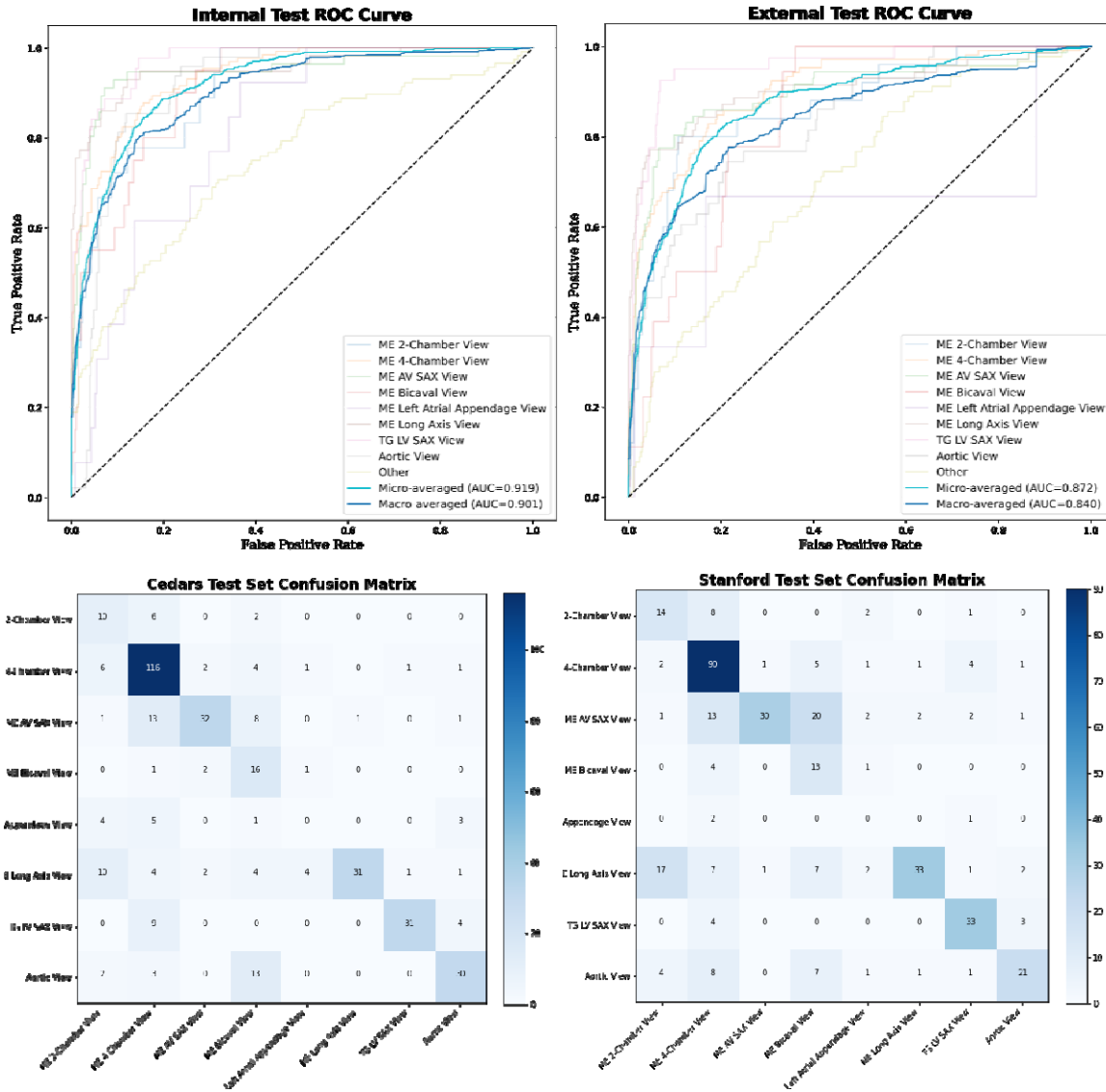
235 **Figures and Tables**

236
237



240
241
242
243
244
245
246
247
248
249
250
251
252

Figure 1. Sample training images used for the deep-learning view classification task. Above images are 2-dimensional still frames sampled from the video data used in model training. Eight standard TEE views were chosen, including: the ME 2-Chamber View, ME 4-Chamber View, ME AV SAX View, ME Bicaval View, ME LAA View, ME Long Axis View, TG LV SAX View, and Aortic View. TEE = transesophageal echocardiography; ME = mid-esophageal; AV = aortic valve; SAX = short axis; LAA = left atrial appendage; TG = trans-gastric; LV = left ventricular.



253

254

255

256 **Figure 2. View classification model performance on internal (CSMC) hold-out test set and external**
 257 **(SUMC) test set. (a) AUC's for each view class, demonstrating high accuracy (with AUC's ranging from**
 258 **0.816 – 0.957). No AUC was able to be calculated for the ME Left Atrial Appendage View in the**
 259 **randomly selected SUMC test set due to low sampling. (b) Confusion matrices showing model**
 260 **performance, with views labeled by a board-certified echocardiographer along the vertical axis and views**
 261 **predicted by the deep learning model on the horizontal axis. Numerical values in the matrices represent**
 262 **the number of images with the indicated ground-truth and model-predicted labels. Color intensity on the**
 263 **heatmap represents model accuracy. AUC = area under the receiver operating curve; CSMC = Cedars**
 264 **Sinai Medical Center; SUMC = Stanford University Medical Center; ME = mid-esophageal; AV = aortic**
 265 **valve; SAX = short axis; TG = trans-gastric; LV = left ventricular.**

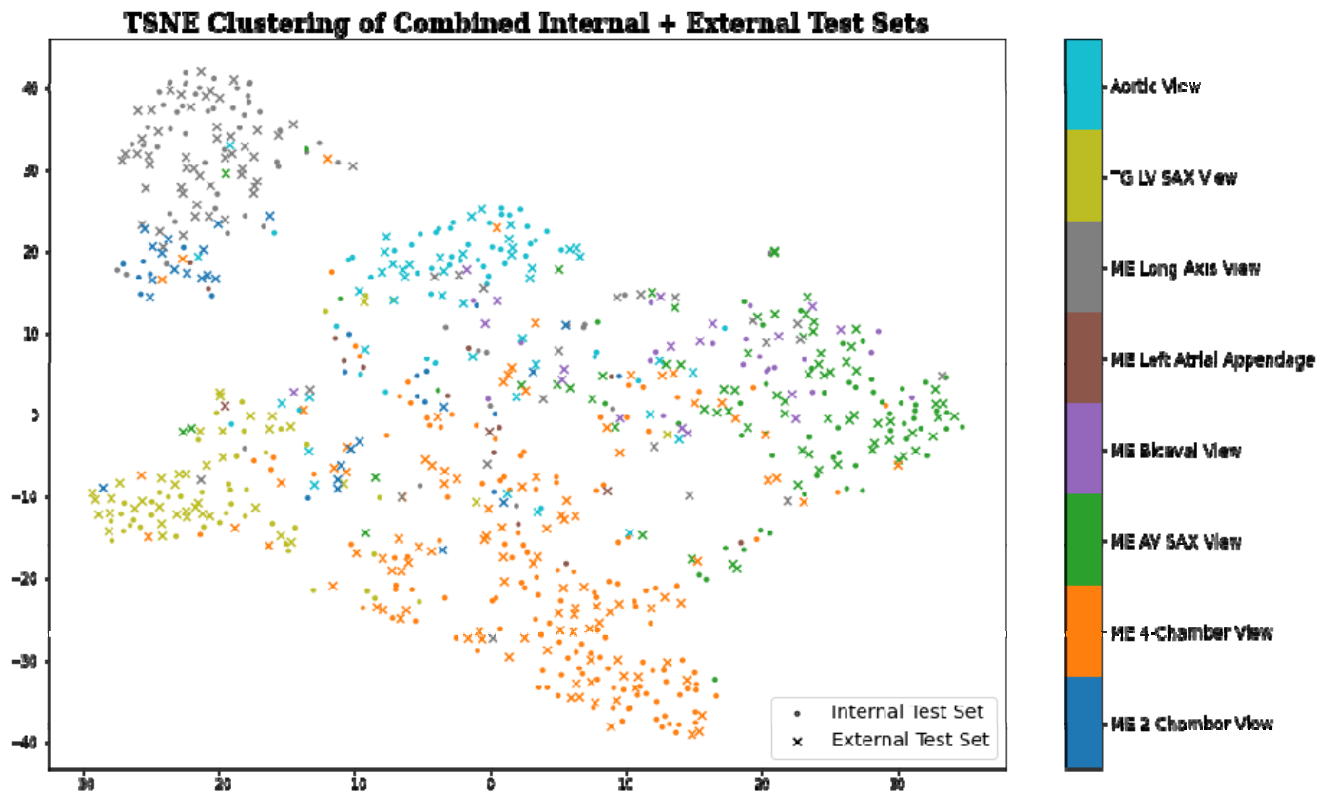
266

267

268

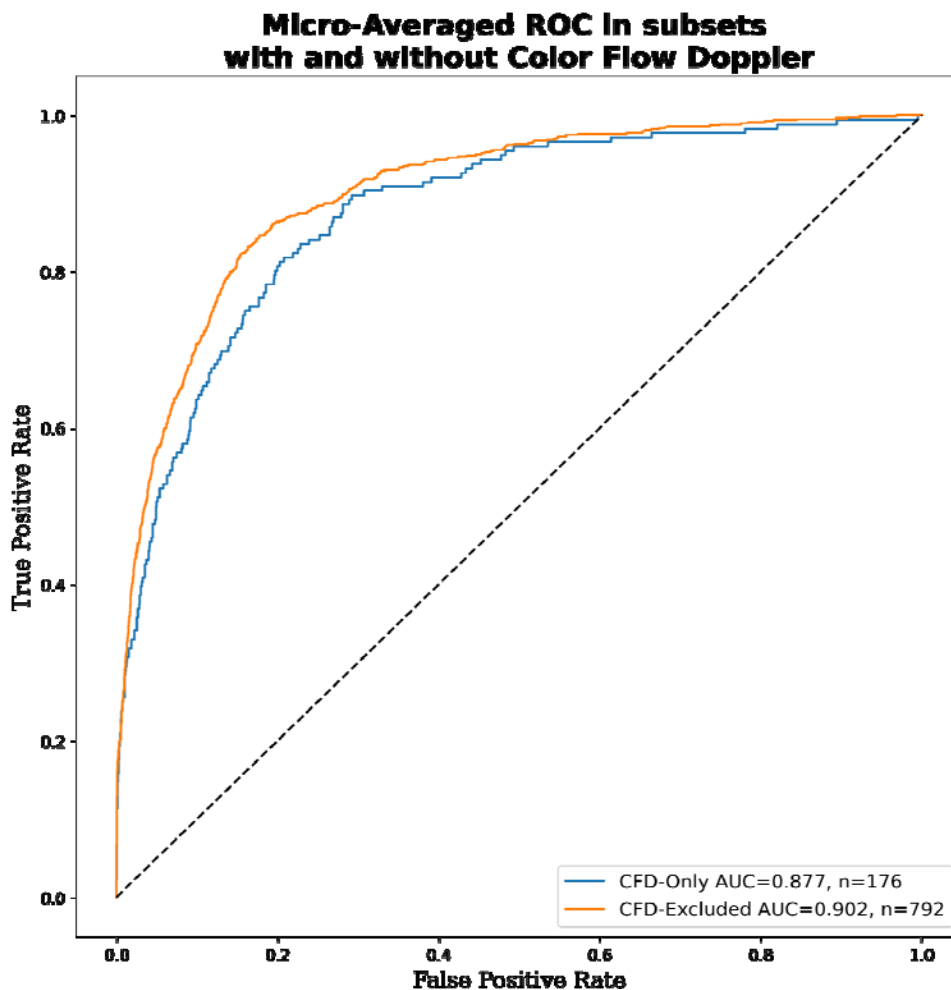
269

270



271
272

273 **Figure 3. Clustering analysis showing the model's ability to distinguish among standard TEE views.**
274 t-SNE clustering analysis of input images demonstrates that meaningful representations of standard TEE
275 views are clustered appropriately together. In other words, images are sorted into groups that reflect
276 standard TEE classes. Embedding representation is consistent across CSMC and SUMC, suggesting
277 robustness and generalizability of the approach. TEE = transesophageal echocardiography; t-SNE = t-
278 Distributed Stochastic Neighbor Embedding; CSMC = Cedars Sinai Medical Center; SUMC =
279 Stanford University Medical Center.



280
281 **Figure 4. Micro-averaged receiver operating characteristic curves for model predictions in subsets**
282 **containing all color flow Doppler videos versus no color flow Doppler videos.** This evaluation was
283 performed using a combination of the internal and external test sets due to the low prevalence of color
284 flow Doppler videos in our data sets.

285
286
287
288
289
290
291
292
293
294
295
296
297
298
299
300

	Total	Train	Validation	Internal Test
Number of videos	3,103	2,076	524	503
Age	67.8 (\pm 15.4)	67.9 (\pm 15.4)	68.3 (\pm 15.7)	66.9 (\pm 15.2)
White, n (%)	2,223 (71.6%)	1,496 (72.1%)	365 (69.7%)	362 (72.0%)
Black, n (%)	317 (10.2%)	224 (10.8%)	62 (11.8%)	31 (6.2%)
Other/Unknown, n (%)	271 (8.7%)	177 (8.5%)	41 (7.8%)	53 (10.5%)
Asian, n (%)	242 (7.8%)	152 (7.3%)	40 (7.6%)	50 (9.9%)
Pacific Islander, n (%)	35 (1.1%)	18 (0.9%)	14 (2.7%)	3 (0.6%)
Native American, n (%)	12 (0.4%)	6 (0.3%)	2 (0.4%)	4 (0.8%)
Hispanic ethnicity, n (%)	395 (12.7%)	255 (12.3%)	68 (13.0%)	72 (14.3%)
Female gender, n (%)	1,120 (36.1%)	757 (36.5%)	194 (37.0%)	169 (33.6%)
Atrial fibrillation, n (%)	1,146 (36.9%)	773 (37.2%)	194 (37.0%)	179 (35.6%)
Heart failure, n (%)	1,504 (48.5%)	1,009 (48.6%)	263 (50.2%)	232 (46.1%)
Hypertension, n (%)	1,681 (54.2%)	1,142 (55.0%)	267 (51.0%)	272 (54.1%)
Diabetes mellitus, n (%)	702 (22.6%)	483 (23.3%)	112 (21.4%)	107 (21.3%)
Ischemic stroke, n (%)	365 (11.8%)	255 (12.3%)	53 (10.1%)	57 (11.3%)
Transient ischemic attack, n (%)	194 (6.3%)	137 (6.6%)	31 (5.9%)	26 (5.2%)
Pulmonary embolism, n (%)	90 (2.9%)	63 (3.0%)	21 (4.0%)	6 (1.2%)
Myocardial infarction, n (%)	339 (10.9%)	214 (10.3%)	55 (10.5%)	70 (13.9%)
Peripheral artery disease, n (%)	540 (17.4%)	376 (18.1%)	83 (15.8%)	81 (16.1%)
Vascular disease, n (%)	814 (26.2%)	551 (26.5%)	126 (24.0%)	137 (27.2%)
Coronary artery disease, n (%)	1,152 (37.1%)	769 (37.0%)	192 (36.6%)	191 (38.0%)
Chronic kidney disease, n (%)	745 (24.0%)	495 (23.8%)	140 (26.7%)	110 (21.9%)
Liver disease, n (%)	159 (5.1%)	110 (5.3%)	24 (4.6%)	25 (5.0%)
Chronic obstructive pulmonary disease, n (%)	200 (6.4%)	139 (6.7%)	27 (5.2%)	34 (6.8%)
Prior smoker, n (%)	181 (5.8%)	119 (5.7%)	35 (6.7%)	27 (5.4%)

301
302
303

Table 1. Clinical characteristics represented in the training, validation, and internal test data sets.

304

305

	Total	Train	Validation	Internal Test
Number of videos	3,103	2,076	524	503
CABG (%)	194 (6.3)	124 (6.0)	31 (5.9)	39 (7.8)
Valve procedure (%)	321 (10.3)	215 (10.4)	42 (8.0)	64 (12.7)
Aortic procedure (%)	42 (1.4)	30 (1.4)	3 (0.6)	9 (1.8)
Combination of CABG, valve, and/or aortic procedure	218 (7.0)	140 (6.7)	35 (6.7)	43 (8.5)
Other open cardiac procedure (%)	317 (10.2)	215 (10.4)	56 (10.7)	46 (9.1)
Mechanical circulatory support (%)	52 (1.7)	30 (1.4)	13 (2.5)	9 (1.8)
Transcatheter procedure (%)	1959 (63.1)	1322 (63.7)	344 (65.6)	293 (58.3)

306

307 **Table 2. Surgery or procedure types represented in our training, validation, and internal test data**
308 **sets.** CABG = Coronary Artery Bypass Graft.

309

310

311 **References**

- 312 1. Vos, T. *et al.* Global burden of 369 diseases and injuries in 204 countries and territories,
313 1990–2019: a systematic analysis for the Global Burden of Disease Study 2019. *Lancet* **396**,
314 1204–1222 (2020).
- 315 2. Doherty, J. U., Kort, S., Mehran, R., Schoenhagen, P. & Soman, P.
316 ACC/AATS/AHA/ASE/ASNC/HRS/SCAI/SCCT/SCMR/STS 2017 Appropriate Use
317 Criteria for Multimodality Imaging in Valvular Heart Disease: A Report of the American
318 College of Cardiology Appropriate Use Criteria Task Force, American Association for
319 Thoracic Surgery, American Heart Association, American Society of Echocardiography,
320 American Society of Nuclear Cardiology, Heart Rhythm Society, Society for
321 Cardiovascular Angiography and Interventions, Society of Cardiovascular Computed
322 Tomography, Society for Cardiovascular Magnetic Resonance, and Society of Thoracic
323 Surgeons. *J. Am. Coll. Cardiol.* **70**, 1647–1672 (2017).
- 324 3. Doherty, J. U. *et al.* ACC/AATS/AHA/ASE/ASNC/HRS/SCAI/SCCT/SCMR/STS 2019
325 appropriate use criteria for multimodality imaging in the assessment of cardiac structure and
326 function in nonvalvular heart disease: A report of the American College of Cardiology
327 Appropriate Use Criteria Task Force, American Association for Thoracic Surgery,
328 American Heart Association, American Society of Echocardiography, American Society of
329 Nuclear Cardiology, Heart Rhythm Society, Society for Cardiovascular Angiography and
330 Interventions, Society of Cardiovascular Computed Tomography, Society for
331 Cardiovascular Magnetic Resonance, and the Society of Thoracic Surgeons. *J. Thorac.*
332 *Cardiovasc. Surg.* **157**, e153–e182 (2019).
- 333 4. Ouyang, D. *et al.* Video-based AI for beat-to-beat assessment of cardiac function. *Nature*
334 **580**, 252–256 (2020).

- 335 5. Zhang, J. *et al.* Fully Automated Echocardiogram Interpretation in Clinical Practice.
336 *Circulation* **138**, 1623–1635 (2018).
- 337 6. Hughes, J. W. *et al.* Deep learning evaluation of biomarkers from echocardiogram videos.
338 *EBioMedicine* **73**, 103613 (2021).
- 339 7. He, B. *et al.* Blinded, randomized trial of sonographer versus AI cardiac function
340 assessment. *Nature* (2023) doi:10.1038/s41586-023-05947-3.
- 341 8. Zamorano, J. L. *et al.* EAE/ASE Recommendations for the Use of Echocardiography in
342 New Transcatheter Interventions for Valvular Heart Disease. *J. Am. Soc. Echocardiogr.* **24**,
343 937–965 (09/2011).
- 344 9. Nicoara, A. *et al.* Guidelines for the Use of Transesophageal Echocardiography to Assist
345 with Surgical Decision-Making in the Operating Room: A Surgery-Based Approach. *J. Am.*
346 *Soc. Echocardiogr.* **33**, 692–734 (06/2020).
- 347 10. Duffy, G. *et al.* High-Throughput Precision Phenotyping of Left Ventricular Hypertrophy
348 With Cardiovascular Deep Learning. *JAMA Cardiology* **7**, 386–395 (2022).
- 349 11. Ghorbani, A. *et al.* Deep learning interpretation of echocardiograms. *npj Digit. Med.* **3**, 1–
350 10 (2020).
- 351 12. Khurshid, S. *et al.* Deep Learning to Predict Cardiac Magnetic Resonance-Derived Left
352 Ventricular Mass and Hypertrophy From 12-Lead ECGs. *Circ. Cardiovasc. Imaging* **14**,
353 e012281 (2021).
- 354 13. Poplin, R. *et al.* Prediction of cardiovascular risk factors from retinal fundus photographs
355 via deep learning. *Nat Biomed Eng* **2**, 158–164 (2018).
- 356 14. Esteva, A. *et al.* Dermatologist-level classification of skin cancer with deep neural
357 networks. *Nature* **542**, 115–118 (2017).

- 358 15. Coudray, N. *et al.* Classification and mutation prediction from non–small cell lung cancer
359 histopathology images using deep learning. *Nat. Med.* **24**, 1559–1567 (2018).
- 360 16. Nagpal, K. *et al.* Development and validation of a deep learning algorithm for improving
361 Gleason scoring of prostate cancer. *npj Digit. Med.* **2**, 1–10 (2019).
- 362 17. Tiu, E. *et al.* Expert-level detection of pathologies from unannotated chest X-ray images via
363 self-supervised learning. *Nat Biomed Eng* **6**, 1399–1406 (2022).
- 364 18. Madani, A., Arnaout, R., Mofrad, M. & Arnaout, R. Fast and accurate view classification of
365 echocardiograms using deep learning. *npj Digital Med* **1**, 1–8 (2018).
- 366 19. Madani, A., Ong, J. R., Tibrewal, A. & Mofrad, M. R. K. Deep echocardiography: data-
367 efficient supervised and semi-supervised deep learning towards automated diagnosis of
368 cardiac disease. *NPJ Digit Med* **1**, 59 (2018).
- 369 20. Hahn, R. T. *et al.* Guidelines for Performing a Comprehensive Transesophageal
370 Echocardiographic Examination: Recommendations from the American Society of
371 Echocardiography and the Society of Cardiovascular Anesthesiologists. *J. Am. Soc.*
372 *Echocardiogr.* **26**, 921–964 (09/2013).
- 373 21. Tran, D. *et al.* A Closer Look at Spatiotemporal Convolutions for Action Recognition. in
374 *2018 IEEE/CVF Conference on Computer Vision and Pattern Recognition* (IEEE, 2018).
375 doi:10.1109/cvpr.2018.00675.
- 376 22. Kingma, D. P. & Ba, J. Adam: A Method for Stochastic Optimization. *arXiv [cs.LG]*
377 (2014).
- 378 23. van der Maaten, L. & Hinton, G. Visualizing Data using t-SNE. *J. Mach. Learn. Res.* **9**,
379 2579–2605 (2008).
- 380 24. Gearhart, A., Goto, S., Deo, R. C. & Powell, A. J. An Automated View Classification

- 381 Model for Pediatric Echocardiography Using Artificial Intelligence. *J. Am. Soc.*
382 *Echocardiogr.* **35**, 1238–1246 (12/2022).
- 383 25. Shad, R. *et al.* Predicting post-operative right ventricular failure using video-based deep
384 learning. *Nat. Commun.* **12**, 5192 (2021).
- 385 26. Nowrangi, S. K., Connolly, H. M., Freeman, W. K. & Click, R. L. Impact of intraoperative
386 transesophageal echocardiography among patients undergoing aortic valve replacement for
387 aortic stenosis. *J. Am. Soc. Echocardiogr.* **14**, 863–866 (2001).
- 388 27. Shapira, Y. *et al.* Impact of intraoperative transesophageal echocardiography in patients
389 undergoing valve replacement. *Ann. Thorac. Surg.* **78**, 579–583 (2004).
- 390 28. MacKay, E. J., Zhang, B., Augoustides, J. G., Groeneveld, P. W. & Desai, N. D.
391 Association of Intraoperative Transesophageal Echocardiography and Clinical Outcomes
392 After Open Cardiac Valve or Proximal Aortic Surgery. *JAMA Network Open* **5**, e2147820
393 (2022).
- 394 29. Metkus, T. S. *et al.* Transesophageal Echocardiography in Patients Undergoing Coronary
395 Artery Bypass Graft Surgery. *J. Am. Coll. Cardiol.* **78**, 112–122 (2021).