

## Neural Correlates of Positive and Negative Formal Thought Disorder in Individuals with Schizophrenia: An ENIGMA Schizophrenia Working Group Study

Rachel J. Sharkey<sup>1,2</sup>, Chelsea Bacon<sup>1,2</sup>, Zeru Peterson<sup>1,2</sup>, Kelly Rootes-Murdy<sup>3</sup>, Raymond Salvador<sup>4,5</sup>, Edith Pomarol-Clotet<sup>4,5</sup>, Andriana Karuk<sup>4</sup>, Philipp Homan<sup>6,7</sup>, Ellen Ji<sup>6</sup>, Wolfgang Omlor<sup>6</sup>, Stephanie Homan<sup>6</sup>, Foivos Georgiadis<sup>6</sup>, Stefan Kaiser<sup>6,8</sup>, Matthias Kirschner<sup>6,8</sup>, Stefan Ehrlich<sup>9</sup>, Udo Dannlowski<sup>10</sup>, Dominik Grotegerd<sup>10</sup>, Janik Goltermann<sup>10</sup>, Susanne Meinert<sup>10,11</sup>, Tilo Kircher<sup>12</sup>, Frederike Stein<sup>12</sup>, Katharina Brosch<sup>12</sup>, Axel Krug<sup>12,13</sup>, Igor Nenadić<sup>12</sup>, Kang Sim<sup>14,15</sup>, Gianfranco Spalletta<sup>16</sup>, Fabrizio Piras<sup>16</sup>, Nerisa Banaj<sup>16</sup>, Scott R Sponheim<sup>16,18,19</sup>, Caroline Demro<sup>18,19</sup>, Ian S Ramsay<sup>18</sup>, Margaret King<sup>20</sup>, Yann Quidé<sup>21,22</sup>, Melissa J. Green<sup>22,23</sup>, Dana Nguyen<sup>24</sup>, Adrian Preda<sup>25</sup>, Vince D. Calhoun<sup>3</sup>, Jessica A. Turner<sup>26,27</sup>, Theo G.M. van Erp<sup>28,29</sup>, Thomas Nickl-Jockschat<sup>1,2,30</sup>

<sup>1</sup> Iowa Neuroscience Institute, Carver College of Medicine, University of Iowa, Iowa City, IA, USA

<sup>2</sup> Department of Psychiatry, University of Iowa, Iowa City, IA, USA

<sup>3</sup> Tri-institutional Center for Translational Research in Neuroimaging and Data Science (TReNDS), Georgia State University, Georgia Institute of Technology and Emory University, Atlanta, GA, United States

<sup>4</sup> FIDMAG Germanes Hospitalàries Research Foundation, Barcelona, Spain.

<sup>5</sup> Centro de Investigación Biomédica en Red de Salud Mental (CIBERSAM), Instituto de Salud Carlos III, Spain.

<sup>6</sup> Department of Psychiatry, Psychotherapy and Psychosomatics, Psychiatric Hospital, University of Zurich, Zurich, Switzerland

<sup>7</sup> Neuroscience Center Zurich, University of Zurich and Swiss Federal Institute of Technology Zurich, Zurich, Switzerland

<sup>8</sup> Division of Adult Psychiatry, Department of Psychiatry Geneva University Hospitals Geneva Switzerland

<sup>9</sup> Translational Developmental Neuroscience Section, Division of Psychological and Social Medicine and Developmental Neurosciences, Faculty of Medicine, TU Dresden, Germany

<sup>10</sup> Institute for Translational Psychiatry, University of Muenster, Muenster, Germany

<sup>11</sup> Institute for Translational Neuroscience, University of Muenster, Muenster, Germany

<sup>12</sup> Department of Psychiatry and Psychotherapy, University of Marburg, Marburg, Germany

<sup>13</sup> Department of Psychiatry and Psychotherapy, University of Bonn, Bonn, Germany

<sup>14</sup> West Region, Institute of Mental Health, Singapore

<sup>15</sup> Yong Loo Lin School of Medicine, National University of Singapore, Singapore

<sup>16</sup> Laboratory of Neuropsychiatry, Santa Lucia Foundation IRCCS, Rome, Italy

<sup>17</sup> Minneapolis Veterans Affairs Health Care System, Minneapolis, MN, USA.

<sup>18</sup> Department of Psychiatry and Behavioral Sciences, University of Minnesota, Minneapolis, MN, USA.

<sup>19</sup> Department of Psychology, University of Minnesota, Minneapolis, MN, USA.

<sup>20</sup> Mind Research Network, Albuquerque, NM, USA

<sup>21</sup> School of Psychology, University of New South Wales (UNSW) Sydney, Sydney, NSW, Australia

<sup>22</sup> Neuroscience Research Australia, Randwick, NSW, Australia

<sup>23</sup> Discipline of Psychiatry and Mental Health, School of Clinical Medicine, University of New South Wales (UNSW) Sydney, Sydney, NSW, Australia

<sup>24</sup> Department of Pediatric Neurology, University of California Irvine, Irvine, CA, 92697, USA

<sup>25</sup> Department of Psychiatry and Human Behavior, University of California Irvine, Irvine, CA, 92697, USA

<sup>26</sup> Psychiatry and Behavioral Health, Ohio State Wexner Medical Center, Columbus, OH, USA

<sup>27</sup> Imaging Genetics and Neuroinformatics Lab, Georgia State University, Atlanta, Georgia

<sup>28</sup> Clinical Translational Neuroscience Laboratory, Department of Psychiatry and Human Behavior, University of California Irvine, Irvine Hall, room 109, Irvine, CA, 92697-3950, USA

<sup>29</sup> Center for the Neurobiology of Learning and Memory, University of California Irvine, 309 Qureshey Research Lab, Irvine, CA, 92697, USA

<sup>30</sup> Department of Neuroscience and Pharmacology, Carver College of Medicine, University of Iowa, Iowa City, IA, USA

**Corresponding author**

Thomas Nickl-Jockschat, MD

Andrew H. Woods Professor

Deps of Psychiatry, Neuroscience and Pharmacology

Iowa Neuroscience Institute

The University of Iowa

200 Hawkins Drive, Iowa City, IA, 52242

[thomas-nickl-jockschat@uiowa.edu](mailto:thomas-nickl-jockschat@uiowa.edu)

## Abstract

Formal thought disorder (FTD) is a key clinical factor in schizophrenia, but the neurobiological underpinnings remain unclear. In particular, relationship between FTD symptom dimensions and patterns of regional brain volume deficiencies in schizophrenia remain to be established in large cohorts. Even less is known about the cellular basis of FTD. Our study addresses these major obstacles based on a large multi-site cohort through the ENIGMA Schizophrenia Working Group (752 individuals with schizophrenia and 1256 controls), to unravel the neuroanatomy of positive, negative and total FTD in schizophrenia and their cellular bases. We used virtual histology tools to relate brain structural changes associated with FTD to cellular distributions in cortical regions. We identified distinct neural networks for positive and negative FTD. Both networks encompassed fronto-occipito-amygdalar brain regions, but negative FTD showed a relative sparing of orbitofrontal cortical thickness, while positive FTD also affected lateral temporal cortices. Virtual histology identified distinct transcriptomic fingerprints associated for both symptom dimensions. Negative FTD was linked to neuronal and astrocyte fingerprints, while positive FTD was also linked to microglial cell types. These findings relate different dimensions of FTD to distinct brain structural changes and their cellular underpinnings, improve our mechanistic understanding of these key psychotic symptoms.

## Introduction

Formal thought disorder (FTD) is a syndrome characterized by disorganized and incoherent speech [1], [2]. While FTD is a cross-diagnostic syndrome, it constitutes a key clinical factor of schizophrenia and a core component of the diagnostic criteria for this disorder in the DSM-5. Multiple lines of evidence point towards a key role for FTD in the pathophysiology of schizophrenia. It predicts transition into psychosis in clinical high-risk samples [3]–[5] and is closely correlated with long-term outcome in chronic disease states [6]–[11]. Clinically, FTD is highly heterogeneous, with impairments ranging from impoverished thought to disorganized thinking to pressured speech [12]. These different facets differentially impact clinical outcomes [7], [9], [13]. To reduce this heterogeneity, researchers have suggested grouping FTD in positive and negative symptoms [14]–[16]. While positive formal thought disorder symptoms are characterized by disorganized or unusual forms of thought or language, negative formal thought disorder includes paucity or slowing of thought or speech [12].

Brain volume reductions in fronto-temporo-basal ganglia-thalamic networks are a hallmark of schizophrenia pathology [17], [18] and might provide a major avenue towards unraveling the neurobiological basis of FTD. These brain structural abnormalities are progressive over the disease course [17] and are, at least retrospectively, linked to symptom patterns [19], [20]. Although there is an established relationship between volume deficits and overall symptom patterns in schizophrenia, major questions remain, specifically about the neuroanatomical basis of FTD in schizophrenia [18], [19], [21]. Several pioneering publications reported brain structural correlates of FTD, but these studies enrolled comparatively small numbers of schizophrenia patients (20–30 patients) [22]–[24]. Studies on much larger samples of thousands of patients, on the other hand, have pooled across patients with various diagnoses [10], [25], [26]. This approach reduces the risk of spurious correlations and increases the power compared to smaller samples; it also has the advantage that it can identify transdiagnostic markers of FTD. However, it might be less sensitive towards pathologies associated specifically with schizophrenia, as their progressive nature, their location and extent might set them apart from brain structural changes observed in other disorders [17], [27], [28].

Finally, a major limitation of conventional structural neuroimaging is that its findings can reflect various histological correlates and are, necessarily, neurobiologically nonspecific. Prior work in *post-mortem* samples has suggested that multiple neuronal and glial cell types are likely involved in the pathophysiology of schizophrenia, making histological specificity especially important [29]–[32]. The lack of specificity in structural neuroimaging is a major obstacle with regard to the identification of cellular mechanisms and neuronal circuits associated with FTD, which is difficult to model in animals. However, while neuroimaging even at ultra-high magnet strengths cannot provide a sufficient resolution to capture this level of detail, modern computational approaches based on gene expression data allow inference on the cellular composition of brain regions [33], [34]. These approaches have been subsumed under the umbrella term “virtual histology”.

This study assesses the neuroanatomical basis of FTD based on a large multi-site cohort and uses virtual histology tools on implicated brain regions to assess its cellular underpinnings. It presents the first study using a large, multi-site ENIGMA Schizophrenia Working Group dataset to identify the structural correlates of FTD. As previous neuroimaging studies [35], [36] have suggested at least at distinct correlates of positive and negative FTD, we decided to separately explore different symptom dimensions, namely positive, negative and total formal thought

disorder. We then use virtual histology tools to relate each of the structural findings to cellular distributions in the cortex. To our knowledge, this is the largest study on the structural correlates of FTD in schizophrenia to date, and the first to apply virtual histology to the structural correlates FTD.

## Results

### *Structural Associations with Formal Thought Disorder*

We employed a general linear model to associate FTD scores with regional surface area or cortical thickness measurements of each Desikan-Killiany brain atlas region [37], controlling for age, age squared to capture potential non-linear relationships, gender and intracranial volume with FDR correction. Separate models were used for total (PANSS items: P2, N5, N6, N7), positive (P2) and negative (N5, N6, N7) FTD, and also for each of the three PANSS items contributing to negative FTD separately. These definitions of formal thought disorder have been used previously for investigating the neural basis of formal thought disorder [35].

#### *Total Formal Thought Disorder*

Total FTD was associated with lower volumes of the bilateral pallidum and left amygdala, and thicker cortex in fronto-occipital regions. In addition, association with thicker cortex in rostral middle frontal and postcentral pole regions, as well as right caudal anterior cingulate cortex and lateral occipital and pericalcarine regions were implicated (Figure 1A, D, G; Table 1).

#### *Positive Formal Thought Disorder*

Positive FTD was associated with frontal, temporal and occipital cortical regions. These include associations with smaller surface area in the bilateral temporal, bilateral lingual, and right medial orbitofrontal cortex, and associations with thinner cortex in the left lateral orbitofrontal and right medial orbitofrontal cortex, the rostral anterior cingulate, left caudal anterior and posterior cingulate, and temporal cortex (including the superior and middle temporal gyri and temporal poles), the parahippocampal, entorhinal and fusiform cortex, and the insula. There were also associations with thicker cortex in the right cuneus, pericalcarine and lateral occipital cortex, left lingual, and pericalcarine (Figure 1B, E, H; Table 2).

#### *Negative Formal Thought Disorder*

Negative FTD was associated with smaller surface area in the lateral occipital cortex, lower pallidum and left amygdala volume, and thicker cortex in the right caudal anterior cingulate and rostral middle frontal gyri. Examining the three PANSS scores contributing to the negative FTD score separately, show that the significant findings were predominantly driven by associations with item N5 (difficulty with abstract thinking) ratings. Item N6 ratings were not significantly associated with cortical volume, and item N7 ratings were only associated with thicker medial orbitofrontal cortex (Figure 1C, F, I; Table 3; Supplementary Table 3).

While a fronto-occipital network was implicated in all three symptom dimensions—total, positive and negative FTD—frontal changes, in particular those in the medial orbitofrontal cortex, showed opposite patterns for cortical thickness: positive FTD was associated with *thinner* cortex, while total and negative FTD was associated with *thicker* cortex relative to other patients. Lateral temporal regions were only implicated in positive FTD. These findings suggest a neurobiological divergence of positive and negative FTD and are in line with recent functional neuroimaging findings [21], [35].

### *The influence of site on the results*

To assess possible site-specific effects on the results, we conducted a leave-one-out analysis. Results were consistent for positive and negative FTD, while findings for total FTD did not reproduce (Figure 2, Tables 5 and 6). These results suggest robust findings for both FTD subscales, while structural correlates of total FTD may at least partially vary by site.

### *Patient vs. Control Comparisons*

In order to compare results related to FTD with those more generally associated with schizophrenia, we used a two-sample t-test comparing patients with schizophrenia with controls. We identified wide-spread smaller cortical surface area and volume, smaller subcortical volumes, and larger lateral ventricle volumes in patients compared to healthy controls, but also larger left caudate volumes in schizophrenia. The regions that showed positive associations with FTD were smaller in schizophrenia compared to the control group, indicating a process of relative sparing rather than enlargement (Supplementary Table 2).

### *Auditory Hallucination Associations*

Prior research has led to the hypothesis that FTD primarily emerges from disturbances in language processing networks (dyssemantic hypothesis of FTD) [38], [39]. To test whether the identified structural changes were specific for FTD or rather indicative of unspecific changes in language processing networks in schizophrenia [2], we explored potential correlations between structural variation in FTD-related brain regions and auditory hallucinations, another major language-associated pathology in schizophrenia [40]. The regions which were significantly associated with FTD were also examined for a relationship with auditory hallucination symptoms using similar general linear models. There were no significant relationships with auditory hallucinations, suggesting the observed network is specific to FTD, not general to auditory and language dysfunction in schizophrenia.

### *Cellular Genetic Fingerprint Associations*

MRI imaging has provided valuable insight into *in vivo* pathologies in schizophrenia, but is unable to provide information about underlying histological changes. Novel virtual histology approaches based on gene expression databases such as the Allen Human Brain Atlas [41] utilize complex gene expression patterns to identify the cellular composition of a given brain region [33], [34]. Capitalizing on this approach, we correlated the distribution of these gene expression fingerprints with the patterns of cortical thickness change identified in our data as described previously [33]. All FTD dimensions were bilaterally associated with transcriptomic fingerprints for astrocytes (“astrocyte”) and dendritic spine maintenance (“CA1 pyramidal”). The “CA1 pyramidal” label here refers to the original source for the genetic fingerprint, but the respective gene expression patterns have been confirmed to be distributed throughout the cortex [33]. Positive FTD was also associated with the fingerprint for microglial function (“microglia”), but negative FTD was associated with microglial function in the right hemisphere only. Hence, the brain structural dissociation between positive and negative FTD appears to be somewhat accompanied by a dissociation also on a cellular level (Table 4). Positive FTD, which was associated with greater cortical atrophy was also more strongly associated with microglia which have been previously associated with excessive synaptic pruning in schizophrenia [42].

## Discussion

This study identified novel neural networks associated with different symptom dimensions of FTD in a large cohort of individuals with schizophrenia (Figure 1). While prior studies of FTD, including meta-analyses have identified abnormalities in superior temporal gyrus activation [43] and connectivity associated with FTD—the latter specifically for positive FTD [35]. This study suggests that these earlier findings are only one component of a more extensive network. The temporal lobe component of the structural network identified in this study overlaps with previously identified functional findings but connects to a wider range of regions, especially in the occipital lobe which is rarely studied in the context of schizophrenia.

Both positive and negative FTD were found to be related to fronto-occipital brain regions, namely the medial orbitofrontal cortex, anterior cingulate, lateral occipital cortex and negative FTD was also found to be related to the left amygdala. However, anatomical measures related differentially between the two FTD dimensions. The associations of our FTD core network provide further insight into a long-standing controversy in the field: whether FTD emerges from dysfunction in language processing networks (“dyssemantic hypothesis”) [44] or rather from deficits in higher-order cognitive processes (“dysexecutive hypothesis”) [38]. Of note, these core regions were outside canonical language-related circuits [45], but rather associated with cognitive and behavioral control (*medial orbitofrontal* [46]–[48] and *anterior cingulate* [49], [50]), affective processing (*amygdala* [51], [52]) which have been associated with schizophrenia in previous studies [18], [22], [53], and abstract thinking and imagination (*lateral occipital cortex* [54]–[59]), which has been less commonly associated with schizophrenia [57], [58], [60]. Our findings suggest a potential role for dysfunctional executive processing as a common feature shared across FTD domains. However, it should be noted that positive FTD was also associated with classical language-related regions, suggesting a role for impaired semantic functions especially in the case of positive FTD (Figure 1B, 1E; Tables 1 – 3).

A closer look at differences between findings for distinct FTD symptom dimensions demonstrates a dissociation between the structural features of positive and negative FTD. In particular, positive and negative FTD showed opposing patterns of associations with cortical thickness in the orbitofrontal cortex and the rostral anterior cingulate (Figure 1B-C, 1E-F). Negative FTD showed a positive correlation with cortical thickness in these frontal brain regions, however, it should be noted that these findings were indicative of a relative sparing from a fronto-temporal pattern of atrophy [18], [22] in individuals with schizophrenia, rather than an absolute increase, when compared to healthy controls (Figure 1). When schizophrenia subjects were compared to healthy controls, widespread smaller cortical surface area, thinner cortex, and smaller volumes were observed (Supplementary Table 2). Different deficiency patterns in two central hubs involved in cognitive control may indicate that differential biological mechanisms or different cellular populations play a role in the emergence of these types of FTD.

Additionally, positive FTD was the only symptom dimension that implicated brain regions in the temporal cortex, particularly in language-related areas (Figure 1B, 1E; Table 2). A previous meta-analysis from our lab highlighted functional changes of the superior and medial temporal gyrus in FTD [43]; central hubs of the human language processing network [61]. The temporal pole, in turn, has been linked to a semantic network involved in creative thinking [62]. Importantly, connectome-based modeling with seeds in the superior and medial temporal cortex edpredicted positive FTD symptom severity, but not any other FTD dimension [21], which is

well in line with our own findings. Together, these findings paint the picture of a role for language-related networks exclusively in positive FTD. The results of our study further support the idea of a fundamental neurobiological divergence between positive and negative symptom dimensions [1], [63] which has both been shown for general schizophrenia psychopathology and its neural correlates [21].

Due to its limited spatial resolution, MR imaging does not allow a direct link between macroscopic changes and underlying molecular or cellular pathologies, a key requirement for the development of new therapeutic approaches. Novel methods, however, allow at least indirect inference on these molecular processes. Our virtual histology approach [33], based on gene expression patterns provided by the Allen Human Brain Atlas [41], identified distinct transcriptomic fingerprints associated with each of the three symptom dimensions (Table 4). Common to both the positive and negative FTD dimensions was a transcriptomic signature associated with dendritic spine maintenance and astrocytes. Consistent with this finding, post mortem studies have reported lower dendritic spine density and impaired dendritic plasticity in the brains of individuals with schizophrenia [32], [64]. Mechanistically, loss of dendritic spines has been linked to altered function in human complex 4 (C4) [65]. Complex genetic variation in the C4 gene, in turn, has been linked to schizophrenia risk [66]. Our own finding that neuroanatomical variation associated with both FTD dimensions is situated in brain regions with a high demand for dendritic spine maintenance appears plausible in light of these prior findings. Besides their role in synapse formation during development [67], astrocytes are known to modulate glutamatergic signaling [29], [31]. Pharmacological antagonization of glutamate signaling, in turn, has been shown to induce both positive and negative FTD in healthy subjects [68]–[70]. Beyond these signatures, positive FTD was also found to be associated with brain regions enriched for another non-neuronal cellular fingerprint: microglia. As resident immune cells of the central nervous system, microglia cells are involved in synaptic pruning during development [42], [71].

Our study has several limitations. The large sample size of our study made possible by the ENIGMA consortium has enabled us to identify novel neural networks associated with FTD that earlier, smaller studies were unable to identify. However, pooling over multiple sites limited us to operationalization of FTD through the use of several PANSS items, as rating scales tailored more precisely for formal thought disorder were not available across all cohorts. Additionally, neuroanatomical abnormalities in schizophrenia have been shown to be progressive. Hence, a longitudinal approach might provide an even better link between brain structural alterations and FTD than a cross-sectional approach and will be an important aim for future studies. Finally, we used a recently established virtual histology approach to identify potential cellular contributions to FTD [33]. While we regard this approach as a unique option to generate observer-independent data-driven hypotheses about the cellular underpinnings of brain structural changes associated with FTD, it does not provide direct evidence of cellular pathologies in the brains of individuals with schizophrenia. Postmortem histological studies with ante-mortem FTD ratings are warranted to verify or falsify the virtual histology findings.

In sum, this study demonstrates a convergence between neuroimaging and cellular endophenotypes and is, to the best of our knowledge, the first to associate glial function with formal thought disorder specifically. The identification of a multi-scale associations between structural and transcriptomic networks associated with cellular function is of specific interest clinically, because it provides the basis for linking neuroimaging findings and clinically relevant molecular targets in a way that is not possible with either method in isolation.



## Methods

### *ENIGMA Schizophrenia Working Group Data*

This study included the data from 752 individuals with schizophrenia and 1256 healthy controls pooled by the ENIGMA Consortium Schizophrenia Working Group. The data comprised cortical thickness and cortical surface area, and subcortical volume for each region in the Desikan-Killiany atlas, subcortical volumes, demographic information, and PANSS symptom scores (see Supplementary Table 1 for sample details and image processing).

### *Formal Thought Disorder Scores*

We calculated formal thought disorder and auditory hallucination symptom score for each patient from the PANSS. Four symptom scores were calculated for each patient: total formal thought disorder, positive formal thought disorder, negative formal thought disorder and hallucinations.

The total formal thought disorder scale was derived from the sum of items P2, N5, N6 and N7, as has been used in previous studies [35]. Of this subset, P2 was used as a measure of positive formal thought disorder, while negative formal thought disorder was measured as the sum of N5, N6 and N7. Hallucinations were measured by the P3 score. Tests of the relationship between formal thought disorder related findings and auditory hallucinations were carried out to test the specificity of the results to formal thought disorder.

### *General Linear Models*

Each of the major comparisons in this study used a general linear model examining associations between a variable of interest and the regional cortical thickness, surface area and subcortical volume values in a mass univariate manner which was then controlled for multiple comparisons to false discovery rate  $q=0.001$ . Each model controlled for age, age squared, gender and intracranial volume in format:

$$Y = \beta_0 + \beta_1\{\text{Variable of interest}\} + \beta_2\text{Age} + \beta_3\text{Age}^2 + \beta_4\text{Gender} + \beta_5\text{Intracranial Volume} + \varepsilon$$

This model was used for the relationship between cortical thickness and surface area and subcortical volume and: Total Formal Thought Disorder, Positive Formal Thought Disorder, Negative Formal Thought Disorder, N5, N6, N7 and Diagnosis. The same model was applied to the relationship between Auditory Hallucinations for regions that showed significant correlations with the formal thought disorder scores. Similar statistical models have been used in multiple ENIGMA studies [72], [73].

### *Leave-one-out Validation for Site Variability*

Matlab scripts were written to check for findings predominantly driven by results from single sites. This analysis repeated the statistical analysis 10 times, each time removing the data from one site. Using the output of these analyses, we summarized any regions that appeared as significant in one or more of the leave one out analyses, taking note of the directionality of the change (see Figure 3).

### *Schizophrenia vs. Control Comparison*

A bidirectional two-sample t-test was performed comparing the schizophrenia and control groups, without controlling for the additional variables of no interest. This was included along with the GLM for diagnosis effects to model effects which include the global reduction in ICV which has been previously demonstrated in schizophrenia.

### *Cellular Genetic Fingerprint Associations*

R scripts released by the Paus Lab were used to associate our regional cortical thickness findings with the regional distributions of different cellular fingerprints (see Shin et al 2018 for details on the method) [33].

## Acknowledgements

FIDMAG: Supported by Instituto de Salud Carlos III (Co-funded by European Regional Development Fund/European Social Fund) "Investing in your future"): Miguel Servet Research Contract (CPII16/00018 to E. Pomarol-Clotet and CP14/00041 to J. Radua.).

SWIFT (Homan, Zurich): Supported by a NARSAD grant from the Brain & Behavior Research Foundation (28445) and by a Research Grant from the Novartis Foundation (20A058).

FOR2107 Marburg: This work was funded by the German Research Foundation (DFG), Tilo Kircher (speaker FOR2107; DFG grant numbers KI 588/14-1, KI 588/14-2), Axel Krug (KR 3822/5-1, KR 3822/7-2), Igor Nenadić (NE 2254/1-2), Carsten Konrad (KO 4291/3-1).

FOR2107 Münster: This work is part of the German multicenter consortium “Neurobiology of Affective Disorders. A translational perspective on brain structure and function“, funded by the German Research Foundation (Deutsche Forschungsgemeinschaft DFG; Forschungsgruppe/Research Unit FOR2107). Work Package WP1, FOR2107/MACS cohort and brainimaging: Udo Dannlowski (co-speaker FOR2107; DA 1151/5-1, DA 1151/5-2)

IGP: The Imaging Genetics in Psychosis (IGP) study was funded by Project Grants from the Australian National Health and Medical Research Council (NHMRC; APP630471 and APP1081603), and the Macquarie University’s ARC Centre of Excellence in Cognition and its Disorders (CE110001021). This project used participants from the Australian Schizophrenia Research Bank (ASRB), funded by the NHMRC Enabling Grant (386500 held by V. Carr, U. Schall, R. Scott, A. Jablensky, B. Mowry, P. Michie, S. Catts, F. Henskens and C. Pantelis; Chief Investigators), and the Pratt Foundation, Ramsay Health Care, the Viertel Charitable Foundation, as well the Schizophrenia Research Institute, using an infrastructure grant from the NSW Ministry of Health.

RomeSL: This study was supported by grants (RC10-11-12-13-14-15/A) from the Italian Ministry of Health and by the ERANET NEURON from the European Commission.

COBRE: The COBRE project was supported by NIH grants R01EB006841 and P20GM103472, and NSF grant 1539067. Jessica A. Turner and Vince D. Calhoun are supported by 5R01MH094524 and 5R01MH121246.

Singapore: This study was supported by research grants from the National Healthcare Group, Singapore (SIG/05004), and the Singapore Bioimaging Consortium (RP C009/2006) research grants awarded to K.S.

UCISZ: The UCISZ study was supported by the National Institutes of Mental Health grant number R21MH097196 to TGMvE. UCISZ data was processed by the UCI High Performance Computing cluster supported by Joseph Farran, Harry Mangalam, and Adam Brenner and the National Center for Research Resources and the National Center for Advancing Translational Sciences, National Institutes of Health, through Grant UL1 TR000153.

T.N.-J. was supported by the Andrew H. Woods Professorship.

### **Conflicts of Interest**

The authors declare that there is no conflict of interest.

## References

- [1] N. C. Andreasen, “Thought, language, and communication disorders. II. Diagnostic significance,” *Arch. Gen. Psychiatry*, vol. 36, no. 12, pp. 1325–1330, Nov. 1979, doi: 10.1001/archpsyc.1979.01780120055007.
- [2] L. E. DeLisi, “Speech disorder in schizophrenia: review of the literature and exploration of its relation to the uniquely human capacity for language,” *Schizophr. Bull.*, vol. 27, no. 3, pp. 481–496, 2001, doi: 10.1093/oxfordjournals.schbul.a006889.
- [3] J. A. Hartmann *et al.*, “Declining transition rates to psychotic disorder in ‘ultra-high risk’ clients: Investigation of a dilution effect,” *Schizophr. Res.*, vol. 170, no. 1, pp. 130–136, Jan. 2016, doi: 10.1016/j.schres.2015.11.026.
- [4] J. E. DeVlyder *et al.*, “Symptom trajectories and psychosis onset in a clinical high-risk cohort: the relevance of subthreshold thought disorder,” *Schizophr. Res.*, vol. 159, no. 2–3, pp. 278–283, Nov. 2014, doi: 10.1016/j.schres.2014.08.008.
- [5] M. Armando *et al.*, “Twelve-month psychosis-predictive value of the ultra-high risk criteria in children and adolescents,” *Schizophr. Res.*, vol. 169, no. 1–3, pp. 186–192, Dec. 2015, doi: 10.1016/j.schres.2015.10.033.
- [6] C. R. Bowie, M. Gupta, and K. Holshausen, “Disconnected and underproductive speech in schizophrenia: unique relationships across multiple indicators of social functioning,” *Schizophr. Res.*, vol. 131, no. 1–3, pp. 152–156, Sep. 2011, doi: 10.1016/j.schres.2011.04.014.
- [7] C. R. Bowie and P. D. Harvey, “Communication Abnormalities Predict Functional Outcomes in Chronic Schizophrenia: Differential Associations with Social and Adaptive Functions,” *Schizophr. Res.*, vol. 103, no. 0, pp. 240–247, Aug. 2008, doi: 10.1016/j.schres.2008.05.006.
- [8] E. Roche *et al.*, “Language disturbance and functioning in first episode psychosis,” *Psychiatry Res.*, vol. 235, pp. 29–37, Jan. 2016, doi: 10.1016/j.psychres.2015.12.008.
- [9] E. Roche *et al.*, “The prognostic value of formal thought disorder following first episode psychosis,” *Schizophr. Res.*, vol. 178, no. 1–3, pp. 29–34, Dec. 2016, doi: 10.1016/j.schres.2016.09.017.
- [10] F. Stein *et al.*, “Dimensions of Formal Thought Disorder and Their Relation to Gray- and White Matter Brain Structure in Affective and Psychotic Disorders,” *Schizophr. Bull.*, vol. 48, no. 4, pp. 902–911, Jun. 2022, doi: 10.1093/schbul/sbac002.
- [11] F. Stein *et al.*, “Psychopathological Syndromes Across Affective and Psychotic Disorders Correlate With Gray Matter Volumes,” *Schizophr. Bull.*, vol. 47, no. 6, pp. 1740–1750, Oct. 2021, doi: 10.1093/schbul/sbab037.
- [12] T. Kircher, H. Bröhl, F. Meier, and J. Engelen, “Formal thought disorders: from phenomenology to neurobiology,” *Lancet Psychiatry*, vol. 5, no. 6, pp. 515–526, Jun. 2018, doi: 10.1016/S2215-0366(18)30059-2.
- [13] E. J. Tan and S. L. Rossell, “Formal thought disorder and neurocognition in schizophrenia: The question of individual mechanisms,” *Schizophr. Res.*, vol. 190, pp. 189–190, Dec. 2017, doi: 10.1016/j.schres.2017.03.039.
- [14] N. C. Andreasen and W. M. Grove, “Thought, language, and communication in schizophrenia: diagnosis and prognosis,” *Schizophr. Bull.*, vol. 12, no. 3, pp. 348–359, 1986, doi: 10.1093/schbul/12.3.348.

- [15] N. C. Andreasen, M. Flaum, V. W. Swayze, G. Tyrrell, and S. Arndt, “Positive and negative symptoms in schizophrenia. A critical reappraisal,” *Arch. Gen. Psychiatry*, vol. 47, no. 7, pp. 615–621, Jul. 1990, doi: 10.1001/archpsyc.1990.01810190015002.
- [16] N. C. Andreasen, “Methods for assessing positive and negative symptoms,” *Mod. Probl. Pharmacopsychiatry*, vol. 24, pp. 73–88, 1990, doi: 10.1159/000418013.
- [17] N. C. Andreasen, P. Nopoulos, V. Magnotta, R. Pierson, S. Ziebell, and B.-C. Ho, “Progressive brain change in schizophrenia: a prospective longitudinal study of first-episode schizophrenia,” *Biol. Psychiatry*, vol. 70, no. 7, pp. 672–679, Oct. 2011, doi: 10.1016/j.biopsych.2011.05.017.
- [18] T. Nickl-Jockschat, F. Schneider, A. D. Pagel, A. R. Laird, P. T. Fox, and S. B. Eickhoff, “Progressive pathology is functionally linked to the domains of language and emotion: meta-analysis of brain structure changes in schizophrenia patients,” *Eur. Arch. Psychiatry Clin. Neurosci.*, vol. 261, no. Suppl 2, pp. S166–S171, Nov. 2011, doi: 10.1007/s00406-011-0249-8.
- [19] B.-C. Ho *et al.*, “Untreated initial psychosis: relation to cognitive deficits and brain morphology in first-episode schizophrenia,” *Am. J. Psychiatry*, vol. 160, no. 1, pp. 142–148, Jan. 2003, doi: 10.1176/appi.ajp.160.1.142.
- [20] S. A. Mitelman, L. Shihabuddin, A. M. Brickman, E. A. Hazlett, and M. S. Buchsbaum, “MRI assessment of gray and white matter distribution in Brodmann’s areas of the cortex in patients with schizophrenia with good and poor outcomes,” *Am. J. Psychiatry*, vol. 160, no. 12, pp. 2154–2168, Dec. 2003, doi: 10.1176/appi.ajp.160.12.2154.
- [21] J. Chen *et al.*, “Neurobiological Divergence of the Positive and Negative Schizophrenia Subtypes Identified on a New Factor Structure of Psychopathology Using Non-negative Factorization: An International Machine Learning Study,” *Biol. Psychiatry*, vol. 87, no. 3, pp. 282–293, Feb. 2020, doi: 10.1016/j.biopsych.2019.08.031.
- [22] L. Palaniyappan, J. Mahmood, V. Balain, O. Mouglin, P. A. Gowland, and P. F. Liddle, “Structural correlates of formal thought disorder in schizophrenia: An ultra-high field multivariate morphometry study,” *Schizophr. Res.*, vol. 168, no. 1–2, pp. 305–312, Oct. 2015, doi: 10.1016/j.schres.2015.07.022.
- [23] M. Mackinley, J. Chan, H. Ke, K. Dempster, and L. Palaniyappan, “Linguistic determinants of formal thought disorder in first episode psychosis,” *Early Interv. Psychiatry*, vol. 15, no. 2, pp. 344–351, Apr. 2021, doi: 10.1111/eip.12948.
- [24] S. Jung, A. Lee, M. Bang, and S.-H. Lee, “Gray matter abnormalities in language processing areas and their associations with verbal ability and positive symptoms in first-episode patients with schizophrenia spectrum psychosis,” *NeuroImage Clin.*, vol. 24, p. 102022, 2019, doi: 10.1016/j.nicl.2019.102022.
- [25] H. Stein, J. Barbosa, and A. Compte, “Towards biologically constrained attractor models of schizophrenia,” *Curr. Opin. Neurobiol.*, vol. 70, pp. 171–181, Oct. 2021, doi: 10.1016/j.conb.2021.10.013.
- [26] F. Stein *et al.*, “Factor analyses of multidimensional symptoms in a large group of patients with major depressive disorder, bipolar disorder, schizoaffective disorder and schizophrenia,” *Schizophr. Res.*, vol. 218, pp. 38–47, Apr. 2020, doi: 10.1016/j.schres.2020.03.011.
- [27] N. C. Andreasen and T. Nickl-Jockschat, “Predicting Outcome in Schizophrenia: Neuroimaging and Clinical Assessments,” in *Neuroimaging in Schizophrenia*, M. Kubicki

- and M. E. Shenton, Eds., Cham: Springer International Publishing, 2020, pp. 343–353. doi: 10.1007/978-3-030-35206-6\_17.
- [28] T. Nickl-Jockschat, B.-C. Ho, and N. Andreasen, “Clinical and neurobiologic predictors of long-term outcome in schizophrenia,” *Psychiatry and Clinical Psychology*, preprint, Aug. 2022. doi: 10.1101/2022.08.05.22278122.
- [29] A. G. Dietz, S. A. Goldman, and M. Nedergaard, “Glial cells in schizophrenia: a unified hypothesis,” *Lancet Psychiatry*, vol. 7, no. 3, pp. 272–281, Mar. 2020, doi: 10.1016/S2215-0366(19)30302-5.
- [30] A. P. Mallya and A. Y. Deutch, “(Micro)Glia as Effectors of Cortical Volume Loss in Schizophrenia,” *Schizophr. Bull.*, vol. 44, no. 5, pp. 948–957, Aug. 2018, doi: 10.1093/schbul/sby088.
- [31] T. Notter, “Astrocytes in schizophrenia,” *Brain Neurosci. Adv.*, vol. 5, p. 23982128211009148, 2021, doi: 10.1177/23982128211009148.
- [32] J. R. Glausier and D. A. Lewis, “Dendritic spine pathology in schizophrenia,” *Neuroscience*, vol. 251, pp. 90–107, Oct. 2013, doi: 10.1016/j.neuroscience.2012.04.044.
- [33] J. Shin *et al.*, “Cell-Specific Gene-Expression Profiles and Cortical Thickness in the Human Brain,” *Cereb. Cortex N. Y. N 1991*, vol. 28, no. 9, pp. 3267–3277, Sep. 2018, doi: 10.1093/cercor/bhx197.
- [34] Writing Committee for the Attention-Deficit/Hyperactivity Disorder *et al.*, “Virtual Histology of Cortical Thickness and Shared Neurobiology in 6 Psychiatric Disorders,” *JAMA Psychiatry*, vol. 78, no. 1, pp. 47–63, Jan. 2021, doi: 10.1001/jamapsychiatry.2020.2694.
- [35] J. Chen *et al.*, “Neurobiological substrates of the positive formal thought disorder in schizophrenia revealed by seed connectome-based predictive modeling,” *NeuroImage Clin.*, vol. 30, p. 102666, Apr. 2021, doi: 10.1016/j.nicl.2021.102666.
- [36] A. Nagels *et al.*, “Distinct Neuropsychological Correlates in Positive and Negative Formal Thought Disorder Syndromes: The Thought and Language Disorder Scale in Endogenous Psychoses,” *Neuropsychobiology*, vol. 73, no. 3, pp. 139–147, 2016, doi: 10.1159/000441657.
- [37] R. S. Desikan *et al.*, “An automated labeling system for subdividing the human cerebral cortex on MRI scans into gyral based regions of interest,” *NeuroImage*, vol. 31, no. 3, pp. 968–980, Jul. 2006, doi: 10.1016/j.neuroimage.2006.01.021.
- [38] A. Barrera, P. J. McKenna, and G. E. Berrios, “Formal thought disorder in schizophrenia: an executive or a semantic deficit?,” *Psychol. Med.*, vol. 35, no. 1, pp. 121–132, Jan. 2005, doi: 10.1017/s003329170400279x.
- [39] L. Palaniyappan, P. Homan, and M. F. Alonso-Sanchez, “Language Network Dysfunction and Formal Thought Disorder in Schizophrenia,” *Schizophr. Bull.*, vol. 49, no. 2, pp. 486–497, Mar. 2023, doi: 10.1093/schbul/sbac159.
- [40] L. Mørch-Johnsen *et al.*, “Auditory Cortex Characteristics in Schizophrenia: Associations With Auditory Hallucinations,” *Schizophr. Bull.*, vol. 43, no. 1, pp. 75–83, Jan. 2017, doi: 10.1093/schbul/sbw130.
- [41] M. J. Hawrylycz *et al.*, “An anatomically comprehensive atlas of the adult human brain transcriptome,” *Nature*, vol. 489, no. 7416, Art. no. 7416, Sep. 2012, doi: 10.1038/nature11405.

- [42] C. M. Sellgren *et al.*, “Increased synapse elimination by microglia in schizophrenia patient-derived models of synaptic pruning,” *Nat. Neurosci.*, vol. 22, no. 3, pp. 374–385, Mar. 2019, doi: 10.1038/s41593-018-0334-7.
- [43] T. Wensing, E. C. Cieslik, V. I. Müller, F. Hoffstaedter, S. B. Eickhoff, and T. Nickl-Jockschat, “Neural correlates of formal thought disorder: An activation likelihood estimation meta-analysis,” *Hum. Brain Mapp.*, vol. 38, no. 10, pp. 4946–4965, Oct. 2017, doi: 10.1002/hbm.23706.
- [44] T. E. Goldberg, M. S. Aloia, M. L. Gourovitch, D. Missar, D. Pickar, and D. R. Weinberger, “Cognitive substrates of thought disorder, I: the semantic system,” *Am. J. Psychiatry*, vol. 155, no. 12, pp. 1671–1676, Dec. 1998, doi: 10.1176/ajp.155.12.1671.
- [45] J. D. Stefaniak, R. S. W. Alyahya, and M. A. Lambon Ralph, “Language networks in aphasia and health: A 1000 participant activation likelihood estimation meta-analysis,” *NeuroImage*, vol. 233, p. 117960, Jun. 2021, doi: 10.1016/j.neuroimage.2021.117960.
- [46] A. de la Vega, L. J. Chang, M. T. Banich, T. D. Wager, and T. Yarkoni, “Large-Scale Meta-Analysis of Human Medial Frontal Cortex Reveals Tripartite Functional Organization,” *J. Neurosci. Off. J. Soc. Neurosci.*, vol. 36, no. 24, pp. 6553–6562, Jun. 2016, doi: 10.1523/JNEUROSCI.4402-15.2016.
- [47] A. Bechara, D. Tranel, and H. Damasio, “Characterization of the decision-making deficit of patients with ventromedial prefrontal cortex lesions,” *Brain J. Neurol.*, vol. 123 ( Pt 11), pp. 2189–2202, Nov. 2000, doi: 10.1093/brain/123.11.2189.
- [48] L. A. Bradfield and G. Hart, “Rodent medial and lateral orbitofrontal cortices represent unique components of cognitive maps of task space,” *Neurosci. Biobehav. Rev.*, vol. 108, pp. 287–294, Jan. 2020, doi: 10.1016/j.neubiorev.2019.11.009.
- [49] B. Aben, C. Buc Calderon, E. Van den Bussche, and T. Verguts, “Cognitive Effort Modulates Connectivity between Dorsal Anterior Cingulate Cortex and Task-Relevant Cortical Areas,” *J. Neurosci. Off. J. Soc. Neurosci.*, vol. 40, no. 19, pp. 3838–3848, May 2020, doi: 10.1523/JNEUROSCI.2948-19.2020.
- [50] D. M. Yee, J. L. Crawford, B. Lamichhane, and T. S. Braver, “Dorsal Anterior Cingulate Cortex Encodes the Integrated Incentive Motivational Value of Cognitive Task Performance,” *J. Neurosci. Off. J. Soc. Neurosci.*, vol. 41, no. 16, pp. 3707–3720, Apr. 2021, doi: 10.1523/JNEUROSCI.2550-20.2021.
- [51] B. Roozendaal, B. S. McEwen, and S. Chattarji, “Stress, memory and the amygdala,” *Nat. Rev. Neurosci.*, vol. 10, no. 6, pp. 423–433, Jun. 2009, doi: 10.1038/nrn2651.
- [52] R. J. Murray, T. Brosch, and D. Sander, “The functional profile of the human amygdala in affective processing: insights from intracranial recordings,” *Cortex J. Devoted Study Nerv. Syst. Behav.*, vol. 60, pp. 10–33, Nov. 2014, doi: 10.1016/j.cortex.2014.06.010.
- [53] B. Dietsche, T. Kircher, and I. Falkenberg, “Structural brain changes in schizophrenia at different stages of the illness: A selective review of longitudinal magnetic resonance imaging studies,” *Aust. N. Z. J. Psychiatry*, vol. 51, no. 5, pp. 500–508, May 2017, doi: 10.1177/0004867417699473.
- [54] N. Dijkstra, S. E. Bosch, and M. A. J. van Gerven, “Vividness of Visual Imagery Depends on the Neural Overlap with Perception in Visual Areas,” *J. Neurosci. Off. J. Soc. Neurosci.*, vol. 37, no. 5, pp. 1367–1373, Feb. 2017, doi: 10.1523/JNEUROSCI.3022-16.2016.
- [55] J. Bergmann, E. Genç, A. Kohler, W. Singer, and J. Pearson, “Smaller Primary Visual Cortex Is Associated with Stronger, but Less Precise Mental Imagery,” *Cereb. Cortex N. Y. N 1991*, vol. 26, no. 9, pp. 3838–3850, Sep. 2016, doi: 10.1093/cercor/bhv186.



- [56] G. Ganis, W. L. Thompson, and S. M. Kosslyn, “Brain areas underlying visual mental imagery and visual perception: an fMRI study,” *Brain Res. Cogn. Brain Res.*, vol. 20, no. 2, pp. 226–241, Jul. 2004, doi: 10.1016/j.cogbrainres.2004.02.012.
- [57] T. Onitsuka *et al.*, “Occipital Lobe Gray Matter Volume in Male Patients with Chronic Schizophrenia: A Quantitative MRI Study,” *Schizophr. Res.*, vol. 92, no. 1–3, pp. 197–206, May 2007, doi: 10.1016/j.schres.2007.01.027.
- [58] H. Tohid, M. Faizan, and U. Faizan, “Alterations of the occipital lobe in schizophrenia,” *Neurosciences*, vol. 20, no. 3, pp. 213–224, Jul. 2015, doi: 10.17712/nsj.2015.3.20140757.
- [59] D. N. Barry and B. C. Love, “A neural network account of memory replay and knowledge consolidation,” *Cereb. Cortex N. Y. N 1991*, vol. 33, no. 1, pp. 83–95, Dec. 2022, doi: 10.1093/cercor/bhac054.
- [60] D. Tordesillas-Gutierrez *et al.*, “The right occipital lobe and poor insight in first-episode psychosis,” *PLoS ONE*, vol. 13, no. 6, p. e0197715, Jun. 2018, doi: 10.1371/journal.pone.0197715.
- [61] H. G. Yi, M. K. Leonard, and E. F. Chang, “The Encoding of Speech Sounds in the Superior Temporal Gyrus,” *Neuron*, vol. 102, no. 6, pp. 1096–1110, Jun. 2019, doi: 10.1016/j.neuron.2019.04.023.
- [62] T. Yan, K. Zhuang, L. He, C. Liu, R. Zeng, and J. Qiu, “Left temporal pole contributes to creative thinking via an individual semantic network,” *Psychophysiology*, vol. 58, no. 8, p. e13841, Aug. 2021, doi: 10.1111/psyp.13841.
- [63] N. C. Andreasen and S. Olsen, “Negative v positive schizophrenia. Definition and validation,” *Arch. Gen. Psychiatry*, vol. 39, no. 7, pp. 789–794, Jul. 1982, doi: 10.1001/archpsyc.1982.04290070025006.
- [64] C. E. Moyer, M. A. Shelton, and R. A. Sweet, “Dendritic Spine Alterations in Schizophrenia,” *Neurosci. Lett.*, vol. 601, pp. 46–53, Aug. 2015, doi: 10.1016/j.neulet.2014.11.042.
- [65] M. Yilmaz *et al.*, “Overexpression of schizophrenia susceptibility factor human complement C4A promotes excessive synaptic loss and behavioral changes in mice,” *Nat. Neurosci.*, vol. 24, no. 2, pp. 214–224, Feb. 2021, doi: 10.1038/s41593-020-00763-8.
- [66] A. Sekar *et al.*, “Schizophrenia risk from complex variation of complement component 4,” *Nature*, vol. 530, no. 7589, pp. 177–183, Feb. 2016, doi: 10.1038/nature16549.
- [67] W.-S. Chung, N. J. Allen, and C. Eroglu, “Astrocytes Control Synapse Formation, Function, and Elimination,” *Cold Spring Harb. Perspect. Biol.*, vol. 7, no. 9, p. a020370, Feb. 2015, doi: 10.1101/cshperspect.a020370.
- [68] W. M. Abi-Saab, D. C. D’Souza, B. Moghaddam, and J. H. Krystal, “The NMDA antagonist model for schizophrenia: promise and pitfalls,” *Pharmacopsychiatry*, vol. 31 Suppl 2, pp. 104–109, Jul. 1998, doi: 10.1055/s-2007-979354.
- [69] L. E. Adler *et al.*, “Schizophrenia, sensory gating, and nicotinic receptors,” *Schizophr. Bull.*, vol. 24, no. 2, pp. 189–202, 1998, doi: 10.1093/oxfordjournals.schbul.a033320.
- [70] J. T. Kantrowitz and D. C. Javitt, “N-methyl-d-aspartate (NMDA) receptor dysfunction or dysregulation: the final common pathway on the road to schizophrenia?,” *Brain Res. Bull.*, vol. 83, no. 3–4, pp. 108–121, Sep. 2010, doi: 10.1016/j.brainresbull.2010.04.006.
- [71] D. P. Schafer *et al.*, “Microglia sculpt postnatal neural circuits in an activity and complement-dependent manner,” *Neuron*, vol. 74, no. 4, pp. 691–705, May 2012, doi: 10.1016/j.neuron.2012.03.026.

- [72] T. Y. Wong *et al.*, “An overlapping pattern of cerebral cortical thinning is associated with both positive symptoms and aggression in schizophrenia via the ENIGMA consortium,” *Psychol. Med.*, vol. 50, no. 12, pp. 2034–2045, Sep. 2020, doi: 10.1017/S0033291719002149.
- [73] E. Walton *et al.*, “Prefrontal cortical thinning links to negative symptoms in schizophrenia via the ENIGMA consortium,” *Psychol. Med.*, vol. 48, no. 1, pp. 82–94, Jan. 2018, doi: 10.1017/S0033291717001283.

## Table legends

**Table 1.** T statistics of regions significantly associated with total FTD ( $p = 0.001$ , FDR corrected).

**Table 2.** T statistics of regions significantly associated with positive FTD ( $p = 0.001$ , FDR corrected).

**Table 3.** T statistics of regions significantly associated with negative FTD ( $p = 0.001$ , FDR corrected).

**Table 4.** FDR Corrected P-Values for associations between FTD related cortical thickness changes and distributions of cellular transcriptomic signatures.

**Table 5.** Results of the leave-one-out (LOO) analyses for positive FTD. All regions are displayed that were significant for at least one LOO analysis ( $p = 0.001$ , FDR corrected). Numbers provided indicate the number of times that these regions were retrieved as significant during the individual LOO runs. Positive numbers indicate positive correlations with FTD, negative numbers indicate negative correlations. Regions that were retrieved by the main analysis are displayed in bold.

**Table 6.** Results of the leave-one-out (LOO) analyses for negative FTD. All regions are displayed that were significant for at least one LOO analysis ( $p = 0.001$ , FDR corrected). Numbers provided indicate the number of times that these regions were retrieved as significant during the individual LOO runs. Positive numbers indicate positive correlations with FTD, negative numbers indicate negative correlations. Regions that were retrieved by the main analysis are displayed in bold.

**Supplementary Table 1.** Demographics of contributions from each ENIGMA site.

**Supplementary Table 2.** Differences between regions of significantly reduced surface area, cortical thickness or subcortical volume in individuals with schizophrenia compared to controls (FDR corrected  $p = 0.001$ ).

**Supplementary Table 3.** T Statistics of regions significantly associated with PANSS N5 (FDR corrected  $p = 0.001$ ).

## Figure legends

**Figure 1.** Regions where cortical surface area or thickness were significantly associated with total, positive and negative FTD (FDR corrected  $p = 0.001$ ). Left hemisphere is shown on the left of each group of images. Blue indicates regions of reduced surface area, cortical thickness or subcortical volumes, red indicates regions of relatively spared surface area, cortical thickness or subcortical volumes. A) surface area changes associated with total FTD; B) surface area changes associated with positive FTD; C) surface area changes associated with negative FTD; D) cortical thickness changes associated with total FTD; E) cortical thickness changes associated with positive FTD; F) cortical thickness changes associated with negative FTD; G) volume changes of subcortical structures associated with total FTD; H) volume changes of subcortical structures associated with positive FTD; I) volume changes of subcortical structures associated with negative FTD.

**Figure 2.** “Leave one out” analysis of FTD correlation. The regions associated with total, positive, or negative FTD (FDR corrected  $p = 0.001$ ) of each of the 10 “leave one out” analyses were added together so that all positively affected regions are shown in red, and all negatively affected regions in blue. The intensity of the color represents the number of “leave one out” analyses where that region was affected. Leave one out analyses were conducted for the following parameters: A) surface area changes associated with total FTD; B) surface area changes associated with positive FTD; C) surface area changes associated with negative FTD; D) cortical thickness changes associated with total FTD; E) cortical thickness changes associated with positive FTD; F) cortical thickness changes associated with negative FTD; G) volume changes of subcortical structures associated with total FTD; H) volume changes of subcortical structures associated with positive FTD; I) volume changes of subcortical structures associated with negative FTD.

Table 1. T statistics of regions significantly associated with total FTD (FDR corrected  $p = 0.001$ ).

Surface Area		Cortical Thickness		Volume			
		Right Lateral Occipital	4.68	Left Pallidum	-6.21	Right Pallidum	-5.35
Left Pericalcarine	4.70	Right Pericalcarine	4.50	Left Amygdala	-4.70		
Left Post Central	4.50						
		Right Rostral Middle Frontal	4.76				
		Right Caudal Anterior Cingulate	4.73				

Table 2. T statistics of regions significantly associated with positive FTD (FDR corrected  $p = 0.001$ ).

Surface Area		Cortical Thickness		Volume	
				Right Lateral Occipital	4.15
				Right Cuneus	4.58
Left Lingual	-4.13	Right Lingual	-5.25	Left Lingual	4.90
Left Pericalcarine	-4.69	Right Pericalcarine	-5.40	Left Pericalcarine	7.17
		Right Medial Orbitofrontal	-4.55	Right Pericalcarine	7.14
		Right Inferior Temporal	-4.48	Right Medial Orbitofrontal	-4.38
		Right Middle Temporal	-4.15	Left Lateral Orbitofrontal	-5.46
				Left Rostral Anterior Cingulate	-7.48
Left Temporal Pole	4.34			Right Rostral Anterior Cingulate	-6.56
		Right Parahippocampal	-4.30		
Left Insula	-4.14	Right Insula	-5.62	Left Caudal Anterior Cingulate	-4.35
				Left Posterior Cingulate	-4.73
				Left Isthmus Cingulate	-5.41
				Left Temporal Pole	-5.66
				Right Temporal Pole	-6.15
				Left Banks of Superior Temporal Sulcus	-6.78
				Right Banks of Superior Temporal Sulcus	-5.95
				Left Superior	-5.15
				Right Superior	-5.86

Temporal Left Middle Temporal	-4.62	Temporal Right Middle Temporal	-7.77
		Right Inferior Temporal	-5.78
Left Fusiform	-6.40	Right Fusiform	-5.62
Left Entorhinal	-5.95	Right Entorhinal	-5.59
Left Parahippocampal	-4.29	Right Parahippocampal	-4.20
Left Insula	-5.93	Right Insula	-4.76

---

Table 3. T statistics of regions significantly associated with negative FTD (FDR corrected  $p = 0.001$ ).

Surface Area		Cortical Thickness			Volume		
Right Lateral Occipital	-4.95	Right Rostral Middle Frontal	4.88	Left Pallidum	-6.20	Right Pallidum	-5.84
		Right Caudal Anterior Cingulate	5.18	Left Amygdala	-4.69		



Table 4. FDR Corrected P-Values for associations between FTD related cortical thickness changes and distributions of cellular transcriptomic signatures.

		Astrocyte	Dendritic Maintenance (CA1 Pyramidal)	Microglia
Total Formal Thought Disorder	Left	0.0013	0.00090	0.048
	Right	0.00045	0.00045	0.0060
Positive Formal Thought Disorder	Left	0.00090	0.00090	0.037
	Right	0.0067	0.00090	0.0069
Negative Formal Thought Disorder	Left	0.0081	0.00090	
	Right	0.011	0.0018	0.013

Table 5. T statistics of regions significantly associated with positive FTD after “leave one out” analysis

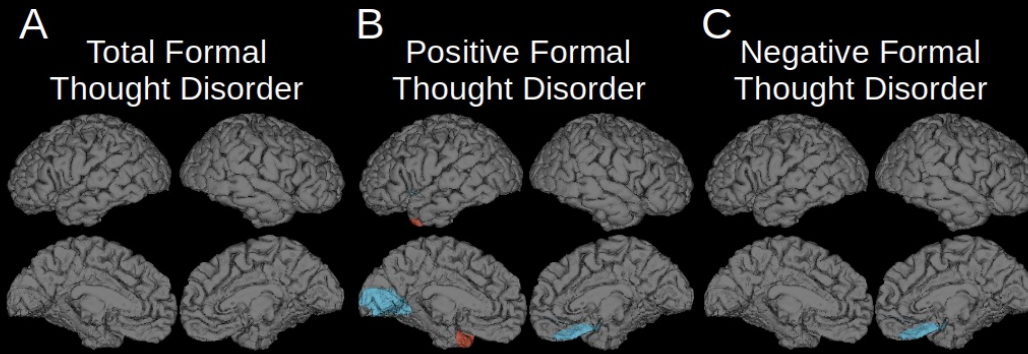
Surface Area		Cortical Thickness		Volume	
				<b>Right Lateral Occipital</b>	6
Left Cuneus	-3	Right Cuneus	-2	<b>Right Cuneus</b>	6
<b>Left Lingual</b>	-6	<b>Right Lingual</b>	-8	<b>Left Lingual</b>	7
<b>Left Pericalcarine</b>	-7	<b>Right Pericalcarine</b>	-8	<b>Left Pericalcarine</b>	9
		<b>Right Medial Orbitofrontal</b>	-8	Right Medial Orbitofrontal	-3
		<b>Right Inferior Temporal</b>	-7	<b>Left Lateral Orbitofrontal</b>	-8
Left Middle Temporal	-3	<b>Right Middle Temporal</b>	-8	<b>Left Rostral Anterior Cingulate</b>	-9
<b>Left Temporal Pole</b>	6			<b>Right Rostral Anterior Cingulate</b>	-8
		<b>Right Parahippocampal</b>	-6	<b>Left Caudal Anterior Cingulate</b>	-7
<b>Left Insula</b>	-8	<b>Right Insula</b>	-8	<b>Left Posterior Cingulate</b>	-9
				<b>Left Isthmus Cingulate</b>	-9
				<b>Left Temporal Pole</b>	-9
		Right Banks of Superior Temporal	-2	<b>Left Banks of Superior</b>	-9
				<b>Right Temporal Pole</b>	-9
				<b>Right Banks of Superior</b>	-9

			<b>Temporal Sulcus</b>		<b>Temporal Sulcus</b>	
			<b>Left Superior Temporal</b>	-8	<b>Right Superior Temporal</b>	-9
			<b>Left Middle Temporal</b>	-8	<b>Right Middle Temporal</b>	-9
					<b>Right Inferior Temporal</b>	-9
	Right Fusiform	-2	<b>Left Fusiform</b>	-8	<b>Right Fusiform</b>	-8
			<b>Left Entorhinal</b>	-8	<b>Right Entorhinal</b>	-8
			<b>Left Parahippocampal</b>	-7	<b>Right Parahippocampal</b>	-7
			<b>Left Insula</b>	-9	<b>Right Insula</b>	-8
	Right Pars Orbitalis	-2				
					Right Superior Parietal	2

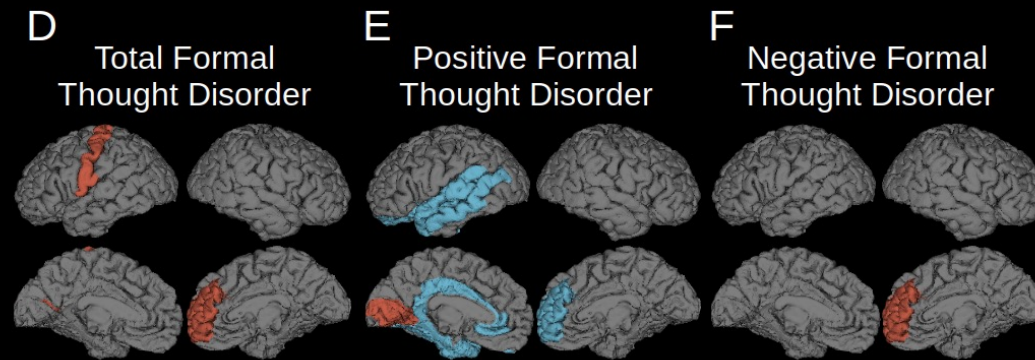
Table 6. T statistics of regions significantly associated with negative FTD after “leave one out” analysis

Surface Area		Cortical Thickness				Volume			
	<b>Right Lateral Occipital</b>	-8				<b>Left Pallidum</b>	-9	<b>Right Pallidum</b>	-8
					<b>Right Rostral Middle Frontal</b>		<b>Left Amygdala</b>	-8	
					<b>Right Caudal Anterior Cingulate</b>	7			
Left Lateral Orbitofrontal	-2								
	Right Cuneus	-2							
	Right Medial Orbitofrontal	-2	Left Medial Orbitofrontal	2	Right Medial Orbitofrontal	2			
			Left Frontal Pole	2	Right Frontal Pole	2			
	Right Insula	-2							

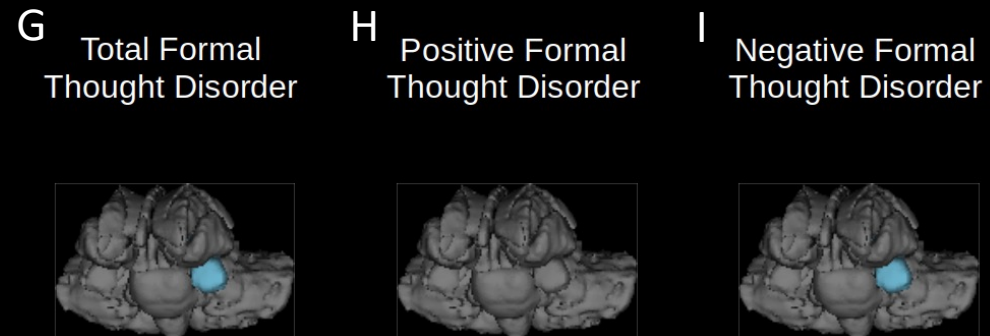
Surface Area



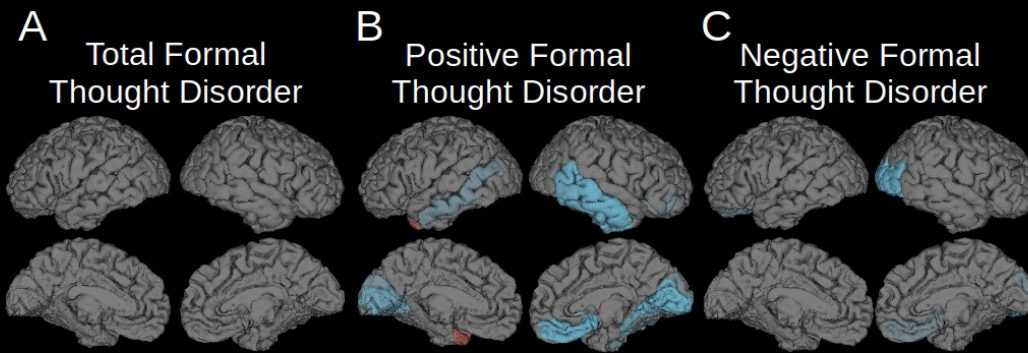
Cortical Thickness



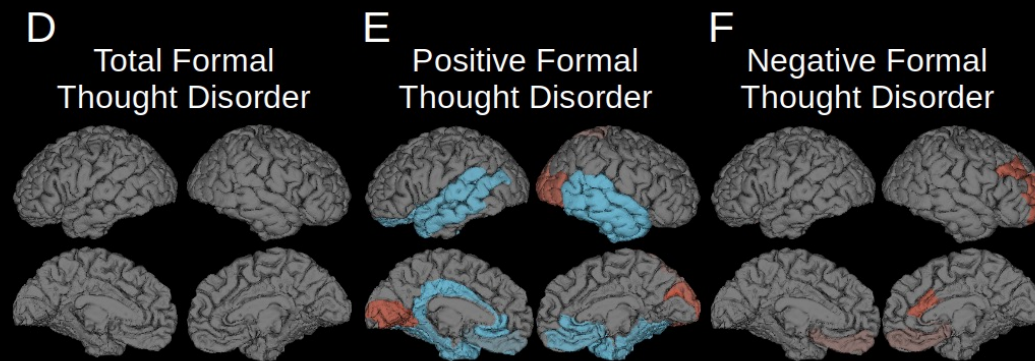
Subcortical volume



Surface Area



Cortical Thickness



Subcortical volume

