

## **Inflammatory Type Focal Cerebral Arteriopathy of the Posterior Circulation in Children: a comparative cohort study**

### **Author(s):**

Nedelina Slavova<sup>1,2,3\*</sup>, MD

Robin Mürger<sup>4\*</sup>

Iciar Sanchez-Albisua<sup>4</sup>, MD

Maria Regényi<sup>4</sup>, MD

Gabriela Oesch<sup>4</sup>, MD

Joël Fluss<sup>5</sup>, MD

Annette Hackenberg<sup>6</sup>, MD

Sébastien Lebon<sup>7</sup>, MD

Oliver Maier<sup>8</sup>, MD

Alexandre Datta<sup>9</sup>, MD

Sandra Bigi<sup>10,11</sup>, MD

Sebastian Grunt<sup>4</sup>, MD, PhD

Maja Steinlin<sup>4</sup>, MD

1. Support Center for Advanced Neuroimaging (SCAN), Institute of Diagnostic and Interventional Neuroradiology, University Hospital, Inselspital, Bern, Switzerland.

2. Pediatric Radiology, University of Basel Children's Hospital (UKBB) and University of Basel, Switzerland

3. Department of Neurology, University Hospital Bern, University of Bern, Bern, Switzerland.
4. Division of Neuropaediatrics, Development and Rehabilitation, Department of Paediatrics, Inselspital, Bern University Hospital, University of Bern, Switzerland
5. Department of Pediatrics, Gynecology and Obstetrics, Pediatric Neurology Unit, University Hospitals of Geneva, Geneva, Switzerland.
6. Department of Pediatric Neurology, University Children's Hospital, Zürich, Switzerland.
7. Pediatric Neurology and Neurorehabilitation Unit, Lausanne University Hospital, Lausanne, Switzerland.
8. Department of Pediatrics, Division of Child Neurology, Children's Hospital, St Gallen, Switzerland
9. Department of Pediatric Neurology and Developmental Medicine, University of Basel Children's Hospital, Basel.
10. Division of Pediatric Neurology, Department of Pediatrics, Children's Hospital Lucerne, Lucerne, Switzerland
11. Institute of Social and Preventive Medicine, University of Bern, Bern, Switzerland.

**Equal Author Contributions:**

Nedelina Slavova and Robin Münger contributed equally to this work.

**Corresponding Author:**

Robin Münger

Division of Neuropediatrics, Development and Rehabilitation, Department of Pediatrics,  
Inselspital, Bern University Hospital, University of Bern

E-mail: [robin.muenger@insel.ch](mailto:robin.muenger@insel.ch)

Short Title: Posterior Focal Cerebral Arteriopathy

Total word count: 5998

1 **Abstract**

2 **Background**

3 Inflammatory type Focal Cerebral Arteriopathy (FCA-i) in the anterior circulation (AC) is  
4 well characterized and the FCA severity score (FCASS) reflects the severity of disease. We  
5 identified cases of FCA-i in the posterior circulation (PC) and adapted the FCASS to describe  
6 these cases.

7 **Methods**

8 Patients from the Swiss NeuroPaediatric Stroke Registry (SNPSR) with ischemic stroke in  
9 the PC and AC due to FCA-i and available neuroimaging were gathered. Comparison of data  
10 regarding Pediatric National Institutes of Health Stroke Scale (pedNIHSS) score and  
11 Pediatric Stroke Outcome Measure (PSOM) and FCASS was performed. We estimated  
12 infarct size by the modified pediatric Alberta Stroke Program Early Computed Tomography  
13 Score (pedASPECTS) in children with AC stroke and the adapted Bernese posterior  
14 diffusion-weighted imaging (DWI) score in the PC.

15 **Results**

16 Thirty-six children with a median age of 6.3 years ([IQR 2.8,8.6; range 0.9,15.6], 21 males,  
17 58.3%) with FCA-i were identified. The total incidence rate was 0.151/100 000/year (95%CI  
18 0.109–0.209). Seven had PC FCA-i and 5 had FCA-i in both circulations. Time to final  
19 FCASS was longer in the PC compared to AC, evolution of FCASS did not differ. Initial  
20 pedNIHSS was highest in children with FCA-i in the PC with a median of 8.0 (IQR 5.0-18.0),  
21 compared to 4.5 (IQR 2.0-8.0) in those with AC FCA-i and 6.0 (IQR 6.0-6.0) with  
22 involvement of both AC and PC. Different to the anterior cases PC infarct volume did not  
23 correlate with higher discharge, maximum or final FCASS scores (R 0.25, 0.35, 0.54).

## 24 **Conclusion**

25 The PC is affected in up to one third of cases of FCA-i. These cases should be included in  
26 future investigations on FCA-i. Although it did not correlate with clinical outcome in our  
27 cohort, the modified FCASS may well serve as a marker for the evolution of the arteriopathy  
28 in posterior FCA-i.

## 29 **Non-standard Abbreviations and Acronyms**

AC	Anterior circulation
AICA	Anterior inferior cerebellar artery
AIS	Arterial ischemic Stroke
BA	Basilar artery
CI	Confidence intervall
CTA	Computed Tomography angiography
DNA	Desoxyribonucleic Acid
DWI	Diffusion-weighted imaging
FCA	Focal Cerebral Arteriopathy
FCA-d	Focal Cerebral Arteriopathy with intracranial arterial dissection
FCA-i	Inflammatory Focal Cerebral Arteriopathy
FCA-u	Focal Cerebral Arteriopathy undefined etiology
FCASS	Focal Cerebral Arteriopathy severity score
IQR	Interquartile range
MRA	Magnetic resonance angiography
PC	Posterior circulation
PCA	Posterior Cerebral artery
pedASPECTS	modified Pediatric Alberta Stroke Program Early Computed Tomography score
pedNIHSS	Paediatric National Institutes of Health Stroke Scale
PICA	Posterior inferior cerebellar artery
PSOM	Pediatric Stroke Outcome Measure
PVA	Post-varicella Arteriopathy
SCA	Superior cerebellar artery
SNPSR	Swiss NeuroPaediatric Stroke Registry
TCA	Transient Cerebral Arteriopathy
VA	Vertebral artery
VIPS	Vascular Effects of Infection in Pediatric Stroke
VWI	Vessel wall imaging
VZV	Varicella Zoster Virus

30

31 **Background**

32 Focal cerebral arteriopathy of the inflammatory type (FCA-i) is an important risk factor for  
33 arterial ischemic stroke (AIS) in previously healthy children.<sup>1</sup> After the first description as  
34 transient cerebral arteriopathy in 1998<sup>2</sup>, FCA-I was defined in 2004<sup>2</sup> by a typical vascular  
35 imaging within 3 months after stroke showing unilateral focal or segmental stenosis or  
36 occlusion at a typical location, non-progressing on follow-up imaging 6 months post-stroke.<sup>3</sup>  
37 Typical locations include the distal part of the internal carotid artery and the initial segments  
38 of the anterior, middle and posterior cerebral arteries (A1, M1 and P1 segments). As a special  
39 variant, post-varicella arteriopathy (PVA) was defined as TCA with a history of acute  
40 varicella infection within the 12 months before AIS.<sup>4,5</sup> Since then, herpes simplex virus,  
41 enterovirus, Mycoplasma pneumoniae or Borrelia burgdorferi infections have been reported  
42 as risk factors for FCA-i and AIS.<sup>6-11</sup>

43 The term focal cerebral arteriopathy (FCA), which included unifocal or multifocal, unilateral  
44 or bilateral stenosis of variable etiologies (e.g. dissection or moyamoya disease and  
45 syndrome) was later defined, and TCA was seen as a subgroup of FCA<sup>12,13</sup>. In the large  
46 international Vascular Effects of Infection in Pediatric Stroke (VIPS) study, the definition of  
47 FCA was narrowed to unifocal and unilateral stenosis or irregularities of the AC. The VIPS  
48 study further subdivided FCA into three groups: intracranial arterial dissection (FCA-d),  
49 inflammation (FCA-i) or undefined etiology (FCA-u)<sup>1,14</sup>. FCA-i accounted for the majority of  
50 FCA in the VIPS study.<sup>1</sup> The evolution of FCA-i is characterized by a monophasic natural  
51 course, frequently showing early progression (over days to weeks), which reaches a plateau  
52 with non-progression by 6 months. The majority of individuals improve or remain stable, but  
53 complete resolution is seen in only a minority of cases.<sup>2,3</sup>

54 Based on the hypothesis of an inflammatory pathogenesis, corticosteroids are increasingly  
55 used to treat FCA-i.<sup>15</sup> However, there is still no clinical trial data to support this treatment.

56 The planning of forthcoming clinical trials in this field (Brechtbühl et. al., PASTA Trial,  
57 unpublished data, 2023) revealed the need for a quantitative measurement of FCA severity.  
58 This led to the development of the FCA Severity Score (FCASS) based on a sub cohort of  
59 children with FCA enrolled in the VIPS study.<sup>14,16</sup> Only children with FCA in AC were  
60 included precluding its utility for posterior circulation stroke.

61 A few case reports have described PVA affecting the PC.<sup>17-19</sup> A study on post-varicella AIS  
62 in Denmark included cases fulfilling clinical and radiologic criteria as well as a positive  
63 cerebrospinal fluid test for varicella-zoster virus (VZV) DNA in combination with intrathecal  
64 VZV IgG production. This includes one case of post-varicella AIS affecting the posterior  
65 circulation.<sup>20</sup> A population-based Swiss study revealed an incidence of PC AIS of 0.18/100  
66 000 children /year. In 25.6% of these cases, the etiology was identified as FCA (FCA-i, FCA-  
67 d and FCA-u).<sup>21</sup> There is currently no scoring system available to describe these cases in  
68 detail.

69 Children with FCA-i mostly present with hemiparesis or hemiplegia.<sup>20,22-24</sup> In general,  
70 children with AIS in the PC show less specific clinical symptoms and signs than those with  
71 AIS in the AC.<sup>21</sup>

72 The aim of our study was to identify all cases of FCA-i in the Swiss NeuroPaediatric Stroke  
73 Registry (SNPSR), to adapt the FCASS to encompass PC FCA-i and to compare clinical and  
74 radiological features of FCA-i between PC and AC.

## 75 **Methods**

### 76 **Patients**

77 We did a retrospective analysis of the prospective nationwide SNPSR which was initiated in  
78 January 2000.<sup>22</sup> It comprises clinical and radiological data on every reported case of  
79 childhood AIS across Switzerland. Hospital-based pediatric neurologists are regularly

80 reminded to report all pediatric stroke cases to the registry in Bern. The follow-up of these  
81 patients is organized centrally from Bern by questionnaires sent to the parents at 2 and 5  
82 years and the clinicians are asked to send in reports from clinical follow up visits according to  
83 their local schedule. Short term follow up is usually done by a pediatric neurologist.

84 The SNPSR has been approved by the competent Ethics Committees and the Swiss Federal  
85 Ministry of Health. All registered patients or their legal guardians have provided written  
86 informed consent. Details of the SNPSR can be found in previous publications.<sup>22,25</sup> Some  
87 patients from the cohort have also been included in previous studies based on the SNPSR.<sup>11,21</sup>  
88 Childhood AIS was defined as a sudden (focal) neurological deficit with radiological proof of  
89 an acute ischemic lesion in the corresponding vascular territory. FCA-i included monophasic  
90 FCA, as in PVA and TCA.<sup>26</sup>

#### 91 **Inclusion and Exclusion Criteria**

92 All data of children (aged 1 month-16 years) with AIS registered between January 2000 until  
93 December 2018 with available good-quality neuroimaging at diagnosis and follow-up, with  
94 documented abnormalities on vascular neuroimaging, were retrospectively reviewed. In  
95 addition, charts from children with history of varicella infection within the last 12 months  
96 before the stroke were also reviewed.

97 Inclusion criteria were:

98 1) childhood stroke due to FCA-i defined by neuroimaging: focal stenosis, irregularity or  
99 banding in any vascular territory which was

100 a) either accompanied by vessel wall contrast enhancement on vessel wall imaging (VWI) or

101 b) preceded by infection (varicella within 12 months, other infections within weeks before

102 stroke) and in the absence of trauma;



103 2) monophasic illness without progression on follow-up.

104 Exclusion criteria were arterial dissections, moyamoya arteriopathy, and underlying systemic  
105 disease like bacterial meningitis, neurofibromatosis, Kawasaki disease or systemic lupus  
106 erythematosus.

#### 107 **Data collection**

108 Demographic and clinical data, accompanying infectious risk factors and related laboratory  
109 investigations, as well as information on the patients' treatment were searched for in the  
110 SNPSR. In cases of missing data, the original charts were reviewed. Data on the Pediatric  
111 National Institutes of Health Stroke Scale (pedNIHSS) score was collected as reported by the  
112 treating physician or performed retrospectively. Neuroimaging was retrospectively analyzed  
113 by a trained pediatric neuroradiologist (NS). Pediatric stroke outcome measure (PSOM)<sup>27</sup> was  
114 collected from SNPSR or medical charts at discharge, after 6 months (range 3 to 9 months),  
115 and after 24 months (range 21 to 27 months). Outcome was dichotomized into good (total  
116 PSOM 0–0.5) or poor (total PSOM  $\geq$  1).

#### 117 **Radiological Scoring of Arteriopathy Severity**

118 FCASS was applied for assessment of the arteriopathy.<sup>14,16</sup> To measure severity of stenosis in  
119 the PC, the same principles were applied to the following segments: intracranial vertebral  
120 artery (VA), basilar artery (BA), P1 and P2 segments of the posterior cerebral artery (PCA),  
121 the superior cerebellar artery (SCA), the anterior inferior cerebellar artery (AICA) and the  
122 posterior inferior cerebellar artery (PICA), see STable 1.

123 FCASS was assessed on all MR angiography (MRA) and - if MRA was unavailable - on CT  
124 angiography (CTA). For further analysis, we included FCASS at baseline, maximum FCASS  
125 during follow-up (if more than one measurement available) and final FCASS (if follow-up  
126 imaging after > 6 months post stroke was available).

127 **Radiological Scoring of infarct Size**

128 Infarct size on admission for AC stroke was calculated using the modified paediatric  
129 ASPECTS score<sup>28-30</sup> (pedASPECTS), with a maximum of 30 points (15 for each side). Since  
130 pedASPECTS does not cover most locations in the PC, the modified Bernese diffusion-  
131 weighted imaging (DWI) score was used for stroke in PC,<sup>31</sup> adding up to a maximum of 22  
132 points (for details see STable 1).

133 **Statistical analyses**

134 First, all variables gathered were analyzed descriptively. The incidence rate of FCA-i in PC in  
135 Swiss children was calculated using data published by the Swiss Federal Statistical Office<sup>32</sup>.  
136 We compared the groups where the effects were strictly confined to the anterior or posterior  
137 circulation. Furthermore, we compared these cases to the group with mixed anterior and  
138 posterior involvement. If missing data could not be reconstructed retrospectively, patients  
139 were excluded from analysis. In-Between-group comparison was performed using  
140 nonparametric statistics (Wilcoxon rank sum and signed rank test). Binary outcomes were  
141 compared using Fisher's exact test. Correlations between subgroups were evaluated with  
142 Spearman's correlation coefficient. A 2-sided p-value < 0.05 was considered statistically  
143 significant. Analysis was performed using R statistical software, version 3.6.1.  
144 We used the STROBE cohort checklist when writing our report<sup>33</sup>.

145 **Data availability**

146 Anonymized raw data is available and can be shared upon reasonable request.

147

## Results

### 148 Study Population and Epidemiology

149 During the study period from January 2000 to December 2018, 301 children with AIS aged  
150 between 1 month and 16 years were registered in the SNPSR (111 female [36.9%]; median  
151 age 5.8 years, IQR 1.9–11.4).

152 126 cases found in the registry with either documented vascular abnormalities on  
153 neuroimaging or an acute VZV infection within 12 months prior to stroke were reviewed  
154 clinically. In the first review all cases with a clear diagnosis other than FCA were excluded.  
155 The remaining cases underwent a central adjudication of the images.

156 Ninety children had to be excluded: In 9 cases, intracranial dissection was found to be the  
157 cause of FCA (FCA-d) and 11 cases were classified as FCA of undetermined etiology (FCA-  
158 u). In 10 cases extracranial dissection of the aorta or the cervical arteries was present, 1 case  
159 showed complete occlusion of the internal carotid artery of unknown etiology, and in 10  
160 cases the arteriopathy was due to other types of pathology (e.g., systemic lupus  
161 erythematosus, Kawasaki syndrome, trisomy 21, neurofibromatosis type 1, moyamoya  
162 disease, and meningitis). Eight children had cardioembolic stroke and 9 children showed  
163 progressive central nervous system angiitis. In 32 cases no arteriopathy was found during  
164 expert radiological review.

165 FCA-i was found in 36 children. The total incidence rate of FCA-i in our Swiss cohort was  
166 0.151/ 100 000 children/ year (95%CI 0.109–0.209). AC was affected in 24 children, PC in 7  
167 with an incidence rate of 0.101 (95%CI 0.067-0.150), and 0.029 (95%CI 0.01-0.06)  
168 respectively. In 5 cases both circulations were affected with an incidence rate of 0.021  
169 (95%CI 0.008-0.050).

170 Table 1 displays the baseline characteristics of all patients. Significant differences were found  
171 in the initial presentation: Patients with AIS affecting the AC presented more often with  
172 facial palsy than those with PC stroke. Headache and tetra paresis were significantly more  
173 often reported among cases with posterior FCA-i. Intravenous lysis was performed  
174 significantly more often if PC was affected. No between-group differences were found in  
175 inclusion criteria, demographic characteristics, and associations with previous infection or  
176 outcome.

177 Children presenting with stroke affecting both circulations did not present with significant  
178 differences to the other two groups and this group was excluded from further comparisons.

179 Details on baseline characteristics, radiological findings, treatment, and outcome are  
180 summarized in STable 2.

#### 181 **FCASS**

182 Table 2 summarizes the FCASS obtained in our study for the anterior and the posterior group.

183 Baseline FCASS was obtained by MRA except in 3 cases of AC by conventional  
184 angiography and one case of PC by CTA (early years of the registry). All follow up FCASS  
185 were obtained by MRA.

186 As shown in Table 2, time to final FCASS differed significantly between the posterior and  
187 the anterior group with a median time of 300 weeks in the former (IQR 227–351, range 157–  
188 359) and 64 weeks (IQR 32 - 169, range 24 - 545) in the latter group ( $p = 0.043$ ). There was  
189 no difference in the scores or in the other time periods between the two groups.

190 Figure 1 shows the evolution of FCASS in the anterior and posterior circulation.

191 Improvement was evident after 6 months in all cases. The median improvement from baseline  
192 to final imaging in AC amounted to 4 points and 5.5 points in PC. Initial worsening seemed

193 to be more pronounced if PC was affected, but there was no significant difference between  
194 groups.

195 Neither for the anterior nor the posterior group a correlation between pedNIHSS score and  
196 FCASS or PSOM and FCASS could be shown. There was also no significant difference  
197 between the groups in this regard.

198 No correlation was evident between FCASS and infarct size. Due to the different scoring  
199 system applied, direct comparison of infarct volume between the anterior and the posterior  
200 cases was not possible.

## 201 **Discussion**

202 The purpose of this study was to characterize cases of inflammation-triggered FCA within the  
203 posterior circulation registered in the SNPSR and to compare them to cases of anterior FCA-  
204 i. Overall, PC was involved in one third of all FCA-i cases. In keeping with published data on  
205 PC- AIS in childhood<sup>17-21</sup> we observed that FCA-i also affects PC in a non-negligible number  
206 of patients. Better understanding of the clinical presentation of these cases and application of  
207 a scoring system to assess severity of the arteriopathy is needed.<sup>34</sup>

208 Comparison of cases restricted to PC and AC showed a similar distribution of age. Sex  
209 distribution mirrored the typical pattern with more males affected by childhood AIS in  
210 general.<sup>22</sup> Similar to PC stroke in general<sup>21,35,36</sup> children with posterior FCA-i presented often  
211 with more non-specific symptoms, mainly headache. This group also showed a higher  
212 pedNIHSS at presentation. This might be because stroke in the brainstem will present with  
213 marked neurological symptoms. Facial palsy was found more often in the anterior group,  
214 consistent with the present literature.<sup>21</sup>

215 The association of VZV infection with FCA-i in the AC was not stronger than in PC. It is  
216 hypothesized that upon reactivation of VZV ganglia,<sup>37</sup> the viral capsid might migrate through

217 axonal retrograde transport (sensory nerve fibers) to the vessel wall of proximal segments of  
218 the circle of Willis, replicate and induce a local inflammatory response after transmural  
219 spreading. Experimental studies in monkeys demonstrated that intracerebral arteries receive  
220 afferent fibers from trigeminal and superior cervical ganglia (harboring latent varicella  
221 infection), not only to the carotid T-junction but to a lesser extent also to the posterior, rostral  
222 BA, PCA and SCA<sup>38</sup> A study in rats demonstrated that the first and second spinal ganglion  
223 reach intracranial parts of the ipsilateral parts of the ipsilateral vertebral artery as well as the  
224 BA (as represented in Figure 2).<sup>39</sup> This explains well the distribution of FCA-i in our study.  
225 A major challenge is the distinction between FCA-d and FCA-i.<sup>21</sup> In the early years of the  
226 registry FCA-i was not defined or scored. With the goal not to miss any case which in  
227 retrospect would be classified as FCA-i, initial inclusion criteria were taken very broad. This  
228 explains why so many cases had to be excluded upon clinical and radiological review.  
229 All FCA cases were reviewed for the typical signs of dissections like ectasia, fusiform  
230 aneurysm, intimal flap, intramural hematoma or pseudoaneurysms. Consistent with the  
231 literature, history of head trauma was considered to support diagnosis of FCA-d.<sup>1</sup> The  
232 presence of multiple lesions (as typical for PC cases) makes the diagnosis of a dissection very  
233 unlikely. Additionally, all lesions in our cases are localized in the typical region of the  
234 wandering of virus along sympathetic and sensory fibers as discussed before. In the cases  
235 affecting the BA the length of the lesion present is very atypical for an intracranial dissection.  
236 Considering all these points, we are convinced that our 7 cases in the posterior circulation are  
237 in fact FCA-i and with a high degree of confidence not FCA-d.  
238 Concerning the difficulty of making a diagnosis of FCA-i we conclude that vessel wall  
239 imaging is needed if FCA-i is suspected, and special attention should be paid to the  
240 localization and the presence of multiple lesions.

241 Only one of our cases was associated with Lyme neuroborreliosis (LNB) and affected solely  
242 the PC, as most of the cases reported in the literature.<sup>11</sup> Notably, this patient (case 25, STable  
243 2) presented with mild symptoms only, but imaging studies revealed involvement of multiple  
244 arteries of the PC. This is in line with the pathophysiological hypothesis that the family  
245 Spirochaetaceae may induce perivascular inflammation rather than transport of infectious  
246 triggers via nerve fibers to vessels. A synopsis of published cases of LNB associated with  
247 pediatric stroke<sup>11</sup> and our data strongly suggest that testing for LNB should be performed in  
248 cases of FCA-i- especially affecting the PC and multiple arterial segments.

249 Regarding treatment, intravenous thrombolysis was more often performed when the PC was  
250 affected, reflecting the severity of the acute disease, especially when BA was involved. Due  
251 to lack of randomized controlled trials on recanalization therapy in children with AIS,  
252 recommendations rely mainly on expert opinion.<sup>40</sup> In the treatment of FCA-i, we consider  
253 that mechanical thrombectomy should be indicated very cautiously and only in selected  
254 patients with major vessel occlusion (e.g., carotid-T or M1). Interventions in vessels with  
255 underlying vessel wall inflammation may lead to unsuccessful recanalization and/or  
256 periprocedural complications. Intravenous or intraarterial thrombolysis (distant to local  
257 lesion) should be preferred over thrombectomy.

258 Median PSOM after 6 and 12 months was higher in the posterior group in our sample (Table  
259 1), but the difference did not reach statistical significance, presumably due to the  
260 underpowered nature of the study. The median PSOM was 1 in cases of AC- and PC-FCA-i.  
261 This is in line with the original VIPS study.<sup>41</sup>

262 To score the extent of arteriopathy in the PC, we adapted the FCASS to fit PC-FCA. A  
263 validation of the posterior FCASS is not possible due to the small number of cases but would  
264 be desirable with a larger number of patients.

265 Previous FCASS studies have reported a positive correlation between infarct size and  
266 FCASS. The original FCASS study also found a correlation between higher 1-year PSOM  
267 and greater maximum FCASS, which could not be replicated in the Swiss study.<sup>16</sup>

268 We found no correlation between infarct size and FCASS or between PSOM and FCASS in  
269 cases involving the PC. Part of the explanation may be the different association between  
270 infarct size and clinical outcome in PC due to anatomical features and different dimensions.  
271 Further, the small sample size may well have prevented detection of possible correlations.

272 The most important limitation of our study is the small sample size, which makes comparison  
273 and correlation difficult. Even over this large time span, only a few cases of FCA-i within the  
274 PC were registered in Switzerland.

275 Because of the small sample size, significance levels must be interpreted with caution.  
276 However, we still consider our sample representative. Given the acquisition process and the  
277 well-established status of the SNPSR, we are convinced that most cases of childhood AIS  
278 during this time would have been captured. Thus, the conclusions drawn from our study still  
279 provide a solid basis for clinical decisions, highlighting the need for prospective randomized  
280 trials, especially regarding treatment regimens.

281 Another limitation is the lack of standardized guidelines for follow-up imaging. Since this is  
282 a retrospective analysis of a population-based registry and the patients were recruited over a  
283 long period of time, the availability of imaging studies and the imaging protocols have  
284 changed and differ between cases. To appreciate vessel wall enhancement, dedicated VWI is  
285 crucial, but was performed at presentation in only a minority of cases. According to the  
286 imaging recommendations, VWI is not necessarily performed in the acute setting<sup>42</sup> although  
287 it can differentiate between the types of FCA.



288 We conclude that FCA-i occurs in the PC alone or in combination with FCA-i in the AC,  
289 although less often than isolated AC involvement. Thus, further studies in this field should  
290 consider including cases of FCA-i in PC. Children with posterior FCA-i present more often  
291 with non-specific symptoms. The modified FCASS may well serve as a marker for the  
292 evolution of disease but needs validation in another cohort. VWI is crucial in evaluating  
293 children presenting with PC stroke and should be included in stroke protocols.

## **Acknowledgements**

We thank all participants of the Swiss NeuroPaediatric Stroke Registry as well as their parents.

We thank Heather J Fullerton (UCSF) for her valuable input in the discussion and Mr. Charles Grose from University of Iowa Hospital, Iowa City to point our interest to the explanations of localizations of FCA-i; all the coworkers of the SNPSR: Andrea Capone Mori (Aarau), Alexandre Datta (Basel), Joël Fluss (Geneva), Annette Hackenberg (Zürich), Elmar Keller (Chur), Oliver Maier (St. Gallen), Jean-Pierre Marcoz (Sion), Claudia Poloni (Lausanne), Gian Paolo Ramelli (Bellinzona), Regula Schmid (Winterthur), and Thomas Schmitt-Mechelke (Lucerne).

## **Sources of Funding**

The work within the Swiss Neuropaediatric Stroke Registry (SNPSR) has been supported by Novartis Research Foundation, Swiss Heart Foundation, Foundation for neuropsychiatric research, Fondazione Ettore e Valeria Rossi, Anna Mueller Grocholski Stiftung, batzefür Kinderkliniken Bern.

## **Disclosures**

The authors report no other financial disclosures relevant to the manuscript.

## **Supplemental Material**

- Supplemental Table S1a: Extended FCASS for the anterior and posterior circulation
- Supplemental Table S1b. Modified Bernese Posterior Stroke Score
- Supplemental Table S1c. Modified pedASPECTS
- Supplemental STable 2: Detailed Results
- Supplemental SFigure 1. Example of acute imaging in strictly posterior involvement

## References

1. Wintermark M, Hills NK, DeVeber GA, Barkovich AJ, Bernard TJ, Friedman NR, et al. Clinical and Imaging Characteristics of Arteriopathy Subtypes in Children with Arterial Ischemic Stroke: Results of the VIPS Study. *American Journal of Neuroradiology* 2017;38:2172–2179.
2. Chabrier S, Rodesch G, Lasjaunias P, Tardieu M, Landrieu P, Sébire G. Transient cerebral arteriopathy: A disorder recognized by serial angiograms in children with stroke. *J Child Neurol* 1998;13:27–32.
3. Sébire G, Fullerton H, Riou E, DeVeber G. Toward the definition of cerebral arteriopathies of childhood. *Curr Opin Pediatr* 2004;16:617–22.
4. Sébire G, Meyer L, Chabrier S. Varicella as a risk factor for cerebral infarction in childhood: A case-control study. *Ann Neurol* 1999;45:679–680.
5. Berger TM, Caduff JH, Gebbers JO. Fatal varicella-zoster virus antigen-positive giant cell arteritis of the central nervous system. *Pediatric Infectious Disease Journal* 2000;19:653–656.
6. Elkind MSV, Hills NK, Glaser CA, Lo WD, Amlie-Lefond C, Dlamini N, et al. Herpesvirus Infections and Childhood Arterial Ischemic Stroke: Results of the VIPS Study. *Circulation* 2016;133:732–741.
7. Ganesan V, Prengler M, McShane MA, Wade AM, Kirkham FJ. Investigation of risk factors in children with arterial ischemic stroke. *Ann Neurol* 2003;53:167–173.
8. Monteventi O, Chabrier S, Fluss J. Prise en charge diagnostique et thérapeutique actuelle des accidents vasculaires cérébraux post-varicelleux chez l'enfant: Revue de la littérature. *Archives de Pédiatrie* 2013;20:883–889.

9. Piccolo B, Barsacchi M, Greco F, Cerasti D, Ormitti F, Pisani F. Transient posterior cerebral arteriopathy: An unusual case enterovirus-related. *Brain Dev* 2019;41:214–216.
10. Socan M, Ravnik I, Bencina D, Dovc P, Zakotnik B, Jazbec J. Neurological Symptoms in Patients Whose Cerebrospinal Fluid Is Culture- and/or Polymerase Chain Reaction-Positive for *Mycoplasma pneumoniae*. *Clinical Infectious Diseases* 2001;32:e31–e35.
11. Monteventi O, Steinlin M, Regényi M, Roulet-Perez E, Weber P, Fluss J. Pediatric stroke related to Lyme neuroborreliosis: Data from the Swiss NeuroPaediatric Stroke Registry and literature review. *European Journal of Paediatric Neurology* 2018;22:113–121.
12. Amlie-Lefond C, Bernard TJ, Sébire G, Friedman NR, Heyer GL, Lerner NB, et al. Predictors of Cerebral Arteriopathy in Children With Arterial Ischemic Stroke. *Circulation* 2009;119:1417–1423.
13. Braun KPJ, Bulder MMM, Chabrier S, Kirkham FJ, Uiterwaal CSP, Tardieu M, et al. The course and outcome of unilateral intracranial arteriopathy in 79 children with ischaemic stroke. *Brain* 2009;132:544–557.
14. Fullerton HJ, Stence N, Hills NK, Jiang B, Amlie-Lefond C, Bernard TJ, et al. Focal Cerebral Arteriopathy of Childhood: Novel Severity Score and Natural History. *Stroke* 2018;49:2590–2596.
15. Steinlin M, Bigi S, Stojanovski B, Gajera J, Regényi M, El-Koussy M, et al. Focal Cerebral Arteriopathy: Do Steroids Improve Outcome? *Stroke* 2017;48:2375–2382.
16. Slavova N, Fullerton HJ, Hills NK, Breiding PS, Mackay MT, Steinlin M. Validation of the focal cerebral arteriopathy severity score (FCASS) in a Swiss cohort:

- Correlation with infarct volume and outcome. *European Journal of Paediatric Neurology* 2020;28:58–63.
17. Ganesan V, Kirkham FJ. Mechanisms of ischaemic stroke after chickenpox. *Arch Dis Child* 1997;76:522–525.
  18. Shuper A, Vining EPG, Freeman JM. Central nervous system vasculitis after chickenpox - Cause or coincidence? *Arch Dis Child* 1990;65:1245–1248.
  19. Sträter R, Becker S, Von Eckardstein A, Heinecke A, Gutsche S, Junker R, et al. Prospective assessment of risk factors for recurrent stroke during childhood - A 5-year follow-up study. *Lancet* 2002;360:1540–1545.
  20. Helmuth IG, Mølbak K, Uldall PV, Poulsen A. Post-varicella Arterial Ischemic Stroke in Denmark 2010 to 2016. *Pediatr Neurol* 2018;80:42–50.
  21. Fink M, Slavova N, Grunt S, Perret E, Regényi M, Steinlin M, et al. Posterior Arterial Ischemic Stroke in Childhood. *Stroke* 2019;50:2329–2335.
  22. Steinlin M, Pfister I, Pavlovic J, Everts R, Boltshauser E, Mori AC, et al. The first three years of the Swiss Neuropaediatric Stroke Registry (SNPSR): A population-based study of incidence, symptoms and risk factors. *Neuropediatrics* 2005;36:90–97.
  23. Miravet E, Danchaivijitr N, Basu H, Saunders DE, Ganesan V. Clinical and radiological features of childhood cerebral infarction following varicella zoster virus infection. *Dev Med Child Neurol* 2007;49:417–422.
  24. MacKay MT, Wiznitzer M, Benedict SL, Lee KJ, Deveber GA, Ganesan V. Arterial ischemic stroke risk factors: The international pediatric stroke study. *Ann Neurol* 2011;69:130–140.

25. Pavlovic J, Kaufmann F, Boltshauser E, Capone Mori A, Gubser Mercati D, Haenggeli CA, et al. Neuropsychological problems after paediatric stroke: Two year follow-up of Swiss children. *Neuropediatrics* 2006;37:13–19.
26. Rafay MF, Shapiro KA, Surmava AM, deVeber GA, Kirton A, Fullerton HJ, et al. Spectrum of cerebral arteriopathies in children with arterial ischemic stroke. *Neurology* 2020;94:e2479–e2490.
27. Kitchen L, Westmacott R, Friefeld S, MacGregor D, Curtis R, Allen A, et al. The pediatric stroke outcome measure: A validation and reliability study. *Stroke* 2012;43:1602–1608.
28. Barber PA, Demchuk AM, Zhang J, Buchan AM. Validity and reliability of a quantitative computed tomography score in predicting outcome of hyperacute stroke before thrombolytic therapy. *The Lancet* 2000;355:1670–1674.
29. Beslow LA, Vossough A, Dahmouh HM, Kessler SK, Stainman R, Favilla CG, et al. Modified pediatric ASPECTS correlates with infarct volume in childhood arterial ischemic stroke. *Front Neurol* 2012;JUL.
30. Mackay MT, Slavova N, Pastore-Wapp M, Grunt S, Stojanovski B, Donath S, et al. Pediatric ASPECTS predicts outcomes following acute symptomatic neonatal arterial stroke. *Neurology* 2020;94:e1259–e1270.
31. Karameshev A, Arnold M, Schroth G, Kappeler L, Stein P, Gralla J, et al. Diffusion-Weighted MRI Helps Predict Outcome in Basilar Artery Occlusion Patients Treated with Intra-Arterial Thrombolysis. *Cerebrovascular Diseases* 2011;32:393–400.
32. Bundesamt für Statistik.  
<https://www.bfs.admin.ch/bfs/de/home/statistiken/bevoelkerung.html>. Accessed June 27, 2019.

33. von Elm E, Altman D, Egger M, Pocock S, Gotsche P, Vandenbroucke J. The Strengthening the Reporting of Observational Studies in Epidemiology (STROBE) Statement: guidelines for reporting observational studies. 2020.
34. Steinlin M, O’callaghan F, Mackay MT. Planning interventional trials in childhood arterial ischaemic stroke using a Delphi consensus process. *Dev Med Child Neurol* 2017;59:713–718.
35. Mackay MT, Prabhu SP, Coleman L. Childhood Posterior Circulation Arterial Ischemic Stroke. *Stroke* 2010;41:2201–2209.
36. Goeggel Simonetti B, Rafay MF, Chung M, Lo WD, Beslow LA, Billingham LL, et al. Comparative study of posterior and anterior circulation stroke in childhood: Results from the International Pediatric Stroke Study. *Neurology* 2020;94:e337–e344.
37. Grose C, Shaban A, Fullerton HJ. Common Features Between Stroke Following Varicella in Children and Stroke Following Herpes Zoster in Adults : Varicella-Zoster Virus in Trigeminal Ganglion. *Curr Top Microbiol Immunol* 2023;438:247–272.
38. Simons T, Ruskell GL. Distribution and termination of trigeminal nerves to the cerebral arteries in monkeys. *J Anat* 1988;159:57.
39. Arbab MAR, Wiklund L, Svendgaard NA. Origin and distribution of cerebral vascular innervation from superior cervical, trigeminal and spinal ganglia investigated with retrograde and anterograde WGA-HRP tracing in the rat. *Neuroscience* 1986;19:695–708.
40. Sporns PB, Fullerton HJ, Lee S, Kim H, Lo WD, Mackay MT, et al. Childhood stroke. *Nat Rev Dis Primers* 2022;8.
41. Fullerton HJ, Stence N, Hills NK, Jiang B, Amlie-Lefond C, Bernard TJ, et al. Focal Cerebral Arteriopathy of Childhood. *Stroke* 2018;49:2590–2596.

42. Mirsky DM, Beslow LA, Amlie-Lefond C, Krishnan P, Laughlin S, Lee S, et al.  
Pathways for Neuroimaging of Childhood Stroke. *Pediatr Neurol* 2017;69:11–23.



**Table 1 Summarized baseline characteristics of the patients**

<b>Inclusion criteria</b>	<b>Anterior circulation FCA-i [N = 24]</b>	<b>Posterior circulation FCA-i [N = 7]</b>	<b>Differences between anterior and posterior FCA-i, p-values</b>	<b>Both anterior and posterior circulation FCA-i [N = 5]</b>	<b>Difference between anterior and posterior FCA-i versus FCA-i in both circulations, p-values</b>
Typical course of FCA, N(%)	18 (75.0)	6 (85.7)	0.51 (0.01-5.79, p=1)*	5 (100.0)	Inf (0.21-inf, p=0.559)*
Vessel wall enhancement, N(%)	6 (25.0)	0 (0.0)	Inf (0.35-inf, p=0.292)*	1 (20.0)	1.04 (0.02-13.50, p=1)*
Proven infection†, N(%) History of infection present in 36/36	13 (54.2)	3 (42.9)	1.55 (0.21–13.00, p=0.69)*	4 (80.0)	3.63 (0.31-196.54, p=0.350)*
<b>Demographic characteristics</b>					
Age, y, median (IQR)	6.4 (2.5–8.6)	6.7 (5.7–8.0)	0.56 (–2.2–4.0, p=0.586)‡	2.9 (1.7–6.3)	2.60 (–2.0–5.40, p=0.410)‡
Male, N(%)	13 (54.2)	4 (57.1)	0.88 (0.11–6.58, p=0.889)*	4 (80.0)	3.20 (0.27–173.4, p=0.376)
<b>Symptoms at presentation</b>					
pedNIHSS, median (IQR)	4.5 (2.0–8.0)	8.0 (5.0–18.0)	4.00 (–2.00–14.00, p=0.162)‡	6.0 (6.0–6.0)	–1.00 (–4.0–4.0, p=0.854)‡
Hemiparesis, N(%)	20 (83.3)	4 (57.1)	3.56 (0.38–32.77, p=0.302)*	4 (80.0)	1.16 (0.09–65.53, p=1)*
Quadriparesis, N(%)	0 (0.0)	2 (28.6)	0 (0–1.44, p=0.045)*	0 (0.0)	0 (0–35.53, p=1)*

Facial palsy	19 (79.2)	2 (28.6)	8.65 (1.04–117.05, p=0.021)*	4 (80.0)	1.87 (0.16–102.99, p=1)*
Altered consciousness	5 (20.8)	3 (42.9)	0.365 (0.04–3.31, p=0.336)*	0 (0.0)	0 (0–2.87, p=0.566)*
Headache	6 (25.0)	7 (100.0)	0 (0–0.33, p=0.001)*	2 (40.0)	0.93 (0.07–9.33, p=1)*
Nausea/vomiting	8 (33.3)	5 (71.4)	0.21 (0.02–1.64, p=0.099)*	1 (20.0)	0.36 (0.01–4.17, p=0.628)*
Ataxia	1 (4.2)	2 (28.6)	0.12 (0.00–2.71, p=0.12)*	0 (0.0)	0 (0–16.87, p=1)*
Vertigo	2 (8.3)	2 (28.6)	0.24 (0.01–4.07, p=0.21)*	0 (0.0)	0 (0–10.74, p=1)*
Seizure	4 (16.7)	2 (28.6)	0.51 (0.05–7.19, p=0.596)*	1 (20.0)	1.04 (0.02–13.50, p=1)*
Fever	2 (8.3)	1 (14.3)	0.56 (0.02–37.49, p=0.557)*	0 (0.0)	0 (0–16.87, p=1)*
<b>Association with infections</b>					
VZV within previous 12 months, N(%)	14 (58.3)	2 (28.6)	3.36 (0.44–42.07, p=0.230)*	3 (60.0)	1.39 (0.14–18.90, p=1)*
Borrelia burgdorferi, N(%)	0 (0.0)	1 (14.3)	0 (0–11.38, p=1)*	0 (0.0)	0 (0–240.89, p=1)*
Other infections, N(%)	9 (37.5)	4 (57.1)	0.46 (0.05–3.43, p=0.413)*	2 (40.0)	0.93 (0.07–9.33, p=1)*
<b>Treatment</b>					
ASA monotherapy, N(%)	9 (37.5)	2 (28.6)	0.95 (0.13–8.00, p=1)*	1 (20.0)	0.36 (0.01–4.17, p=0.628)*
Combinations, N(%)	14 (58.3)	2 (28.6)	3.36 (0.44–42.07,	4 (80.0)	3.63 (0.31–196.54,

			p=0.220)*		p=0.355)*
ASA + Heparin/LMWH, N(%)	1 (4.2)	1 (14.3)	0.41 (0.00–23.86, p=0.41)*	0 (0.0)	0 (0–35.53, p=1)*
ASA + steroids, N(%)	3 (12.5)	1 (14.3)	0.86 (0.06–52.41, p=1)*	2 (40.0)	4.25 (0.28–51.96, p=0.186)*
ASA + acyclovir, N(%)	3 (12.5)	0 (0.0)	Inf (0.11–inf, p=1)*	0 (0.0)	0 (0–16.87, p=1)*
ASA + steroids + acyclovir, N(%)	6 (25.0)	0 (0.0)	Inf (0.35–inf, p=0.203)*	1 (20.0)	1.04 (0.02–13.50, p=1)*
ASA + heparin/LMWH + steroids + acyclovir, N(%)	0 (0.0)	0 (0.0)	-	1 (20.0)	Inf (0.16–Inf, p=0.139)*
Heparin/LMWH + steroids, N(%)	1 (4.2)	0 (0.0)	Inf (0.01–inf, p=1)*	0 (0.0)	0 (0–240.89, p=1)*
IV lysis, N(%)	1 (4.2)	3 (42.9)	0.07 (0.00–1.05, p=0.027)*	0 (0.0)	0 (0–10.74, p=1)*
<b>Outcome</b>					
PSOM discharge, median(IQR)[N]	1.0 (0.5–2.0)[24]	1.0 (0.25–4.8)[7]	0.50 (–1.00–3.50, p=0.597)‡	1.0 (0.5–3.0)[5]	–0.00 (2.00–1.00, p=0.816)‡
PSOM 6 months, median(IQR)[N]	0.5 (0.0–1.0)[21]	1.5 (0.5–4.0)[7]	1.00 (–0.50–3.00, p=0.165)‡	1.5 (0.0–2.5)[5]	0.00 (–2.50–0.50, p=0.681)‡
PSOM 24 months, median(IQR)[N]	0.5 (0.0–1.0)[20]	1.25 (0.1–2.8)[6]	0.50 (–0.50–2.50, p=0.490)‡	0.5 (0.3–2.3)[3]	0.00 (–3.50–1.50, p=0.941)‡
Death, N(%)	0 (0.0)	0 (0.0)	–	0 (0.0)	–

Recurrence, N(%)	1 (4.2)	1 (14.3)	0.28 (0.00–23.86, p=0.406)*	0 (0.0)	0 (0–35.53, p=1)*
------------------	---------	----------	-----------------------------	---------	-------------------

FCA = focal cerebral arteriopathy; y = years; IQR = interquartile range; pedNIHSS = pediatric National Institutes of Health Stroke Scale; ASA = acetyl salicylic acid; LMWH = low-molecular-weight heparin; PSOM = pediatric stroke outcome measure; Inf = infinity; VSV = varicella-zoster virus.

\*Fisher's exact test: OR (95% confidence interval, two tailed p-value). †By serology or PCR. Wilcoxon Rank Sum test: difference in location (95% confidence interval, tow tailed p-value).

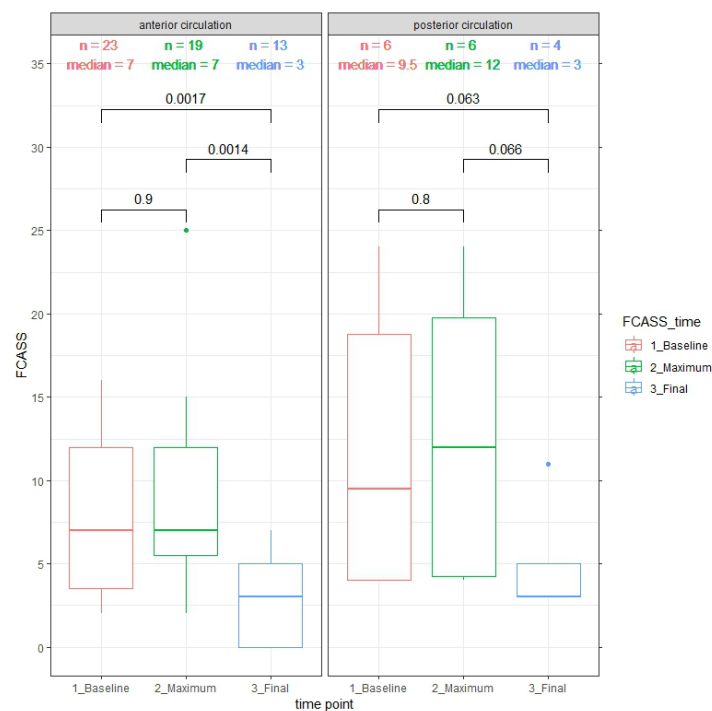
**Table 2 Focal Cerebral Arteriopathy Severity Score (FCASS) summary at different time points**

	Posterior circulation		Anterior circulation	
	Time after stroke in days, median (IQR),[N]	Score, median (IQR)	Time after stroke in days, median (IQR),[N]	Score, median (IQR)
FCASS baseline	1.0 (0.25–13.0),[6]	9.5 (4.0–18.75)	1.0 (0.0–10.0),[23]	7.0 (3.5–12.0)
FCASS maximum	15.5 (4.25–17.75),[6]	12.0 (4.25–19.75)	1.0 (1.0–7.5),[19]	7.0 (5.5–12.0)
FCASS final	2098 (1592–2458),[4]	3.0 (3.0–5.0)	451 (226–1185),[13]	3.0 (0.0–5.5)

FCASS baseline = FCASS of the first available imaging after stroke; FCASS maximum = highest FCASS of all available imaging – only for those patients with serial neuroimaging; FCASS final = FCASS of last imaging – only if imaging more than 24 weeks post-stroke was available; IQR = interquartile range; N = number of available FCASS in this group.

## Figures

Figure 1: Baseline maximum and final FCAS-Score



Comparison by Wilcoxon rank sum and signed rank test; 2-sided p-value indicated.

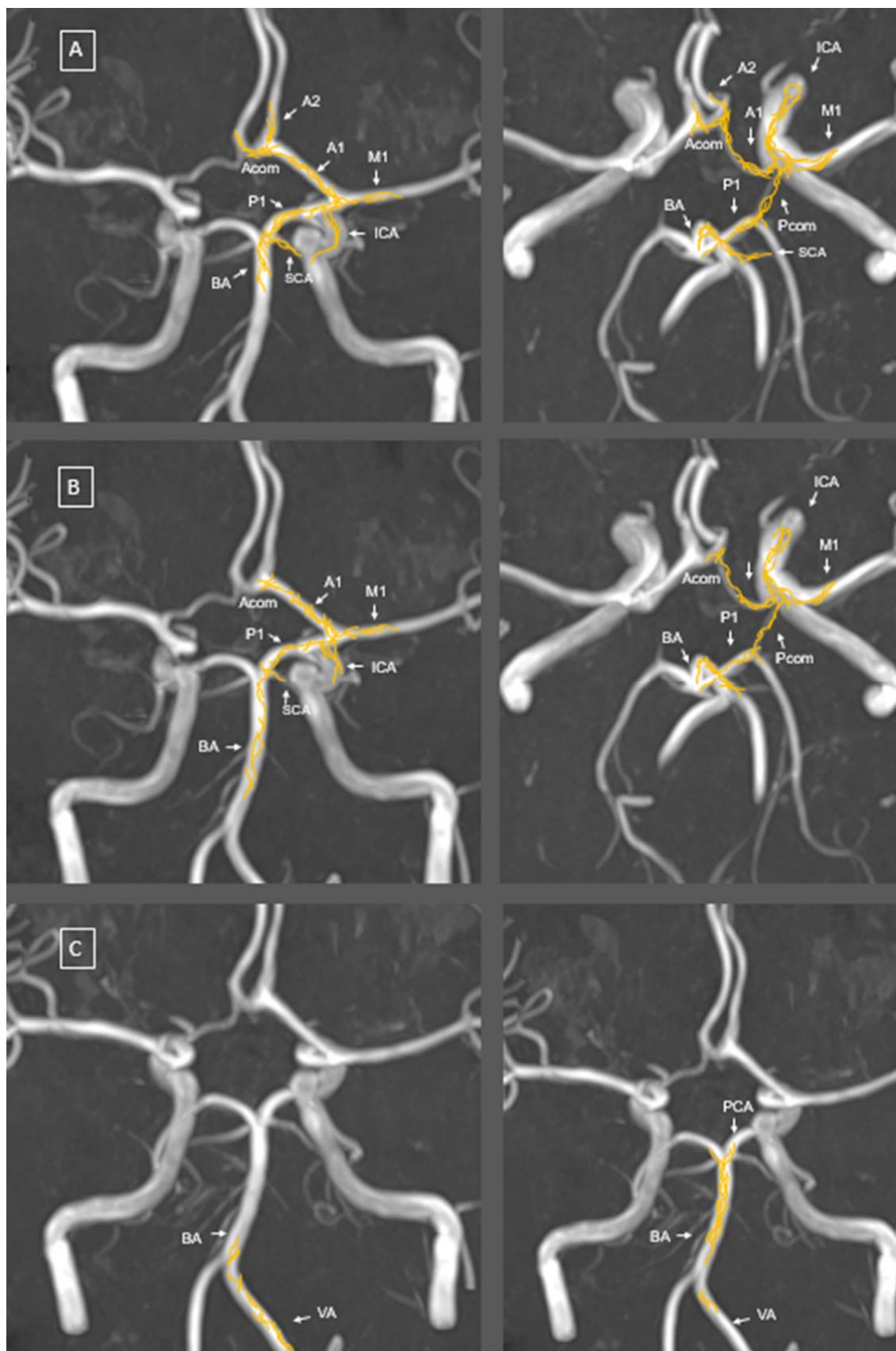


Figure 2. Schematic representation of nerve fibre distribution

Adapted from Arbab et al. using neuroanatomical tracing techniques after tracer injection into

A) the trigeminal ganglion, B) the superior cervical ganglion and C) first (left image) and second (right image) spinal ganglia. The distribution of the anterogradely labelled nerve fibres (in yellow) was mapped on time-of-flight magnetic resonance angiography (MRA) maximum intensity projection (MIP) reconstruction imaging of the cerebral blood vessels.

ACA, anterior cerebral artery; Acom, anterior communicating artery; BA, basilar artery; ICA, internal carotid artery; MCA, middle cerebral artery; PCA, posterior cerebral artery; Pcom, posterior communicating artery; SCA, superior cerebellar artery; VA, vertebral artery.